

Available online at www.sciencedirect.com

SciVerse ScienceDirect

British Journal of Oral and Maxillofacial Surgery xxx (2015) xxx–xxx

BRITISH
Journal of
Oral and
Maxillofacial
Surgerywww.bjoms.com

Facial injuries in Iranian veterans during the Iraq–Iran war (1980–88): differences from recent conflicts

M.H. Khosravi^{a,*}, A. Akhavan^b^a Students' Research Committee, Baqiyatallah University of Medical Sciences, Tehran, Islamic Republic of Iran^b Department of Otorhinolaryngology, Faculty of Medicine, Baqiyatallah University of Medical Sciences, Tehran, Islamic Republic of Iran

Accepted 19 June 2015

Abstract

Our aim was to identify the pattern and mechanism of facial injuries in Iranian veterans during the Iraq–Iran war and to assess the effectiveness of current protective equipment by retrospectively evaluating 100 Iranian veterans of that war. We randomly included veterans with injuries to various parts of the face, with or without injuries to other organs. None died. We recorded anatomical distribution, incidence, and mechanism of injury as well as injury scores using common references scales. Data are expressed as mean (SD) or number. Fragmentation injuries were the most common ($n = 40$) followed by blast ($n = 37$), shock wave ($n = 18$), and gunshots ($n = 5$). Thirty-five patients had mandibular fractures with a mean (SD) score of 3.7 (1.4). Fifteen patients had injuries to the upper face and 79 to the midface. Twenty-four patients had facial lacerations more than 10 cm long, with a mean facial injury score of 2.4 (2.0). Nineteen had ocular injuries with a mean (SD) ocular trauma score of 64.9 (12.9). Despite recent developments in protective equipment we have seen no significant reduction in the incidence of facial injuries in battle, which could indicate that we need better facial support equipment and more effective education in its use. However, using protective equipment such as goggles and a mandibular protector is highly recommended.

© 2015 The British Association of Oral and Maxillofacial Surgeons. Published by Elsevier Ltd. All rights reserved.

Keywords: Facial injuries; Mandibular fracture; Iraq–Iran conflict; Ocular injuries

Introduction

Facial injuries are a combination of injuries to the eyes and upper third of the face together with maxillofacial injuries that range from superficial lacerations or abrasions to multiple fractures of the middle or lower third of the facial skeleton.¹

With all the recent progress in the weapon industries and the changing face of modern warfare, there is a need for better protection, devices, and education in military systems. These developments have changed the range of war injuries and also made the previous armour and protection less efficient. Recent publications have reported an increasing trend

in injuries to the head, face, and neck during the 20th and 21st centuries with an incidence of 21% and 39% among US and UK forces,^{2,3} which is a result of improved thoracoabdominal protection and the changed pattern of war injuries as a result of the introduction of improvised explosive devices.²

Assessment of the distribution of war injuries and their related mechanisms could enable us to lower the risks and expenses of war injuries, as well as the mortality. Facial injuries are most important among battle-related injuries because of their dramatic impressions on survival, quality of life, and cosmesis. Previous studies have regarded protection of vulnerable areas of the face as important, as they were responsible for many deaths of servicemen.^{2–5}

The Iraq–Iran conflict (1980–1988), during which more than 800 000 people were injured, is a useful source for evaluating the characteristics of war injuries and effectiveness of

* Corresponding author at: Baqiyatallah Hospital, Mollasadra st., Vanaq sq., Tehran, Islamic Republic of Iran. Tel.: +98 2188620826; fax: +98 2188620826.

E-mail address: dr.mhkhosravi@gmail.com (M.H. Khosravi).

<http://dx.doi.org/10.1016/j.bjoms.2015.06.021>

0266-4356/© 2015 The British Association of Oral and Maxillofacial Surgeons. Published by Elsevier Ltd. All rights reserved.

previous methods of protection. Few statistics are available about the range of facial injuries during that war, so we aimed to assess the pattern and severity of facial injuries in Iranian veterans and to compare them with those in recent conflicts to find out how effective current protective equipment is.

Materials and methods

The study was approved by the ethics committee of Baqiyatallah University of Medical Sciences, and we followed the guidelines of the Helsinki declaration. In this descriptive study we have retrospectively studied 100 male Iranian veterans who developed facial injuries during the Iraq–Iran conflict. We randomly selected them from nearly 5000 veterans with profiles in the Iranian Commission of Injured Troops. We included those with injuries to various parts (upper face, midface, and lower face) and elements of the face (eyes, bones, teeth, and nerves) whether or not they had injuries to other organs and extremities. Veterans who had injuries only to the eye as a result of chemical weapons were excluded. No patient died.

Fractures were diagnosed on plain radiographs at the time of admission to military hospitals, and confirmed by orthopantomogram, posteroanterior views of the skull, lateral and lateral oblique views for the mandible, occipitomeatal views for midfacial injuries and fractures of the sinuses, jughandle view for fractures of the zygomatic arch, and intraoral radiographs such as periapical and occlusal views for dentoalveolar injuries. After radiographic evaluation, patients were referred to an ophthalmologist, otorhinolaryngologist, or oral and maxillofacial surgeon for assessment of possible ocular, ENT, and dental injuries.

Data collected included age, anatomical distribution and incidence of facial injuries, and mechanisms of injury. The severity of injuries was evaluated and scored using scoring methods used in military hospitals: fracture score for mandibular fractures,⁶ facial injury severity scale,⁷ ocular trauma score,⁸ classification of dental injuries based on World Health Organization (WHO), and the House–Brackmann severity scale for injuries to the facial nerve.⁹

The scoring system for mandibular fractures takes account of the preoperative anatomical site of fracture, amount of displacement, complexity of fracture, together with operative systemic factors such as difficult positioning and reduction, undefined occlusion, and difficult soft tissue coverage. The minimum score for a single fracture is 0 and the maximum is 15. The higher the score, the more severe the fracture.⁶ The facial injury severity score includes facial laceration and injury to the upper, lower, and midface. The minimum score is 0, the maximum is influenced by the total number of fractures, and the maximum reported by Bagheri et al. was 13.⁷

The ocular trauma score considered initial vision and complications. The minimum score is -15 and the maximum is 100. The higher the score the better the condition of the

eye. The House–Brackmann severity grades for injury to the facial nerve are based on facial appearance and movement; the higher the grade the worse the function of the nerve.

Data were analysed with the help of SPSS for Windows (version 16, SPSS Inc., Chicago, IL, USA), and are reported as mean (SD), or number.

Results

We studied 100 Iranian veterans with a mean age of 47 (10) years at the time of injury. Fragmentation was the most common mechanism of injury ($n = 40$) followed by blast injuries ($n = 37$). Only 18 of the facial injuries were caused by shock waves alone, whereas gunshots were responsible for 5. In 15 patients the upper third of the face was injured, with the middle and lower thirds involving 79 and 35, respectively. Some had combined injuries that involved 2 or 3 thirds of the face.

Thirty-five patients had mandibular fractures with a mean (SD) severity score of 3.7 (1.4); this was the most common injury to the facial skeleton. The molar region of the mandible had the highest rate of injury ($n = 15$), followed by the ramus, the symphysis, the angle, and the premolar region (Fig. 1). Of these, 20 had serious, and 15 had minor, fractures. None required repositioning or reduction, there was no difficulty in covering the soft tissue, and there were no complex fractures. Four had undefined occlusions, 2 minor and 2 major. Few complications were recorded: 13 in the temporomandibular joint (TMJ), plus 2 of malocclusion, and 2 of disturbed wound healing.

Ninety-one patients had a mean (SD) facial injury severity score of 2.4 (2.0); in 9 it was zero. Most patients ($n = 76$) had facial lacerations equal to or less than 10 cm long; in others they were longer. Six had orbital fractures, and 5 had displaced, and 10 non-displaced, fractures of the frontal sinus. Dentoalveolar injuries of maxilla and mandible were reported in 43 and 42 patients, respectively, and only one had a unilateral type II Le Fort fracture. Naso-orbitoethmoid fractures were recorded in only 3 cases, while fractures of the

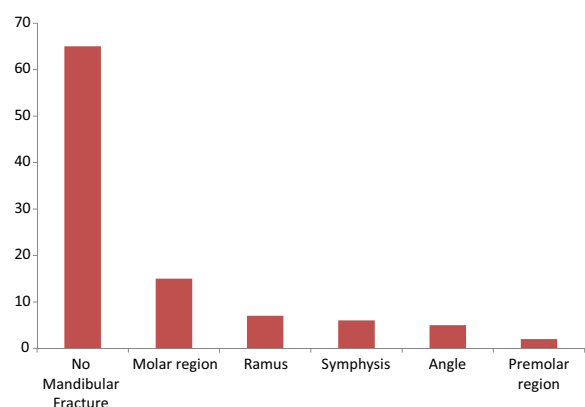


Fig. 1. Distribution and anatomical site of mandibular fractures.

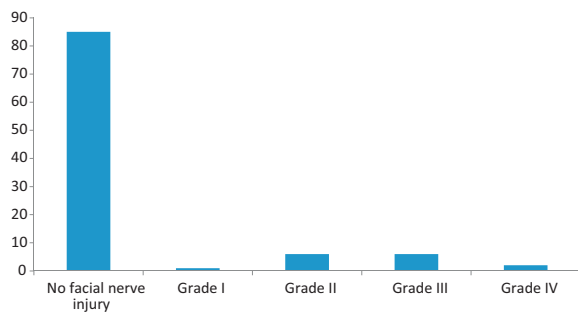


Fig. 2. Injuries to the facial nerve according to the House–Brackmann severity scale.⁹

zygomaticomaxillary complex were more common ($n = 22$). Nasal fracture alone had the same incidence.

The mean (SD) ocular trauma score was 64.9 (12.9) for the 19 veterans with injured eyes, 8 of whom had ruptured the globe. There was no record of afferent pupillary defect or endophthalmitis. Eleven had retinal detachment and 2 a perforating injury. All 81 of those without eye injuries had a best-corrected visual acuity of better than 20/40. Of the 19 injured, 2 had no perception of light, 2 had perception of light or hand movements only, and 5 each had visual acuity better than 20/40, 20/50 to 20/200, or 19/200 to 1/100. In three cases both eyes were injured.

The mean (SD) total number of damaged teeth was 9 (8)/61 patients, and only one had fracture of the enamel of a tooth. A crown was fractured with pulpal involvement in 17, mean (SD) score 4.2 (4.8), and in 4 cases without pulpal involvement with a mean of 7.4 (6.2). Two patients had fractured roots, in 3 and 4 teeth each, but no patient had a crown-root fracture. Two reported one loose tooth each. Fifty-three patients had a total 452 avulsed teeth, mean (SD) 8.5 (7.5). The alveolar process was fractured in one case.

Fifteen patients injured the facial nerve: in one it was grade I, in 6 grade II, in 6 grade III, and in 2 grade IV (Fig. 2). The infraorbital nerve was injured in 17.

Discussion

Head, neck, and facial injuries (which make up only 12% of the body's surface) are some of the most important causes of mortality and morbidity.³ There has been a dramatic increase in such injuries reported from the Iraq and Afghanistan conflicts^{10–12} when compared with the 20th century, and Breeze et al. found an increasing trend in the proportion of maxillofacial injuries from 2005 to 2007 in British military personnel.¹³

Fragmentation injuries were the most common in Iranian veterans during the Iraq–Iran conflict, which confirms the study by Sadda who reported that fragmentation was responsible for 80% of maxillofacial injuries, followed by bullets (19.7%).¹⁴ Bullets and fragments of mortar shells

were the most common causes of maxillofacial injuries in the Iraq–Iran conflict according to Akhlaghi and Aframian-Farnad,¹⁵ and Will et al. reported that half the maxillofacial injuries in Iraq were caused by fragmentation after detonation of improvised explosive devices,¹⁶ which is in agreement with the study by Breeze et al about the Iraq and Afghanistan conflicts.¹⁷ Explosive injuries were also responsible for many craniomaxillofacial injuries.¹⁸

We found that the mandible was the most injured part of the facial skeleton in Iranian veterans. The body was the part affected most often, followed by the symphysis, and this again agrees with Sadda's study.¹⁴ Lew et al. (in a study on the battlefields of recent wars in Iraq and Afghanistan) also reported that the mandible was the part of the face most often injured, and they mentioned the prominence of the mandible in the facial skeleton together with the lack of protection as the main reasons.¹⁸ Sadda also reported pure mandibular fractures as the most common facial injuries in 40% of their patients.¹⁴ Khan et al. reported the mandible as the facial bone most often fractured in the armed forces in Pakistan, and they found that the body of mandible was the most involved part, followed by the angle.¹⁹

Ocular injury was recorded in 19 of our patients with a mean score of 64.9 (12.9), among whom 2 had no perception of light and 86 had corrected visual acuity of better than 20/40. Weichel et al. reported a mean (SD) ocular trauma score of 70 (25) in the recent Iraqi conflict, during which 42% of eyes achieved corrected visual acuity more than 20/40 and 32% had no perception of light.²⁰ Ari evaluated the eye injuries in the Iraqi and Afghanistan conflicts, and mentioned that the incidence of eye injuries in combat have increased over time,²¹ and that the most common causes were explosive devices. Lew et al. confirmed this, and mentioned the combined use of tactically-placed surgical units, rapid evacuation, and modern body armour as the main reasons.¹⁸

The Iraq–Iran conflict can be categorised as a “minor conventional war” based on Eiseman's classification, in that the more limited the war, the greater the probability of trauma to the head and face.²²

The use of helmets, face shields, or protective glasses has been recommended by Akhlaghi and Aframian-Farnad for reducing the amount and effect of head and facial trauma.¹⁵ It has been mentioned that personal protective equipment could protect infantry soldiers against fragmentation injuries — which were the major cause of facial injuries in our study — and that current items of protective clothing protect the eyes but not the remaining face.¹⁷ It should be mentioned that a simple helmet was the only protection that most of the Iranian veterans had during the Iraq–Iran conflict, which reflects the large number of facial (and particular mandibular) injuries. The newest British military prototypes are of a mandibular protector and protective glasses. Nearly all our dental injuries were associated with dentoalveolar injuries of the mandible and maxilla, so the use of mandibular protectors may reduce both the incidence of dental injuries and

of mandibular fractures. Many nerve injuries were associated with mandibular and midfacial injuries, and there could have been fewer of these if mandibular protectors had been worn.

Ari suggested that combat eye protection or goggles should be used to prevent eye injuries during battles, however not all could be prevented. Despite being a part of the personal protective equipment of the US and UK armies, goggles resulted in no appreciable reduction in eye injuries during recent conflicts in Iraq and Afghanistan, and while using them servicemen remained anonymous.²¹ No combat eye protection or goggles were used by Iranian veterans during Iraq–Iran conflicts.

Despite all the recent progress in weapons and military industry and the use of the newest protection methods and devices during recent decades, there has been no dramatic reduction in facial injuries during battle. This is confirmed by comparison of the characteristics of facial injuries in the Iraq–Iran conflict, with those reported from the recent Iraq and Afghanistan conflicts. This could indicate either that the current protective methods are of little use, or servicemen were not trained to use them properly.

In conclusion, the use of modern protective equipment such as goggles, mandibular protectors, and modern helmets is highly recommended, as is more effective education for servicemen on the importance of using protective equipment. Future studies should be organised about the effectiveness of military education on the importance of using protective equipment properly.

Conflict of interest

We have no conflicts of interest.

Ethics statement/confirmation of patients' permission

The study was approved by the ethics committee of the University of Medical Sciences. Patients' permission not required.

Acknowledgements

The authors would like to thank Dr. Keshavarz, head, and all the staff of the great commission of injured troops for their kind co-operation in providing related profiles.

References

1. Banks P. *Killey's fractures of the middle third of the facial skeleton*. 5th ed. Oxford: Butterworth Heinemann; 1988.
2. Xydakis MS, Fravell MD, Nasser KE, et al. Analysis of battlefield head and neck injuries in Iraq and Afghanistan. *Otolaryngol Head Neck Surg* 2005;**133**:497–504.
3. Wade AL, Dye JL, Mohrle CR, et al. Head, face, and neck injuries during Operation Iraqi Freedom. II: Results from the US Navy-Marine Corps Combat Trauma Registry. *J Trauma* 2007;**63**:836–40.
4. Ramasamy A, Harrison S, Lasrado I, et al. A review of casualties during the Iraqi insurgency 2006—a British field hospital experience. *Injury* 2009;**40**:493–7.
5. Blanch RJ, Scott RA. Military ocular injury: presentation, assessment and management. *J R Army Med Corps* 2009;**155**:279–84.
6. Joos U, Meyer U, Tkotz T, et al. Use of a mandibular fracture score to predict the development of complications. *J Oral Maxillofac Surg* 1999;**57**:2–5.
7. Bagheri SC, Dierks EJ, Kademani D, et al. Application of a facial injury severity scale in craniomaxillofacial trauma. *J Oral Maxillofac Surg* 2006;**64**:408–14.
8. Kuhn F, Maisiak R, Mann L, et al. The Ocular Trauma Score (OTS). *Ophthalmol Clin North Am* 2002;**15**:163–5.
9. House JW, Brackmann DE. Facial nerve grading system. *Otolaryngol Head Neck Surg* 1985;**93**:146–7.
10. Rustemeyer J, Kranz V, Bremerich A. Injuries in combat from 1982–2005 with particular reference to those to the head and neck: a review. *Br J Oral Maxillofac Surg* 2007;**45**:556–60.
11. Roberts P, editor. *The British military surgery pocket book*. London: British Army Publications; 2004.
12. Dobson JE, Newell MJ, Shepherd JP. Trends in maxillofacial injuries in war-time (1914–1986). *Br J Oral Maxillofac Surg* 1989;**27**:441–50.
13. Breeze J, Gibbons AJ, Opie NJ, et al. Maxillofacial injuries in military personnel treated at the Royal Centre for Defence Medicine June 2001 to December 2007. *Br J Oral Maxillofac Surg* 2010;**48**:613–6.
14. Sada RS. Maxillofacial war injuries during the Iraq–Iran War: an analysis of 300 cases. *Int J Oral Maxillofac Surg* 2003;**32**:209–14.
15. Akhlaghi F, Aframian-Farnad F. Management of maxillofacial injuries in the Iran–Iraq war. *J Oral Maxillofac Surg* 1997;**55**:927–31.
16. Will MJ, Goksel T, Stone Jr CG, et al. Oral and maxillofacial injuries experienced in support of Operation Iraqi Freedom I and II. *Oral Maxillofac Surg Clin North Am* 2005;**17**:331–9.
17. Breeze J, Gibbons AJ, Hunt NC, et al. Mandibular fractures in British military personnel secondary to blast trauma sustained in Iraq and Afghanistan. *Br J Oral Maxillofac Surg* 2011;**49**:607–11.
18. Lew TA, Walker JA, Wenke JC, et al. Characterization of craniomaxillofacial battle injuries sustained by United States service members in the current conflicts of Iraq and Afghanistan. *J Oral Maxillofac Surg* 2010;**68**:3–7.
19. Khan SU, Khan M, Khan AA, et al. Etiology and pattern of maxillofacial injuries in the armed forces of Pakistan. *J Coll Physicians Surg Pak* 2007;**17**:94–7.
20. Weichel ED, Colyer MH, Ludlow SE, et al. Combat ocular trauma visual outcomes during operations Iraqi and enduring freedom. *Ophthalmology* 2008;**115**:2235–45.
21. Ari AB. Eye injuries on the battlefields of Iraq and Afghanistan: public health implications. *Optometry* 2006;**77**:329–39.
22. Eiseman B. Casualty care planning. *J Trauma* 1979;**19**:848–51.