

Vegetative Endocarditis in Equids (1994–2006)

S.R. Porter, C. Saegerman, G. van Galen, C. Sandersen, C. Delguste, H. Guyot, and H. Amory

Background: Endocarditis is a rare heart condition with variable clinical expressions in equids. Risk factors for this disease are incompletely understood.

Objective: Describe risk factors for endocarditis in equids.

Animals: One hundred and fifty-three equids admitted to Liège University, 9 diagnosed with endocarditis and 144 free from endocarditis but admitted to the hospital with a differential diagnosis including this disease.

Methods: Retrospective case-control study.

Results: Equids with endocarditis were significantly younger (mean age = 4.84 ± 5.74 years) than control equids (mean age = 10.8 ± 7.73 years) ($P = .01$). No sex or breed predisposition was observed. Animals with hyperthermia (odds ratio [OR] = 24.4; confidence interval [CI] = 1.40–428), synovial distension (OR = 13.4; CI = 3.00–59.8), lameness (OR = 6.52; CI = 1.63–26.1), hyperglobulinemia (OR = 26.4; CI = 3.03–229), hypoalbuminemia (OR = 11.4; CI = 1.34–96.8), hyperfibrinogenemia (OR = 9.81; CI = 1.16–82.7), or leukocytosis (OR = 7.12; CI = 1.40–36.4) presented a significantly higher risk of having endocarditis than control horses. The presence of two of the clinical signs mentioned above significantly increased the probability of a diagnosis of endocarditis ($P \leq .05$).

Conclusions and Clinical Importance: Age is associated with equine endocarditis. The diagnostic value of certain clinical signs and abnormalities in blood parameters in this disease are described.

Key words: Case-control study; Clinical study; Equine; Exploratory factors; Valvulitis.

Bacterial endocarditis, also called vegetative or infective endocarditis, is a rare cardiac disease in equids.^{1–5} Two different forms of vegetative endocarditis can be distinguished: an acute form and a subacute or chronic form.^{1,6,7} Signs characterizing the acute form are pyrexia, depression, reluctance to move due to thoracic discomfort or lameness, and the rapid development of signs of cardiac insufficiency including edema and increased jugular filling.¹ In the subacute or chronic form, which is much more common, equids might have intermittent pyrexia, weight loss, shifting lameness, poor performance, lethargy/depression, a heart murmur, or a combination of these signs lasting for weeks or months.¹ Signs of cardiac failure usually occur only as a terminal event.¹ Although endocarditis is frequently associated with the presence of a heart murmur, this is not always the case.^{2,4–6,8} Vegetative endocarditis can also be associated with cardiac arrhythmias including atrial fibrillation and ventricular premature

beats.^{4,5,9} Atrial premature beats and ventricular tachycardia^{10–13} also occur, but less frequently.

Vegetative endocarditis^{2,8} can be suspected on the basis of history and physical examination but complementary examinations are required for definitive diagnosis. Echocardiography and electrocardiography can be useful in diagnosis, prognosis, and serial assessment of endocarditis by identifying anatomic lesions and characterizing arrhythmias.^{3,4,7,9} Echocardiography remains the most specific, but not highly sensitive, modality in diagnosis of endocarditis.^{1,6,9,14} Other complementary examinations can be useful in equids with manifestations of metastatic disease. Once established, the endocarditis lesion can release bacteria and emboli into the circulation, causing bacteremia, infarctions, and metastatic infections leading to secondary organ dysfunction.^{1,2,6–8,15} The infection stimulates the immune system causing the formation of immune complexes and secondary immune-mediated complications.^{1,2,4–7,15}

Vegetative endocarditis being an infection of the valvular endothelium by a specific microorganism, treatment logically consists of a high dose of bactericidal antibiotic, ideally based on the results of the blood culture and antibiogram^{1,4–7,9,16,17}, for a minimum period of 4–6 weeks.^{1,2,4–8,10,11,18} Resolution of clinical signs, improvement of echocardiographic findings, and reduction in leukocytosis and hyperfibrinogenemia should be used to evaluate the response and determine the duration of therapy.^{4,17} The prognosis is poor^{1,4–6,8} in all cases of infective endocarditis. Valvular insufficiency caused by vegetative endocarditis can remain despite reduction of the size and sterilization of the lesion.^{2,6} In addition, infarctions, metastatic infections, and financial limitations can also complicate treatment and affect prognosis.^{1,2,6} Because of the nonspecific signs associated with endocarditis, early detection of the disease is often difficult.² However, early initiation of aggressive therapy has been shown to greatly affect the final outcome.^{4,5,7} An early diagnosis is thus essential to succeed in treating a patient.^{4,5,7} A predisposition to infective endocarditis in

From the Equine Teaching Hospital, Department of Companion Animals and Equids Clinical Sciences, Faculty of Veterinary Medicine, University of Liège, Liège, Belgium (Porter, van Galen, Sandersen, Delguste, Amory); Department of Infectious and Parasitic Diseases, Faculty of Veterinary Medicine, Epidemiology and Risk Analysis applied to Veterinary Sciences, University of Liège, Liège, Belgium (Saegerman); and the Clinic for Ruminants, Clinical Department of Production Animals, Faculty of Veterinary Medicine, University of Liège, Liège, Belgium (Guyot). This study was performed at the Equine Teaching Hospital, Faculty of Veterinary Medicine, University of Liège, Liège, Belgium. The epidemiological and statistical analyses of data were performed at the Research Unit of Epidemiology and Risk Analysis applied to Veterinary Sciences, Faculty of Veterinary Medicine, University of Liège, Liège, Belgium.

Corresponding author: H. Amory, Equine Teaching Hospital, Department of Companion Animals and Equids Clinical Sciences, Faculty of Veterinary Medicine, University of Liège, Bat. B41, Sart-Tilman, 4000 Liège, Belgium; e-mail: helene.amory@ulg.ac.be.

Submitted October 27, 2007; Revised January 3, 2008; Accepted June 23, 2008.

Copyright © 2008 by the American College of Veterinary Internal Medicine

10.1111/j.1939-1676.2008.0192.x

young^{2,7,12,17}, male^{1,2,7,12} or both equids has been suggested by previous studies but contradictions between studies remain.¹⁷ No breed predisposition was obvious in a study of 10 cases.¹⁷

The purpose of this study was to determine the physical data, the clinical signs, the associations of the clinical signs, and the abnormal blood parameters, which should lead the practitioner to consider a potential diagnosis of infective endocarditis.

Materials and Methods

Case Definition

Each animal was identified by its physical description, its name, its microchip number if present, and name and address of owner. Each animal admitted to the Veterinary Teaching Hospital of Liège University was always registered under a specific unique file with a record number identifying the animal throughout its stay at the hospital.

The diagnosis of vegetative endocarditis was made by echocardiography or by postmortem examination for the animals included in the case group.

For the control group, animals were selected from the files of equids admitted to the Veterinary Teaching Hospital during the period from 1994 to 2006. Vegetative endocarditis had to be included in their initial differential diagnosis, based on history and physical examination, but its diagnosis was thereafter excluded on the basis of echocardiography and/or postmortem examination. The clinical signs on which was based the choice of including vegetative endocarditis in the differential diagnosis were the presence of one or more of the following signs: hyperthermia, tachycardia, heart murmur, tachypnea/dyspnea, depression, weight loss, lameness, neurological symptoms, synovial distension, poor body condition, intensity variation of peripheral pulse, recurrent/persistent anorexia or inappetence, and arrhythmia. These clinical signs were the most frequently reported signs in the cases of endocarditis admitted to Liège University and in cases of endocarditis in the scientific literature.^{1,6,9,10,11,16–33}

Animals

A total of 153 equids including horses, ponies, or donkeys were studied and consisted of 2 groups: a group of animals with endocarditis (case group, $n = 9$), and a group of control animals (control group, $n = 144$).

The case group included 9 cases (7 horses, 1 donkey, and 1 pony) suffering from vegetative endocarditis and admitted to the Veterinary Teaching Hospital of Liège University between 1994 and 2006.

The control group consisted of 144 cases (horses, ponies, or donkeys) that were admitted to the Veterinary Teaching Hospital of Liège University between 1994 and 2006.

Clinical Findings and Laboratory Analyses

For each animal included in this study, the description (breed, age, sex), the date of admission to the Veterinary Teaching Hospital, and all clinical signs reported in the history and physical examination at initial examination were abstracted from the medical record. The values of evaluated blood parameters were recorded. The blood parameters included CBC, serum protein profile, serum alkaline phosphatase activity, and serum haptoglobin and fibrinogen content. The reference values used for each blood parameter were the reference values used by Liège University's Biochemistry Laboratory. For the control group, the final diagnosis was recorded.

In addition, for clinical data, including physical abnormalities and abnormal clinical chemistry, on CBC, a value of 1 was attrib-

uted for each observed clinical sign, and the score of an individual animal is defined as the sum of all clinical signs present.

Statistical Analyses

The prevalence of infection among the equids included in the study, the sensitivity, the specificity, and the accuracy of each clinical sign were estimated with 95% confidence intervals (95% CI) assuming a binomial exact distribution. The mean ages and the mean values for each blood parameter in the 2 respective groups of animals, with unequal variance and considering nonnormal data, were compared with a Wilcoxon's rank-sum test.³⁴ The limit of statistical significance of the tests performed was defined as $P \leq .05$. The potential influence of age, sex, and breed was assessed. Statistical analysis of these data was performed using a χ^2 -test and the tendency of each parameter to become a risk factor was evaluated by an odds ratio (OR) calculation with 95% CI (logarithmic approximation); a P value $\leq .05$ was considered significant.³⁵

A receiver operating characteristic (ROC) curve is a graph of the relationship between the sensitivity (the true-positive rate) against 1 minus the specificity (the false-positive rate) for different cut-off values. A good test is 1 which has a high true-positive rate and a low false-positive rate and whose value, therefore, lies close to the top left-hand corner of the graph. The ROC curve is typically used to evaluate accuracy of different cut-off values for 1 variable and this variable can be the number of clinical signs (score of combination of clinical signs). In the present study, the determination of the best score of combination of clinical signs was made using the ROC curve. Epidemiological software for veterinary medicine was used.³⁶

Results

Animals

Nine of the 153 equids in which vegetative endocarditis was included in the initial differential diagnosis had a final diagnosis of vegetative endocarditis (5.9% with 95% CI: 2.7–10.9%).

The mean age of the equids was 4.84 ± 5.74 and 10.8 ± 7.73 years in the case and in the control groups, respectively ($P = .01$).

Sex and breed were not risk factors to developing endocarditis in equids in this study. With geldings as the referent group, OR for stallions and females were 5.18 (95% CI: 0.885–30.3) and 1.32 (95% CI: 0.212–8.15), respectively.

Clinical Signs

The clinical signs presented by the 9 cases with endocarditis were hyperthermia ($n = 9$), tachycardia ($n = 7$), heart murmur ($n = 7$), tachypnea/dyspnea ($n = 7$), depression ($n = 7$), lameness ($n = 5$), recurrent/persistent anorexia or lack of appetite ($n = 5$), weight loss ($n = 4$), synovial distension ($n = 4$), neurological symptoms ($n = 3$), poor body condition ($n = 3$), intensity variation of peripheral pulse ($n = 1$), and arrhythmia ($n = 1$).

The 3 clinical signs associated with a significant higher risk of the presence of endocarditis were hyperthermia, synovial distension, and lameness (Table 1).

Blood Parameters

The abnormal blood parameters most frequently reported were hyperfibrinogenemia ($n = 8$), leukocytosis

Table 1. Odds ratio (OR), sensitivity, specificity, and accuracy calculated for the 13 clinical signs and the 9 blood parameters in equids with confirmed endocarditis and in equids with suspected endocarditis but free from the disease.

Parameter ^a	Number of Observations				OR (95% CI) ^b	Sensitivity (95% CI)	Specificity (95% CI)	Accuracy (95% CI)
	Cases		Controls					
	Presence	Absence	Presence	Absence				
Clinical signs								
Hyperthermia	9	0	63	81	24.4 (1.40–428)*	100 (71.7–100)	56.3 (47.7–64.5)	58.8 (50.6–66.7)
Tachycardia	7	2	94	49	1.82 (0.365–9.12)	77.8 (40.0–97.2)	34.3 (26.5–42.7)	43.6(31.6–39.6)
Heart murmur	7	2	83	61	2.57 (0.516–12.8)	77.8 (40.0–97.2)	42.4 (34.2–50.9)	44.4 (36.4–52.7)
Tachypnea/dyspnea	7	2	88	55	2.19 (0.438–10.9)	77.8 (40.0–97.2)	38.5 (30.5–47.0)	40.8 (32.9–49.0)
Depression	7	2	64	79	4.32 (0.867–21.5)	77.8 (40.1–97.3)	55.2(46.7–63.6)	44.7(36.7–53.0)
Lameness	5	4	23	120	6.52 (1.63–26.1)*	55.6 (21.2–86.3)	83.9 (76.9–89.5)	82.2 (75.2–88.0)
Recurrent/ persistent anorexia or inappetence	5	4	48	96	2.5 (0.642–9.74)	56.6 (21.2–86.3)	66.7 (58.3–74.3)	66.0 (57.9–73.5)
Weight loss	4	5	81	62	0.612 (0.158–2.38)	44.4 (13.7–78.8)	43.4 (35.1–51.9)	43.4 (35.4–51.7)
Synovial distension	4	5	8	134	13.4 (3.00–59.8)*	44.4 (13.7–78.8)	94.4 (89.2–97.5)	90.7 (84.9–94.8)
Neurological symptoms	3	6	36	107	1.49 (0.353–6.25)	33.3 (7.49–70.1)	74.8 (66.9–81.7)	72.4 (64.5–79.3)
Poor body condition	3	6	53	90	0.849 (0.204–3.54)	33.3 (7.49–70.1)	62.9 (54.5–70.9)	61.2 (52.9–69.0)
Intensity variation of peripheral pulse	1	8	24	119	0.62 (0.0740–5.19)	11.1 (0.280–48.2)	83.2 (76.1–88.9)	79.0 (71.5–85.1)
Arrhythmia	1	8	36	107	0.372 (0.0449–3.07)	11.1 (0.280–48.2)	74.8 (66.9–81.7)	71.0 (63.2–78.1)
Blood parameters								
Fibrinogen	8	1	32	38	9.81 (1.16–82.7)*	88.9 (51.8–99.7)	54.3 (41.9–66.3)	58.2 (46.6–69.2)
Leukocytes	7	2	31	60	7.12 (1.40–36.4)*	77.8 (40.0–97.2)	65.9 (55.3–75.5)	67.0 (56.9–76.1)
Albumin	7	1	33	52	11.4 (1.34–96.8)*	87.5 (47.3–99.7)	61.2 (50.0–71.6)	63.4 (52.8–73.1)
Globulins	7	1	18	64	26.4 (3.03–229)*	87.5 (47.3–99.7)	78.0 (67.5–86.4)	78.9 (69.0–86.8)
Neutrophils	6	2	55	38	2.19 (0.419–11.5)	75.0 (34.9–96.8)	40.9 (30.8–51.5)	45.5 (35.6–55.8)
Hematocrit	5	4	35	60	2.18 (0.549–8.65)	55.6 (21.2–86.3)	63.2 (52.6–72.8)	62.5 (52.5–71.8)
Haptoglobin	5	1	23	12	2.86 (0.298–27.4)	83.3 (35.9–99.6)	34.3 (19.1–52.2)	41.5 (26.3–57.9)
Alkaline phosphatase	4	1	21	21	3.81 (0.391–37.1)	80.0 (28.4–99.5)	50.0 (34.2–65.8)	53.2 (38.1–67.9)
Total protein	2	6	23	69	2.19 (0.396–12.2)	25.0 (3.19–65.1)	71.0 (61.1–79.6)	71.0 (61.1–79.6)

^aThresholds for parameters: hyperthermia when temperature > 38.5 °C, tachycardia when heart rate > 44 beats/min, tachypnea when respiratory rate > 16 respirations/min, anemia when hematocrit < 33%, hyperfibrinogenemia when concentration ([]) > 3 g/L, leukocytosis when [] > 12 × 10⁹/L, neutrophilia when [] > 6 × 10⁹/L, hyperproteinemia when [] > 75 g/L, hyperglobulinemia when [] > 45 g/L, increased haptoglobin content when [] > 500 mg/L, hypoalbuminemia when [] < 25 g/L, increased alkaline phosphatase when > 400 U/L.

^bThe 95% confidence interval (CI) (binomial exact).

*Values statistically significant at *P* = .05.

(*n* = 7), hypoalbuminemia (*n* = 7), hyperglobulinemia (*n* = 7), neutrophilia (*n* = 6), anemia (*n* = 5), increased serum haptoglobin content (*n* = 5), increased serum alkaline phosphatase activity (*n* = 4), and hyperproteinemia (*n* = 2). The mean values for the 9 blood parameters in the case group and in the control group were significantly different for 5 parameters: fibrinogen, white blood cell count, albumin, total protein, and globulins (Table 2). The 4 abnormal blood parameters associated with a significant higher risk of the presence of vegetative endocarditis were hyperglobulinemia, hypoalbuminemia, hyperfibrinogenemia, and leukocytosis (Table 1).

Combination of the Significant Clinical Signs

A ROC curve shows that the association of 2 of the 3 of hyperthermia, synovial distension, and lameness gives the best test performance for a diagnosis of vegetative endocarditis (Fig 1). This result was not significantly different when a 2nd clinical pattern study was performed that considered lameness and synovial distension as being

linked clinical signs. In the 1st pattern study, the specificity was higher than the sensitivity. Whereas in the 2nd pattern study, it was the contrary (Table 3).

Discussion

For the case-control study concerning the risk factors of vegetative endocarditis, age was identified as a significant risk factor. Animals with endocarditis were significantly younger than animals free from endocarditis. This supports previous suggestions on the subject.^{12,17} The greater risk in young equids could be due to a more frequent occurrence of bacteremia in young animals than in adults, bacteremia being necessary for valve infection. Lower immune function, more frequent occurrence of severe worm infestation, or both could predispose young animals to infective endocarditis. No sex predisposition was found in the current study, which is consistent with some, but not all other studies.¹² In addition, because of the small sample size (*n* = 9) the ability to evaluate sex as an exploratory variable was

Table 2. Values for the 9 most frequently observed abnormal blood parameters in 9 equids suffering from endocarditis and in 144 equids with clinical signs suggestive of endocarditis but not suffering from endocarditis.

Blood Parameter	Mean Value \pm SD		P Value
	Case Group	Control Group	
Hematocrit (%)	33.4 \pm 10.6	35.0 \pm 7.96	.36
Fibrinogen (g/L)	4.26 \pm 1.07	3.09 \pm 1.55	.01 ^a
WBC (cells \times 10 ⁹ /L)	17.9 \pm 9.73	11.2 \pm 6.81	.03 ^a
Neutrophils (cells \times 10 ⁹ /L)	13.7 \pm 8.67	9.24 \pm 7.06	.11
Albumin (g/L)	20.9 \pm 3.45	25.3 \pm 7.90	.01 ^a
Total protein (g/L)	74.2 \pm 14.6	61.8 \pm 12.5	.01 ^a
Globulins (g/L)	51.9 \pm 19.4	37.7 \pm 12.8	.005 ^a
Alkaline phosphatase (U/L)	554 \pm 138	530 \pm 414	.33
Haptoglobin (mg/L)	2023 \pm 1210	1014 \pm 1005	.052

^aBlood parameters with mean values significantly different in the case group and in the control group.

WBC, white blood cell count.

limited. No breed predisposition was observed in the study. This could be attributable to the large variety of breeds present in the control and case groups and to an insufficiently large case group. Seasonal effect is impossible to identify in infective endocarditis because endocarditis can have initially vague clinical signs and usually following a chronic evolution in time, the date of diagnosis of the disease can differ greatly from the date of the initial infection.^{2,4,5,7}

This study shows that the clinical signs significantly increasing the probability of diagnosis of vegetative endocarditis are hyperthermia, synovial distension, and lameness. It is interesting to notice that none of the cardiac clinical signs (tachycardia, heart murmur, arrhythmia, and intensity variation of peripheral pulse) was significant. These results suggest that endocarditis should not be considered merely a localized infection, but, rather, a systemic problem via associated bacteremia, or the circulation of antibody-antigen complexes, or both. The abnormal blood parameters whose presence significantly increases the probability of the diagnosis of vegetative endocarditis were hyperglobulinemia, hypoalbuminemia, hyperfibrinogenemia, and leukocytosis. Vegetative endocarditis following more frequently a subacute or chronic evolution, these blood abnormalities were likely as they occur in most cases of chronic inflammation.^{8,37} It is however important to underline that in the present study, haptoglobin concentration and alkaline phosphatase activity were measured on a small number of animals. Thus, their importance could be increased or diminished in further studies with more clinical values.

The result of the statistical clinical pattern study of the present study shows that a way forward to an early diagnosis of vegetative endocarditis is the study of associations of clinical signs. Because infective endocarditis produces systemic effects on the organism, this is not surprising.^{2,5-7} A statistical clinical pattern study of a larger number of clinical signs and animals could

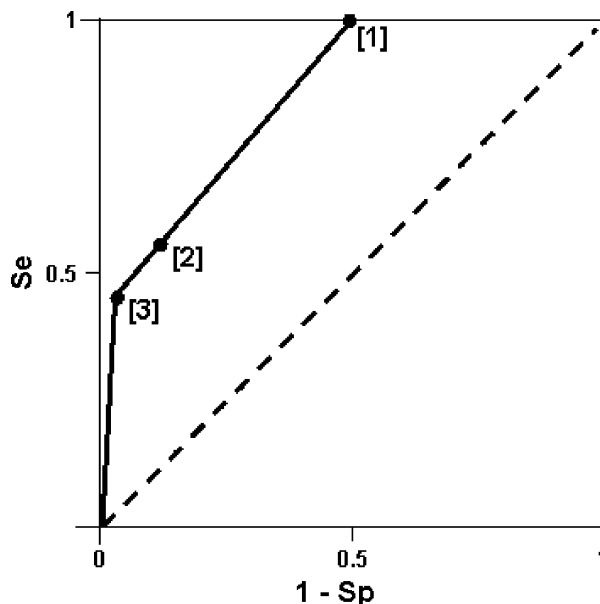


Fig 1. Receiver operating characteristic (ROC) curve of the score of the 3 most relevant clinical signs of vegetative endocarditis (hyperthermia, synovial distension, and lameness). Se, sensitivity; Sp, specificity; [1], [2], and [3]: endocarditis clinical signs score. Score [1] = hyperthermia or synovial distension or lameness. Score [2] = hyperthermia and synovial distension simultaneously present, or hyperthermia and lameness simultaneously present, or synovial distension and lameness simultaneously present. Score [3] = hyperthermia and synovial distension and lameness present. The test performance (clinical diagnostic) can be depicted graphically by plotting a ROC curve, which compares the true-positive rate, or Se, on the vertical axis with the false-positive rate (1-Sp) on the horizontal axis. The diagonal series of dashes reflect test values that are uninformative, eg, where the true-positive rate equals the false-positive rate. The dot on the continuous line that is the closest to the left superior corner of the figure represents the optimal number of clinical signs to reach a diagnosis of vegetative endocarditis in the horse.

increase our knowledge on the clinical expression of vegetative endocarditis and could help to determine the multiple associations of clinical signs occurring most frequently in animals affected by the disease.

It must be noted that the only clinical signs and laboratory findings evaluated in this study were those reported frequently enough to ensure that the statistical analysis was valid. Moreover, it was assumed that all veterinary surgeons from Liège University proceeded in the same way while taking a history, conducting a physical examination, and a complementary examination. Their diagnoses were not reviewed.

Conclusion

This study is aimed in priority at the equine practitioner with a limited number of complementary examinations available. The determination of the risk factors, significant clinical signs, and abnormal blood parameters through the case-control study should increase the practitioners' awareness of equine endocarditis and its clinical expression, leading to an earlier diagnosis of endocarditis. An

Table 3. Characteristics^a of 2 receiver operating characteristic (ROC) curves in function of the combination of clinical signs observed in 151 equids with clinical signs suggestive of endocarditis.

Combination of Clinical Signs ^b	Area under the ROC Curve (%)	Sensitivity (%)	Specificity (%)	Accuracy (%)
Hyperthermia and synovial distension and lameness	84.7 (79.2–90.3)	55.6 (23.1–88.0)	88.0 (82.7–93.4)	86.1 (79.5–91.2)
Hyperthermia and synovial distension or lameness	84.0 (76.7–89.4)	100 (71.7–100)	50.0 (41.6–58.4)	84.0 (78.7–89.4)

^aIn brackets: the 95% confidence interval.

^bClinical signs associated with a significant higher risk of the presence of endocarditis (see Table 1).

early diagnosis being a major factor for the success of the medical treatment, it is therefore an essential aspect of this study. An increased success rate for the treatment of vegetative endocarditis would also diminish the financial losses associated with the numerous treatment failures.

Acknowledgments

The authors thank the staff of the Equine Teaching Hospital of Liège University for their contribution to the data of this study and for the management of hospitalized horses. The authors also thank Mrs Lisette Trzpiot from the Liège Biochemistry Laboratory, Belgium, for clerical assistance. Professor C. Saegerman and Professor H. Amory contributed to the work in equal proportions.

References

1. Travers CW, Van Den Berg JS. *Pseudomonas spp.* associated vegetative endocarditis in two horses. *J S Afr Vet Assoc* 1995;66:172–176.
2. Jesty SA, Reef VB. Septicemia and cardiovascular infections in horses. *Vet Clin Equine* 2006;22:481–495.
3. Reef VB, Spencer P. Echocardiographic evaluation of equine aortic insufficiency. *Am J Vet Res* 1987;48:904–909.
4. Patteson MW. Equine cardiology. 2002. Available at: <http://www.provet.co.uk/equinecardiology/5a66646.htm>. Accessed November 5, 2006.
5. Patteson MW. Equine Cardiology. UK: Blackwell Science Ltd; 1996:150–154.
6. Ball MA, Weldon AD. Vegetative endocarditis in an Appaloosa gelding. *Cornell Vet* 1992;82:301–309.
7. Verdegaal EJMM, Sloet van Oldruitenborgh-Oosterbaan MM. Clinical commentary: Endocarditis in the horse. *Equine Vet Educ* 2006;18:196–198.
8. Brown CM. Symposium on cardiology: Acquired cardiovascular disease. *Vet Clin North Am Equine Pract* 1985;1:371–381.
9. Karzenski S, Crisman MV, Robertson J. Endocarditis in a stallion with a history of testicular torsion. *Equine Pract* 1997;19:24–27.
10. Collatos C, Clark ES, Reef VB, Morris DD. Septicemia, atrial fibrillation, cardiomegaly, left atrial mass, and *Rhodococcus equi* septic osteoarthritis in a foal. *J Am Vet Med Assoc* 1990;197:1039–1042.
11. Dedrick P, Reef VB, Sweeney RW, Morris DD. Treatment of bacterial endocarditis in a horse. *J Am Vet Med Assoc* 1988;193:339–342.
12. Buergelt CD, Cooley AJ, Hines SA, Pipers FS. Endocarditis in six horses. *Vet Pathol* 1985;22:333–337.
13. Roby KA, Reef VB, Shaw DP, Sweeney CR. Rupture of an aortic sinus aneurysm in a 15-year-old broodmare. *J Am Vet Med Assoc* 1986;189:305–308.
14. Bonagura JD, Herring DS, Welker F. Symposium on cardiology: Echocardiography. *Vet Clin North Am Equine Pract* 1985;1:312–333.
15. Freedman LR. The pathogenesis of infective endocarditis. *J Antimicrob Chemother* 1987;20(Suppl A):1–6.
16. Ewart S, Brown C, Derksen F, Kufuor-Mensa E. *Serratia marcescens* endocarditis in a horse. *J Am Vet Med Assoc* 1992;200:961–963.
17. Maxson AD, Reef VB. Bacterial endocarditis in horses: Ten cases (1984–1995). *Equine Vet J* 1997;29:394–399.
18. Hillyer MH, Mair TS, Holmes JR. Treatment of bacterial endocarditis in a Shire mare. *Equine Vet Educ* 1990;2:5–7.
19. Fröhlich W, Wlaschitz S, Riedelberger K, Reifinger M. Fallbericht: Aortenklappenendocarditis beim Pferd. *Dtsch Tierärztl Wochenschr* 2004;111:370–373.
20. Deegen E, Lieske R, Schoon H. Klinische und kardiologische Untersuchungsbeobachtungen bei 3 Deckhengsten mit Aortenklappeninsuffizienz. *Tierärztl Prax* 1980;8:211–222.
21. McCormick BS, Peet RL, Downes K. *Erysipelothrix rhusiopathiae* vegetative endocarditis in a horse. *Aust Vet J* 1985;62:392.
22. Reef VB. Mitral valvular insufficiency associated with ruptured chordae tendineae in three foals. *J Am Vet Med Assoc* 1987;191:329–331.
23. Kaplan NA, Moore BR. Case report: Streptococcus equi endocarditis, meningitis and panophthalmitis in a mature horse. *Equine Vet Educ* 1996;8:313–316.
24. Pace LW, Wirth NR, Foss RR, Fales WH. Endocarditis and pulmonary aspergillosis in a horse. *J Vet Diagn Invest* 1994;6:506–508.
25. Bonagura JD, Pipers FS. Echocardiographic features of aortic valve endocarditis in a dog, a cow, and a horse. *J Am Vet Med Assoc* 1983;182:595–599.
26. Hatfield CE, Rebhun WC, Dietze AE. Endocarditis and optic neuritis in a quarter horse mare. *Compendium Equine* 1987;9:451–454.
27. Hines MT, Heidel JR, Barbee DD. Bacterial endocarditis with thrombus formation and abscessation in a horse. *Vet Radiol Ultrasound* 1993;34:47–51.
28. Ramzan PHL. Case report: Vegetative bacterial endocarditis associated with septic tenosynovitis of the digital sheath in a Thoroughbred racehorse. *Equine Vet Educ* 2000;12:120–123.
29. Sponseller BT, Ware WA. Case report: Successful treatment of staphylococcal endocarditis in a horse. *Equine Vet Educ* 2001;13:298–302.
30. Fröhlich W, Wlaschitz S, Riedelberger K, Reef VB. Case report: Tricuspid valve endocarditis in a horse with ventricular septal defect. *Equine Vet Educ* 2006;18:172–176.
31. Verdegaal EJMM, De Heer N, Meertens NM, et al. Case report: A right-sided bacterial endocarditis of dental origin in a horse. *Equine Vet Educ* 2006;18:191–195.
32. Nilsford L, Lombard CW, Weckner D, Kvart C. Case report: Diagnosis of pulmonary valve endocarditis in a horse. *Equine Vet J* 1991;23:479–482.

33. Church S, Harrigan KE, Irving AE, Peel MM. Endocarditis caused by *Pasteurella caballi* in a horse. *Aust Vet J* 1998;8:528–530.
34. Dagnelie P. Statistique théorique et appliquée. Tome 2. Inférence statistique à une et à deux dimensions. France: De Boeck & Larcier; 1998:1–659.
35. Grenier B. Utilisation des ODDS dans les tests associés ou séquentiels. In: Grenier B., ed. *Décision médicale: analyse et stratégie de la décision dans la pratique médicale*. France: Masson; 1990:102–106.
36. Thrusfield M, Ortega C, De Blas I, et al. WIN EPISCOPE 20: Improved epidemiological software for veterinary medicine. *Vet Rec* 2001;148:567–572.
37. Van Lierde H. *Vademecum biologique du vétérinaire*. Belgium: Prodim; 1988:1–612.