Clinical utility of nasal lavage cytology and predictors of nasal biopsy success in dogs with nasal masses

Mathilde VILCOT[1], Eve RAMERY[2], Frédéric BILLEN[1], Cécile CLERCX[1], Géraldine BOLEN[1], Elodie ROELS[1]

[1] Department of Companion Animal Teaching and Clinical Practice, FARAH, Faculty of Veterinary Medicine, University of Liège, Belgium

[2] VETCYT, Pollionnay, France

Corresponding authors: mvilcot@uliege.be, eroels@uliege.be

1 Background

Nasal tumors account for approximately 1–2% of all canine neoplasms[1]. While identification of a **nasal mass** on CT or rhinoscopy raises clinical suspicion for a tumor[2,3], a definitive diagnosis requires **histopathological confirmation**. This remains challenging due to tumor characteristics and inherent limitations of biopsy techniques[4,5].

2 Objectives

ⓐ To evaluate the **diagnostic performance of nasal lavage cytology** compared with endoscopic-guided nasal biopsy in dogs with a nasal mass.

ⓑ To identify **predictive factors of successful biopsy sampling**

3 Materials & Methods

Single-centre retrospective observational study (2019-2026)

Case selection

Dogs with a **nasal mass** identified on CT or rhinoscopy.

Nasal lavage (NAL)

NAL was performed before endoscopy as previously described[6,7]. Cytospin preparations (1400rpm x 4min) were retrospectively reviewed by one board-certified clinical pathologist.

Predictors of successful biopsy sampling

Variables screened for association with obtention of a definitive histopathology diagnosis after nasal biopsy are listed in Table 1.

Statistical Analysis

Predictors were assessed by univariate and stepwise multivariate logistic regression models, with Firth correction when required. Significance level was set at 5% (SAS 9.4).

Table 1. Predictors evaluated for association with a definitive histopathological diagnosis.

Category	Predictors evaluated
Signalment (n=52)	Breed category, sex, neuter status, body weight, age
Clinical signs (n=52)	Duration of clinical signs, presence of epistaxis
Biopsy (n=43)	Largest biopsy specimen size
CT (n = 41)	Mass centre location, laterality, extension to the contralateral side, extent, width, height, length, perinasal extension
CT with IV contrast (n=32)	Post-contrast enhancement, presence of cavitation

4 Results

68 Dogs included

77.9% Epistaxis (53/68)

8.0 mm Median biopsy size (range 2.0–40.0, n=43)

Histopathological diagnosis (n=52)

Nasal biopsy success

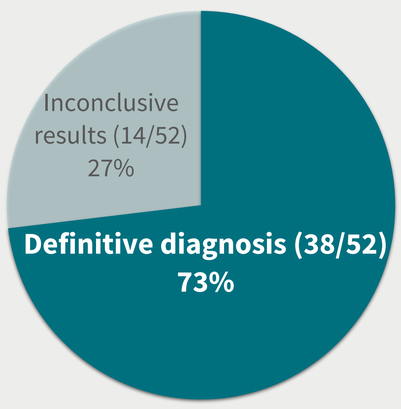

Histopathological result

Definitive diagnosis (n = 38)

- Carcinoma — **76.3% (29/38)**
- Sarcoma — **21.1% (8/38)**
- Undifferentiated tumor — **2.6% (1/38)**

Inconclusive result (n = 14)

- Inflammatory changes — **85.7% (12/14)**
- Epithelial proliferation — **7.1% (1/14)**
- Vascular proliferation — **7.1% (1/14)**

ⓐ Nasal lavage cytology (n=14)

Neoplastic cells were detected in the NAL of 4/14 dogs (Table 2): **poor sensitivity (28%)**

Table 2. Cytology results and histopathological diagnosis (n=14)

Nasal lavage cytology	n	Final histopathological diagnosis
Suggestive of carcinoma	**4**	Carcinoma (1), undifferentiated tumor (1), no biopsy available (2)
Inflammation	**5**	Carcinoma (3), sarcoma (2)
Non-diagnostic	**5**	Carcinoma (3), sarcoma (1), inconclusive (1)

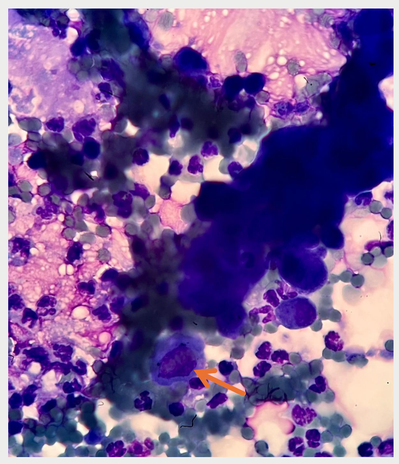

Neutrophilic inflammation was **present in all NAL samples**, sometimes accompanied by secondary bacterial infection, which limited the cytological distinction between reactive and neoplastic changes except when atypia was marked (Figure 1).

Figure 1. Dense clusters of cohesive epithelial cells. The hyperbasophilic cytoplasm and the thickness of preparation make cytologic details hard to discern inside the clusters. Peripheral singly occurring cells (arrow) exhibit marked atypia: high nucleocytoplasmic ratio and irregular nuclei.

ⓑ Predictors of biopsy success

Only 2 variables were independently associated with biopsy success (Table 3).

Table 3. Multivariable logistic regression model (32 dogs with contrast CT; AUC = 0.896).

Predictor	Adjusted OR	95% confidence interval	P-value
Biopsy specimen size (per log-unit increase)	**9.51**	1.05-85.9	0.045
Cavitary tumor on CT (yes vs no)	**0.11**	0.01-0.87	0.037

5 Conclusions

ⓐ **Nasal lavage cytology showed low sensitivity** for characterizing nasal masses in dogs and should not be relied upon as standalone diagnostic modality. However, it may occasionally allow early identification of nasal carcinoma pending histopathological confirmation.

ⓑ **Absence of mass cavities** on CT images and **larger biopsy specimen size** were independent predictors of nasal biopsy success, supporting the use of techniques maximizing tissue yield during endoscopic sampling.

References

1. Malinowski C. (2006). Canine and Feline Nasal Neoplasia. Clinical Techniques in Small Animal Practice;Nasal Disease21(2):89–94
2. Auler F. et al (2015). Tomography, Radiography, and Rhinoscopy in Diagnosis of Benign and Malignant Lesions Affecting the Nasal Cavity and Paranasal Sinuses in Dogs: Comparative Study. Topics in Companion Animal Medicine 30(2):39–42.
3. Van Scoyk K. et al (2025). Comparison of Computed Tomographic Features of Confirmed Nasal Neoplasia in Dogs. Vet Radiology Ultrasound; 66(6):e70099.
4. Harris B. et al. (2021). Diagnostic accuracy of three biopsy techniques in 117 dogs with intra-nasal neoplasia. J of Small Animal Practice;55(4):219–24.
5. Lent S. et al. (2023). Evaluation of rhinoscopy and rhinoscopy-assisted mucosal biopsy in diagnosis of nasal disease in dogs: 119 cases (1985-1989). J Am Vet Med Assoc;201(9):1425–9.
6. Biénès T, et al (2023). Intranasal and Serum Gentamicin Concentration: Comparison of Three Topical Administration Protocols in Dogs. Veterinary Sciences;10(8):490.
7. Boss M. et al. (2024). Saline lavage for sampling of the canine nasal immune microenvironment. J Vis Exp; 214:67577.

ECVIM-CA Congress 2026 — Berlin, Germany