United European Gastroenterology Journal

WILEY

UNITED EUROPEAN GASTROENTEROLOGY ueg journal

ORIGINAL ARTICLE OPEN ACCESS

TNF Inhibitor-Induced Sarcoidosis-Like Lesions in Inflammatory Bowel Disease

Zlata Chkolnaia[1] | Benedicte Lebrun-Vignes[2] | Aurelien Amiot[3] | Mathieu Uzzan[4] | Nicolas Richard[5] | Maeva Charkaoui[6] | Guillaume Le Cosquer[7] | Carmen Stefanescu[8] | Melanie Serrero[9] | Laurianne Plastaras[10] | Sophie Vieujean[11] | David Laharie[12,13] | Philippe Seksik[14]

[1]Paris Cite University, Paris, France | [2]Regional Pharmacovigilance Centre, Department of Medical Pharmacology, Pitié-Salpêtrière Hospital, APHP. Sorbonne Université, Paris, France | [3]Department of Gastroenterology, University Hospital of Bicêtre, Assistance Publique-Hôpitaux de Paris, Université Paris-Saclay, Inserm, CESP, Le Kremlin Bicêtre, France | [4]Gastroenterology Department, Paris Est Créteil University UPEC, Assistance Publique-Hôpitaux de Paris (AP-HP), Henri Mondor Hospital, Fédération Hospitalo-Universitaire TRUE InnovaTive theRapy for ImmUne disordErs, Créteil, France | [5]Department of Gastroenterology, University Rouen Normandie, INSERM, ADEN UMR1073, "Nutrition, Inflammation and Microbiota-gut-brain Axis", CHU Rouen, Rouen, France | [6]Department of Hepatogastroenterology, Dijon University Hospital, Dijon, France | [7]Department of Gastroenterology and Pancreatology, Toulouse University Hospital, Toulouse, France | [8]Paris IBD Center, Institut des MICI, Groupe hospitalier privé Ambroise Paré Hartmann, Neuilly sur Seine, France | [9]Department of Gastroenterology, North Hospital, Marseille, France | [10]Department of Hepato-Gastroenterology, Hospital Pasteur, Colmar, France | [11]Hepato-Gastroenterology and Digestive Oncology, University Hospital CHU of Liège, Liège, Belgium | [12]CHU de Bordeaux, Hôpital Haut-Lévêque, Service d'Hépato-gastroentérologie et oncologie digestive – Université de Bordeaux, Bordeaux, France | [13]Groupe d'Etude Therapeutique des Affections Inflammatoires du Tube Digestif, Paris, France | [14]Gastroenterology Department, Sorbonne Université, INSERM, Centre de Recherche Saint-Antoine, CRSA, AP-HP, Saint-Antoine Hospital, Paris, France

Correspondence: Philippe Seksik (philippe.seksik@aphp.fr)

Received: 13 December 2024 | **Revised:** 14 January 2025 | **Accepted:** 30 January 2025

Funding: The authors received no specific funding for this work.

Keywords: corticosteroid treatment | Crohn's disease | inflammatory bowel disease | sarcoidosis-like lesions | TNF inhibitors | ulcerative colitis

ABSTRACT

Background: While tumor necrosis factor (TNF) inhibitors can induce paradoxical reactions, sarcoidosis-like disease has hardly been reported so far. This study aimed to describe the epidemiological, diagnostic and therapeutic features of TNF inhibitor-induced sarcoidosis-like lesions in patients with inflammatory bowel disease.

Methods: We conducted a case series across 59 institutions affiliated with the *Groupe d'Etude Therapeutique des Affections Inflammatoires du Tube Digestif*. Diagnosis of TNF inhibitor-induced sarcoidosis was based on typical clinical and radiological signs, histological evidence of non-necrotizing granuloma, exclusion of alternative diagnoses, and a timeline consistent with drug exposure. A pharmacovigilance expert reviewed each case to confirm drug causality.

Results: We identified 14 cases of sarcoidosis-like lesions, including 9 patients with Crohn's disease, 4 ulcerative colitis, and 1 with unclassified inflammatory bowel disease. The implicated medications were infliximab (8), adalimumab (5), and golimumab (1), predominantly in first-time biotherapy users (71%). The median time from treatment initiation to sarcoidosis diagnosis was 27.5 months (range 3–91). Common clinical manifestations included dyspnea (71%), coughing (50%) and fever (50%). Ten patients discontinued TNF inhibitor therapy and started oral steroids, leading to complete symptom resolution in seven cases and improvement in two. Median time from steroid initiation to clinical remission of sarcoidosis was 84 days (range 11–134). After a median follow-up of 40 months, while no relapses occurred in 13 patients, one showed persistent sarcoidosis activity.

This is an open access article under the terms of the Creative Commons Attribution-NonCommercial-NoDerivs License, which permits use and distribution in any medium, provided the original work is properly cited, the use is non-commercial and no modifications or adaptations are made.

© 2025 The Author(s). *United European Gastroenterology Journal* published by Wiley Periodicals LLC on behalf of United European Gastroenterology.

Conclusions: TNF inhibitor-induced sarcoidosis should be considered in inflammatory bowel disease patients with chronic respiratory symptoms or fever after exclusion of mycobacterial infection. Management involves discontinuation of TNF inhibitors and a course of steroids.

1 | Introduction

Tumor necrosis factor inhibitors (anti-TNF) are increasingly used for inducing and maintaining remission in patients with inflammatory bowel disease (IBD), bringing to light new adverse events. While psoriasiform lesions represent the most common paradoxical side effect, less common occurrences of drug-induced sarcoidosis-like disease have also been documented [1]. It is a multisystemic granulomatous reaction that occurs during or after exposure to anti-TNF therapy, with no history suggestive of sarcoidosis before the start of the treatment, and improvement or resolution of symptoms within weeks or months after withdrawal of the drug [2]. Despite existing literature suggesting potential mechanisms such as an increased susceptibility to infection or changes in cytokine and cellular environment, a clear understanding of the physiopathology of this granulomatous inflammation has yet to be identified [3–7].

Anti-TNF-induced sarcoidosis typically presents similarly to sarcoidosis itself [2]. The absence of specific clinical, radiological or histological signs and the multitude of alternative diagnoses, especially mycobacterial infections, make their diagnosis a challenge [8, 9]. Managing such reactions can also be challenging, often necessitating discontinuation of anti-TNF therapy in patients with refractory IBD [10].

Sarcoidosis-like lesions were initially described in inflammatory rheumatisms [11, 12]. To date, only case reports are available regarding their occurrence in the context of IBD [10, 13–25]. There is a notable lack of large-scale studies addressing this serious adverse reaction in IBD patients.

To address this knowledge gap, our objective was to provide a comprehensive overview of the epidemiological, diagnostic, and therapeutic aspects of sarcoidosis-like lesions in IBD patients undergoing anti-TNF therapy, alongside patient outcomes.

2 | Materials and Methods

2.1 | Study Design

We conducted a multicentre international case series of IBD patients with anti-TNF-induced sarcoidosis diagnosed from 2009 to 2022 across 59 institutions in France, Belgium and Switzerland, all affiliated with the *Groupe d'Etude Therapeutique des Affections Inflammatoires du Tube Digestif* (GETAID).

2.2 | Diagnosis of Anti-TNF-Induced Sarcoidosis-Like Lesions

Sarcoidosis is a systemic granulomatous disease of unknown etiology. Similar to IBD, its diagnosis relies on a combination of clinical, radiological, and pathological findings, along with the exclusion of differential diagnoses [8].

Clinical presentation spans from dyspnea and fever to cutaneous lesions and uveitis. Common radiological findings include bilateral hilar adenopathy and perilymphatic micronodular infiltration. Biological markers suggestive of sarcoidosis are hypercalcemia and elevated serum angiotensin-converting enzyme (ACE) levels, though these are neither sensitive nor specific [26]. Histopathologically, sarcoid granulomas are typically non-necrotizing and localized around bronchovascular bundles and fibrous septa. However, pathological evaluation alone cannot distinguish sarcoidosis from other granulomatous diseases. Mycobacterial infection is the primary differential diagnosis, especially given the increased incidence of tuberculosis among patients treated with infliximab [9]. Additionally, granulomatous interstitial lung disease can occur as an extra-intestinal manifestation of Crohn's disease (CD) itself, mimicking parenchymal sarcoidosis [27].

The following criteria for diagnosing anti-TNF-induced sarcoidosis were established together with the pharmacovigilance expert (BLV):

1. Typical clinical and/or radiological signs of sarcoidosis according to the 1999 Consensus Statement [28].
2. At least one bacteriological negative test for mycobacterial infection.
3. Presence of non-necrotizing granulomas on biopsies, except in patients with Löfgren's syndrome (pathognomonic association of fever, erythema nodosum, arthralgias and bilateral hilar lymphadenopathy) [28].
4. Timeline compatible with drug exposure, meaning the first clinical or radiological signs of sarcoidosis have appeared during anti-TNF treatment, at least 3 months after the first injection or within the first 3 months following the last injection (Figure 1).

2.3 | Inclusion and Exclusion Criteria

All adult IBD patients with a diagnosis of anti-TNF-induced sarcoidosis-like lesions were eligible for inclusion. The diagnosis of IBD was based on a combination of clinical, biological, endoscopic, and histopathological investigations in accordance with the latest ECCO guidelines [29]. Patients were treated for their IBD with infliximab, adalimumab, or golimumab. Certolizumab has not been included as it is not approved by the European Medicines Agency for this indication.

Exclusion criteria were defined as follows:

- Patients under age 18 at the time of the diagnosis of sarcoidosis.

Summary

- Anti-TNF therapy can induce sarcoidosis-like reactions, but their occurrence in IBD patients is rarely reported.
- This study presents the largest case series of anti-TNF-induced sarcoidosis in IBD patients, detailing clinical features and treatment outcomes.
- It highlights the need to consider anti-TNF-induced sarcoidosis-like lesions in IBD patients with chronic respiratory symptoms or fever, guiding clinicians toward discontinuation of anti-TNF therapy and steroid use for effective management.

– First symptoms related to sarcoidosis occurred more than 3 months after the last anti-TNF injection.

– No histological evidence of granulomas, except in cases of Löfgren's syndrome.

– Presence of another cause of granulomatous disease.

2.4 | Data Collection

Members of the GETAID were contacted via email to gather reports of adult IBD patients undergoing anti-TNF therapy who were diagnosed with drug-induced sarcoidosis-like lesions. Investigators in each center determined the eligibility of patients according to the inclusion and exclusion criteria. Ten of the 59 centers reported clinical cases and completed our electronic case report form (e-CRF).

2.5 | Pharmacovigilance Review

Each case was reviewed by a pharmacovigilance expert (BLV) using the French method to assess the relationship between the anti-TNF drug and the occurrence of sarcoidosis-like reactions [30]. This method combines an intrinsic score and a bibliographic scale.

Intrinsic imputability is determined by evaluating both chronological and semiological criteria. Chronological criteria include the time to onset after drug administration, the effect's progression upon discontinuation, and the result of potential re-administration. The chronological score ranging from C0 to C3 results from the combination of these 3 criteria. Semiological criteria encompass signs and symptoms suggesting the drug's role in the reaction, contributing factors, results from specific examinations, and the search for other non-drug etiologies. The scoring system ranges from S0 to S3, with S3 representing the highest degree of semiological relation between the drug and the adverse reaction. Chronological and semiological scores are combined in a table to determine intrinsic imputability, with scores ranging from I0 to I6. A higher score indicates a stronger relationship between the drug and the reaction.

The bibliographic scale differentiates expected from unexpected adverse drug reactions. This rating system is organized into several levels, from B1 to B4, based on a systematic analysis of reference documents and databases.

Finally, declarations were made to the respective regional pharmacovigilance centers for all previously unreported cases, in order to transmit them to the French Drug Agency (*Agence Nationale de Sécurité du Médicament et des Produits de Santé*) for recording in the French pharmacovigilance database.

2.6 | Ethics

This study was conducted according to the French reference methodology MR-004 available as Supporting Information S1. It

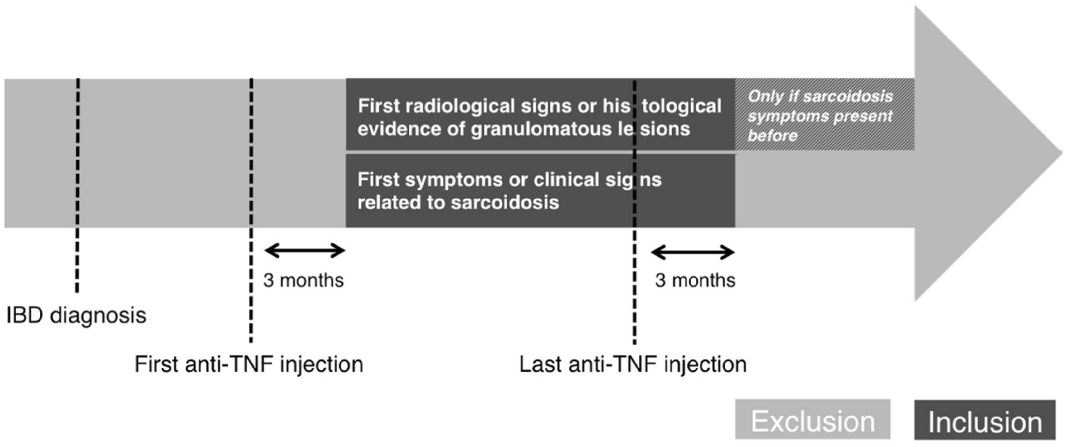

FIGURE 1 | Timeline of anti-TNF exposure for the diagnosis of drug-induced sarcoidosis-like lesions. Inclusion criteria (dark gray): The first clinical, radiological, or histopathological signs of sarcoidosis must appear during anti-TNF treatment, either at least 3 months after the first injection or within 3 months following the last injection. Additionally, patients with radiological signs or histopathological evidence of granulomatous lesions that are discovered more than 3 months after the last injection, provided symptoms are present during treatment or within 3 months following the last injection, are also included. Exclusion Criteria (light gray): Patients are excluded if the first symptoms or clinical signs related to sarcoidosis occur before the first anti-TNF injection, within 3 months following it, or more than 3 months after the last injection. Alt text: Timeline illustrating the chronological criteria for the diagnosis of anti-TNF-induced sarcoidosis.

was supervised by and registered with GETAID (registration number F20230918161408 in the Health Data Hub).

3 | Results

3.1 | Patients and IBD Characteristics

Fourteen cases of sarcoidosis-like lesions during anti-TNF therapy were identified in 10 centers affiliated with GETAID. General and IBD-related patient characteristics are presented in Table 1 [31].

Most patients (10, 71%) were first-time users of advanced therapy. Only one patient with infliximab was on combination therapy with azathioprine at the time of sarcoidosis diagnosis. Anti-TNF therapy was administered at an optimized dose in 7 (50%) cases, exclusively with infliximab. The median time from anti-TNF initiation to sarcoidosis diagnosis was 27.5 months (range 3–91). Infliximab trough levels ranged from 3.2 to 10.0 μg/mL, with no detectable anti-drug antibodies in the five patients tested.

Among CD patients (n = 9), based on the Harvey-Bradshaw Index (HBI) and according to the Stride II consensus, 4 were in a non-active state, three had mild disease activity, and one had moderate activity at the time of sarcoidosis-like lesions diagnosis [32]. For patients with colitis (n = 5), the partial Mayo score indicated that two were in remission, two had mild disease activity, and one had moderate activity [33].

3.2 | Diagnostic Features of Anti-TNF-Induced Sarcoidosis

Regarding the most common clinical signs of anti-TNF-induced sarcoidosis, 10 (71%) patients experienced dyspnea, 7 (50%) reported coughing, and 7 (50%) presented with fever. Other symptoms included arthralgia (3, 21%), asthenia (3, 21%), chest pain (2, 14%), erythema nodosum (2, 14%), and night sweats (2,

TABLE 1 | Patient characteristics at the time of sarcoidosis-like lesions diagnosis.

		Status at sarcoidosis diagnosis
General		
Male/Female, *n*		7/7
Age (years), median [range]		39 [25–55]
BMI (kg/m^2), median [range]		24.5 [17.7–46.9]
Smoking, *n*	Current smokers	5
	Non smokers	5
	Ex-smokers	4
Smoking exposure (pack-years), mean		11.2
IBD		
Type, *n*	CD	9
	UC	4
	IBD-U	1
Duration (years), median [range]		15.4 [5–29]
CD location, *n*[a]	L1	3
	L2	0
	L3	6
CD phenotype, *n*[a]	B1	3
	B2	3
	B3	3
	p	1
UC Extent, *n*[a]	E1	1
	E2	1
	E3	2
IBD-related surgery, *n*[b]	CD patients	5
	UC patients	0

Abbreviations: B1, non-stricturing, non-penetrating; B2, stricturing; B3, penetrating; BMI, body mass index; CD, Crohn's disease; E1, ulcerative proctitis; E2, left sided UC; E3, pancolitis; IBD, inflammatory bowel disease; IBD-U, inflammatory bowel disease unclassified; L1, ileal; L2, colonic; L3, ileocolonic; p, perianal disease; UC, ulcerative colitis.
[a]CD location and phenotype, as well as UC extent are described according to the Montreal classification.
[b]Five patients underwent IBD-related surgery, all with CD.

14%). There were also isolated cases of meningitis, Löfgren syndrome, parotidomegaly and dry eye syndrome.

Most frequent biological markers indicative of sarcoidosis were bronchoalveolar lavage (BAL) lymphocytosis (6, 43%) and elevated ACE levels (5, 36%). The median C-reactive protein level was 23.5 mg/L (range 1–81). Bilateral mediastinal and hilar adenopathy (12, 86% and 11, 79%, respectively) and perilymphatic lung micronodules (3, 21%) presented as the most common radiological findings. Figure 2 illustrates the thoracic lesions observed in two patients from our cohort. Other paraclinical characteristics are detailed in Figure 3. Histopathological confirmation of non-necrotizing granuloma was primarily obtained through endobronchial ultrasound-guided transbronchial needle aspiration (EBUS-TBNA) of mediastinal lymph nodes (5, 36%).

All 14 patients exhibited lung involvement. Other affected organs included joints (3, 21%), extra-thoracic lymph nodes (3, 21%), liver (2, 14%), spleen (2, 14%), and isolated cases involving the salivary glands, kidneys, central nervous system, and skin. The median diagnostic delay, defined as the time from symptom onset to either corticosteroid initiation or discontinuation of anti-TNF therapy (if corticosteroids were not used), was 29 days (range 1–1268). Hospitalization details were not provided for all cases, but at least eight patients were hospitalized due to their sarcoidosis-like lesions. The severity of these adverse reactions was classified as Grade 3, according to the Common Terminology Criteria for Adverse Events (CTCAE).

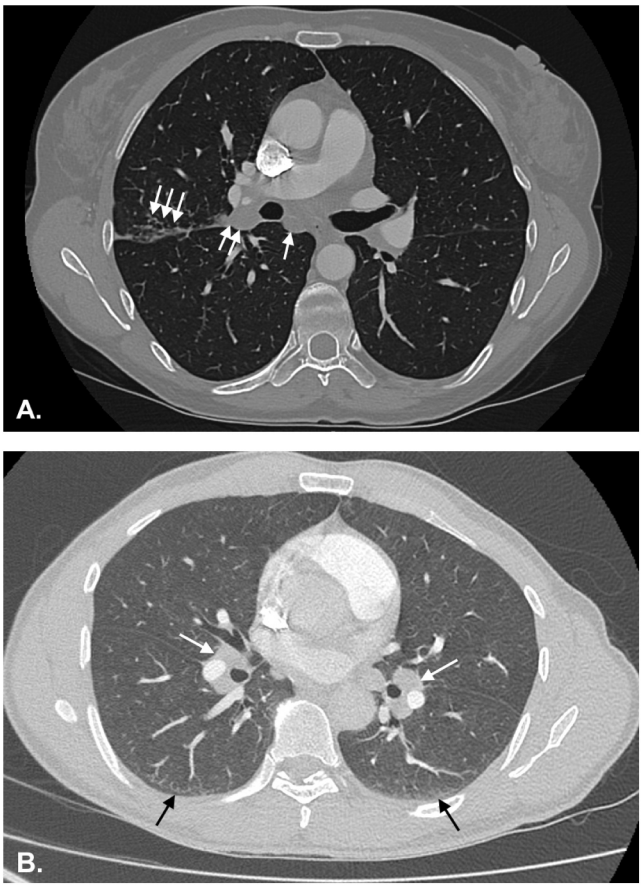

FIGURE 2 | Pulmonary CT scan Manifestations of Anti-TNF-induced Sarcoidosis. (A) Right mediastinal (single arrow) and hilar (2 arrows) non-necrotic adenopathy, along with perilymphatic micronodules on the fissure (3 arrows). (B) Bilateral hilar adenopathy (white arrows) and subpleural micronodules (black arrows).

3.3 | Treatment of Sarcoidosis-Like Lesions

Anti-TNF therapy was discontinued in 13 patients, while 1 continued treatment due to rapid favorable evolution under steroids. Oral corticosteroids were administered to 11 (79%) patients with a daily dose of either 30 or 60 mg. The median duration of corticosteroid therapy was 99 days (range 12–664). Ten patients discontinued anti-TNF therapy and started oral steroids, resulting in complete resolution of symptoms in seven cases and improvement in two. One patient with multivisceral sarcoidosis required the addition of azathioprine due to renal insufficiency. Anti-TNF discontinuation alone led to clinical remission in three cases. The median time from corticosteroid initiation to clinical remission was 84 days (range 11–134). For patients who only discontinued anti-TNF therapy, the median time to clinical remission was 197 days (range 134–305). Radiological monitoring showed lesion disappearance in 4 (29%) patients and scannographic improvement in 7 (50%) patients. The median time from corticosteroid initiation or anti-TNF discontinuation to radiological response was 210 days (range 32–512).

3.4 | Evolution Following Anti-TNF-Induced Sarcoidosis

The median follow-up period after diagnosis of anti-TNF-induced sarcoidosis was 40 months (range 17–174). Controlled IBD was observed in five patients, while one patient experienced a mild flare-up, seven had moderate flare-ups, and one had a severe flare-up. The median time to an IBD flare-up was 4 months (range 0–15). During the follow-up period, all 14 patients underwent treatment changes, with 6 (43%) patients switching to vedolizumab and 3 (21%) to ustekinumab. One patient has continued the same anti-TNF therapy for 21 months following sarcoidosis diagnosis without recurrence of granulomatous lesions. Three patients resumed an anti-TNF treatment, two with another agent and one with the same. Characteristics of these patients are resumed in Table 2. No recurrence of anti-TNF-induced sarcoidosis was observed. At the last news, 9 (64%) patients were in remission for their IBD. One patient exhibited clinically persistent sarcoidosis and still required corticosteroid therapy. Table 3 presents the evolution of sarcoidosis-like lesions and IBD according to the administered treatment.

3.5 | Pharmacovigilance Analysis

Two of the 14 cases had been reported to pharmacovigilance before the study was carried out, with no contraindications for the anti-TNF class identified by pharmacovigilance experts. A pharmacovigilance analysis to assess the relationship between anti-TNF therapy and sarcoidosis-like reactions was conducted for the 14 cases according to the updated French causality method [30]. Chronological assessment most frequently indicated a C2 score. Semiological analysis consistently indicated an S1 score, as

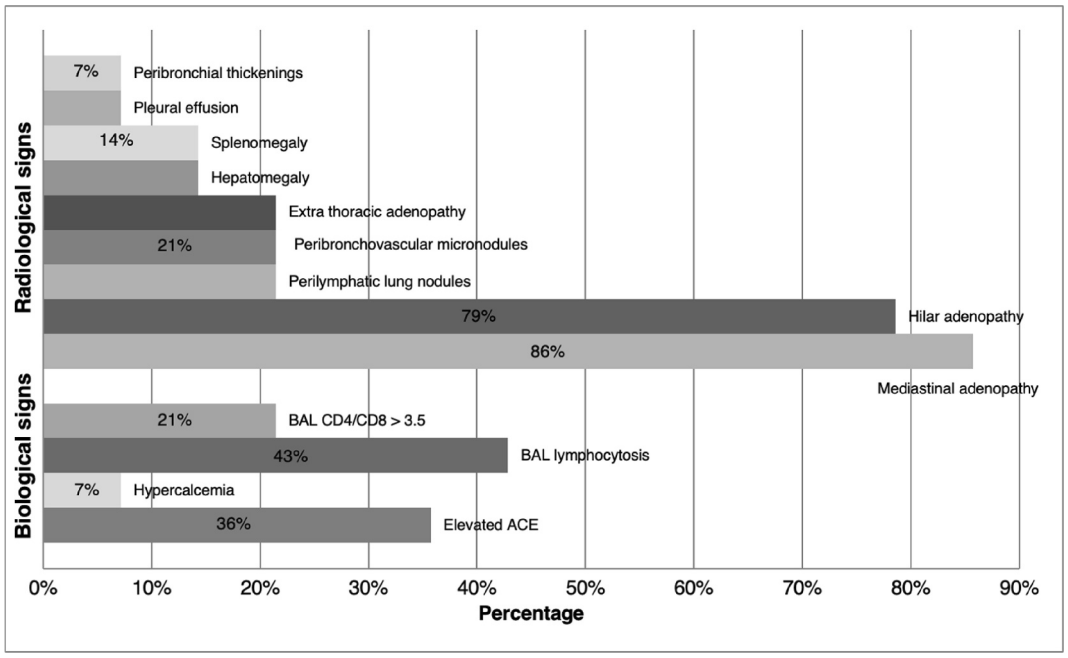

FIGURE 3 | Paraclinical signs of sarcoidosis-like lesions. ACE, Angiotensin-Converting Enzyme; BAL, Bronchoalveolar Lavage. Alt text: Diagram illustrating the frequencies of radiological and biological signs of anti-TNF-induced sarcoidosis in our cohort of IBD patients.

TABLE 2 | Characteristics and evolution of patients who maintained or resumed anti-TNF therapy.

Patient	IBD treatment and duration	Sarcoidosis presentation	Sarcoidosis treatment	Anti TNF post sarcoidosis	Evolution after sarcoidosis diagnosis
Man, 43 years, CD	ADA 40 mg/ 14 days 71 months	Löfgren's syndrome, peribronchial thickenings, hepatomegaly	Oral CS 30 mg/day	ADA maintained for 21 months	– Clinical remission of sarcoidosis by D52 after CS initiation, with no recurrence – CD flare at M7 post-diagnosis without change of biotherapy, swap to vedolizumab at M21
Woman, 39 years, CD	IFX 10 mg/ kg/8 w 71 months	Dyspnea, pulmonary micronodules	Anti-TNF discontinua-tion and oral CS 60 mg/day	IFX resumed at M24, change to ADA at M26 and to GOL at M79	– Clinical remission of sarcoidosis by D11 after CS initiation, with no recurrence – CD flare at M15 post-diagnosis leading to the reintroduction of IFX at M24, followed by 2 other lines of anti-TNF
Man, 39 years, CD	IFX 5 mg/ kg/4 w 66 months	Fever, coughing, mediastinal and hilar adenopathy	Anti-TNF discontinua-tion and oral CS[a]	Switch to ADA at M3	– Clinical remission of sarcoidosis by D68 after CS initiation, with no recurrence – Controlled CD under ADA for 171 months
Man, 52 years, CD	IFX 10 mg/ kg/6 w 35 months	Coughing, mediastinal, hilar and mesenteric adenopathy	Anti-TNF discontinua-tion alone	CERT at M21 maintained for 15 months	– Clinical remission of sarcoidosis by D134 after IFX discontinua-tion, with no recurrence – CD flare at M2 post-diagnosis treated by UST, then swap to CERT at M21

Abbreviations: ADA, Adalimumab; CD, Crohn's disease; CERT, Certolizumab; CS, corticosteroids; D, day; GOL, Golimumab; IFX, Infliximab; M, month; UST, Ustekinumab; w, weeks.
[a]Dosage of corticosteroids is unknown.

TABLE 3 | Evolution of sarcoidosis-like lesions and IBD according to treatment.

	Anti-TNF discontinuation + steroids 60 mg[a] (*N* = 5)	Anti-TNF discontinuation + steroids 30 mg[a] (*N* = 3)	Anti-TNF discontinuation alone (*N* = 3)
Clinical evolution of sarcoidosis			
Remission	3	2	3
Improvement	1	1	
Persistent activity	1		
Time to clinical remission[b]	77 days (11–91)	113 days (109–117)	197 days (134–305)
Radiological evolution of sarcoidosis lesions[c]			
Disappearance	1	1	2
Improvement	3	2	1
Time to radiological response[b]	223 days (97–468)	116 days (32–485)	409 days (210–512)
IBD flare-up			
Controlled disease	1	2	
Mild	1		
Moderate	2	1	3
Severe	1		
Time to IBD flare-up[b]	4.5 months (3–15)	6 months	2 months (0–3)
IBD activity at last news[c]			
Clinical remission	4	2	1
Mild-to-moderate activity		1	
Moderate-to-severe activity	1		1

[a]Daily doses of corticosteroids are indicated. This data was missing for 2 patients who are not included in this table. Another patient was treated with steroids alone without anti-TNF discontinuation.
[b]All durations are expressed as medians (range).
[c]The radiological evolution of sarcoidosis lesions and IBD activity at last news was not known for one patient.

there is no identified etiology for sarcoidosis or any specific predisposing factors. This results in a relatively low intrinsic imputability, categorized as I1 or I2. However, the bibliographical evidence is maximal (B4) for all anti-TNF agents, as sarcoidosis is listed in the summary of product characteristics for these drugs. This strong bibliographical evidence supports the association between anti-TNF therapy and sarcoidosis-like reactions.

4 | Discussion

We collected 14 cases of sarcoidosis-like lesions in IBD patients undergoing anti-TNF therapy, representing the largest international series to date. The existing literature on this subject is very scarce, with only case reports available, and the largest review to date includes 7 patients with CD who developed anti-TNF-induced sarcoidosis [25]. Given the widespread use of anti-TNF nowadays, this drug-induced granulomatous reaction appears relatively rare, although the prevalence of this adverse event was estimated at 1/2800 (0.04%) in the context of rheumatic diseases [12]. An analysis of the World Health Organization pharmacovigilance database, encompassing data from 130 countries (VigiBase), identified 2425 sarcoidosis-related adverse drug reactions recorded until January 2019, of which 882 were associated with anti-TNF treatment [2]. However, these data are likely underestimated given the low rate of pharmacovigilance reporting observed in our study. On the other hand, the small number of patients in our cohort is probably due to strict inclusion criteria, particularly the challenging requirement for histopathological evidence, which is one of the main diagnostic criteria for sarcoidosis. Additionally, the underreporting can be explained by the selection bias inherent in the retrospective design of the study, with each center only reporting cases that were known to the physicians.

Sarcoidosis-like reactions are a class effect of anti-TNF agents. In a review by Decock et al., etanercept was the underlying drug in 59% of cases, adalimumab in 23%, and infliximab in 18% [10]. These reactions seem to occur more commonly with etanercept, which might be explained by the different mechanisms of TNF

neutralization. While infliximab increases the lysis of T cells, thereby reducing interferon-gamma (IFN-γ) expression, etanercept increases the production of IFN-γ, a key factor in granuloma formation [34]. This could explain the lower number of cases in our study compared with those in inflammatory rheumatic diseases, where etanercept is commonly used, unlike in IBD.

The mechanisms underlying these drug-induced lesions remain unknown. Among the proposed pathophysiological hypotheses, anti-TNF therapy could promote sarcoidosis through cytokine imbalance, particularly an excess of interferon-alpha [3, 4]. Moreover, suppressing pathogenic T effector cells concomitantly impairs T regulatory cell activity, which would normally modulate TNF-driven inflammation [6]. An infectious agent could also trigger the granulomatous inflammatory response [7, 25].

Drug-induced sarcoidosis-like reaction is not the only cause of granulomatous pulmonary lesions under anti-TNF therapy. In addition to the increased rate of tuberculosis among patients treated with infliximab, there have also been reported cases of cryptococcosis and *Pneumocystis jiroveci* infections [9, 35, 36]. An infectious workup, including screening for mycobacteria and opportunistic infections, is essential prior to establishing a diagnosis of sarcoidosis.

Sarcoidosis and CD share clinical features such as erythema nodosum, uveitis, and arthritis. Both conditions involve granulomatous, Th1- and Th17-driven inflammation. The nucleotide oligomerization domain *nod2/card15*, a well-known susceptibility gene for CD, has also been implicated in early-onset sarcoidosis [37]. In this context, determining whether sarcoidosis occurring after anti-TNF treatment represents true paradoxical inflammation, the intrathoracic presentation of CD, or the co-existence of CD and sarcoidosis can be challenging. Arguments supporting a relationship between granulomatous reactions and anti-TNF therapy in our cases include the compatible chronology and the observed improvement following the discontinuation of anti-TNF agents. Additionally, the co-occurrence of IBD and sarcoidosis is exceedingly rare [38].

Our findings are consistent with previous publications. In a review of seven cases of sarcoidosis induced by anti-TNF therapy in CD patients, the median duration between the initiation of anti-TNF and the development of sarcoidosis was 24 months [25]. The median time to remission after drug discontinuation was 6 months in a French rheumatologic case series [12].

Notably, we did not observe any cases of eye involvement and only one with skin involvement, whereas these were the most frequently affected organs after the lungs in another publication [10]. In that review, anti-TNF discontinuation combined with corticosteroid therapy was the treatment for half of the patients, compared to 71% in our study. Non-severe lesions without functional impairment could likely be managed initially by discontinuing anti-TNF therapy, with steroids added only if there is no improvement. However, patients' conditions in our case series were relatively severe, as more than half required hospitalization. This severity likely explains the high use of corticosteroids in our cohort. Another explanation could be recall bias, with investigators remembering and reporting the most complex cases. It should be noted as well that time to clinical remission was longer with anti-TNF discontinuation alone.

In our series, anti-TNF therapy was maintained or reintroduced in 4 patients, who have not had a recurrence of granulomatous lesions. Even though imputability is low in cases of symptom regression despite continued anti-TNF therapy, we chose to include this patient's case, as it involved Löfgren syndrome, a pathognomonic presentation of sarcoidosis. The largest review on anti-TNF reintroduction found a 57.1% recurrence rate when the same anti-TNF was used and a 16.7% recurrence rate when a different anti-TNF was administered [25]. These data suggest that if anti-TNF therapy needs to be reinitiated, a different anti-TNF biotherapy should be considered. Nevertheless, given the current treat-to-target strategy, it may be possible to discuss the reintroduction of the anti-TNF involved in sarcoidosis at a multidisciplinary meeting, in certain specific cases where no other options are available, with input from pharmacovigilance.

In conclusion, sarcoidosis-like lesions represent a rare but significant adverse reaction to anti-TNF therapy in IBD patients. This diagnosis should be considered when patients present with persistent respiratory symptoms and/or fever after ruling out mycobacterial infection. Management involves discontinuation of anti-TNF therapy and introduction of oral steroids. Patients generally achieve clinical remission after several months of treatment, and no anti-TNF-induced sarcoidosis recurrence was observed, even in patients who resumed these agents. Enhanced reporting of rare side effects of IBD drugs will improve our understanding of this difficult-to-diagnose reaction, which has a significant impact on the IBD evolution.

Acknowledgments

Other collaborators from GETAID centers: Cyrielle Gilletta (Toulouse).

Conflicts of Interest

Aurelien Amiot received consulting fees from Abbvie, Hospira, Janssen, Tillotts, Adacyte, Pfizer, Takeda, Gilead and Biocodex; lecture fees and travel accommodations from Abbvie, Adacyte, Janssen, Biocodex, Hospira, Ferring, Pfizer, Biogen, Amgen, Fresenius Kabi, Ferring, Tillotts, Takeda and MSD. He also received advisory board fees from Gilead, Tillotts, Takeda and Abbvie. Mathieu Uzzan declares counseling, boards, transports or fees from Abbvie, Amgen, Celltrion, Ferring, Fresenius, Galapagos, Janssen, Pfizer and Takeda. Nicolas Richard has received lecture/consultant fees from Abbvie, Janssen and Takeda. Maeva Charkaoui received lecture fees from Abbvie, MSD, Takeda, Amgen, Janssen, Fresenius-Kabi, and consulting fees from Tillotts. Guillaume Le Cosquer declares lecture, transports or fees from Abbvie, Janssen, Takeda and Pfizer. Carmen Stefanescu declares consulting fees from Abbvie, Celltrion, Takeda, Janssen, Amgen, Galapagos/Alphasigma and Pfizer. Melanie Serrero declares board or lecture fees from Abbvie, Alfasigma, Amgen, Biogen, Celltrion, Janssen, MSD, and Takeda. Sophie Vieujean declares lecture, transports or fees from Abbvie, Celltrion, Ferring, Galapagos, Janssen, Lilly, Pfizer and Takeda. D Laharie declares counseling, boards, transports and/or fees from Abbvie, Amgen, Biogen, Ferring, Galapagos, Janssen, Lilly, MSD, Pfizer, Prometheus, Roche, Takeda, Tillots. Philippe Seksik received consulting fees from Takeda, Abbvie, Merck-MSD, Biocodex, Janssen, Amgen, Astellas and Pfizer and grants from Biocodex and Janssen. The other authors report no conflicts of interest.

Data Availability Statement

The data that support the findings of this study are available from the corresponding author upon reasonable request.

References

1. D. Wendling and C. Prati, "Paradoxical Effects of Anti-TNF-α Agents in Inflammatory Diseases," *Expert Review of Clinical Immunology* 10, no. 1 (2014): 159–169, https://doi.org/10.1586/1744666x.2014.866038.

2. F. Cohen Aubart, R. Lhote, A. Amoura, et al., "Drug-Induced Sarcoidosis: An Overview of the WHO Pharmacovigilance Database," *Journal of Internal Medicine* 288, no. 3 (2020): 356–362, https://doi.org/10.1111/joim.12991.

3. A. Massara, L. Cavazzini, R. La Corte, and F. Trotta, "Sarcoidosis Appearing During Anti-Tumor Necrosis Factor α Therapy: A New 'Class Effect' Paradoxical Phenomenon. Two Case Reports and Literature Review," *Seminars in Arthritis and Rheumatism* 39, no. 4 (2010): 313–319, https://doi.org/10.1016/j.semarthrit.2008.11.003.

4. I. Cleynen and S. Vermeire, "Paradoxical Inflammation Induced by Anti-TNF Agents in Patients With IBD," *Nature Reviews Gastroenterology & Hepatology* 9, no. 9 (2012): 496–503, https://doi.org/10.1038/nrgastro.2012.125.

5. C. A. Dinarello, "Differences Between Anti-Tumor Necrosis Factor-Alpha Monoclonal Antibodies and Soluble TNF Receptors in Host Defense Impairment," *Journal of Rheumatology* 74 (2005): 40–47.

6. X. Chen and J. J. Oppenheim, "Paradoxical Effects of Targeting TNF Signalling in the Treatment of Autoimmunity," *Nature Reviews Rheumatology* 12, no. 11 (2016): 625–626, https://doi.org/10.1038/nrrheum.2016.145.

7. D. van der Stoep, G. J. Braunstahl, J. van Zeben, and J. Wouters, "Sarcoidosis During Anti-Tumor Necrosis Factor-α Therapy: No Relapse After Rechallenge," *Journal of Rheumatology* 36, no. 12 (2009): 2847–2848, https://doi.org/10.3899/jrheum.090307.

8. E. D. Crouser, L. A. Maier, K. C. Wilson, et al., "Diagnosis and Detection of Sarcoidosis. An Official American Thoracic Society Clinical Practice Guideline," *American Journal of Respiratory and Critical Care Medicine* 201, no. 8 (2020): e26–e51, https://doi.org/10.1164/rccm.202002-0251st.

9. J. Keane, S. Gershon, R. P. Wise, et al., "Tuberculosis Associated With Infliximab, a Tumor Necrosis Factor α–Neutralizing Agent," *New England Journal of Medicine* 345, no. 15 (2001): 1098–1104, https://doi.org/10.1056/nejmoa011110.

10. A. Decock, G. Van Assche, S. Vermeire, W. Wuyts, and M. Ferrante, "Sarcoidosis-Like Lesions: Another Paradoxical Reaction to Anti-TNF Therapy?," *Journal of Crohn's and Colitis* 11, no. 3 (2017): 378–383.

11. F. D. O'shea, T. K. Marras, and R. D. Inman, "Pulmonary Sarcoidosis Developing During Infliximab Therapy," *Arthritis Care & Research* 55, no. 6 (2006): 978–981, https://doi.org/10.1002/art.22351.

12. C. I. Daien, A. Monnier, P. Claudepierre, et al., "Sarcoid-Like Granulomatosis in Patients Treated With Tumor Necrosis Factor Blockers: 10 Cases," *Rheumatology* 48, no. 8 (2009): 883–886, https://doi.org/10.1093/rheumatology/kep046.

13. H. Takahashi, K. Kaneta, M. Honma, et al., "Sarcoidosis During Infliximab Therapy for Crohn's Disease," *Journal of Dermatology* 37, no. 5 (2010): 471–474, https://doi.org/10.1111/j.1346-8138.2010.00861.x.

14. K. C. Fok, W. W. S. Ng, C. J. A. Henderson, and S. J. Connor, "Cutaneous Sarcoidosis in a Patient With Ulcerative Colitis on Infliximab," *Journal of Crohn's and Colitis* 6, no. 6 (2012): 708–712, https://doi.org/10.1016/j.crohns.2012.01.008.

15. P. G. Kotze, I. F. de Barcelos, and L. M. da Silva Kotze, "Sarcoidosis During Therapy With Adalimumab in a Crohn's Disease Patient: A Paradoxical Effect," *Journal of Crohn's and Colitis* 7, no. 11 (2013): e599–e600, https://doi.org/10.1016/j.crohns.2013.06.002.

16. M. J. McDonnell, R. M. Rutherford, and A. O'Regan, "Sarcoidosis Complicating Treatment With Adalimumab for Crohn's Disease," *Journal of Crohn's and Colitis.* 8, no. 9 (2014): 1140–1141, https://doi.org/10.1016/j.crohns.2014.02.006.

17. M. Villemaire, J. C. Cartier, N. Mathieu, et al., "Renal Sarcoid-Like Granulomatosis During Anti-TNF Therapy," *Kidney International* 86, no. 1 (2014): 215, https://doi.org/10.1038/ki.2013.452.

18. D. A. Simonetto and K. A. Papadakis, "New-Onset Paresthesias in Inflammatory Bowel Disease," *Gastroenterology* 148, no. 5 (2015): 906–907, https://doi.org/10.1053/j.gastro.2014.12.040.

19. T. Numakura, T. Tamada, M. Nara, et al., "Simultaneous Development of Sarcoidosis and Cutaneous Vasculitis in a Patient With Refractory Crohn's Disease During Infliximab Therapy," *BMC Pulmonary Medicine* 16, no. 1 (2016): 30, https://doi.org/10.1186/s12890-016-0193-5.

20. G. E. Gîlcă, S. Diaconescu, G. Gh Bălan, O. Timofte, and G. Ştefănescu, "Sarcoidosis Associated With Infliximab Therapy in Ulcerative Colitis," *Medicine (Baltimore)* 96, no. 10 (2017): e6156, https://doi.org/10.1097/md.0000000000006156.

21. T. K. Kim, S. H. Kang, H. S. Moon, J. K. Sung, H. Y. Jeong, and H. S. Eun, "Pulmonary Sarcoidosis That Developed During the Treatment of a Patient With Crohn Disease by Using Infliximab," *Ann Coloproctol* 33, no. 2 (2017): 74–77, https://doi.org/10.3393/ac.2017.33.2.74.

22. M. S. Ali, R. Franco, D. Dhotre, and N. Rao, "Tumour Necrosis Factor (TNF) Inhibitor-Induced Isolated Pleural Granulomas: A Rare Adverse Effect," *BMJ Case Reports* 2017 (2017): bcr2017219883, https://doi.org/10.1136/bcr-2017-219883.

23. M. Okoshi, H. Sato, T. Honma, and S. Terai, "Rare Paradoxical Adverse Event in Crohn's Disease: A Case Report," *Annals of Translational Medicine* 8, no. 4 (2020): 133, https://doi.org/10.21037/atm.2019.12.122.

24. S. Fukahori, Y. Obase, C. Fukushima, et al., "Determining Response to Treatment for Drug-Induced Bronchocentric Granulomatosis by the Forced Oscillation Technique," *Medicina (Kaunas)* 57, no. 12 (2021): 1315, https://doi.org/10.3390/medicina57121315.

25. S. Kashima, K. Moriichi, K. Ando, et al., "Development of Pulmonary Sarcoidosis in Crohn's Disease Patient Under Infliximab Biosimilar Treatment After Long-Term Original Infliximab Treatment: A Case Report and Literature Review," *BMC Gastroenterology* 21, no. 1 (2021): 373, https://doi.org/10.1186/s12876-021-01948-6.

26. E. Bargagli, A. Mazzi, and P. Rottoli, "Markers of Inflammation in Sarcoidosis: Blood, Urine, BAL, Sputum, and Exhaled Gas," *Clinics in Chest Medicine* 29, no. 3 (2008): 445–458, https://doi.org/10.1016/j.ccm.2008.03.004.

27. M. Harbord, V. Annese, S. R. Vavricka, et al., "The First European Evidence-Based Consensus on Extra-Intestinal Manifestations in Inflammatory Bowel Disease," *Journal of Crohn's and Colitis* 10, no. 3 (2016): 239–254, https://doi.org/10.1093/ecco-jcc/jjv213.

28. Statement on Sarcoidosis," *American Journal of Respiratory and Critical Care Medicine* 160, no. 2 (1999): 736–755.

29. C. Maaser, A. Sturm, S. R. Vavricka, et al., "ECCO-ESGAR Guideline for Diagnostic Assessment in IBD Part 1: Initial Diagnosis, Monitoring of Known IBD, Detection of Complications," *Journal of Crohn's and Colitis* 13, no. 2 (2019): 144–164K, https://doi.org/10.1093/ecco-jcc/jjy113.

30. Y. Arimone, I. Bidault, J. P. Dutertre, et al., "Updating the French Method for the Causality Assessment of Adverse Drug Reactions," *Therapie* 68, no. 2 (2013): 69–76, https://doi.org/10.2515/therapie/2013016.

31. J. Satsangi, M. S. Silverberg, S. Vermeire, and J. F. Colombel, "The Montreal classification of Inflammatory Bowel Disease: Controversies, Consensus, and Implications," *Gut* 55, no. 6 (2006): 749–753, https://doi.org/10.1136/gut.2005.082909.

32. R. F. Harvey and J. M. Bradshaw, "A Simple Index of Crohn's-Disease Activity," *Lancet* 1, no. 8167 (1980): 514, https://doi.org/10.1016/s0140-6736(80)92767-1.

33. J. D. Lewis, S. Chuai, L. Nessel, G. R. Lichtenstein, F. N. Aberra, and J. H. Ellenberg, "Use of the Noninvasive Components of the Mayo Score to Assess Clinical Response in Ulcerative Colitis," *Inflammatory Bowel Diseases* 14, no. 12 (2008): 1660–1666, https://doi.org/10.1002/ibd.20520.

34. R. S. Wallis and S. Ehlers, "Tumor Necrosis Factor and Granuloma Biology: Explaining the Differential Infection Risk of Etanercept and Infliximab," *Seminars in Arthritis and Rheumatism* 34, no. 5, Supplement 1 (2005): 34–38, https://doi.org/10.1016/j.semarthrit.2005.01.009.

35. C. A. Hage, K. L. Wood, H. T. Winer-Muram, S. J. Wilson, G. Sarosi, and K. S. Knox, "Pulmonary Cryptococcosis After Initiation of Anti-Tumor Necrosis Factor-α Therapy," *Chest* 124, no. 6 (2003): 2395–2397, https://doi.org/10.1378/chest.124.6.2395.

36. K. Imaizumi, M. Sugishita, M. Usui, T. Kawabe, N. Hashimoto, and Y. Hasegawa, "Pulmonary Infectious Complications Associated With Anti-tnfα Therapy (Infliximab) for Rheumatoid Arthritis," *Internal Medicine* 45, no. 10 (2006): 685–688, https://doi.org/10.2169/internalmedicine.45.1623.

37. F. Caso, P. Galozzi, L. Costa, P. Sfriso, L. Cantarini, and L. Punzi, "Autoinflammatory Granulomatous Diseases: From Blau Syndrome and Early-Onset Sarcoidosis to NOD2-Mediated Disease and Crohn's Disease," *RMD Open* 1, no. 1 (2015): e000097, https://doi.org/10.1136/rmdopen-2015-000097.

38. H. Black, M. Mendoza, and S. Murin, "Thoracic Manifestations of Inflammatory Bowel Disease," *Chest* 131, no. 2 (2007): 524–532. https://doi.org/10.1378/chest.06-1074.

Supporting Information

Additional supporting information can be found online in the Supporting Information section.