



15TH EROC GLOBAL FORUM 2026

15 – 17 JANUARY 2026
INTERCONTINENTAL FESTIVAL CITY, DUBAI, UAE

Supported By



In Conjunction with



Union of the European Phoniaticians



Korean Society of Otorhinolaryngology-Head and Neck Surgery

 www.eroc.ae



Anatomy of the larynx

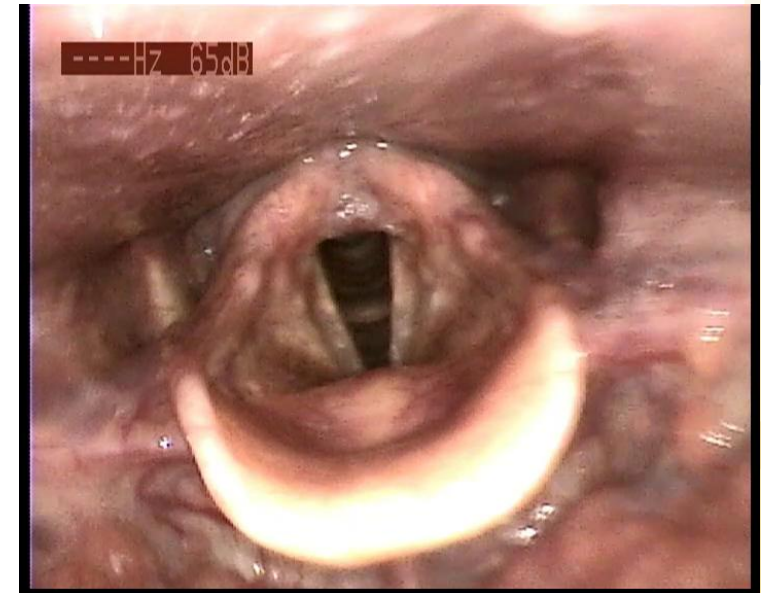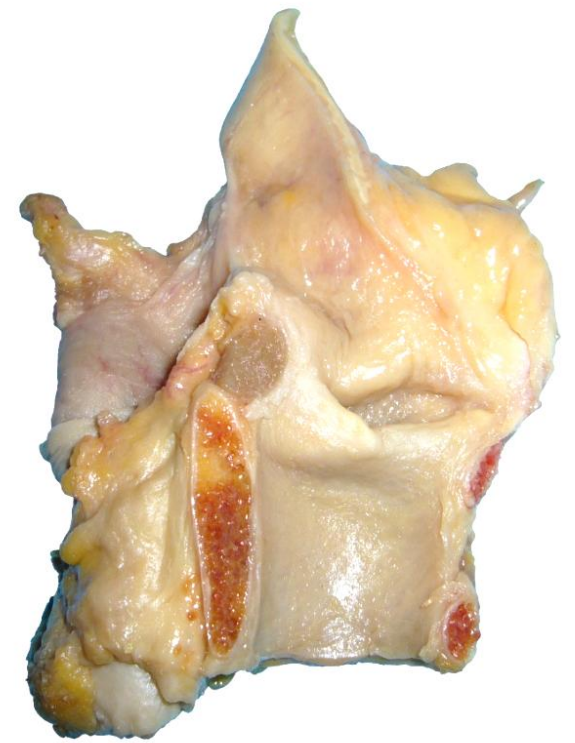
Focus on the laryngeal vestibule

A.Lagier, L. Dugardin, C. Darimont, V. Defaweux
Liège, Belgium

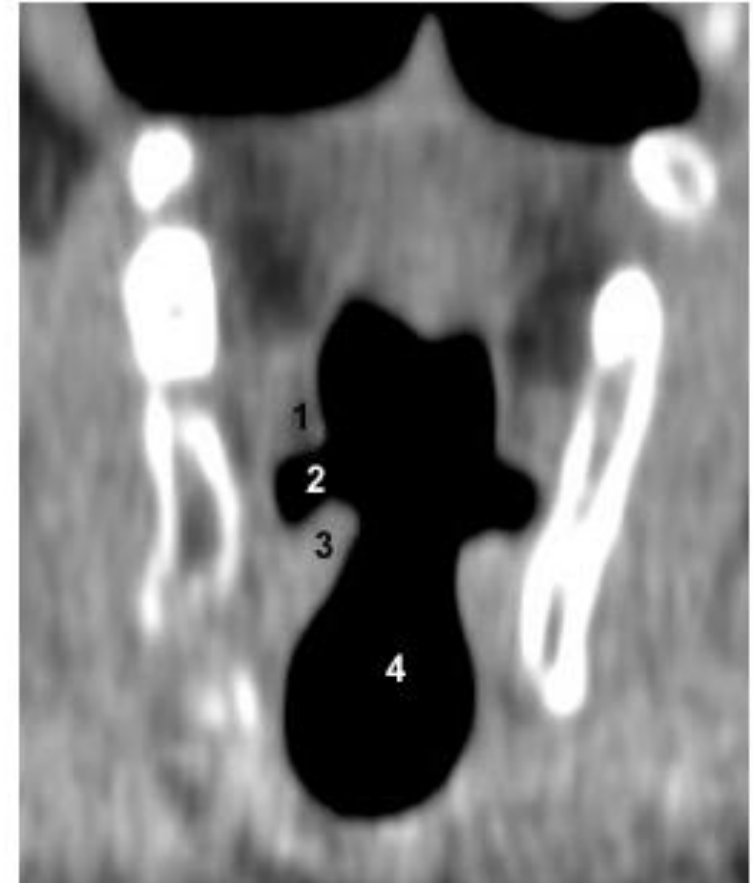


The vestibule of the larynx

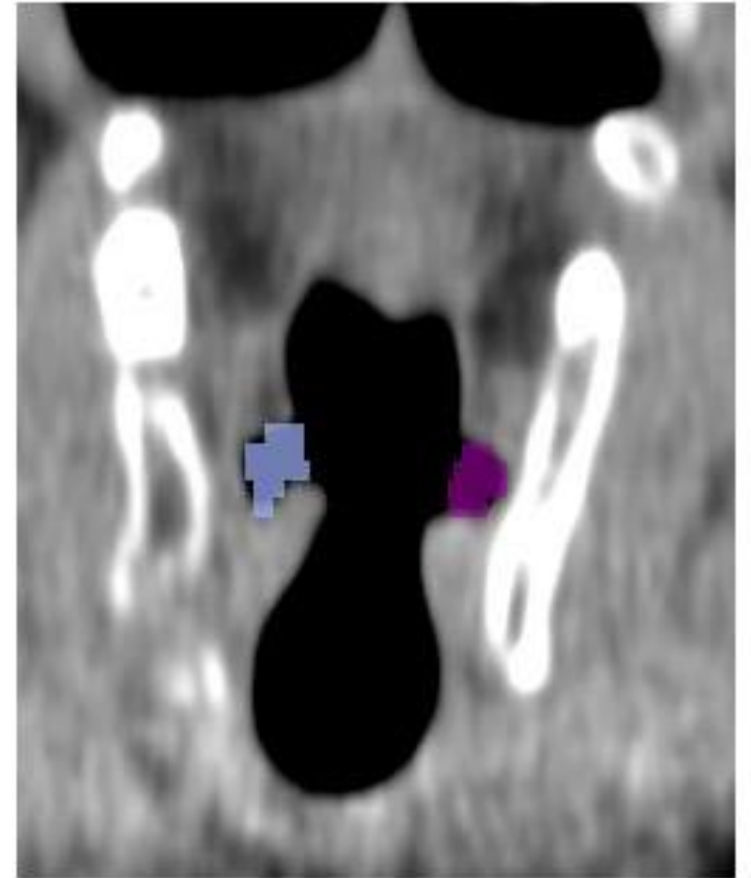
- Area of the larynx limited
 - upward: by the aditus of the larynx
 - Downward: the superior aspect of the vocal folds
- Content
 - Vestibular folds
 - Laryngeal ventricle
- Roles
 - Swallowing: airtight seal
 - Voice:
 - Low physiologic involvement in speech
 - Significant involvement in some singing notes or styles
 - Significant involvement in most dysphonic patients

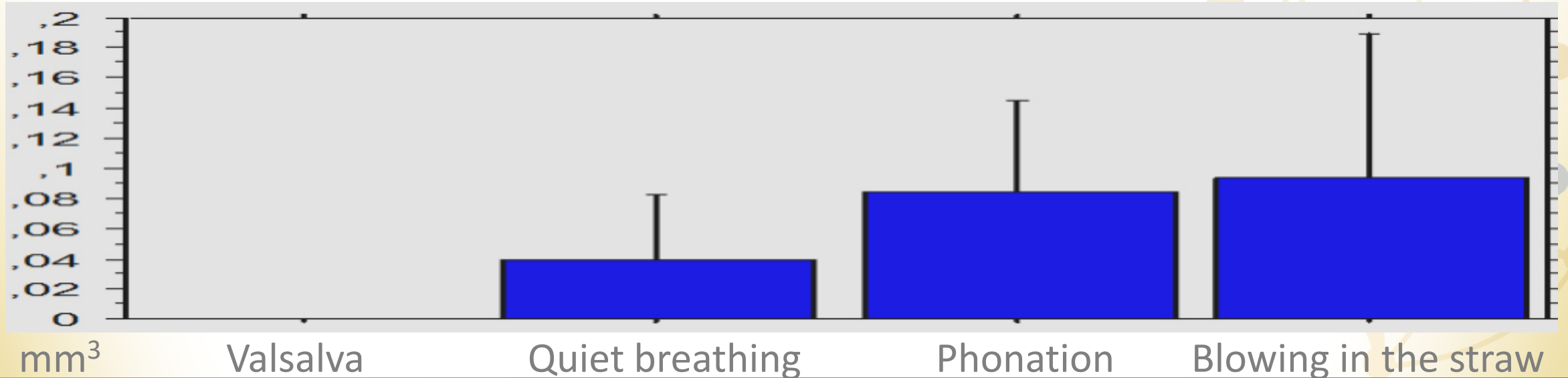
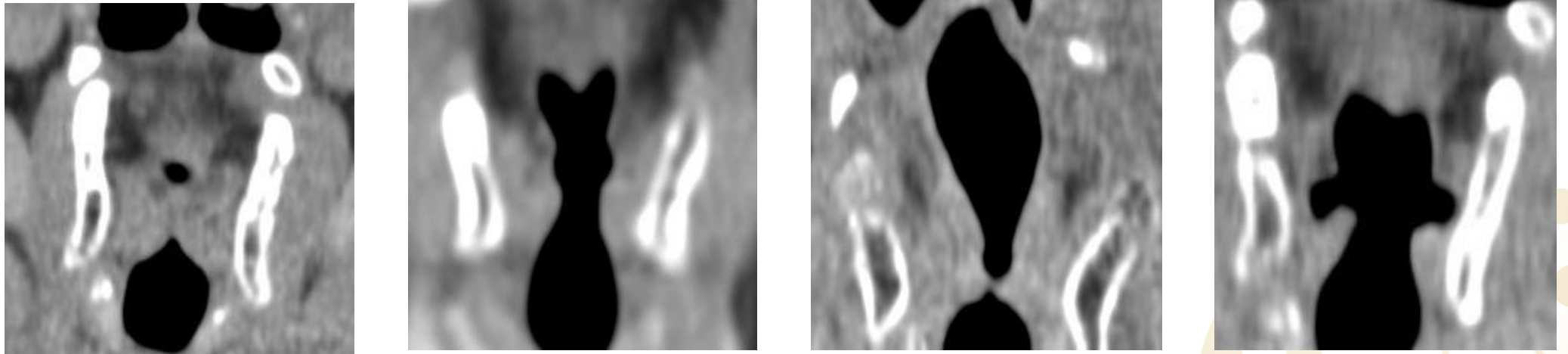


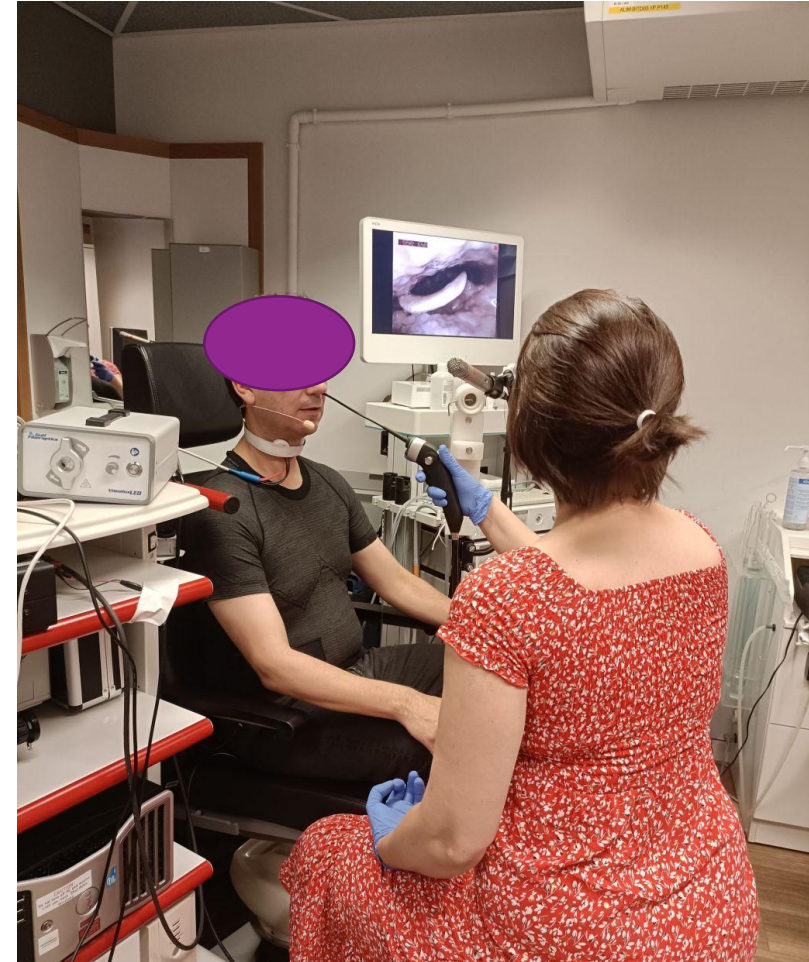

- Diverticulum
 - Into the ary-epiglottic fold
 - Between
 - Superior aspect of the vocal fold
 - Free edge of the vestibular fold.
- First resonance cavity of the supra-glottal tract
low-pass filter has been known for long.
- Dimension and shape of the ventricle
 - Vary during phonation depending on the vowel, pitch, SPL
 - Depend on the positions and shapes of the vocal and vestibular folds
 - Controlled mainly by the thyroarytenoid muscle



- CT-scans of 19 patients with normal larynx
- 4 tasks: quiet breathing, phonation, blowing in a narrow straw (1mm diameter) or during Valsalva maneuver.
- Using high resolution 3-D CT-scan data,
 - Measures in the frontal and axial planes, and volumetric analysis
 - Myrian[®] software (Intrasense, France).
 - The volume of the ventricle determined using manual contouring of the ventricle



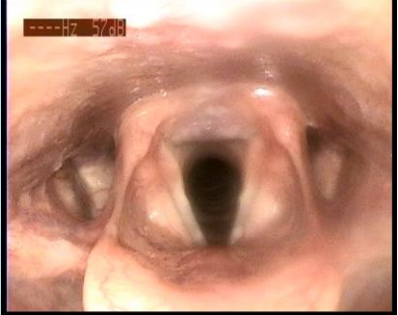



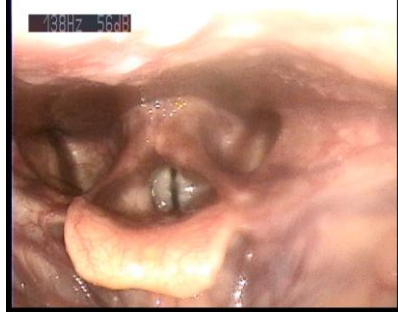


Falsetto Estill

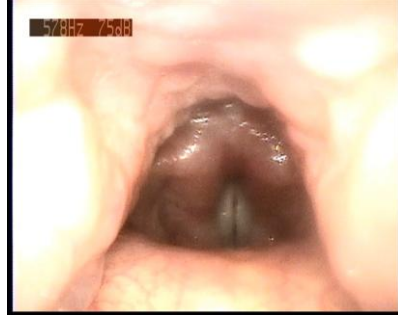Open



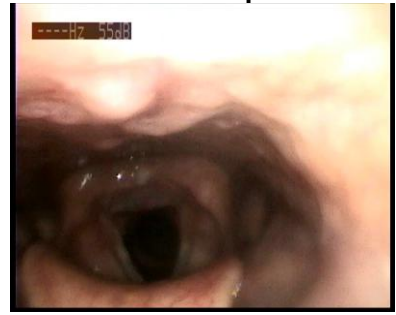
Fo min



Fo max

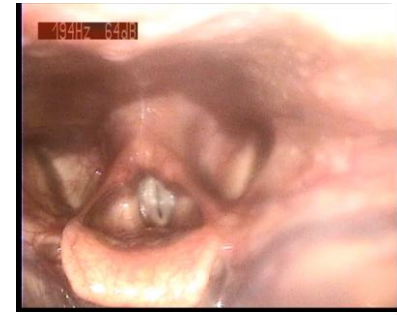

Open

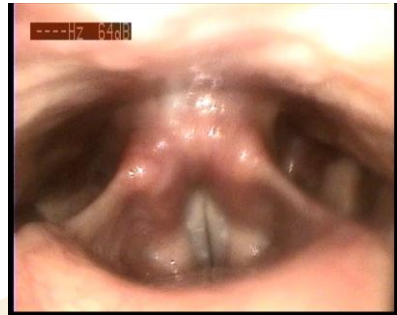

Opera Estill

Fo min

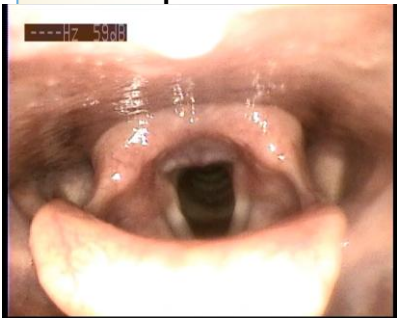

Fo max

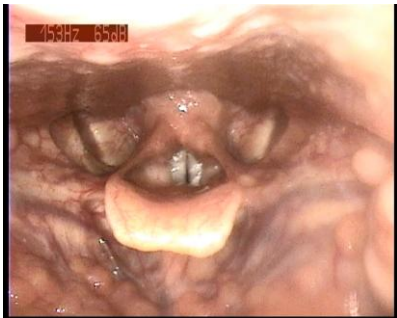

Voice Range Profile « usual »

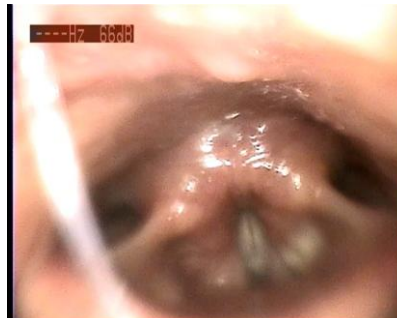Open



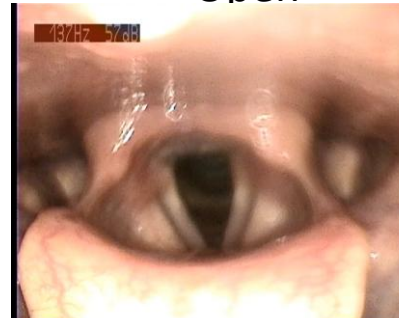Fo min



Fo max

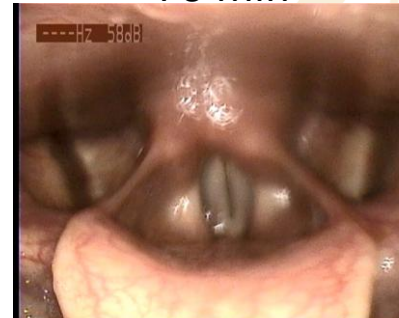

Open

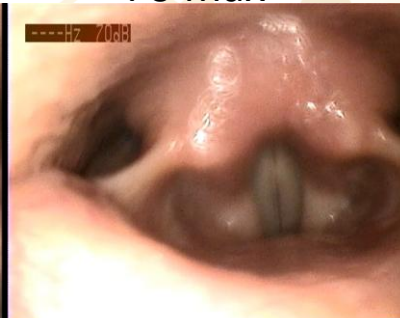

Glissando

Fo min

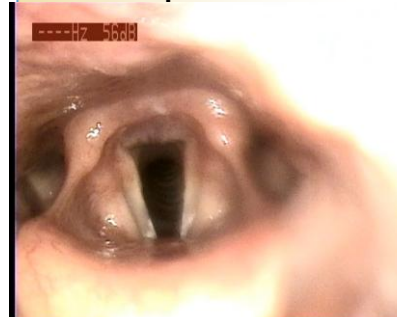

Fo max

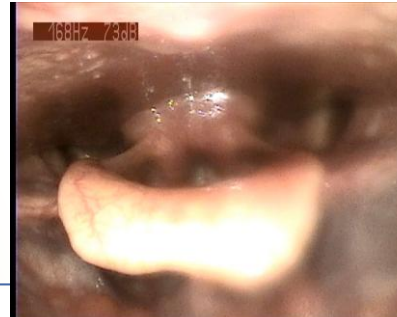

Twang Estill

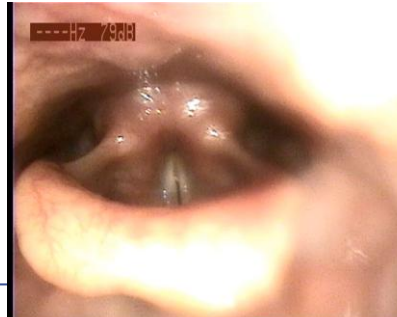Open



Fo min

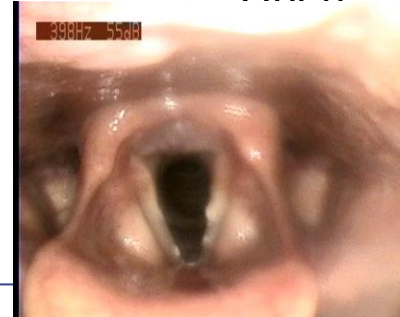

Fo max

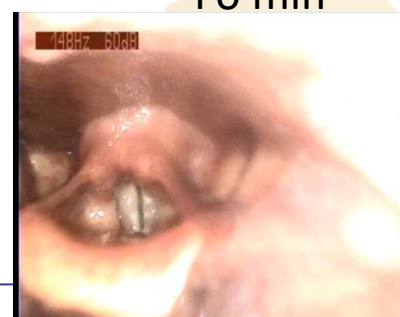

Speech Estill

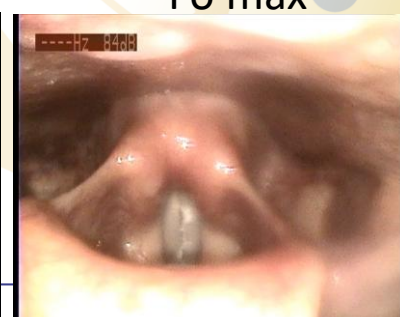Open



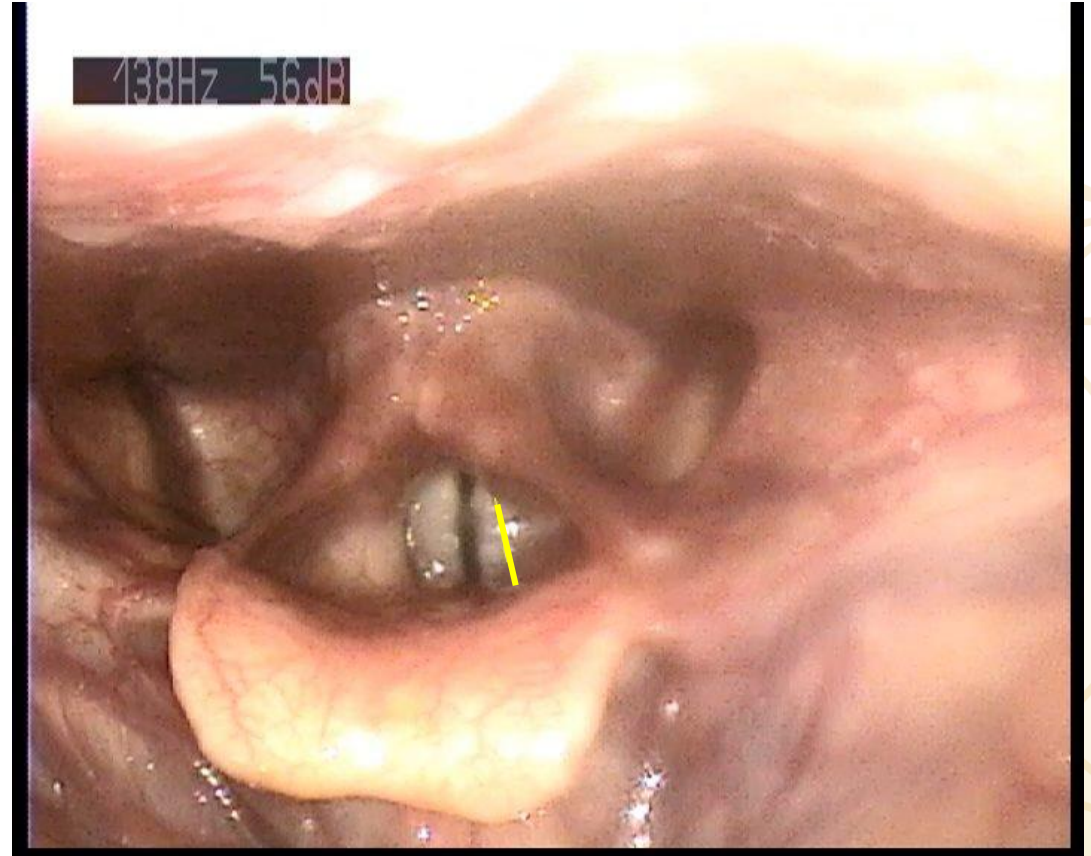
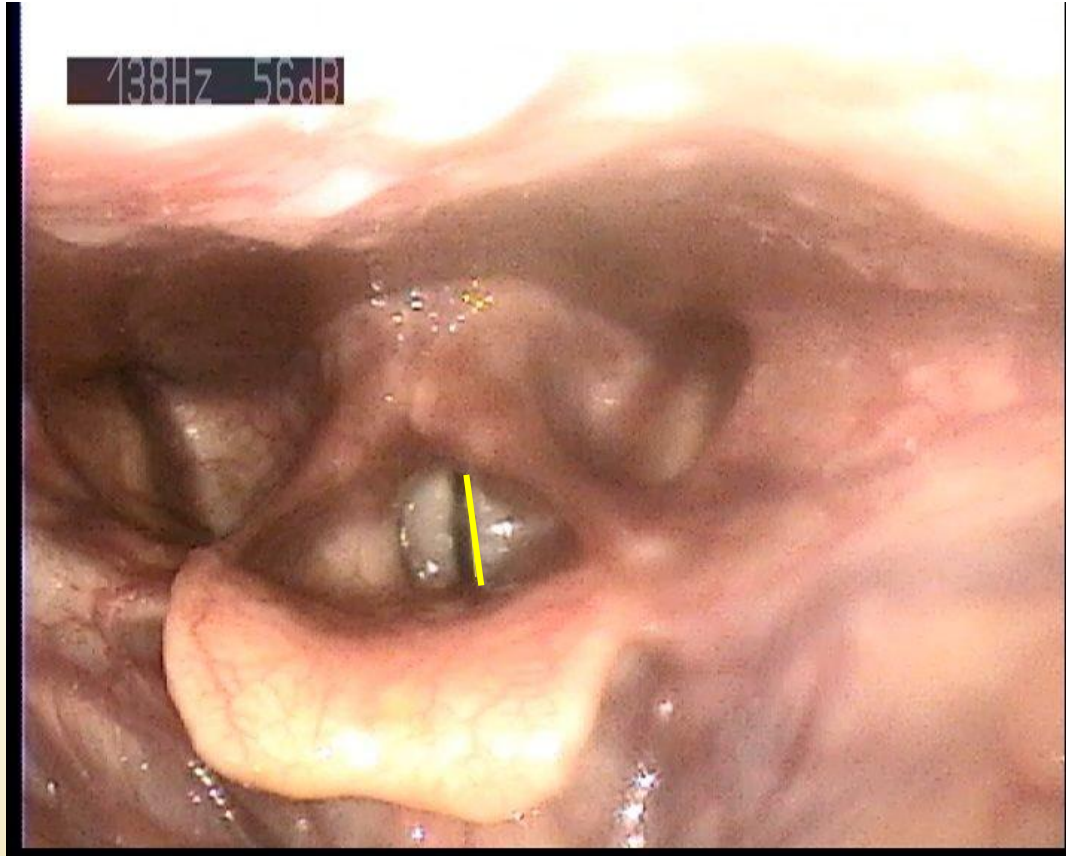
Fo min



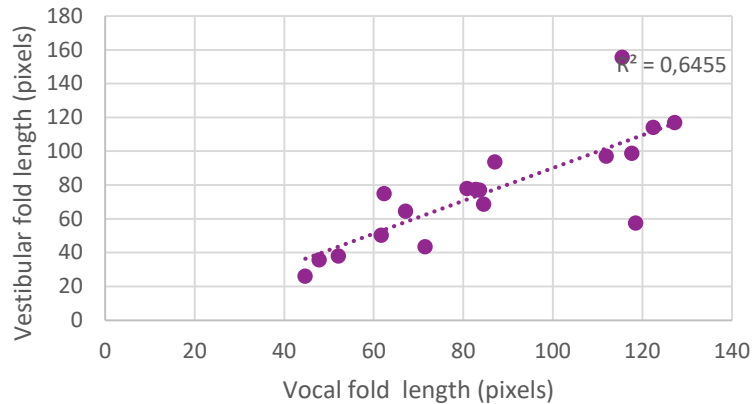
Fo max



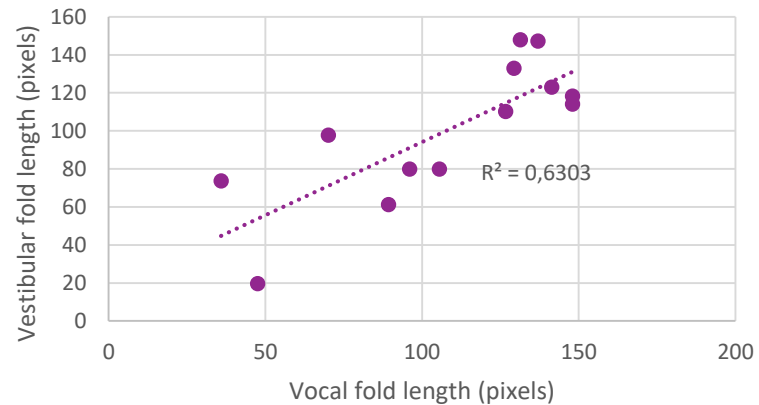
Vestibular folds length



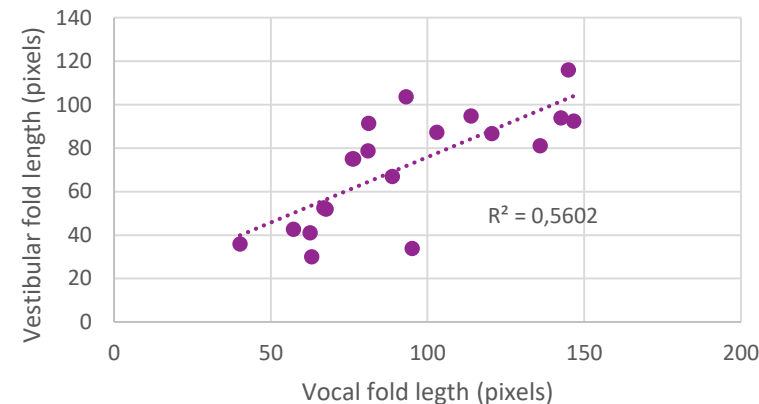
S1



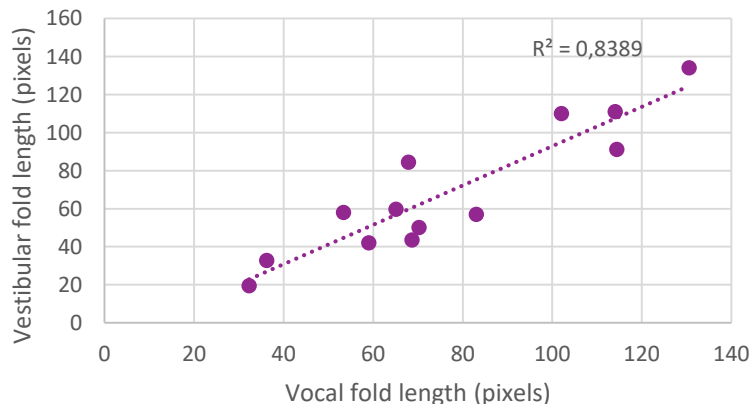
S3



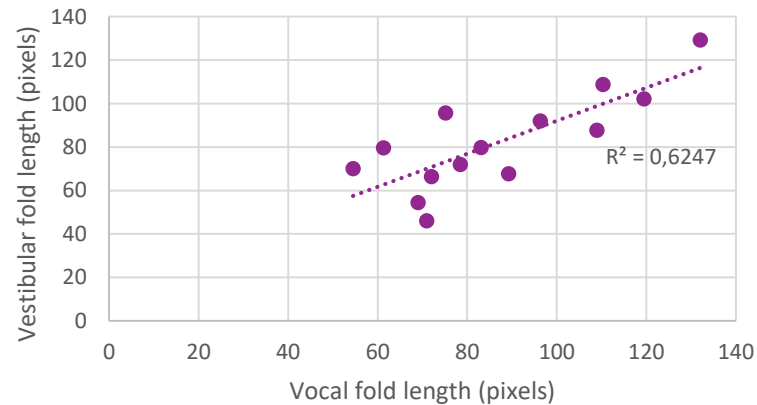
S4



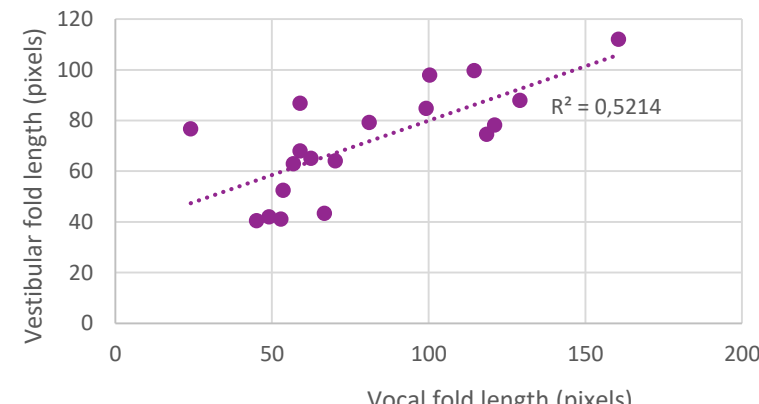
S5



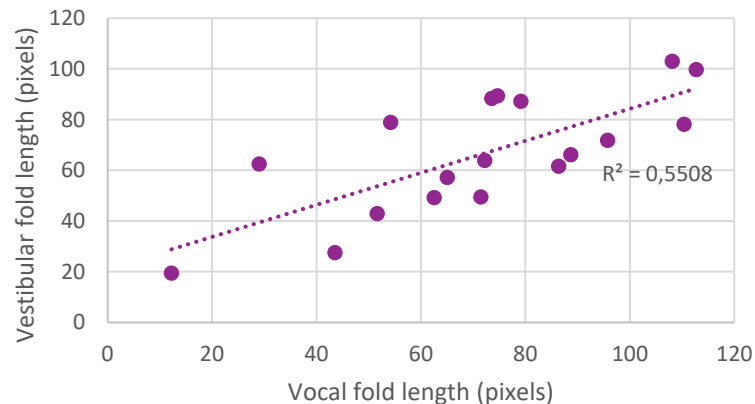
S6



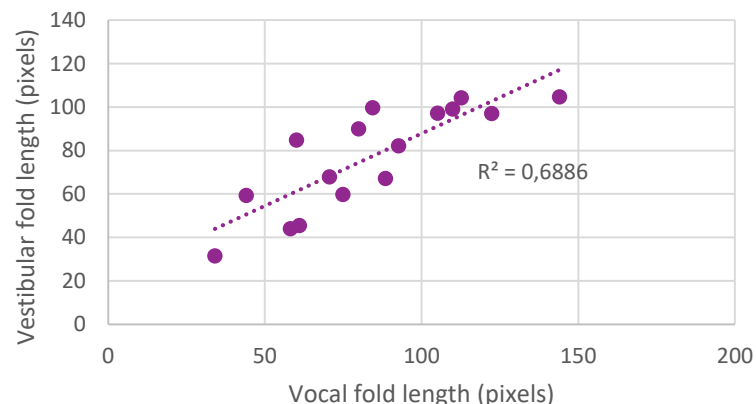
S7



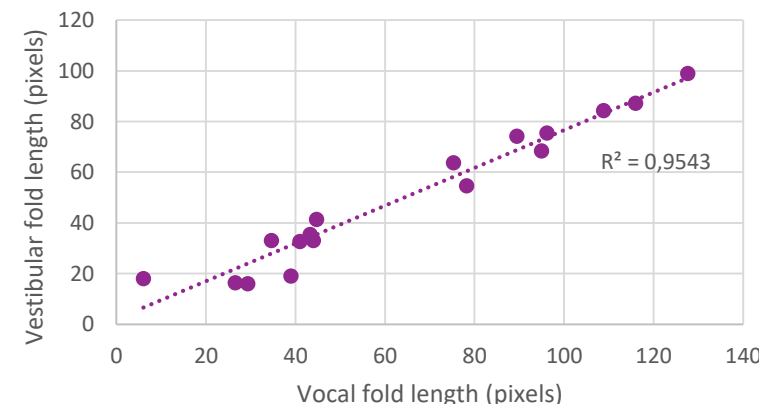
S8

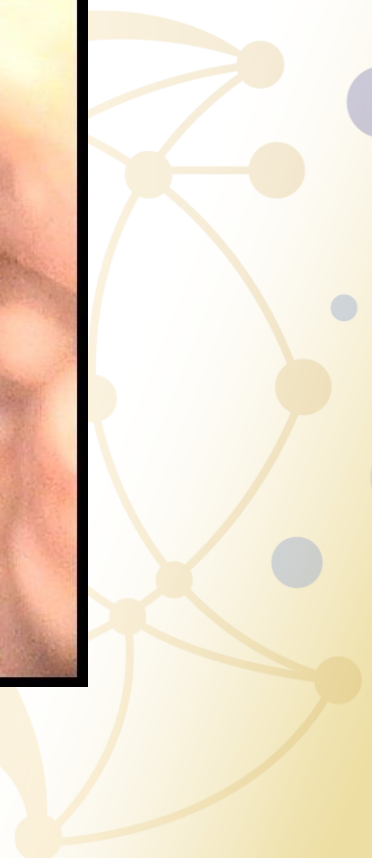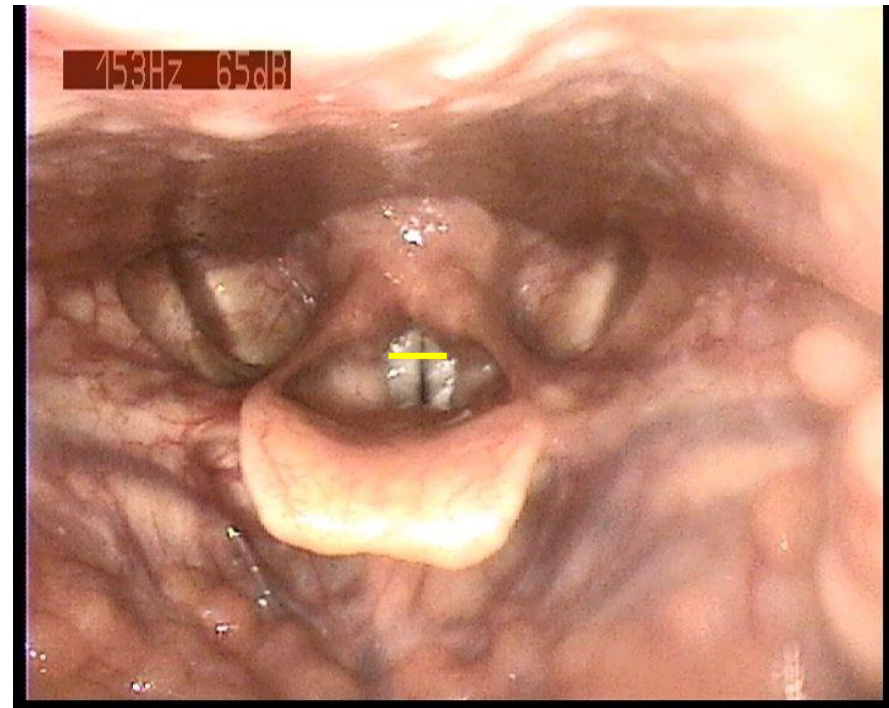
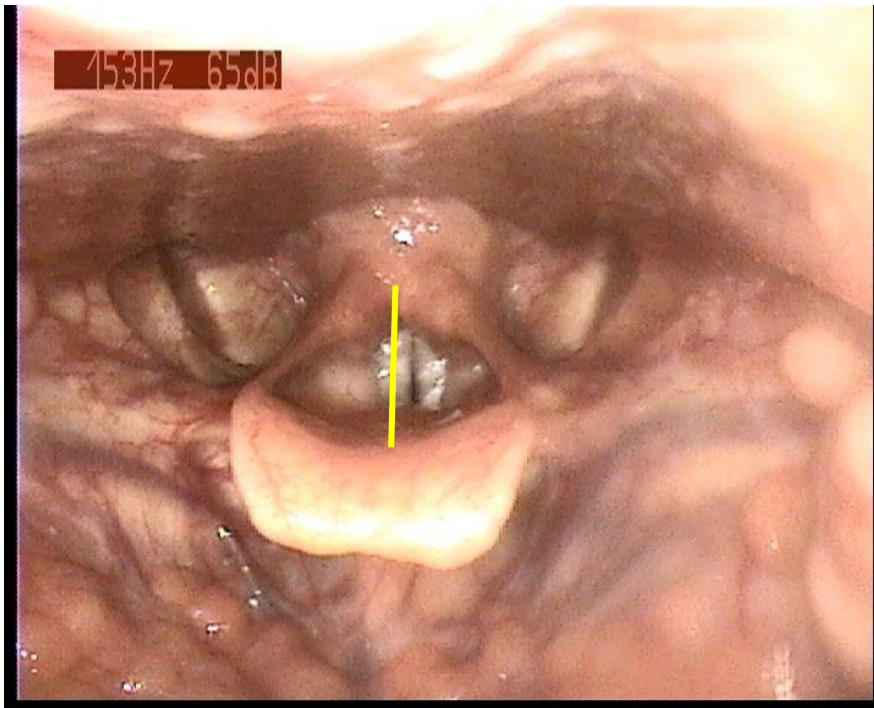


S9

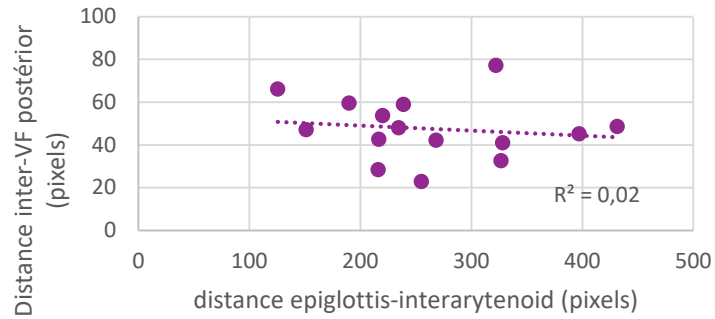


S10

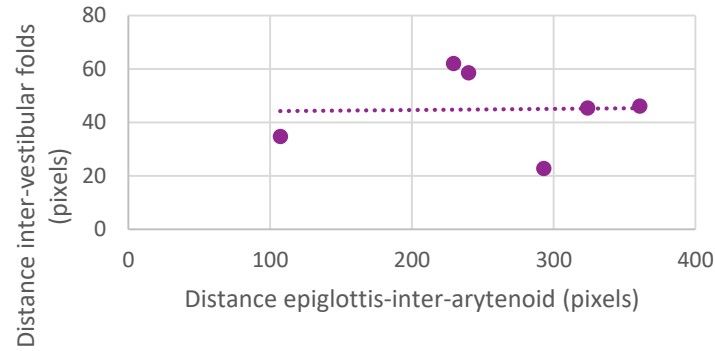




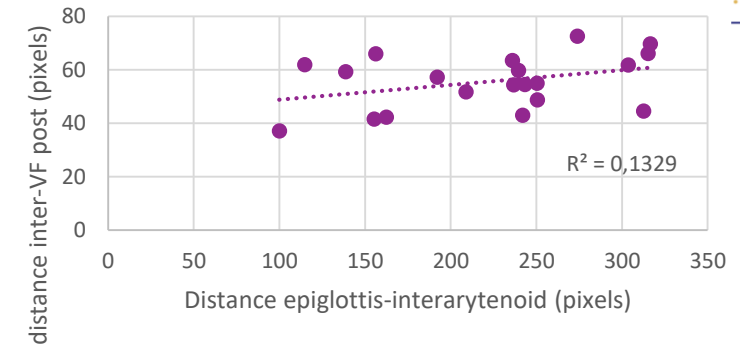
S1, F, trained



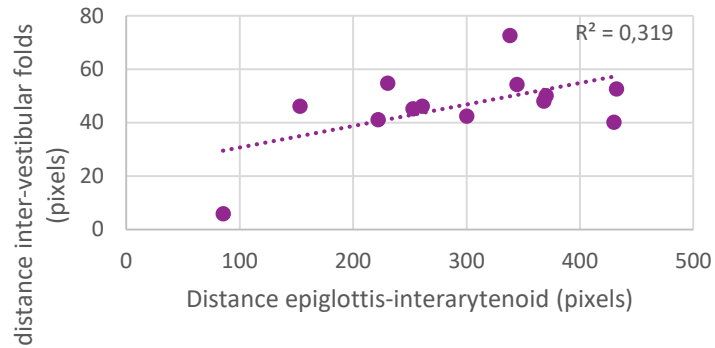
S3, F, trained



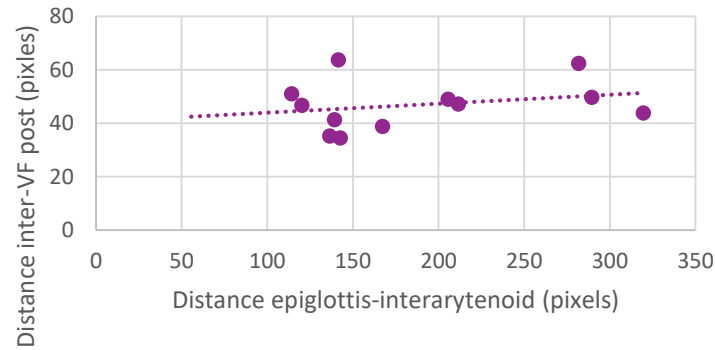
S4, F, trained



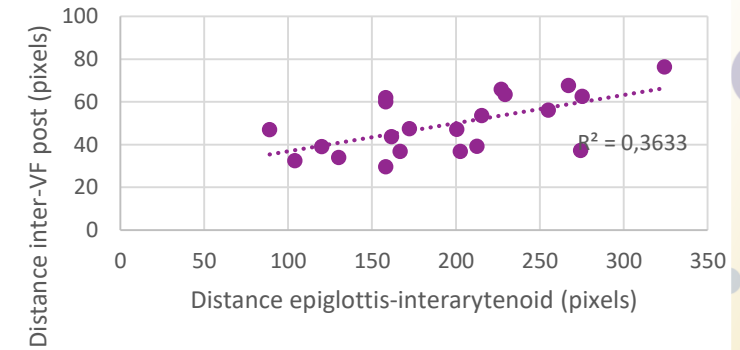
S5, M, untrained



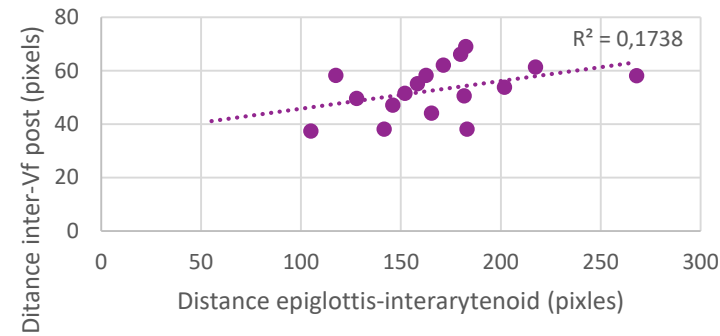
S6, F, untrained, nodules



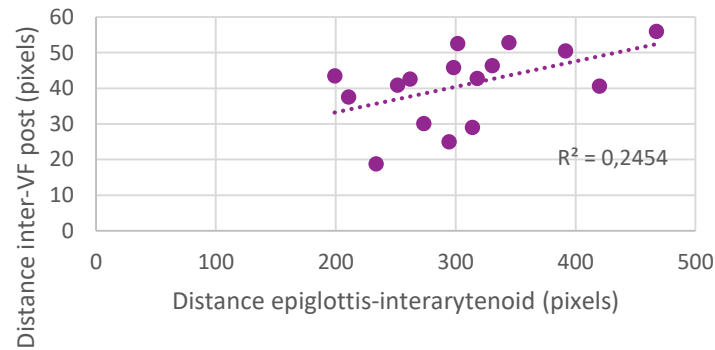
S7, F, trained



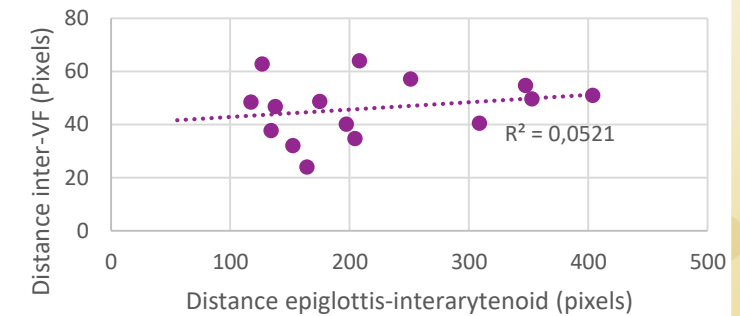
S8, F, trained



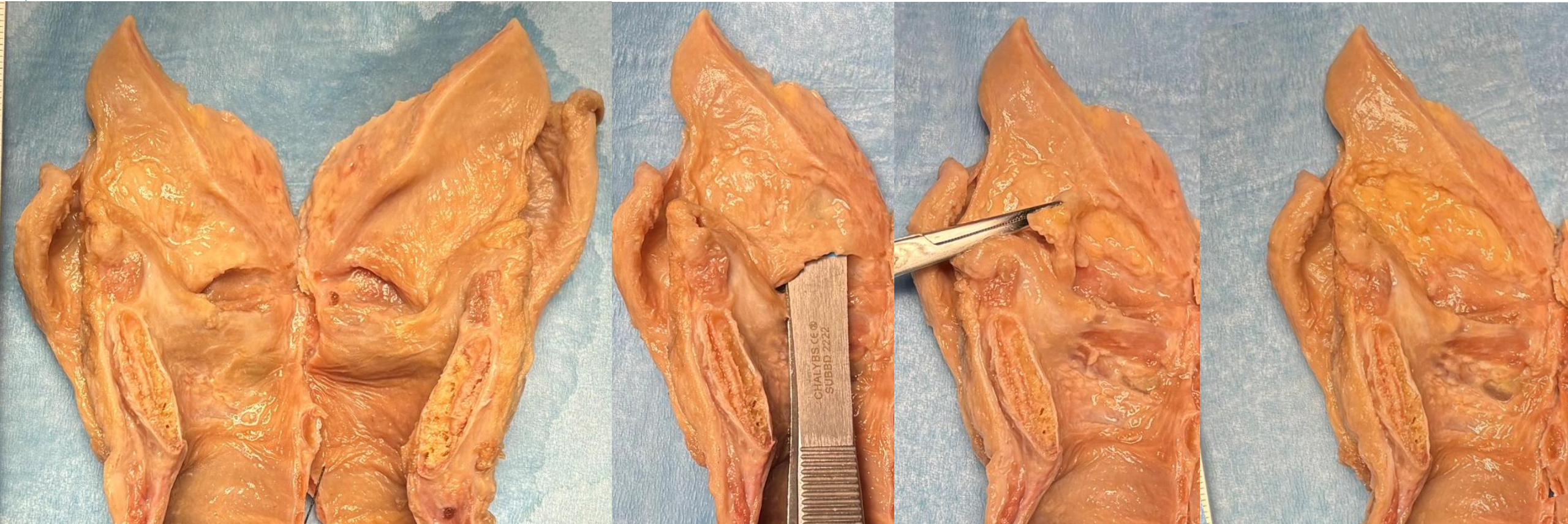
S9, M, untrained



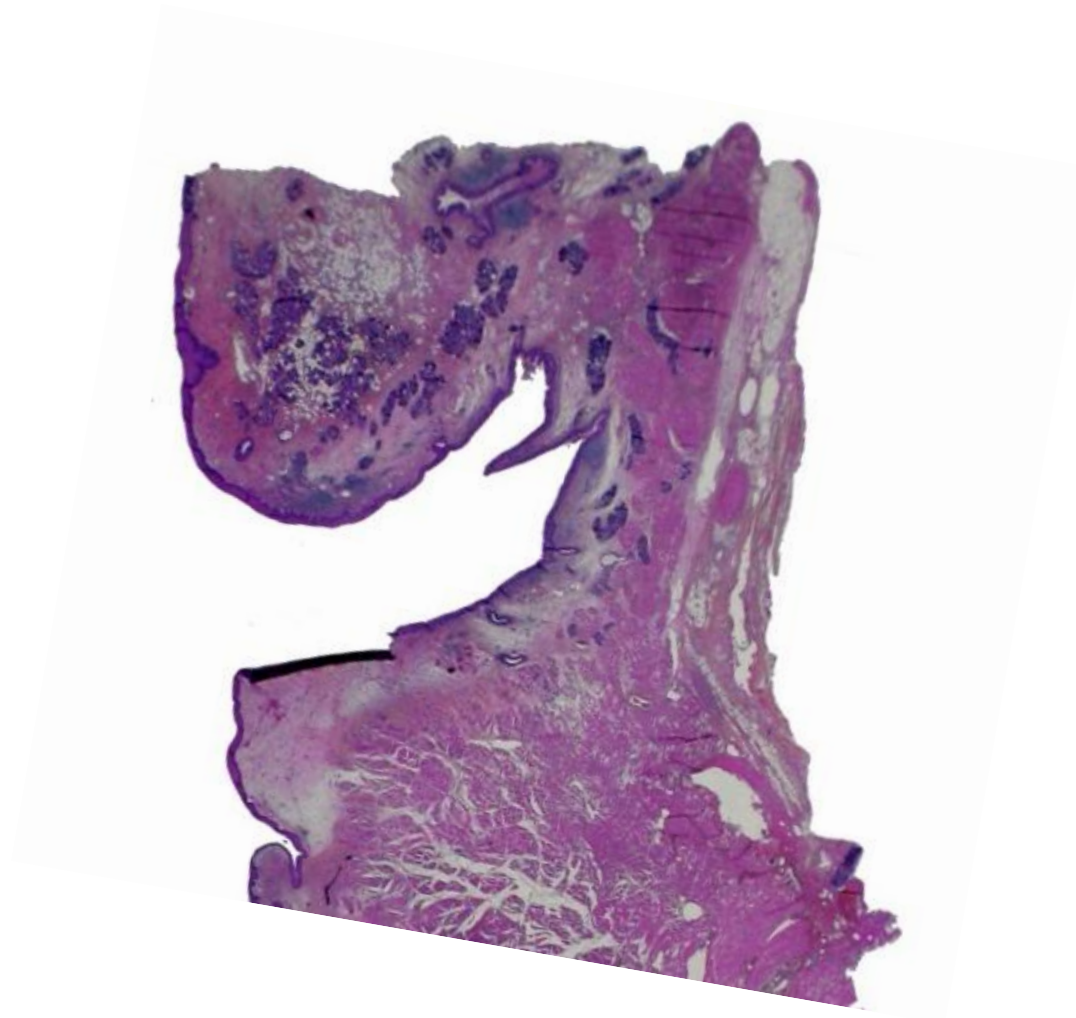
S10, F, untrained



- We need muscles to control the shapes...



- We need muscles to control the shapes...



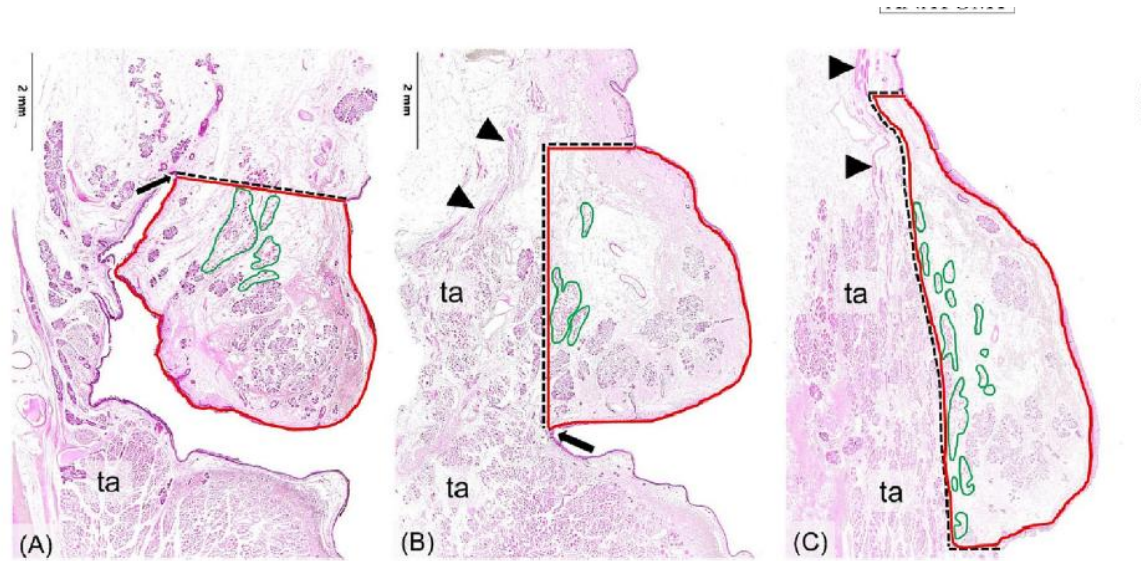


FIGURE 3 Boundaries of coronally sectioned vestibular folds at the anterior third (level 1) in (A), mid-third (level 2) in (B) and posterior third (level 3) in (C) encircled in red. Dashed lines mark the upper, lateral, and lower boundaries. The upper borders are defined: in level 1 (A) as a line drawn between the upper limit of the medial bulge of vestibular tissue and the laryngeal apex (arrow). In level 2 (B) they are defined by a horizontal line through the upper limit of the medial bulge ending at a vertical line through the deepest point of the laryngeal ventricle (arrow). In level 3 (C) they are shown as a horizontal line through the upper limit of the medial bulge. The lower borders are found in levels 2 and 3 at the deepest point of the laryngeal ventricle and/or on a horizontal line through the lower limit of the medial bulge. The lateral borders of levels 2 and 3 are the innermost layer of the lateral (external) part of the thyroarytenoid muscle (ta). The areas of ventricularis muscle fibers measured are marked in green. Arrowheads indicate muscle bundles representing the thyroepiglottic part of the thyroarytenoid muscle (B) and aryepiglottic part of the oblique arytenoid muscle (C). HE stains; ta thyroarytenoid muscle (external part).

Median area of vestibular fold: 27,5 mm²
 Median area of muscle fibers 1,5mm²

Histology of the vestibular folds

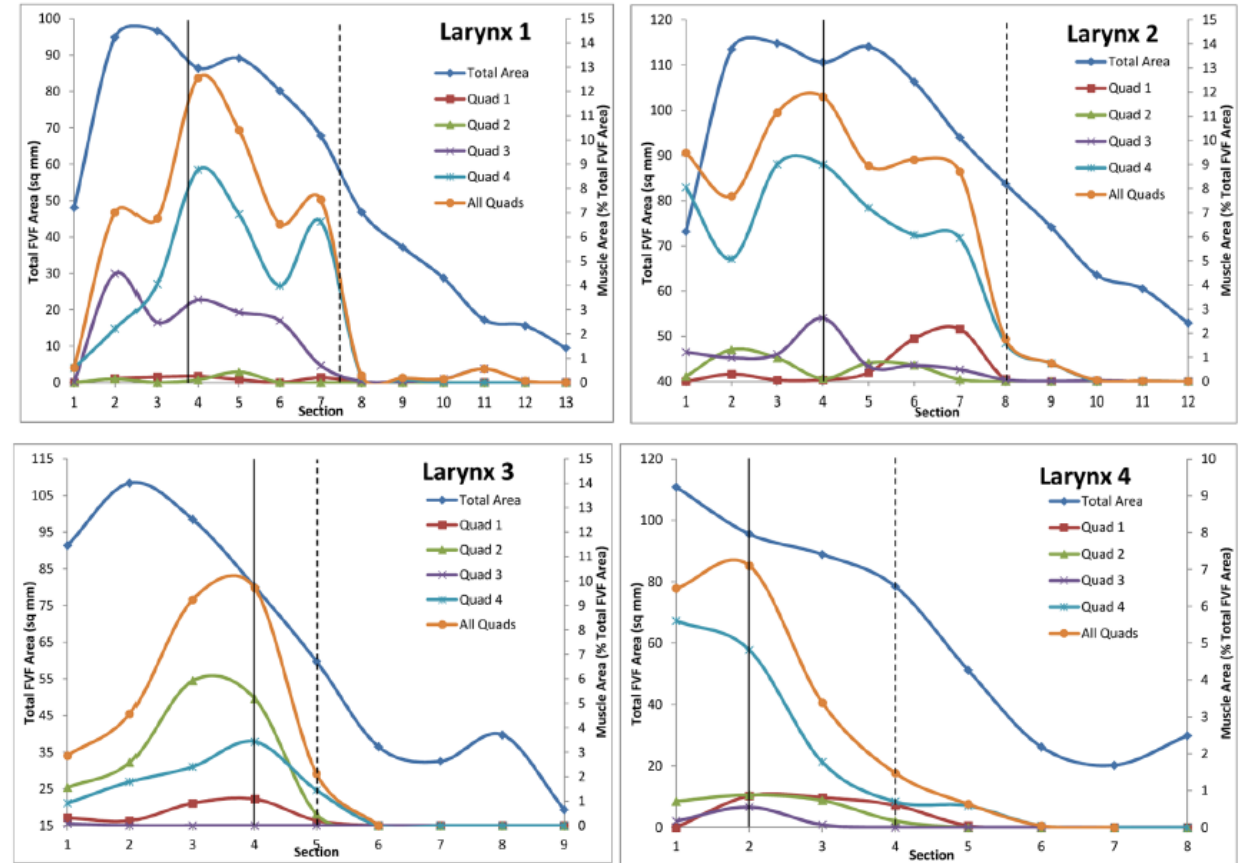
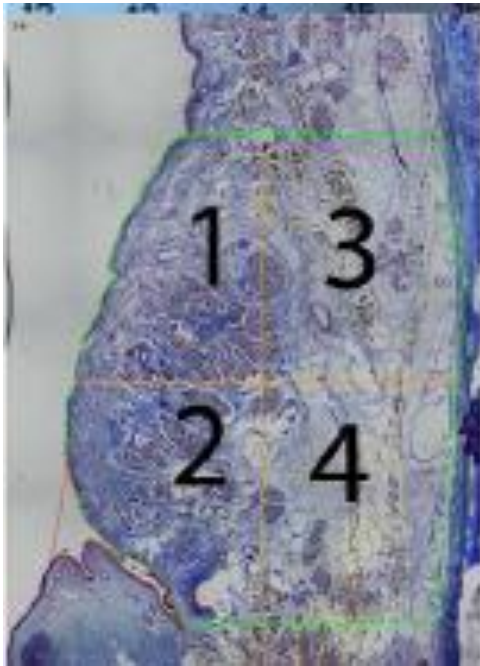


Figure 2. Total FVF cross-sectional area (left y-axis) and muscle cross-sectional area within each quadrant and all quadrants combined expressed as a percentage of total FVF area (right y-axis) for four larynges. Solid black vertical line represents anterior margin of vocal process of arytenoid. Dashed vertical line represents section first showing communication between laryngeal ventricle and laryngeal saccule.

Moon, J., & Alipour, F. (2013). Muscular anatomy of the human ventricular folds. *The Annals of otology, rhinology, and laryngology*, 122(9), 561–567.

<https://doi.org/10.1177/000348941312200905>

- Contraction of the lateral part of the TA is likely to induce:
 - Shortening of the vestibular fold
 - Approximation epiglottis-arytenoids
 - Some bulking in the vestibular fold
 - Narrowing the laryngeal vestibule
- Occlusion of the laryngeal ventricle
 - With negative acoustic impacts
- Control of the vestibular folds bulking?
 - They may behave like an hydrostat
 - Instead of a direct motor/muscular control

