

A Multimodal Assessment of Visual Impairments in Post-Coma Patients

Atakan Selte^{1,2,3,#}, MD, Leandro R. D. Sanz^{1,4,5,#}, MD, Cécile Andris^{1,4,6}, MD, Aurore Thibaut^{1,4,7}, PhD, Stephen K. Larroque¹, MSc, Claire Bernard^{4,8}, MD, Roland Hustinx^{4,8}, MD, Steven Laureys^{1,9,10,11}, MD, Arianna Sala^{1,4,7*}, PhD, Olivia Gosseries^{1,4*}, PhD

1. Coma Science Group, GIGA Consciousness, University of Liège, Liège, Belgium
2. Department of Neurology, University of Wisconsin-Madison, Madison, WI, USA
3. Department of Neurology, Harbor-UCLA Medical Center, Torrance, California, USA
4. NeuroRehab & Consciousness Clinic, Neurology department, University Hospital of Liège, Liège, Belgium
5. Service of Neurology, Department of Clinical Neurosciences, Lausanne University Hospital and University of Lausanne, Lausanne, Switzerland
6. Department of Ophthalmology, University Hospital of Liège, Liège, Belgium
7. NeuroRecovery Lab, GIGA Consciousness, University of Liège, Liège, Belgium
8. Department of Nuclear Medicine, University Hospital of Liege, Liege, Belgium
9. Joint International Research Unit on Consciousness, CERVO Brain Research Centre, Laval University, Canada
10. Anesthesia, Critical Care and Pain Medicine Research, Harvard Medical School, Beth Israel Deaconess Medical Center, Boston, USA
11. International Consciousness Science Institute, Hangzhou Normal University, Hangzhou, China

#Contributed equally as first authors

*Contributed equally as last authors

Corresponding author: Olivia Gosseries, Coma Science Group, GIGA Research, B34, CHU de Liège, 11 Avenue de l'Hôpital, 4000 Liège. Email: ogosseries@uliege.be

Key Points

Question: What is the frequency and nature of visual impairments among post-coma patients with severe acquired brain injury?

Findings: This observational study found that a majority of post-coma patients display visual impairments with a severity and frequency that increase with the degree of consciousness alteration. Specifically, patients with unresponsive wakefulness syndrome had significantly more vision impairments, abnormal visual evoked potentials and visual network hypometabolism than patients in a minimally conscious state.

Meaning: Visual impairments are frequent among post-coma patients and vary with consciousness levels, highlighting the role of visual pathways in conscious behavior, as well as the necessity to systematically screen these patients for ophthalmological conditions.

Abstract

Importance: Post-coma patients typically present disorders of consciousness of varying degrees, which limit their ability to self-report visual disturbances. An early identification of visual impairments is crucial in these patients, as deficits may bias the diagnostic evaluations, with dramatic consequences on therapeutic decisions.

Objective: To examine the relationship between ophthalmological impairments, visual evoked potentials (VEPs), cerebral metabolism, and consciousness levels in post-coma patients with severe brain injuries.

Design: Observational cross-sectional study between 2009 and 2020.

Setting: Study conducted in a referral center for disorders of consciousness in Belgium.

Participants: Referred sample of 74 adult patients with a history of prolonged acquired severe brain injury resulting in coma (at least 28 days since brain injury), with a diagnosis of unresponsive

wakefulness syndrome/vegetative state (UWS/Vs), minimally conscious state (MCS), emergence from the MCS (eMCS) or locked-in syndrome (LIS). Thirteen patients were further excluded after initial screening.

Main Outcomes and Measures: Ophthalmology reports, VEP and [¹⁸F]fluorodeoxyglucose-positron emission tomography ([¹⁸F] FDG-PET) data were analyzed. Frequency of visual impairments was used as primary outcome measurement using ten ophthalmological features: eyelid, cornea, fundus, eye alignment, gaze deviation, pupillary reflex, ocular motility, visual pursuit and fixation. Secondary outcome measurements included VEP amplitudes (normal versus abnormal) and hypometabolic voxel count in visual regions using [¹⁸F] FDG-PET. Patients were stratified by diagnostic groups based on the Coma Recovery Scale - Revised.

Results: The final sample included 61 patients (27 female; mean age, 42.3 years), including 11 with UWS/Vs, 29 with MCS, 17 with eMCS, and 4 with LIS (median time since injury, 12 months). Seventy percent of patients exhibited at least one ophthalmological impairment (100% UWS/Vs, 69% MCS, 53% eMCS, and 75% LIS), with ocular motility impairment being the most frequent (31%). Abnormal VEPs were more common in UWS/Vs (40%) than in MCS (5%; $P = .03$). UWS/Vs patients had greater visual network hypometabolism compared with MCS ($P = .02$) and eMCS/LIS ($P = .02$), with no significant difference between MCS and eMCS/LIS ($P = .86$). The right occipital lobe showed a similar pattern, with UWS/Vs differing from MCS ($P = .02$) and eMCS/LIS ($P = .03$), but no difference between MCS and eMCS/LIS ($P = .64$).

Conclusions and Relevance: Visual impairments were present in 70% of patients. This high frequency calls for systematic screening of visual disturbances among severely brain-injured patients, especially those with altered consciousness where deficits may mask covert awareness. UWS/Vs patients had greater visual network hypometabolism compared to MCS and eMCS/LIS, with no differences between the latter groups. Increased VEP amplitude and [¹⁸F] FDG-PET metabolism were linked to fewer

ophthalmological impairments, highlighting the role of visual pathways in consciousness recovery and the potential of VEP and [¹⁸F]FDG-PET in predicting outcomes.

Keywords: Disorders of consciousness, visual evoked potentials, [¹⁸F] FDG-PET, visual network, unresponsive wakefulness syndrome, minimally conscious syndrome, emergence from minimally conscious syndrome, locked-in syndrome

Introduction

Disorders of consciousness (DoC) following brain injury include coma, unresponsive wakefulness syndrome/vegetative state (UWS/VS) and minimally conscious state (MCS).^{1,2} MCS is subdivided into MCS- and MCS+ based on the presence of language-related behaviors.^{3,4}

Clinical diagnosis relies primarily on behavioral assessment using standardized tools such as the Coma Recovery Scale-Revised (CRS-R), which evaluates domains including visual pursuit and fixation.^{5,6} While widely used, standardized behavioral evaluations can result in misdiagnosis rates up to 40% %, especially in patients with sensory or motor impairments that limit overt responses.^{2,7-10}

More objective methods such as electrophysiology (EEG, VEP) and neuroimaging (fMRI, PET) are increasingly used to complement clinical exams and identify covert consciousness.⁹⁻¹⁴

¹⁵ Visual behaviors, particularly pursuit and fixation, are critical indicators of consciousness and among the earliest signs of recovery from UWS/VS.^{16,17} However, the visual system itself may be impaired in DoC due to cortical, thalamic, brainstem, cranial nerve or ocular injury. Without ophthalmological evaluation, such impairments may go unrecognized, potentially confound diagnosis, delay recovery, or influence end-of-life decisions. Currently, there is no consensus on how and when to perform an ophthalmological assessment in DoC patients and many of these visual impairments go unnoticed due to

the patients' inability to communicate. Although studies have investigated brain metabolism using [¹⁸F] FDG-PET and evoked responses using visual evoked potentials (VEP), the relationship between these objective measures and clinically assessed visual function in DoC remains underexplored.

In this multimodal study, we assessed visual impairments in patients with prolonged DoC (i.e., UWS/VS and MCS), and with preserved consciousness (i.e., who emerged from MCS - eMCS - or with locked-in syndrome - LIS) based on detailed ophthalmological evaluations, CRS-R data, VEPs and [¹⁸F] FDG-PET imaging. We hypothesized that visual impairments would be more frequent in patients with lower clinical expression of consciousness, and would correlate with reduced VEP amplitude and hypometabolism

. Methods

Participants

We retrospectively included adult patients (>18 years old) diagnosed with UWS/VS, MCS, eMCS or LIS who were hospitalized in Liege University Hospital between 2009 and 2020. Clinical diagnosis was based on ≥ 3 CRS-R assessments^{6,18} (see Supplementary Methods) and current guidelines.^{19,20} Inclusion criteria also required a time since injury >28 days and a written report from an ophthalmological evaluation.

Electronic records of 74 patients were retrieved using an in-house open-source tool.²¹ After removing patients with non-standardized ophthalmological exams (n=10) and duplicate entries (n=3), 61 unique patients were included. VEP data were available for 32 patients, and [¹⁸F] FDG-PET imaging for 55; five PET scans were excluded due to extensive anatomical damage that precluded normalization. Thirty-three healthy participants (15 female, mean age 43.1) were included as controls for [¹⁸F] FDG-PET analyses²² (see flowchart, Figure 1). All procedures were approved by the University of Liege Ethics Committee. Written informed consent was obtained from legal representatives of all patients and healthy controls.

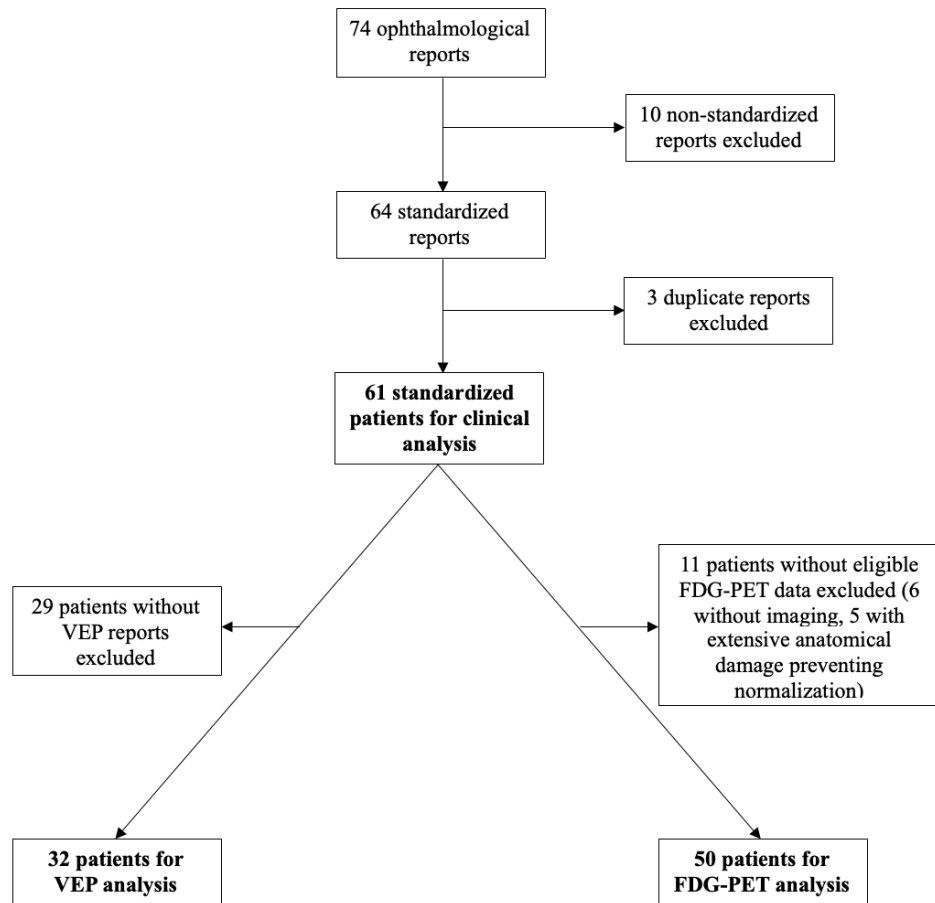


Figure 1. Flowchart of the study.

Clinical assessment

All included patients underwent an ophthalmological evaluation (systematically performed as part of a multimodal assessment of consciousness). Reports were retrieved by searching for the word “ophthalm” in the database. Reports were screened for 15 features defined collectively between a neuro-ophthalmologist (CA) and DoC experts (AS, LS, OG): eyelid, cornea, fundus, eye alignment, gaze deviation, baseline pupils, pupillary reflex, ocular motility, nystagmus, oculocephalic reflex, visual pursuit, fixation, visual acuity, visual field, and VEP. Ten features were analyzed, excluding those with excessive missing data (pupillary reflex, oculocephalic reflex, nystagmus, visual field, visual acuity).

Each feature was scored as normal, abnormal, not testable, or missing. If multiple evaluations were performed, the most comprehensive was used.

Clinical features were compared across three diagnostic groups: UWS/VS, MCS and eMCS/LIS (communicative group that recovered from DoC, as previously done²³). Total visual impairments per patient were summed for correlation with imaging and electrophysiology data. Visual fixation and visual pursuit reported by the ophthalmologists and the CRS-R examiners were also compared to assess if there was a possible discrepancy.

Visual evoked potentials amplitude

VEPs were recorded using standard clinical procedures (see Supplementary Methods for details) Responses were analyzed quantitatively using N1-P1 amplitudes from both eyes.

Brain metabolism

[¹⁸F] FDG-PET voxel-wise metabolism was calculated with SPM12, comparing each patient to n=33 healthy controls (P<.05, uncorrected). The proportion of hypometabolic voxels was calculated in bilateral occipital lobes, thalami (defined by the AAL atlas)²⁴ and the visual network (defined by the CAREN atlas)²⁵(see Supplementary Methods for [¹⁸F] FDG-PET acquisition and preprocessing details).

Statistical analysis

Demographic and clinical variables were compared using Chi-square, ANOVA, or Kruskal-Wallis tests, depending on data distribution. Normality of distributions was tested with the Shapiro-Wilk test. When expected counts were <5, Fisher exact test was used. Post-hoc comparisons were performed with t-tests or Mann-Whitney U tests as indicated. Subgroup analysis was conducted for MCS- and MCS+. Bonferroni correction was applied for multiple comparisons. Correlations between total visual impairments, VEP amplitude, and [¹⁸F] FDG-PET hypometabolism were examined using Spearman's rank correlation. Significance was set at P<.05.

Results

Demographic information

We included 61 patients (44% female, mean age: 42.3 years): 11 UWS/Vs, 29 MCS (12 MCS-, 17 MCS+), 17 eMCS, and 4 LIS. Median time since injury was 12 months (IQR 5.7-30.7). Etiologies included traumatic brain injury (41%), anoxia (26%), stroke (23%) and other causes (10%) (Table 1, see also Supplementary Table 1 for full breakdown).

Table 1: Diagnostic and Etiologic Information of Diagnostic Groups.

	Total	UWS/Vs	MCS	eMCS/LIS	p-value
N (%)	61	11 (18%)	29 (48%)	21 (34%)	
Age, years (mean (SD))	42.3 (15.7)	43.4 (15.2)	41.9 (16.8)	42.4 (15.2)	.97
Gender (males, N (%))	34 (56%)	5 (45%)	17 (59%)	12 (57%)	.75
Etiology					.75
TBI	25 (41%)	4 (36%)	13 (44%)	8 (38%)	
Stroke	14 (23%)	0 (0%)	6 (21%)	8 (38%)	
Anoxia	16 (26%)	6 (55%)	6 (21%)	4 (19%)	
Other	6 (10%)	1 (9%)	4 (14%)	1 (5%)	
TSI, months (median (IQR))	11.6 (25.7)	10.8 (6.9)	13.8 (28.1)	11.4 (63.9)	.43
CRS-R total score (median (IQR))	10 (8)	5 (1)	9.5 (4.25)	18 (6)	<.001

Abbreviations: CRS-R: Coma Recovery Scale–Revised, eMCS: Emergence from minimally conscious state, IQR: Interquartile range, LIS: Locked-in syndrome, MCS: Minimally conscious state, SD: Standard deviation, TBI: Traumatic brain injury, TSI: Time since injury (months), UWS/VS: Unresponsive wakefulness syndrome/vegetative state.

Clinical assessment

Seventy percent of patients exhibited at least one visual impairment. The most impaired features were ocular motility (31.2% abnormal, 34.4% not testable), visual fixation (34.4% absent) and visual pursuit (32.8% absent). An ophthalmological diagnosis was reported in 45.9% of cases, most commonly exophoria (9.8%) and anisocoria (8.2%) (see Supplementary Table 2). Pupillary reflex was abnormal for 41.9% of reported cases (unreported in 50.8% of patients) (Figure 1).

When comparing the 10 analyzed clinical features across diagnostic groups (UWS/VS, MCS, eMCS/LIS), visual pursuit and fixation were significantly more preserved in higher consciousness states ($P < .001$ and $P = .002$ respectively), as expected, because they are diagnostic criteria for MCS (Figure 2). When VEP was treated as a binary clinical variable (i.e., normal vs. abnormal) in 45 patients (11 UWS/VS, 20 MCS, 14 eMCS/LIS), abnormalities were more common in UWS/VS (40%) compared with MCS (5%, $P = .04$), while rates in eMCS/LIS (14%) did not differ from either group. Four cases (8.9%) showed abnormal VEPs due to low amplitude, while 3 cases (6.6%) had prolonged latency.

The total number of visual impairments per patient ranged from 0 to 4 (mean 1.46). Impairments were more frequent in UWS/VS (mean 2.64) than in MCS (1.21) or eMCS/LIS (1.14), $P = .002$. This difference was no longer significant when fixation and pursuit were excluded ($P = .93$). No difference was observed between MCS- and MCS+ in impairment rate ($P = .51$). Comparing the same-day CRS-R and ophthalmological reports revealed a mismatch in 6.6% (pursuit) and 9.8% (fixation) of cases, where ophthalmologists rated behaviors as present, and the CRS-R examiner did not.

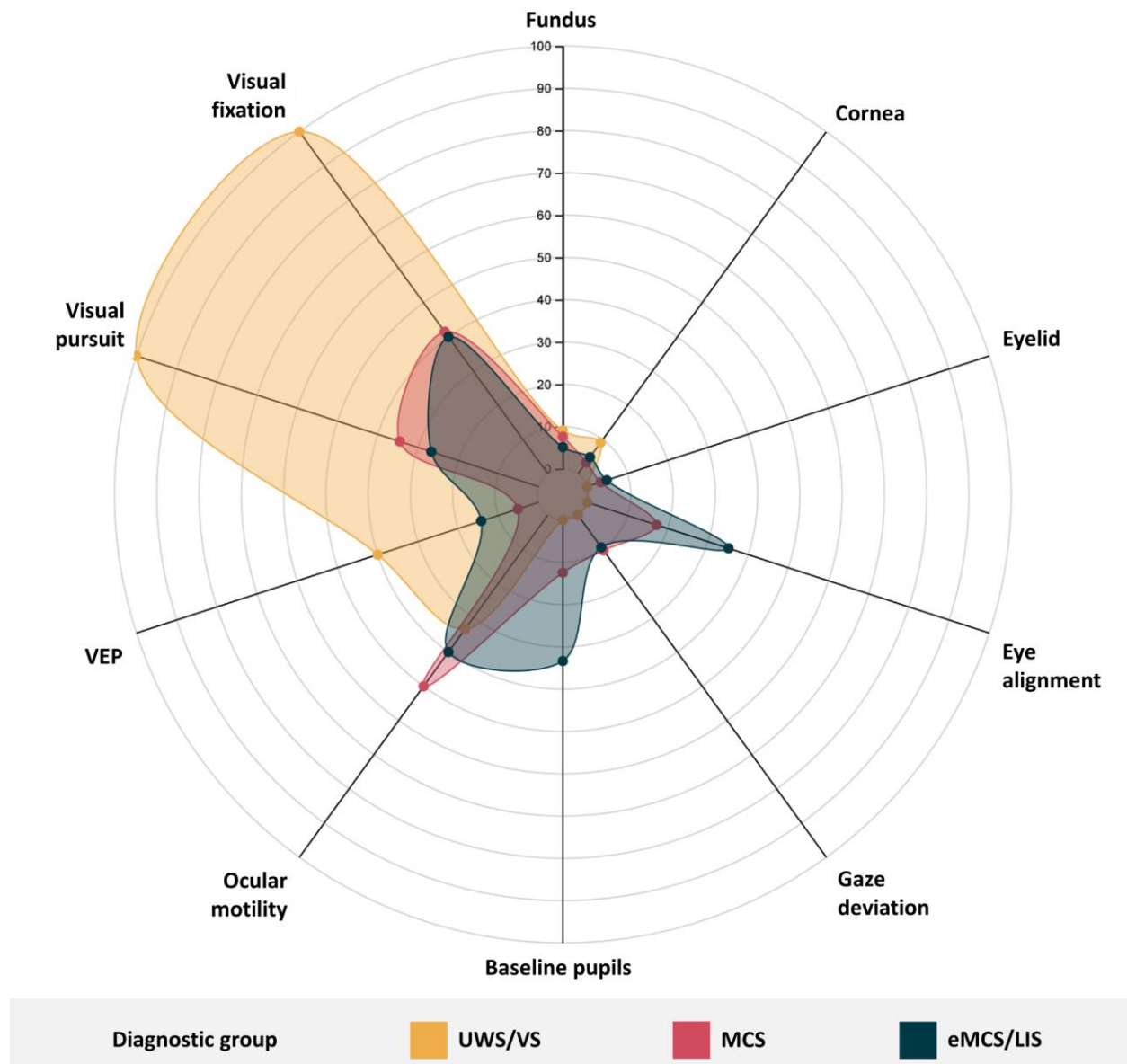


Figure 2. Distribution of Ophthalmological Abnormalities Across Diagnostic Groups.

Radar plot illustrating the percentage of patients with abnormal findings across ophthalmological and visual domains in unresponsive wakefulness syndrome/vegetative state (UWS/Vs), minimally conscious state (MCS), and emerged from minimally conscious state or locked-in syndrome (eMCS/LIS). Higher

values indicate higher prevalence of ophthalmological abnormalities. Exact values and statistical comparisons are provided in Supplementary Table 3.

Abbreviations: eMCS, Emergence from minimally conscious state, LIS, Locked-in syndrome, MCS, Minimally conscious state, UWS/VS, Unresponsive wakefulness syndrome, VEP, visual evoked potentials

Visual evoked potentials amplitude

Thirty-two patients were eligible for the quantitative analysis of VEP amplitudes: 17 female (53%), mean age: 41.9 (SD: 17), median time since injury 11.2 (IQR 5.6-22.9) months, 9 UWS/VS, 15 MCS, 7 eMCS, 1 LIS, 13 patients with traumatic brain injury, 13 with anoxia, 5 with hemorrhagic stroke, and 1 with hypoglycemia.

No significant difference was found between diagnostic groups for the average VEP amplitude of both eyes ($P=.310$), as well as for the right eye ($P=.152$) and left eye ($P=.607$) individually.

Brain metabolism

Fifty patients were eligible for [^{18}F]FDG-PET analysis: 24 female (48%), mean age: 43.2 (SD: 15.6) years, median time since injury 12 (IQR 7.1-33.9) months, 10 UWS/VS, 22 MCS, 15 eMCS, 3 LIS, 18 patients with traumatic brain injury, 19 with anoxia, 7 with hemorrhagic stroke, 3 with mixed etiology and 3 other causes. The [^{18}F] FDG-PET control group included 33 participants: 15 female (45%), mean age: 43.2 (SD 15.1) years.

FDG-PET results showed an average hypometabolism in 32% of voxels in the right occipital lobes, 31% in the visual network, and 53% in the thalami across all diagnostic groups compared to healthy controls. UWS/VS, MCS, and eMCS/LIS patients showed varying degrees of hypometabolism in the visual regions (Figure 3, Supplementary Table 4). UWS/VS showed greater hypometabolism than MCS and eMCS/LIS in the visual network ($P=.037$) and right occipital lobe ($P=.014$). In the left occipital lobe, eMCS/LIS had less hypometabolism than UWS/VS ($P=.003$) and MCS ($P=.019$); however, UWS/VS and MCS did not

differ ($P=.861$). There was no significant difference between groups for the metabolism of the left and right thalamus ($P=.30$ and $P=.66$ respectively) (Figure 3).

The subgroup analysis showed no difference between MCS+ ($n=14$) and MCS- ($n=8$) for visual network ($P=.63$), left occipital ($P=.73$), right occipital lobe ($P=.36$), left thalamus ($P=.34$) and right thalamus ($P=.68$).

Brain-behavior correlations

There was a significant correlation between the total number of impairments and the amplitude of VEP ($r=-0.34$, $P=.029$, Figure 4A). There was also a correlation between number of visual impairments and hypometabolism in the visual network ($r=0.27$, $P=.027$, Figure 4B), as well as hypometabolism in the left occipital lobe ($r=0.30$, $P=.017$). A non-significant trend was observed for the right occipital lobe ($r=0.23$, $P=.057$).

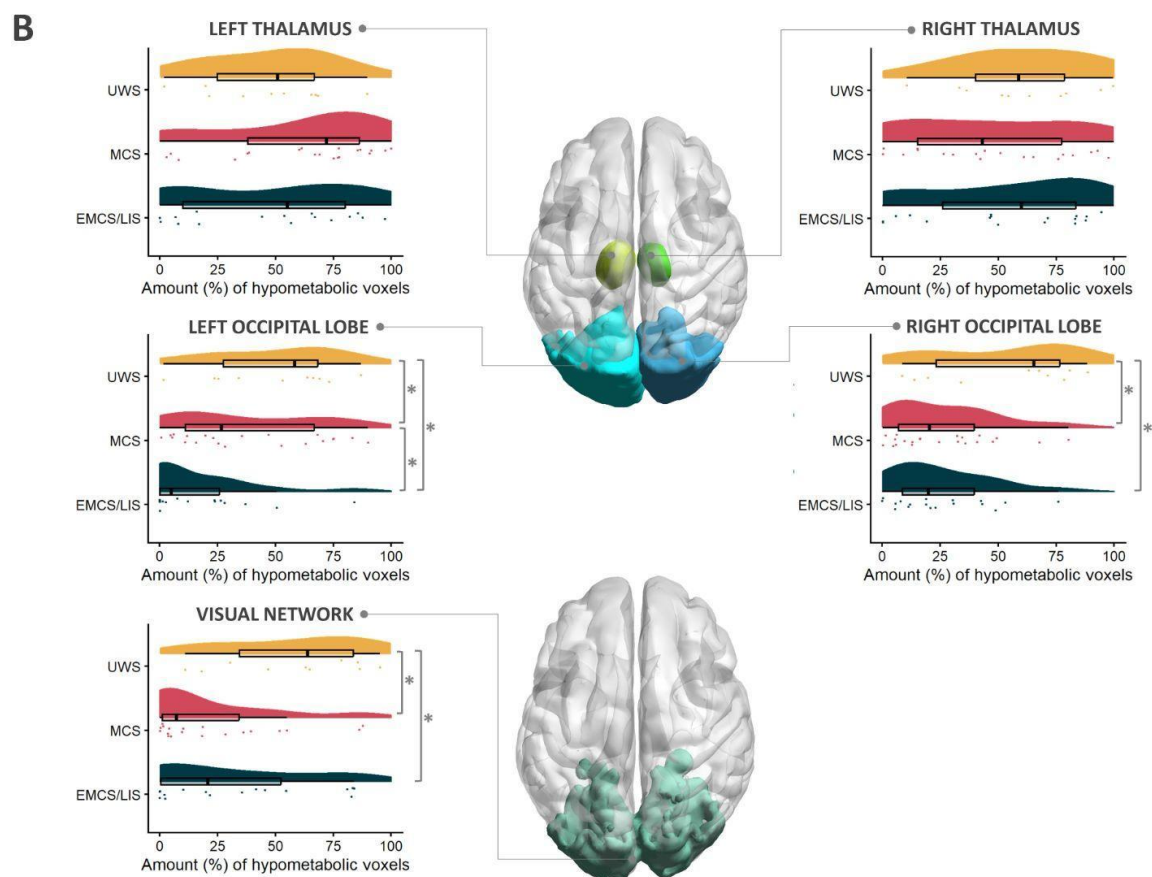
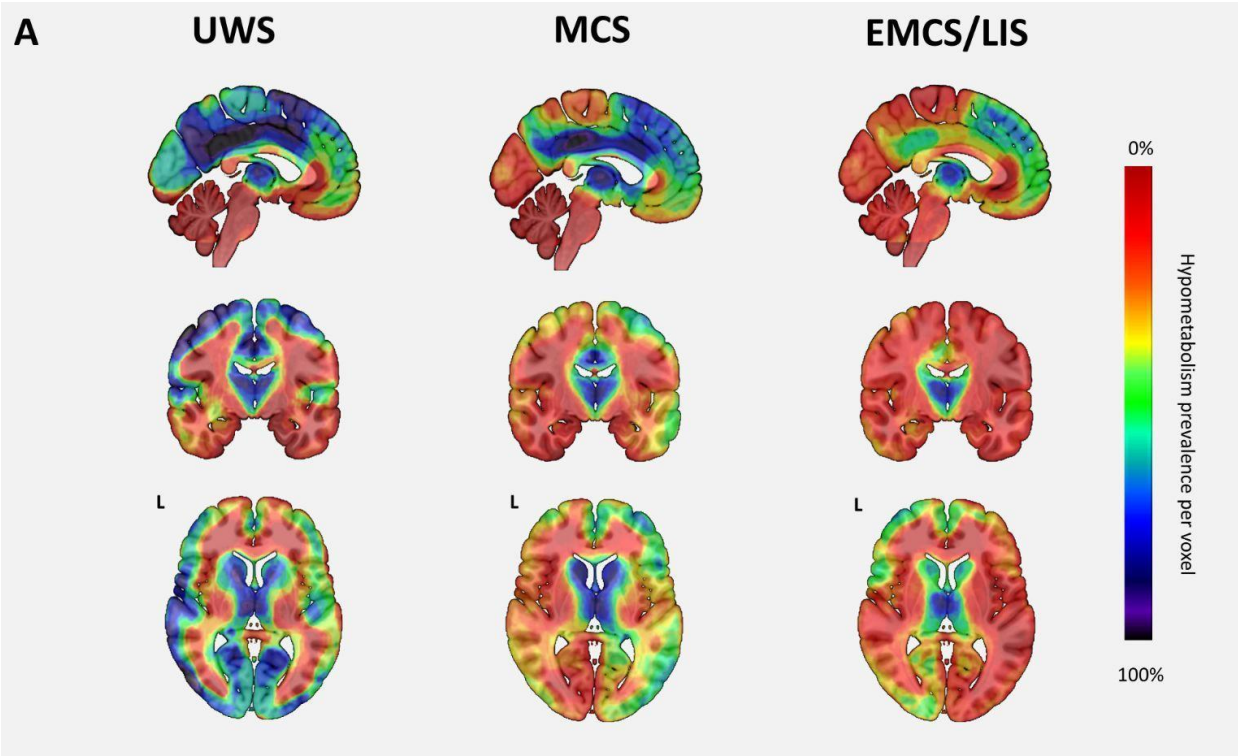


Figure 3: Comparison of Brain Hypometabolism in UWS/VS, MCS and eMCS/LIS patients. (A)

Figure shows voxel-wise hypometabolism maps of each clinical group; the value of each voxel indicates the group frequency (%) of voxel-wise hypometabolism, as computed based on single-subject SPM T-maps. We observe large hypometabolic areas (in blue) in the parieto-occipital region in UWS/VS patients, that is improved in MCS patients mostly in occipital lobes and further normalized across the whole brain in eMCS/LIS patients. Renders in neurological convention are superimposed on a high resolution T1 anatomical template as available in MRIcroGL (<https://www.nitrc.org/projects/mricrogl>). (B) Raincloud plots show the proportion (%) of hypometabolic voxels in each clinical group (UWS/VS in yellow, MCS in red, eMCS/LIS in blue), in a series of visual ROIs. UWS/VS patients display significantly more hypometabolism in bilateral occipital lobes and the visual network compared to other diagnostic groups, without significant differences in the thalamus. Significant differences (*) at $p < 0.05$ were determined based on Kruskal-Wallis nonparametric test. The raincloud plots were generated in R (v. 4.3.2) based on the raincloud package.²⁶ ROIs, including the left and right thalamus and left and right occipital lobe (based on the Automated Anatomical Labeling Atlas) and a consensus fMRI bilateral visual network (based on a Consensual Atlas of REsting-state Networks), were rendered in neurological convention using BrainNet Viewer²⁷

Abbreviations: eMCS, Emergence from minimally conscious state, LIS, Locked-in syndrome, MCS, Minimally conscious state, UWS/VS, Unresponsive wakefulness syndrome

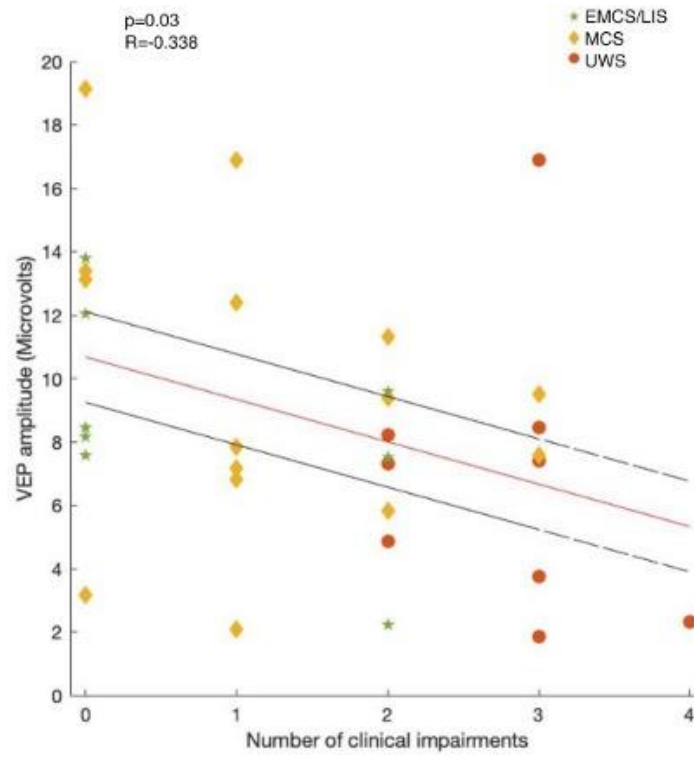
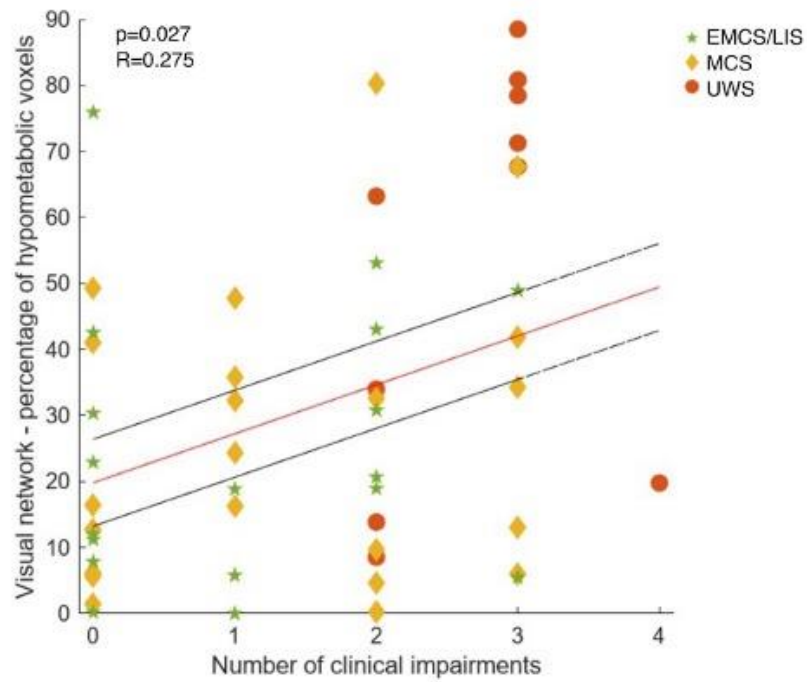
A**B**

Figure 4. Associations Between Clinical Visual Impairment Burden and VEP Amplitudes and FDG-PET Metabolism.

(A) Correlation between the number of clinical ophthalmological impairments and visual evoked potential (VEP) amplitude.

(B) Correlation between the number of clinical ophthalmological impairments and the percentage of hypometabolic voxels within the visual network on [¹⁸F] FDG-PET.

Each point represents an individual patient, color-coded by diagnostic group (UWS/VS, MCS, eMCS/LIS). Red lines indicate linear regression fits, and black lines represent 95% confidence intervals.

Abbreviations: eMCS, Emergence from minimally conscious state, LIS, Locked-in syndrome, MCS, Minimally conscious state, UWS/VS, Unresponsive wakefulness syndrome, VEP, Visual evoked potentials

Discussion

In this multimodal study, we evaluated visual impairments, VEP and brain metabolism in visual regions among post-coma patients. Seventy percent of patients displayed at least one visual impairment, with ocular motility, pursuit, and fixation most frequently affected. Individual clinical variables did not demonstrate significant differences across the three diagnostic groups, except for abnormal VEP, visual pursuit and fixation. The two latter variables are diagnostic criteria of the MCS, and they also showed a higher detection rate by the ophthalmologist compared to the CRS-R examiners, possibly linked to different testing methods. [¹⁸F] FDG-PET revealed more hypometabolism in the visual network and occipital lobes in UWS/VS compared to MCS and eMCS/LIS. Visual impairments correlated with reduced VEP amplitude and greater hypometabolism in visual regions. The high prevalence of ophthalmological abnormalities has important diagnostic implications, as visual pursuit and fixation are often the first signs of transition from UWS/VS to MCS^{15,28,29}. Given an estimated 40% misdiagnosis rate in DoC when using clinical consensus^{8,30}, standardized ophthalmological evaluation should be integrated into routine DoC assessment to prevent diagnostic inaccuracies.³¹

Ocular motility deficits were the most common, but abnormalities in eye alignment, fundoscopy, or acuity were present in 8-20% of all patients and may also confound visual behaviors. Tools such as mirrors, multidirectional pursuit testing, and eye-tracking devices can improve diagnostic accuracy.³²⁻³⁶ Although not seen in our sample, Terson's syndrome can cause reversible vision loss in up to 19% of subarachnoid hemorrhage patients, reinforcing the value of early eye examination.^{37,38}

Our VEP results align with previous studies showing better electrophysiological responses in patients exhibiting conscious behaviors.³⁹ While amplitude differences alone were nonsignificant, combining amplitude and latency into a binary normal/abnormal measure distinguished groups with UWS/VS showing more abnormalities. This suggests both parameters are relevant for assessing visual processing in DoC. While our study focused on validated visual behaviors such as pursuit and fixation, emerging research suggests that other clinical indicators could play a significant role in diagnosing DoC.

Resistance to eye opening, pupillary light-off reflex and spontaneous eye blink rate, although not analyzed in this study, may also warrant consciousness at the bedside and should be integrated in future research on visual function in DoC).⁴⁰⁻⁴³

In our work, the presence of visual pursuit and fixation was detected approximately 6-10% more often by the ophthalmologist than the CRS-R examiners, which may suggest better sensitivity is achieved by the specialist's assessment. Reasons for this difference could be attributed to two potential reasons. First, ophthalmologists devote more time and attention to the ophthalmological examination, leading to increased sensitivity in their assessment of these features. Alternatively, it could be argued that the criteria for scoring visual pursuit and fixation in the CRS-R protocol are more stringent than those used by the ophthalmologist, leading to a lower detection rate.

[¹⁸F]FDG-PET, which has been shown to be highly sensitive and congruent with CRS-R in the diagnosis of DoC⁹, can complement clinical examination by assessing brain metabolism underlying visual function in post-coma patients. We observed that UWS/VS patients had more hypometabolism in the visual network and right occipital lobe compared to MCS and eMCS/LIS patients. The reason we obtained lateralized results could be due to a small sample size, or the fact that we did not control for the laterality

of the etiology. The pattern observed in visual network metabolism parallels behavioral findings: visual behaviors typically emerge during UWS/VS-MCS transition but do not necessarily change between MCS and eMCS. Prior fMRI studies in DoC showed functional connectivity differences in the default mode, frontoparietal and auditory networks.⁴⁴⁻⁴⁹ Subsequent research replicated these findings but also showed differences in visual, somatosensory and salience networks, with visual and auditory connectivity most sensitive for discriminating MCS from UWS/VS.⁵⁰ Hypometabolism in regions mediating visual signal processing in UWS/VS but not MCS or eMCS/LIS may account for the higher frequency of functional visual deficits, consistent with prior PET studies showing disconnection of visual, auditory and somatosensory information between primary and secondary areas in UWS/VS.⁵¹ The absence of significant differences in visual network or occipital metabolism between MCS and eMCS/LIS suggests that visual regions are not reliable to distinguish these states metabolically.

Neither clinical nor neuroimaging analysis revealed differences between MCS- and MCS+, as previously demonstrated for the occipital lobe.⁵² This is consistent with the fact that these subgroups are defined by language-dependent behaviors, not visual functions.^{3,4}

Patients with more ophthalmological impairments also had lower VEP amplitudes, supporting the link between visual pathway dysfunction and reduced cortical responses. This correlation should be interpreted cautiously in MCS, due to its important clinical and radiological heterogeneity.^{4,52} A higher impairment load was also associated with more severe visual network hypometabolism. Together, these results suggest that ophthalmological findings, VEP and PET provide convergent information on visual system integrity and could serve as proxies for visual performance. A prior study using multimodal data from 54 DoC patients showed structural MRI and VEPs predicted visual pursuit, with the primary visual cortex as a critical predictor, and demonstrated correlations between visual behavior and cognitively mediated responses⁵³. Similarly, case-level multimodal assessments combining fMRI paradigms and VEP validated behavioral observations.⁵⁴ Further studies should test composite models integrating behavioral, ophthalmological, electrophysiological, and neuroimaging data to better predict outcomes. Emerging

tools such as eye-tracking and novel interventions (e.g., light therapy) may also improve detection, prognostication and recovery in DoC.^{36,55}

Clinical recommendations

Our findings support the following recommendations for clinicians assessing post-coma patients. Given the high frequency of ophthalmological impairments, clinicians should be aware of these potential confounding factors when evaluating visual function. Ophthalmological evaluation should be systematically requested when visual abnormalities are suspected, including the assessment of visual pursuit, fixation, ocular motility, baseline gaze, gaze deviation, eyelids, cornea, fundus, pupillary reflex, oculocephalic reflex, nystagmus, visual acuity and field. Objective tools such as pupillometry, automated perimetry, OCT or fundoscopy are particularly useful, especially in patients with hemorrhagic etiologies where Terson's syndrome must be excluded. Clinicians should carefully observe pursuit and fixation in UWS/VS patients, since these are often the first signs of transition to MCS, and monitor emerging indicators such as resistance to eye opening or increased blink rate. Given their correlation with clinical impairments, VEP and [¹⁸F] FDG-PET should be used as supplementary diagnostic tools when diagnostic uncertainties or inconsistencies remain after standardized clinical examination.

Limitations

This study has limitations. Its retrospective design and reliance on non-standardized clinical reports resulted in missing data for certain measures, notably the pupillary reflex⁴³. Inclusion based on ophthalmological evaluation may have introduced selection bias, and ophthalmologists were not systematically blinded to DoC diagnoses. The absence of a VEP control group and relatively small sample size limit interpretation. PET results may also have been influenced by lesion laterality, which was not accounted for. Finally, the frequency and distribution of visual impairments in this sample referred to a university center for multimodal assessment may not reflect the broader DoC population. Prospective studies using standardized ophthalmological protocols and consistent use of objective

measures are needed. Importantly, our results demonstrate correlations between visual impairments and consciousness levels or brain activity measures, but causality relationships remain unresolved.

Conclusion

This study provides the first multimodal evaluation of visual function in patients with DoC following severe brain injury. We found that over two-thirds of patients exhibited visual impairments, particularly those in UWS/VS, who also showed higher rates of abnormal VEPs and visual network hypometabolism. Importantly, visual abnormalities correlated with both electrophysiological and metabolic measures, highlighting the value of combining ophthalmology with VEP and [¹⁸F] FDG-PET in diagnostic workflows. Visual deficits may confound the identification of residual consciousness if not recognized early. Systematic screening for ophthalmological impairments, alongside validated behavioral scales, may improve diagnostic accuracy, prognostic estimates and decision-making in post-coma patients.

Conflict of interest

None

Acknowledgements

The study was supported by the University and University Hospital of Liège, the Belgian National Funds for Scientific Research (FRS-FNRS), the FNRS MIS project (F.4521.23), the FNRS PDR project (T.0134.21), the FLAG-ERA JTC2021 project ModelDXConsciousness (Human Brain Project Partnering Project) and FLAG-ERA JTC 2023 - HBP - Basic and Applied Research, project BrainAct, the fund Generet, the King Baudouin Foundation, the BIAL Foundation, the Mind Science Foundation, the Fondation Leon Fredericq, the Mind-Care foundation, the National Natural Science Foundation of China (Joint Research Project 81471100), the European Foundation of Biomedical Research FERB Onlus, and

the Horizon 2020 MSCA – Research and Innovation Staff Exchange DoC-Box project (HORIZON-MSCA-2022-SE-01-01; 101131344).

SKL is a PhD fellow, AS is a post-doctoral researcher, OG and AT are research associates and SL is research director at F.R.S.-FNRS.

The authors thank the whole staff from the Nuclear Medicine Department. We are highly grateful to the members of the Coma Science Group for their assistance in clinical evaluations, as well as the clinicians from the Intensive Care Unit of the University Hospital of Liege, especially Didier Ledoux, Paul Massion and Gaelle Tronconi.

We are also thankful to the patients and their families for agreeing to take part in this study.

References

1. Laureys S, Celesia GG, Cohadon F, et al. Unresponsive wakefulness syndrome: a new name for the vegetative state or apallic syndrome. *BMC Med.* 2010;8(1):68. doi:10.1186/1741-7015-8-68
2. Giacino JT, Ashwal S, Childs N, et al. The minimally conscious state: definition and diagnostic criteria. *Neurology.* 2002;58(3):349-353. doi:10.1212/wnl.58.3.349
3. Thibaut A, Bodien YG, Laureys S, Giacino JT. Minimally conscious state “plus”: diagnostic criteria and relation to functional recovery. *J Neurol.* 2020;267(5):1245-1254. doi:10.1007/s00415-019-09628-y
4. Bruno MA, Vanhaudenhuyse A, Thibaut A, Moonen G, Laureys S. From unresponsive wakefulness to minimally conscious PLUS and functional locked-in syndromes: recent advances in our understanding of disorders of consciousness. *J Neurol.* 2011;258(7):1373-1384. doi:10.1007/s00415-011-6114-x
5. American Congress of Rehabilitation Medicine, Brain Injury-Interdisciplinary Special Interest Group, Disorders of Consciousness Task Force, Seel RT, Sherer M, et al. Assessment scales for disorders of consciousness: evidence-based recommendations for clinical practice and research. *Arch Phys Med Rehabil.* 2010;91(12):1795-1813. doi:10.1016/j.apmr.2010.07.218
6. Giacino JT, Kalmar K, Whyte J. The JFK Coma Recovery Scale-Revised: measurement characteristics and diagnostic utility. *Arch Phys Med Rehabil.* 2004;85(12):2020-2029. doi:10.1016/j.apmr.2004.02.033
7. Andrews K, Murphy L, Munday R, Littlewood C. Misdiagnosis of the vegetative state: retrospective study in a rehabilitation unit. *BMJ.* 1996;313(7048):13-16. doi:10.1136/bmj.313.7048.13

8. Schnakers C, Vanhaudenhuyse A, Giacino J, et al. Diagnostic accuracy of the vegetative and minimally conscious state: Clinical consensus versus standardized neurobehavioral assessment. *BMC Neurol.* 2009;9(1):35. doi:10.1186/1471-2377-9-35
9. Stender J, Gosseries O, Bruno MA, et al. Diagnostic precision of PET imaging and functional MRI in disorders of consciousness: a clinical validation study. *The Lancet.* 2014;384(9942):514-522. doi:10.1016/S0140-6736(14)60042-8
10. Bodien YG, Allanson J, Cardone P, et al. Cognitive Motor Dissociation in Disorders of Consciousness. *N Engl J Med.* 2024;391(7):598-608. doi:10.1056/NEJMoa2400645
11. Gosseries O, Zasler ND, Laureys S. Recent advances in disorders of consciousness: focus on the diagnosis. *Brain Inj.* 2014;28(9):1141-1150. doi:10.3109/02699052.2014.920522
12. Thibaut A, Panda R, Annen J, et al. Preservation of Brain Activity in Unresponsive Patients Identifies MCS Star. *Ann Neurol.* 2021;90(1):89-100. doi:10.1002/ana.26095
13. Schiff ND. Cognitive Motor Dissociation Following Severe Brain Injuries. *JAMA Neurol.* 2015;72(12):1413-1415. doi:10.1001/jamaneurol.2015.2899
14. Aubinet C, Claassen J, Edlow BL, et al. Covert consciousness: what's in a name? *Brain.* Published online September 23, 2025;awaf349. doi:10.1093/brain/awaf349
15. Bagnato S, Boccagni C, Sant'Angelo A, Fingelkurts AA, Fingelkurts AA, Galardi G. Longitudinal Assessment of Clinical Signs of Recovery in Patients with Unresponsive Wakefulness Syndrome after Traumatic or Nontraumatic Brain Injury. *J Neurotrauma.* 2017;34(2):535-539. doi:10.1089/neu.2016.4418
16. Wannez S, Hoyoux T, Langohr T, et al. Objective assessment of visual pursuit in patients with disorders of consciousness: an exploratory study. *J Neurol.* 2017;264(5):928-937. doi:10.1007/s00415-017-8469-0
17. Dolce G, Lucca LF, Candelieri A, Rogano S, Pignolo L, Sannita WG. Visual pursuit in the severe disorder of consciousness. *J Neurotrauma.* 2011;28(7):1149-1154. doi:10.1089/neu.2010.1405
18. Wannez S, Heine L, Thonnard M, Gosseries O, Laureys S, Coma Science Group collaborators. The repetition of behavioral assessments in diagnosis of disorders of consciousness. *Ann Neurol.* 2017;81(6):883-889. doi:10.1002/ana.24962
19. Giacino JT, Katz DI, Schiff ND, et al. Practice Guideline Update Recommendations Summary: Disorders of Consciousness: Report of the Guideline Development, Dissemination, and Implementation Subcommittee of the American Academy of Neurology; the American Congress of Rehabilitation Medicine; and the National Institute on Disability, Independent Living, and Rehabilitation Research. *Arch Phys Med Rehabil.* 2018;99(9):1699-1709. doi:10.1016/j.apmr.2018.07.001
20. Kondziella D, Bender A, Diserens K, et al. European Academy of Neurology guideline on the diagnosis of coma and other disorders of consciousness. *Eur J Neurol.* 2020;27(5):741-756. doi:10.1111/ene.14151
21. Stephen Karl Larroque. Irq3000/csg_datafusion: CSG DataFusion v2.7.3-2. Published online February

- 8, 2025. doi:10.5281/ZENODO.14836354
22. Annen J, Sala A, Bonin EAC, et al. FDG-PET/CT data of healthy volunteers and patients with disorders of consciousness. Published online October 2, 2021. doi:10.25493/7TXP-WCF
23. Annen J, Frasso G, Van Der Lande GJM, et al. Cerebral electrometabolic coupling in disordered and normal states of consciousness. *Cell Rep.* 2023;42(8):112854. doi:10.1016/j.celrep.2023.112854
24. Tzourio-Mazoyer N, Landeau B, Papathanassiou D, et al. Automated Anatomical Labeling of Activations in SPM Using a Macroscopic Anatomical Parcellation of the MNI MRI Single-Subject Brain. *NeuroImage.* 2002;15(1):273-289. doi:10.1006/nimg.2001.0978
25. Doucet GE, Lee WH, Frangou S. Evaluation of the spatial variability in the major resting-state networks across human brain functional atlases. *Hum Brain Mapp.* 2019;40(15):4577-4587. doi:10.1002/hbm.24722
26. Allen M, Poggiali D, Whitaker K, Marshall TR, Van Langen J, Kievit RA. Raincloud plots: a multi-platform tool for robust data visualization. *Wellcome Open Res.* 2021;4:63. doi:10.12688/wellcomeopenres.15191.2
27. Xia M, Wang J, He Y. BrainNet Viewer: A Network Visualization Tool for Human Brain Connectomics. *PLOS ONE.* 2013;8(7):e68910. doi:10.1371/journal.pone.0068910
28. Martens G, Bodien Y, Sheau K, Christoforou A, Giacino JT. Which behaviours are first to emerge during recovery of consciousness after severe brain injury? *Ann Phys Rehabil Med.* 2020;63(4):263-269. doi:10.1016/j.rehab.2019.10.004
29. Carrière M, Llorens R, Navarro MD, Olaya J, Ferri J, Noé E. Behavioral signs of recovery from unresponsive wakefulness syndrome to emergence of minimally conscious state after severe brain injury. *Ann Phys Rehabil Med.* 2022;65(2):101534. doi:10.1016/j.rehab.2021.101534
30. van Erp WS, Lavrijsen JCM, Vos PE, Bor H, Laureys S, Koopmans RTCM. The Vegetative State: Prevalence, Misdiagnosis, and Treatment Limitations. *J Am Med Dir Assoc.* 2015;16(1):85.e9-85.e14. doi:10.1016/j.jamda.2014.10.014
31. Edlow BL, Sanz LRD, Polizzotto L, et al. Therapies to Restore Consciousness in Patients with Severe Brain Injuries: A Gap Analysis and Future Directions. *Neurocrit Care.* 2021;35(S1):68-85. doi:10.1007/s12028-021-01227-y
32. Vanhaudenhuyse A, Schnakers C, Brédart S, Laureys S. Assessment of visual pursuit in post-comatose states: use a mirror. *J Neurol Neurosurg Psychiatry.* 2008;79(2):223. doi:10.1136/jnnp.2007.121624
33. Thonnard M, Wannez S, Keen S, et al. Detection of visual pursuit in patients in minimally conscious state: a matter of stimuli and visual plane? *Brain Inj.* 2014;28(9):1164-1170. doi:10.3109/02699052.2014.920521
34. Johansson J, Franzon K, Godbolt AK, Möller MC. Methodological aspects of using a wearable eye-tracker to support diagnostic clinical evaluation of prolonged disorders of consciousness. *J Rehabil Med.* 2021;53(7):jrm00213. doi:10.2340/16501977-2847
35. Trojano L, Moretta P, Loreto V, Cozzolino A, Santoro L, Estraneo A. Quantitative assessment of

- visual behavior in disorders of consciousness. *J Neurol*. 2012;259(9):1888-1895. doi:10.1007/s00415-012-6435-4
36. Johansson J, Möller M, Franzon K, Stenberg J, Godbolt AK. Eye tracking to support assessment of patients with prolonged disorder of consciousness – a case series. *J Rehabil Med*. 2025;57:jrm41324. doi:10.2340/jrm.v57.41324
37. Maslias E, Vijjala S, Epiney JB, Konstantinidis L, Kawasaki A, Diserens K. Terson Syndrome: Not to Be Missed in Patients with Disorders of Consciousness. *Brain Sci*. 2023;13(6):879. doi:10.3390/brainsci13060879
38. Frizzell RT, Kuhn F, Morris R, Quinn C, Fisher WS. Screening for ocular hemorrhages in patients with ruptured cerebral aneurysms: a prospective study of 99 patients. *Neurosurgery*. 1997;41(3):529-533; discussion 533-534. doi:10.1097/00006123-199709000-00004
39. Sattin D, Rossi Sebastiano D, D'Incerti L, et al. Visual behaviors in disorders of consciousness: Disentangling conscious visual processing by a multimodal approach. *Eur J Neurosci*. 2020;52(10):4345-4355. doi:10.1111/ejn.14875
40. Mat B, Sanz LRD, Arzi A, Boly M, Laureys S, Gosseries O. New Behavioral Signs of Consciousness in Patients with Severe Brain Injuries. *Semin Neurol*. 2022;42(3):259-272. doi:10.1055/a-1883-0861
41. van Ommen HJ, Thibaut A, Vanhaudenhuyse A, et al. Resistance to eye opening in patients with disorders of consciousness. *J Neurol*. 2018;265(6):1376-1380. doi:10.1007/s00415-018-8849-0
42. Magliacano A, Rosenfelder M, Hieber N, Bender A, Estraneo A, Trojano L. Spontaneous eye blinking as a diagnostic marker in prolonged disorders of consciousness. *Sci Rep*. 2021;11(1):22393. doi:10.1038/s41598-021-01858-3
43. Zarifkar P, Othman MH, Hansen KIT, et al. The Pupillary Light-Off Reflex in Acute Disorders of Consciousness. *Neurocrit Care*. Published online September 25, 2024. doi:10.1007/s12028-024-02133-9
44. Boly M, Tshibanda L, Vanhaudenhuyse A, et al. Functional connectivity in the default network during resting state is preserved in a vegetative but not in a brain dead patient. *Hum Brain Mapp*. 2009;30(8):2393-2400. doi:10.1002/hbm.20672
45. Vanhaudenhuyse A, Noirhomme Q, Tshibanda L, et al. Default network connectivity reflects the level of consciousness in non-communicative brain-damaged patients. *Brain J Neurol*. 2010;133(Pt 1):161-171. doi:10.1093/brain/awp313
46. Demertzi A, Gómez F, Crone JS, et al. Multiple fMRI system-level baseline connectivity is disrupted in patients with consciousness alterations. *Cortex J Devoted Study Nerv Syst Behav*. 2014;52:35-46. doi:10.1016/j.cortex.2013.11.005
47. Huang Z, Dai R, Wu X, et al. The self and its resting state in consciousness: an investigation of the vegetative state. *Hum Brain Mapp*. 2014;35(5):1997-2008. doi:10.1002/hbm.22308
48. Norton L, Hutchison RM, Young GB, Lee DH, Sharpe MD, Mirsattari SM. Disruptions of functional connectivity in the default mode network of comatose patients. *Neurology*. 2012;78(3):175-181. doi:10.1212/WNL.0b013e31823fcd61

- 49.Soddu A, Vanhauzenhuysse A, Bahri MA, et al. Identifying the default-mode component in spatial IC analyses of patients with disorders of consciousness. *Hum Brain Mapp.* 2012;33(4):778-796. doi:10.1002/hbm.21249
- 50.Demertzi A, Antonopoulos G, Heine L, et al. Intrinsic functional connectivity differentiates minimally conscious from unresponsive patients. *Brain J Neurol.* 2015;138(Pt 9):2619-2631. doi:10.1093/brain/awv169
- 51.Giacino JT, Hirsch J, Schiff N, Laureys S. Functional Neuroimaging Applications for Assessment and Rehabilitation Planning in Patients With Disorders of Consciousness. *Arch Phys Med Rehabil.* 2006;87(12):67-76. doi:10.1016/j.apmr.2006.07.272
- 52.Aubinet C, Cassol H, Gosseries O, et al. Brain Metabolism but Not Gray Matter Volume Underlies the Presence of Language Function in the Minimally Conscious State (MCS): MCS+ Versus MCS– Neuroimaging Differences. *Neurorehabil Neural Repair.* 2020;34(2):172-184. doi:10.1177/1545968319899914
- 53.Sattin D, Rossi Sebastiano D, Magnani FG, et al. Visual fixation in disorders of consciousness: Development of predictive models to support differential diagnosis. *Physiol Behav.* 2021;230:113310. doi:10.1016/j.physbeh.2021.113310
- 54.Coleman MR, Bekinschtein T, Monti MM, Owen AM, Pickard JD. A multimodal approach to the assessment of patients with disorders of consciousness. *Prog Brain Res.* 2009;177:231-248. doi:10.1016/S0079-6123(09)17716-6
- 55.Ren S, Zhu J, Xie X, et al. The visual stimulation in disorders of consciousness. *Appl Neuropsychol Adult.* Published online December 17, 2023:1-8. doi:10.1080/23279095.2023.2292244