

Follow-up of patients after revascularisation for peripheral arterial diseases: a consensus document from the European Society of Cardiology Working Group on Aorta and Peripheral Vascular Diseases and the European Society for Vascular Surgery

Maarit Venermo^{1,*}, Muriel Sprynger^{2,*}, Ileana Desormais³,
Martin Björck⁴, Marianne Brodmann⁵, Tina Cohnert⁶,
Marco De Carlo⁷, Christine Espinola-Klein⁸, Serge Kownator⁹,
Lucia Mazzolai¹⁰, Ross Naylor¹¹, Charalambos Vlachopoulos¹²,
Jean-Baptiste Ricco¹³ and Victor Aboyans¹⁴

Published by SAGE and Elsevier Limited on behalf of The European Society of Cardiology and the European Society for Vascular Surgery. All rights reserved. The article has been co-published with permission in the European Journal of Preventative Cardiology [DOI: 10.1177/2047487319846999] on behalf of the European Society of Cardiology and European Journal of Vascular and Endovascular Surgery [DOI: 10.1016/j.ejvs.2019.06.017] on behalf of the European Society for Vascular Surgery. The articles are identical except for minor stylistic and spelling differences in keeping with each journal's style

Abstract

Peripheral arterial diseases comprise different clinical presentations, from cerebrovascular disease down to lower extremity artery disease, from subclinical to disabling symptoms and events. According to clinical presentation, the patient's general condition, anatomical location and extension of lesions, revascularisation may be needed in addition to best medical treatment. The 2017 European Society of Cardiology guidelines in collaboration with the European Society for Vascular Surgery have addressed the indications for revascularisation. While most cases are amenable to either

¹Department of Vascular Surgery, Helsinki University Hospital and University of Helsinki, Finland

²Department of Cardiology, University of Liege Hospital, Belgium

³Department of Thoracic and Vascular Surgery and Vascular Medicine, Dupuytren University Hospital, France

⁴Department of Surgical Sciences, Uppsala University, Sweden

⁵Division of Angiology, Medical University of Graz, Austria

⁶Department of Vascular Surgery, Graz University Hospital, Austria

⁷Cardiothoracic and Vascular Department, Azienda Ospedaliero-Universitaria Pisana, Pisa, Italy

⁸Center for Cardiology – Cardiology I, University Medical Center of the Johannes Gutenberg University Mainz, Germany

⁹Centre Cardiologique et Vasculaire, France

¹⁰Division of Angiology, Lausanne University Hospital, Switzerland

¹¹Department of Vascular Surgery, Leicester Vascular Institute, UK

¹²First Department of Cardiology, Athens Medical School, Greece

¹³Department of Clinical Research, Jean Bernard University Hospital, France

¹⁴Department of Cardiology, Dupuytren University Hospital and Inserm 1098, France

*The first two authors contributed equally

Corresponding author:

Maarit Venermo, Helsinki University Hospital and University of Helsinki
Haartmaninkatu 4, FI00290 Helsinki, Finland.

Email: Maarit.venermo@hus.fi

Twitter: @VenerMa

endovascular or surgical revascularisation, maintaining long-term patency is often challenging. Early and late procedural complications, but also local and remote recurrences frequently lead to revascularisation failure. The rationale for surveillance is to propose the accurate implementation of preventive strategies to avoid other cardiovascular events and disease progression and avoid recurrence of symptoms and the need for redo revascularisation. Combined with vascular history and physical examination, duplex ultrasound scanning is the pivotal imaging technique for identifying revascularisation failures. Other non-invasive examinations (ankle and toe brachial index, computed tomography scan, magnetic resonance imaging) at regular intervals can optimise surveillance in specific settings. Currently, optimal revascularisation surveillance programmes are not well defined and systematic reviews addressing long-term results after revascularisation are lacking. We have systematically reviewed the literature addressing follow-up after revascularisation and we propose this consensus document as a complement to the recent guidelines for optimal surveillance of revascularised patients beyond the perioperative period.

Keywords

Revascularisation, peripheral arterial disease, follow-up, restenosis

Received 14 February 2019; accepted 8 April 2019

Introduction

Peripheral arterial diseases encompass different clinical presentations, from cerebrovascular disease to lower extremity artery disease (LEAD), from subclinical to disabling symptoms and events.^{1,2} The 2017 European Society of Cardiology (ESC) guidelines in collaboration with the European Society for Vascular Surgery (ESVS) have addressed the indications for revascularisation.³ In 2008, over 98,000 endovascular procedures and over 86,000 surgical revascularisations were performed for lower limb arterial disease in Germany alone,⁴ illustrating the burden of peripheral revascularisation interventions in Europe.

Maintaining long-term patency after revascularisation is often challenging. Early and late procedural complications, but also target and non-target lesion recurrences, frequently lead to revascularisation failure. Henceforth, the rationale for surveillance is:

- to detect and treat imminent revascularisation failure before patency loss and thereby to prevent complications and redo revascularisations.
- to implement optimal preventive strategies for disease progression and avoid other cardiovascular events.

This consensus document combines a systematic literature review on the follow-up beyond the perioperative period and experts' inputs to standardise the follow-up of revascularised patients. It is a complement to the recent guidelines elaborated through the collaboration of the ESC and the ESVS.³

The evidence supporting systematic surveillance after revascularisation is poor, largely due to a lack of good evidence. In this situation, the opinion of the authors of this interdisciplinary consensus document is that the proposed surveillance strategy may be

appropriate while awaiting better quality data to be acquired. Importantly, the regular follow-up of revascularised patients does not systematically imply the use of imaging techniques. Clinical assessment and implementation of preventive measures remain the pillars of the follow-up programme. These could either be performed by general practitioners or cardiovascular specialists (cardiologists, vascular physicians or vascular surgeons) according to the management of patients in different countries. The recommendations here apply irrespective of the healthcare systems.

General aspects

Complications after revascularisation

Revascularisation success is multifactorial, starting with the indication of the procedure, the quality of the preoperative assessment and the intervention itself. The postoperative events are time dependent: the rates of procedure-specific adverse events decrease over time while disease-specific events are predominant thereafter. The postoperative complications are usually divided into early (<1 month), mid (1–12 months) and long-term (>12 months). This paper focuses on the surveillance needed to prevent mid and long-term adverse events. During these periods the events are either local, specific to the revascularised organ/limb (e.g. bypass thrombosis), or general (e.g. myocardial infarction). Follow-up should therefore include general cardiovascular prevention, surveillance and care by a multidisciplinary team (Table 1). In the case of repetitive thrombosis after revascularisation, drug adherence, response to antithrombotic drugs and coagulation disorders should be investigated.

Mid-term complications (1–12 months). Acute thrombosis of the revascularised site despite antithrombotic

Table 1. Checklist of items to be regularly assessed during the mid and long-term follow-up visits.**Cardiovascular prevention**

- Tobacco smoking status
 - If smoking history: is cessation achieved?
 - If yes: be supportive
 - If not: propose specific intervention and follow-up, refer to smoking cessation programmes if available
- Hypertension
 - Check brachial blood pressure bilaterally, at least annually: blood pressure should be <140/90 mmHg with the target of 130/80 mmHg if tolerated
 - If treated hypertension:
 - Check diet and drug adherence
 - Check for other target organ damage (e.g. renal disease)
 - If high blood pressure during a visit:
 - Reassess (ambulatory)
 - Refer to hypertension specialists
- Diabetes
 - Check fasting glucose at least annually
 - If diabetes: check glycated haemoglobin (optimally HbA1c < 7%)
 - Check treatment and diet adherence
 - If newly detected or poorly controlled diabetes: refer to diabetes specialist
- Cholesterol
 - Check lipid levels at least annually: low-density lipoprotein cholesterol should be <1.8 mmol/l (70 mg/dL) or decreased at least by 50% compared to the baseline levels
 - Assess statin tolerance and compliance
 - In the case of significant statin intolerance and/or failure to reach target levels, refer to lipid specialist (consider ezetimibe and PCSK9 inhibitors)
- Other
 - Check for adherence to antithrombotic drugs
 - Check renal function (urea, creatinine, electrolytes, estimated glomerular filtration rate)
 - Record body mass index, advise optimal body weight
 - Re-enforce the importance of regular physical exercise

Symptoms and physical signs related to the revascularisation site (and contralateral if applicable)

Other cardiovascular conditions

- Assess for cardiovascular symptoms
- Full clinical cardiovascular examination (including 12-lead ECG)
- Screening for AAA

AAA: abdominal aortic aneurysm; PCSK9: proprotein convertase subtilisin/kexin 9.

therapy is a major complication after revascularisation. Embolism to arteries distal to the revascularised site can also cause ischaemic symptoms.

Restenosis may occur several months after surgical or endovascular revascularisation.^{5–7}

The primary pathway is intimal hyperplasia, with luminal area loss despite geometric remodelling.

Intimal hyperplasia lesions are classically detected from a few weeks to 2 years after intervention.⁸

Wall shear stress and wall tension stress are considered as initiators and modulators of intimal hyperplasia.⁹ Vascular reconstructions such as vein bypass grafts and stented diseased arteries frequently induce a disordered flow pattern with low wall shear stress which accelerates intimal hyperplasia.¹⁰ At suture lines the process is also induced by differential compliance between the prosthesis and the grafted artery.

Long-term complications (>12 months). Complications directly related to revascularisation can still occur after one year, but are progressively dominated by disease progression and general cardiovascular events, both highly dependent on the quality of cardiovascular prevention. The optimal medical management of patients with peripheral arterial diseases is detailed in the ESC and ESVS guidelines.³

Patients' follow-up

Clinical follow-up. The clinical follow-up includes the assessment of any symptom or physical sign suggesting revascularisation failure, or any other cardiovascular condition, as well as ensuring optimal cardiovascular prevention and drug adherence (Table 1). The compliance to secondary prevention and exercise training, as well as awareness of revascularisation failure symptoms needing immediate contact with vascular specialists, are important factors of long-term success.^{11–14}

Imaging techniques. Because it is non-invasive and widely available, duplex ultrasound (DUS) performed by experienced operators is usually the first-line technique. It can be repeated over time to detect subclinical abnormalities or verify whether symptoms are related to revascularisation failure and/or disease progression. Other functional tests such as ankle brachial index (ABI) or toe brachial index (TBI) can optimise the surveillance of lower limbs. Computed tomography angiography (CTA) and magnetic resonance angiography (MRA) are mostly limited to the confirmation and investigation of DUS findings but can be performed straight away in urgent cases. Radiation (CTA), contrast agent nephrotoxicity (CTA, but also MRA) and allergies should always be considered.

Extracranial carotid artery disease**Mid and long-term outcome after revascularisation**

Carotid endarterectomy. In a meta-analysis of 11 randomised clinical trials (RCTs) including 4249 patients with follow-up over a mean of 47 months, the rate of

stenosis greater than 70% or occlusion after carotid endarterectomy (CEA) was 5.8% (95% confidence interval (CI) 4.1–8.2).¹⁶ In seven RCTs involving 2810 patients and over a mean of 37 months of surveillance, 5.2% CEA patients with a restenosis greater than 70% or occlusion had a late ipsilateral stroke compared with 1.5% in patients without restenosis (odds ratio (OR) 4.77, 95% CI 2.29–9.92, $P < 0.0001$).¹⁶ In a secondary analysis of the CREST study, female sex, diabetes, dyslipidaemia and continuing smoking were independent predictors of restenosis after CEA.¹⁵

Carotid artery stenting. After carotid artery stenting (CAS), most restenoses occur in the first year. The rate of recurrent cerebral ischaemic events is not significantly higher in patients with in-stent restenosis than in those without.¹⁷

A meta-analysis of five RCTs observed that the prevalence of stenosis greater than 70% (or occlusion) in patients undergoing CAS was 10.0% (95% CI 6.0–16.3) over a mean follow-up of 62 months.¹⁶ In the EVA-3S study, the 3-year rate of restenosis ($\geq 50\%$) after CAS was 12.5%,¹⁷ with most restenoses occurring at 12 months or later. However, most of these restenotic lesions were moderate and severe lesions were infrequent. Female gender, diabetes, and dyslipidaemia (but not smoking) were independent predictors of restenosis. The rate of late ipsilateral stroke in CAS patients with asymptomatic untreated restenosis greater than 70% is very low (0.8% over 50 months). In fact, 97% of those strokes occur in patients without significant restenosis or occlusion.¹⁶

Recurrence or development of atherosclerotic lesions.

Contralateral lesions are more common than ipsilateral restenosis as their progression depends on the severity of the disease at the time of intervention. In EVA-3S, most patients with restenosis after CAS had recurrent stenosis instead of residual stenosis.¹⁷ The rate of contralateral greater than 70% restenosis or occlusion was 19.8% in the CAS group and 18.5% in the CEA group. In a cohort of 1639 patients, a 50–69% internal carotid artery (ICA) stenosis observed in 282 patients progressed to severe 70–99% stenosis in 32 patients (11.3%) during a mean time of 30.7 ± 26.5 months.¹⁸

Whether serial DUS surveillance confers any benefit remains controversial. DUS surveillance enables monitoring of disease progression in the ipsilateral and contralateral carotid arteries. Patients with greater than 50% contralateral stenoses have been reported to be five times more likely to progress during follow-up. In some series, progression of the contralateral stenosis has been associated with an increased risk of transient ischaemic attack/stroke. In other series no stroke was associated with a severe ($>70\%$) contralateral ICA stenosis.¹⁹

Long-term surveillance methods

Surveillance for restenosis after endarterectomy and stenting relies mostly on DUS and particularly on the peak systolic velocity (PSV), the systolic carotid velocity ratio and the end-diastolic velocity.^{20, 21} Each DUS laboratory should validate its own criteria. Following intervention (CEA or CAS), due to structural modifications of the arterial wall, it has been proposed that DUS criteria for measuring restenosis severity should be adapted.

After CAS, increased arterial stiffness and reduced compliance of the ICA has haemodynamic consequences. DUS velocity criteria for diagnosing greater than 70% in-stent restenosis is higher than after CEA (Table 2).^{22,23}

In the case of an inconclusive study with DUS, CTA is preferred as an alternative. MRA is not an option for surveillance after CAS due to stent-related metal artifacts.

Management of restenosis

In the absence of specific RCTs, symptomatic restenoses should be treated as soon as possible according to the usual recommendations regarding ICA stenosis.⁷

The management of asymptomatic restenoses remains highly controversial. In a recent meta-analysis by Kumar et al.,¹⁶ the risk of late ipsilateral stroke in patients with an asymptomatic 70–99% restenosis after CAS was less than 1% at 4 years. Accordingly, any reintervention would be unlikely to confer any significant long-term benefit.

In contrast, the presence of an asymptomatic greater than 70% restenosis after CEA was associated with a small but significant increase in the risk of late ipsilateral stroke (about 3.7% increase in absolute risk over 3 years). Consequently, for redo CEA or CAS to confer any long-term benefit (in terms of late stroke prevention), the procedural death/stroke rate should not exceed 1%.

However, an important patient subgroup to consider for serial surveillance and reintervention would include CEA and CAS patients who had a significant decrease in cerebral blood flow during the procedure.⁷ This might include CEA patients who developed neurological symptoms, coma or seizures during carotid clamping under local anaesthesia, or similar symptoms during a CAS procedure. Another subgroup includes CEA patients who developed significant electroencephalographic changes and/or a drop in mean middle cerebral artery velocities to less than 15 cm/second during clamping under general anaesthesia. These patients would be likely to have a stroke in the case of restenosis progression.⁷

In light of the ongoing controversy, in patients with an asymptomatic greater than 70% restenosis after

Table 2. DUS criteria for restenosis after revascularisation of various arterial territories.

	PSV (cm/s)	PSV ratio	Reference
Carotid artery, stenosis after CEA			
>50%	≥210–220	>2.25	AbuRahma et al., 2009 ⁷⁴ , Aburahma, 2011 ⁷⁵
>70–80%	≥270–280	>3.35	AbuRahma et al., 2009 ⁷⁴ , AbuRahma, 2011 ⁷⁵
Carotid artery, in stent stenosis after CAS			
>50%	>220		Lal et al., 2008 ²² , Stanziale et al., 2005 ²³
>70%	≥300	>4	Lal et al., 2008 ²² , Stanziale et al., 2005 ²³ , Zhou et al., 2008 ⁷⁶
Mesenterial artery, in stent stenosis			
SMA ≥50%	>325	≥3.5*	AbuRahma et al., 2012 ³⁰
Celiac trunk ≥50%	>270	≥3.5*	AbuRahma et al., 2012 ³⁰
SMA ≥70%	≥400–445	≥8.45*	AbuRahma et al., 2012 ³⁰ , Soult et al., 2016 ⁷⁷
Celiac trunk ≥70%	≥290–360	≥5.75*	AbuRahma et al., 2012 ³⁰ , Soult et al., 2016 ⁷⁷
Renal artery, in stent stenosis**			
Excludes >60% in stent stenosis	<240		Del Conde et al., 2014 ⁷⁸
Intermediate zone	240–300		Del Conde et al., 2014 ⁷⁸
In stent stenosis (Specificity 94%)	≥300		Del Conde et al., 2014 ⁷⁸
>50%	>200–350	>4.1*	Schäberle et al., 2016 ³⁷
>60%	>250		Fleming et al., 2010 ³⁸ , Boateng et al., 2013 ³⁶
≥70%	≥395	≥5.1*	Chi et al., 2009 ⁷⁹
Lower extremity, in stent stenosis			
>50%	≥190	≥1.5	Baril et al., 2009 ⁷³
>70%	≥200–250	>2.0	Baril et al., 2009 ⁷³
≥80%	≥275	>3.5	Baril et al., 2009 ⁷³
Lower extremity, stenosis of vein bypass graft			
>50%	180–300	2–3.5	Tinder et al., 2008 ⁶⁹
>70–80%	≥300	>3–3.5	Tinder et al., 2008 ⁶⁹

*Systolic ratio: target artery compared to PSV in aorta

**Cut-offs for renal ISR are still controversial and should be validated in individual laboratories (Del Conde et al., 2009). Higher values of PSV and changes from baseline PSV increase specificity.

CEA, decisions regarding whether redo CEA or CAS might be appropriate should involve multidisciplinary team input.

Mid and long-term surveillance protocol

Most RCT protocols for surveillance after CEA or CAS have involved DUS studies at 1, 3, 6 and 12 months and then yearly thereafter. Given the low incidence of restenosis and the very low risk of late ipsilateral stroke in patients with a restenosis after CEA or CAS, the overall benefit of routine DUS surveillance remains questionable. However, subgroups of patients might carry an increased risk of restenosis, particularly women, patients with diabetes and those with unfavourable control of their risk factors. DUS also enables surveillance of disease progression in the contralateral carotid artery.⁷ In conclusion, although it may remain controversial, given a favourable benefit/risk ratio, carotid DUS surveillance at 1, 6, 12 and 24 months is reasonable. Beyond the

initial 2 years after revascularisation, and in the absence of restenosis over the first 2 years and any significant contralateral lesion an annual cardiovascular check-up remains suitable, but DUS surveillance is not necessarily needed (Figure 1).

Upper extremity artery disease

Mid and long-term outcome after revascularisation

The incidence of main mid and long-term (restenosis or reocclusion) after revascularisation of upper extremity artery disease is comparable for both modalities: primary patency rates of 93% at 2 years and 83–85% at 5 years have been reported for endovascular treatment (EVT)^{24, 25} versus 96% at 54 months for surgical subclavian–carotid transposition.²⁶ Extra-anatomical bypass surgery (mostly carotid–subclavian bypass) has shown a secondary patency of 97% after 5 years.²⁷

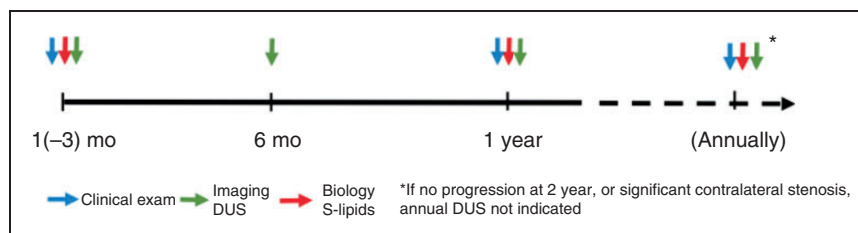


Figure 1. Surveillance recommendation after carotid endarterectomy and carotid artery stenting. Although it may remain controversial, given a favourable benefit/risk ratio, duplex ultrasound (DUS) surveillance at 1, 6 and 12 months then yearly is reasonable until new data are available. Beyond the initial 2 years after revascularisation, and in the absence of restenosis over the first 2 years and any significant contralateral lesion, a less frequent DUS follow-up (e.g. every 2–3 years) can be considered, but an annual appointment with a cardiovascular specialist remains suitable.

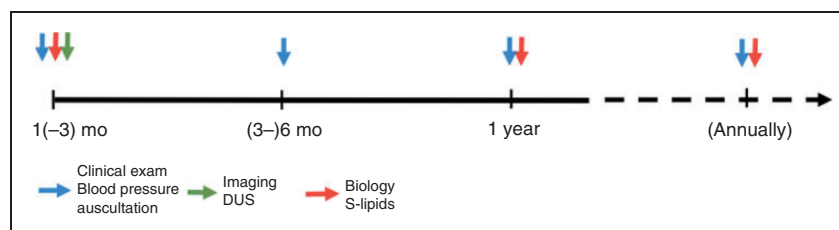


Figure 2. Surveillance recommendation after subclavian artery stenting or bypass. Physical examination including cervical and subclavian auscultation, and bilateral upper extremity BP measurement is recommended at 3, 6 and 12 months, and annually thereafter. In specific cases (see text), serial duplex ultrasound (DUS) surveillance may be beneficial. In these cases, we advise DUS surveillance at 1, 6 and 12 months, and annually thereafter. If there is a suspicion of restenosis with severe symptoms, DUS is indicated at 6 months, and annual DUS may be beneficial in the following indications: haemodialysis fistula, arteria mammaia coronary artery bypass grafting and subclavian steal syndrome.

Significant risk factors for restenosis are age, smoking, small stent diameter, implantation of two or more stents, inflammation (e.g. high sensitivity C-reactive protein level, leucocytosis) and concurrent carotid or vertebral disease.²⁸

Mid and long-term surveillance protocol

As subclavian artery stenosis is an acknowledged marker of cardiovascular mortality, these patients need the best medical treatment with a strict control of cardiovascular risk factors (Table 1).³ Physical examination including bilateral upper extremity blood pressure (BP) measurement is recommended at 3, 6 and 12 months, and annually thereafter. If a restenosis is suspected, DUS is indicated. After stenting or bypass, DUS surveillance protocols are still debated and vary in different centres. In specific cases such as ipsilateral or contralateral haemodialysis arteriovenous fistula, coronary artery bypass with the ipsilateral internal mammary artery and bilateral subclavian artery stenosis, serial DUS surveillance may be beneficial. In these cases, it is advisable to perform DUS surveillance at 1, 6 and 12 months, and annually thereafter (Figure 2).

Mesenteric artery disease

Imaging follow-up after treatment of acute or chronic mesenteric artery disease is only needed if the patient benefits from an early diagnosis of a restenosis or occlusion before symptoms develop.²⁹ In the case of acute embolic mesenteric ischaemia, appropriate care should prevent new embolism, by treating the cause and/or prescribing anticoagulants. If the first acute event was due to atherosclerosis, further bowel loss due to recurrent mesenteric occlusion might be life threatening. This supports imaging follow-up in patients who had a mesenteric artery stenting or surgical procedure after acute mesenteric ischaemia.³⁰ We recommend DUS every 3 months during the first year, and then yearly, in line with previous reports.^{29,31,32} In the case of recurrent clinical symptoms, CT is appropriate.

The follow-up strategy is very different after the treatment of chronic mesenteric ischaemia (CMI). Most patients will develop symptoms of CMI (postprandial pain, weight loss, and/or diarrhoea) prior to life-threatening bowel ischaemia. Thus, there is little evidence that routine imaging follow-up after intervention for CMI results in patient benefit.²⁹ However,

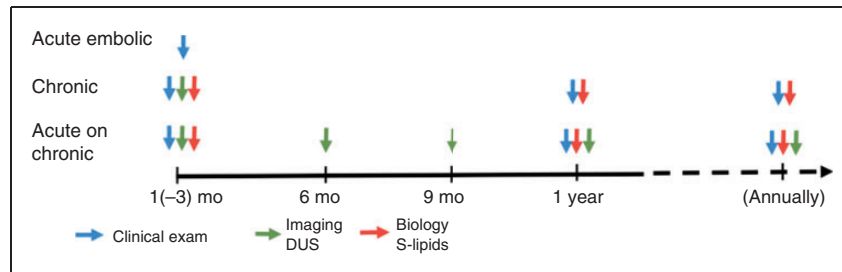


Figure 3. Surveillance recommendation after mesenteric artery stenting or bypass. In the case of embolic acute mesenteric ischaemia, appropriate care should prevent a new embolism, by treating the cause and/or prescribing anticoagulants. If the acute event was due to atherosclerosis (acute on chronic), trimestrial duplex ultrasound (DUS) during the first year and then annually is recommended. There is little evidence that routine imaging follow-up after intervention for chronic mesenteric ischaemia results in patient benefit. Annual clinical follow-up is recommended to secure best medical treatment, including smoking cessation, and to enable the patient to report symptom recurrence.

clinical follow-up to secure best medical treatment and to enable the patient to report symptom recurrence is highly recommended (Figure 3).

Renal artery disease

Mid and long-term outcome

In atherosclerotic renal stenosis, a history of cardiovascular disease (hazard ratio (HR) 2.84) and a 90% or greater stenosis (HR 3.95) are independent predictors of restenosis.³³

Fibromuscular dysplasia is also an independent factor of restenosis after endovascular angioplasty (HR 2.65). In these patients, primary and assisted primary patency is 95%, 71% and 50%, and 100%, 100% and 100% at 1, 5 and 9 years, respectively. Most of the restenoses occur within the first 6 months.³⁴

Mid and long-term surveillance protocol

The follow-up of patients after renal revascularisation depends on the cause of the initial renal artery stenosis. It should be kept in mind that the course of hypertension (i.e. its cure and/or recurrence) is not always related to renal restenosis, although it will always be a signal requiring renal imaging.

Atherosclerotic renal artery stenosis. While the incidence of restenosis after revascularisation is not well known, restenosis may be influenced by the treatment modality (e.g. angioplasty with or without stenting, surgical repair).³⁵

Surveillance after endovascular intervention, usually stenting, is based on BP, renal function and DUS.^{36–38} Currently, no specific protocol has demonstrated any superiority over others. Home-based BP surveillance and renal function assessment every 3 months during the first year after stenting and every 6 or 12 months

thereafter are recommended. Furthermore, baseline post-procedure DUS 1–3 months after stenting is recommended (Figure 4). Thereafter the imaging follow-up should be clinically driven (changes in kidney function, BP control, antihypertensive therapy requirements or occurrence of heart failure). If a restenosis is suspected, DUS should be performed as the first imaging option to assess renal arteries and kidneys. The criteria of in-stent restenosis (ISR) are presented in Table 2. Changes from baseline post-stenting PSV add sensitivity.

If the diagnosis by DUS remains doubtful and clinical suspicion is strong, an angiogram with pressure gradient measurement is recommended. CTA demonstrates a high accuracy for detecting restenosis, but should be limited to inconclusive DUS and/or preoperatively, in order to avoid renal damage.³⁷ Due to stent-related metal artifacts, renal MRA is often suboptimal.

A similar follow-up protocol is recommended for surgical repair.

Although the optimal treatment of restenosis is still debated,³⁹ there is a trend favouring the repetition of the initial EVT, or bypass surgery following two failures. The final decision should be guided by a consensus between nephrologists, interventionists and vascular surgeons.³⁷

Fibromuscular dysplasia. The optimal post-revascularisation surveillance protocol is not well evidenced. DUS is recommended at 1–3 months, every 6 months for the first 24 months and then annually (Figure 4). BP and plasma creatinine levels must be carefully followed after the first month, and then every 3 months during the first year and twice a year thereafter. After a successful revascularisation, antihypertensive medication will probably need to be reduced or stopped, at least temporally. As restenosis mostly occurs within the first 6 months, DUS will be performed earlier in the case of BP and/or plasma creatinine elevation.^{3,40} CTA or

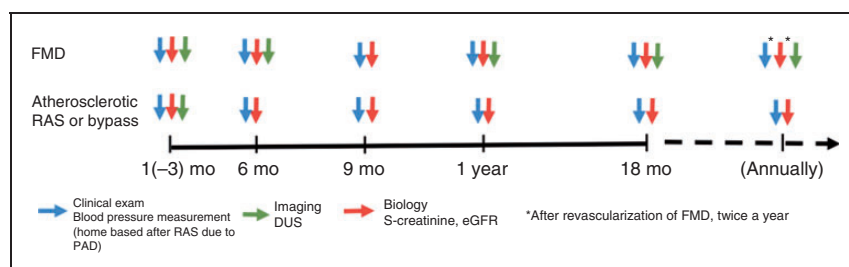


Figure 4. Surveillance recommendation after renal artery stenting or bypass. Fibromuscular dysplasia (FMD): Currently the optimal post-revascularisation monitoring protocol is not well evidenced. We propose a duplex ultrasound (DUS) at baseline, every 6 months for the first 24 months and then annually. Blood pressure (BP) and plasma creatinine levels must be carefully followed with a first control one month after revascularisation, every 3 months during the first year and twice a year thereafter. Atherosclerotic lesions: We recommend a home-based BP surveillance and renal function testing every 3 months during the first year after stenting and every 6–12 months thereafter. Furthermore, baseline post-procedure and DUS 1–3 months after stenting or surgical repair is recommended. Thereafter the imaging follow-up should be clinically driven (changes in kidney function, BP control, antihypertensive therapy requirement or heart failure). If there is a suspicion of restenosis in BP or renal function testing, DUS is recommended.

MRA are not recommended for routine surveillance in the absence of untreated aneurysms.

Any significant restenosis should lead to angiography and angioplasty. CTA or MRA might be needed to confirm the DUS diagnosis and better assess potential technical issues. Surgery should be considered in the case of complex lesions or recurrent stenosis.

Lower extremity artery disease

The revascularisation indications in LEAD relate primarily to chronic limb-threatening ischaemia (CLTI), and severe, disabling claudication, especially if medical management and exercise therapy are ineffective. Follow-up may differ according to the indication for revascularisation, the type of revascularisation and the patient's physical condition. The aim of surveillance is to prevent revascularisation failure and eventually amputation. The surveillance should not only focus on the revascularisation site, but must include the completely revascularised limb as well as the contralateral limb, along with a general clinical cardiovascular surveillance (Table 1).

Mid and long-term outcome

After surgery. The first-year incidence of vein graft stenosis is 20%.^{41,42} During the first 3 months, bypass stenosis/thrombosis can be due to technical issues. Almost 15% of graft failures occur during the first month; almost 80% during the first 2 years and no more than 5% thereafter.^{43, 44} During the mid-term period, bypass failure is predominantly associated with intimal hyperplasia causing anastomotic stenosis, graft stenosis or occasionally with fibrosis of the valve cusp. These are the most common causes of potentially identifiable and treatable graft stenoses.

The majority of significant graft stenoses are asymptomatic and only 11–38% can be diagnosed by ischaemic symptoms or decreased pulse on physical examination.^{45,46} ABI drop greater than 0.15 has been proposed to detect revascularisation failure, but its sensitivity is poor. Hence, the use of ABI alone to monitor a revascularised limb should be avoided, and it should always be used in combination with DUS.⁴⁷ In patients with abnormal DUS and ABI the reported graft failure is 66% in the 3-month period following measurements.⁴⁸ Angiography (CTA, MRA or digital subtraction angiography) is proposed only if there are clinical and/or ultrasound data suggesting graft failure or disease progression.

Significant (>50%) vein graft or anastomosis stenoses are usually treated by EVT. Studies comparing endovascular techniques are scarce.⁴⁹ In the case of multiple restenosis, surgical revision and replacement of the diseased segment with a vein interposition or a jump graft/patch angioplasty in the anastomotic stenosis is recommended. In the case of vein graft occlusion, thrombolysis should be performed within 6–48 hours after symptom onset with treatment of the defect, but re-thrombosis is not rare even though the underlying cause has been corrected. For prosthetic bypasses (polytetrafluoroethylene, dacron), thrombolysis can usually be effective up to 2 weeks. The intra-arterial catheter for thrombolysis is usually introduced inside the graft by the contralateral groin. Low dose alteplase (1 mg/hour) for 12–48 hours is a commonly used protocol.

After EVT for vein graft stenosis, a 1–6-month dual antiplatelet therapy with aspirin and clopidogrel is usually prescribed unless the patient has an increased bleeding risk.³

After revascularisation following vein graft occlusion, anticoagulants (usually low molecular weight

heparin) are combined with antiplatelet therapy (aspirin or clopidogrel). The duration of the anticoagulation varies between one month and lifelong and should be tailored according to the cause of the graft occlusion, to previous thrombotic events (particularly previous graft occlusions) and to the patient's bleeding risk. In long-term anticoagulation treatment, vitamin K antagonists are used.

After prosthetic bypass occlusion, long-term anticoagulation therapy should be considered.⁵⁰ Considering the lack of data on direct oral anticoagulant use for this indication, long-term vitamin K antagonists are usually recommended.

If the autologous vein bypass graft has been uneventful for 12 months, late issues are scarce. After the first postoperative year, the annual incidence of autologous graft failure is estimated to be approximately 1–2%.^{51,52} After venous bypass surgery, 5-year follow-up has shown LEAD progression in 19% of cases.⁵³ For prosthetic grafts, late occlusion rates are higher, as 40% of femoropopliteal prosthetic grafts are expected to occlude within 5 years.⁵⁴ Anastomotic pseudoaneurysms are rare.

The progression of atherosclerosis can be seen either in the inflow or outflow vessels. Prosthetic grafts may show late anastomosis stenoses. In the case of severe progression of atherosclerosis in the inflow or outflow arteries, typical symptoms of LEAD (claudication, rest pain, tissue lesion) or graft occlusion may occur. However, in many cases disease progression can be asymptomatic. Typically, these patients show up when LEAD symptoms appear. Imaging is indicated irrespective of symptoms. If bypass patency is threatened, intervention is usually recommended even if clinical symptoms are mild, according to the multidisciplinary team assessment.

After EVT. The most common mid-term complications after EVT are restenosis and occlusion of the treated

vessel segment, ranging from approximately 5% in the pelvic region up to over 50% in the infrapopliteal arteries. Recurrence of symptoms may also be due to disease progression above or below the angioplasty site.⁵⁵

Restenosis is mainly related to intimal hyperplasia at the balloon dilation site and at the proximal or distal end of the stent. Restenosis can also be related to initial suboptimal procedural results (residual dissection, >50% residual stenosis, distal embolisation, acute recoil, or inadequate inflow or outflow treatment).^{56,57} Restenosis/occlusion can be asymptomatic or can cause typical symptoms (claudication, recurrence of leg pain and/or non-healing lesions) requiring reintervention. Pulse palpation and ABI in combination with DUS are used for follow-up (Figure 5). In the case of recurrent claudication, the treadmill test with post-exercise ABI can assess the functional severity.³ Stent thrombosis usually presents with acute worsening of symptoms and sometimes acute limb ischaemia.

Endovascular reintervention is the first-line treatment option in clinically relevant restenosis or occlusion. If EVT is not successful, bypass surgery might be considered. After a second failure of EVT, a multidisciplinary vascular team should evaluate the patient.³ After endovascular reintervention, dual antiplatelet therapy with aspirin and clopidogrel should be considered for a longer period than after the first intervention, taking into account the patient's bleeding risk and the lesion location, with shorter duration in proximal versus distal lesions. A period of at least 3 months is recommended. However, due to the lack of evidence for these recommendations, this is based on clinical experience and expert opinion.

The long-term natural history of LEAD following EVT has been poorly investigated. Unlike surgery, no plateau phase is seen in the incidence of EVT failure after the first months, but there is a relatively constant

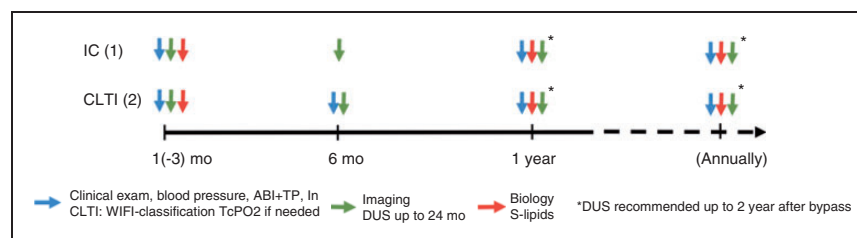


Figure 5. Surveillance recommendation after vein bypass for lower extremity artery disease. Surveillance includes clinical examination, ankle brachial index (ABI) (or toe pressure/toe brachial index (TBI)) measurement and duplex ultrasound (DUS). Although solid scientific evidence is lacking, there is consensus that the first post-discharge test should be performed within 4–6 weeks, thereafter at 3 months, 6 months, 12 and 24 months after bypass surgery. If a new intervention is performed for graft stenosis or occlusion, the surveillance programme is re-initiated from the start. Clinical surveillance is lifelong and of paramount importance especially for patients with chronic limb-threatening ischaemia (CLTI) (see Table 1). If there is a suspicion of restenosis, an angiogram is recommended.

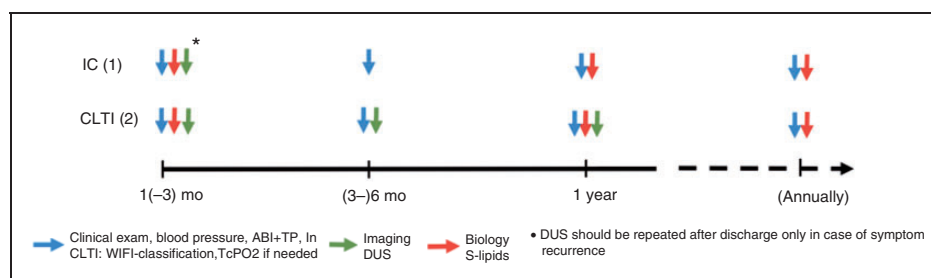


Figure 6. Surveillance recommendation after endovascular treatment (EVT) for lower extremity artery disease (LEAD). Surveillance includes clinical assessment looking for recurrent symptoms or signs, ankle brachial index (ABI) measurement and duplex ultrasound (DUS). Further tests such as toe pressure and/or transcutaneous oxygen tension (TcPO₂) may be needed in the case of chronic limb-threatening ischaemia (CLTI). DUS surveillance after EVT by means of an initial test performed between discharge and one month is recommended; if results are normal, subsequent examinations should be performed at 6 and 12 months; while if the initial DUS is abnormal, reintervention or closer DUS follow-up should be decided on a case-by-case basis. The usefulness of a yearly DUS beyond 12 months in revascularised patients who remain asymptomatic has never been proved, and cannot be recommended as routine surveillance; however, these patients require a comprehensive cardiovascular surveillance focused on risk factor management, exercise training and medical therapy on a yearly basis. Clinical surveillance is lifelong and of paramount importance especially for patients with CLTI (Table 1). If there is a suspicion of restenosis which requires treatment, an angiogram is recommended.

failure rate for at least the first 5 years. The failure rate is quite low for iliac arteries, but definitely higher for femoropopliteal and for below the knee arteries (Figure 6).

Severe restenosis accounts for the majority of reinterventions; because restenosis is usually symptomatic, the role of DUS surveillance in guiding reinterventions is questionable.⁵⁸

Beyond one year, the reported incidence of late stent thrombosis is 10% at a median follow-up of 19 months in the femoropopliteal segment.⁵⁸ It is not always preceded by severe in-stent restenosis, making this complication unpredictable by means of DUS surveillance.

After iliac stenting, the reported reintervention rate at 5 years is as low as 2.5% for primary stenotic lesions and 12.5% for primary occlusions, with a 6-year primary patency rate of 82.4% and 77.7%, respectively.⁵⁹ In the femoropopliteal segment, most studies reporting long-term data include only patients with Trans-Atlantic Consensus (TASC) A and B lesions. In this setting, the average 5-year freedom from target lesion revascularisation has been reported to be approximately 70–80%.⁶⁰

Very few studies describe long-term results after infrapopliteal EVT; 5-year primary patency ranges from 38% in one study on balloon angioplasty,⁶¹ to 9% with bare metal stents and 12% with drug-eluting stents in another trial.⁶² Importantly, 5-year freedom from major amputation (range 66–81%) was definitely higher than primary patency in both trials.

Late complications are usually suspected by the reoccurrence of symptoms. DUS is the mainstay for the diagnosis and guidance of treatment. Restenosis after EVT is usually amenable to repeat balloon angioplasty with or without stenting or to bypass in the case

of repeated failure. Acute thrombosis can be treated by aspiration and/or thrombolysis, but revascularisation by EVT is much more difficult if the thrombosis is old. Reintervention should be decided on a case-by-case basis, taking into account the severity of symptoms, the general condition of the patient (renal function, bleeding risk) and the likelihood of success (history of recurrent restenosis) preferably by the multi-disciplinary team.

Disease progression. Atherosclerosis involves the whole vascular tree and coexisting atherosclerotic manifestations in other vascular beds are very common in patients with LEAD.³ Patients with multisite artery disease more often have progressive atherosclerosis in all vascular beds and have a higher incidence of cardiovascular events.^{63,64} Therefore, it is of paramount importance to prevent atherosclerosis progression by regularly monitoring risk factor modification, exercise training and medical therapy.

In patients with intermittent claudication, disease progression to CLTI may be underestimated. In a meta-analysis of studies conducted between 1990 and 2015, 21% of patients with intermittent claudication were diagnosed with CLTI during a 5-year follow-up period and 4–27% of them had amputations.⁵⁵ On the other hand, a recent RCT on EVT for femoropopliteal disease showed a rate of persistent or worsening claudication or CLTI at 5 years of 20% in the DES arm and of 41% in the balloon angioplasty with or without bare metal stent arm.⁶⁰ Therefore, the regular follow-up programme should involve assessment for atherosclerosis in both lower limbs and clinical manifestations of other clinical sites such as coronary arteries, carotid arteries and the abdominal aorta.

Mid and long-term surveillance protocol

After bypass surgery. Graft failure should be identified before occlusion occurs. Not all graft stenoses progress to occlusion: in a study of 63 duplex-verified stenosis with over 50% of diameter reduction, 43% resulted in bypass thrombosis during the following 8 months.⁶⁵ Low flow is also reported as an indicator of an increased risk of graft failure.⁶⁶

Surveillance includes clinical examination, ABI (or TBI) measurement and DUS. Optimally, detailed description of the procedure and previous DUS examinations should be available for the sonographer. In a meta-analysis of 15 RCTs, DUS surveillance after venous bypass surgery did not improve graft patency and was associated with a statistically non-significant decrease in the amputation rate (OR 0.7, 95% CI 0.23–2.13).⁶⁷ In another retrospective analysis on 1404 bypass patients scheduled for routine DUS surveillance, 200 (14%) patients sustained graft occlusion. In a multivariate analysis, non-adherence to a DUS surveillance programme was independently associated with venous graft occlusion (HR 1.58, 95% CI 1.10–2.27).⁶⁸ This cannot only be due to DUS surveillance but also to treatment adherence and accurate clinical follow-up, emphasising the importance of long-term medical management of these patients beyond imaging.

In the lack of solid evidence, there is a consensus that the first post-discharge test should be performed within 4–6 weeks, thereafter at 3 months, 6 months, 12 and 24 months after bypass surgery. If a reintervention is performed for graft stenosis or occlusion, the surveillance programme should be reinitiated from the start. Although DUS surveillance may stop after 24 months, clinical surveillance is lifelong and of paramount importance especially for patients with CLTI (Figure 5, Table 1).

Some features are considered as high risk for graft thrombosis and requiring closer attention: spliced grafts, poor quality vein (varicose lesions, vein with a thick wall, post-thrombotic manifestations, vein diameter <3 mm), poor run-off or secondary bypass surgery.^{69,70} Also, an abnormal DUS scan at 4–8 weeks has been predictive of later graft failure. McBride et al.⁷⁰ proposed a decision tree to identify high-risk grafts for DUS surveillance. In the surveillance of 249 bypass grafts the sensitivity and specificity of their model for the prediction of graft stenosis occlusion were 95% and 52%, respectively; the negative predictive value being 97%.⁶⁶

After EVT. Surveillance includes clinical assessment looking for recurrent symptoms or signs, ABI (or TBI) measurement and DUS. Although ABI adds significant information to clinical examination, it correlates poorly with angiographic stenosis, and a significant

decrease in ABI (>0.15) may not be present until a greater than 60% stenosis exists. However, it may be useful to perform ABI measurements within one month of EVT, at 6 and 12 months. Duplex scan is more sensitive to detect restenosis, but to date there is no clear evidence showing that DUS surveillance improves limb outcomes. Initial studies indicated that an abnormal first DUS (1–30 days after EVT) was associated with higher target lesion revascularisation at one year.^{71,72} More recently, DUS surveillance has been reported to predict severe in-stent restenosis with a specificity greater than 90%.⁷³ However, a DUS-based surveillance protocol at 3, 6 and 12 months after superficial femoral artery (SFA) or popliteal angioplasty with or without stenting reported a sensitivity and a specificity of 88% and 60%, respectively, to predict complete occlusion with 2 years of follow-up.⁵⁸ About half of severe restenoses present with ischaemic symptoms requiring reintervention, regardless of DUS findings. Whether identifying asymptomatic severe restenoses should lead to immediate reintervention or closer follow-up is uncertain. If restenosis requiring treatment is suspected in DUS, a digital subtraction angiogram is recommended and re-EVT if possible at the same session.

In conclusion, based on consensus rather than strong evidence, we recommend DUS surveillance after EVT by means of an initial test performed between discharge and one month; if the results are normal, DUS is recommended if symptoms reappear. However, if the initial DUS is abnormal, reintervention or closer DUS follow-up should be discussed on a case-by-case basis. The usefulness of a yearly DUS beyond 12 months in revascularised patients who remain asymptomatic has never been proved, and cannot be recommended as routine surveillance. These patients require a comprehensive cardiovascular surveillance focused on risk factor management, exercise training and medical therapy on a yearly basis.

Special aspects after revascularisation for CLTI

After revascularisation for CLTI, closer follow-up and wound care is recommended until wounds are healed, and 30-day, 3–6 and 12-month surveillance is recommended. After wound healing, annual appointments with vascular physicians/surgeons should be organised to check for symptoms, foot condition, ABI, cardiovascular risk factors as well as availability to check toe pressures and transcutaneous oxygen tension ($TcPO_2$) if needed (Table 1).

Conclusion

This paper aims to provide a standardised follow-up approach, based on a combination of evidence and

authors' expertise, emphasising the importance of a multidisciplinary management of these patients with an optimal, clinically reasonable and cost-effective strategy. This collaborative work highlights many gaps in the evidence and suggests collaborative research to provide further data and evidence in this setting.

Appointed reviewers

Sebastian Debus, Department of Vascular Medicine, University Heart Centre Hamburg, University Medical Centre Hamburg-Eppendorf, Hamburg, Germany; Melina De Vega, Department of Angiology and Vascular Surgery, Hospital de Galdakao-Usansolo, Bizkaia, Spain; Anders Gottsäter, Vascular Center, Department of Cardio-Thoracic and Vascular Surgery, Skåne University Hospital and Lund University, Sweden; Juraj Madaric, Department of Cardiology and Angiology, National Institute of Cardiovascular Diseases, Bratislava, Slovakia; Antonio Micari, Humanitas Gavazzeni Hospital, Bergamo, Italy; Emmanuel Messas, Department of Vascular Medicine, Hôpital Européen Georges Pompidou, Université Paris Descartes Paris Cité Sorbonne, Paris, France; Katarina Naka, 2nd Cardiology Department, University of Ioannina Medical School, University Campus, Ioannina, Greece; Henrik Sillesen, Department of Vascular Surgery, Rigshospitalet, University of Copenhagen, Copenhagen, Denmark.

Author contribution

All authors (MVe, MS, ID, MBj, MBr, TC, MDC, CEK, SK, LM, RN, MVI, JBR and VA) contributed to the conception and design of the work, drafted the manuscript, critically revised the manuscript, gave final approval and agree to be accountable for all aspects of the work ensuring integrity and accuracy.

Declaration of conflicting interests

The author(s) declared no potential conflicts of interest with respect to the research, authorship, and/or publication of this article.

Funding

The author(s) received no financial support for the research, authorship, and/or publication of this article.

References

1. Fowkes FG, Rudan D, Rudan I, et al. Comparison of global estimates of prevalence and risk factors for peripheral artery disease in 2000 and 2010: a systematic review and analysis. *Lancet* 2013; 382: 1329–1340.
2. Timmis A, Townsend N, Gale C, et al. European Society of Cardiology: cardiovascular disease statistics 2017. *Eur Heart J* 2018; 39: 508–579.
3. Aboyans V, Ricco J-B, Bartelink M-LEL, et al. 2017 ESC Guidelines on the diagnosis and treatment of peripheral arterial diseases, in collaboration with the European

- Society for Vascular Surgery (ESVS). *Eur Heart J* 2018; 39: 763–816.
4. Eickmeyer F, Moysidis T, Nowak T, et al. Trends in lower extremity surgical and endovascular revascularization in Germany. *VASA* 2011; 40: 398–403.
5. Lau GT, Ridley LJ, Bannon PG, et al. Lumen loss in the first year in saphenous vein grafts is predominantly a result of negative remodeling of the whole vessel rather than a result of changes in wall thickness. *Circulation* 2006; 114: 1435–1440.
6. Conte MS, Bandyk DF, Clowes AW, et al. Results of PREVENT III: a multicenter, randomized trial of edofoligide for the prevention of vein graft failure in lower extremity bypass surgery. *J Vasc Surg* 2006; 43: 742–751.
7. Naylor AR, Ricco JB, de Borst GJ, et al. Management of atherosclerotic carotid and vertebral artery disease: 2017 Clinical Practice Guidelines of the European Society for Vascular Surgery (ESVS). *Eur J Vasc Endovasc Surg* 2018; 55: 3–81.
8. Hellings WE, Moll FL, de Vries JP, et al. Histological characterization of restenotic carotid plaques in relation to recurrence interval and clinical presentation: a cohort study. *Stroke* 2008; 39: 1029–1032.
9. Davies MG and Hagen PO. Pathobiology of intimal hyperplasia. *Br J Surg* 1994; 81: 1254–1269.
10. Owens CD, Gasper WJ, Rahman AS, et al. Vein graft failure. *J Vasc Surg* 2015; 61: 203–216.
11. Cugusi L, Manca A, Yeo TJ, et al. Nordic walking for individuals with cardiovascular disease: a systematic review and meta-analysis of randomized controlled trials. *Eur J Prev Cardiol* 2017; 24: 1938–1955.
12. Dopheide JF, Rubrech J, Trumpp A, et al. Supervised exercise training in peripheral arterial disease increases vascular shear stress and profunda femoral artery diameter. *Eur J Prev Cardiol* 2017; 24: 178–191.
13. Kirchberger I, Amann U, Heier M, et al. Presenting symptoms, pre-hospital delay time and 28-day case fatality in patients with peripheral arterial disease and acute myocardial infarction from the MONICA/KORA Myocardial Infarction Registry. *Eur J Prev Cardiol* 2017; 24: 265–273.
14. Shalaeva EV, Saner H, Janabaev BB, et al. Tenfold risk increase of major cardiovascular events after high limb amputation with non-compliance for secondary prevention measures. *Eur J Prev Cardiol* 2017; 24: 708–716.
15. Lal BK, Beach KW, Roubin GS, et al. Restenosis after carotid artery stenting and endarterectomy: a secondary analysis of CREST, a randomised controlled trial. *Lancet Neurol* 2012; 11: 755–763.
16. Kumar R, Batchelder A, Saratzis A, et al. Restenosis after carotid interventions and its relationship with recurrent ipsilateral stroke: a systematic review and meta-analysis. *Eur J Vasc Endovasc Surg* 2017; 53: 766–775.
17. Arquizan C, Trinquart L, Touboul PJ, et al. Restenosis is more frequent after carotid stenting than after endarterectomy: the EVA-3S study. *Stroke* 2011; 42: 1015–1020.
18. Avgerinos ED, Go C, Ling J, et al. Carotid artery disease progression and related neurologic events after carotid endarterectomy. *J Vasc Surg* 2016; 64: 354–360.

19. Naylor AR, John T, Howlett J, et al. Fate of the non-operated carotid artery after contralateral endarterectomy. *Br J Surg* 1995; 82: 44–48.
20. Oates CP, Naylor AR, Hartshorne T, et al. Joint recommendations for reporting carotid ultrasound investigations in the United Kingdom. *Eur J Vasc Endovasc Surg* 2009; 37: 251–261.
21. von Reutern GM, Goertler MW, Bornstein NM, et al. Grading carotid stenosis using ultrasonic methods. *Stroke* 2012; 43: 916–921.
22. Lal BK, Hobson RW 2nd, Tofighi B, et al. Duplex ultrasound velocity criteria for the stented carotid artery. *J Vasc Surg* 2008; 47: 63–73.
23. Stanziale SF, Wholey MH, Boules TN, et al. Determining in-stent stenosis of carotid arteries by duplex ultrasound criteria. *J Endovasc Ther* 2005; 12: 346–353.
24. van de Weijer MA, Vonken EJ, de Vries JP, et al. Technical and clinical success and long-term durability of endovascular treatment for atherosclerotic aortic arch branch origin obstruction: evaluation of 144 procedures. *Eur J Vasc Endovasc Surg* 2015; 50: 13–20.
25. Babic S, Sagic D, Radak D, et al. Initial and long-term results of endovascular therapy for chronic total occlusion of the subclavian artery. *Cardiovasc Interv Radiol* 2012; 35: 255–262.
26. Duran M, Grottemeyer D, Danch MA, et al. Subclavian carotid transposition: immediate and long-term outcomes of 126 surgical reconstructions. *Ann Vasc Surg* 2015; 29: 397–403.
27. Modarai B, Ali T, Dourado R, et al. Comparison of extra-anatomic bypass grafting with angioplasty for atherosclerotic disease of the supra-aortic trunks. *Br J Surg* 2004; 91: 1453–1457.
28. Przewlocki T, Wrotniak L, Kablak-Ziembicka A, et al. Determinants of long-term outcome in patients after percutaneous stent-assisted management of symptomatic subclavian or innominate artery stenosis or occlusion. *EuroIntervention* 2017; 13: 1355–1364.
29. Bjorck M, Koelemay M, Acosta S, et al. Editor's choice – Management of the diseases of mesenteric arteries and veins: clinical practice guidelines of the European Society of Vascular Surgery (ESVS). *Eur J Vasc Endovasc Surg* 2017; 53: 460–510.
30. AbuRahma AF, Stone PA, Srivastava M, et al. Mesenteric/cealic duplex ultrasound interpretation criteria revisited. *J Vasc Surg* 2012; 55: e426; 428–436; discussion 435–426.
31. Tallarita T, Oderich GS, Macedo TA, et al. Reinterventions for stent restenosis in patients treated for atherosclerotic mesenteric artery disease. *J Vasc Surg* 2011; 54: e1421; 1422–1429.
32. Sharafuddin MJ, Nicholson RM, Kresowik TF, et al. Endovascular recanalization of total occlusions of the mesenteric and celiac arteries. *J Vasc Surg* 2012; 55: 1674–1681.
33. Iwashima Y, Fukuda T, Yoshihara F, et al. Incidence and risk factors for restenosis, and its impact on blood pressure control after percutaneous transluminal renal angioplasty in hypertensive patients with renal artery stenosis. *J Hypertens* 2016; 34: 1407–1415.
34. Mousa AY, Campbell JE, Stone PA, et al. Short- and long-term outcomes of percutaneous transluminal angioplasty/stenting of renal fibromuscular dysplasia over a ten-year period. *J Vasc Surg* 2011; 55: 421–427.
35. Patel VI, Conrad MF, Kwolek CJ, et al. Renal artery revascularization: outcomes stratified by indication for intervention. *J Vasc Surg* 2009; 49: 1480–1489.
36. Boateng FK and Greco BA. Renal artery stenosis: prevalence of, risk factors for, and management of in-stent stenosis. *Am J Kidney Dis* 2013; 61: 147–160.
37. Schaberle W, Leyerer L, Schierling W, et al. Ultrasound diagnostics of renal artery stenosis: stenosis criteria, CEUS and recurrent in-stent stenosis. *Gefasschirurgie* 2016; 21: 4–13.
38. Fleming SH, Davis RP, Craven TE, et al. Accuracy of duplex sonography scans after renal artery stenting. *J Vasc Surg* 2010; 52: 953–957; discussion 958.
39. Zeller T, Sixt S, Rastan A, et al. Treatment of reoccurring in-stent restenosis following reintervention after stent-supported renal artery angioplasty. *Catheter Cardiovasc Interv* 2007; 70: 296–300.
40. Olin JW, Gornik HL, Bacharach JM, et al. Fibromuscular dysplasia: state of the science and critical unanswered questions: a scientific statement from the American Heart Association. *Circulation* 2014; 129: 1048–1078.
41. Wilson YG, Davies AH, Currie IC, et al. Vein graft stenosis: incidence and intervention. *Eur J Vasc Endovasc Surg* 1996; 11: 164–169.
42. Bandyk DF, Bergamini TM, Towne JB, et al. Durability of vein graft revision: the outcome of secondary procedures. *J Vasc Surg* 1991; 13: 200–208; discussion 209–210.
43. Mills JL. Mechanisms of vein graft failure: the location, distribution, and characteristics of lesions that predispose to graft failure. *Semin Vasc Surg* 1993; 6: 78–91.
44. Shah DM, Darling RC 3rd, Chang BB, et al. Long-term results of in situ saphenous vein bypass. Analysis of 2058 cases. *Ann Surg* 1995; 222: 438–446; discussion 446–438.
45. Disselhoff B, Buth J and Jakimowicz J. Early detection of stenosis of femoro-distal grafts. A surveillance study using colour-duplex scanning. *Eur J Vasc Surg* 1989; 3: 43–48.
46. Ihlberg L, Luther M, Alback A, et al. Does a completely accomplished duplex-based surveillance prevent vein-graft failure? *Eur J Vasc Endovasc Surg* 1999; 18: 395–400.
47. Meissner OA, Verrel F, Tato F, et al. Magnetic resonance angiography in the follow-up of distal lower-extremity bypass surgery: comparison with duplex ultrasound and digital subtraction angiography. *J Vasc Interv Radiol* 2004; 15: 1269–1277.
48. Green RM, McNamara J, Ouriel K, et al. Comparison of infrainguinal graft surveillance techniques. *J Vasc Surg* 1990; 11: 207–214; discussion 214–205.
49. Bjorkman P, Kokkonen T, Alback A, et al. Drug-coated vs. plain balloon angioplasty in bypass vein grafts (the DRECOREST I-study). *Ann Vasc Surg* 2019; 55: 36–44.
50. Liang NL, Baril DT, Avgerinos ED, et al. Comparative effectiveness of anticoagulation on midterm infrainguinal bypass graft patency. *J Vasc Surg* 2017; 66: e492; 499–505.

51. Saarinen E, Kauhanen P, Soderstrom M, et al. Long-term results of inframalleolar bypass for critical limb ischaemia. *Eur J Vasc Endovasc Surg* 2016; 52: 815–822.
52. Armstrong PA, Bandyk DF, Wilson JS, et al. Optimizing infrainguinal arm vein bypass patency with duplex ultrasound surveillance and endovascular therapy. *J Vasc Surg* 2004; 40: 724–730.
53. McLafferty RB, Moneta GL, Masser PA, et al. Progression of atherosclerosis in arteries distal to lower extremity revascularizations. *J Vasc Surg* 1995; 22: 450–455; discussion 455–456.
54. Ambler GK and Twine CP. Graft type for femoro-popliteal bypass surgery. *Cochrane Database Syst Rev* 2018; 2: Cd001487.
55. Sigvant B, Lundin F and Wahlberg E. The risk of disease progression in peripheral arterial disease is higher than expected: a meta-analysis of mortality and disease progression in peripheral arterial disease. *Eur J Vasc Endovasc Surg* 2016; 51: 395–403.
56. Jaff MR. IN.PACT Global full clinical cohort. *VIVA 2016 Congress*. Las Vegas, NV, 2016.
57. Shishehbor MH and Jaff MR. Percutaneous therapies for peripheral artery disease. *Circulation* 2016; 134: 2008–2027.
58. Bui TD, Mills JL Sr., Ihnat DM, et al. The natural history of duplex-detected stenosis after femoropopliteal endovascular therapy suggests questionable clinical utility of routine duplex surveillance. *J Vasc Surg* 2012; 55: 346–352.
59. Pulli R, Dorigo W, Fargion A, et al. Early and long-term comparison of endovascular treatment of iliac artery occlusions and stenosis. *J Vasc Surg* 2011; 53: 92–98.
60. Dake MD, Ansel GM, Jaff MR, et al. Durable clinical effectiveness with paclitaxel-eluting stents in the femoropopliteal artery: 5-year results of the Zilver PTX Randomized Trial. *Circulation* 2016; 133: 1472–1483; discussion 1483.
61. Lo RC, Darling J, Bensley RP, et al. Outcomes following infrapopliteal angioplasty for critical limb ischemia. *J Vasc Surg* 2013; 57: 1455–1463; discussion 1463–1454.
62. Spreen MI, Martens JM, Knippenberg B, et al. Long-term follow-up of the PADI Trial: Percutaneous Transluminal Angioplasty Versus Drug-Eluting Stents for Infrapopliteal Lesions in Critical Limb Ischemia. *J Am Heart Assoc* 2017; 6: e004877.
63. Bhatt DL, Steg PG, Ohman EM, et al. International prevalence, recognition, and treatment of cardiovascular risk factors in outpatients with atherothrombosis. *JAMA* 2006; 295: 180–189.
64. Nicoloff AD, Taylor LM Jr., Sexton GJ, et al. Relationship between site of initial symptoms and subsequent progression of disease in a prospective study of atherosclerosis progression in patients receiving long-term treatment for symptomatic peripheral arterial disease. *J Vasc Surg* 2002; 35: 38–46; discussion 46–47.
65. Nielsen TG. Natural history of infrainguinal vein bypass stenoses: early lesions increase the risk of thrombosis. *Eur J Vasc Endovasc Surg* 1996; 12: 60–64.
66. Brumberg RS, Back MR, Armstrong PA, et al. The relative importance of graft surveillance and warfarin therapy in infrainguinal prosthetic bypass failure. *J Vasc Surg* 2007; 46: 1160–1166.
67. Abu Dabrh AM, Mohammed K, Farah W, et al. Systematic review and meta-analysis of duplex ultrasound surveillance for infrainguinal vein bypass grafts. *J Vasc Surg* 2017; 66: 1885–1891; e1888.
68. Oresanya L, Makam AN, Belkin M, et al. Factors associated with primary vein graft occlusion in a multicenter trial with mandated ultrasound surveillance. *J Vasc Surg* 2014; 59: 996–1002.
69. Tinder CN, Chavanpun JP, Bandyk DF, et al. Efficacy of duplex ultrasound surveillance after infrainguinal vein bypass may be enhanced by identification of characteristics predictive of graft stenosis development. *J Vasc Surg* 2008; 48: 613–618.
70. McBride OMB, Mofidi R, Griffiths GD, et al. Development of a decision tree to streamline infrainguinal vein graft surveillance. *Ann Vasc Surg* 2016; 36: 182–189.
71. Spijkerboer AM, Nass PC, de Valois JC, et al. Evaluation of femoropopliteal arteries with duplex ultrasound after angioplasty Can we predict results at one year? *Eur J Vasc Endovasc Surg* 1996; 12: 418–423.
72. Mewissen MW, Kinney EV, Bandyk DF, et al. The role of duplex scanning versus angiography in predicting outcome after balloon angioplasty in the femoropopliteal artery. *J Vasc Surg* 1992; 15: 860–865.
73. Baril DT, Rhee RY, Kim J, et al. Duplex criteria for determination of in-stent stenosis after angioplasty and stenting of the superficial femoral artery. *J Vasc Surg* 2009; 49: 133–138.
74. AbuRahma AF, Stone P, Deem S, et al. Proposed duplex velocity criteria for carotid restenosis following carotid endarterectomy with patch closure. *J Vasc Surg* 2009; 50: 286–291.
75. Aburahma AF. Duplex criteria for determining $\geq 50\%$ and $\geq 80\%$ internal carotid artery stenosis following carotid endarterectomy with patch angioplasty. *Vascular* 2011; 19: 15–20.
76. Zhou W, Felkai DD, Evans M, et al. Ultrasound criteria for severe in-stent restenosis following carotid artery stenting. *J Vasc Surg* 2008; 47.
77. Soult MC, Wuamett JC, Ahanchi SS, et al. Duplex ultrasound criteria for in-stent restenosis of mesenteric arteries. *J Vasc Surg* 2016; 64: 1366–1372.
78. Del Conde I, Galin ID, Trost B, et al. Renal artery duplex ultrasound criteria for the detection of significant in-stent restenosis. *Catheter Cardiovasc Interv* 2014; 83: 612–618.
79. Chi YW, White CJ, Thornton S, et al. Ultrasound velocity criteria for renal in-stent restenosis. *J Vasc Surg* 2009; 50: 119–123.