



E-ISSN: 2707-8353

P-ISSN: 2707-8345

IJCRO 2025; 7(1): 26-28

[www.orthocasereports.com](http://www.orthocasereports.com)

Received: 13-12-2024

Accepted: 19-01-2025

**Renzone Nicolas**Orthopaedics Surgery, ULiege,  
Liège, Belgium**Daniel Christophe**Orthopaedics surgery, ULiege,  
Liège, Belgium**Dunand Xavier**Orthopaedics Surgery, ULiege,  
Liège, Belgium**Thirion Thierry**Orthopaedics Surgery, ULiege,  
Liège, Belgium**Corresponding Author:****Renzone Nicolas**Orthopaedics Surgery, ULiege,  
Liège, Belgium

## Multiligament Knee injury with MCL intra-articular incarceration: A case report

**Renzone Nicolas, Daniel Christophe, Dunand Xavier and Thirion Thierry**

**DOI:** <https://www.doi.org/10.22271/27078345.2025.v7.i1a.242>

### Abstract

Knee dislocations are rare but severe injuries, often associated with multiligament damage and potential neurovascular compromise. Intra-articular incarceration of the medial collateral ligament (MCL) is a rare but serious condition that may require urgent intervention. This case report presents a rare instance of multiligament knee injury with MCL incarceration, discusses the mechanism of injury, and details the surgical management. A 45-year-old man was admitted to the emergency department with severe knee pain and deformity following a skiing accident. Radiographs showed lateral tibial translation with a widened medial joint space, and MRI confirmed a multiligament injury, including a complete anterior cruciate ligament (ACL) rupture, a subtotal posterior cruciate ligament (PCL) rupture, and a complete proximal MCL rupture with intra-articular incarceration. The patient underwent a two-stage surgical approach. The first procedure involved an arthroscopic reduction of the incarcerated MCL bundle, followed by extra-articular extrusion and reattachment using two suture anchors. Due to persistent knee instability, a second surgery was performed, consisting of ACL and PCL reconstruction using synthetic LARS ligaments and an extra-articular Lemaire plasty. Postoperative imaging confirmed well-positioned graft tunnels and joint realignment. The patient was immobilized in a Jack brace and followed a structured rehabilitation protocol. This case highlights the importance of early recognition and management of multiligament knee injuries. MCL incarceration can lead to complications such as skin necrosis, necessitating timely reduction. Proximal MCL tears are known to have a poorer prognosis with residual valgus laxity, making surgical intervention crucial. When addressing multiligament injuries, ACL and PCL reconstruction should be prioritized, especially in cases of significant instability. Due to the complexity of such injuries, treatment should be performed by an experienced knee surgeon to ensure optimal outcomes.

**Keywords:** Medial collateral ligament tears, knee dislocation, knee multiligament injury

### Introduction

Knee dislocations are uncommon, accounting for only 0.02% of all orthopedic traumas <sup>[1]</sup>. They typically result from high energy trauma <sup>[2]</sup> and often lead to severe knee injuries involving multiple ligaments <sup>[3]</sup>. Furthermore, they are often associated with neurovascular complications, making early diagnosis and appropriate management crucial. Recognising the signs of a multiligament knee injury and understanding optimal management strategies are essential to improve patient outcomes. In this article, we present a rare case of multiligament knee injury with MCL intra-articular incarceration. We discuss the presumed mechanism of injury and describe the surgical approach applied in this case.

### Case report

A 45-year-old man was admitted to the emergency department with severe pain and a visible deformity of the left knee following a skiing accident. Clinical examination revealed no neurovascular deficits. Radiographs (Fig 1) showed lateral translation of the tibia with an increased medial femoro-tibial space and a significant intra-articular effusion. MRI confirmed a multiligament knee injury including a complete rupture of the anterior cruciate ligament (ACL), a subtotal rupture of the posterior cruciate ligament (PCL) and a complete proximal rupture of the MCL with intra-articular incarceration of the deep bundle (Fig 2).

The patient underwent a two-stage surgical management. First, an arthroscopic reduction of the incarcerated MCL bundle was performed, followed by its extra-articular extrusion and reattachment using two suture anchors. Despite the initial procedure, the knee remained unstable with both anterior and posterior drawer signs and rotational instability. A second procedure was therefore required, consisting of arthroscopic ligament reconstruction of both

the ACL and PCL (Fig. 3). Since the MCL had previously been sutured, a standard hamstring (DIDT) graft technique was avoided to prevent additional damage to the repaired ligament. Instead, two synthetic LARS ligaments were used for reconstruction. In addition, a Lemaire extraarticular plasty was performed to improved rotational stability. Post-operative radiographs confirmed well-positioned graft tunnels and proper alignment of the knee joint (Fig 4). The patient was immobilized in a Jack brace and followed a structured rehabilitation protocol.

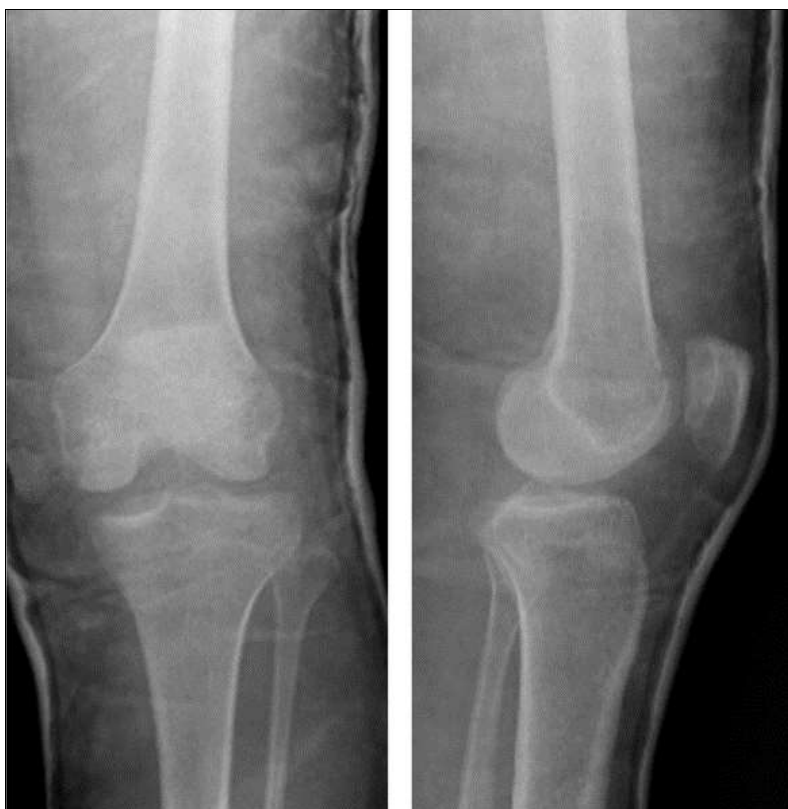### Discussion

The present case demonstrates a rare presentation of a MCL grade III rupture with intra-articular incarceration. Approximately 80% of MCL grade III injuries occur in the context of multiligament knee trauma [4]. In this case, the combination of MCL, ACL and partial PCL ruptures suggests a lateral knee dislocation in valgus stress. Using the Schenck classification system, this injury was categorized as a grade KD III knee dislocation [3, 5]. The incarceration of the MCL can sometimes be seen clinically if the 'enchoche sign' is present. It is a transversal cutaneous fold at the medial joint line which indicates an

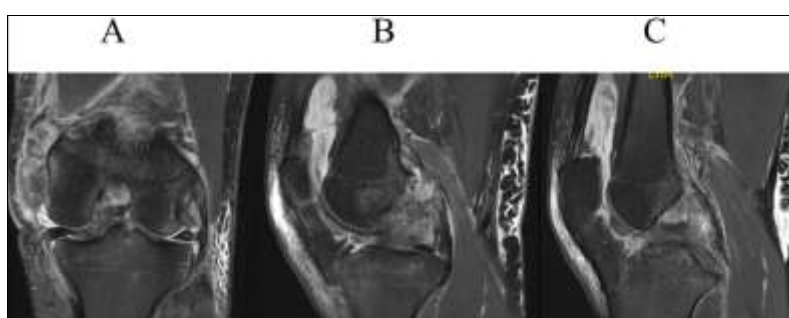
invagination of the MCL between the femoral condyle and the medial tibial plateau. This finding is significant, as prolonged incarceration can lead to skin necrosis, necessitating urgent open reduction [6, 7]. However, this sign was absent in our case and no neurovascular complications were observed. This lesion shows better postoperative knee stability if treated in the first three weeks of the injury [8].

An arthroscopic reduction of the MCL was performed two weeks after the injury followed by suture fixation to its femoral attachment using two anchors. The patient was then placed in a articulated brace. Given the generally poorer prognosis of proximal MCL ruptures compared to distal ones—particularly due to increased residual valgus laxity [9]—postoperative rehabilitation was approached with caution.

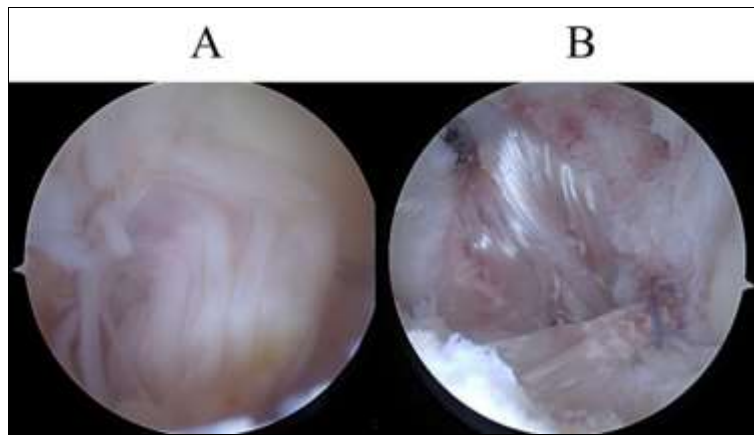
Despite initial MCL repair, the knee remained highly unstable, with a persistently positive posterior drawer test. This warranted subsequent ACL and PCL reconstruction, despite the PCL appearing only partially ruptured on MRI. This suggests that in similar cases, central pivot ligament injuries should be addressed early, either before or in conjunction with MCL repair [10].



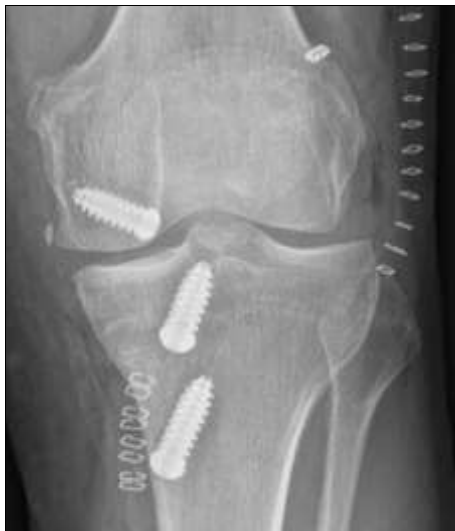**Fig 1:** Radiograph showing a widened medial joint space and lateral tibial translation.



**Fig 2:** (A) MRI demonstrating MCL incarceration. (C) Complete ACL rupture. (D) Partial PCL rupture.



**Fig 3:** (A) Arthroscopic view showing compromised PCL fibers. (B) ACL and PCL ligament reconstruction.



**Fig 4:** Postoperative radiographs showing well-placed graft tunnels, restored joint alignment, and reduction of medial joint space widening.

### Conclusion

MCL incarceration is a severe injury that may require emergency reduction. It is important to suspect associated multiligament injuries as they frequently result from knee dislocation. Given the potential risk of neurovascular compromise, prompt diagnosis and management are essential.

When treating multiligament knee injuries, ACL reconstruction should be performed as a priority either before or during MCL repair. If a posterior drawers test is present with signs of PCL rupture on the RMN, a PCL reconstruction should be performed in priority.

These are complex procedures, which should be performed by an experienced knee surgeon to ensure optimal functional outcomes.

**Funding:** The authors declare no funding.

**Declaration of competing interest:** The authors declare no conflict of interest.

### References

1. Rihn JA, Groff YJ, Harner CD, Cha PS. The acutely dislocated knee: evaluation and management. *Journal of the American Academy of Orthopaedic Surgeons*. 2004;12:334-346.

2. Brautigan B, Johnson DL. The epidemiology of knee dislocations. *Clinics in Sports Medicine*. 2000;19:387-397.
3. Taft TN, Almenkinders LC. The dislocated knee. In: Fu F, editor. *Knee Surgery*. Baltimore: Williams & Wilkins; c1994. p. 837-857.
4. Fetto JF, Marshall JL. Medial collateral ligament injuries of the knee: a rationale for treatment. *Clinical Orthopaedics and Related Research*. 1978 May;(132):206-218. PMID: 67954.
5. Schenck RC Jr. The dislocated knee. *Instructional Course Lectures*. 1994;43:127-136.
6. Wand J. A physical sign denoting irreducibility of a dislocated knee. *Journal of Bone and Joint Surgery - British Volume*. 1989;71-B(5):862. DOI:10.1302/0301-620X.71B5.2584265.
7. Patel JJ. Intra-articular entrapment of the medial collateral ligament: radiographic and MRI findings. *Skeletal Radiology*. 1999 Nov;28(11):658-660. DOI:10.1007/s002560050570. PMID: 10591931.
8. Harner CD, Waltrip RL, Bennett CH, Francis KA, Cole B, Irrgang JJ. Surgical management of knee dislocations. *Journal of Bone and Joint Surgery - American Volume*. 2004;86-A:262-273.
9. Robins AJ, Newman AP, Burks RT. Postoperative return of motion in anterior cruciate ligament and medial collateral ligament injuries: The effect of medial collateral ligament rupture location. *The American Journal of Sports Medicine*. 1993;21(1):20-25. DOI:10.1177/036354659302100104.
10. EFORT Open Reviews. 2018;3:398-407. DOI:10.1302/2058-5241.3.170035.

### How to Cite This Article

Nicolas R, Christophe D, Xavier D, Thierry T. Multiligament Knee injury with MCL intra-articular incarceration: A case report. *International Journal of Case Reports in Orthopaedics*. 2025; 7(1): 26-28.

### Creative Commons (CC) License

This is an open access journal, and articles are distributed under the terms of the Creative Commons Attribution-NonCommercial-ShareAlike 4.0 International (CC BY-NC-SA 4.0) License, which allows others to remix, tweak, and build upon the work non-commercially, as long as appropriate credit is given and the new creations are licensed under the identical terms.