



ESGE
32nd
ANNUAL
CONGRESS

Create history by shaping the future

1st - 4th October 2023
Brussels BELGIUM



OFFICIAL ABSTRACT PUBLICATION

of the ESGE 32nd Annual Congress

1st - 4th October 2023 | Brussels, Belgium

FACTS, VIEWS & VISION

Journal of the European Society for Gynaecological Endoscopy (ESGE)

inObGyn

Volume 15 | Number 3 | September 2023
Supplement 1

BEST SELECTED ABSTRACTS ORAL

ES32-0121 -

Best Selected Abstracts 1

Same day discharge following total laparoscopic hysterectomy: realistic target or utopian thought?

Lina Antoun¹, Paul Smith², Emily Fox², Gemma Clarke², T Justin Clark²

¹Birmingham Women's Hospital, Obstetrics and Gynaecology, Birmingham, United Kingdom

²Birmingham Women's Hospital, Gynaecology, Birmingham, United Kingdom

Background

Laparoscopic hysterectomies (LH) in the UK increased significantly over the last 20 years compared to abdominal or vaginal approach. The implementation of an enhanced recovery pathway requires changes to clinical interventions and supporting clinical systems. The process of change is multifaceted and iterative and starts with awareness raising and winning hearts and minds.

Methods

A prospective observational cohort study. The laparoscopic hysterectomies were undertaken at the Birmingham Women's and Children's Hospital (BWC). Data was collected from February 2021-May 2023.

We also invited all BSGE (British Society of Gynaecological Endoscopy) members to complete a short survey which we hope will illustrate some common practices, differences, and potentially even heated debate about how to optimise this Quality Improvement Initiative in the years to come.

Results

Short-stay hysterectomy procedures were completed successfully in 71/92 (77%) of eligible cases. Day case laparoscopic hysterectomy patients were less likely to have undergone a previous laparotomy ($P < 0.001$), and less likely to have undergone a caesarean delivery ($P < 0.001$).

Most readmissions within 7 days were due to Clavien-Dindo (grade 1) 2/71 (3%) post-operative complications: upper respiratory tract infection, pyelonephritis, wound dehiscence. Two patients 2/71 (3%) were re-admitted post-operatively due to Clavien-Dindo (grade 3b) complication: pelvic collection, ureteric thermal injury.

The main barriers to same day discharge were surgeon decision, pain, nausea and vomiting scores and the use of anti-emetics. Early introduction of diet, opioids, laxatives and anti-emetics made no significant difference between the two groups of patients. Patients who had their catheter removed in theatre at the end of the procedure or within 6 hours were more likely to go home same day compared to patients who had their catheter for more than 6 hours.

For our BSGE survey, we had 85 respondents from different centres in the UK. Respondents were asked if have a specific protocol /pathway for the implementation of SDD for TLH in their hospital, and elements of the pathway were discussed in the survey including (Patient's selection, analgesia/pain relief, catheter removal, mobilisation, eating and drinking, anaesthetic protocol, and nursing support).

Conclusions

•Day case hysterectomy is comparably safe, feasible and effective for benign conditions, and early stage cervical or endometrial cancer.

•Successful same-day discharge can be optimised by implementing a short-stay pathway to ensure:

- Appropriate patient selection and information
- Standardised protocols for care according to best evidence where available
- Establishing nurse-led discharge and follow up
- Understand factors associated with prolonged admission and try to mitigate against these
- Reduce hospital costs and decrease iatrogenic complications associated with hospitalisation such as infection

Furthermore, implementation of a national perioperative quality improvement program targeted to enhance recovery following laparoscopic hysterectomy can significantly improve same day discharge rates while maintaining a low 30 day perioperative complication rate and excellent patient experience.

**ES32-0182 -
Best Selected Abstracts 1**

Transvaginal ultrasound evaluation according to #Enzian classification and symptoms: new frontiers in endometriosis diagnosis

Consuelo Russo¹, Lucia Lazzeri², Aikaterini Selintigia¹, Francesco Martire¹, Errico Zupi², Caterina Exacoustos¹

¹University of Rome "Tor Vergata"- Rome- Italy.,

Department of Surgical Sciences- Obstetrics and Gynecological Clinic, Rome, Italy

²University of Siena,

Department of Molecular and Developmental Medicine- Obstetrics and Gynecological Clinic, Siena, Italy

Background

New #Enzian classification represents a system to describe endometriotic lesions during surgery. Its use was well established in correlating ultrasound findings with surgical ones. This study aimed to describe its ultrasound feasibility and interobserver reproducibility and to correlate symptoms with the compartments involved.

Methods

To assess interobserver reproducibility, two experienced operators (A and B), independently, performed twice transvaginal sonography (TVS) in 52 patients affected by pelvic endometriosis. Rate agreement between the two operators was determined. To correlate symptoms with the different compartments, other 200 women with endometriotic TVS signs, with no previous surgery and not taking any hormonal therapy, were staged according to the #Enzian (compartments A, B, C, O, T, FA, FB, FI, FU, FO). Statistical analysis compared all the compartments, as single or associated, with single or combined symptoms (dysmenorrhea, dyspareunia, heavy menstrual bleeding-HMB-, bowel symptoms).

Results

We observed an excellent agreement between the two operators in evaluating almost all the compartments ($k > 0,8$) and a good agreement in studying FA and compartment A ($k > 0,7$). In our population, dysmenorrhea was the most represented symptom; it resulted not correlate with any specific compartment, so it was considered associated with other symptoms analysed. We observed a significant association between dyspareunia and B ($p=0.02$), A+B ($p=0.01$), B+FA ($p<0.01$), T+FA ($p<0.01$), and A+B+FA ($p<0.01$). HMB is statistically associated with FA ($p=0.02$) and B+C ($p=0.01$). Bowel symptoms showed a significant association with B ($p=0.02$) and A+C ($p=0.04$). Combining more symptoms, we found more statistical significance; dyspareunia and HMB showed more association with compartments B+C ($p=0.01$), B+FA ($p=0.03$), and A+B+FA ($p=0.05$). Dyspareunia and bowel symptoms are associated with the combination of compartments B+C ($p=0.02$), B+O ($p<0.01$), A+T ($p=0.04$), A+B ($p=0.01$), B+FA (<0.01), T+FA ($p=0.01$) and A+B+FA ($p=0.01$). In patients with HMB and bowel symptoms more frequently occurred lesions in compartments B+C ($p=0.02$), A+B ($p=0.05$), T+FA ($p=0.01$), and A+B+FA ($p=0.05$).

Conclusions

New #ENZIAN classification is reproducible and easy to use in the evaluation of pelvic endometriosis. Some symptoms are correlated to specific ultrasound signs and can guide the TVS examination to detect specific endometriotic lesions and establish the best management for these patients.

**ES32-0190 -
Best Selected Abstracts 1**

Could 3D ultrasound measurements of septate uterus predict septal remnants after metroplasty?

Federica Iacobini¹, Consuelo Russo¹, Giulia Monaco¹, Sara Valeriani¹, Elvira Nocita¹, Caterina Exacoustos¹
¹*University of Rome Tor Vergata- Italy, Department of Surgical Sciences- Gynaecologic and Obstetrics Unit, Rome, Italy*

Background

Septate uterus is the most common congenital uterine anomaly and is associated with poor reproductive and obstetrics outcomes. In patients with reproductive problems hysteroscopic metroplasty is the most effective treatment in correcting this anomaly with the resultant restoration of the uterine cavity and improvement of fertility. After hysteroscopic metroplasty, residual septal remnants or adhesions are not infrequent, resulting in subsequent reproductive failures and in repeated surgery. The purpose of this study was to evaluate by 3D transvaginal sonography (TVS) uterine cavity morphology of septate uteri and to correlate measurements before and after metroplasty in order to assess possible ultrasound parameters that can predict septal remnants.

Methods

In this study, we included 54 pre-menopausal patients with a septate uterus (U2 ESHRE-ESGE classification) diagnosed by 3D TVS, underwent hysteroscopic metroplasty. All patients underwent, after at least two months from surgery, 3D TVS evaluation of the uterine cavity. On the coronal view septal length (L), uterine cavity width (W), uterine fundal wall thickness (M), fundal indentation angle (α) and the ratios L/M, W/L and L/ α were measured and all the measurements before and after metroplasty were compared. We exclude patients with L \leq 5 mm.

Results

Of the 54 patients with septate uterus, 12/54 (22.2%) were U2b and 42/54 (77.8%) were U2a. We observed in all 54 patients statistically significant differences comparing L (14.0 ± 4.2 vs 9.5 ± 3.5 , $p < 0.0001$), α (100 ± 11.3 vs 127.5 ± 14.8 , $p < 0.0001$) and W (37.5 ± 3.5 vs 35.5 ± 0.7 , $p < 0.0001$) before and after metroplasty. After metroplasty we obtained 28/54 patients (51.8%) without septal remnant and 26/54 (48.1%) classified as U2a. Comparing the measurements before metroplasty of these two groups, we noticed statistically significant higher length (14.0 ± 12.7 vs 9.5 ± 0.7 , $p=0.01$), smaller width (32.5 ± 4.2 vs 37.0 ± 7.0 , $p 0.001$) and lower angle α (100.0 ± 31.1 vs 115.0 ± 21.2 , $p= 0.002$) in patients with septal remnants (U2a).

Conclusions

3D TVS is a useful non-invasive tool to diagnose and follow-up uterine septa. Angle and length before metroplasty are correlated to septal remnant and could be used to counselling the patients to perform a 3D follow-up and eventually a second procedure.

Prevalence of T-shaped uterus in infertile patients according to Congenital Uterine Malformations by Experts (CUME) diagnostic criteria

Eyuphan Ozgozen¹, Onur Yavuz¹, Begum Ertan¹, Omer Erbil Dogan¹

¹*Dokuz Eylul University Faculty of Medicine, Obstetrics and Gynecology, Izmir, Turkey*

Background

T shaped uterus (Class U1-a) according to ESHRE/ESGE classification is a rare uterine anomaly of unknown significance in infertile patients and without any established objective diagnostic criteria. Recently, CUME has described diagnostic criteria for this anomaly using three-dimensional ultrasonography (3D-US) which is a highly accurate and non-invasive imaging method in diagnosing uterine pathologies. The aim of the study is to determine the prevalence of T-shaped uteri and other congenital anomalies by 3D-US in patients with infertility using the CUME criteria.

Methods

This prospective cohort study included 476 patients (age range 18-45) with primary or secondary infertility and/or recurrent abortions. Participants were recruited from a university hospital infertility clinic between January 2020 and December 2022. 3D US transvaginal examination were performed during the luteal phase of the menstrual cycle (21st- 25th day). Abnormal findings were defined according to the ESHRE/ESGE classification of congenital anomalies of the female genital tract. CUME criteria were used for the diagnosis of T-shaped uterus. Patients with pathologies distorting the shape of the uterine cavity or failure to create a suitable coronal view image with 3D USG were excluded. Additional morphometric measurements including uterine volume were also performed. The study was approved by Dokuz Eylul University Ethics Committee.

Results

Overall, 13% of the patients had congenital uterine anomalies (64/476). Among the population, 4% had borderline and 1.9% had complete T-shaped uterine anomaly. Other congenital anomalies were %5.9 uterine septum, %0.8 hemiuterus and %0.4 bicorporal uterus. Recurrent abortion (²) rates were higher in the borderline (%21.1 [4/19]), and T shaped uterus (%22.2 [2/9]) groups compared to the normal uterus group (11.4% [47/414]), although the difference did not reach a significant value ($p>0.05$). Additionally, we defined the percentile ranges for the 3 main measurements for CUME criteria, namely the T and lateral indentation angles and the lateral indentation depth. Percentile cut off values were similar with CUME criteria for both the lateral indentation depth (6.4mm versus 7mm [90th]) and the lateral indentation angle (129° versus 130° [10th]). However, 10th percentile cut off for T angle value was narrower than the accepted CUME criteria (32° versus 40°).

Conclusions

This is the first study demonstrating the prevalence of T shaped uterus in a group of infertile patients using objective diagnostic criteria with 3D-US. Previous studies using subjective criteria have shown that prevalence of this anomaly ranged between 0.1%-3.7%. In a study with patients of proven fertility using CUME criteria reported a 0.4% prevalence, which seems to be lower than our prevalence of 1.9% in the infertile group. Patients with T shaped uterus may have increased risk for abnormal reproductive outcomes. Further studies using objective diagnostic criteria are needed to evaluate the effect of T-shaped uterine anomaly on reproductive outcomes.

Unmasking the hidden player: are subtle endometrial lesions hindering the success of the infertility treatments

Roger MOLINAS¹, Jorge Gavilán Herreros¹, Diego Daniel Manavella¹, Gustavo Daniel Manavella¹, Oscar Ruiz Valdés¹, Conrado Avendaño¹
¹Neolife - Medicina y Cirugía Reproductiva, Neolife - Medicina y Cirugía Reproductiva, Asunción, Paraguay

Background

This retrospective observational study was designed to determine the prevalence of subtle endometrial lesions in infertility patients undergoing hysteroscopy, and to evaluate the impact of these lesions upon ART outcomes.

Methods

All hysteroscopies were performed by experts hysteroscopists using the same technique and instrumentation in a single fertility centre in Asunción, Paraguay.

For the first objective, the hysteroscopic findings 1879 consecutive patients were evaluated. According to the indication, patients were grouped in two groups: infertility only (n=1725) and infertility with abnormal uterine bleeding (AUB) (n=154). Findings were classified as normal or abnormal, including major lesions (structural deformation of the normal uterine cavity), and subtle lesions (changes in endometrial appearance but without deformation of the uterine cavity). Some of these lesions are associated with chronic endometritis (strawberry pattern, focal hyperaemia, haemorrhagic spots, focal/diffuse micropolyps, thick/pale endometrium), whereas others with adenomyosis (endometrial cysts and cracks and focal hypervascularization).

For the second objective, 262 patients aged <40 years submitted to IVF were classified in two groups: normal hysteroscopy (n=189), and subtle lesions (n=73). IVF was performed according to the clinical standards and 1-2 blastocysts were transferred on fresh or frozen cycles.

Prevalence of finding and IVF outcomes were evaluated with appropriate statistics tests.

Results

In patients with infertility only, normal (n=860, 50%) and abnormal (n=865, 50%) findings were equally distributed, being the abnormalities: endometrial polyps (22%), submucous myomas (5%), malformations (8%), adhesions (11%), isthmocele (12%), thick/hypervascularized endometrium (4%), cervical stenosis (9%), endocervical polyps (6%), and subtle lesions (23%), 68% of them associated with chronic endometritis and 32% with adenomyosis.

In patients with infertility and AUB, the prevalence of abnormal findings increases up to 80% (p<0.00001), and the distribution of the abnormalities was also different: endometrial polyps (30%), submucous myomas (9%), malformations (3%), adhesions (5%), isthmocele (5%), RPOC (3%), thick/hypervascularized endometrium (6%), cervical stenosis (9%), endocervical polyps (5%), and subtle lesions (25%), 60% of them associated with chronic endometritis and 40% with adenomyosis.

Age, number of inseminate oocytes, fertilization rate and number of embryos transferred were comparable between patients with normal hysteroscopy and with subtle lesions. However, the latest group was associated with lower clinical pregnancy rate and implantation rate (NS), and higher miscarriage rate (p<0.05).

Conclusions

Our data demonstrate that the prevalence of abnormal findings exceeds expectations, particularly when AUB is a concomitant symptom. This high prevalence is largely attributed to subtle lesions, which additionally have a negative impact on ART outcomes. This study highlights the critical role of hysteroscopy in evaluating infertility and the need for a methodical, standardized, and comprehensive approach to identify and document abnormal findings in general and subtle lesions in particular. Larger studies are needed to evaluate the association of these lesions with pathological entities and their treatment modalities to improve the IVF outcomes.

Quality of life 6 months after uterine artery embolization versus hysterectomy for symptomatic adenomyosis, a prospective cohort study

Lisa Trommelen¹, Rozenn Vuilleumier¹, Marissa Harmsen¹, Wouter Hehenkamp¹, Annefleur De Bruijn¹
¹Amsterdam UMC, Gynecology, Amsterdam, The Netherlands

Background

Adenomyosis is a common condition among women of reproductive age. Symptoms such as abnormal uterine bleeding and dysmenorrhea can affect quality of life. When conservative treatments fail or cause undesirable side effects, hysterectomy has traditionally been the last resort. Uterine artery embolization (UAE) has been proven safe and effective for symptomatic uterine fibroids and has the potential to be a less-invasive uterus-preserving option in adenomyosis.

Methods

A 2-year prospective multicentre study has been conducted in 12 Dutch hospitals to compare the health-related quality of life (HRQoL) outcomes between UAE and hysterectomy for symptomatic, MRI-confirmed, adenomyosis. Pre-menopausal women, eligible for surgical treatment, without wish to conceive, were offered either UAE or hysterectomy. HRQOL scores were assessed at baseline, 6, 12, and 26 weeks using validated questionnaires: World Health Organization Quality-of-Life Scale (WHOQOL-100 and WHOQOL-Bref), EuroQOL 5 Dimension 3 levels (EQ-5D-3L), and the short-form-12 (SF-12). The analysis included intention-to-treat and per-protocol approaches. The sample size was determined based on non-inferiority of UAE compared to hysterectomy when delta HRQoL was ≤ 5 . Recovery was measured using the recovery index (RI-10), patient satisfaction was evaluated using Likert scales.

Results

101 patients were included, 50 received UAE, 51 hysterectomies. Hypermenorrhoea was the primary reason for treatment in the UAE group (65.2%), while dysmenorrhea was the primary indication for hysterectomy (63.3%), and patients receiving hysterectomy had a longer duration of symptoms compared to UAE. At baseline, mean HRQOL was similar across all domains in both groups. Hospital admission was longer after UAE than after hysterectomy (2.0 vs 1.4 days, $p < .001$). One major perioperative complication occurred (vaginal cuff dehiscence), no significant differences in minor perioperative complications. Survival curves showed a significantly faster return to activities (work, household, leisure activities) in favour of UAE. Six months after intervention the uncorrected mean WHOQOL-Bref scores (physical, psychological, social relations, environment domain), SF-12 (physical and mental) and EQ5D improved and were similar in both groups. WHOQOL-100 Pain-score was significantly better 6 months after hysterectomy than UAE (respectively 22.9 vs. 32.7; $p = .022$) and WHOQOL-100 Sexual Activity scored >6 points higher in the hysterectomy group than UAE, although not significant (64.2 vs 57.7, $p = 0.279$). Repeated measurement analysis corrected for predefined covariates, showed no significant longitudinal differences in the HRQOL scores nor in the recovery index. Finally, fewer UAE patients were moderately or higher satisfied than hysterectomy patients. (71.4% versus 95.2%, $p = .007$). Within these six months two patients received a hysterectomy after UAE.

Conclusions

Uterine artery embolization is non-inferior in terms of quality of life 6 months after intervention. It should be considered as a safe, less-invasive, alternative for hysterectomy in patients with symptomatic adenomyosis, without the wish to conceive. Long-term follow-up assessments of quality of life at one and two year and cost-effectiveness analysis will follow.

**ES32-0371 -
Best Selected Abstracts 1**

Association between endometriosis and congenital uterine malformations: a single centre retrospective study

Petya Tanovska¹, Nicolas Samartzis¹, Dimitrios Rafail Kalaitzopoulos¹, Maria Zografou Themeli¹, Laurin Burla¹, Markus Eberhard¹

¹*Cantonal Hospital of Schaffhausen, Gynecology and Obstetrics, Schaffhausen, Switzerland*

Background

Endometriosis is a common, benign, chronic gynaecological disorder affecting approximately 10 % of women in reproductive age. Congenital uterine malformations with a prevalence of about 7% are associated with recurrent miscarriages. The aim of our study was to investigate the co-existence and association of endometriosis and congenital uterine malformations and to describe the clinicopathological characteristics of these patients.

Methods

In a retrospective single-centre study which included women with surgically diagnosed endometriosis between January 2006 and July 2021, after reviewing the medical charts and the intraoperative videos we found those patients with the co-existence of uterine malformations based on hysteroscopy or magnetic and resonance imaging (MRI). We classified the endometriosis according to the ASRM and #ENZIAN classification and the Mullerian anomalies according to the ESHRE/ESGE consensus. In the case of infertility, the Endometriosis Fertility Index (EFI) Score was calculated.

Results

Of the 1566 women with endometriosis, 98 patients presented a uterine malformation (prevalence 6.3 %). The mean age of the included patients was 33.3±7.8 years. 59 patients (60.2%) had dysmenorrhea and 28 patients had dyspareunia (28.6%). Forty-three patients (43.9%) had a primary infertility and 10 patients (10.2%) a secondary infertility. The most common uterine anomalies were U1c (41 patients, 42%), U2a (19 patients, 19.4%), U3b (17 patients, 17.3%) and U3a (10 patients, 10.2%). 56 (57.1%) of the included patients had stage III-IV endometriosis. There was no significant difference in ASRM score between the different subgroups of uterine malformations. The mean EFI score for all women with primary and secondary infertility was 6.4 (standard deviation, SD 2.1). There was no significant difference between the most common subgroups of uterine malformations ($p=0.37$).

Conclusions

The prevalence of congenital uterine malformations in women with endometriosis seems to be similar to the general population. The most frequent uterine malformation in our collective was the arcuate uterus, which was proposed to be classified as U1c. The severity of endometriosis according to ASRM score, as well as EFI score did not differ significantly in the different subgroups of uterine malformations.

Reproductive outcome in unicornuate uterus (U4): correlation with 2D and 3D TVS ultrasound measurements

Sara Valeriani¹, Consuelo Russo¹, Giulia Monaco¹, Federica Iacobini¹, Daniele Farsetti¹, Caterina Exacoustos¹
¹University of Rome Tor Vergata, Department of Surgical Sciences- Gynecological Unit, Rome, Italy

Background

Unicornuate uterus is associated with a lower live-birth rate and a higher risk of miscarriage, preterm delivery and malpresentation at birth. On the other hand some women with unicornuate uterus had normal pregnancy and discovers only incidentally to have a unicornuate uterus. The aim of this study was to correlate 2D and 3D transvaginal sonographic (TVS) features and measurements of unicornuate uterus with the reproductive outcomes.

Methods

This is a single centre retrospective study including women with unicornuate uterus and reproductive desire. 2D and 3D TVS measurements obtained on the unicornuate uterus were correlated to reproductive history. Infertility and pregnancy outcome evaluated in live birth, early pregnancy loss (miscarriage, ectopic pregnancy, termination of pregnancy) and preterm delivery were correlated to the single uterine diameters and to the volumes. Presence of rudimentary-horn with or without functional endometrium, concomitant gynaecological abnormalities (endometriosis, adenomyosis, fibroids) were also recorded and correlated to pregnancy outcome.

Results

Of 74 patients diagnosed with unicornuate uterus in our unit, 60 had pregnancy desire and were included in this study. Mean maternal age was 36.6 years (± 7.1), average BMI was 23.5 (± 4.0). 40 had a unicornuate uterus with a rudimentary horn of these 8 with functional endometrium and 20 without. 24 patients were infertile, 16 had a live birth (6 preterm delivery) and 20 had an early pregnancy loss. The transverse diameter showed the highest significance between patients who had a live birth compared to infertile women (4.7 ± 1.4 vs 3.7 ± 0.6 cm, $p=0.0005$). No differences were observed in the different reproductive outcome regarding presence or absence of rudimentary-horn and for anterior-posterior diameter. The total uterine volume was significantly higher in patients who delivered compared to infertile women (6.9 ± 3.2 vs 4.6 ± 1.9 cm³, $p=0.0050$) and those who showed an early pregnancy loss (vs 4.7 ± 1.4 cm³, $p=0.0064$). These data were confirmed also by ROC curves analysis.

Conclusions

Unicornuate uterine *width* and *volume* could be a prognostic factor for delivery. Women with a unicornuate uterus should be evaluated by 3D TVS and measurements of the unicornuate uterus should be taken and could be useful for patient counselling.

Normalization of uterine peristalsis following laparoscopic niche resection

Saskia Klein Meuleman¹, Yizhou Huang², Massimo Mischì², Dick Schoot³, Emiel Post Uiterweer⁴, Judith Huirne¹

¹AmsterdamUMC - location VUmc, Gynaecology, Amsterdam, The Netherlands

²Eindhoven University of Technology, Electrical Engineering, Eindhoven, The Netherlands

³Catarina hospital, Gynaecology and Obstetrics, Eindhoven, The Netherlands

⁴AmsterdamUMC, Gynaecology, Amsterdam, The Netherlands

Background

A common complication following Caesarean Section is development of a uterine niche. A uterine niche is associated with lower pregnancy rates during assisted reproductive treatment (ART). We hypothesized that changes in uterine peristalsis could play an intermediary role. Our previous study showed less coordinated subendometrial peristalsis as well as increased contraction amplitude in women with a niche compared to women with normal uteri. The aim of this study is to evaluate if laparoscopic niche resection can improve subendometrial peristalsis in women with a large post-caesarean niche.

Methods

A prospective cohort study in a Dutch tertiary medical centre including women with a large niche scheduled for a laparoscopic niche resection. All consecutive women underwent a 5-minute transvaginal ultrasound recording during early luteal phase before surgery and three months post-surgery. Women using hormonal contraception were excluded. Subendometrial peristalsis was evaluated by strain analysis using dedicated two-dimensional optical flow speckle tracking method.

Results

Fourteen women with a large niche and successful laparoscopic niche resection were included. The mean volume of the niche changed from 1215.1 mm³ (SD ± 343.0) before surgery to 115.7 mm³ (SD ± 60.9) post-surgery. The mean residual myometrial thickness increased from 0.82 mm (SD ± 1.1) to 7.06 mm (SD ± 2.6). Three months following laparoscopic niche repair subendometrial peristalsis showed significant normalization of coordination ($p = 0.021$) as well as increased cervix to fundus propagation in the anterior wall ($p = 0.035$). A decrease in amplitude to normal values was observed. This was seen in combination with a decrease of power of the peristalsis in longitudinal direction, lower contraction frequency in radial direction and a higher contraction frequency in longitudinal direction.

Conclusions

Following laparoscopic niche resection, women with a large uterine niche show significant improvement in subendometrial peristalsis. These changes included normalization of the coordination, direction, amplitude and frequency. So, changes in subendometrial peristalsis may be a connecting link between large niches and poor outcome in ART. Laparoscopic niche resection can potentially restore normal subendometrial peristalsis thereby improving fertility.

Accuracy of hysterosalpingography in the diagnosis of T-shaped uterus compared to three-dimensional ultrasonography according to congenital uterine malformation by experts (CUME) criteria: a compatibility study

Ömer Erbil Doğan¹, Eyuphan Ozgozen¹, Asli Akdoner¹, Begum Ertan¹, Onur Yavuz¹, Mustafa Secil²

¹Dokuz Eylul University Faculty of Medicine, Obstetrics and Gynecology, Izmir, Turkey

²Dokuz Eylul University Faculty of Medicine, Radiology, Izmir, Turkey

Background

T shaped uterus is a rare uterine anomaly associated with poor reproductive outcomes. Recently, CUME defined objective criteria for diagnosing this anomaly with three-dimensional ultrasonography (3D-US) which is the gold standard method in diagnosing uterine pathologies. Hysterosalpingography (HSG) is the primary test in evaluating the uterine cavity and tubal patency in infertility. The aim of the study is to demonstrate the applicability of T-shaped uterus CUME criteria to HSG comparing it with 3D-US.

Methods

This prospective study included 402 infertile patients (18-45 years). Participants were recruited from a university hospital clinic. Patients with pathologies distorting the uterine cavity, uterine anomalies (except T-shaped uterus) or failure to create a suitable coronal view with 3D USG were excluded. During HSG, after calibrating the measurement with a coin placed during the procedure, the most representative image of the uterus was chosen to measure the defined CUME criteria, namely bilateral T and lateral indentation angles and bilateral lateral indentation depths. Uterine morphology and endometrial cavity were assessed with 3D volume acquisition obtaining the coronal view of the uterus. The same morphometric measurements were repeated with 3D US as well. All the measurements for the T shape diagnosis made by HSG were compared to the 3D US measurements for concordance. The study was approved by the Ethics Committee of the university.

Results

The study population consisted of 402 patients. However, either HSG or 3D USG images were not suitable for measurement in 9.7% (39/402) of the patients and 8.5% (34/402) of them were removed from the analysis because of having other uterine anomalies than T-shaped uterus. The final analysis was made with the remaining 329 (81.9%) patients in which 14 (4.2%) had borderline and 9 (2.7%) had T shaped anomaly diagnosed by 3D US. The sensitivity and specificity of HSG in diagnosing T shaped uteri were 88.8% (8/9) and 99.6% (319/320), respectively.

In the borderline plus T shape group, the sensitivity of HSG was 78.4% (18/23) and the specificity was 96.4% (295/306). HSG showed a high diagnostic accuracy for this anomaly with a Kappa index of 0.68: 95% CI (0.53-0.82, $p < 0.05$). Additionally, there was a high degree of agreement between HSG and 3D US for the CUME measurements (for T-angle $r = 0.85$, for lateral indentation angle $r = 0.83$ and for lateral indentation depth $r = 0.83$ $p < 0.05$).

Conclusions

The results of our study show that the CUME diagnostic criteria for T-shaped uterine anomaly defined to be used for 3D US can also be applied to HSG images. The 3 morphometric criteria measurements of CUME can be made by HSG with a high degree of agreements. We conclude that HSG and 3D US can be used interchangeably for diagnosing this rare uterine anomaly.

Results of dienogest observational study at the Cwm Taf Morgannwg University Health Board, United Kingdom

Irina Ramzan¹, Jonathan Rogers¹

¹*Cwm Taf Morgannwg University Health Board, Gynaecology, Merthyr, United Kingdom*

Background

ESHRE recommends prescription of progestogens to reduce endometriosis associated pain and postoperative hormonal treatment to improve the immediate outcome of surgery in women not desiring immediate fertility.² Dienogest is a norethisterone derivative, has a progesteric effect and suppresses endometriotic lesions.⁴ Studies demonstrated that 2mg of dienogest daily alleviates painful symptoms of endometriosis.⁵ We undertook prospective observational study to assess effects of dienogest. We used BSGE endometriosis and pelvic pain questionnaire when collecting data. BSGE symptoms questionnaire enquires about premenstrual, menstrual, and non-cyclical pain, back pain, deep dyspareunia, bowel and bladder symptoms, global quality of life.¹ 32 patients with confirmed and clinically suspected endometriosis were included in the study. 66% (21) patients had laparoscopy prior treatment with dienogest, confirming diagnosis of endometriosis. Patients' age varied between 17 and 46; BMI - in the range of 20 to 45. A follow up period was between 2 to 10 months.

Methods

Observational prospective study to review effects of dienogest in the treatment of patients with pelvic pain associated with endometriosis.

Results

70% (22) patients have reported improvement of their symptoms – pelvic pain, dysmenorrhoea and dyspareunia, and global quality of life. 27% (6) patients reported complete resolution of dysmenorrhoea, noncyclical pain and dyschezia. Out of 32 patients, 9 (28%) patients discontinued dienogest. Five (16%) of those patients did not notice improvement of their symptoms and the rest had side effects. Side effects reported were headache in one patient, mood changes in two patients, one patient had a history of bipolar disorder. One patient developed headache when taking dienogest, two patients – hot flushes, one patient reported increased hair loss, one patient complained of ongoing breast tenderness and one increased weight. Two patients discontinued treatment, even though their symptoms have improved, due to side effects – headache and ongoing bleeding.

Conclusions

Dienogest has shown to be effective and safe in the management of patient with endometriosis and can be offered as a first line long term treatment.⁵ 70% of patients in our study have improved on 2mg once daily dienogest and there have been minimal side effects. We are planning to follow up patient up to 24 months to assess long term effects.

References:

1. Pelvic pain questionnaire, BSGE. <https://www.bsge.org.uk/useful-resources-endometriosis-centres/>.
2. Endometriosis. Guideline of European Society of Human Reproduction and Embryology, 2022.
3. Impact of Long term Dienogest Therapy on Quality of Life in Asian Women with Endometriosis: The Prospective Non-Interventional Study. K. Techatrasak et al. Reproductive Sciences, 2022.
4. Dienogest. British national formulary. <https://bnf.nice.org.uk/drugs/dienogest/medicinal-forms/>.
5. Dienogest in long-term treatment of endometriosis. AE Schindler. Int J Womens Health, 2011.

Uterine artery embolization versus surgical treatment in patients with symptomatic uterine fibroids: systematic review and meta-analysis of individual participant data

Annika Semmler¹, Wouter J.K. Hehenkamp¹, Ben Willem J. Mol², Isaac Manyonda³, Michal Mara⁴, Wu Olivia⁵

¹Amsterdam University Medical Center - location Vumc, Obstetrics and Gynecology, Amsterdam, The Netherlands

²Monash University, Obstetrics and Gynecology, Clayton, Australia

³St George's Hospital- Blackshaw Road, Obstetrics and Gynecology, London, United Kingdom

⁴General Faculty Hospital and 1st Medical Faculty of Charles University, Obstetrics and Gynecology, Prague, Czech Republic

⁵University of Glasgow, Institute of Health and Wellbeing, Glasgow, United Kingdom

Background

Uterine artery embolization (UAE) offers a safe and effective alternative to hysterectomy or myomectomy for the treatment of symptomatic uterine fibroids. While it provides a minimally invasive treatment option, it is important to consider the trade-off of a notable risk of reintervention, estimated to be 15-32%. Individual participant data (IPD) meta-analysis not only offers more precise effect estimates but also has the ability to detect patient-level effect modifiers that could impact the clinical outcome. The aim of this study is to assess which patients undergoing UAE compared to surgical treatment have the highest improvement in clinical outcomes and the least chance of reintervention.

Methods

A systematic review and meta-analysis of IPD was performed from randomized controlled trials comparing surgical intervention (hysterectomy and myomectomy) to UAE in pre-menopausal women with symptomatic uterine fibroids. IPD were analysed according to the 'one-stage' approach, where a single model was created from the individual data, taking clustering into account. The primary outcome assessed whether certain patient-level characteristics may impact (1) a higher chance of surgical reintervention at two-year and (2) a higher quality of life at one-year follow-up, as measured by the EQ5D questionnaire, in patients undergoing UAE versus surgical treatment.

Results

IPD were available from five randomized controlled trials with a total of 766 women (360 assigned to the surgical group and 406 assigned to UAE). Preliminary results are as follows: Within two years 19% of patients had a reintervention in the UAE group. Of women assigned to undergo a myomectomy, 3% received a hysterectomy. Women undergoing a UAE had increased odds of having a reintervention when they had a higher pictorial blood assessment score (odds ratio (OR) 1.0006, 95%CI 1.0001 to 1.0011), a lower age (OR 0.94, 95%CI 0.89 to 0.99), and more severe bowel-related symptoms at baseline (OR 2.13, 95%CI 1.09 to 4.17). As compared to women undergoing a surgical treatment, women treated with a UAE had an overall lower quality of life at one year (-0.05, 95%CI -0.09 to -0.01). Larger fibroid diameters (-0.02, 95%CI -0.030 to -0.004) and anaemia (-0.11, 95%CI -0.21 to -0.02) at baseline had a negative impact on quality of life in the UAE group compared to surgery.

Conclusions

Women undergoing a UAE had a one in five chance of needing a reintervention. Preliminary results suggest that women were more likely to undergo a reintervention if they were younger, had severe menstrual blood loss, or severe bowel-related symptoms. Compared to surgery, women who had undergone a UAE had a lower quality of life at one-year follow-up, which was negatively impacted by a larger fibroid diameter and anaemia at baseline. With these patient-level effect modifiers, clinicians can provide more personalized treatment recommendations to patients.

**ES32-0391 -
Best Selected Abstracts 2**

What are the origin of uterine innervation?

Krystel Nyangoh Timoh¹, Fabien Robin², Ludivine Dion¹, Vincent Lavoue¹, Jean Leveque¹, Xavier Morandi³

¹CHU Rennes, Gynecology Obstetrics, Rennes, France

²CHU Rennes, digestive surgery, Rennes, France

³CHU Rennes, neurosurgery, Rennes, France

Background

To better understand the physiology of pain in pelvic pain pathologies such as endometriosis or adenomyosis, we carried out an anatomical and functional mapping of the macro-innervation of the human uterus. Our aim was to provide a three-dimensional reconstruction model of uterine innervation.

Methods

This was an experimental study. We dissected the pelvises of four human female fetuses treated with HES, and immunostained (classic immunohistochemistry complemented by immunofluorescence for co-staining). Main outcome measures: detection of nerves (anti-protein S100 antibodies) and characterize the different types of nerves. The slices obtained were scanned by a high-resolution optical scanner and aligned to construct a three-dimensional model.

Results

The inferior hypogastric plexus received the Hypogastric nerves and Pelvic splanchnic nerves. Nerve fibres were sympathetic, parasympathetic, sensitive. The point of entry for the nerve fibres in the uterus was laterally to the uterine isthmus and cervix and came directly from the IHP. Two paths were individualized according to its position from the ureter: - A principal medial path to the ureter. - A secondary antero-lateral path to the ureter. These paths create a real peri-ureteral loop.

Conclusions

We constructed a three-dimensional model of the human uterine innervation, based on a complete study in a physiological situation. This model could provide a solid base for studying uterine innervation and understand pain pathway.

Y-shaped uteri: which are the most important 3D ultrasound features to differentiate this dysmorphic cavity from septate and t-shaped morphology?

Giulia Monaco¹, Sara Valeriani¹, Federica Iacobini¹, Daniele Farsetti¹, Giorgia Soreca¹, Caterina Exacoustos¹
¹University of Rome 'Tor Vergata', Department of Surgical Sciences Obstetrics and Gynecological Clinic, Rome, Italy

Background

Y-shaped uterus could be described as a uterus characterized by a narrow uterine cavity due to thickened lateral walls and a fundal indentation of <50% of the uterine wall thickness at the midline level, with a correlation 2/3 uterine corpus and 1/3 cervix. The dysmorphic Y-shaped uterus doesn't represent yet an ill-defined entity and no ultrasound criteria or classifications have been proposed to diagnose it. The aim of the study is to identify the most significant 3D ultrasound differences between Y-shaped, Septate and T-shaped uteri to improve the accuracy of the diagnosis.

Methods

20 stored 3D transvaginal uterine volumes of women with a subjective diagnosis of Y- shaped uterus were evaluated offline. All the included uteri were considered Y-Shaped by four ultrasonographers. These uteri were compared to 40 Septate uteri (20 with a wide septum > 90° and 20 with an acute septum < 90°), 40 T-shaped uteri and 40 normal uteri. Uterine morphology assessment was performed on a coronal plane by measuring: fundal cavity width (Wf); corpus-isthmic level cavity width (Wi); lateral indentation angle (AI); lateral bulging (LB); septum angle (A); septum length (L); residual myometrium (M); length of the intracavitary line parallel to the interstitial line at 10 mm from it (R10); length of the intracavitary line parallel to the interstitial line at 20 mm from it (R20).

Results

Among the cohort, comparing the 20 Y-shaped uteri with the 20 septate uteri with a wide septum, significant differences are highlighted in R0, LB, AI, R10 and R20. No statistically significant differences, instead, were identified in the septum (A, L and M) measurements. This finding indicates that Y-shaped uteri have a narrower cavity and thicker lateral walls than septate uteri, but no differences on the septum measurements. Comparing instead the 20 Y-shaped with 40 T-shaped uteri, no significant differences emerged in the LB, R10 and R20, demonstrating that both have a narrow cavity. The only significant difference is in AI, which is statistically larger in the Y-shaped than in the T-shaped.

Conclusions

Y-shaped are dysmorphic uteri with characteristics in common with both T-shaped and septate uteri with a wide septum. The identification of 3D ultrasound criteria could help to diagnose this type of malformation in order to ensure the correct treatment.

The feasibility and acceptability of outpatient procedures using 15Fr mini-resectoscope

*Sabrina Reppuccia¹, Fabiola Nardelli¹, Virginia Foreste¹, Brunella Zizolfi¹, Maria Chiara De Angelis¹,
Alessandra Gallo¹*

¹University of Naples Federico II, Department of Public Health- School of Medicine, Naples, Italy

Background

To evaluate the feasibility and acceptability of outpatient procedures using a 15Fr mini-resectoscope. The feasibility of the procedure was evaluated by considering the success of the procedure and its duration, while the acceptability was assessed by the pain and discomfort complained by the patient during the procedure assessed by a Visual Analogic Scale (VAS).

Methods

Retrospective study conducted from April 2016 to May 2023 at the "Federico II" Hysteroscopy Unit in Naples recruiting patients undergoing outpatient hysteroscopy for the treatment of various endocavitary pathologies; a 15 Fr bipolar continuous-flow miniresectoscope with vaginoscopic approach was used, without cervical dilatation or analgesia or anaesthesia; uterine cavity distension was achieved with saline solution, keeping the mean intrauterine pressure constant at 30-40 mmHg with an electronically controlled pump with a flow rate of 200 ml/min, an irrigation pressure of 50-75 mmHg and a suction pressure of 0.25 bars.

Results

100 patients were enrolled, 25 with a diagnosis of endometrial polyp, 37 of myoma, 7 of retained product of conception (RPOC), 19 of uterine malformations and 12 with more than one uterine pathology. All procedures were conducted without anaesthesia in outpatient setting. Of the 25 polyps removed (mean polyp size was 22.6±10.3 mm), all the procedures had been successfully completed with a mean operating time of 4.6±1.3 min and mean VAS of 2.5±1.8. 34 out of 37 myomas (12 G0, 11 G1, 11 G2 according to FIGO classification system for uterine leiomyoma) were completely removed with a mean operating time of 5.9±1.4 min, and mean VAS of 3.1±0.8. The mean myoma size was 16.1±6.3 mm. 19/19 patients with uterine malformations (4 U2a, 2 U2b, 8 U1a and 5 U1c according to ESHRE/ESGE classification) underwent uterine metroplasty. In these patients the mean operating time was 4.1±1.3 min and the mean VAS was 2.6±0.7. 7/7 patients with RPOC were completely treated with mean operating time of 5.3±1.0 min and mean VAS of 2.7±0.5. Success of the procedure was obtained also for patients with more than one pathology: 4 patients with both polyp and myoma, 6 patients with both polyp and uterine malformation and for 2 patients with both myoma and uterine malformation. Only 7 out 100 procedures were interrupted (in 3 patients with myomectomy and in 4 patients with both myomectomy and polypectomy) and required a second hysteroscopic step: in these patients the mean myoma size was 16.7 ± 6.1 mm and the main limit was the patient's compliance (mean VAS 8.4 ± 1.5). In all procedures, no complications were observed.

Conclusions

Outpatient hysteroscopy using a 15Fr mini-resectoscope is an efficient and safe way to treat uterine pathologies. Advantages in term of efficiency and time saving procedures have been obtained.

Does history of surgery for endometriosis effect pregnancy outcome? A prospective study

M Abhigna¹, Sumana Manohar²

¹*Apollo women's hospital, Obstetrics and gynaecology, Nellore district, India*

²*Apollo women's hospital, Obstetrics and gynaecology, Chennai, India*

Background

Endometriosis is a chronic inflammatory condition, characterized by the presence of endometrial glands and stroma outside the uterine cavity, mostly in the pelvic compartment. The objective of this study was to assess the relationship between history of surgery for endometriosis and adverse obstetric outcomes.

Methods

The study was done in a tertiary care referral centre. Total of 1138 women with history of surgery for endometriosis included. Postoperative conception and pregnancy progression over 28 weeks with any risk factors was assessed. The study period was two years Jan 2020 till Jan 2022. Intervention in the study was surgery for endometriosis. The main outcome measured was small for gestational age status of newborn, spontaneous preterm birth and placenta previa.

Results

Out of 2534 patients who underwent surgery during the study period, 1466 pregnancies included in the study, 1132 deliveries were recorded (77.2%) of which 1070 were singleton (72.9% of pregnancies) and 62 twins(4.2%). Small for gestation was observed in 162 of 1070 (15.1%) singleton pregnancies and 18 of 62 (29%) twin pregnancies. Preterm birth occurred in 106 of 1132 (9.9%) singleton pregnancies and 38 of 62(61.2%) twin pregnancies. The number of singleton and multiple pregnancies complicated by placenta previa were respectively 18 of 1070 singleton (1.7%) and 0 of 62. The independent factor found to relate to small for gestation age was the absence of endometriomas; conception with use of assisted reproductive technique only tended towards statistical significance. Independent factors found to increase the risk of preterm birth were conception with the use of artificial reproductive technology (ART), body mass index >30kg/m², and surgery of deep endometriosis infiltrating the rectum and bladder. Independent factors associated with placenta previa were conception with ART and history of stage III or IV endometriosis.

Conclusions

The risk of small for gestation age and preterm is increased in women with a history of endometriosis surgery and higher rate of conception with the use of ART may jeopardize the outcomes.

Efficiency and safety of ovarian stimulation with letrozole and levonorgestrel-intrauterine system after combined fertility-sparing treatment of women with atypical endometrial lesions

Alessandra Gallo¹, Giuseppe Gabriele Iorio², Alessandro Conforti², Brunella Zizolfi¹, Maria Chiara De Angelis¹, Carlo Alviggi¹

¹University of Naples Federico II, Public Health, Naples, Italy

²University of Naples Federico II, Neuroscience- Reproductive Science and Odontostomatology, Naples, Italy

Background

The aim of this study was to demonstrate the safety and efficacy of ovarian stimulation (OS) with Levonorgestrel Intrauterine System (LNG-IUS) in situ and co-treatment with letrozole in patients undergoing fertility-sparing combined treatment for atypical endometrial hyperplasia (AEH) or endometrioid type, well-differentiated (G1) early endometrial cancer (EEC), limited to endometrium (International Federation of Gynecology and Obstetrics [FIGO] stage IA).

Methods

This retrospective case-control study analysed young women diagnosed with AEH or EEC who underwent fertility-sparing "combined" treatment and subsequent OS with letrozole and LNG-IUS in situ at Gynecology Unit of University of Naples Federico II, from January 2019 to December 2022. Patients were treated with "three-steps" hysteroscopic technique in case of focal development lesion, or with superficial endometrial resection, preserving the basal layer of the endometrium, in case of diffuse lesion. 52 mg LNG-IUS was inserted in all patients after surgery. Follow-up was performed every 3 months with endometrial biopsies by hysteroscopic "grasp" technique. After complete response was obtained, an OS was started, oocytes retrieval was performed, and mature oocytes were cryopreserved. After removal of LNG-IUS, embryo-transfer procedure (ET) was performed. Comparative analysis of outcomes of assisted reproductive technologies (ART) was performed considering two control groups, matched for age, ovarian reserve, and BMI: i) healthy infertile women undergoing OS for IVF/ICSI; ii) patients diagnosed with breast cancer who underwent OS with Letrozole.

Results

25 women were enrolled, 22 with diagnosis of AEH and 3 with diagnosis of EEC; 12/25 women underwent oocyte cryopreservation. No statistically significant differences were observed in oocyte and mature oocytes retrieved between the patients who underwent controlled OS with LNG-IUS in situ, and the control groups. Of the stimulated patients, 9/12 underwent ET. The clinical pregnancy rate was 55.6%, the cumulative live birth rate was 44.4%, the miscarriage rate was 20%. Three patients with AEH had recurrence (12%), occurring 3, 6 and 16 months after removal of LNG-IUS to attempt ET, respectively.

Conclusions

The combined treatment, with hysteroscopic resection and subsequent progestin therapy with 52 mg LNG-IUS, is confirmed as a safe and effective fertility-sparing approach. The use of ART procedures conducted with letrozole and in the presence of LNG-IUS can reduce the time to pregnancy of these women, and consequently reduce the likelihood of disease recurrence, and has no harmful effects on oocyte yield. This type of stimulation is also able to balance the potentially dangerous effect of hypoestrogenism on the endometrium of patients with AEH or EEC. Promising pregnancy outcomes can be expected.

**ES32-0606 -
Best Selected Abstracts 2**

The use of tissue removal device followed by LNG-IUS for fertility sparing treatment of atypical endometrial hyperplasia/endometrial intraepithelial neoplasia: oncologic outcomes

*Fedora Ambrosetti¹, Raffaella Del Papato², Maria Chiara De Angelis³, Roberto Bartoli³, Brunella Zizolfi³,
Alessandra Gallo³*

¹*University of Modena and Reggio Emilia,*

Department of Medical and Surgical Sciences for Mother- Child and Adult, Modena, Italy

²*University of Bari,*

Department of Biomedical Sciences and Human Oncology- Section of Gynecology and Obstetrics, Bari, Italy

³*University of Naples Federico II, Department of Public Health, Napoli, Italy*

Background

We aimed to demonstrate safety and effectiveness of the use of hysteroscopic tissue removal devices (TRD), followed by progestin therapy with Levonorgestrel-Intrauterine System (LNG-IUS) for fertility-sparing treatment of young patients with Atypical Endometrial Hyperplasia (AEH)/Endometrial Intraepithelial Neoplasia (EIN).

Methods

Young patients diagnosed with AEH/EIN, limited to the uterus, with no myometrial invasion and strongly desiring to preserve their fertility, were enrolled. They underwent "combined" fertility-sparing treatment, consisting of Visual D&C, followed by insertion of 52mg LNG-IUS. The endometrial resection by Visual D&C technique involved the use of hysteroscopic TRDs with an outer sheath from 5.25 mm to 6.15 mm, not requiring cervical dilatation and anaesthesia. In an office setting a complete resection was achieved, preserving the basal layer of the endometrium, thus allowing its complete regeneration after the end of the treatment and preserving the fertile potential of the woman. Not using electrosurgery reduces the risk of postoperative intrauterine adhesions, which may result in better reproductive outcomes. Follow-up was performed after 3, 6 and 12 months with hysteroscopic endometrial biopsies, to evaluate the response to treatment. Preliminary oncologic outcomes are presented. Complete Response (CR) was defined as absence of any pretreatment lesions; Partial Response (PR) as regression of pretreatment lesion grade; Stable Disease (SD) as persistence of pretreatment lesions; Progressive Disease (PD) as worsening of the baseline histologic grade. Relapse was defined as the presence of AEH/EIN after previous achievement of CR.

Results

22 women with AEH/EIN were enrolled, with mean age of 31.36 years old, ranging from 21 to 42 years. CR was achieved at 3-month follow-up in 86.3% (19/22), while 13.6% (3/22) showed SD. At 6-months follow-up, a CR of 81.8% (18/22) was achieved, with a relapse in one case (4.5%). At 12-months follow-up, CR was achieved in 86.4% of the patients (19/22); PR was obtained in 2 of the 3 patients that previously showed a SD. No patient showed PD during the follow-up period. These data are consistent with those found in Literature on oncologic outcomes of patients undergoing fertility-sparing "combined" treatment.

Conclusions

Visual D&C technique, using hysteroscopic TRDs, followed by intrauterine progestin therapy, was found to be a safe and effective approach for fertility-sparing "combined" management of AEH/EIN in outpatient setting. CR was effectively achieved in these patients as early as after 3 months of therapy, allowing optimal cytoreduction and facilitating the subsequent therapeutic effect of progestins. Efficacy was also stable at longer-term follow-up. Promising oncologic outcomes can be expected.

**ES32-0615 -
Best Selected Abstracts 2**

Endometriosis excision alone versus excision and hysterectomy, with and without bilateral oophorectomy: an analysis of 10 years of national registry data

Jonathan Lewin¹, Arvind Vashisht¹, Martin Hirsch², Ertan Saridogan¹

¹*University College London Hospital, Gynaecology, London, United Kingdom*

²*John Radcliffe Hospital, Gynaecology, Oxford, United Kingdom*

Background

The aim of this study was to compare symptom and quality-of-life (QoL) improvement after endometriosis surgery in 3 patient groups: patients undergoing excisional endometriosis surgery (EES) alone, EES with hysterectomy and ovarian conservation (Hyst-OC), and EES with hysterectomy and bilateral salpingo-oophorectomy (Hyst-BSO).

Methods

Following approval from the British Society for Gynaecological Endoscopy (BSGE) scientific advisory group we obtained a download of the BSGE endometriosis centres database from 2012 to 2021. Patients were excluded if they had previously had a hysterectomy or BSO. We compared symptoms (0-10 scale) and quality of life (EQVAS, 0-100 scale) scores between treatment groups using mixed-effects regression with a time-by-treatment interaction term and a random intercept for each patient and endometriosis centre, controlling for age, smoking, and BMI.

Results

We analysed data from 8442 operations for endometriosis, 1075 (12.7%) of which were Hyst-OC, and 650 (7.7%) were Hyst-BSO. Patients undergoing Hyst-OC had significantly greater reduction in non-cyclical pelvic pain from their pre-operative baseline at 6-months (1.11/10, 95%CI 0.85-1.37, p<.001), 12 months (1.16/10, 95%CI 0.87-1.45, p<.001) and 24 months post-op (1.41/10, 95%CI 1.04-1.78, p<.001) compared to patients undergoing EES alone. Similarly, patients undergoing Hyst-BSO had significantly greater improvement in non-cyclical pain scores than patients undergoing EES at 6-months (1.48/10, 95%CI 1.16-1.81, p<.001), 12 months (1.69/10, 95%CI 1.34-2.04, p<.001) and 24 months (2.22/10, 95%CI 1.81-2.63, p<.001). Patients undergoing Hyst-OC and Hyst-BSO also demonstrated significantly greater improvement in dyspareunia and lower back pain compared to patients undergoing EES, and differences between these groups increased with follow-up time.

Greater improvement in QoL was seen in Hyst-OC compared to EES, with higher EQVAS scores at 6 months (8.23/100, 95%CI 6.13-10.34, p<.001), 12 months (8.24/100, 95%CI 5.91-10.57, p<.001) and 24 months (8.71/100, 95%CI 5.75-11.68, p<.001). Patients undergoing Hyst-BSO also had greater improvement in QoL compared to EES at 6 months (10.31/100, 95%CI 7.74-12.88, p<.001), 12 months (12.06/100, 95%CI 9.27-14.85, p<.001) and 24 months (12.18/100, 95%CI 8.88-15.48, p<.001).

In sub-group analysis comparing Hyst-OC with Hyst-BSO, patients undergoing Hyst-BSO had significantly greater improvement in non-cyclical pelvic pain at 6 months (0.42/10, 95%CI 0.05-0.80, p=0.028), 12 months (0.54/10, 95%CI 0.13-0.95, p=0.010) and 24 months post-op (0.86/10, 95%CI 0.36-1.36, p<.001). Hyst-BSO patients showed significantly greater improvement in QoL than Hyst-OC patients at 12 months (3.77/100, 95%CI 0.51-7.03, p=0.023), but not at other time-points.

Conclusions

Patients undergoing EES with hysterectomy achieved superior postoperative symptom control and quality of life than those undergoing EES alone. Surgical menopause was associated with an additional improvement in symptoms and quality of life. This must be balanced against the limitations of this analysis and operative risk.

**ES32-0638 -
Best Selected Abstracts 2**

Prediction of vesicouterine adhesions by transvaginal sonographic sliding sign technique: a validation study

Naomi Min¹, Renée Visser¹, Nicole Burger¹, Jasmijn Rake², Judith Huirne¹, Robert De Leeuw¹
¹Amsterdam University Medical Center- location Vrije Universiteit Amsterdam, Obstetrics & Gynaecology, Amsterdam, The Netherlands
²Amsterdam University Medical Center- location Amsterdam Medical Center, Obstetrics & Gynaecology, Amsterdam, The Netherlands

Background

Adhesions between the uterus, bladder, and anterior abdominal wall are associated with various complications, including chronic pelvic pain, infertility and dyspareunia. The transvaginal sonographic (TVS) sliding bladder sign could be a less invasive diagnostic tool to evaluate the presence of these adhesions. This study aims to determine the predictive value, intra- and interobserver variation of the TVS sliding bladder sign for vesicouterine adhesions.

Methods

A prospective observational double-blind cohort study was conducted in the Amsterdam UMC. Patients who underwent laparoscopic gynaecological surgery for a benign disorder between January 2020 and December 2022 were included in whom a prior routine TVS examination was performed including sliding sign video recordings. Patients with a history of previous uterine surgery and/or pelvic infection were considered high-risk patients. All recorded ultrasound examinations were assessed for the presence of the sliding bladder sign by two experienced gynaecologists and one less experienced resident in gynaecology and obstetrics. Adhesions between uterus and bladder, abdominal fascia and omentum were scored based on laparoscopic video clips and divided into three groups: no adhesions, mild adhesions, and severe adhesions also referred to as 'frozen bladder'.

Results

During the study period, recorded preoperative TVS sliding bladder sign and laparoscopic data were available for 116 women: 87 women were included in the high-risk subgroup. Based on laparoscopy 79/116 (68%) women had adhesions and 28/79 (35%) of these women had severe adhesions. The sliding bladder sign had a sensitivity of 91.9% with a negative predictive value (NPV) of 94.7% in predicting vesicouterine adhesions. In the high-risk subgroup, the sensitivity and NPV were 91.7% and 98.1%, respectively. The specificity of the sliding bladder sign in predicting severe adhesions was 89.3% with a positive predictive value (PPV) of 94.9%. Specificity was 88.9% for predicting severe adhesions in the high-risk subgroup. The inter- and intraobserver correlation between experienced gynaecologists, using Cohen's kappa coefficient, were 0.78 and 0.69, respectively. The correlation between the experienced gynaecologist and the resident was slightly lower, i.e. 0.67.

Conclusions

The TVS sliding bladder sign technique is a reliable and less invasive diagnostic tool for predicting vesicouterine adhesions, especially in high-risk patients. Patient is most likely to have vesicouterine adhesions in case of a negative sliding bladder sign during TVS examination. A positive sliding bladder sign rules out the presence of a 'frozen bladder', which can be useful in planning and clinical decision-making in patients undergoing abdominopelvic surgery.

BEST SELECTED ABSTRACTS VIDEO

ES32-0122 - Best Selected Videos 1

Unification and orificing of two functional non-communicating uterine horns through the created neovagina using peritoneum

Gurkan Uncu¹, Kiper Aslan¹, Isil Kasapoglu¹

¹Uludağ University Hospital, Obstetrics and Gynecology, Bursa, Turkey

Background

The incidence of Mullerian abnormalities is extremely rare. There is no exact surgical method to make the anatomy functional. The present case demonstrates the surgical approach for Mullerian agenesis with bilateral uterine remnant with functional endometrium.

Methods

An 18-year-old adolescent was admitted to a tertiary university hospital with primary amenorrhea and cyclic pelvic pain complaints. The physical examination and MRI scans suggested a complex Mullerian abnormality. The patient had uterine remnants with bilateral functional endometrium and cervicovaginal agenesis. An operation was planned to reconstruct her anatomy by providing a neovagina and anastomosis of uterine remnants. GnRH analogues were prescribed to suppress her menstruation until the process. The operation was performed in the third month of the first diagnosis. She underwent a laparoscopy. There were approximately 5x6 cm bilateral uterine horns with healthy adnexa.

As the first step, neovagina was created using a modified peritoneal pull-down technique, a standard approach in that clinic. A vaginal incision was applied, and a blind vaginal dissection was performed to reach the peritoneum vaginally. Then, an acrylic vaginal mold was inserted. The vaginal orifice was laparoscopically incised by ultrasonic energy with the guidance of inserted vaginal acrylic mold. The orifice was gradually dilated with larger molds. The whole pelvic peritoneum was circularly dissected, and the distal part of the dissected peritoneum was pulled down with four 2.0 vicryl sutures at 0, 90, 180, and 270 degrees of opened vaginal orifice. The uterine cavities of bilateral remnants were incised, and two separate Foley catheters were replaced in both cavities. A mold with a hole was used to insert the catheters through the vagina. Both catheters were fixated in cavities with prolene sutures pulled up from the anterior abdominal wall.

The next step was uterine anastomosis. The uterine remnants were unified by continued saturation. Therefore, a normally shaped uterus was consisted of. As the last step, the created uterus and neovagina were anastomosed. The patient was educated about how to apply mold exercises and follow-ups.

Results

The postoperative 1-month MRI scan showed the healed unified uterine cavities and vagina. She had spontaneous menstruation in the second month after surgery. Now she has regular menses with approximately 9-10 cm functional vagina.

Conclusions

Mullerian abnormalities are extremely uncommon, and their broad spectrum makes it challenging to identify an exact surgical method to restore functional anatomy. Therefore, a customized surgical approach should be designed for each patient based on their unique condition.

<https://player.vimeo.com/video/826361496?autoplay=1>

**ES32-0170 -
Best Selected Videos 1**

Pelvic sentinel lymphnode staging for endometrial cancer: a multi-modal infrared signal technology

Federica Perelli¹, Emanuele Arturo Fera¹, Marco Giusti¹, Alberto Mattei¹, Giuseppe Vizzielli², Giovanni Scambia³

¹Santa Maria Annunziata Hospital, Maternal and Child Department, Florence, Italy

²"Santa Maria Della Misericordia" University Hospital, Department of Medical Area DAME, Udine, Italy

*³Fondazione Policlinico Universitario A. Gemelli- IRCCS,
Dipartimento per la salute della Donna e del Bambino e della Salute Pubblica, Roma, Italy*

Background

This video shows a pelvic sentinel lymphnode (SLN) staging for endometrial cancer (EC) performed with a multi-modal infrared signal technology.

SLN staging was developed as a trade-off between systematic and no lymphadenectomy to limit morbidity while conserving good oncological outcomes.

Methods

To perform the identification and removal of SLN in EC we should follow the SLN algorithm, starting with the retroperitoneal evaluation. In case of bulky nodes, it is necessary to remove them independently from mapping. If there is no mapping on a hemi-pelvic, a side-specific lymphadenectomy must be performed.

In our Institution we perform a cervical injection at 3 o'clock and 9 o'clock with 1 ml deeply in the cervix, parallel to the cervical channel and 1 ml superficially.

SLN most common location is the external iliac area or the obturator area, a less common location is the common iliac area, and a much less common location is the aortic area.

Results

This video shows the identification and the removal of a SLN in the external iliac area by the indocyanine green system. The Fluorescence imaging mode can be changed to help the identification of the SLN. Available modes are the following:

- 1) the overlay image combines the white light image and the detected near infrared signal. The near infrared signal is displayed in green together with the white light signal.
- 2) the monochromatic visualization displays the near infrared signal in greyscale without white light signal.
- 3) the intensity map combines the white light image and the detected near infrared signal. The infrared signal information is displayed in a colour scale to differentiate between strong and weak infrared signals. The yellowish display represents stronger signals, the blue display weaker signals.

Conclusions

SLN dissection can be greatly facilitated by multimodal technology for indocyanine green-enhancing sentinel node detection.

<https://player.vimeo.com/video/826673667?autoplay=1>

**ES32-0287 -
Best Selected Videos 1**

The visual effect of a down-regulation with Dienogest and GnRH-analogues: a retrospective cohort study

*Dimitrios Kalaitzopoulos¹, Laurin Burla¹, Filip Farkas¹, Markus Eberhard¹, Nicolas Samartzis¹
¹Cantonal Hospital Schaffhausen, Gynecology and Obstetrics, Schaffhausen, Switzerland*

Background

Endometriosis is a hormone-dependent and, in its active form, a highly inflammatory disease. Various endocrine therapeutics are used for treatment, for postoperative recurrence prophylaxis, but also for preoperative downregulation. The aim of our study was to evaluate the intraoperative visual effect of treatment with GnRH analogues and dienogest.

Methods

A total of 193 patients with histological proven endometriosis, who underwent two step surgical procedure from 2007 to 2021 were included. We excluded patient who had prior hormonal treatment in the last 6 months. Data and intraoperative videos were reviewed by two independent reviewers at one referral centre. The study was approved by the local ethics committee.

Results

We found 193 patients for our study. 77 received GnRH-analogues and 116 Dienogest for preoperative hormone down-regulation. The median duration of down-regulation with GnRH-analogues or Dienogest was 3 months. The mean age was 32.3 (SD 6.3) years for GnRH-analogues and 32.6 (SD 6.3) years for Dienogest, $p=0.619$ respectively. The visible intraoperative effect will be demonstrated in the video.

Conclusions

The effect of a hormonal downregulation can be observed intraoperatively in endometriosis. This can help to assess the in vivo response to the administrated treatment.

<https://player.vimeo.com/video/826723424?autoplay=1>

**ES32-0068 -
Best Selected Videos 1**

Robot-assisted nerve plane-sparing modified radical hysterectomy for deep endometriosis with FireFly® Technology

Kiyoshi Kanno¹, Shiori Yanai¹, Masaaki Andou¹
¹*Kurashiki Medical Center, Gynecology, Kurashiki, Japan*

Background

Nerve-sparing modified radical hysterectomy (NS-mRH) is known for its benefits as a definitive treatment for severe endometriosis. In addition, considering the high complication rate of deep endometriosis (DE) surgery and difficulty of identifying DE lesion, the use of indocyanine green(ICG), as a support to surgery for endometriosis, has been spreading over the last few years. Recently, we reported the new combined nerve-sparing technique using FireFly technology for the first time, therefore, the objective of this video is to show tips and tricks for this technique and provide perioperative outcomes of the procedure.

Methods

Our NS-mRH was performed using following 8 steps with da Vinci Xi: Step 0, observing peritoneal endometriotic lesions; Step 1, adhesiolysis and adnexal surgery; Step 2, separation of the pelvic autonomic nerve plane (no-touch dissection); Step 3, dissection of the ureter; Step 4, reopening of the pouch of Douglas; Step 5, complete removal of DE lesions while avoiding injury to the nerve plane; Step 6, hysterectomy; Step 7, checking for rectal injury using air leakage test and tissue perfusion; and Step 8, barrier agents for adhesion prevention. Autonomic nerves pass through the avascular layer between mesorectum and lateral pelvic wall. Therefore, if we carefully dissect the layer both above and below of the hypogastric nerve, autonomic nerves are separated as a "nerve plane". A recent article about pelvic nerve dissection suggested to apply a "no-touch dissection" on the nerves, exerting no mechanical force with the instruments that could damage the nerve fibres. Nerve plane-sparing is one of the no-touch dissection technique. Although ICG is not a nerve-specific agent and it loses specificity in highly vascular area, pelvic autonomic nerves were strongly highlighted by ICG during early phase of ICG injection, indicating that these nerves are surrounded by many capillaries. Near-infrared fluorescence-ICG(NIR-ICG) imaging is one of the tool for improving decision making process in DE surgery.

Results

50 patients underwent this procedure. 22% of patients had history of previous surgeries for endometriosis. 50% of the patients presented with complete cul-de-sac obliteration and 96% of the patients presented with Enzian B2 or B3 lesions which were predictive factors for postoperative voiding dysfunction. All procedures included NS-mRH, uterosacral ligament resection and posterior compartment peritonectomy. Mean operative time was 129 min and blood loss was 35 ml. DE was histologically confirmed in all patients. We resected DE lesions from 229 sites visualized in white light and NIR-ICG imaging. Endometriosis or fibrosis was confirmed pathologically from 228 sites (99.6%). No patients developed perioperative complications, including postoperative bladder, rectal and sexual dysfunctions.

Conclusions

Our novel nerve plane-sparing modified radical hysterectomy using FireFly technology is safe and feasible with excellent surgical outcomes. Application of NIR-ICG imaging appears potentially useful, not only to remove DE, but also to improve nerve-sparing.

<https://player.vimeo.com/video/822277401?autoplay=1>

**ES32-0202 -
Best Selected Videos 1**

Intraoperative ultrasound evaluation for safety surgical management of bowel endometriosis

Shiori Yanai¹, Masaaki Andou¹, Kiyoshi Kanno¹

¹Kurashiki Medical Center, Gynecology, Kurashiki, Japan

Background

For management of rectal endometriosis, segmental resection, disc excision, and shaving have been proposed. Some algorithms are recommended for selecting the type of surgical management, depending on the size of the lesion and the patient's symptoms. Preoperative imaging evaluation by MRI and ultrasound have shown relatively high sensitivity and specificity. However, the actual depth and width of the rectal endometriosis cannot be assumed exactly during surgery. We aimed to evaluate rectal lesions accurately using intraoperative ultrasound for proper surgical management.

Methods

Ultrasound probe was inserted from the 12 mm trocar or posterior vaginal fornix incision to assess rectal lesions. The extent of lesion resection was determined under ultrasound guidance. MRI, intraoperative ultrasound, and pathological image of 8 patients with presumed rectal lesions was investigated.

Results

Segmental resection, disc excision, and shaving were performed in 1, 5, and 2 patients, respectively, and the procedure was performed as planned before surgery. Preoperative MRI showed rectal muscle invasion in six patients, and intraoperative ultrasonography and pathology confirmed lesions at or deeper than the muscle layer of the rectum. Two patients in whom MRI did not show rectal muscle lesions did not show muscle invasion on intraoperative ultrasound, and shaving was performed. There was no complication associated with surgery.

Conclusions

Intraoperative ultrasound reflects the actual range of rectal lesions well, so it is considered a simple and useful method for determining the actual resection line and confirming safety.

<https://player.vimeo.com/video/857809073?autoplay=1>

**ES32-0329 -
Best Selected Videos 1**

Robot assisted exploration of the Alcock canal: a novel surgical technique

Kateryna Kolesnikova¹, Khashayar Shakiba¹

¹*Women's Pelvic Surgery of North Jersey, Gynecology, Hackensack- NJ, USA*

Background

This video abstract presented the stepwise surgical technique of a robot-assisted exposure of the Alcock canal and decompression of the pudendal nerve, while providing a thorough review of the pertinent anatomy.

Methods

This was a video presentation of a step-by-step surgical technique. During the procedure, the patient was positioned in lithotomy position and 3 robotic ports were used in the following locations: umbilical, right and left upper quadrant. The robotic system was docked in the usual right-sided fashion.

Results

The video abstract demonstrated the step-by-step surgical technique of robot-assisted exploration and exposure of the pudendal nerve inside the Alcock canal. This exposure allowed full decompression of the nerve from its entry into the lesser sciatic foramen to the distal portion entering the deep perineal pouch. There was minimal estimated blood loss with no intra-operative complications.

Conclusions

This video abstract exhibits a safe and effective approach to a full pudendal nerve decompression with favourable patient outcomes. Unlike existing surgical technique, this procedure provides a comprehensive view of anatomy and an opportunity for improved decompression of the pudendal nerve and vessels. Additional research is necessary to validate its efficacy, verify long-term outcomes, and establish its position in the management of pudendal neuralgia and associated conditions.

<https://player.vimeo.com/video/827015801?autoplay=1>

**ES32-0175 -
Best Selected Videos 1**

Deferred surgical laparoscopic management of placenta percreta

Stas Shabanov¹, Eddy Christine¹, Dubuisson Jean¹

¹Geneva University Hospitals, Department of Paediatrics- Gynaecology and Obstetrics, Geneva, Switzerland

Background

The incidence of placenta percreta has been increasing in recent years, and it remains a significant challenge for obstetricians and gynaecologists worldwide. Treatment usually involves a combination of surgical techniques to remove the placenta while minimizing bleeding and preserving the uterus as much as possible. In severe cases, a hysterectomy may be necessary.

Methods

Stepwise video explanation of the technique.

Results

Uterine artery embolization with the addition of intraoperative positioning of vascular clips as preventive measure to minimize blood loss during deferred surgical laparoscopic management.

Conclusions

Deferred management of placenta percreta can be safely and effectively performed with a laparoscopic approach.

<https://player.vimeo.com/video/826685624?autoplay=1>

**ES32-0241 -
Best Selected Videos 1**

Laparoscopy guided hysteroscopic metroplasty and vaginal septum resection

Dimitrios Balafoutas¹, Andreas Grieger¹, Nikolaos Vlahos², Ralf Joukhadar¹

¹Spital Männedorf, Obstetrics & Gynecology, Zürich, Switzerland

²University of Athens, Obstetrics & Gynecology, Athens, Greece

Background

We demonstrate a hysteroscopic metroplasty under laparoscopic guidance for the treatment of a near-complete uterine septum and the resection of a complete vaginal septum in a case with cervical duplicity.

Methods

A 31-year-old patient with dyspareunia and history of missed Abortion presented with suspected genital malformation. The malformation was confirmed clinically, sonographically and with a preoperative MRI. The vaginal septum was completely resected with a monopolar knife. For the confirmation of the diagnosis and the exact definition of the anatomical relationships, the "Campo Trophyscope" was utilized. Simultaneously diagnostic laparoscopy facilitated the exact localization of the intracavitary instruments and helped estimate the uterine wall thickness. The uterine septum was completely resected with a bipolar resectoscope under laparoscopic guidance.

Results

A complete resection of both the vaginal and the uterine septum was achieved. Recovery was uneventful.

Conclusions

This rare video, showing simultaneous footage of multiple endoscopic cameras, demonstrates the exact technique of restoration of the above complex genital malformations and highlights the value of laparoscopy to safeguard the application of the resectoscope in challenging cases.

<https://player.vimeo.com/video/826885312?autoplay=1>

**ES32-0291 -
Best Selected Videos 1**

Neovagina and cervico-vaginal anastomosis surgery in a case of complex genital malformation

*Marta Hinarejos Companyó¹, Antoni Pessarrodona Isern¹, Jordi Cassadó Garriga¹, Ana Paula Vélez Vintimilla¹,
Jordi Rodríguez González¹, Oriol Porta Roda¹*

¹Hospital Universitari Mútua de Terrassa, Gynecology and Obstetrics, Terrassa, Spain

Background

We present you a case of a thirteen-year-old patient who consulted for cyclic abdominal pain in correlation with a cervico-hematometra, diagnosed of cervico-vaginal agenesis.

Multiple techniques have been described both to create the neovagina and to perform the uterovaginal anastomosis, most of them in two surgical times. We plan to design a technique combining known surgical resources with 3D impression reconstruction methods to create an anatomical vaginal mold specific to this patient.

The aim of this video is to present the surgical approach of neovagina and cervico-vaginal anastomosis in a 13-year-old patient with cervico-vaginal agenesis.

Methods

Using digital 3D anatomical reconstruction and 3D impression, we created a silicon vaginal mold specifically designed for this patient, with minimally invasive surgical strategy to accomplish anatomical collocation in a complex genital malformation. We proved the adaptability of the system using animal tissue.

Using ultrasound control and laparoscopic supervision, we placed a silicon covered with cadaveric decellularized skin in a simple way. Medical silicon grade IV allowed us to maintain the mold for weeks, until we accomplished a cellular invasion of the cadaveric skin.

The patient didn't have any postoperative pain. We performed a magnetic resonance after surgery, showing a proper anatomic correction.

Three weeks after the surgery, we changed the prothesis under sedation. Two months later, we withdraw completely the prothesis and we performed a hysteroscopy, showing an endocervical orifice with a single ostium. From this moment, the patient has had normal cyclic periods without pain and uses vaginal dilators thirty minutes every day to ensure vaginal patency.

Results

We can use innovative techniques combining known surgical resources with three-dimensional impression reconstruction methods to create an anatomical vaginal mold specific to our patient. We performed a successful less-invasive surgical approach to create a neovagina and cervico-vaginal anastomosis in a 13-year-old patient with a complex genital malformation.

Conclusions

We expect that this technique can help in the future other women with complex genital malformations.

<https://player.vimeo.com/video/826969720?autoplay=1>

**ES32-0380 -
Best Selected Videos 1**

Excision of endometriosis: conservative management of deep infiltrative rectovaginal endometriosis

Michelle Bennett¹, Jessie Jones¹, Laura Haworth¹, Joseph Hudgens¹

¹Eastern Virginia Medical School, Obstetrics and Gynecology Division of Advanced Gynecologic Surgery, Norfolk, USA

Background

Endometriosis is a common gynaecologic chronic pelvic pain condition. It predominately occurs in women of reproductive age with a prevalence of 5-10%. Of reproductive age women the majority of women present with infertility or chronic pelvic pain. Rectovaginal Endometriosis affects between 3.8%-37% of women with endometriosis.

Methods

This is a case of a 36yo nulliparous female with rectovaginal endometriosis noted on ultrasound. She desired a fertility sparing excisional procedure with conservative bowel measures. This video is a quick overview of medial and lateral pararectal dissection with nerve sparing to gain access to the rectovaginal nodule. Once the nodule is mobilized then the video reviews methods for bowel shaving and techniques for dissection to decrease risk of enterotomy.

Results

Rectovaginal endometriosis can be safely excised with conservative measures.

Conclusions

In conclusion, there are some key strategies to assist with conservative management of bowel endometriosis. The use of traction and counter-traction are important to assist with delineation between bowel and endometriotic nodule. Also, the designation between the fat and non-fat interface of the bowel and the nodule assists with a safe dissection. Overall, the risk of leaving residual disease must be balanced against the risk of enterotomy when deciding how to excise rectovaginal endometriosis disease.

<https://player.vimeo.com/video/826779227?autoplay=1>

**ES32-0352 -
Best Selected Videos 1**

Video-endoscopic inguinal sentinel lymph node biopsy with indocyanine green in vulvar cancer

Angelica Naldini¹, Nicolò Bizzarri¹, Filippo Maria Capomacchia², Aniello Foresta², Anna Fagotti¹, Giovanni Scambia¹

¹Fondazione Policlinico Universitario A. Gemelli- IRCCS, Department of Woman- Child and Public Health, Rome, Italy

²Catholic University of the Sacred Heart, Department of Woman- Child and Public Health, Roma, Italy

Background

The standard surgical treatment of vulvar carcinoma < 4 cm in size without clinical or radiological suspicion of lymph node metastases consists of resection of the vulvar tumor with negative margins with mono- or bilateral sentinel lymph node biopsy performed by inguinal incision. The inguinal approach to inguinal lymph node staging is associated with a high rate of post-operative complications such as wound dehiscence, lymphocele, lymphedema, infections, and psychosexual impairment.

Methods

In this video, we present the case of an 83 years-old patient with 2 cm central anterior vulvar squamous carcinoma and in which inguinal sentinel lymph node biopsy was performed with an innovative video-endoscopic approach using indocyanine green. The surgery was carried out in an Italian Comprehensive Cancer Center.

Results

The vulvar–vaginal examination under general anaesthesia reported a central anterior vulvar lesion of 2 cm. 2.5mg of indocyanine green was injected all around the tumor mass. After placement of a 15mm main trocar distal to the apex of the femoral triangle and two accessory trocars, the procedure began developing the anterior working space. Then, we performed a blunt dissection developed up to the inguinal ligament. The lymphatic tissue was identified from the fascia lata with a combination of blunt and sharp dissection up to the fossa ovalis. Sentinel lymph node was visualized with fluorescence near-infrared detection and then resected.

Conclusions

We believe that this approach to inguinal sentinel lymph node identification and excision may be associated with a reduction in incision-related postoperative complications without compromising the ability to effectively identify any lymph node metastases that impact post-operative management and patient prognosis. Prospective randomized clinical trials are needed to clarify whether this type of procedure will replace the inguinal approach to inguinal sentinel lymph node biopsy as the standard technique in the surgical treatment of vulvar carcinoma.

<https://player.vimeo.com/video/827031749?autoplay=1>

**ES32-0663 -
Best Selected Videos 2**

Laparoscopic removal of large gossypiboma developed after caesarean section

Islam Magalov¹, Nergiz Nagiyeva², Elnara Mastiyeva², Gunel Mereyeva², Zulya Abbasova²
¹Baku Branch of Sechenov Medical University, Obstetrics and Gynecology, Baku, Azerbaijan
²Baku Health Center, Obstetrics and Gynecology, Baku, Azerbaijan

Background

Gossypibomas are retained surgical sponge left accidentally during an intervention. This complication is quite rare medical event (Lovrec, 2018). Sometimes it could cause a serious complication such as obstruction, peritonitis, adhesions, fistula, abscess formations, erosion into the gastrointestinal tract that can threaten patients' life but usually there are no symptoms (Steelman, 2017; Lovrec, 2018). Due to the latter and inconclusive imaging findings, the diagnosis often comes as a surprise many years after the initial surgery (Rehman, 2014; Alemu, 2020). According to the literature, most of the forgotten of intra-abdominal textile items are removed laparotomically explained by the fact of size, difficult approach, and dense adhesions around them (Khanduri, 2022).

Methods

In the video we present a case of laparoscopic removal of large gossypiboma left in the pelvis after the caesarean section. It was found in ultrasound followed by MRI and described as an ovarian solid papillar mass of 9.7x8.6x7.7sm adherent to the anterior wall of the uterus. Clinically 33 years old patient complained of low abdominal pain. She was performed caesarean section 8 years before.

Results

The whole surgery took 142.50 min and could be divided in the following stages: 1) primary adhesiolysis and exposition – separation of omentum from the abdominal wall and uterus and left adnexa, creation of appropriate approach – 32.11 min, 2) mobilization of the mass from all sides – starting from the left and right lateral spaces with dissection of the right ligamentum rotundum, opening of the retzius space and separation from the bladder, uterus and vagina – 62.05 min 3) insertion of the evacuation bag, placement of the mass in it and removal from the abdominal cavity -36.10 min, 4) haemostasis control, suturing of bleeding areas on uterus and resuturing of the right round ligament – 12.24 min. Total blood loss was less than 50 ml.

Conclusions

Although different 'checklist' are applied mistakes will continue to be committed since it depend on human factor. Once the foreign body is diagnosed its removal should be planned even in asymptomatic cases for the future risk in the adjoining structures leading to organ damage and fistula formation. Removal of the retained sponge even in case of severe adhesion can be successfully performed by laparoscopic route.

<https://player.vimeo.com/video/835972732?autoplay=1>

**ES32-0471 -
Best Selected Videos 2**

Robotic assisted en-bloc removal of kidney, ureter and bladder wall and wedge resection of a full thickness sigmoid endometriotic nodule

Averyl Bachi¹, Shaheen Khazal², Rajesh Nair³, Pasha Nisar⁴, Michael Adamczyk⁵

¹St. Peter's Hospital, Centre for Endometriosis and Minimally Invasive Gynaecology, Chertsey, United Kingdom

*²The Lister Hospital- part of HCA Healthcare,
Centre for Endometriosis and Minimally Invasive Gynaecology CEMIG London, London, United Kingdom*

³Guy's and St. Thomas' NHS Foundation Trust, Urology Centre, London, United Kingdom

⁴St. Peter's Hospital, Department of Colorectal Surgery, Chertsey, United Kingdom

⁵St. Peter's Hospital, Centre for Endometriosis and Minimally Invasive Gynaecology CEMIG, Chertsey, United Kingdom

Background

Ureteral endometriosis is a rare entity of endometriosis, affecting 0.1% of patients. In this video, we present a case of a 29-year-old lady with pelvic pain and cyclical rectal bleeding. Further investigation showed significant left hydronephrosis and almost complete loss of left kidney function (8% on MAG3). MRI revealed endometriosis involving the posterior bladder wall and distal left ureter, a large full-thickness sigmoid nodule and a large left endometrioma.

Methods

This patient underwent a robotic-assisted left nephroureterectomy, partial cystectomy (bladder), Robotic excision of pelvic endometriosis and sigmoid wedge resection. This procedure was performed jointly with the gynaecologist, urologist and colorectal surgeon. The specimen (left kidney, whole length of ureter and bladder wall around ureteric orifice) was removed en-bloc.

Results

Histology confirmed endometriosis involving the bladder muscularis propria and surrounding the intramural portion of the left ureter. The patient made a good recovery post-operatively and reported complete resolution of her pain symptoms at her follow up visit.

Conclusions

Ureteric endometriosis is an indolent and aggressive condition which can lead to silent kidney loss. It is essential that hydronephrosis and hydroureter is ruled out in cases with deep endometriosis.

<https://player.vimeo.com/video/831185041?autoplay=1>

**ES32-0454 -
Best Selected Videos 2**

Combined robotic transanal transection single-stapled technique (TTSS) in ultra-low rectal endometriosis involvement associated with parametrial and vagina infiltration

Gianmarco D'Ancona¹, Benjamin Merlot², Quentin Denost³, Stefano Angioni¹, Thomas Dennis², Horace Roman²

¹Policlinico Universitario Monserrato - Cagliari,

Division of Gynecology and Obstetrics- Department of Surgical Sciences, Cagliari, Italy

²Clinique Tivoli-Ducos, Franco-European Multidisciplinary Endometriosis Institut IFEMEndo, Bordeaux, France

³Clinique Tivoli-Ducos, Bordeaux Colorectal Institute, Bordeaux, France

Background

The achievement of a perfect bowel anastomosis in patients with ultra-low rectal endometriosis could be challenging due to the limited angulation system of currently stapling devices together with the narrowness pelvic cavity. By allowing a right angle rectotomy with a single stapled anastomosis, the transanal transection single-stapled technique (TTSS) overcomes these technical difficulties ensuring a good quality anastomosis with an easier correction of postoperative anastomotic leakage when it occurs. In addition, the manual assessment of the distal transection margin could be associated with lower risk of residual disease.

Methods

Educational surgical video article. Patient's consent to present and publish the video has been obtained.

Results

The surgery starts by splitting the nodule in three components according to different anatomical structures involved (parametrium, vagina and rectum). Once parametrial and vaginal fragments are excised, the rectal involvement is approached following several steps. (1) Isolation and cut of inferior mesenteric vessels in order to obtain a proper colon mobilization. (2) Transanal rectotomy (3) and subsequent extraction of the specimen through the anus. (4) Proximal bowel segment transection under real time fluorescence imaging. (5) Placement of circular stapler anvil into the sigmoid colon secure by a pursestring. (6) Placement of a second pursestring at the distal rectal cuff. (7) Connection of the anvil to the shoulder of circular stapler. (8) Circular stapler firing and colo-anal anastomosis formation. (9) Reinforcement of anastomosis by placing some stitches along the stapled line. (10) Integrity anastomosis test.

Conclusions

Even though no data are yet available in patients with endometriosis, the use of TTSS technique can be considered a valid surgical alternative in patients with very low rectal endometriosis involvement.

<https://player.vimeo.com/video/830301124?autoplay=1>

**ES32-0650 -
Best Selected Videos 2**

Laparoscopic approach to uterovaginal prolapse

Tânia Barros¹, Cristiana Moreira¹, Rosa Zulmira Macedo², Hélder Ferreira³

*¹Centro Materno Infantil do Norte- Centro Hospitalar Universitário do Porto,
Departamento da Mulher e da Medicina Reprodutiva, Porto, Portugal*

*²Centro Materno Infantil do Norte- Centro Hospitalar Universitário do Porto, Serviço de Ginecologia, Porto,
Portugal*

*³Centro Materno Infantil do Norte- Centro Hospitalar Universitário do Porto,
Unidade de Endoscopia Ginecológica, Porto, Portugal*

Background

Urogenital prolapse is a common problem, concerning approximately a third of adult women. The main objective of this video is to illustrate and describe the steps in detail during laparoscopic promontofixation.

Methods

Step-by-step video demonstration of the technique.

Results

Procedure: Opening the field. Dissection of the anterior vertebral ligament on the right of the promontory. Pararectal dissection. Dissection of the rectovaginal and vesicovaginal spaces. Supracervical hysterectomy. Fixation of the meshes anteriorly on the vagina, and posteriorly on the levator ani and uterosacral ligaments. Fixed mesh to the promontory. Peritonization.

Conclusions

This technique allows the correction of the genital prolapse with good anatomical and functional results. Standardization of laparoscopic techniques helps make the procedure faster and safer.

<https://player.vimeo.com/video/831980608?autoplay=1>

**ES32-0446 -
Best Selected Videos 2**

Measurement of mid-fundal indentation length of partial septate uterus using hysteroscopic scissors

Manuel Merida¹, Hudson Macy¹, Brown Jenna¹, Youssef Youssef¹, Abuzeid Mostafa¹

¹Hurley Medical Center - Michigan State University College of Human Medicine, Obstetrics and Gynecology, Flint- Michigan, USA

Background

Uterine septum is the most common Mullerian anomaly associated with negative fertility and pregnancy outcomes. Hysteroscopic metroplasty is the gold standard for surgical correction in patients with uterine septum. Hysteroscopic diagnosis and optimal treatment of this pathology are of vital importance to ensure positive fertility and pregnancy outcomes and to avoid uterine perforation or thinning of the fundal region.

Methods

This is a video presentation to show different techniques for indirect and direct mid-fundal indentation measurement for the treatment of complete and partial uterine septum with the introduction of a new technique.

Results

This video demonstrates techniques for both direct and indirect measurement of the mid-fundal indentation with the graduating uterine palpator and the hysteroscopic scissors. This suggests that hysteroscopic scissors can be considered an accurate hysteroscopic measuring device.

Conclusions

In the absence of graduating uterine palpator, hysteroscopic scissors might serve as an accurate measuring device to determine the extent of mid-fundal indentation. This may help in the diagnosis of a partial septate uterus as this device is readily available in hysteroscopic surgical kits. The technique may also be helpful during hysteroscopic metroplasty by ensuring complete surgical correction and avoiding uterine perforation or thinning the fundal region.

<https://player.vimeo.com/video/830023852?autoplay=1>

**ES32-0537 -
Best Selected Videos 2**

Introduction of the Fri-Endo-Score app a web-based application for the automated calculation of the endometriosis scores

Carolin Marti¹, Benedetta Guani¹, Nordine Ben Ali¹, Gaby Moawad², Arrigo Fruscalzo¹, Anis Feki¹

¹HFR Hopital Fribourgeois, Gynecology and obstetrics, Fribourg, Switzerland

²The George Washington University School of Medecine and Health Sciences, Obstetrics and Gynecology, Washington DC/Baltimore, USA

Background

Endometriosis is one of the most impacting diseases in childbearing age, affecting up to 15% of women and responsible for infertility, chronic pain and pelvic organ disruption. Surgery allows the diagnosis and assessment of endometriosis and surgeons are strongly encouraged to report the extent and localization of the endometriosis according to three different classifications: the revised American Society for Reproductive Medicine (rASRM), the revised Enzian (#Enzian) and the Endometriosis Fertility Index (EFI). Currently, surgeons need to fill out paper forms to calculate the three recommended scores, which is time consuming and subject to errors.

Methods

We developed an online application for the automated documentation of the localization and the extent of endometriosis. This information is entered online, and the data is converted according to the three classifications currently used for documenting and staging endometriosis. The application generates a summary and the different scores in an exportable PDF format.

Results

We will present the functionalities of the application in a short video. We show an endometriosis surgery, and the surgical key moments are highlighted. The endometriosis scores will be calculated via our application according to the rASRM, #Enzian and EFI classifications.

Conclusions

The Fri-Endo-Score web-based application facilitates the documentation of the surgical localization and extent of the endometriosis and enables an automated calculation of the endometriosis scores according to the rASRM, #Enzian and EFI classifications.

<https://player.vimeo.com/video/831549843?autoplay=1>

**ES32-0417 -
Best Selected Videos 2**

A complex case of reparation of ureteral lesion

Daniele Neola¹, Martino Vetrella¹, Mario Malzoni²

¹University of Naples Federico II, Department of Neuroscience- Reproductive Sciences and Dentistry, Naples, Italy

²Endoscopica Malzoni, Center for Advanced Endoscopic Gynecological Surgery, Avellino, Italy

Background

We report the case of 42 years old woman with an anamnesis of only a non-specified endometriosis, treated with dienogest 2 mg. The BMI was 23.73 and previous surgery included two caesarean sections and a laparotomic appendectomy.

Methods

She was initially admitted to another clinic for fever and acute pelvic pain due to a suspected pelvic inflammatory disease. She underwent a CT scan evaluation which found the presence of a bilateral tubal-ovarian abscess, for which she underwent an intervention of laparoscopic adhesiolysis, drainage of bilateral tubal abscess and bilateral adnexectomy. During the postoperative course, she had fever, left pelvic pain and loss of citric liquid through the drainage tube. She underwent an urgent URO CT scan, which detected a lesion of the left ureter. Therefore, she was referred to our centre for the surgical management. Patient was admitted to our clinic and appeared in stable clinical conditions. At the clinical evaluation, the abdomen was palpable, with negative Bloomberg sign, but globular, with drainage of citric liquid through the previously inserted drainage tube. We performed a transvaginal and transabdominal ultrasound, detecting the presence of an abdominal urinoma.

Results

We initially decided to perform a left ureter reimplantation with psoas hitch technique. However, our initial surgical plan was not feasible due to the shortness of the remaining proximal ureter tissue. Thus, we decided for a laparoscopic procedure of ureterolysis, mobilization of the abdominal segment of the left ureter, fixation of the proximal ureter (abdominal segment) to the psoas muscle and termino-terminal anastomosis with the distal hemi-ureter.

Conclusions

With our report, we want to show a different approach to repair a ureteral lesion.

<https://player.vimeo.com/video/831671622?autoplay=1>

**ES32-0431 -
Best Selected Videos 2**

Laparoscopic treatment of a vascular entrapment and schwannoma of the right sciatic nerve

Marc Possover¹, Yatsentiuk Vitalina¹

¹Possover International Medical Center AG, Neuropelveology & Gynecology, Zürich, Switzerland

Background

A 32-year-old airline pilot presented to our neuropelveology centre for treatment of a suspected schwannoma of the right sciatic nerve on MRI. She started to develop a right sciatica three years ago, which neuropathic pain reaches since then a permanent threshold of VAS 8-10/10 und strong pain medications. For 1.5 years, she also developed increasing neurological disorders with in particular a right foot drop that requires walking with crutches. Due to the localization of the tumour lateral to the iliac vessels and the difficulties of invasive access by dorsal neurosurgical approach, no neurosurgeon has dared the intervention. Neuropelveological examination confirmed a neurogenic radiculopathy L5-S1 right. The MRI examination confirmed the suspicion of a schwannoma of the intrapelvic portion of the right sciatic nerve, as well as the suspicion of a "vascular entrapment" by atypical gluteal vessels.

Methods

A laparoscopic approach was planned. Access to the supracardinal part of the sciatic nerve was obtained by dissection of the lumbosacral space. Following identification of both the obturator nerve and the lumbosacral trunk, the presence of atypical gluteal vessels responsible for vascular compression of the sciatic nerve (sc "vascular entrapment") was confirmed. These vessels were coagulated and resected. By further blunt dissection of the sciatic nerve, the schwannoma was localized. A longitudinal neurotomy of the sciatic nerve was performed followed by an interfascicular neurolysis with enucleation in toto of the schwannoma.

Results

The intervention went well without complications. After a primary decrease in pain for few days due to the induced neurapraxie, the pain reappeared but improved considerably in the following months (VAS <3/10 without medications). The operation was followed by a postoperative physiotherapy. The histological examination confirmed a benign schwannoma.

Conclusions

In conclusion, this video demonstrates that laparoscopy is a suitable approach for neurosurgical pelvic procedures.

<https://player.vimeo.com/video/827550829?autoplay=1>

3D Imaging reconstruction and laparoscopic robotic surgery approach to disseminated peritoneal leiomyomatosis

Giuseppe D'Angelo¹, Gaby N Moawad², Mario Ascione¹, Roberta Danzi³, Pierluigi Giampaolino⁴, Giuseppe Bifulco⁴

¹*University of Naples Federico II,*

Department of Neuroscience- Reproductive Sciences and Dentistry- School of Medicine, Naples, Italy

²*George Washington University, Department of Obstetrics and Gynecology, Washington, USA*

³*Pineta Grande Hospital, Department of Radiology, Castel Volturno, Italy*

⁴*University of Naples Federico II, Department of Public Health, Naples, Italy*

Background

Disseminated peritoneal leiomyomatosis is a benign condition, defined as the presence of multiple peritoneal nodules of various sizes composed of bland smooth muscle cell. This video article aims to explore the combined approach of 3D imaging reconstruction and laparoscopic robotic surgery for disseminated peritoneal leiomyomatosis, focusing on the advantages offered by robotic surgery, including reduced tremor, enhanced precision in confined spaces, decreased operating time and uterine surface incisions.

Methods

A case study of a 43-year-old nulliparous infertile woman with multiple symptomatic uterine myomas is presented. Robotic surgery was chosen due to the widespread localization of peritoneal leiomyomatosis associated with uterine myomatosis. 3D imaging reconstruction technology was utilized for preoperative and intraoperative planning, accurately determining the location, size, and volume of the fibroids through MRI imaging.

Results

Robotically assisted laparoscopic surgery successfully validated the preoperative 3D reconstruction findings. Multiple intraperitoneal fibroids were visualized and removed. 3D imaging reconstruction technology guided the surgeon in real-time, facilitating rapid localization of myomas and adjustment of the surgical strategy. The procedure resulted in the removal of 15 fibroids, with minimal blood loss (250 mL) and a total operative time of 120 minutes.

Conclusions

The combined approach of 3D imaging reconstruction and laparoscopic robotic surgery provides several advantages for disseminated peritoneal leiomyomatosis management, guaranty the patient to have a procedure effective as a classic open myomectomy while maintaining the advantages of a minimally invasive technique. 3D imaging reconstruction technology overcomes limitations associated with robotic surgery, compensating for the lack of depth perception and haptic feedback. The accurate virtual landmark of the uterus and fibroids aids surgeons in efficient and effective surgery, reducing the time required for fibroid localization. Further research is needed to fully evaluate the clinical impact of this promising technology.

<https://player.vimeo.com/video/830679303?autoplay=1>

**ES32-0474 -
Best Selected Videos 2**

Excision of DIE nodule involving the sciatic nerve

Hasan Onur Topcu¹, Atahan Toyran¹

¹Turkish society of minimally invasive gynecology, gynecology, Ankara, Turkey

Background

This study aims to present the clinical profile of a 35-year-old female patient, including her surgical history and current complaints, with a focus on the effectiveness of the performed surgical procedures in reducing her symptoms and improving her overall well-being.

Methods

This study analysed the clinical profile of a 35-year-old female patient, focusing on her current complaints. The patient's current complaints, including dysmenorrhea, dyspareunia, dyschezia, dysuria, and radiating pain, were recorded based on clinical assessments and patient reports. Preoperative findings such as numbness, decreased muscle strength, inability to perform certain movements, and rectovaginal nodularity were also documented. The subsequent reduction in symptoms following the surgical interventions was analysed, highlighting the effectiveness of the procedures in improving the patient's well-being.

Results

The surgical interventions led to a significant reduction in the patient's symptoms. Dysmenorrhea, dyspareunia, dyschezia, dysuria, and radiating leg pain notably improved. Numbness, muscle weakness, and nodularity in the rectovaginal area were also alleviated. The findings highlight the effectiveness of the surgeries in improving the patient's well-being.

Conclusions

It can be challenging to diagnose deep infiltrating endometriosis, especially in the absence of endometriomas. However, surgery can alleviate symptoms and improve the quality of life for patients in this particular group.

<https://player.vimeo.com/video/831255781?autoplay=1>

BEST SELECTED PHD

ES32-0041 - Best Selected PhD Abstracts

EQUUSUM: classification and registration in deep endometriosis surgery cracking the enigma

*Jeroen Metzemaekers¹, Frank Willem Jansen¹, Andries Twijnstra¹, Mathilde Smeets¹, Mathijs Blikkendaal¹,
Stephanie Both²*

¹LUMC, Gynaecology, Leiden, The Netherlands

²AMC-Vu, Psychology and sexuology, Amsterdam, The Netherlands

Aim

The aim of this thesis is to propose the creation of a digital system, EQUUSUM, to facilitate uniform registration and classification of endometriosis, and to emphasize the importance of patient-reported outcomes (PROMs) and a uniform benchmark data for adverse event reporting in the decision-making process for endometriosis patients.

Background

The lack of uniformity in endometriosis registration and classification has hindered communication among healthcare providers and limited scientific research, hindering the development of improved treatment strategies. The absence of uniform benchmark data for adverse event reporting has made quality assessments of provided care challenging. Finally, the lack of patient-reported outcomes has limited the decision-making process for endometriosis patients.

Materials / Patients

This thesis was conducted on patients with endometriosis.

Methods / Results

This thesis highlights the importance of uniformity in endometriosis registration and classification, adverse event reporting, and patient-reported outcomes. It proposes the use of EQUUSUM, adverse event classification systems, and simple visual analogue scales for quality of life as tools to improve the healthcare system related to endometriosis. This thesis emphasizes the importance of patient's view in the decision-making process and the need for better information provision and training for healthcare providers in the shared decision-making process.

Discussion

The thesis highlights the importance of uniformity in endometriosis registration and classification, adverse event reporting, and patient-reported outcomes. The thesis proposes the use of EQUUSUM, adverse event classification systems, and simple visual analogue scales for quality of life as tools to improve the healthcare system related to endometriosis. The thesis also emphasizes the importance of patient's view in the decision-making process and the need for better information provision and training for healthcare providers in the shared decision-making process.

Conclusion

This thesis concludes that the proposed tools are necessary to improve the healthcare system related to endometriosis. Healthcare providers should implement these tools swiftly to provide endometriosis patients with benefits from insights of (future) scientific research.

Impact to Patients' Health

The proposed tools, including EQUUSUM, adverse event classification systems, and simple visual analogue scales for quality of life, could facilitate communication among healthcare providers, enable the development of improved treatment strategies, provide a uniform database for scientific research, and improve the decision-making process for endometriosis patients, ultimately improving the quality of care for endometriosis patients.

**ES32-0117 -
Best Selected PhD Abstracts**

Optimizing hysteroscopic treatment

Steffi Van Wessel¹, Tjalina Hamerlynck¹, Jan Bosteels², Benedictus Schoot³, Steven Weyers¹

¹Universitair Ziekenhuis Gent, Vrouwenkliniek, Gent, Belgium

²Imelda Ziekenhuis, Gynaecologie, Bonheiden, Belgium

³Catharina Ziekenhuis, Gynaecologie, Eindhoven, The Netherlands

Aim

To explore innovations that could improve hysteroscopic practice with regard to pain relief (part I), instrumentation (part II) and reproductive outcomes (part III).

Background

The technique of hysteroscopy has evolved over the years. Currently, there is a preference for small diameter and mechanical instruments, and for the office setting.

Materials / Patients

Part I

Women (18 – 50 years) undergoing outpatient diagnostic hysteroscopy. Pilot-RCT comparing nifedipine, naproxen and placebo.

Part II

A. RCT comparing hysteroscopic tissue removal (HTR) with conventional bipolar resection of removal of submucous type 0 and 1 fibroids (≤ 3 cm).

B. Non-inferiority RCT comparing hand with motor-driven HTR device for polypectomy (≥ 8 mm - ≤ 20 mm).

C. Observational study using a small diameter hand driven HTR device for outpatient hysteroscopic polypectomy (≤ 8 mm) without anesthesia.

Part III

A. Follow-up study of the reproductive outcomes in women who participated in a previous RCT comparing HTR with loop resection for hysteroscopic retained products of conception (RPOC) removal.

B. RCT on the influence of anti-adhesion gel on the reproductive outcomes after operative hysteroscopy (for polyps, fibroids with uterine cavity distortion, septa, intrauterine adhesions (IUA) or RPOC in women wishing to conceive (18 – 47 years).

Methods / Results

Part I

Pain scores and success rates were not significantly different. Nifedipine was significantly more related with side-effects.

Part II

A. HTR is faster than conventional bipolar resection.

B. Instrumentation set-up and total procedure time were not significantly different. Fluid deficit and surgeon reported outcomes were significantly higher in the hand-driven group.

C. 90% of the procedures were completed in 7.6 minutes (95% confidence interval 6.2 – 8.1). Surgeon and patient reported outcomes were high.

Part III

A. Reproductive outcomes were not significantly different, but placental complications occurred in around 20%.

B. Ongoing trial. Results are to be expected mid-2025.

Discussion

Part I

Pain relief might not always be necessary, but non-steroid anti-inflammatory drugs could be considered taking Tmax into account.

Part II

A. Calcified fibroids are a limiting factor for complete resection.

B. The simplified set-up was non-inferior. Overall, fluid deficits were low, and surgeon reported outcomes were high.

C. Outpatient hand driven HTR is feasible.

Part III

A. There is a trend towards more live births using HTR system.

Conclusion

The role of pain relief in outpatient diagnostic hysteroscopy is uncertain. HTR is superior for submucous type 0 and 1 fibroids. The hand driven HTR device is an alternative for hysteroscopic polypectomy and polypectomy with the small diameter variant is feasible in an outpatient setting. Hysteroscopic RPOC removal is not detrimental for reproductive outcomes.

Impact to Patients' Health

Attention is being paid to make hysteroscopy tolerable, efficient, and safe.

**ES32-0188 -
Best Selected PhD Abstracts**

Temporary occlusion of uterine arteries in laparoscopic myomectomy: a randomized clinical trial

Enrique Moratalla Bartolomé¹, Lopez Carrasco Irene², Cabezas Lopez Elena¹, Miro Matos Maria², Montero Pastor Nerea², Lazaro-Carrasco De la Fuente Jesus³

¹University Hospital Ramón y Cajal. University Hospital HM Montepincipe, Obstetrics and Gynecology, Madrid, Spain

²University Hospital HM Montepincipe, Obstetrics and Gynecology, Madrid, Spain

³University Hospital Ramón y Cajal., Obstetrics and Gynecology, Madrid, Spain

Aim

The aim of this randomized controlled prospective study is to compare results between laparoscopic myomectomies with and without bilateral temporary occlusion of uterine arteries and utero-ovarian ligaments.

Background

Intraoperative bleeding is one of the most common complications of laparoscopic myomectomy and requires blood transfusion in some cases. For this reason, methods have been proposed that could reduce bleeding during surgery, such as temporary uterine arteries occlusion and utero-ovarian ligaments. The efficacy and safety of this technique for its application during laparoscopic myomectomy has not been yet clearly investigated.

Materials / Patients

From February 2020 to December 2022, a total of 80 patients with symptomatic uterine myomas were randomly divided into trial (clip group: A, n = 40) and control groups (non-clip group: B, n = 40).

Temporary bilateral uterine artery and utero-ovarian ligaments occlusion and myomectomy were performed in group A and laparoscopic myomectomy only in group B.

The occlusion was performed with a titanium laparoscopic clip at the beginning of the surgery.

All the laparoscopic myomectomies were performed by the same surgeon.

Principal surgical outcome was perioperative bleeding; it was evaluated by pre and post-operative hemoglobin level (g/dL) and blood aspirate in milliliters during surgery. Other secondary surgical outcomes include operative time, admission time and complications.

Methods / Results

	NUMBER	CLIPS NO	CLIPS YES	P value	
N		40	40		
Age mean (IQR)		38 (35 -41)	37 (35.4 – 39)	0.32	
Weight, mean (SD)		60.5 (10,0)	64,3 (10,2)	0.092	
Height, mean (SD)		1,6 (0,1)	1,7 (0,1)	0,35	
BMI, mean (SD)		22,5 (3,5)	23,4 (4,0)	0,30	
Previous Pregnancies	0	37 (93 %)	33 (83 %)	0,30	
	1	1 (3 %)	5 (13 %)		
	2	1 (3 %)	1 (3 %)		
	3	1 (3 %)	0 (0 %)		
	7	0 (0 %)	1 (3 %)		
N fibroids	1	13 (33 %)	13 (33 %)	0,77	
	2	13 (33 %)	9 (23 %)		
	3	3 (8 %)	7 (18 %)		
	4	5 (13 %)	5 (13 %)		
	5	2 (5 %)	2 (5 %)		
	6	2 (5 %)	1 (3 %)		
	8	0 (0 %)	1 (3 %)		
	9	1 (3 %)	0 (0 %)		
	10	1 (3 %)	1 (3 %)		
	12	0 (0 %)	1 (3 %)		
Size of the major Fibroid (mm), mean (SD)		74,9 (20,3)	77,5 (24,7)		0,61
Hb Preqx, mean (SD)		13,4 (1,2)	13,3 (1,2)		0,70

	CLIPS NO	CLIPS Yes	p-value
N	40	40	
Hb postqx, mean (SD)	11,1 (1,2)	11,4 (1,4)	0,43
Dif Hb, mean (SD)	2,3 (0.9)	1,9 (1,1)	0,15
Blood Loss (ml), mean (SD)	394,4 (231,0)	227,1 (247,2)	0,025
Days of Admission, median (IQR)	1,0 (1,0, 1,0)	1,0 (1,0, 2,0)	0,17
Surgical Time (min), mean (SD)	82,7 (25,0)	92,1 (35,4)	0,17

Discussion

Mean age of women with clips (group A) was 37 years vs 38 years in the non-clip group (group B) ($p=0.32$). Body mass index (BMI) was 22.5 ± 4.0 kg/m² in group B and 23.4 ± 3.5 kg/m² in group A ($p=0.30$). Groups showed no differences in the mean number of previous pregnancies or the size of the myomas. Mean size of the largest fibroid in group A was 77.5 ± 24.7 mm and 74.9 ± 20.3 mm in group B ($p= 0.61$).

Operative time between groups was not significantly different in both groups: 92.1 ± 35.4 minutes in group A vs 82.7 ± 25.0 minutes in group B ($p = 0.17$).

No significant differences were found between preoperative and postoperative hemoglobin levels (1.9 ± 1.1 g/dL in group A, 2.3 ± 0.9 g/dL in group B) ($p=0.43$). However, intraoperative blood loss in group A was notably lower than in the conventional surgery group (group B): 227.1 ml and 394.4 ml, respectively ($p < 0.05$).

All patients in this study underwent successful laparoscopic surgery without intraoperative complications.

Conclusion

Temporary bilateral uterine artery occlusion during laparoscopic myomectomy proves to be a good alternative to reduce blood loss effectively and safely and does not significantly increase neither operative time nor admission time, compared with conventional surgery.

Impact to Patients' Health

Temporary occlusion of uterine arteries allows minimally invasive surgery to be performed safely with lower blood loss for patients.

**ES32-0278 -
Best Selected PhD Abstracts**

Volumetric growth of uterine myomas: analysis of the risk factors from a prospective study

Alessandro Arena¹, Eugenia Degli Esposti¹, Giulia Rovero¹, Enrico Pazzaglia¹, Paolo Casadio¹, Renato Seracchioli²

¹Sant'Orsola Hospital - University of Bologna, Gynaecology and Human Reproduction Physiopathology, Bologna, Italy

Aim

To evaluate the anamnestic, clinical, and ultrasound factors capable of predicting the growth of myomas in patients enrolled at our academic centre.

Background

Uterine myomas are the most common uterine neoplasms, affecting up to 30% of women of childbearing age. Despite the high prevalence, in Literature few studies have analysed the risk factors for the growth of uterine myomas, showing conflicting results.

Materials / Patients

In our prospective observational study, we enrolled patients who met the inclusion and exclusion criteria and who had received a first sonographic diagnosis of uterine myomas at our outpatient clinic, starting in June 2017. For each patient, uterine myomas were evaluated by ultrasound and described according to MUSA criteria. Since January 2019 (follow-up 24±5 months), we have evaluated all the previously enrolled patients who had returned to our clinics for ultrasound, until reaching the designated sample of 450 patients.

Methods / Results

The annual growth rate of the largest myoma was evaluated for each patient and a multivariable fractional polynomial approach was used to select anamnestic and/or ultrasonographic risk factors associated with the volumetric growth. About half (230/450) of the uterine myomas analysed remained stable in size during the follow-up (growth ≤10%), while the remaining grew in volume > 10%. Patients' age, ethnicity, as well as fibroids' number, FIGO type, location, vascularisation, and site were not significantly associated with the risk of growth. The only risk factor associated with the volumetric growth of uterine myomas was the fibroid's volume at first ultrasound (P = 0.001): small myomas have a higher growth rate than large myomas.

Discussion

Our study clearly demonstrated that small myomas are more likely to grow than larger myomas. Moreover, our analysis has disproven what had previously been suggested by some studies, especially regarding the risk of myomas' enlargement in case of myomas > 50mm of diameter, or a higher risk of growth based on myomas' vascularisation. The study provides a very large series that allows us to gain significant insight into an area, the one relating to the natural history of uterine myomas, in which evidence is scarce and fragmented, despite the high prevalence of the pathology.

Conclusion

The present study collected the largest case series in the literature in the evaluation of the natural course of dimensional modification of uterine myomas. Our data demonstrate that approximately 50% of uterine myomas have an annual volumetric growth rate greater than 10% per year, and that small myomas are more likely to grow than larger ones.

Impact to Patients' Health

Although further studies with larger sample sizes are needed, this study could help counsel patients affected by uterine myomas. For myomas edging the uterine cavity, especially, knowing the natural growth pattern of fibroids could be crucial to plan the best therapeutic approach in symptomatic women or those desiring pregnancy.

**ES32-0451 -
Best Selected PhD Abstracts**

NOSE technique in the surgical treatment of colorectal endometriosis

Alexandr Popov¹, Anton Fedorov¹, Michail Belousov¹, Yulia Sopova¹, Elena Efremova¹
¹Moscow Regional Institute of Obstetrics and Gynecology, Gynecology, Moscow, Russia

Aim

The purpose of this study was to determine the most optimal surgical tactics and evaluate the effectiveness of the NOSE technique in the treatment of colorectal endometriosis, both by classical laparoscopic access and using the DaVinci robotic unit.

Background

In recent years, there has been an increase in the frequency of detection of deep infiltrative endometriosis, which occupies up to 33% in the total structure of patients with endometriosis. The hallmarks of this type of endometriosis are the germination of endometriotic lesions from the surface of the peritoneum to a depth of more than 5 mm, which is accompanied by dysfunction of the affected organs, the development of adhesions, and a violation of anatomical relationships in the pelvic cavity. The involvement of the intestinal wall in the infiltrate was found in 8-12% of women with endometriosis. In this case, in 90% of cases, the large intestine is affected.

Materials / Patients

A prospective study was conducted, including the experience of colorectal resection with the NOSE technique in 31 patients with infiltrative endometriosis of the intestine for the period from 2021 to 2023.

Methods / Results

The indications for surgical treatment were: 1. Patients with a symptomatic form of colorectal endometriosis. 2. Characteristics of the endometrioid infiltrate: length 30 mm or more, depth of invasion 7 mm or more, and degree of involvement of the intestinal circumference 40% or more. 3. Narrowing of the intestinal lumen according to colonoscopy in asymptomatic patients diagnosed with colorectal endometriosis using endoscopic diagnostic methods. Research results: all patients were operated on using a minimally invasive approach: in 16 cases, the treatment was performed by laparoscopic access, and in 15 cases, by robot-assisted access.

Discussion

NOSE technology eliminates the extra-abdominal stage of the operation, thereby reducing the duration of surgical treatment from 153.4 (54.61) to 98.0 (75;128) minutes in the laparoscopic group and from 172.5 (33.35) to 158.0 (150;170) minutes in robotic, eliminates complications associated with minilaparotomy size, has a better cosmetic effect. The use of a fully intracorporeal anastomosis significantly reduces the cost of laparoscopic surgery, without excluding its reliability.

Conclusion

Colorectal resection for endometriosis leads to a significant improvement in quality of life indicators (from 34.1% in the preoperative stage to 81.1% in the late postoperative period in the laparoscopic group and from 30.8% to 87.0% in the robotic group according to the pelvic questionnaire), reduction of proctological complaints (from 30.7% in the pre-operative stage to 10.3% in the late postoperative period in the laparoscopic group and from 25.6% to 12.8% in the robotic scoring system for impaired bowel evacuation function). The quality-of-life index was better in the robotic group in percentage terms, despite the absence of a statistically significant difference between the groups.

Impact to Patients' Health

No negative impact to patients Health

**ES32-0453 -
Best Selected PhD Abstracts**

Intraovarian application of PRP and place of transvaginal hydro laparoscopy

Sylvie Gordts¹, Isabelle Seghaert¹, Valerie Schutyser¹, Rudi campo², Stephan Gordts²

¹LIFE, Regionaal ziekenhuis Heilig Hart, Leuven, Belgium

²life expert centre, Life expert centre, Leuven, Belgium

Background

Pilot study evaluating the possibility of ovarian rejuvenation by injecting autologous PRP (Platelet Rich Plasma) in both ovaries.

Methods

The treatment was proposed to patients diagnosed as poor responders on ovarian stimulation after several attempts of failed IVF (POR), patients with POF (premature ovarian failure), and patients at the beginning of menopause. PRP was obtained after centrifugation at high speed in special vials of 60-80 cc of the patient's blood samples, resulting in approximately a concentration of 800.000-900000/microL. Application of PRP into the ovaries is performed under ultrasound guidance transvaginally using a 19G needle. In each ovary, 3ml is injected at one puncture place. Due to the small size of the ovaries in this selected group of patients, frequently ovaries are not clearly visible under ultrasound. In these patients' application of PRP was done using the technique of transvaginal hydro laparoscopy (THL). All procedures are performed in a day hospital setting under sedation. All patients were clearly informed that at this stage the treatment is still experimental and that results cannot be guaranteed.

Results

In total 97 procedures were done in 61 patients. For 13 patients the follow-up is still too short for evaluation of results. 7 patients were lost of follow-up and were included as non-successful resulting in 32 non-reacting patients (32/48). 16/48 patients had a positive pregnancy test (33.3%). 10 pregnancies are evolutive or already delivered a born child (10/48: 20.8%). 3 pregnancies were biochemical, 2 abortions, and one ectopic.

Conclusions

These preliminary results show a possible beneficial effect of ovarian application of PRP for reactivation of the ovaries. In the absence of a control group Interpretation of results should be careful. The THL offers a minimally invasive way for the intra-ovarian application of PRP when visualization of ovaries at ultrasound is doubtful.

**ES32-0484 -
Best Selected PhD Abstracts**

The diagnosis and treatment of endometrial pathology in the outpatient setting

Prathiba De Silva¹, Paul Smith², Arri Coomarasamy¹, Justin Clark²

¹University of Birmingham, Institute of Metabolism and Systems Research, Birmingham, United Kingdom

²Birmingham Women's Hospital, Department of Gynaecology, Birmingham, United Kingdom

Aim

To determine the optimal method of delivering hysteroscopy in the outpatient setting and explore the role of outpatient hysteroscopy (OPH) in the treatment of retained products of conception (RPOC) following miscarriage.

Background

Pain remains the greatest barrier to a successful OPH and so it is vital that clinicians are informed as to how best to perform hysteroscopy to minimise this. An area where hysteroscopy remains in its infancy is in the management of RPOC which is thought to be safer and better than alternate treatments because tissue removal is done under direct vision, however, no randomised data exists.

Materials / Patients

The first half of this thesis demonstrates the work involved in developing a national evidence-based 'green-top' guideline (GTG) for the Royal College of Obstetricians and Gynaecologists (RCOG) on how OPH should be provided and performed. The second half comprises a pilot RCT evaluating the feasibility of a trial (HYMMN) investigating the effectiveness of OPH compared to standard treatment (ST) (expectant/medical/surgical) for the removal of RPOC with regards to future pregnancy outcome.

Methods / Results

Where possible, recommendations for the GTG were directly linked to the evidence supporting them, which were accrued through systematic reviews of RCTs, of which seven were published in high-impact scientific journals (JMIG(3), BJOG(1), EJO(3)). Recommendations that lacked evidence were agreed upon by expert consensus (>200 clinicians). 158 patients were identified for inclusion into the HYMMN trial over 6 months. 6% (9/158) declined participation. 15% (23/149) failed to attend their ultrasound scan. Randomisation of patients with RPOC to either OPH or ST was acceptable to all (n=42). Ultrasound and OPH were highly acceptable (>99%) and successful, without any complications. In 12 months, only 9% (11/126) could not provide us with pregnancy data.

Discussion

Recommendations for the GTG were made regarding service provision, documentation, antimicrobial prophylaxis, conscious sedation, analgesia, local anaesthesia, vaginoscopy, hysteroscopic devices, cervical preparation, and distension medium type, pressure and temperature. A future, full-scale, well-powered, multi-centre RCT investigating OPH against ST for the management of RPOC was demonstrated to be highly feasible, with high numbers of eligible patients, high patient acceptability of trial interventions and low attrition rates.

Conclusion

The work from this thesis has resulted in the production of a national UK guideline on how OPH should be delivered and has provided pilot data and highlighted important implications that must be considered when creating a full-scale RCT investigating OPH against ST for the treatment of RPOC.

Impact to Patients' Health

Informing clinicians on how to deliver hysteroscopy in a way that minimises pain directly improves the patient experience. Additionally, demonstrating that the hysteroscopic treatment of RPOC is safe, effective and feasible in the outpatient setting negates the risks/inconveniences of general anaesthesia and reduces the risks of incomplete treatment and uterine perforation which can occur with 'blind' treatments.

ABSTRACTS IN PLENARY SESSIONS

ES32-0516 - Endometriosis 1 | Surgical Aspects

Deep endometriosis: a series of 732 cases of more than 4cm A3C3 lesion proving that the 3cm rule should be abandoned

Olivier Donnez¹

¹Complex Endometriosis Center, Gynecology, Avignon, France

Background

Deep endometriosis remains one of the most aggressive forms of endometriosis, especially when both vagina and rectum are involved. As shaving is wrongly considered as superficial treatment, lesions of more than 3 cm size are usually treated by bowel resection or disc excision, with an increased risk of rectovaginal fistula.

We present here the result of 732 patients operated on the shaving technique with more than 4cm in size lesion classified A3C3 according to the # Enzian classification.

Methods

732 patients present with deep endometriosis lesions of more than 4cm in size, classified A3C3 according to the # Enzian classification.

exclusion criteria were less than 4cm deep endometriotic lesions, rectal stenosis of more than 80% of the lumen and rectal mucosa infiltration diagnosed by colonoscopy and biopsy.

All patients were operated on by the shaving technique using CO2 laser after proper bowel preparation. Surgical outcomes, intra and post operative complications were prospectively recorded as well as fertility outcomes. and recurrence rates.

Results

Shaving was performed in all cases whatever the size. The rectum was inadvertently opened in 11% of the case and immediately sutured with no further consequence.

Rectovaginal fistula occurred in 0.27% (n=2) of the cases and were treated with colostoma. One recovered spontaneously and the other was successfully operated by both vaginal and laparoscopic approach.

Ureteral fistula occurred in 0.54% (n=4) of the cases. One of them were treated by robotic ureteral implantation and the 3 others recovered 2 months after JJ placement.

59% of the patients were spontaneously pregnant within the 18 months after surgery and 81% after IVF attempt.

The recurrence rate based on imaging or the need to laparoscopic procedure was 0.82% (n=8)

Conclusions

Based on these result, size of deep rectovaginal endometriosis should not be a criterion for choosing radical rectal resection. Shaving can be proposed whatever the size with both low complication and recurrence rates.

Surgical treatment of cystic forms of adenomyosis in women with recurrent implantation failure

Nataliia Kotsabyn¹, Larysa Nykolyn¹, Iryna Kyshakevych²

¹*Medical center Damia, Department of Assisted Reproductive Technologies, Ivano-Frankivsk, Ukraine*

²*Ivano-Frankivsk National Medical University, Obstetrics and Gynecology, Ivano-Frankivsk, Ukraine*

Background

Adenomyosis increasingly complicates the fertility potential of women. Estimates of the prevalence of adenomyosis range from 5% to 70%.

According to Rasmussen et al. classification (2019) based on ultrasound data we can distinguish adenomyosis of inner myometrium, adenomyosis of junctional zone and adenomyosis of outer myometrium.

According to the data from P. Pirtea et al., Fertil Steril, 2021, true recurrent implantation failure (RIF) is rare, less than 5% would fail to achieve a clinical pregnancy with three euploid embryos transferred.

Methods

225 women with anatomically normal uterus, negative test for chronic endometritis who underwent 3 and more consecutive frozen embryo transfers with two embryos high quality (according to morphological score) were included in the study. The mean age of the patients included in the study was of 37,4 years. Monitoring was carried out from 2021 to 2023. Statistical analysis was carried out using the Statistics 6.0 program.

Biochemical pregnancy occurred in 207 patients (92%), clinical pregnancy in 170 (75.5%), of which 39 (17,3%) had an early miscarriage, 1 ectopic pregnancy (0.4%). The percentage of live births was 57,3% (129 women). Pregnancy did not occur in 18 women (8%).

Among 18 women who did not become pregnant, in 13 (72,2%) using 3d ultrasound investigation were diagnosed with cystic adenomyotic lesion located close to the junctional zone. It was decided to perform surgical treatment of cystic forms of adenomyosis in these patients as a preparation for embryo transfer.

During Hysteroscopy in the operative room under general anaesthesia using 16 Fr bipolar resectoscope excision and ablation (in case of deep penetration of cyst the ablation of its inner layer was performed) of cysts respecting healthy myometrium were performed. After appropriate preparation of the endometrium with agonists of Gonadotropin releasing hormone (1 dose of 3.75 mg) and oestrogen, all patients were performed frozen embryo transfers with two embryos high quality (according to morphological score).

Results

Among women with anatomically normal uterus, negative test for chronic endometritis who underwent 3 and more consecutive frozen embryo transfers with two embryos high quality pregnancy did not occur in 18 (8%). 13 women (72,2%) using 3d ultrasound investigation were diagnosed with cystic adenomyotic lesion located close to the junctional zone.

Among patients whom surgical treatment of cystic forms of adenomyosis was performed biochemical pregnancy occurred in 11 cases (77,3%%), live births was 60 % (9).

Conclusions

According to the data of our study, the frequency of women with RIF was 8%, which coincides with the data of P. Pirtea et al., Fertil Steril, 2021.

Among patients with RIF, the prevalence of cystic form of adenomyosis is 72.2%.

Surgical treatment during hysteroscopy (excision or ablation) of cystic forms of adenomyosis that are located close to the junctional zone in infertile women with RIF appear to be feasible and efficacious.

**ES32-0161 -
Urogynaecology 1**

Robot-assisted sacropexy: comparison between the novel HUGO robot-assisted surgery system and the established Da Vinci surgical system at a tertiary referral robotic centre

Margarita Afonina^{1,2}, Claudia Collà Ruvolo^{2,3}, Eleonora Balestrazzi^{2,3}, Marco Paciotti^{2,3}, Alexandre Mottrie³, Geert De Naeyer³

¹San Paolo Hospital Medical School, Department of Obstetrics and Gynecology, Milan, Italy

²Orsi Academy, Training center, Melle, Belgium

³OLV, Department of Urology, Aalst, Belgium

Background

Robotic sacropexy (RSC) emerged as a valid alternative to the laparoscopic technique in the last years. However, the robotic approach is still limited by platform availability. Recently, new robotic platforms joined the market, offering the possibility to expand the robotic approach. The aim of our study was to demonstrate the technical feasibility and the comparability of the procedure with the novel HUGO™ Robot-Assisted Surgery (RAS) System, operative at Onze Lieve Vrouw (OLV) Hospital (Aalst, Belgium) from January 2022, relative to the established Da Vinci® surgical system.

Methods

We reported data on the RSC performed with the Da Vinci® surgical system or with the HUGO™ RAS system, from January 2021 to January 2023, at OLV Hospital (Aalst, Belgium), by three expert robotic surgeons. The novel HUGO™ RAS platform consists of four fully independent carts, an open 3D console, and a system tower equipped for both laparoscopic and robotic surgery. We collected patients' characteristics, intraoperative data, perioperative complications, and clashes of instruments.

Results

Data from 38 women affected by a ≥ 2-grade pelvic organ prolapse (POP) according to the POP-quantification system, released by the International Continence Society, who underwent RSC at our centre, was recorded. Of all, 15 (39.5%) and 23 (60.5%) procedures were performed with Da Vinci® surgical system and with HUGO™ RAS system, respectively. The overall median age was 67 years (IQR: 59-75). No statistically significant differences were recorded regarding age, BMI, CCI, previous abdominal surgery, ASA score and comorbidities, between patients treated with either system. Of 20 RSC performed in 2022, 14 (70%) were executed with the HUGO™ RAS system. The median total operative time was 121.5 minutes (Da Vinci® 123 [IQR:106.5-140.5] vs HUGO™ RAS 120 [IQR:120-146], p=0.5). All patients removed the catheter between postoperative days 1 and 2 (median Da Vinci® 1 [IQR: 1-1] vs HUGO™ RAS 1 [IQR: 1-1],p=0.5). The median length of stay was 2 days (Da Vinci® 2 [IQR: 2-2] vs HUGO™ RAS 2 [IQR: 2-2.5],p=0.4). No need for conversion to open/laparoscopic surgery was required. No intraoperative complications, instrument clashes, or system failures that compromised the surgery's completion were recorded. No postoperative complications occurred. One patient who underwent RSC with HUGO™ RAS System was readmitted 7 days after surgery for abdominal pain. Due to negative imaging response, a conservative approach was used, and the patient was discharged the next day.

Conclusions

This study represents the first worldwide RSC comparison executed with the HUGO™ RAS vs Da Vinci® System. The RSC may be safely performed with both robotic platforms achieving optimal perioperative outcomes. Future investigations are needed to compare functional long-term outcomes between the novel HUGO™ RAS and the established Da Vinci® System.

**ES32-0201 -
Hysterectomy and Endometrial Ablation**

Vaginal versus abdominal approach for specimen extraction after laparoscopic hysterectomy: a randomized controlled trial

Gaby Moawad¹, Jordan Klebanoff², Youssef Youssef³, Maria V. Vargas⁴, Jenny Lachance⁵, Cherie Marfori⁶

¹George Washington University,

Division of Minimally Invasive Gynecologic Surgery- Department of Obstetrics and Gynecology, Washington, USA

²Main Line Health System,

Division of Minimally Invasive Gynecologic Surgery- Department of Obstetrics and Gynecology, Wynnewood- PA, USA

³Maimonides Medical Center,

Division of Minimally Invasive Gynecologic Surgery- Department of Obstetrics and Gynecology, Brooklyn- New York, USA

⁴Johns Hopkins Medicine-Sibley Memorial Hospital,

Division of Minimally Invasive Gynecologic Surgery- Department of Obstetrics and Gynecology, Washington, USA

⁵Hurley Medical Center/Michigan State University College of Human Medicine, Department of Research, Flint- MI, USA

⁶Inova Fairfax Hospital,

Division of Minimally Invasive Gynecologic Surgery- Department of Obstetrics and Gynecology, Virginia, USA

Background

Minimally invasive techniques have become the standard of care for hysterectomy. When removing large uteri, surgeons may choose either mini-laparotomy or vaginal morcellation for tissue extraction. The purpose of this randomized controlled trial is to compare the operative time required for tissue extraction via these two routes for uteri of different weights, with the aim of determining the uterine size at which mini laparotomy becomes more efficient than vaginal morcellation for specimen extraction and morcellation.

Methods

Randomized Clinical Trial was conducted between February 2016 and March 2019, at a single, urban university hospital providing tertiary care for minimally invasive gynaecologic surgery. The institutional review board approved the study protocol. Included patients were randomized to either mini-laparotomy or vaginal tissue extraction following their laparoscopic hysterectomy.

Results

The primary outcome of interest was the 'time to morcellate,' defined as the total time required from the start of extracorporeal morcellation to complete removal of the specimen. The study randomized seventy-four patients for either mini-laparotomy (n=38, 51%) or vaginal (n=36, 49%) approaches to tissue morcellation. Four cases were switched from vaginal to mini-laparotomy approaches, and two cases assigned to vaginal approach required no morcellation as the specimen was removed intact. An intention-to-treat analysis was performed, with medians reported when appropriate. Patient demographics, gravity, parity, and uterine weight were similar between the two groups, except for BMI, which was significantly lower in the vaginal approach group (31.9 kg/m² vs. 35.4 kg/m², p=0.043). Access time to the specimen was shorter in the vaginal approach group (47 seconds vs. 77.5 seconds, p<0.001). Although there was no significant difference in the overall time to morcellate between the vaginal approach (501 seconds) and mini-laparotomy (413 seconds, p=0.079), subgroup analysis revealed that the time to morcellate with the mini-laparotomy approach was significantly shorter for specimens weighing >1000 grams (641 seconds vs. 1715 seconds, p<0.001). Even when controlling for parity and BMI through multivariate analysis, the group with specimens >1000g continued to have significantly longer time to morcellate (P=0.002)

Table: Time needed to morcellate stratified by uterine weight (N= 74).

	n	Mini-laparotomy tissue extraction (n=38, 51%)	Colpotomy tissue extraction (n=36, 48.6%)	P
<=250	8	78 (33, 123)	123 (120, 125)	NE

>250 - <=500	19	254 (109, 635)	125 (79, 256)	0.371
>500 - <=750	20	323 (205, 450)	436 (379, 780)	0.138
>750 - <=1000g	14	787 (660, 803)	673 (462, 1080)	0.947
>1000g	14	641 (480.5, 937.5)	1715 (1380, 2291)	0.028

Reported median (IQR); NE: not estimable due to few events.

Conclusions

Based on the findings of this trial, the vaginal route for morcellation should be considered the optimal approach for large uteri projected to weigh less than 1000 grams. For uteri projected to weight more than 1000 grams, the mini-laparotomy approach may be favoured.

ES32-0344 -

Laparoscopy: Complications I Training

Surgical skills education and training on fetoscopy and fetal surgery

Francisco Margallo¹, Blanca Fernandez², Fernando Vuletin³, Alberto Galindo⁴, Silvia Arevalo⁵, José Luis Peiró⁶

¹Minimally Invasive Surgery Center, Laparoscopy, Caceres, Spain

²Minimally Invasive Surgery Centre, Laparoscopy, Caceres, Spain

³Catholic University Hospital, Paediatric surgery department, Santiago, Chile

⁴Hospital Universitario 12 de octubre de Madrid-, Obstetrics and Gynecology, Madrid, Spain

⁵Vall d' Hebron University Hospital-, Obstetrics Surgery Department, Barcelona, Spain

⁶Cincinnati Fetal Center, Director of Cincinnati Fetal Center, Cincinnati, USA

Background

Surgical education must constantly strive to keep up with the most current methods of surgical practice. We present our experience in organizing ten international editions of the training course in fetoscopic surgery. We have developed several inanimate training models and a sheep-animal model for training and research in foetal surgery that are practical and reproducible.

Methods

Various practices and surgical sessions are developed during training: Knowledge of sheep anatomy and physiology as a model of pregnancy, introduction to basic fetoscopy material, exploration of the uterine cavity, use of the Nd-YAG laser for photocoagulation of placental vessels, resolution of foetal and amniotic constriction bands, and endoscopic balloon tracheal occlusion (treatment of severe CDH).

Results

Fetoscopic surgery is technically challenging, and practicing and learning new skills in a clinical setting is fraught with risk. Successful performance requires a new set of technical skills and familiarity with surgical procedures. Understanding how to use the fetoscope, learning intrauterine vessel orientation, and becoming familiar with laser coagulation before operating on patients can reduce surgical complications. This training can shorten the learning curve for new surgeons and reinforce practice among experts as fundamental skills are developed using realistic tissue models and surgical simulators.

Conclusions

The sequential skill acquisition program using a simulator and animal model is transferable to human patients and shortens the learning curve for new specialists, although expert consultation is recommended in the initial phase to minimize potential complications.

**ES32-0553 -
Oncology 1**

Validation of two circulating MI-RNAs as potential biomarkers in the diagnosis and follow-up of women with atypical endometrial hyperplasia and endometrial cancer

*Maria Chiara De Angelis¹, Alfonso Manzi², Raffaella Del Papato³, Antonio Mercurio², Brunella Zizolff²,
Alessandra Gallo²*

¹University of Naples Federico II, Department of Public Health, Naples, Italy

²University of Naples " Federico II", Department of Public Health, Naples, Italy

³University of Bari, Department of Biomedical Sciences and Human Oncology, Bari, Italy

Aim

the aim of this study was to determine the accuracy of the predictive value of a selected panel of micro RNA obtained on endometrial tissue samples, in detecting endometrial cancer (EC) and its precursor, atypical endometrial hyperplasia (AEH)

Background

incidence of EC is still growing, mostly in patients that are not yet satisfied their desire for pregnancy at the time of diagnosis. Unfortunately, there are no diagnostic and follow-up biomarkers for this kind of tumour and the gold standard for diagnosis still remains tissue biopsy, which however have some limitations including the invasiveness of the procedure and the costs

Materials / Patients

a prospective observational study was conducted at University of Naples Federico II, among patients over the age of 18, with diagnosis of EC or AEH, in the absence of any previous treatment. Women with other kind of malignancy were excluded. Patients were divided into three groups: women with EC (group1), women with AEH(Group2), women with normal proliferative endometrium(Group3). All patients underwent office hysteroscopic biopsy using a standardized "grasp biopsy" technique. For each sample, after RNA extraction, the PCR Real Time analysis was performed to evaluate miRNA 504-5p and miRNA-429 expression, in order to compare the different level of expression between endometrial cancer tissue, hyperplasia tissue and healthy endometrial tissue.

Methods / Results

a total of 33 women were enrolled. Specifically, 15/33(45.5%) women were diagnosed with EC, 15/33(45.5%) patients with hyperplasia and 3/33(9%) with normal proliferative tissue. In Group1, a valid amplification plot for the miRNA 504-5p was expressed in 14/15(93.3%) women, and in 15/15(100%) of women for miRNA-429. In Group2, a valid amplification plot was found in 14/15(93.3%) patients for miRNA-504-5p and in 13/15(86.7%) patients for miRNA-429. In Group3, miRNA 504-5p was detected in 3/3 patients (100%) and miRNA-429 in 2/3(66.7%) women. A higher expression of the miRNA analysed was observed on the endometrial tissue obtained at the biopsy.

Discussion

our data share some important similarities with previously published reports, demonstrating that these two miRNAs are related to the diagnosis of AEH and EC. Their expression level was significantly lower in patients with AEH than those in healthy controls. Furthermore, they were found to be expressed at even lower levels in patients with EC compared to those with AEH.

Conclusion

this preliminary data demonstrated that this panel of miRNA could be proposed as a potential biomarker for diagnosis of EC and/or AEH; in particular, miRNA 429 expression could be linked to EC. Further studies are needed in order to validate the role of miRNAs for an earlier and reliable diagnosis.

Impact to Patients' Health

the identification of non-invasive diagnostic biomarkers to reduce the number of women who undergo invasive diagnostic testing, such as microRNA, could be useful as well as prognostic marker that can aid timing of treatment for AEH.

**ES32-0361 -
Robotics 1**

Results of robotic metrics and annotated videos analysis in gynecologic surgery

Felix Neis¹, Sara Brucker¹, Tjeerd Dijkstra¹, Christl Reisenauer¹, Bernhard Kraemer¹, Christina Walter¹
¹University of Tübingen, Gynecologie and Obstetrics, Tübingen, Germany

Background

Objective measurement of learning curves and surgical progress in surgical gynaecology is a major challenge. The introduction of the Intuitive data recorder (IDR) with the possibility of annotation of video data and collection of metric data has shown great potential.

Methods

Prospective collection of video and metric data in robot-assisted total laparoscopic hysterectomies (rTLH) and laparoscopic supracervical hysterectomy with cervicosarcopexy as part of the SOS trial. Comparison of the individual surgical steps in experienced surgeons and beginners.

Results

The study analysed 49 cases. Difference in the length of the individual tasks between beginners and experts are apparent. There are obvious differences in the use of clutches, current application and camera movement. A learning curve with improvement of the individual surgical steps can be shown visually.

Conclusions

Using IDR, surgeries of individual surgeons can be analysed and compared with those of other surgeons. Learning curves can be visually displayed.

ES32-0435 - Adenomyosis

Clinical characteristics of women in reproductive age suffering from histologically proved adenomyosis: a single centre retrospective cohort of 498 cases

Marie Timmermans¹, Katty Delbecque², Laurent de Landsheere¹, François Closos¹, Stavros Karampelas³, Michelle Nisolle¹

¹CHU of Liege, Obstetrics and Gynecology - site Citadelle, Liege, Belgium

²CHU of Liege, Pathology, Liege, Belgium

³CHU Brugmann, Obstetrics and Gynecology, Brussels, Belgium

Background

To characterize the population of women in reproductive age who benefit from a hysterectomy in terms of adenomyosis and endometriosis.

Methods

A retrospective single centre study was performed on patients of reproductive age (≤ 45 years-old) who underwent hysterectomy for benign reasons between 2016 and 2022 in the Obstetrics and Gynecology Department at Liege University Hospital - Citadelle. Clinical data were collected from pathology and medical reports.

Results

A cohort of 498 patients, mostly Caucasian (73%), underwent a hysterectomy, at a mean age of 41 years (range 21- 45). Main surgical indications were chronic pelvic pain (CPP) (134/498, 27%), abnormal uterine bleeding (AUB) (172/498, 35%) or a combination of both symptoms (164/498, 33%). At the preoperative assessment, 171 (34%) of them presented endometriosis. Transvaginal ultrasound was performed in 351 cases and adenomyosis was accurately diagnosed in 66% of these patients. At the histological analysis, adenomyosis was found in 80% (401) of cases.

When we compared the population with histologically proved adenomyosis with the one without adenomyosis, we noticed that the presence of both concomitant AUB and CPP symptoms is more often expressed by women suffering from adenomyosis (respectively 141/401, 35% vs 23/97, 24%; $p < 0.05$). Moreover, the sensitivity of ultrasound was higher for adenomyosis when both symptoms were present compared to when the patients suffered from CPP only (respectively 83/111, 75% vs 43/73, 59%; $p < 0.05$). Patients with a diagnosis of endometriosis, pre- or post-operatively, presented more often adenomyosis than the others (147/171, 86 %). Focal Adenomyosis of the Outer Myometrium (FAOM) is more often found in patients with endometriosis (27/147, 18%, vs 10/254, 4%; $p < 0.05$). Adenomyoma was found histologically in older women (42.4 vs 41.0 years, $p < 0.05$). We did not notice any significant link between older age and a deeper invasion of the adenomyosis into the myometrium ($p = 0.08$).

Conclusions

Women at reproductive age suffering from concomitant symptoms of chronic pelvic pain and AUB have a high probability of presenting adenomyosis. Moreover, endometriosis increases the risk of presence of concomitant adenomyosis.

**ES32-0282 -
Adhesions**

4Synless – comparison of effectiveness of 4DryField vs. Hyalobarrier gel for prevention of relapse of Asherman’s syndrome: feasibility study

Zdenka Lisa¹, Michal Mara¹, Kristyna Hlinecka¹, David Kuzel¹, Adela Richtarova¹, Michael Fanta¹

*¹General Faculty Hospital and 1st Medical Faculty of Charles University in Prague,
Center for gynecology endoscopy- Department of Obstetrics and Gynecology, Prague, Czech Republic*

Background

4Synless is single-site, single blinded randomized controlled feasibility study. The aim is to present innovative use of 4DryField® PH (premix) in prevention of recurrence of intrauterine adhesions in patients with Asherman’s syndrome (AS) after hysteroscopic adhesiolysis.

Methods

Twenty-three patients with moderate or severe AS were eligible for the study and randomized into two groups with randomization ratio 1:1. 4DryField® PH were applicated in group A (n=10), Hyalobarrier® gel in group B (n=10). Three patients were excluded. We evaluated intrauterine adhesions (primary AFS score) by the first hysteroscopy and then by the second-look hysteroscopy (secondary AFS score) one month apart and calculated the AFS progress. In addition, parameters such as secondary capacity of uterine cavity, need for secondary adhesiolysis and final uterine cavity capacity were determined. We followed-up the patients for three months and compared both groups as follows: restored menstrual pattern, complications, number of achieved conceptions after treatment.

Results

Both groups were comparable in demographic and anamnestic data as well as in severity of IUAs. The mean of primary AFS scores was 9 in group A vs. 8,5 in group B, $p = .476$. There were no between groups difference in AFS progress (5,9 vs. 5,6, $p = .675$) and need for secondary adhesiolysis (7 vs. 7, $p = 1$). If we compare both groups with respect to severity of disease, the expected AFS progress is 0,38 lower in group B than in group A ($p = .675$, CI 95% (-1,50;2,26)). The expected value of AFS progress was 1,9 higher in patients with severe IUAs than patients with moderate IUAs ($p = .06$, CI 95% (-0,15;3,65)). In both groups, we managed to regain 100% restoration of uterine cavity capacity in 70% of patients. There was no subject with final uterine cavity capacity less than 90%. We did not observe significant between-group differences in the follow-up period.

Conclusions

Our findings indicate that 4DryField® PH (premix) could be a promising antiadhesive agent in prevention of relapse of AS. 4DryField® PH seemed as effective as Hyalobarrier® gel. Furthermore, our results suggested that 4DryField® PH might be a prospective option in patients with severe IUAs. We did not record any adverse events. However, there is a need for prospective validation high-number participants trials.

Asherman syndrome in low socio-economic settings for a reproductive age group

Shrikant Ohri¹

¹*NewLife Hospital, gynaecological laparoscopic surgeon, Varanasi, India*

Background

This study was done to evaluate prevalence, assess risk factors and surgical management by hysteroscopy and reproductive outcome obtained in infertile patients diagnosed with Asherman syndrome in a low socio-economic setting.

Methods

It is a prospective study performed on patients age 21 to 40 years who visited with infertility and were diagnosed with Asherman's syndrome for a period of 4 years at NewLifeHospital, Varanasi, UP, India.

3D USG was the investigation of choice, hysteroscopic adhesiolysis with scissors was done in all till both the ostia were seen in a line or reddish myometrium was visualized.

Results

A total of 194 out of 1240 patients with infertility had Asherman syndrome with a prevalence of 15%

The most common complains were pain (10%) and menstrual abnormalities 108(56%), hypomenorrhea was 117(60%). repeated pregnancy loss (10%) and pregnancy complications(8%) and no symptom(10%) were the other common presenting complains.

Patients of primary infertile were 80 (41%) rest were of secondary infertility.

History of miscarriage without curettage was in 15(7%) and miscarriage with curettage in 55(28%) cases, 13(6%) females had history of operative hysteroscopy for a different cause and 3 had history of laparoscopic myomectomy. 71(37%) patients had no previous significant history. Other causes were abnormal placentation, genital tuberculosis and compression sutures for obstetrics haemorrhage.

All underwent hysteroscopic adhesiolysis with scissors or bipolar current under normal saline.

Adhesions were classified into mild, moderate, or severe according to the MEC classification.

35(18%) had severe Asherman, 118(61%) had moderate and 41(21%) were mild Asherman.

Re adhesion preventive measures (Pediatric foleys, hormone, hyaluronic acid gel) were taken in all even after 2nd or 3rdrelook surgery.

relook surgery was performed in 60 (30%) patients and 3rdsurgery was done in 19 patients, total surgery performed was 273. Mean operative time was 17 mins.

Post-surgery spontaneous pregnancy was obtained in 59(30%), by ART in 31(16%), failed ART 19(10%) with a total pregnancy of 90(46%) and term delivery in 58 patients.

Hypomenorrhea was cured in 80(71%) And amenorrhea in 22(49%) cured.

Conclusions

Choosing patients of Asherman from the infertility group by 3D USG the prevalence of the disease in infertility was established as 15%. We tried to create a comprehensive summary of problems related the condition and its treatment modality and outcome of it

The management of moderate to severe disease is still a challenge, and the prognosis of severe disease remains poor. Close antenatal surveillance and monitoring are necessary for women who conceive after treatment.

**ES32-0165 -
Endometriosis 3 | Early Diagnosis**

Prediction of MRI diagnosis on MRI – an external validation study

Cynthia Klaassen¹, Connie Rees^{1,2,3}, Marloes van de Wiel¹, Joost Nederend⁴, Huib van Vliet^{1,2}, Dick Schoot^{1,2,5}

¹Catharina Hospital, Gynaecology and Obstetrics, Eindhoven, The Netherlands

²Ghent University Hospital, Reproductive Medicine, Ghent, Belgium

³Ghent University Hospital, Reproductive Medicine, Ghent, The Netherlands

⁴Catharina Hospital, Radiology, Eindhoven, The Netherlands

⁵Eindhoven University of Technology, Electrical Engineering, Eindhoven, The Netherlands

Background

Non-invasive diagnosis of adenomyosis remains challenging as there is still no consensus on diagnostic criteria on MRI. This indicates a current need for a non-invasive diagnostic tool. This study aims to externally validate a previously developed prediction model to predict likelihood of histopathological adenomyosis diagnosis based on MRI and clinical parameters.

Methods

In this single centre retrospective cohort study, we aimed to externally validate a multivariate prediction model for histological adenomyosis diagnosis based on MRI and clinical parameters. The study was conducted in a non-academic teaching hospital in Enschede, the Netherlands. 195 patients who underwent an MRI prior to hysterectomy for benign pathology in the participating centre between 2014 and 2022 were included.

The MRIs were retrospectively assessed for adenomyosis markers. The developed model was applied to the patients in this external dataset. The prediction model utilised several clinical factors and MRI factors such as mean junctional zone (JZ) thickness, JZdiff>5mm, JZ/myometrium ratio >0.40, and presence of high signal intensity (HSI) foci. The predictive performance of the model was assessed using the receiver operating characteristic (ROC) curve analysis and its calibration and discrimination were evaluated.

Results

Out of 195 patients, 78 patients (40%) received a diagnosis of adenomyosis based on histopathology. The previously developed model showed good external validity in this population with an Area Under the Curve (AUC) of 0.831 (95%CI 0.761 – 0.901). As for calibration, the Hosmer-Lemeshow test did not show significant difference between the predicted and observed outcome (chi-square 4.398, p = 0.820).

Conclusions

The developed model showed good to excellent discriminative performance in this external cohort in predicting the adenomyosis diagnosis based on MRI in individual patients. Given the model's accurate performance after external validation, its implementation in daily clinical practice could be considered.

**ES32-0463 -
Fibroids 2**

A prospective randomized controlled study of the advantages of barbed suturing in laparoscopic myomectomy compared to conventional suturing

Eirini Angelidou¹, Savas Papageorgiou¹

¹*Euromedica General Clinic of Dodecanese Rhodes Greece, Gynecological Department, Rhodes, Greece*

Background

The goal of laparoscopic myomectomy is to reduce blood loss, operating time and to secure a safe suturing of the uterus walls to avoid reoperations and uterus rupture and to improve fertility.

Methods

Of the 200 patients with myomas enrolled in this study 100 were prospectively randomized to the conventionally suturing group with Vicryl 1/0 (group A) and the 100 others to the group of the V- Loc 180 (Covidien ®) suturing (Group B). To avoid variations in surgical proficiency the two laparoscopic surgeons of the clinic operated all the cases together. Age, gravidity, parity, Body Mass Index, history of previous abdominal surgery, including caesarean section, maximal diameter, and type of myomas, number and weight of removed myomas were obtained. The two groups were evaluated for Total operating time from skin incision to closure (TOT), blood loss (BL), need for blood transfusion, need for laparotomic inversion, reoperation for bleeding, length of hospital stays, any complication related to myomectomy and fertility rates and uterus rupture during pregnancy. All statistical analyses were conducted using SPSS Statistics, version 25.0 (IMB Corp. Armonk, NY USA). P values <0,05 were considered statistically significant.

Results

The number of myomas, the maximal myoma diameter and the history of abdominal surgery affected the TOT and BL statistically significantly. The multivariate analysis showed that the use of barbed sutures was an independent factor for lower TOT, less BL and less intraoperative and postoperative complications of laparoscopic myomectomy. 102 patients experienced at least one postoperative pregnancy, with no differences between the groups (group A 50%, group B 56%). Of the 130 recorded postoperative pregnancies, 90 (69.23%) resulted in live births, 40 (30,76%) in first-trimester miscarriages. No uterus rupture during pregnancy was reported in the two groups.

Conclusions

Barbed sutures have a similar impact on reproductive outcomes as conventional sutures, both in terms of pregnancy and obstetric complication rates. However, the barbed sutures group was related to lower TOT, less BL and less intraoperative and postoperative complications of laparoscopic myomectomy.

**ES32-0533 -
Hysteroscopy**

Endometrial wound healing duration after hysteroscopic treatment of submucous myomas, type 1, 2 and 3

*Raffaella Del Papato¹, Alfonso Manzi², Sabrina Reppuccia², Alessandra Gallo², Brunella Zizolfi²,
Maria Chiara De Angelis²*

¹University of Bari,

Department of Biomedical Sciences and Human Oncology- Section of Gynecology and Obstetrics, Bari, Italy

²University of Naples Federico II, Department of Public Health, Naples, Italy

Background

To assess the mean resolution time of the fovea after hysteroscopic treatment of Type 1, 2 and 3 submucous myomas

Methods

A prospective observational study was conducted at the Department of Obstetrics and Gynecology of University Federico II, Naples, Italy. Women with at least one Type 1, 2 or 3 myoma, history of infertility and/or uterine bleeding were included. All patients have been submitted to hysteroscopic myomectomy, using a 15 Fr or 26 Fr resectoscope, either outpatient or in the operating room. All surgical procedures were performed by one expert hysteroscopist. Cold loop myomectomy applied to bipolar resectoscope was used for the removal of the intramural component of the myomas. A follow-up office hysteroscopy was performed every two weeks until the complete resolution of the fovea was observed.

Results

Thirty-one patients were enrolled. The mean age was 42 years old, ranging from 29 to 54 years. 27/31 patients (87.0%) had just one myoma, while 4/31 (12.9%) had two myomas or more. Totally 37 myomas were studied, including type 1 (n= 9/37, 24.3%), Type 2 (n=21/37, 56.7%) and type 3 (n=7/37, 18.9%). The average of resolution days was of 55 days for Type 3 myoma, 23.5 days for Type 2 and 14.5 days for Type 1. The main size of myomas was 2,3 cm (ranging from 0.5 cm to 4 cm). 2/37 myomas (5.4%) measured 1 cm or less and 35/37 (94.5%) were over the centimetre. The main resolution time of the fovea for myomas whose dimension was 1 cm or less was 14 days, while that one of bigger myomas was 31,3 days. Just 6/31 patients (19,3%) underwent a pharmacological therapy with P, EP or combined therapy (Relugolix, estradiol, norethisterone acetate) and the main resolution time of these ones was 29,5 days; 25/31 patients, instead, did not do any additional medical therapy, having a resolution time of fovea of 30,6 days. People whose age was 40 or more had a time of resolution of 31,6 days, that one of younger women was 27,2 days.

Conclusions

these preliminary data show short time to resolution of the fovea for all type 1, 2 and 3 submucous myomas. Time to resolution seemed to be inversely proportional to the intracavitary percentage of myoma. Bigger or equal to one cm myomas had a faster resolution time. Additional medical therapy seemed to cause a slight reduction of resolution time. There was no correlation between the resolution time and: patient's age, different localization of myomas. The respect of the myometrium and the reduced thermal injury obtained thanks to the cold loop technique applied to bipolar resectoscope, may have influenced the resolution time of the fovea. Further studies are needed.

**ES32-0281 -
Oncology 2**

To use or not to use? The uterine manipulator for the surgical treatment of early-stage, low-grade endometrial carcinoma

Julienne Janse¹, Yexin Ye², Maite Timmermans¹, Saskia le Cessie³, Kees Gerestein²

¹LUMC, Gynaecology, Leiden, The Netherlands

²UMCU, Gynaecology and Oncology, Utrecht, The Netherlands

³LUMC, Department of Clinical Epidemiology - Department of Medical Statistics and Bioinformatics, Leiden, The Netherlands

Background

The primary treatment for early-stage, low-grade endometrial cancer (EEC) is a total laparoscopic hysterectomy (TLH) with bilateral salpingo-oophorectomy. During this procedure, uterine manipulators are commonly used. Especially those manipulators with intrauterine (IU) tip provide the added advantage of optimal uterine mobilisation and enhanced exposure of the surgical field. However, the use of uterine devices for malignant diseases has been subject to controversy and possibly worse oncological prognosis.

Methods

This retrospective, nationwide, multicentre, comparative effectiveness study assessed the influence of different treatment strategies regarding uterine manipulator type, with or without IU tip, on the oncological outcome in a large cohort of EEC patients. All patients with EEC who underwent a TLH between 01-01-2010 and 31-12-2020 within the Netherlands were included. Inclusion criteria were: i) histologically confirmed grade 1 or 2 EEC; ii) disease stage I; and iii) surgery performed by laparoscopic and robotic-assisted laparoscopic hysterectomy. Exclusion criteria were: i) patients younger than 18 years; ii) patients with concurrent adnexal malignancy; and iii) patients with missing histopathology report. Eligible patients were categorised based on manipulator preference of the hospital at which they received surgery (the instrumental variable). Patients were identified from the Netherlands Cancer Registry (NCR), which is a population-based registry with coverage of all newly diagnosed malignancies in the Netherlands. National medical centres (n = 62) were contacted to retrieve data regarding centre TLH strategy (i.e., uterine manipulator with or without IU tip) between 2010 and 2020 by means of an online questionnaire. The primary outcome measures were recurrence, recurrence-free survival, and overall survival. Recurrence was defined as histologically confirmed recurrence during follow-up. An instrumental variable analysis, based on the preference for using manipulators with and without IU tip, will be performed.

Results

A total of 5815 patients were identified with early-stage, low-grade EEC who had undergone TLH between 01-01-2010 and 31-12-2020 in the Netherlands. Mean age at onset was 66 years. Regarding the clinical stage, 3993 patients (68.7%) had a stage IA according to FIGO 2009; 1822 (31.3%) stage IB. Of all patients, 4586 (78.9%) were diagnosed with a grade I tumour, 1229 (21.1) with a grade II. In total, 224 recurrences were found (3.9%). The results of the instrumental variable analyses based on type of manipulator will be presented during the conference.

Conclusions

This comprehensive, nationwide study in the Netherlands will shed light on the possible influence of the use of a manipulator with IU tip during TLH in women with early-stage, low-grade endometrial cancer on the oncological prognosis.

**ES32-0136 -
Reproductive Surgery 2 | Fertility Preservation**

Reproductive and obstetric outcomes after removal of retained products of conception: hysteroscopic removal versus ultrasound-guided electric vacuum aspiration

Wouter Van Vugt¹, Liselot Wagenaar¹, Huib van Vliet¹

¹*Catharina Hospital, Department of Obstetrics and Gynecology, Eindhoven, The Netherlands*

Background

Traditionally, curettage is the most widely performed surgical intervention used to remove retained product of conception. However, hysteroscopic removal is increasingly performed as an alternative due to the potentially lower risk of intrauterine adhesions, possibly leading to better reproductive and obstetric outcomes of a subsequent pregnancy. Currently, no randomized controlled clinical trials have been performed that compare curettage with hysteroscopic removal with regards to reproductive and obstetric outcomes.

The aim of this study is to study reproductive and obstetric outcomes of the first subsequent pregnancy in women treated for retained products of conception by either hysteroscopic removal or ultrasound-guided electric vacuum aspiration.

Methods

This is a prospective long-term follow-up study, conducted in three teaching hospitals and one university hospital. Patients were included from April 2015 until June 2022 for follow-up; either in a randomized controlled, non-blinded trial (n=173) on the risk of intrauterine adhesions after removal of retained products of conception or in a cohort alongside the trial (n=176). Adult women were eligible to participate if ultrasonographic imaging was suggestive for RPOC ranging from 1 to 4 cm. Surgical procedures used in the cohort were the hysteroscopic techniques of hysteroscopic morcellation and cold loop resection, as well as ultrasound-guided electric vacuum aspiration, while in the randomized controlled trial group only hysteroscopic morcellation and ultrasound-guided electric vacuum curettage were performed. Follow-up was performed between October and December 2022 by using a standardized case report form. In the case of normally distributed continuous variables, means, standard deviations, and 95% confidence intervals were reported, with mean differences being analysed using the unpaired t-test. For non-symmetrically distributed continuous variables, median and interquartile ranges were described, with analysis performed using the Mann-Whitney *U* test. Categorical data were presented as frequencies and percentages and analysed by χ^2 or Fisher's exact test.

Results

Subsequent live birth rate was 76.8% (63/82) in the hysteroscopic removal-group and 76.0% (38/50) in the ultrasound-guided electric vacuum aspiration-group ($p=.931$). The median time to pregnancy was 9.1 weeks (IQR, 5.8–14.7 weeks) for the hysteroscopic removal-group and 8.1 weeks (IQR, 5.7–17.8 weeks) for the ultrasound-guided vacuum aspiration-group ($p=.902$). Complications during pregnancy such as placental complications and recurrent RPOC occurred in 27.5% (22/80) in the hysteroscopic removal-group and 24.5% (13/53) in the ultrasound-guided vacuum aspiration-group ($p=.703$).

Conclusions

Hysteroscopic removal and ultrasound-guided electric vacuum aspiration of retained products of conception seem to have no significantly different effects on subsequent live birth rate, time to pregnancy and pregnancy complications.

How can we make robotic surgery sustainable

Frank Willem Jansen¹

¹*Leiden University Medical Center, Gynaecology, Leiden, The Netherlands*

Background

With the introduction of robotic surgery, a new era has opened for the minimally invasive surgery (MIS) approach. The initial force feedback, which played an essential role in tissue handling, turned out to be a relative concept. In addition, robotic surgery would provide better clinical outcomes due to better suturing, better visualization and help with difficult surgical procedures. For example, several studies showed that there was a significant improvement in clinical outcomes. However, many studies that have shown statistical significance are clinically irrelevant. Recently additional new studies tout the ergonomic benefits for the surgeon. Unfortunately, with a climate crisis on our heels, the robot appears to have a large share in our CO₂ footprint compared to conventional MIS and open surgery. Reason to make an inventory of the hotspots of that pollution factor.

Methods

Literature was systematically analysed with regard to the CO₂ footprint. Life Cycle Analyzes (LCA) are measured and it is analysed where profit can be made to make robot surgery greener or more sustainable.

The robot surgery is also placed along the circularity ladder of sustainability, to see where gains can be made for users, industry and legislators.

Results

The literature shows that robotic surgery is a major energy consumer. The amount of waste produced is also significantly higher compared to the MIS approach or open surgeon.

The robotic approach to hysterectomy appears to be 6x less durable than vaginal hysterectomy.

From a systematic review (2456 abstracts: 16 studies with 5203 MIS procedures) comparing laparoscopy versus robot, there were the following findings: per case there is a production of 6-814 kg CO₂, the waste production is 0.25 -14.3 kg per case and the robot has a 43.5% higher Greenhouse emission and produces 24% more waste.¹

Conclusions

Our systematic literature search shows that both, the energy consumption, and the amount of waste produced (as a result of the use of disposables and covering materials) the robot has a larger CO₂ footprint compared to MIS and open surgery. This enormous increase in the environmental impact of robotic surgery does not sufficiently justify its assumed clinical added value.

Based on these findings, the following recommendations are made to both the user (surgeon) and the industry (engineer) and legislator (government) in line with circularity:

1. Set the correct indication to deploy the robot in surgery (Refuse)
2. Challenge the supplier, industry to make the robot more sustainable (Redesign, Reuse)
3. Ask the legislator to change the rules regarding disposables (Reuse)
4. User, pay attention to greenwashing phenomenon.

Reference:

1. Papadopoulou A, Kumar N, Vanhoestenbergh A, Francis N. Environmental sustainability in robotic and laparoscopic surgery: systematic review. *Br J Surg* 2022;109:921-932

**ES32-0675 -
Endometriosis 2 |Preservation of Fertility**

The microbiome endometriosis connection

Amira Quevedo¹, Paya Pasic²

¹University of Florida, Obstetrics and Gynecology, Gainesville, USA

²University of Louisville, Obstetrics and Gynecology, Louisville, USA

Background

Endometriosis is one of the most common women's health issues, affecting 1 in 10 women around the world. It is a chronic inflammatory condition involving endometrial-like glands at extrauterine sites with an enigmatic pathogenesis. It is characterized by crippling painful pelvic symptoms, infertility, and in severe cases kidney failure and bowel obstruction. It may be found in up to 87% of patients with chronic pelvic pain and 50% of patients with infertility. Early diagnosis is problematic given the lack of awareness, lack of non-invasive diagnostic tools, and lack of effective long-term treatments. Alarmingly, studies report a delay in the diagnosis of endometriosis of up to 10 years. Complicating management, uterine sparing surgery carries approximately 50% risk of repeat surgery at 5 years.

New studies have found that the microbiome of women with endometriosis is significantly altered. Specifically, stool, peritoneal, menstrual, and ovarian samples analysing bacterial 16sRNA composition has shown specific bacterial patterns in endometriosis patients. *Escherichia coli* bacteria carrying lipopolysaccharides, an endotoxin behind the strong immune response in septic shock, is found in menstrual fluid of women with endometriosis in four to six times greater quantities vs. controls. Lipopolysaccharides potently activate immune cells via toll like receptors in the peritoneal cavity as a result of reflux of menstrual fluid through the fallopian tubes.

Methods

Review

Results

n/a

Conclusions

In this video we will review the microbial influence on the pathogenesis of endometriosis and explore novel therapeutic targets that may guide alternative treatments in endometriosis.

<https://player.vimeo.com/video/844555618?autoplay=1>

Novel technique of laparoscopic rectus fascial sling insertion for urinary stress incontinence.

Abdalla Fayyad¹, Moath Hasan¹

¹Fayyad Urogynaecology and Laparoscopic Surgery Centre, Urogynaecology and Laparoscopic Surgery, Amman, Jordan

Background

Stress urinary incontinence is a common condition that has a significant impact on quality of life. The integral theory showed that defective mid urethral support and the resultant low urethral pressure are the main mechanisms behind stress urinary incontinence. Concerns have been raised about safety and long-term complications of vaginal mid urethral mesh tapes. There has been a resurgence in the native tissue surgical management of female stress urinary incontinence. Aldridge fascial sling was described almost eighty years ago through a laparotomy, and was associated with high rates of voiding dysfunction post operatively. More recently, the concept of a sling on a string was introduced using a laparotomy. The ends of the strings are sutured to the rectus fascia. In this video, a novel technique of laparoscopic mid urethral fascial sling insertion using abdominal rectus fascia is shown in managing stress incontinence.

Methods

Women with urodynamic stress urinary incontinence consented to this new procedure. Under general anaesthesia, and after urinary catheterisation, a 4 cm transverse lower abdominal incision is made, and a strip of rectus fascia is harvested measuring 6x2 cm. A sling on a string is then formed using 2/0 Ethibond sutured to both ends of the sling. A vaginal incision is made 1.5 cm from the external urethral meatus. Para urethral tunnels are then created. After routine laparoscopic entry with three ports, the retropubic space is opened and the bladder dissected free. The endopelvic fascia is then perforated under laparoscopic vision either side of the urethra. The Ethibond sutures on the end of the sling are retrieved laparoscopically and sutured to the Coopers ligaments after tension free adjustment of the sling under the mid urethra. The vaginal skin is then closed with interrupted absorbable sutures and check cystoscopy performed.

Results

The procedure was successfully completed in all cases. The duration of the procedure ranged from 90 to 150 minutes. The average blood loss was 100 ml. All subjects resumed normal voiding after urinary catheter removal after 24 hours. All subjects were discharged home after 24 hours. At three months follow up, all subjects reported cure of the stress urinary incontinence with normal voiding.

Conclusions

To our knowledge, this is the first description of laparoscopic rectus fascial sling insertion under the mid urethra to treat female stress urinary incontinence. We demonstrated the feasibility and safety of the technique. The advantages of this technique include the small incision in the lower abdomen, introduction of the sutures under vision, which avoids the complication of bladder perforation. This is particularly important in cases of previous surgery for urinary incontinence. Furthermore, fixation of the strings to the Coopers ligaments maintains the sutures original tension and avoids over tightening of the sling and voiding dysfunction.

<https://player.vimeo.com/video/811643847?autoplay=1>

FREE COMMUNICATIONS

ES32-0040 - Free Communication

Pregnancy Outcomes Following Abdominal Laparoscopic Surgeries During Pregnancy

Hadel Watad¹, Yonatan Patt¹, Aviran Ohayon¹, Yossi Bart¹, Raanan Meir¹, Shlomi B. Cohen¹

¹Sheba Medical Center, Obstetrics and Gynecology, Ramat Gan, Israel

Background

The aim of our study was to compare obstetric and neonatal outcomes of laparoscopic abdominal surgeries performed during pregnancy according to trimester.

Methods

A retrospective cohort study between April 2011 and March 2020 at a single tertiary affiliated medical centre. All patients who underwent laparoscopic abdominal surgery during pregnancy and delivered at our hospital were included.

Results

A total of 191 women underwent laparoscopic surgery during pregnancy: 95 (50%), 82 (43%) and 14 (7%) at first, second and third trimester respectively. Baseline characteristics and obstetric history were comparable between groups. More patients underwent adnexal surgery at first and third trimester compared to mid trimester (62.1%, 50% and 41.5% respectively; $p=0.02$). There was increasing trend of using Hasson entry technique at second and third trimesters compared to first trimester (55.3%, 72.7% and 5.9% respectively; $p<0.001$). Conversion to laparotomy and post operative ileus rates were higher at third trimester, however rates of other intraoperative and postoperative complications were comparable. Pregnancy and neonatal outcomes were also comparable. Rate of preterm labor (PTL) was 15.7%, in multivariate regression analysis multifetal pregnancy (aOR 95% CI 16.6, 4.97-55.69) and adnexal surgery (aOR 95% CI 0.31 ,0.12-0.79) were independently associated with PTL.

Clinical presentation and surgical data

	First trimester (N=95)	Second trimester (N=82)	Third trimester (N=14)	P value
Presenting symptoms				
•Abdominal pain	92 (96.8)	68 (82.9)	14 (100.0)	0.002
•Fever	1 (1.1)	3 (3.7)	0	0.41
•Gastrointestinal	36 (37.9)	19 (23.2)	2 (14.3)	0.04
•Contractions	0	3 (3.7)	4 (28.6)	<0.001
•Infection/sepsis/peritonitis	2 (2.1)	1 (1.2)	1 (7.1)	0.36
Type of surgery				
•Adnexal	59 (62.1)	34 (41.5)	7 (50.0)	0.02
•Appendectomy	19 (20.0)	30 (36.6)	6 (42.9)	0.02
•Cholecystectomy	1 (1.1)	6 (7.3)	0	0.06
•Other	16 (16.8)	12 (14.6)	1 (7.1)	0.63
Entry technique				
•Hasson	5 (5.9)	42 (55.3)	8 (72.7)	<0.001
•Veress	80 (94.1)	34 (44.7)	3 (27.3)	<0.001

Surgical Complications

•Bleeding	0	1 (1.2)	0	0.51
•Adjacent tissue injury	1 (1.1)	1 (1.2)	0	0.92
•Conversion to laparotomy	1 (1.1)	3 (3.7)	2 (14.3)	0.03

Post-op complications

•Ileus	1 (1.1)	1 (1.2)	2 (14.3)	0.004
•Surgical site infection	1 (1.1)	1 (1.2)	1 (7.1)	0.22
•Re-laparotomy	0	1 (1.2)	0	0.51

Conclusions

Laparoscopic abdominal surgery during pregnancy is feasible and relatively safe regardless of pregnancy trimester. Hasson technique was more used during third trimester compared to first and second trimesters, and rates of conversion to laparotomy and post operative ileus were higher at third trimester compared to first and second trimesters. However, pregnancy outcomes following surgery were comparable between the three trimesters.

**ES32-0061 -
Free Communication**

Laparoscopic treatment of advanced interstitial pregnancy: the keys to success

Antonio Mercurio¹, Luigi Della Corte¹, Paolo Serafino¹, Maria Chiara De Angelis¹, Brunella Zizolfi¹, Pierluigi Giampaolino¹

¹University of Naples Federico II, Obstetrics and Gynecology, Naples, Italy

Background

Interstitial pregnancies are rare but compared with other localizations of ectopic pregnancy present a seven times higher risk of mortality.

This is due to their greater propensity to expand before rupture, leading often to a diagnostic delay, made only once catastrophic bleeding secondary to the rupture of highly vascularized structures has already begun.

In cases of advanced gestational age a conservative management is difficult to achieve and their treatment often result in wedge resection or hysterectomy by laparotomy.

Methods

Video case report with demonstration of key steps for the management of a rare subtype of ectopic pregnancy.

Three-dimensional ultrasound was mandatory to accurately localize the ectopic pregnancy. During surgery, to reduce intraoperative bleeding, the retro-peritoneum was opened and bulldog clamps were used to temporarily reduce uterine vascularization. An intramyometrial injection of vasopressin was performed. After a first cornuostomy attempt, we had to get on a cornual resection to achieve a complete removal of the ectopic mass. Multilayer uterine suture and anatomical restoration to prevent adhesion was then accomplished.

Results

The overall operation time was 55 minutes, and the estimated blood loss was 55cl. A successfully conservative treatment was achieved with no short-term complications. Postoperative ultrasound showed a normal uterus and complete regression of hCG was obtained two weeks after surgery.

Conclusions

Despite the dimension of the lesion, in our case, the tube was still intact, and patient was in stable clinical condition.

Although cornuostomy is a more conservative solution, in these cases cornual resection should be preferred.

Through the accomplishment of reproducible key steps, laparoscopic removal of interstitial pregnancy is a feasible method and can be proposed even for advanced cases of interstitial pregnancies.

<https://player.vimeo.com/video/824546147?autoplay=1>

**ES32-0081 -
Free Communication**

Development and description of the Okabayashi space during nerve sparing hysterectomy

Nikos Vlahos¹, Ioannis Blliatas¹, Stavroula Morfiri², Olga Triantafyllidou¹

¹University of Athens School of Medicine,

2nd Dept. of Obstetrics and Gynecology- Aretaieion University Hospital, Athens, Greece

Background

Development of the Okabayashi's space is required during nerve-sparing radical hysterectomy or in cases with deep endometriosis in order to preserve nerves. Dissection of Okabayashi's and Latzco's space is essential for identification and preservation of the hypogastric nerves. Latzco's space is defined: ventrally-cardinal ligament; dorsally- presacral fascia, ventrolateral aspect of the sacrum, laterally-internal iliac artery (hypogastric artery); medially-ureter, mesoureter. Whereas Okabayashi's space boundaries are ventrally-cardinal ligament; dorsally- presacral fascia, sacrum; laterally-ureter, mesoureter; medially-rectum or for others the uterosacral ligament for others. Here we present the method for laparoscopic development of the Okabayashi and the Latzco spaces and the identification of the hypogastric nerves on the right pararectal space in a patient undergoing laparoscopic surgical staging for endometrial cancer.

Methods

Access to the Okabayashi 's space is performed after entering the retro peritoneum on the right side by incising the peritoneum laterally to the IP ligament. Following the development of the para-rectal space the ureter is visualized attached to the medial leaf of the broad ligament. Careful detachment of the ureter from the medial leaf of the broad ligament with preservation of the meso-ureter allows for the formation of the Okabayashi's space medially and the Latzco's space laterally. The dividing border between these two spaces being the intact meso-ureter visualised in the video presented here. The hypogastric nerve travels in the same connective tissue plane defined by the ureter (meso-ureter), and is localized 2–3 cm dorsally to the ureter as presented in the video. The fibres of the hypogastric nerve can be easily identified from either side of the meso-ureter and these fibres may be preserved during nerve sparing procedures.

Results

Development of the Okabayashi's space is easy to perform by laparoscopy or laparotomy providing the certain surgical rules are observed and the refined anatomy is respected.

Conclusions

The development of the avascular spaces of the pelvis during gynaecological oncological procedures is necessary for the identification of the precise anatomy of the pelvis, allows for the improvement of the surgical technique, prevents unattended injury to adjacent organs and allows for the preservation of the nerves. In addition training new colleagues in the retro-peritoneal anatomy will increase their confidence decrease complication rates and improve their surgical performance even in simple cases.

<https://player.vimeo.com/video/824891130?autoplay=1>

Behavioural and contextual factors of gynaecologists and residents affecting sustainability in minimally invasive surgery. Is educational reform needed?

Kim Van Nieuwenhuizen¹, Ingena Both¹, Anne van der Eijk², Petra Porte³, Frank Willem Jansen¹

¹Leiden University Medical Center, Gynaecology, Leiden, The Netherlands

²Leiden University Medical Center, Operating Room Department, Leiden, The Netherlands

³Erasmus University, Health Policy & Management, Rotterdam, The Netherlands

Background

The healthcare sector is responsible for 7-8% of carbon emissions. As physicians pledge to 'do no harm' and promote health, reducing the healthcare sector's carbon footprint is essential. The operating room is particularly resource-intensive, using three to six times more energy than the rest of the hospital, making it a critical area for improvement. Surgeries have a significant environmental impact due to energy use, anaesthetic gases, and disposable medical equipment. Sustainable practices are necessary to mitigate environmental harm in healthcare. However, implementation of sustainable behaviour and sustainable strategies seem to fall behind. With this study we aim to explore the behavioural and contextual factors affecting sustainable behaviour and implementations in gynaecological minimally invasive surgery (MIS). Differences between gynaecologists and residents will be evaluated, which can provide valuable insights into residents' perspectives and education as they represent the future of the profession.

Methods

This study used a qualitative analysis of semi-structured interviews to determine sources of behavioural and contextual factors, facilitators and barriers regarding environmental sustainability in gynaecological surgery. In total, 16 semi-structured interviews were conducted (10 gynaecologists, 6 residents) until saturation of the data occurred. The interviews were transcribed, coded and analysed by thematic analysis. The results were interpreted using the Capability, Opportunity, Motivation-Behaviour (COM-B) model and a contextual framework.

Results

All participants possessed knowledge on sustainability but insufficient awareness to change practice in the hospital. Participants' motivation expressed in their personal lives was often untransferable to the hospital. This was due to barriers in the individual and surrounding context. Individually, insufficient knowledge and ease of use concerning certain medical instruments led to common use of disposables. This was maintained by a lack of visibility of their climate impact. Regarding the internal system, participants mentioned time restraints, lack of initiatives and informal pathways as barriers. A lack of perceived availability for alternatives and financial incentives motivated use of disposables. Residents lacked information about sustainability during their education and were dependent on their supervisor's (instrument) choices. Their dependent position made sustainable initiatives harder to implement.

Conclusions

The lack of integration of sustainability into the professional responsibilities of gynaecologists and residents is a significant obstacle to its implementation. Addressing this issue requires interventions to change their professional standards on multiple levels. At the individual level: education, training, and increasing awareness of the impact of sustainability can be effective. On an organizational level: guidelines and job responsibilities can be updated to support sustainability initiatives. Gynaecologists should also allow residents the opportunity to explore their own preferences in the operating room. Furthermore, the internal procurement system can use its influence to promote sustainable alternatives, thereby affecting external availability. To successfully implement sustainability in MIS, it is essential to change professional standards by employing interventions at various levels.

**ES32-0097 -
Free Communication**

To validate the capability of AR in surgical training utilising objective & subjective assessment, health economics & systematic review (SR) of available literature.

David Rawaf¹, Mohamed Sheikh², Mohammed ElBahnasawi³, Courtney Ludick⁴, Matt Harris², Gurpreet Beghal²

¹NHS / Inovus Medical, Clinical Excellence, London, United Kingdom

²NHS, Surgery, London, United Kingdom

³NHS / Inovus, Surgery, Manchester, United Kingdom

⁴NTU, MSc, Dundee, United Kingdom

Background

To validate the capability of the LapAR through objective & subjective assessment and health economics analysis with a systematic review of literature.

Methods

Utilising a novel Augmented Reality (AR) high-fidelity laparoscopic simulator (LapAR¹), we performed scientific validations of the efficacy of the device objectively and subjectively. Furthermore, we performed a health economics study utilising the validation data to provide evidence of financial benefit to adopting this technology as a gold standard to laparoscopic surgical training. Finally, to cement this position, we performed an appropriate systematic review of the available evidence & various styles of training (AR vs VR vs traditional box vs cadaveric).

Results

Our pilot study focussed on benchmarking either two appendectomies or vaginal cuff closures with two rounds of appropriate LapPass² tasks (UK equivalent of FLS³) as an intervention period. Totalling under an hour for each junior trainee on the simulator, we found statistically significant 'completion time' savings of 19% and 36.9%, and 'distance travelled(m)' savings of 25% and 56.5% respectively following regression / ANOVA analyses. An in-progress multi-centre study (currently n=6), has shown, with similar statistical methods, that through 10 appendectomy benchmarks, with three rounds of LapPass equally interspersed over the course of two weeks, that 'completion time' can be reduced by 55-66% and 'distance travelled' by 39-72% when controlled for outliers.

A concurrent study looking at self-confidence scores pre & post-LapAR exercises on a day course indicated that all areas of trainee's self-confidence improved, with a mean improvement of 3.82 (likert, p=0.018). Interestingly, the more junior the trainee, the greater their increase in confidence. We also found statistically improved 'distance travelled' metrics when compared to cohort averages.

A BMJ peer-reviewed health economics review⁴ found that £79 could be saved per appendectomy patient at 10% translation of skills attained on the LapAR simulator. Once validation of the efficiency assumptions were made using the study data, we can extrapolate and realise a potential cost saving of up to £455 at 100% translation through reduced anaesthetic time and shorter inpatient stay.

Finally, an independent systematic review (n=26) of the available appropriate literature on the main four modalities (as above) was performed. We demonstrated that AR is preferred, improves procedural success & provides faster skill acquisition when compared to other modalities.

Conclusions

Effects of potential reduced complication rates, savings associated with being able to increase the number of patients on a list, the impact of patients returning to contributing to the economy, and faculty-led subjectivity were all not assessed as part of the studies.

However, we can now infer that AR-based laparoscopic training with the LapAR is not only preferred, but it is more effective at providing clinically translatable, and scalable cost-effective laparoscopic training as a potential new gold standard.

ES32-0401

Free Communication

A prospective observation cohort study of the risk of preterm birth in women with endometriosis

Elisabeth Bean¹, Nikolaos Thanatsis¹, Lucrezia De Braud¹, Jure Knez², Anna David¹, Davor Jurkovic¹

¹University College London Hospital, Women's Health, London, United Kingdom

²University Hospital Maribor, Gynaecology, Maribor, Slovenia

Background

Deep and/or ovarian endometriosis is present in approximately 5% of pregnant women. Emerging literature has suggested that women with endometriosis have an increased risk of adverse obstetric and neonatal outcomes. Our aim was to study obstetric and neonatal outcomes in women with endometriosis compared to those without, where all women underwent screening for the presence of endometriosis in pregnancy.

Methods

This was a prospective observational study of 503 women attending the Early Pregnancy Unit at UCLH between October 2017 and November 2019. The primary outcome was the risk of pre-term delivery <37+0 weeks' gestation. Secondary outcomes included risk of Caesarean section, placenta previa/accreta, antepartum/postpartum haemorrhage, gestational diabetes, blood pressure disorders of pregnancy, small for gestational age babies and neonatal unit admission.

Results

Endometriosis was diagnosed in 110/503 (21.9%, 95% CI 18.3 – 25.5) women. For 26/110 (23.6%, 95% CI 15.7 – 31.5) women with endometriosis, this was a new diagnosis made during pregnancy. 25/110 (22.7%, 95% CI 14.9 – 30.5) women had endometrioma alone, 42/110 (38.2%, 95% CI 29.1 – 47.3) women had deep nodules alone and 33/110 (30.0%, 95% CI 21.4 – 38.6) women had evidence of both endometrioma and deep nodules. The remaining 10/110 (9.1%, 95% CI 3.7 – 14.5) women had a background of surgical excision of endometriosis with no evidence of residual or recurrent endometriosis on their initial pregnancy scan. On univariate analysis, the presence of endometriosis was significantly associated with postpartum haemorrhage >500ml, delivery by Caesarean, hypertensive disorders of pregnancy and neonatal unit admission. Following multivariate logistic regression, adjusting for co-variables including age, gravidity, in vitro fertilisation conception, history of miscarriage, history of previous pelvic surgery and presence of concurrent uterine adenomyosis, only the increased risk of postpartum haemorrhage during Caesarean section remained significant (aOR 3.64 95% CI 2.07 – 6.35); P<0.001). There was no evidence of an increased risk of pre-term birth <37 weeks' (aOR 1.48, 95% CI 0.66 – 3.31; P=0.340).

Conclusions

The results of our study showed that women with endometriosis were at increased risk of postpartum haemorrhage during Caesarean section, but there was no association with any other antenatal or intra-partum complications. These findings support ESHRE guidance that women with endometriosis do not warrant increased antenatal monitoring and should not be dissuaded from becoming pregnant. There is no evidence to support routine antenatal screening of women for the presence of endometriosis.

Environmental sustainability in gynaecology: a systematic review

*Eva Cohen¹, Lisanne Kouwenberg², Niek Sperna Weiland³, Dionne Kringos², Anne Timmermans¹,
Wouter Hehenkamp¹*

¹*Amsterdam UMC, Dept. of Obstetrics and Gynaecology, Amsterdam, The Netherlands*

²*Amsterdam UMC, Dept. of Public and Occupational Health, Amsterdam, The Netherlands*

³*Amsterdam UMC, Dept. of Anaesthesiology, Amsterdam, The Netherlands*

Background

The healthcare sector is responsible for 4-10% of global greenhouse gas (GHG) emissions, a large part of these emissions originating from the operating rooms. Considering the broad range of surgical care that gynaecologists provide, mitigation strategies within this specialty could result in significant reductions of the environmental footprint across the whole healthcare industry. The aim of this review was to identify for what procedures within gynaecological care the environmental impact has been studied, to assess the magnitude of such impact and to identify mitigation strategies to diminish it.

Methods

The search strategy combined terms related to environmental impact, sustainability, climate change or carbon footprint, with the field of gynaecology. Articles reporting on the environmental impact of any service, procedure or product within the field of gynaecology were included. Included outcomes covered midpoint impact categories, CO₂-emissions, waste generation and energy consumption. A systematic literature search was conducted in the databases of MEDLINE (Ovid), Embase (Ovid) and Scopus, and a grey literature search was performed on Google Scholar and two websites of gynaecological associations.

Results

This review found that various operative gynaecological procedures, such as hysterectomies and endometrial cancer staging, have distinct environmental impacts dependent on the chosen surgical technique. Among the highest yielding mitigation strategies were displacing disposable with reusable materials, minimising content of surgical custom packs, improving energy efficiency within operating theatres and switching from anaesthetic gases to intravenous anaesthetics.

Conclusions

This systematic review highlights opportunities for gynaecologists to decrease their environmental footprint in the operating room in many ways. More high quality studies are needed to investigate the environmental impact of other aspects of women's and reproductive healthcare.

**ES32-0176 -
Free Communication**

Long-term outcomes after cervicovaginal reconstruction with small intestinal submucosa graft in congenital cervicovaginal atresia

Yan Ding¹, Xuyin Zhang¹, Ying Zhang¹, Fang Shen¹, Jingxin Ding¹, Keqin Hua¹

¹Obstetrics and Gynecology Hospital of Fudan University, Department of Gynecology, Shanghai, China

Background

To explore the long-term outcomes in patients with congenital cervicovaginal malformation after cervicovaginal reconstruction with an acellular porcine small intestinal submucosa (SIS) graft.

Methods

Thirty eight patients were included in the study from January 2012 to December 2019. Of these, twenty one patients underwent conventional laparoscopy, nine underwent robotic surgery, and eight underwent laparoendoscopic single-site (LESS) surgery. Clinical characteristics, perioperative data, condition of the neovagina and neocevis, body image, resumption of menstruation, sexual function, and quality of life were assessed.

Results

The average age was 16.4 ± 5.78 years. All surgery completed successfully. The cosmetic scores were significant higher in the LESS group ($P<0.001$). In the follow-up of 49.79 ± 31.02 months, all patients resumed menstruation except one patient underwent hysterectomy. The average length of neovagina was 8.11 ± 0.75 cm. There were one patient of vaginal stenosis, two patients of cervical occlusion, two patients of cervical stenosis, and six patients of IUD loss. Seven patients experienced sexual activity, with FSFI scores of 26.83 ± 3.49 . The scores of PCS and MCS were significantly lower in the first two years of follow-up ($P<0.001$).

Conclusions

Cervicovaginal reconstruction using an SIS graft in patients with congenital cervicovaginal atresia showed long-term good surgical outcomes and high quality of life.

**ES32-0183 -
Free Communication**

Structured patient feedback from 50 cases of vNOTES in Epsom and St Helier University Hospitals

Oudai Ali¹, Zini Mudiaga¹, Al-Rubaye hind¹, Abdullatif Elfituri¹, Jan Haider¹

¹Epsom and St Helier University Hospital NHS trust, Obstetrics and Gynaecology, London, United Kingdom

Background

Vnotes is an innovative surgical philosophy combining vaginal and laparoscopic approach and leaves no visible scars. It is important to seek patient's opinion and reflect on the outcomes. vNOTES Surgery has been established as regular service in Epsom and St Helier Trust since 2022. The procedure was mainly adopted in managing oncology cases vetted by the local and the regional cancer meetings. 100 cases of various complexity were performed within one year.

Patients were asked for their feedback on the procedure and encourage to contribute with suggestions to improve the care. This is an ongoing exercise but here is the results of the first 50 responses.

Methods

The vnotes cases were registered into a data base and a structured feedback questionnaires were agreed. Patients were contacted and they were asked about pain scores before the procedures and within immediate recovery, within 48 hours and on day 7 postoperative. They were also asked about the return to 90% and 100% return to function. Also there was questions about the side effects and their types, quality of the care, if the procedure worked and if they recommend it. The patients were contacted by a team different from the operating team and were blinded to the operative details and outcomes avoiding bias. Patients were contacted after 8 weeks from the procedure to allow enough time separation from the hospital experience.

Results

When asked if the procedure worked 49/50 replied yes and one case said she still had pain. With regard to side effects 7/50 had reported side effects including transient bowel, bladder symptoms and pain. In this series there was case with bladder injury repaired intraoperatively with a good recovery on later follow up. Preoperatively 9/50 had no pain and this increased to 17/50 on day7. 23/50 had mild pain preoperatively and remained stable in within 48 hours of the procedure and later 32/50 had mild pain on day7. Moderate pain was reported in 2/50 preoperatively then reported in 8/50 within 48 postoperatively then only in 2/50 on day7. There were two cases with severe pain preoperatively and there were no cases with severe pain postoperatively or on day7. 37/50 cases returned to 90% function 4 weeks and 45/50 returned to 100% function in 8 weeks. 2/50 cases did not recommend the procedure due to chronic pain and new bladder symptoms.

Conclusions

This standardised feedback has been integral to the governance of this novel technique and it was important to get it collected by an unbiased team. It demonstrated efficacy of the technique to achieve low pain scores and good satisfaction with low transient side effects. It also interesting to prove patient information about return function as most of the cohort returned to complete normal function within two months.

**ES32-0296 -
Free Communication**

Anatomical landmarks in laparoscopic sacrocolpopexy and TOT-like Burch colposuspension

Ana Kashia¹, Revaz Botchorishvili²

¹OB/GYN resident doctor, OB/GYN, Tbilisi, Georgia

²Estaing Clermont-Ferrand university hospital, Obstetrics and gynecology, Clermont-Ferrand, France

Background

Understanding and knowing anatomical landmarks is fundamental for successful and safe surgery. Especially for challenging surgeries, like Laparoscopic sacrocolpopexy with synthetic mesh and TOT-like Burch colposuspension, which are used to treat pelvic organ prolapse and stress urinary incontinence.

Methods

In this video, we demonstrate step-by-step key anatomical landmarks in laparoscopic sacrocolpopexy and TOT-like Burch colposuspension.

Results

Promontofixation

1. Opening of promontory region-anatomical landmarks: Promontory, aortic bifurcation, left common iliac vein, right common iliac artery, right ureter, posterior longitudinal ligament, and middle sacral vessels.
2. Pararectal dissection-Anatomical landmarks: Right hypogastric nerve, right ureter, rectosigmoid colon, right uterosacral ligament.
3. Recto-vaginal dissection- Anatomical landmarks: Rectum, uterus, right and left uterosacral ligaments, vagina, rectovaginal septum, perineal body, right and left puborectalis muscles.
4. Vesical-vaginal dissection- Anatomical landmarks: Uterus, bladder, vesical-uterine fold.
5. Fixation of the prothesis- the posterior mesh is attached to both puborectalis muscles and the posterior vaginal wall. The anterior mesh is attached to the lowest anterior vaginal wall. Another part of the posterior mesh is attached to the promontory.
6. Peritonization: Vesicouterine-rectovaginal peritonization, Lateral peritonization.

TOT-like Burch colposuspension:

1. Entry into the Retzius space- Anatomical landmarks: Median umbilical ligament, preperitoneal fatty tissue, umbilical vesical fascia.
2. Dissection of the Retzius space- Anatomical landmarks: Posterior part of the pubic symphysis, bladder, pubourethral ligaments, Cooper's ligament, obturator foramen, arcus tendinous fascia pelvis (ATFP), corona mortis, ischial spine, and sacrospinous ligament.
3. Dissection of the vagina- Anatomical landmarks: Urethra, vagina, ATFC, pubourethral ligaments, pubocervical fascia.
4. Suspension of the vagina-This modified type of suspension, involves the pubocervical fascia, the ATFP, and the Coopers ligament.
5. Closure of the peritoneum.

Conclusions

The video demonstrates the step-by-step procedures for both techniques, emphasizing the critical role of identifying and utilizing specific anatomical landmarks. Overall, the video article serves as a valuable resource for surgeons seeking to enhance their understanding and technical skills in performing these procedures.

<https://player.vimeo.com/video/826972631?autoplay=1>

Laparoscopic management of a recurrent interstitial ectopic pregnancy

*Aniello Foresta¹, Vincenzo Tarantino¹, Chiara Tersigni², Giovanni Panico², Francesco Fanfani²,
Giovanni Scambia²*

¹*Catholic University of the Sacred Heart, Department of Woman- Child and Public Health, Roma, Italy*

²*Fondazione Policlinico Universitario A. Gemelli IRCCS- Rome- Italy,
Department of Woman- Child and Public Health, Rome, Italy*

Background

Treating ectopic interstitial pregnancy is a difficult surgery since this region of the uterus is supplied by a rich vascular anastomosis between the uterine and ovarian vessels and uterine architecture must be respected to ensure fertility in these young patients

Methods

We report the case of a 38 years old patient tertigravida at 5 weeks + 6 days of amenorrhoea with a previous salpingectomy and suspicion of interstitial ectopic pregnancy. Transvaginal ultrasound showed decidualized endometrium and a single ectopic gestational sac of 25 mm of diameter in the interstitial tract of the remnant left tube, placed 5 mm outside the uterine cavity and surrounded by a continuous 1.5 mm rim of uterine serosa containing a single embryo with a crown-rump length of 14 mm. Considering the large size of the interstitial ectopic pregnancy, B-Hcg level and the high risk of rupture with subsequent severe hemorrhage, surgical management was judged the safest therapeutic approach.

Results

At laparoscopy, left interstitial pregnancy was confirmed with a mass of 4cm diameters in the left uterine cornual region with evidence of neovascularization and hemorrhagic tissue. Access to the retroperitoneum and identification of the left uterine artery was gained to be able to perform its ligation in case of bleeding. Cornual resection of the interstitial pregnancy was performed: the interstitial pregnancy and the surrounding uterine cornua were excised en bloc through a circumferential incision followed by suture closure of the myometrium with a single layer of vicryl. Intraoperative blood loss was less than 50mL. Postoperative recovery was uncomplicated, the patient was discharged three days after the procedure. Histology report later confirmed products of conception.

Conclusions

Interstitial pregnancy poses a significant diagnostic and therapeutic challenge. Fertility sparing minimally invasive management is feasible in experts' hands and should be considered as a first therapeutic option when dealing with this rare challenging condition.

<https://player.vimeo.com/video/826997539?autoplay=1>

Endometriosis, chronic endometritis and persistence of ureoplasma (parvum and urealyticum) in women with primary infertility

*Valentyna Sklyarova*¹, *Rostyslav Chajkivskyj*², *Taras Rozhansky*³

¹*Danylo Halytskyi National Medical University of Lviv, Family medicine, Lviv, Ukraine*

²*Danylo Halytskyi National Medical University of Lviv,*

Department of clinical pharmacy- pharmacotherapy and medical standardization, Lviv, Ukraine

³*Volyn Regional Oncology Centre, Department of gynecological oncology-, Luts'k-, Ukraine*

Background

Diagnosis and treatment of small forms of endometriosis and chronic endometritis (CE) in the structure of infertility is an urgent problem that is important for obtaining positive results and bearing healthy children.

The aim of this study was to examine women with primary infertility for *Ureoplasma* (parvum and urealyticum) infections and determine the presence of endometriosis and chronic endometritis.

Methods

The research took place at Yu. Lypy Lviv regional hospital of disabled people of war and repressed, where studies were conducted. Screening for *Ureoplasma* infections is not mandatory but is essential for effective examination of women with infertility. Due to protocol recommendations, all 174 patients with primary infertility were carefully examined. Our control group consisted of 160 healthy women, aged 18-36, who willingly underwent a prophylactic medical examination. *Ureoplasma* screenings, laparoscopy, and colposcopy were carried out to visually detect endometriosis in the patients. Furthermore, hysteroscopy, conventional histology, and immunohistochemistry were used to diagnose CE by identifying CD138 cells.

Results

When examining the data related to detecting the state of vaginal microbiocenosis in women with primary infertility, it is important to highlight the following findings: *Gardnerella vaginalis* was found at a notable frequency (3 times, CI=2.1-12.3, $\chi^2=8.7$, $p<0.01$, $r=0.22$); there was a significant increase in the growth of pathogenic *Escherichia coli* (2.7 times, CI=1.4-1.7, $\chi^2=5.5$, $p=0.02$, $r=0.18$); *Ureaplasma urealyticum* and parvum were also detected more frequently (1.7 times, CI=11.6-27, $\chi^2=5.2$, $p=0.02$, $r=0.18$); and lastly, the groups of nonspecific inflammatory infectious agents (*Proteus* sp, *Klebsiella* sp, *S. aureus*, *S. Agalactiae*) were observed to have a 2.9 times higher incidence (CI=2.1-12.3, $\chi^2=7.8$, $p<0.01$, $r=0.21$). In outpatient's department, cervical endometriosis and adenomyosis were found in 18.4% of patients with primary infertility, while in laparoscopy it was found in 43%. Among the 174 patients with primary infertility, 46% had CE, with 72% of them having a history of reproductive significant infections. In the control group, CE was found in only 4.3%.

Conclusions

Gardnerella vaginalis, a pathogenic growth of *Escherichia coli* and *Ureaplasma urealyticum*, as well as *Proteus* sp, *Klebsiella* sp, *S. aureus*, and *S. Agalactiae* can all contribute to the development of chronic endometritis, even after prior treatment. In the outpatient's department, cervical endometriosis and adenomyosis can be found in 18.4% of patients with primary infertility, while in laparoscopy it is found in 43% of cases. It is quite common for patients with infertility to also have chronic endometritis from previous nonspecific infection. We believe that retrograde spread of endometrial inflammatory tissues due to chronic endometritis can lead to the development of endometriosis.

**ES32-0363 -
Free Communication**

Laparoscopic treatment of isthmocele: a stepwise approach

Tiago Meneses Alves¹, Ana Beatriz de Almeida¹, Hélder Ferreira¹

*¹Centro Materno Infantil do Norte- Centro Hospitalar Universitário do Porto- Portugal,
Department of Gynecology and Obstetrics, Porto, Portugal*

Background

Isthmocele is not a rare finding in patients with a previous caesarean section and can be easily observed during transvaginal ultrasound examination as an indentation of the myometrium at the hysterotomy site with a depth of ≥ 2 mm. It is usually asymptomatic but symptoms can include intermittent abnormal bleeding, cyclic pelvic pain and infertility. To women with isthmocele-related complications and symptoms or desires future pregnancy a surgical treatment should be offered to restore normal uterine anatomy and it will depend on isthmocele's characteristics and surgeon expertise.

Methods

This surgical video described a stepwise approach of isthmocele correction with laparoscopy guided by hysteroscopy in a case of a secondary infertility with residual myometrium (RM) 2,8 mm diagnosed on transvaginal ultrasound.

Results

During the surgical intervention the caesarean scar was identified by transillumination and excision of the fibrotic tissue from its edges was realized. A subsequent double-layer closure using a monofilament absorbable suture was done followed by a ligamentopexy. No intra- and postoperative complications were observed.

Conclusions

The laparoscopic repair of a caesarean scar should be encouraged in symptomatic women and/or wish to conceive with RM < 3 mm.

<https://player.vimeo.com/video/827040453?autoplay=1>

Laparoscopic transabdominal cerclage in pregnant women after fertility sparing treatment for early stage cervical cancer: a safe and feasible procedure

Matteo Pavone^{1,2,3}, Nicolò Bizzarri⁴, Anna Fagotti⁴, Giovanni Scambia⁴, Denis Querleu⁴, Cherif Akladios⁵

¹Institute of Image-Guided Surgery- IHU Strasbourg- Strasbourg, ihu, Strasbourg, France

²Research Institute against Digestive Cancer IRCAD- University of Strasbourg, Ircad, Strasbourg, France

³Fondazione Policlinico Universitario A. Gemelli- IRCCS- Roma- Italy,

UOC Ginecologia Oncologica- Dipartimento per la salute della Donna e del Bambino e della Salute Pubblica, Rome, Italy

⁴Fondazione Policlinico Universitario A. Gemelli- IRCCS- Roma- Italy,,

UOC Ginecologia Oncologica- Dipartimento per la salute della Donna e del Bambino e della Salute Pubblica, Rome, Italy

⁵Université de Strasbourg, Department of Gynecologic Surgery- Hôpitaux Universitaires de Strasbourg, Strasbourg, France

Background

In recent years fertility sparing treatments are increasingly developing in patients with early-stage cervical cancer. At the same time a short residual cervix after conservative surgery appears to increase the risk of late abortion and preterm birth. When a vaginal cerclage is not technically feasible due to a short or scarred cervix, transabdominal cerclage could be offered before or after conception.

Methods

In this video we will show how it is possible to perform a post-conception laparoscopic abdominal cerclage in patients who have undergone fertility sparing surgery for early stage cervical cancer with insufficient residual cervix length for vaginal cerclage. The case is of a 34-year-old patient in the twelfth week of gestation underwent repeated conization for cervical cancer stage FIGO IA1 in 2021. She was referred for intractable cervical stenosis which required a subsequent vaginal tracheloplasty in 2022. She became pregnant 3 months later. Ultrasound monitoring of the cervix showed a suboptimal 15 mm cervical length.

Results

Pneumoperitoneum was obtained with Verress needle. The optic trocar was placed above the umbilicus. Two lateral and one mid-line laparoscopic trocars were introduced under vision. Dissection of the para-vesical space was performed bilaterally to expose the ureters and the branches of uterine artery. The bladder was then reflected. A window was created through the broad ligament lateral to the uterine vessels with access to the pouch of Douglas. A 3 mm monofilament polypropylene sling was introduced in the abdominal cavity. The sling was thus positioned from posterior to anterior through the broad ligament window on each side around the isthmus portion of the uterus. After checking the correct positioning, the sling was loosely tied anteriorly. The Doppler velocimetry of the uterine arteries at the end of the procedure was normal. The following day a uterine artery doppler confirmed normal flow bilaterally. A caesarean section was scheduled at 36 week of gestation with excellent obstetric and neonatal outcomes.

Conclusions

Laparoscopic transabdominal cerclage in pregnant women with shortened cervix after conservative procedures, although made more difficult due to the size of the uterus and the impossibility to mobilize it, is a safe and feasible procedure in expert hands combining the advantages of minimally invasive surgery with excellent obstetric result.

<https://player.vimeo.com/video/825382447?autoplay=1>

**ES32-0375 -
Free Communication**

Surgical neuropelveology: laparoscopic nerve resection for deep infiltrating sciatic nerve endometriosis

Mariano Catello Di Donna¹, Giuseppe Cucinella¹, Francesca De Maria², Rosa Anna Guiglia², Antonio Simone Laganà³, Vito Chiantera³

¹University of Palermo- 90133 Palermo- Italy,

Department of Surgical- Oncological and Oral Sciences Di.Chir.On.S., Palermo, Italy

²University of Palermo- 90133 Palermo- Italy, Gynecologic Oncology Department- ARNAS "Civico-Di Cristina-Benfratelli"- 90127 Palermo- Italy, Palermo, Italy

³University of Palermo- 90133 Palermo- Italy,

Department of Health Promotion- Mother and Child Care- Internal Medicine and Medical Specialties PROMISE - University of Palermo- 90133 Palermo- Italy, Palermo, Italy

Background

Deep infiltrating endometriosis of the sciatic nerve is uncommon and very often undiagnosed disease with a subsequent delayed treatment and symptoms exacerbation. The aggressive behaviour with nerve destruction leads to gait and neurological disorders. Surgical resection is the gold standard in case of sciatic endometriosis. Laparoscopic excision of the lesion is mandatory to completely remove the disease.

Methods

University tertiary referral centre. Surgical demonstration of a large laparoscopic resection for deep infiltrating sciatic nerve endometriosis. Video showing principles of laparoscopic neurolysis of the pelvic nerves in order to resect the endoneurial sciatic endometriosis nodule.

Results

45-year-old woman, with a referred pain due to a potential neuropathy since 2017, with a diagnostic delay of 4 years. At the neurological examination showed a cyclical sciatic pain associated with a gait difficulty and resultant foot drop. Magnetic resonance showed a 3 cm left endometriosis nodule with a clear process of axonal destruction of the first sacral root and of the lateral part of the intrapelvic sciatic. A laparoscopically assisted neuronavigation and subsequent neurolysis allowed the identification of the lateral nodule without damage to the autonomic pelvic innervation. Intrafascicular neurolysis of the sciatic nerve was necessary with a partial resection of the nerve removing the destroyed parts. Then the dissection of the different vascular branches permits good exposure of the distal part of the sciatic nerve close to the great sciatic foramen. The complete isolation of the nerves ensures a safe further dissection of the endometriosis infiltrating nodule.

Conclusions

Deep infiltrating endometriosis of the pelvic somatic nerves should be treated in referral centers by experienced surgeon in the field of «laparoscopic neuro-functional pelvic surgery». A wide Knowledge of the pelvic neuro-vascular anatomy as well as high surgical skills in the laparoscopic field are mandatory due to the high intraoperative risk.

<https://player.vimeo.com/video/827043454?autoplay=1>

**ES32-0464 -
Free Communication**

Ovarian transplantation after chemotherapy for breast cancer management in a young woman

Pierre Carvelli¹, Laurie Henry¹, Michelle Nisolle¹, Léna Pirson¹, François Closon¹
¹Citadelle- CHU Liège, Gynécology-Obstetrics, Liege, Belgium

Background

Preservation of fertility in cancerology is a challenge for young women who require immediate chemotherapy. Treatments are increasingly effective but can result in iatrogenic premature ovarian insufficiency (IPOI). Ovarian tissue cryopreservation (OTC) can restore hormonal cycles and fertility, but a substantial proportion of follicle reserve is lost because of the freezing process, exposure to hypoxia and probably tissue traumatism, manipulation, and suturing. Meta-analysis report 37% of pregnancy, 28% of live birth. Median duration of graft function is 2.5 years. A crucial concern is the risk of reimplanting malignant cells with the grafted tissue. The purpose of this video is to focus on surgical steps of ovarian transplantation (OT) after breast cancer treatment.

In this case, a breast cancer was diagnosed in a 30-year-old nulligravid patient.

Preservation of fertility by biopsy and freezing of ovarian tissue before chemotherapy was done in 2019. No cancerous cell observed on immunohistopathology.

Then neo-adjuvant chemotherapy (Four cures of taxol and twelve of xeloda), lumpectomy and radiotherapy were done during 2019-2020. Final staging: ypT1bN0, RE-, RP 5%, HER2+, P53 95%; 3+, no BRCA mutation.

In the first-hand secondary amenorrhea and several LH, FSH, E2 and Pg dosage reveal an IPOI. In the second hand a status of oncological remission and the absence of cancerous cells in ovarian biopsies allowed to perform the OT in 2023.

Methods

The procedure starts with the hysteroscopy and shows an atrophic uterine cavity.

Then the OT begins with a classic laparoscopy. Eleven millimetres suprapubic trocar is chosen to carry the grafts with forceps.

The grafts have been warmed up at the last moment and the transplant takes place within an hour.

Left ovary is opened without electrical energy. A new ovarian biopsy, histopathology is compatible with POI and exclude metastatic cell.

Orthotopic transplant is made on left ovary. 3 grafts are placed taking care to put the cortex outwards. Sub-peritoneal transplantation is performed with 4 grafts in the right ovarian fossa opened with a safe distance from the ureter, vascular and nerve structures.

Both sides, stabilisation of ovarian grafts is ensured by applying GYNECARE INTERCEED® (ETHICON Jhonson&Jhonson) and application of physiological fluids to fix it.

Results

The OT is technically a success. The Interceed® was useful and allowed a reduction of graft manipulation, especially no sutures were needed to fix the grafts to the ovary and in ovarian fossa.

We are expecting hormonal awaking, with hope of spontaneous pregnancy otherwise a medically assisted procreation procedure will be started.

Conclusions

OTC and transplantation may not only be effective in restoring fertility but also the return of endocrine function. Surgical details should improve the chances of success.

This video shows steps and issues of OT and the interest of Interceed® for graft stabilisation without suturing.

<https://player.vimeo.com/video/831111965?autoplay=1>

**ES32-0569 -
Free Communication**

The probability of continuing intermittent self-catheterization for de novo urinary retention after endometriosis surgery in relation to the postoperative week

Sari Boulus¹, Benjamin Merlot¹, Thomas Dennis Dennis¹, Horace Roman¹

¹IFEMEndo- Clinique Tivoli-Ducos, Gynecology, Bordeaux, France

Background

Deeply infiltrating endometriosis (DIE) can affect not only pelvic organs, but also pelvic nerves causing intestinal and urinary disorders, such as bladder voiding dysfunction. On the other hand, urinary dysfunction in patients with DIE can also occur as a result of disruption of the pelvic nerves and plexuses during surgery leading to transient or persistent self-catheterization, which is a well-known complication after radical surgeries for deep endometriosis.

Methods

This is a retrospective study based on data recorded in a large prospective database. Patients managed for endometriosis and discharged with the need of intermittent self-catheterization for de novo urinary retention after DIE surgery from March 2018 to June 2022 were included.

The aim of our study was to assess the probability of continuing intermittent self-catheterization in relation to the postoperative week and try to identify any risk factors that might affect the recovery process.

Results

A total of 61 patients were included in the study. 43 patients (70.5%) were able to stop the self-catheterization during the follow up period, while 18 (29.5%) were still under self-catheterization. The follow up period was variable with 223 weeks being the longest follow up period (for one patient). Forty eight patients (78.7%) had laparoscopy and 13 (21.3%) robotic assistance. During the first four postoperative weeks, fifteen patients were able to stop the self-catheterization and void the bladder normally, meaning that 75% of patients discharged with the need for self-catheterization had to continue beyond four weeks. The probability dropped to 46%, 41%, 28%, and 23% after 8, 12, 52, and 78 weeks respectively. Cox's multivariate model did not reveal any statistically significant independent predictor of a higher/lower probability.

Conclusions

Patients needing intermittent self-catheterization for de novo urinary retention after endometriosis surgery have a probability of 75% to continue for a period of more than one month postoperatively and 23% for more than 78 weeks postoperatively. No independent predictors of a higher probability were identified.

**ES32-0043 -
Free Communication**

Residents training in vaginal natural orifice transluminal endoscopic surgery (vNOTES)

*Aya Mohr-Sasson¹, Mason Hui¹, Alvaro Montealegre¹, Randa Jalloul¹, Olivia Dziadek¹, Asha Bhalwal¹
¹McGovern Medical School at The University of Texas Health Science Center,
Advanced Minimally Invasive Gynecologic Surgery, Houston, USA*

Background

As the vaginal natural orifice transluminal endoscopic surgery (vNOTES) is becoming a common acceptable approach to perform benign gynaecological surgeries there is need to incorporate it in resident's curriculum for surgical training. The aim of this study was to estimate the impact of hands-on lab simulation for vNOTES on residents' perception and confidence in this surgical approach.

Methods

This is a prospective observational study conducted at a single tertiary University affiliated medical center including 12 fourth year residents that were evaluated by 7 faculty attending surgeons between July to August 2022. All residents completed didactic online training of adnexectomy, and hysterectomy performed by vNOTES. Three hands on simulation labs were scheduled on a monthly base during the study period. Each resident performed both procedures on each encounter. Residents were evaluated by experienced surgeons in vNOTES approach. Survey evaluating the knowledge and confidence in the vNOTES approach was completed by the residents before and following all simulations.

Results

49 assessments were completed, of them 23 adnexectomies and 26 hysterectomies. Competence in adnexectomy and hysterectomy were achieved in 2/12 and 5/12 of the residents, respectively. Feedback was completed by 7 residents before and after the simulations. 33% increase in the confidence to perform anterior and posterior colpotomy was reported by the residents. 71% versus 85% reported confidence in transecting the uterosacral ligaments before and after the simulations, respectively. Confidence in transecting the uterine artery was found doubled (14% versus 28%) during vNOTES compared to laparoscopic approach following the simulation. 15% increase in the confidence to perform adnexectomy was noted following the simulation, however, 14% reduction was reported by the residents in choosing vNOTES approach for hysterectomy.

Conclusions

Hands-on simulation in vNOTES approach increases the knowledge and confidence of residents in the surgical steps of adnexectomy and hysterectomy.

**ES32-0147 -
Free Communication**

Anatomical landmarks of the avascular spaces of the pelvis: laparoscopic approach during hysterectomy

Morfiri Stavroula¹, Ioannis Billiatis¹, Kalliopi Kordopati-Zilou¹, Alexandros Petrolekas¹, Olga Triantafyllidou¹, Nikolaos Vlahos¹

¹Aretaieion University Hospital- National and Kapodistrian University of Athens- 2nd Dept. of Obstetrics and Gynecology- Athens- Greece, 2nd Dept. of Obstetrics and Gynecology, Athens, Greece

Background

Development of the pararectal and paravesical spaces of the female pelvis is mandatory while performing hysterectomy during gynaecologic oncological procedures . Knowledge of the anatomical landmarks is necessary. The paravesical space is defined: ventrally by the superior pubic ramus, dorsally by the cardinal ligament and uterine vessels, medially by the vesico-uterine ligament and bladder, and laterally by the obturator internus muscle and external iliac vessels. The obliterated umbilical artery divides this space into lateral and medial paravesical space. Pararectal space boundaries consist of: ventrally the cardinal ligament, dorsally the sacrum, laterally the internal iliac artery, medially the rectum, cranially the posterior leaf of the broad ligament, and caudally the levator ani muscle. The ureter divides the pararectal space into medial (Okabayashi's space) and lateral (Latzko's space) pararectal spaces. In this video we perform laparoscopic development of these spaces, during a hysterectomy in a patient diagnosed with endometrial cancer.

Methods

After dissection of the round ligament, entering the retroperitoneum laterally to the ip ligament, allows the visualization and development of the left ureter and the left uterine vessels. Development of the paravesical space continues while detaching the obliterated umbilical artery, which divides this space in lateral and medial. Careful detachment of the ureter cranially, while preserving the mesoureter, allows the development of the pararectal space.

Results

Laparoscopic identification of the anatomical landmarks of the avascular spaces of the pelvis is very important during oncological operations of the pelvis.

Conclusions

Knowledge of the anatomical landmarks of the avascular spaces of the pelvis is important, while it provides the identification and safe development of those spaces which is necessary in oncological procedures of the pelvis. Furthermore, education of the retroperitoneal anatomy is helpful for new surgeons, even while performing simple procedures.

<https://player.vimeo.com/video/826520835?autoplay=1>

**ES32-0156 -
Free Communication**

A guide to laparoscopic ureteral reconstruction for gynaecologists: techniques we learned from 100 cases

Masaaki Andou¹, Ochi Yoshifumi¹, Mari Sawada¹, Kiyoshi Kanno¹, Shintaro Sakate¹, Shiori Yanai¹
¹*Kurashiki Medical Center, Gynecology, Kurashiki-shi, Japan*

Background

This presentation will present techniques in a 'how to' style learned from over one hundred cases of experience of ureteral reconstruction from the viewpoint of gynaecologists. Through our experience we were able to hone skills and techniques to make ureteral reconstruction possible in same-session and post-operative-session gynaecologic surgery.

Methods

Detailed techniques description in this presentation of laparoscopic ureteral reconstruction will include simple ureteral reimplantation, psoas hitch and Boari flap techniques, as well as the interposition of an ileal graft. The cases presented will be cases with intraoperative ureteral injury, post-operative stenosis or fistula, ureteral endometriosis, and advanced or recurrent gynaecologic malignancy. Consent was gained to present and publish information on these cases on the condition of anonymity.

Extensive resection and ureteral injury repair require advanced and specialized skills such as intracorporeal suturing and knowledge of pelvic anatomy and how to reconstruct the urinary tract, even when extensive defects need compensating for. This includes knowing which techniques and combinations of techniques are best for the reconstruction.

This presentation will show steps to safe and genuine repair which have been developed as a result of dedicated training and experience. Graphic descriptions as well as surgical videos will illustrate the steps and skills involved in each repair technique.

Results

From January 2006 to April 2023, 104 cases have been performed with 103 cases successfully managed. The cases who underwent the interventions on this presentation were: 40 cases of intraoperative injury or post-operative stenosis or fistula, 7 cases of advanced or recurrent gynaecologic malignancy, and 57 cases of ureteral or bladder endometriosis.

No cases required blood transfusion or suffered ureteral stenosis. The single unsuccessful case suffered from simultaneous rectal and ureteral anastomosis, suffering ureteral anastomotic breakdown due to infection from the site of the rectal surgery.

Conclusions

With dedicated training, techniques can be implemented to advance the understanding and further facilitation of ureteral repair by gynaecologists. These techniques can allow for same-session and post-operative-session repair of ureteral injuries by gynaecologists, making patient care more efficient and patient-friendly. These techniques also allow for surgery of greater radicality to be performed minimally invasively.

**ES32-0238 -
Free Communication**

Laparoscopic hysterectomy for deep infiltrating endometriosis: retrograde hysterectomy technique

Nasuh Utku Doğan¹, Selen Dogan¹, Sefa Metehan Ceyhan¹, Fatma ceren Guner¹
¹Akdeniz University, Gynecology, Antalya, Turkey

Background

In symptomatic patients with deep infiltrating endometriosis, when fertility is of no concern, the ultimate goal is macroscopic clearance of all visible endometriotic tissue by using radical organ resections. When there is an involvement of Douglas along with rectosigmoid colon, hysterectomy should be started followed by anterior colpotomy and dissection of Douglas dissection by posterior colpotomy (retrograde hysterectomy). By this was, hysterectomy will be easier.

Methods

In this video, technique of laparoscopic retrograde hysterectomy was presented in a 44 year old multiparous woman with a previous surgeries for endometriosis.

Results

Along with hysterectomy, BSO, endometriotic nodul excision in sacrouterin ligament and rectal shaving were all performed. In this video, Douglas dissection after anterior colpotomy is presented. Total operation time was 195 minutes and blood loss was 75 cc. In postoperative third day, she was discharged.

Conclusions

Laparoscopic hysterectomy for deep infiltrating endometriosis becomes easier when certain surgical steps are followed and by this way complication rates decrease

<https://player.vimeo.com/video/826777005?autoplay=1>

**ES32-0260 -
Free Communication**

Laparoscopic pectopexy in 10 steps

Angelos Daniilidis¹, Georgios GRIGORIADIS², Dimitra Dalakoura²

¹Aristotle University of Thessaloniki,

1st Department of Obstetrics and Gynecology- Papageorgiou Genral Hospital, Thessaloniki, Greece

²Aristotle University of Thessaloniki,

2nd University Department of Obstetrics and Gynecology- Hippokration General Hospital, Thessaloniki, Greece

Background

Laparoscopic pectopexy is a surgical procedure that has gained popularity in the management of uterine prolapse. Our aim was to identify and describe 10 consecutive, easy to follow steps in order to safely perform a laparoscopic pectopexy.

Methods

Narrated video of a case of laparoscopic pectopexy we performed, presented in a stepwise approach, with clear description of each surgical step.

Results

We identify the following 10 surgical steps: 1. Division of Round Ligament and Extension of Dissection towards the Pelvic Sidewall 2. Identification of the Iliopectineal ligament. 3. Division of the uterovesical peritoneum and development of the vesicovaginal space. 4. Routine subtotal Hysterectomy 5. Opening of the rectovaginal space 6. Closure of the cervical canal 7. Insert the mesh and fix it with sutures on the cervix, anterior and posterior vagina. 8. Anchor the lateral arms of the mesh on the iliopectineal ligaments bilaterally. 9. Closure of the overlying peritoneum. 10. Morcellation of the uterine corpus. Our patient had minimal intra-operative blood loss, was discharged home on post-operative day 1 and made an uneventful recovery.

Conclusions

Laparoscopic pectopexy is a reproducible surgical technique for the management of uterine prolapse. Through knowledge of the pelvic anatomy, careful dissection and skilful laparoscopic suturing are mandatory for performing this technique safely.

ES32-0252 -
Free Communication

Adenomyosis: the impact of different type and localization on recurrent pregnancy loss (RPL)

Irene Colombi¹, Giuseppe Gabriele Iorio², Elena Vaquero³, Carlo Ticconi³, Giuseppe Rizzo⁴, Caterina Exacoustos³

¹*Obstetrics and Gynecological Clinic University of Siena,*

Department of Molecular and Developmental Medicine, Siena, Italy

²*University of Naples Federico II, Department of Public Health, Napoli, Italy*

³*Obstetrics and Gynecology of Unit- University of Rome Tor Vergata, Department of Surgical Sciences, Rome, Italy*

⁴*University of Rome Tor Vergata, Department of Biomedicine and Prevention, Rome, Italy*

Background

The main aim of this retrospective observational study was to investigate the correlation between RPL and type of adenomyosis in terms of focal or diffuse lesions, localization in the external or internal myometrium, and degree.

Methods

The Study group included women in reproductive age who were diagnosed with adenomyosis on transvaginal sonography (TVS) with RPL considering 2 or more consecutive miscarriages. Controls were matched 1:1 with cases by age and body mass index and included: Control group A, patients with RPL without TVS findings of adenomyosis; Control group B, patients with TVS diagnosis of adenomyosis without RPL and at least one pregnancy with live birth.

All patients underwent 2D, 3D and power Doppler TVS and those with RPL underwent screening tests for miscarriages. Medical and reproductive history was collected for each patient before and after the TVS examination for myometrium evaluation. Adenomyosis was defined if at least one direct TVS sign was seen (MUSA 2022) and classify according to our previous published classification system (Lazzeri 2018, Exacoustos 2020).

Results

Study and control groups consisted of 40 patients each. Patients in the study group displayed higher number of pregnancy losses (3(2-4) vs 2(2-3), $p=0.03$) and lower age at first miscarriage (31.82 ± 5.45 vs 34.1 ± 3.97 , $p=0.03$) compared to control group A. Study group showed higher incidence of fibroids (50% vs 13%, OR 7.0, $p<0.01$) but no statistically significant difference was found considering other risk factors for RPL. Comparing the characteristics of adenomyosis between the study group and the control group B, the former showed mainly focal lesions of the inner myometrium (23% vs 0%, $p<0.001$), while the latter showed more frequently focal adenomyosis of the outer myometrium (25% vs 8%, $p=0.03$). In addition, investigating the presence of endometriosis, we found a significantly higher presence of the disease in the control group B compared to the study group (78% vs 30%, $p<0.001$). In the control group B 67% conceived through in vitro fertilization (IVF).

Conclusions

Our results demonstrated that RPL is more often associated to adenomyosis of the inner myometrium, while adenomyosis of the outer myometrium is more frequently associated with live birth pregnancy. In patients with RPL adenomyosis should be closely investigated not only in presence of the disease but also regarding type and localization in the myometrial layers.

Bowel function after segmental bowel resection versus bowel shave for endometriosis: a national database study

Jonathan Lewin¹, Ertan Saridogan¹, Anton Emmanuel², Arvind Vashisht¹

¹University College London Hospital, Gynaecology, London, United Kingdom

²University College London Hospital, Gastroenterology, London, United Kingdom

Background

Segmental bowel resection is an option for the treatment of bowel endometriosis. However there are concerns regarding post-operative bowel dysfunction after bowel resection. The aim of this study was to compare bowel symptom change in patients undergoing bowel resection versus bowel shave for endometriosis.

Methods

Following approval from the British Society for Gynaecological Endoscopy (BSGE) scientific advisory group we obtained a download of the BSGE endometriosis centres database from 2012 to 2021. We only included patients who had rectal, rectosigmoid or rectovaginal endometriosis. We compared symptom severity (5-point Likert items) for all bowel function symptoms recorded (constipation, diarrhoea, tenesmus and faecal urgency) between treatment groups using mixed-effects ordinal regression with a random intercept for each patient and endometriosis centre, controlling for age, smoking, opioid use and BMI.

Results

A total of 5,596 patients with bowel endometriosis were included in analysis, of which 4,681 (83.6%) had a bowel shave, 10.3% had a bowel resection (152 disc, 424 segmental), and 339 (6.1%) had no treatment of their bowel endometriosis.

In the cohort as a whole, there was a 49% reduction in constipation severity (aOR 0.51, 95% CI 0.47-0.55, $p < .001$), 20% reduction in diarrhoea (aOR 0.80, 95% CI 0.74-0.86, $p < .001$), 45% reduction in tenesmus (aOR 0.55, 95% CI 0.51-0.59, $p < .001$), and 48% reduction in faecal urgency (aOR 0.52, 95% CI 0.48-0.56, $p < .001$) at 6 months versus baseline, and improvement remained significant at 2 years post-op for all four symptoms.

Pre-operative symptom scores were significantly worse in patients who had bowel resection compared to patients who had a bowel shave. However, compared with those undergoing bowel shave, patients who underwent bowel resection had 38% greater reduction in constipation severity at 6 months (aOR 0.62, 95% CI 0.47-0.82, $p = 0.001$), 31% greater reduction at 12 months (aOR 0.69, 95% CI 0.51-0.93, $p = 0.015$), and 38% greater reduction at 24 months (aOR 0.62, 95% CI 0.42-0.93, $p = 0.019$). Patients undergoing bowel resection had 25% greater reduction in diarrhoea severity at 12 months compared to those undergoing bowel shave (aOR 0.75, 95% CI 0.57-0.99, $p = 0.043$), and no significant difference for diarrhoea at other time-points. Patients undergoing bowel resection had 51% greater reduction in faecal urgency at 6 months (aOR 0.49, 95% CI 0.37-0.66, $p < .001$), 53% greater reduction at 12 months (aOR 0.47, 95% CI 0.34-0.64, $p < .001$) and 52% greater reduction at 24 months (aOR 0.48, 95% CI 0.32-0.71, $p < .001$) compared to patients who had a bowel shave. There was no difference between groups in the change in severity of tenesmus at any follow-up time-point.

Conclusions

Overall, all four bowel function symptoms improved significantly after surgery for bowel endometriosis. Although patients who had a bowel resection had worse bowel symptoms pre-operatively, they showed greater reduction in symptom severity for constipation, diarrhoea and faecal urgency postoperatively compared to those who had a bowel shave.

**ES32-0110 -
Free Communication**

Evaluating the use of virtual 3D models in patient understanding of endometriosis and site of pathology

Jyoti Sharma¹, Amr Moneib², Mohamed Mabrouk³, Bruce Ramsay¹

¹Peterborough City Hospital, Obstetrics and Gynaecology, Peterborough, United Kingdom

²Queen Elizabeth Hospital, Obstetrics and Gynaecology, London, United Kingdom

³Cambridge University Hospitals, Obstetrics and Gynaecology, Cambridge, United Kingdom

Background

Understanding endometriosis is critical for patient counseling and providing informed consent, particularly in preoperative clinics. Most units utilize simple sketches, or graphics that patients find difficult to grasp. In a variety of medical specialties, including gynecology, 3D modeling has emerged as a viable method for enhancing patient education and participation. However, using 3D models in endometriosis clinics is still in its early stages, and further research must be done to explore its potential benefits.

Endosketch.co.uk is a free website with 3D virtual images of female pelvis that can be rotated 360 degrees in real time in an outpatient clinic on a tablet. It is designed by one of the authors and it shows different variants of endometriosis. Clinical findings can be simulated on these models to support the explanation and counseling. The aim was to allow better patient understanding when explaining and consenting for surgery.

Methods

In this pilot assessment of 3D models on endosketch.co.uk, as a tool, patients at two hospitals (Peterborough City Hospital and Whipps Cross Hospital) were asked about the value of this new tool. We had responses from 24 patients in total.

Results

The results showed that 22 out of 24 (91%) strongly agreed or agreed that 3D models helped them understand the nature of endometriosis. 23 out of 24 (95%) strongly agreed or agreed that they got to understand the anatomy better with 3D modeling. According to 66%, 3D models were not used to explain endometriosis to them before. 87% said they see the value of having customized illustrations of their endometriosis added to their records and in correspondence. 75% said they would like to have a physical 3D print of their customized model. 58% said they liked that the models are simplified to facilitate understanding (compared to laparoscopy pictures where anatomy can be distorted). Regarding other sources of information, 62% used Google and search engines to help them understand their condition, and 50% used NHS, NICE, RCOG, or Endometriosis.co.uk, 45% used social media/forums while 20% put books or support groups as sources of information. 20% said these sources had no illustrations while 25% had 2D illustrations and 41% had pictures from laparoscopic procedures, none had 3D models.

Conclusions

Using virtual 3D models in endometriosis clinics could improve patient understanding and engagement with their health information. Majority of the patients found these models useful in comprehending their illness. It could also help healthcare providers and patients communicate by offering shared language and visual aid. Future studies are needed to investigate the potential benefits of virtual 3D models in bigger and more diverse patient populations.

**ES32-0349 -
Free Communication**

Ultrasound follow-up and factors associated with the progression of uterine adenomyosis

Linda Bertoldo¹, Giulia Borghese¹, Benedetta Orsini², Marisol Doglioli², Diego Raimondo¹, Renato Seracchioli²
¹Division of Gynaecology and Human Reproduction Physiopathology- IRCCS Azienda Ospedaliero-Universitaria di Bologna, Department of Medical and Surgical Sciences DIMEC- University of Bologna, Bologna, Italy

Background

No evidence of the natural history of adenomyosis is available in the literature. Therefore, the purpose of this study is to evaluate the rate of regression, stability, and progression of the disease at 12 months in patients with a sonographic diagnosis of adenomyosis, based on the change in uterine volume. The second objective is to describe the factors associated with the progression of the disease.

Methods

This single-centre prospective observational study was conducted from January 2020 to October 2022 at the Division of Gynaecology and Human Reproduction Physiopathology, IRCCS Azienda Ospedaliero-Universitaria di Bologna, Bologna, Italy. A TVUS scan was performed by expert operators in an outpatient setting. Uterine biometry (longitudinal, transverse and anteroposterior diameter) was measured, and uterine volume was subsequently calculated using the formula $D1 \times D2 \times D3 \times 0.52$. To evaluate the junctional zone, the 3D uterine volumes were acquired, and the rendered volume was manipulated to provide a coronal view of the uterus. Diagnosis of adenomyosis was made when at least two ultrasound characteristics, of which one direct feature, were observed among the Morphological Uterus Sonographic Assessment (MUSA) features of uterine adenomyosis. TVUS was carried out by the same expert operators, at the first visit (T0) and after 12 months (range 10-14 months) (T1). Anamnestic, clinical and ultrasound data previously described were compared between T0 and T1. Adenomyosis progression was defined as increase in uterine volume greater than or equal to 20%.

Results

Of the 258 patients enrolled between January 2020 and October 2021, 221 patients completed the follow-up at 12 months. A stability/regression rate of 78.7% and a progression rate of 21.3% were found. Patients who showed an ultrasound progression of the adenomyosis at 12 months reported worse dysmenorrhea ($p=0.03$) and chronic pelvic pain ($p=0.04$) compared with women with stable/regressed disease. The percentage of patients with worsening chronic pelvic pain at 12-month follow up was higher in the group of women with progression of adenomyosis (12 out of 47 patients, 25.5%) than in the group of women with stable/regressed disease (20 out of 174 patients, 11.5%) (p -value 0.04). According to our data, medical therapy was found to have no influence on the progression of adenomyosis in terms of increased uterine volume.

Conclusions

At the 12-month follow-up, adenomyosis remained stable or regressed in most patients (78.3%) and its ultrasonographic progression in terms of increased uterine volume was found to correlate with progression of dysmenorrhea and chronic pelvic pain. Medical therapy was found to be a non-determining factor in disease progression.

**ES32-0400 -
Free Communication**

Workplace bullying and burnout among residents in obstetrics and gynaecology in France: myth or reality?

Krystal Nyangoh Timoh¹, Chloé Gaillard¹, Jean Leveque¹, Vincent Lavoue¹

¹CHU Rennes, Gynecology Obstetrics, Rennes, France

Background

Workplace bullying is increasingly reported within hospitals. No study have been carried out in France among obstetrics and gynaecology residents. To evaluate the exposure of workplace bullying among GO residents in France, the prevalence of burnout syndrome, to study the association between bullying and burnout.

Methods

We conducted a national observational cross-sectional study in France (2021-2022 academic year). Between November 2021 and July 2022, data were collected by an anonymous online self-questionnaire based on standardized and validated questionnaires: the Maslach Burnout Inventory (MBI) assessing burnout, the Negative Act Questionnaire-Revised (NAQ-R) assessing workplace bullying, and the HADS assessing residents' mental health. Questions were also asked about socio-demographic data. The associations were examined using multivariable regression models.

Results

Among 625 respondents (response rate 61%), 52.4% were victim of moral harassment. Attending physicians were the most common source. The rate of burnout was estimated to 18.4%. An association was found between workplace bullying and burnout, confirmed after adjustment. Social support from superiors was a protective factor and frequent exposure to workplace violence was identified as a risk factor for burnout (OR 9.39), as was the number of hours worked per week (>70h) (OR 3.69).

Conclusions

Workplace bullying is widespread and associated with burnout in GO residents in France, leading to individual psychological and professional impact. Identification of actionable strategies may allow for targeted preventive interventions to develop safer and more positive and caring culture in the learning environment.

**ES32-0517 -
Free Communication**

Visual-Numeric Endometriosis Scoring System (VNESS) for mapping surgical findings: a validation and reliability study

Shaheen Khazal¹, Benedetto Mondelli², Kyle Fleischer³, Michael Adamczyk⁴, Averyl Bachi¹

¹HCA the Lister hospital, Centre for Endometriosis and Minimally Invasive Gynaecology CEMIG London, London, United Kingdom

²Ashford and St Peter's Hospitals NHS Foundation Trust, Obstetrics & Gynaecology, Chertsey, United Kingdom

³Royal Surrey County Hospital NHS Foundation Trust, Obstetrics and Gynaecology, Guildford, United Kingdom

⁴Ashford and St Peter's Hospitals NHS Foundation Trust, Centre for Endometriosis and Minimally Invasive Gynaecology CEMIG Chertsey, Chertsey, United Kingdom

Background

Since its identification, clinicians have made numerous attempts to classify and stage endometriosis. The rASRM system, although widely used, has several limitations. Newer ones have made important steps to address these, however, there is still no universally accepted system that maps the disease, correlates with imaging/symptoms/surgical complexity and is easy for patients to understand. The authors present a novel classification system (VNESS) that categorises the pelvis into nine anatomical zones and disease severity from zero to four.

Methods

Fifty gynaecologists from twelve different countries undertook a survey embedded with ninety-three short video clips displaying endometriosis in the pelvis and were asked to score each using VNESS. This was compared to the reference score determined by SK and percentage agreement/near-agreement, two way interclass correlation coefficient and Cohen/Weighted Kappa coefficient were calculated.

Results

Overall percentage of perfect agreement and agreement with one score difference was 77.11% and 99.09% respectively. In terms of inter-rater reliability, the total ICC was 0.905, which would be classified as excellent. The highest and lowest percentage agreement with the reference score was seen in VNESS 4 (full thickness disease, 97% perfect agreement) and VNESS 1 (superficial disease, 53% perfect agreement) respectively.

Conclusions

This study has shown that VNESS classification can be reliable and reproducible between scorers. Agreement is stronger with more severe disease. Currently VNESS is a classification system, but it is the authors' intention to develop it into a validated staging system and assess correlation between symptoms, surgical complexity and imaging.

**ES32-0545 -
Free Communication**

Ureteral reimplantation with Boari Flap in deep endometriosis

Ligia Balulescu¹, Simona Brasoveanu¹, Cristina Secosan¹, Marilena Pirtea¹, Laurentiu Pirtea¹

¹University of Medicine and Pharmacy "Victor Babeş" Timișoara, Department of Obstetrics and Gynecology, Timisoara, Romania

Background

To present our experience with the Boari flap we present a case of intrinsic endometriosis ureteral obstruction due to invasion of the ureteral muscularis or severe fibrosis.

Methods

A 39 year old patient referred to our department for management of stage IV endometriosis. She presented with left lumbar pain with radiation in the left iliac fossa. One year ago, the patient underwent laparoscopic excision of endometriosis, bilateral ureterolysis and left adnexectomy. An ureterohydronephrosis was found by renal ultrasonography and an Uro-CT scan revealed a distal left ureteral obstruction and left hydronephrosis (gr. II). A ureteral stent was placed and removed before surgery.

Results

This video demonstrates a Boari flap of ureteric repair using laparoscopy in an endometriosis ureteral obstruction. An exploratory laparoscopy revealed a pelvic adhesion process. The much-dilated left ureter was identified due to the fibrosis process at the level and extensive ureterolysis was performed, with its mobilization. The Retzius space and the paravesical spaces were dissected with mobilization of the bladder. A flap is mobilized in the entire layer of the bladder wall, which anastomoses proximally in the previously sectioned ureter. Vesico-ureteral anastomosis was performed using 3 stitches of PDO 3.0 monofilament. The ureter was catheterized using a double-J stent. The bladder is then closed in two layers using a 3.0 monofilament. A Foley catheter remained in place for 2 weeks and the double J stent was removed after 6-8 weeks by cystoscopy.

Conclusions

In conclusion, Boari flap is a valid method to bridge distal ureteral defects. Laparoscopic surgery has advantage being a minimal invasive surgery with less estimated blood loss, less pain, quicker post-operative recovery and shorter duration of hospital stay.

<https://player.vimeo.com/video/831578833?autoplay=1>

Laparoscopic neovagina creation by Vecchietti technique in Mayer-Rokitansky-Küster-Hauser syndrome

Maria Teresa Murcia Oliveras¹, Eva Magret Descamps¹, Patricia Muro Blanc¹, Taisiia Melnychuk¹, Irene Mora Hervas¹, Ramon Rovira Negre¹

¹Hospital de la Santa Creu i Sant Pau, Gynecology Service, Barcelona, Spain

Background

The objective is to explain laparoscopic neovagina creation by Vecchietti technique and to describe anatomical and functional results.

Methods

Sixteen-year-old woman was diagnosed with Mayer-Rokitansky-Küster-Hauser (MRKH) syndrome after consulting in our Gynecology Service for primary amenorrhea. Clinical examination showed total vaginal agenesis and complementary examinations (transvaginal ultrasound and MRI) demonstrated uterus absence and left ureteral duplicity. Genetic study was not performed.

At the age of 18, patient underwent neovagina creation surgery using Vecchietti laparoscopic technique.

Surgery preparation steps: patient asepsis, surgical field set up, bladder discharge catheterization and material preparation (straight needle, curve needle, abdominal prosthesis, vaginal dilator and two silk threads).

Operation steps: prosthesis reference markings on abdominal wall, pneumoperitoneum creation, abdominal ports placement, abdominal cavity examination (normal ovaries, normal fallopian tubes attached to rudimentary uterine horns, uterus absence and vaginal agenesis), cystoscopy exploration, straight needle insertion through vagina into abdominal cavity, cystoscopy verification, silk threads introduction through vagina into abdominal cavity, straight needle removal, curve needle insertion through abdominal port into pre-peritoneum, rudimentary uterus access, curve needle threading with vaginal threads, curve needle and silk threads removal through abdominal incisions, same steps on the other patient site, suprapubic urinary catheterization under cystoscopy control, skin preparation, external prosthesis placement, silk threads tension.

Results

Correct post-operative evolution occurred. Progressive vaginal dilator pressure took place. Eight days after primary operation, patient underwent a new surgery in order to remove vaginal dilator and suprapubic urinary catheterization. Procedure was completed without complication. Clinical exploration previous dismissal showed a 9cm vaginal length. The neovagina created was maintained with the use of a vaginal dilator 8 hours per day. Three months after surgery, clinic exploration showed a correct anatomic and functional 8cm vagina.

Conclusions

Due to minimal morbidity and good results, laparoscopic neovagina creation in MRKH syndrome by Vecchietti technique should be considered as a first line treatment.

<https://player.vimeo.com/video/831626791?autoplay=1>

**ES32-0579 -
Free Communication**

Laparoscopic hysterectomy after uterine rupture

Alice Moïse¹, Pierre Carvelli¹, Michèle Nisolle¹
¹CHU liege, gynecocology obstetric, Liege, Belgium

Background

Uterine rupture occurs most of the time in patient with previous intra myometrial section such as c section.

We have performed an inter ovarian hysterectomy for a uterine rupture of unknow origin.

Methods

This is a video of a surgical procedure of a uterine rupture form an unknow origin.

The patient came by the emergency for intense abdominal pain, menorrhagia for 10 days and no notion of pregnancy. She had medical history of two cesarian, two vaginal deliveries and high blood pressure.

The biological analysis shows HCG rate at 2800U/L, white blood cells at 21. 820 X10³/mm³, hemoglobin at 9,1 g/dL and a CRP 220 mg/L. At the physical examination we find a perineal swelling and soreness.

A vaginal ultrasound was performed and does not reveal any pregnancy, the uterus is blowed (20 cm of major axis), annexes were normal and there was no liquid in Douglas pouch.

Facing the patient pain, a CT scan has been performed. The gynaecological compartment was described as normal but a pre pubial swelling was noted.

The patient received 48h of IV antibiotherapy (flagyl and ceftriaxone) for a suspected necrotizing fasciitis.

Nevertheless, there was no clinical improvement, so we have asked for an MRI to complete pelvic exploration. This exam revealed a large right uterine rupture on a post gravid uterus.

Results

An interovarian hysterectomy has been performed by laparoscopy for a uterine rupture demonstrated by MRI.

At the beginning of the intervention, it was difficult to get a good visual field due to the big size of the uterus.

We used a ligasure to perform the hysterectomy to reduce bleeding.

We have proceeded a normal intervention until the opening of the right broad ligament where a hematoma was present. After aspirating this hematoma we have seen the rupture.

The hematoma dissected the pre vesical space and did not allow us to see correctly the vesico uterine plane.

We have decided to make a transversal section of the uterus form the angle of the rupture at the level of the uterus isthmus (as a sub total hysterectomy).

To remove the cervix, we have performed a colpotomy by vaginal way with a cold blade.

At the end of the hysterectomy, we have removed the uterus by laparotomy.

Conclusions

We are presenting a video of a surgical treatment for a complex uterine rupture on a post gravid uterus.

After the surgery the patient felt better, and the biological analysis get better also.

The origin of the rupture is still unknown.

Due to the size of the uterus, the placenta insertion and the cervical incompetence described at the anatomopathological examination, we suspect a clandestine abortion at 20 weeks or more which could be at the origin of the rupture.

<https://player.vimeo.com/video/831636521?autoplay=1>

**ES32-0590 -
Free Communication**

Deep endometriosis, correlation between preoperative images and intraoperative findings

María Cuadra¹, Beatriz Bueno¹, Sofía Fabra¹, Ainhoa Rodríguez¹, John Peay¹, Julio Álvarez Bernardi¹
¹Hospital Universitario Infanta Sofía, Ginecología y Obstetricia, Madrid, Spain

Background

We present a clinical case of deep endometriosis. The surgery that was performed and its correlation between preoperative findings and intraoperative lesions.

Methods

A 33-year-old nulliparous woman diagnosed with endometriosis. As personal medical history she had performed a right hysterectomy due to the rupture of a 20 cm endometriotic cyst.

Before the planned laparoscopic endometriosis excisional surgery, we carried out an USG assessment using International Deep Endometriosis Analysis (IDEA) protocol and #ENZIAN score. We illustrate the correlation between the preoperative ultrasound assessment and the following intraoperative findings.

Results

Ultrasound assessment based on the IDEA protocol and the #ENZIAN score is accurate for mapping pelvic endometriosis in all its forms and correlates with laparoscopic findings, this helps the surgeon plan a better technique and provides a roadmap to perform it.

The ENZIAN score, created through a consensus process, is a comprehensive visual documentation system for a complete mapping of endometriosis including peritoneal endometriotic implants and the extent of organ involvement by deep infiltrating endometriosis (DIE). It is useful with both non-invasive diagnostic (USG/MRI) and laparoscopic methods.

Conclusions

A consistent and shared reporting system between therapeutic and imaging modalities will simplify communication and will improve the management of patients avoiding reoperation on patients and improving the quality of the treatment.

<https://player.vimeo.com/video/831645561?autoplay=1>

**ES32-0043 -
Free Communication**

Residents training in vaginal natural orifice transluminal endoscopic surgery (vNOTES)

*Aya Mohr-Sasson¹, Mason Hui², Alvaro Montealegre¹, Randa Jalloul¹, Olivia Dziadek¹, Asha Bhalwal¹
¹McGovern Medical School at The University of Texas Health Science Center,
Advanced Minimally Invasive Gynecologic Surgery, Houston, USA*

Background

As the vaginal natural orifice transluminal endoscopic surgery (vNOTES) is becoming a common acceptable approach to perform benign gynaecological surgeries there is need to incorporate it in resident's curriculum for surgical training. The aim of this study was to estimate the impact of hands-on lab simulation for vNOTES on residents' perception and confidence in this surgical approach.

Methods

This is a prospective observational study conducted at a single tertiary University affiliated medical centre including 12 fourth year residents that were evaluated by 7 faculty attending surgeons between July to August 2022. All residents completed didactic online training of adnexectomy and hysterectomy performed by vNOTES. Three hands on simulation labs were scheduled on a monthly base during the study period. Each resident performed both procedures on each encounter. Residents were evaluated by experienced surgeons in vNOTES approach. Survey evaluating the knowledge and confidence in the vNOTES approach was completed by the residents before and following all simulations.

Results

49 assessments were completed, of them 23 adnexectomies and 26 hysterectomies. Competence in adnexectomy and hysterectomy were achieved in 2/12 and 5/12 of the residents, respectively. Feedback was completed by 7 residents before and after the simulations. 33% increase in the confidence to perform anterior and posterior colpotomy was reported by the residents. 71% versus 85% reported confidence in transecting the uterosacral ligaments before and after the simulations, respectively. Confidence in transecting the uterine artery was found doubled (14% versus 28%) during vNOTES compared to laparoscopic approach following the simulation. 15% increase in the confidence to perform adnexectomy was noted following the simulation, however, 14% reduction was reported by the residents in choosing vNOTES approach for hysterectomy.

Conclusions

Hands-on simulation in vNOTES approach increases the knowledge and confidence of residents in the surgical steps of adnexectomy and hysterectomy.

**ES32-0045 -
Free Communication**

Clavien-Dindo, comprehensive complication index (CCI) and classification of intraoperative adverse events (ClassIntra): uniform and holistic approach in adverse event registration for (deep) endometriosis surgery

Jeroen Metzemaekers¹, Lotte Bouwman¹, Marit de Vos¹, Frank Willem Jansen¹, Andries Twijnstra¹, Mathijs Blikkendaal¹

¹LUMC, Gynaecology, Leiden, The Netherlands

Background

Surgical procedures for endometriosis often have a high incidence of adverse events (AEs), which are reported inconsistently, making it difficult to compare outcomes across studies. The Clavien-Dindo (CD) system and the comprehensive complication index (CCI) are recommended for adverse event classification, but the CCI is not widely used in endometriosis care and research. Additionally, there is no established method for intraoperative adverse events (ioAEs) registration in endometriosis surgery. This study aims to evaluate the additional value of using the CCI and ClassIntra system for adverse event reporting in deep endometriosis (DE) surgery compared to only using the CD system.

Methods

This prospective mono-centre study collected data from 870 surgical (deep) endometriosis cases from a non-university DE expertise centre between February 2019 and December 2021. The EQUSSUM system, a publicly available web-based application for registration of surgical procedures for endometriosis, was used to collect the cases. Postoperative AEs were classified using the CD complication system and CCI, and ioAEs were assessed with the ClassIntra. The primary outcome measure was to assess the additional value of the CCI and ClassIntra towards the CD classification, and a benchmark for the CCI in DE surgery was also reported.

Results

Out of 870 DE procedures, 145 procedures had one or more postoperative AEs, resulting in a postoperative AE rate of 16.7%. In 36 cases (4.1%), the postoperative AE was classified as severe (\geq grade 3b). The median CCI of patients with postoperative AEs was 20.9 (20.9-31.7), and 33.7 (33.7-39.7) in the group of patients with severe postoperative AEs. In 20 patients (13.8%), the CCI was higher than the CD due to multiple postoperative AEs. There were 11 ioAEs reported (1.3%) in all procedures, mostly minor and directly repaired serosa injuries.

Conclusions

The CCI and ClassIntra are useful additional tools alongside the CD system for a complete and uniform overview of the total AE burden in patients with extensive surgery (such as DE). The CCI provided a more complete overview of the total burden of postoperative AEs compared to only reporting the most severe postoperative AE (as with CD). If the use of the CD, CCI and ClassIntra is widely adapted, uniform data comparison is possible on (inter)national level, providing better insight into the quality of care. The data from this study can be used as a benchmark for other DE centres to optimize information provision in the shared decision-making process. However, the results of this study are mono-centre, and further studies are needed to evaluate the generalizability of these findings.

**ES32-0147 -
Free Communication**

Anatomical landmarks of the avascular spaces of the pelvis: laparoscopic approach during hysterectomy

Morfiri Stavroula¹, Ioannis Billiatis¹, Kalliopi Kordopati-Zilou¹, Alexandros Petrolekas¹, Olga Triantafyllidou¹, Nikolaos Vlahos¹

¹Aretaieion University Hospital- National and Kapodistrian University of Athens- 2nd Dept. of Obstetrics and Gynecology- Athens- Greece, 2nd Dept. of Obstetrics and Gynecology, Athens, Greece

Background

Development of the pararectal and paravesical spaces of the female pelvis is mandatory while performing hysterectomy during gynaecologic oncological procedures. Knowledge of the anatomical landmarks is necessary. The paravesical space is defined: ventrally by the superior pubic ramus, dorsally by the cardinal ligament and uterine vessels, medially by the vesico-uterine ligament and bladder, and laterally by the obturator internus muscle and external iliac vessels. The obliterated umbilical artery divides this space into lateral and medial paravesical space. Pararectal space boundaries consist of: ventrally the cardinal ligament, dorsally the sacrum, laterally the internal iliac artery, medially the rectum, cranially the posterior leaf of the broad ligament, and caudally the levator ani muscle. The ureter divides the pararectal space into medial (Okabayashi's space) and lateral (Latzko's space) pararectal spaces. In this video we perform laparoscopic development of these spaces, during a hysterectomy in a patient diagnosed with endometrial cancer.

Methods

After dissection of the round ligament, entering the retroperitoneum laterally to the ip ligament, allows the visualization and development of the left ureter and the left uterine vessels. Development of the paravesical space continues while detaching the obliterated umbilical artery, which divides this space in lateral and medial. Careful detachment of the ureter cranially, while preserving the mesoureter, allows the development of the pararectal space.

Results

Laparoscopic identification of the anatomical landmarks of the avascular spaces of the pelvis is very important during oncological operations of the pelvis.

Conclusions

Knowledge of the anatomical landmarks of the avascular spaces of the pelvis is important, while it provides the identification and safe development of those spaces which is necessary in oncological procedures of the pelvis. Furthermore, education of the retroperitoneal anatomy is helpful for new surgeons, even while performing simple procedures.

<https://player.vimeo.com/video/826520835?autoplay=1>

**ES32-0156 -
Free Communication**

A guide to laparoscopic ureteral reconstruction for gynaecologists: techniques we learned from 100 cases

Masaaki Andou¹, Ochi Yoshifumi¹, Mari Sawada¹, Kiyoshi Kanno¹, Shintaro Sakate¹, Shiori Yanai¹

¹Kurashiki Medical Center, Gynaecology, Kurashiki-shi, Japan

Background

This presentation will present techniques in a 'how to' style learned from over one hundred cases of experience of ureteral reconstruction from the viewpoint of gynaecologists. Through our experience we were able to hone skills and techniques to make ureteral reconstruction possible in same-session and post-operative-session gynaecologic surgery.

Methods

Detailed techniques description in this presentation of laparoscopic ureteral reconstruction will include simple ureteral reimplantation, psoas hitch and Boari flap techniques, as well as the interposition of an ileal graft. The cases presented will be cases with intraoperative ureteral injury, post-operative stenosis or fistula, ureteral endometriosis, and advanced or recurrent gynaecologic malignancy. Consent was gained to present and publish information on these cases on the condition of anonymity.

Extensive resection and ureteral injury repair require advanced and specialized skills such as intracorporeal suturing and knowledge of pelvic anatomy and how to reconstruct the urinary tract, even when extensive defects need compensating for. This includes knowing which techniques and combinations of techniques are best for the reconstruction.

This presentation will show steps to safe and genuine repair which have been developed as a result of dedicated training and experience. Graphic descriptions as well as surgical videos will illustrate the steps and skills involved in each repair technique.

Results

From January 2006 to April 2023, 104 cases have been performed with 103 cases successfully managed. The cases who underwent the interventions on this presentation were: 40 cases of intraoperative injury or post-operative stenosis or fistula, 7 cases of advanced or recurrent gynaecologic malignancy, and 57 cases of ureteral or bladder endometriosis.

No cases required blood transfusion or suffered ureteral stenosis. The single unsuccessful case suffered from simultaneous rectal and ureteral anastomosis, suffering ureteral anastomotic breakdown due to infection from the site of the rectal surgery.

Conclusions

With dedicated training, techniques can be implemented to advance the understanding and further facilitation of ureteral repair by gynaecologists. These techniques can allow for same-session and post-operative-session repair of ureteral injuries by gynaecologists, making patient care more efficient and patient-friendly. These techniques also allow for surgery of greater radicality to be performed minimally invasively.

**ES32-0238 -
Free Communication**

Laparoscopic hysterectomy for deep infiltrating endometriosis: retrograde hysterectomy technique

Nasuh Utku Doğan¹, Selen Dogan¹, Sefa Metehan Ceyhan¹, Fatma ceren Guner¹
¹Akdeniz University, Gynecology, Antalya, Turkey

Background

In symptomatic patients with deep infiltrating endometriosis, when fertility is of no concern, the ultimate goal is macroscopic clearance of all visible endometriotic tissue by using radical organ resections. When there is an involvement of Douglas along with rectosigmoid colon, hysterectomy should be started followed by anterior colpotomy and dissection of Douglas dissection by posterior colpotomy (retrograde hysterectomy). By this was, hysterectomy will be easier.

Methods

In this video, technique of laparoscopic retrograde hysterectomy was presented in a 44-year-old multiparous woman with a previous surgeries for endometriosis.

Results

Along with hysterectomy, BSO, endometriotic nodul excision in sacrouterin ligament and rectal shaving were all performed. In this video, Douglas dissection after anterior colpotomy is presented. Total operation time was 195 minutes and blood loss was 75 cc. In postoperative third day, she was discharged.

Conclusions

Laparoscopic hysterectomy for deep infiltrating endometriosis becomes easier when certain surgical steps are followed and by this way complication rates decrease.

<https://player.vimeo.com/video/826777005?autoplay=1>

**ES32-0260 -
Free Communication**

Laparoscopic pectopexy in 10 steps

Angelos Daniilidis¹, Georgios GRIGORIADIS², Dimitra Dalakoura²

¹Aristotle University of Thessaloniki,

1st Department of Obstetrics and Gynecology- Papageorgiou Genral Hospital, Thessaloniki, Greece

²Aristotle University of Thessaloniki,

2nd University Department of Obstetrics and Gynecology- Hippokration General Hospital, Thessaloniki, Greece

Background

Laparoscopic pectopexy is a surgical procedure that has gained popularity in the management of uterine prolapse. Our aim was to identify and describe 10 consecutive, easy to follow steps in order to safely perform a laparoscopic pectopexy.

Methods

Narrated video of a case of laparoscopic pectopexy we performed, presented in a stepwise approach, with clear description of each surgical step.

Results

We identify the following 10 surgical steps: 1. Division of Round Ligament and Extension of Dissection towards the Pelvic Sidewall 2. Identification of the Iliopectineal ligament. 3. Division of the uterovesical peritoneum and development of the vesicovaginal space. 4. Routine subtotal Hysterectomy 5. Opening of the rectovaginal space 6. Closure of the cervical canal 7. Insert the mesh and fix it with sutures on the cervix, anterior and posterior vagina. 8. Anchor the lateral arms of the mesh on the iliopectineal ligaments bilaterally. 9. Closure of the overlying peritoneum. 10. Morcellation of the uterine corpus. Our patient had minimal intra-operative blood loss, was discharged home on post-operative day 1 and made an uneventful recovery.

Conclusions

Laparoscopic pectopexy is a reproducible surgical technique for the management of uterine prolapse. Through knowledge of the pelvic anatomy, careful dissection and skilful laparoscopic suturing are mandatory for performing this technique safely.

<https://player.vimeo.com/video/826911882?autoplay=1>

**ES32-0400 -
Free Communication**

Workplace bullying and burnout among residents in obstetrics and gynaecology in France: myth or reality?

Krystal Nyangoh Timoh¹, Chloé Gaillard¹, Jean Leveque¹, Vincent Lavoue¹

¹CHU Rennes, Gynecology Obstetrics, Rennes, France

Background

Workplace bullying is increasingly reported within hospitals. No study have been carried out in France among obstetrics and gynaecology residents. To evaluate the exposure of workplace bullying among GO residents in France, the prevalence of burnout syndrome, to study the association between bullying and burnout.

Methods

We conducted a national observational cross-sectional study in France (2021-2022 academic year). Between November 2021 and July 2022, data were collected by an anonymous online self-questionnaire based on standardized and validated questionnaires: the Maslach Burnout Inventory (MBI) assessing burnout, the Negative Act Questionnaire-Revised (NAQ-R) assessing workplace bullying, and the HADS assessing residents' mental health. Questions were also asked about socio-demographic data. The associations were examined using multivariable regression models.

Results

Among 625 respondents (response rate 61%), 52.4% were victim of moral harassment. Attending physicians were the most common source. The rate of burnout was estimated to 18.4%. An association was found between workplace bullying and burnout, confirmed after adjustment. Social support from superiors was a protective factor and frequent exposure to workplace violence was identified as a risk factor for burnout (OR 9.39), as was the number of hours worked per week (>70h) (OR 3.69).

Conclusions

Workplace bullying is widespread and associated with burnout in GO residents in France, leading to individual psychological and professional impact. Identification of actionable strategies may allow for targeted preventive interventions to develop safer and more positive and caring culture in the learning environment.

**ES32-0545 -
Free Communication**

Ureteral reimplantation with Boari Flap in deep endometriosis

Ligia Balulescu¹, Simona Brasoveanu¹, Cristina Secosan¹, Marilena Pirtea¹, Laurentiu Pirtea¹

¹University of Medicine and Pharmacy "Victor Babeş" Timișoara, Department of Obstetrics and Gynecology, Timisoara, Romania

Background

To present our experience with the Boari flap we present a case of intrinsic endometriosis ureteral obstruction due to invasion of the ureteral muscularis or severe fibrosis.

Methods

A 39 year old patient referred to our department for management of stage IV endometriosis. She presented with left lumbar pain with radiation in the left iliac fossa. One year ago the patient underwent laparoscopic excision of endometriosis, bilateral ureterolysis and left adnexectomy. An ureterohydronephrosis was found by renal ultrasonography and an Uro-CT scan revealed a distal left ureteral obstruction and left hydronephrosis (gr. II) A ureteral stent was placed and removed before surgery.

Results

This video demonstrates a Boari flap of ureteric repair using laparoscopy in an endometriosis ureteral obstruction. An exploratory laparoscopy revealed a pelvic adhesion process. The much dilated left ureter was identified due to the fibrosis process at the level and extensive ureterolysis was performed, with its mobilization. The Retzius space and the paravesical spaces was dissected with mobilization of the bladder. A flap is mobilized in the entire layer of the bladder wall, which anastomoses proximally in the previously sectioned ureter. Vesico ureteral anastomosis was performed using 3 stitches of PDO 3.0 monofilament. The ureter was catheterized using a double-J stent. The bladder is then closed in two layers using a 3.0 monofilament . A Foley catheter remained in place for 2 weeks and the double J stent was removed after 6-8 weeks by cystoscopy.

Conclusions

In conclusion, Boari flap is a valid method to bridge distal ureteral defects. Laparoscopic surgery has advantage being a minimal invasive surgery with less estimated blood loss, less pain, quicker post-operative recovery and shorter duration of hospital stay.

<https://player.vimeo.com/video/831578833?autoplay=1>

Laparoscopic neovagina creation by Vecchietti technique in Mayer-Rokitansky-Küster-Hauser syndrome

*Maria Teresa Murcia Oliveras¹, Eva Magret Descamps¹, Patricia Muro Blanc¹, Taisiia Melnychuk¹,
Irene Mora Hervas¹, Ramon Rovira Negre¹*

¹Hospital de la Santa Creu i Sant Pau, Gynecology Service, Barcelona, Spain

Background

The objective is to explain laparoscopic neovagina creation by Vecchietti technique and to describe anatomical and functional results.

Methods

Sixteen-year-old woman was diagnosed with Mayer-Rokitansky-Küster-Hauser (MRKH) syndrome after consulting in our Gynecology Service for primary amenorrhea. Clinical examination showed total vaginal agenesis and complementary examinations (transvaginal ultrasound and MRI) demonstrated uterus absence and left ureteral duplicity. Genetic study was not performed.

At the age of 18, patient underwent neovagina creation surgery using Vecchietti laparoscopic technique.

Surgery preparation steps: patient asepsis, surgical field set up, bladder discharge catheterization and material preparation (straight needle, curve needle, abdominal prosthesis, vaginal dilator and two silk threads).

Operation steps: prosthesis reference markings on abdominal wall, pneumoperitoneum creation, abdominal ports placement, abdominal cavity examination (normal ovaries, normal fallopian tubes attached to rudimentary uterine horns, uterus absence and vaginal agenesis), cystoscopy exploration, straight needle insertion through vagina into abdominal cavity, cystoscopy verification, silk threads introduction through vagina into abdominal cavity, straight needle removal, curve needle insertion through abdominal port into pre-peritoneum, rudimentary uterus access, curve needle threading with vaginal threads, curve needle and silk threads removal through abdominal incisions, same steps on the other patient site, suprapubic urinary catheterization under cystoscopy control, skin preparation, external prosthesis placement, silk threads tension.

Results

Correct post-operative evolution occurred. Progressive vaginal dilator pressure took place. Eight days after primary operation, patient underwent a new surgery in order to remove vaginal dilator and suprapubic urinary catheterization. Procedure was completed without complication. Clinical exploration previous dismissal showed a 9cm vaginal length. The neovagina created was maintained with the use of a vaginal dilator 8 hours per day. Three months after surgery, clinic exploration showed a correct anatomic and functional 8cm vagina.

Conclusions

Due to minimal morbidity and good results, laparoscopic neovagina creation in MRKH syndrome by Vecchietti technique should be considered as a first line treatment.

<https://player.vimeo.com/video/831626791?autoplay=1>

**ES32-0579 -
Free Communication**

Laparoscopic hysterectomy after uterine rupture

Alice Moïse¹, Pierre Carvelli¹, Michèle Nisolle¹

¹CHU liege, gynecocology obstetric, Liege, Belgium

Background

Uterine rupture occurs most of the time in patient with previous intra myometrial section such as c section.

We have performed an inter ovarian hysterectomy for a uterine rupture of unknow origin.

Methods

This is a video of a surgical procedure of a uterine rupture form an unknow origin.

The patient came by the emergency for intense abdominal pain, menorrhagia for 10 days and no notion of pregnancy. She had medical history of two caesarean, two vaginal deliveries and high blood pressure.

The biological analysis shows HCG rate at 2800U/L, white blood cells at 21. 820 X10³/mm³, haemoglobin at 9,1 g/dL and a CRP 220 mg/L. At the physical examination we find a perineal swelling and soreness.

A vaginal ultrasound was performed and does not reveal any pregnancy, the uterus is blowed (20 cm of major axis), annexes were normal and there was no liquid in Douglas pouch.

Facing the patient pain, a CT scan has been performed. The gynaecological compartment was described as normal but a pre pubial swelling was noted.

The patient received 48h of IV antibiotherapy (flagyl and ceftriaxone) for a suspected necrotizing fasciitis.

Nevertheless, there was no clinical improvement, so we have asked for an MRI to complete pelvic exploration. This exam revealed a large right uterine rupture on a post gravid uterus.

Results

An interovarian hysterectomy has been performed by laparoscopy for a uterine rupture demonstrated by MRI.

At the beginning of the intervention, it was difficult to get a good visual field due to the big size of the uterus.

We used a ligasure to perform the hysterectomy to reduce bleeding.

We have proceeded a normal intervention until the opening of the right broad ligament where a hematoma was present. After aspirating this hematoma we have seen the rupture.

The hematoma dissected the pre vesical space and did not allow us to see correctly the vesico uterine plane.

We have decided to make a transversal section of the uterus form the angle of the rupture at the level of the uterus isthmus (as a sub total hysterectomy).

To remove the cervix, we have performed a colpotomy by vaginal way with a cold blade.

At the end of the hysterectomy, we have removed the uterus by laparotomy.

Conclusions

We are presenting a video of a surgical treatment for a complex uterine rupture on a post gravid uterus.

After the surgery the patient felt better, and the biological analysis get better also.

The origin of the rupture is still unknow.

Due to the size of the uterus, the placenta insertion and the cervical incompetence described at the anatomopathological examination, we suspect a clandestine abortion at 20 weeks or more which could be at the origin of the rupture.

<https://player.vimeo.com/video/831636521?autoplay=1>

**ES32-0590 -
Free Communication**

Deep endometriosis, correlation between preoperative images and intraoperative findings

María Cuadra¹, Beatriz Bueno¹, Sofía Fabra¹, Ainhoa Rodríguez¹, John Peay¹, Julio Álvarez Bernardi¹
¹Hospital Universitario Infanta Sofía, Ginecología y Obstetricia, Madrid, Spain

Background

We present a clinical case of deep endometriosis. The surgery that was performed and its correlation between preoperative findings and intraoperative lesions.

Methods

A 33-year-old nulliparous woman diagnosed with endometriosis. As personal medical history she had performed a right oophorectomy due to the rupture of a 20 cm endometriosis cyst.

Before the planned laparoscopic endometriosis excisional surgery, we carried out an USG assessment using International Deep Endometriosis Analysis (IDEA) protocol and #ENZIAN score. We illustrate the correlation between the preoperative ultrasound assessment and the following intraoperative findings.

Results

Ultrasound assessment based on the IDEA protocol and the #ENZIAN score is accurate for mapping pelvic endometriosis in all its forms and correlates with laparoscopic findings, this helps the surgeon plan a better technique and provides a roadmap to perform it.

The ENZIAN score, created through a consensus process, is a comprehensive visual documentation system for a complete mapping of endometriosis including peritoneal endometriotic implants and the extent of organ involvement by deep infiltrating endometriosis (DIE). It is useful with both non-invasive diagnostic (USG/MRI) and laparoscopic methods.

Conclusions

A consistent and shared reporting system between therapeutic and imaging modalities will simplify communication and will improve the management of patients avoiding reoperation on patients and improving the quality of the treatment.

<https://player.vimeo.com/video/831645561?autoplay=1>

**ES32-0090 -
Free Communication**

Ovarian ectopic pregnancy after IVF

Sayed Elakhras¹, Bassem Sobhy², Mohamed Salama³, Tanos Vasilios⁴

¹Omam Hospital, Dept. of Minimally Invasive Gynaecology, Cairo, Egypt

²Galaa Teaching Hospital, Galaa Teaching Hospital, Cairo, Egypt

³Ain Shams University, Obstetrics and Gynaecology, Cairo, Egypt

⁴University of Nicosia Medical School, Obstetrics and Gynaecology, Nicosia, Cyprus

Background

Ovarian ectopic pregnancy is a rare event in both natural and assisted human reproduction settings. There are few reports of this event after in vitro fertilization. Diagnosis can be challenging, since it requires specific medical expertise. However, neither a definite mechanism nor clear risk factors were identified and therefore prevention strategies are yet unavailable.

Methods

We present a 24-year-old gestational carrier who presented with suprapubic and pelvic pain at 6 weeks and 2 days' gestation. An ultrasound scan demonstrated an empty uterus and a complex mass in the RT adnexa with free fluid in douglas pouch .

Thus, a ruptured ectopic pregnancy was suspected and a decision was made to proceed to surgical management.

Results

An urgent laparoscopy was performed shortly after. After aspiration of the blood, a ruptured RT ovarian ectopic pregnancy was identified. The tissue was removed from the ovary,. The surgeons described a normal RT fallopian tube and left adnexa.

The operative and postoperative course was otherwise uneventful. The patient was instructed to have serial measurements of serum β hCG concentration until it declines to zero. In a follow-up visit in our clinic, the patient was feeling well and symptom free.

The pathological report confirmed the presence of chorionic villi in the ovary, validating the diagnosis of an ovarian ectopic pregnancy.

Conclusions

Ovarian pregnancy is a challenging diagnosis; however, clinicians should be aware of the possible risk of ovarian pregnancy in ART treatment. It should be actively pursued in high-risk patients in order to prevent complications.

<https://player.vimeo.com/video/825140453?autoplay=1>

**ES32-0112 -
Free Communication**

Pregnancy after laparoscopic surgery for endometriosis: how long should we wait?

Morva Tahmasbi Rad¹, Dilara Akpınar-İsci¹, Khayal Gasimli¹, Sven Becker¹

¹University of Frankfurt, Department of Gynecology and Obstetrics, Frankfurt, Germany

Background

Endometriosis is associated with a reduced quality of life as well as infertility. The surgical intervention, the time restriction before pregnancy can be expected and treatment with assisted reproductive therapy can be crucial.

Methods

This is a retrospective analysis that includes a prospective evaluation of patients with infertility and with the diagnosis of endometriosis. A subgroup of patients who desired to be pregnant after laparoscopic intervention (102 patients) was followed up 36 to 197 months after the surgery.

Results

In this study, 69.9% and 58.8% of the patients achieved pregnancy and live birth, respectively. In the group of patients who became pregnant, the duration of infertility was significantly lower (2.7 ± 2.1 years versus 4.7 ± 3.2 years). The median time until pregnancy after laparoscopic intervention was 8 months (the average was 10 months). After 38th month, no pregnancy occurred.

Conclusions

In the group of patients with endometriosis and infertility, the first 12 months were the optimal time for pregnancy. For rASRM stages I and II, spontaneous pregnancy can probably be delayed for up to 24 months, but in patients in rASRM stages III and IV, ART may be considered after 12 months. The gynaecologist must be careful about the timing of further interventions after the operation.

**ES32-0128 -
Free Communication**

Laparoscopic unilateral salpingo-oophorectomy in a woman with multiple past laparotomies

Nikoletta Mili¹, Kalliopi Kordopati-Zilou¹, Theodoros Kalampokas¹, Stavroula Morfiri¹, Nikolaos Vlahos¹, Emmanouil Kalampokas¹

*¹Aretaieio University Hospital- National and Kapodistrian University of Athens-,
2nd Department of Obstetrics and Gynecology, Athens, Greece*

Background

Laparoscopic management of patients with a surgical history of multiple laparotomies presents a challenge due to possible postoperative adhesions and altered anatomy.

Methods

This case concerns a thirty-nine-year-old with past surgical history, including four caesarean sections and one emergency peripartum hysterectomy with left salpingo-oophorectomy due to placental abruption. The patient had symptoms of early menopause since then and was diagnosed with premature ovarian failure. Due to pelvic pain, a pelvic MRI was performed; it demonstrated a multilocular cystic mass on the remaining right ovary that measured 3.6 x 5.4 x 4.9 cm.

Results

Intraoperatively, the right ovary had firmly adhered to the anterior abdominal wall. The infundibulopelvic ligament was coagulated and dissected. The right retroperitoneal space was developed, and the ipsilateral ureter was recognized. The right ovary and fallopian tube were detached from the anterior abdominal wall. The histopathology revealed a serous cystadenoma of the ovary.

Conclusions

This video showcases the laparoscopic detachment of the right ovary and fallopian tube from the anterior abdominal wall in a woman with multiple previous laparotomies.

<https://player.vimeo.com/video/826329216?autoplay=1>

**ES32-0172 -
Free Communication**

The tips of lateral approach of 30-degree scope during single port laparoscopic surgery of total hysterectomy with bladder endometriosis

Chun-Hui Wei¹, Yan-Fong Lu²

¹*Chi-Mei Medical Center- Liouying, OBGYN department, Tainan, Taiwan*

²*Shin Kong Wu Ho-Su Memorial Hospital, OBGYN department, Taipei, Taiwan*

Background

To demonstrate the tips of using 30-degree scope during single port laparoscopic surgery of total hysterectomy with severe bladder adhesion due to endometriosis.

Methods

The 51 y/o female, G0, had menorrhagia and dysmenorrhea for years. She asked for operation due to severe anaemia (Hb: 7 g/dl). Transvaginal echo showed an AV uterus with multiple myomata about 10*6.7cm in dimension and right ovarian endometrioma about 5*3cm in size. Dense adhesion between urinary bladder and anterior uterine wall was suspected. We arranged single port laparoscopic total hysterectomy and bilateral salpingo-oophorectomy for her.

Results

During the operation, dense adhesion between urinary bladder and lower uterine segment was noted. The margin of urinary bladder was unclear. Besides, firm adhesive band led to bleeding during separation. Herein, we took advantage of 30-degree scope, approaching the adhesive boundary laterally after opening peritoneum. It made sharp and blunt dissection of adhesive band easier. The specimen weighted 733 g, operation time was 120 minutes, and blood loss was 250cc. The patient was discharged on the next day after operation.

Conclusions

To identify the adhesive boundary of urinary bladder is a challenge of surgery. However, using 30-degree scope to rotate visual field could overcome the situation, making surgery safer and easier.

<https://player.vimeo.com/video/826675212?autoplay=1>

**ES32-0194 -
Free Communication**

Safety of early hospital discharge after laparoscopic hysterectomy

Hossam El-Mansy¹, Marwan Eltalhawy², Mohamed Abdelhafez³, Amr Gaber⁴, Karim El-Etriby¹, Mohamed Nabil⁵

¹Helwan University, Gynecology, Cairo, Egypt

²Helwan University Hospitals, Gynecology, Cairo, Egypt

³Mansoura University, Gynecology, Mansoura, Egypt

⁴Ain Shams University, Anesthesia, Cairo, Egypt

⁵Cairo University, Gynecology, Cairo, Egypt

Background

The concept of same-day postoperative discharge is becoming more popular today due to its positive effects on patients and healthcare systems. Laparoscopy has numerous advantages as an approach for hysterectomy, including being effective with less predicted blood loss. Detecting the likelihood of an early hospital release following a laparoscopic hysterectomy is our goal.

Methods

This prospective observational study was conducted at the Department of the Obstetrics & Gynecology, Helwan University Hospitals, on 50 patients who underwent laparoscopic hysterectomy and then the idea of same day discharge was offered to the patients when there were no complications.

Results

Fifty laparoscopic hysterectomies were performed. Ninety-four percent (n=47) of the patients were discharged home the same-day. The most common readmission diagnoses (4 %) included loin pain, lower abdominal pain, and vaginal bleeding. Only 4% of patients presented for emergency care within 48 or 72 hours.

Conclusions

Same-day discharge after laparoscopic hysterectomy is associated with low readmission rates and minimal emergency visits in the immediate postoperative period. So it may be a safe option for healthy patients undergoing uncomplicated laparoscopic hysterectomy.

Enhanced recovery after surgery for recto-sigmoid deep infiltrating endometriosis following the COVID-19 pandemic: results from an academic referral centre

Roberto Palermo¹, Alessandro Arena¹, Benedetta Orsini¹, Eugenia Degli Esposti¹, Anna Chiara Aru¹, Renato Seracchioli¹

¹Division of Gynaecology and Human Reproduction Physiopathology- IRCCS Azienda Ospedaliero-Universitaria di Bologna, Department of Medical and Surgical Sciences DIMEC- University of Bologna, Bologna, Italy

Background

Endometriosis can involve many extragenital organs, such as the ureters, the bladder, and the bowel, causing chronic pain, infertility, and decreasing women's quality of life. Surgery is a pillar of endometriosis management, but it can be complex and is burdened by non-negligible complications. Recently, enhanced recovery after surgery (ERAS) programs have been introduced in deep infiltrating endometriosis (DIE) surgery to improve patients' management while shortening the length of hospitalization. The 2019 coronavirus pandemic has ulteriorly pushed surgeons and patients towards early discharge, because of limitations in available hospital beds and concerns over virus transmission. Our study aims to evaluate the influence of the COVID-19 pandemic on endometriosis patients' perioperative management and implementation of fast-track protocols. We also examined whether these changes led to increased complication and readmission rates.

Methods

We retrospectively examined the charts of patients undergoing laparoscopic surgery for bowel endometriosis between February 2017 and February 2023. Patients were divided into two groups, pre-pandemic and post-pandemic cohorts, based on when surgery was performed (before or after the introduction of the protocols limiting elective surgeries at our hospital on March 5th, 2020). All surgeries were performed by three gynaecologists extensively trained in laparoscopy for DIE, who resorted to shaving, nodulectomy, or segmental bowel resection depending on the disease. During and after the COVID-19 pandemic we implemented opioid-free multimodal analgesia, early nutrition, and early mobilization, and avoided the use of drains and nasogastric tubes. We compared the two groups in terms of length of hospitalization, occurrence of postoperative complications, and hospital readmission within 30 days of surgery.

Results

A total of 579 patients were included in our analysis, 316 in the pre-pandemic cohort and 263 in the post-pandemic one. The mean length of hospital stay before and after the introduction of the fast-track protocol was 5.8 ± 3.1 days and 4.8 ± 2.9 days respectively, with a significant decrease of one day. We performed 317 shaving procedures (196 vs 121), 63 nodulectomies (28 vs 35), and 199 segmental resections (92 vs 107). Complication rates were also lower in the post-pandemic cohort compared to the other group (12.5% vs 19.0%, $p = 0.04$), with most adverse events being non-serious and needing only medical care. No significant differences were observed in terms of readmission rates.

Conclusions

The implementation of a fast-track protocol following the restrictions imposed by the COVID-19 pandemic did not negatively affect the perioperative course of patients undergoing surgery for DIE. Length of hospitalization was shorter during and after the pandemic and the rates of early perioperative complications also decreased, with no differences in terms of hospital readmissions after discharge. This study corroborates what was previously known with data from the largest and most homogeneous cohort of patients to date.

**ES32-0360 -
Free Communication**

Should opportunistic salpingectomy be performed in all abdominal surgeries for ovarian cancer prevention?

Mariona Rius Dorca¹, Meritxell Gracia¹, Cristian deGuirior¹, Maria-Angeles Martinez-Zamora¹, Marta Camacho¹, Francisco Carmona¹

¹Hospital Clinic, Gynecology Department- ICGON, Barcelona, Spain

Background

Epithelial ovarian cancer (OC), and mostly high-grade serous ovarian carcinoma (HGSOC), is the first cause of death due to gynaecologic malignancy among women. Since 2010, after Kurman and Shih developed a unified theory of the role of distal Fallopian tube in the pathogenesis of HGSOC, most of the gynaecological societies recommend to perform bilateral opportunistic salpingectomy (OS) in benign gynaecological procedures such as hysterectomy, sterilization or after C-section. However, there is no formal recommendation regarding OS in case of abdominal surgery (i.e., cholecystectomy or appendicectomy). The objective of this study is to describe the evidence of OS in the OC prevention and its impact on menopause onset and surgical complications.

Methods

We reviewed all data published to our knowledge regarding OS for ovarian cancer prevention as well as its impact on ovarian reserve, early menopause onset and surgical complications.

Results

According to McAlpine et al, OS does not increase the surgical time, the complications rates, the hospital stay or risk of readmission. Regarding the impact on ovarian reserve, in a recent study published by Wang and Gu, who analysed ovarian reserve markers (antimüllerian hormone (AMH), FSH, LH levels and antral follicular count) before surgery (hysterectomy with OS) and after (3 and 9 months), did not find differences in any of the ovarian reserve markers. The same findings were confirmed by Vahedpour et al, where they did not find differences in AMH levels before and after surgery. Regarding the early onset of menopause, a group from Canada did not find early onset of menopause nor menopause related symptoms. In a nationwide case and control study in Sweden, salpingectomy was associated with reduced risk of OC. Naumann et al created a model to simulate the risk of OC and OC mortality to calculate lifetime costs associated with OS and OC. They estimated that OS will be effective in reducing the number of future OC cases, reducing healthcare costs and mortality at the same time. According to their model, OS at the time of tubal ligation will reduce OC mortality by 8.13%; OS at the time of hysterectomy will reduce OC mortality by 6.34% for a combined decrease of 14.5%. Thus, OS will prevent 1,854 deaths per year from OC and save \$392 million per year. Moreover, and taking one step forward, Tomasch et al demonstrated that OS when cholecystectomy is performed only increased a median of 13 minutes the surgical time and it is not related to intra or postoperative complications.

Conclusions

In the absence of definite long-term data, OS is safe, effective and feasible at the time of any abdominal surgery as an OC prevention strategy and it should be offered to all women after extensively and comprehensive counselling.

**ES32-0408 -
Free Communication**

Laparoscopic loop sacrohysteropexy: a step-by step video presentation and important anatomical considerations

Gregor Prša¹, Nika Prša², Igor But³, Tamara Serdinšek³

¹General Hospital Murska Sobota, Department of Gynecology and Obstetrics, Murska Sobota, Slovenia

²Faculty of Natural Sciences and Engineering, Department of Textiles- Graphic Arts and Design, Ljubljana, Slovenia

³University Hospital Maribor, General gynaecology and urological gynaecology, Maribor, Slovenia

Background

Laparoscopic sacrohysteropexy (LSH) is an efficient surgical treatment for pelvic organ prolapse (POP) with low reoperation rate, high patient-reported satisfaction rate, and good anatomical results. However, the procedure is technically demanding and can have life-threatening complications, especially during the dissection of the sacral promontory. Our aim was to create an instructional video of laparoscopic loop sacrohysteropexy (LLSP) with the emphasis on the important anatomical structures.

Methods

Using graphic design software and the existing anatomical literature, we created an instructional video that depicts the main steps of LLSP with important anatomical considerations.

Results

During LLSH, dissection of the promontory is performed to expose the anterior longitudinal ligament for mesh fixation. Then, the peritoneum is opened towards the right sacrouterine ligament (SUL) and above the cervix. Both broad ligaments (BL) are opened through the avascular area and the incision of the peritoneum in the vesico-uterine fold is made. The mesh is introduced through the window in the right BL, over the anterior cervix, through the window in the left BL and then sutured together to the superior portion of the right SUL. Additionally, mesh is fixated to the left SUL. Peritoneum in the vesico-uterine fold and above the posterior cervix is sutured before attachment of the mesh to the promontory under slight tension. The remaining part of the peritoneum is closed. We have previously shown that this approach is comparable to classic LSH in terms of medium-term success rates.

Conclusions

Laparoscopic treatment of POP is safe and effective. However, the surgeon needs to obtain necessary anatomical knowledge and laparoscopic skills to avoid possible dangerous complications.

<https://player.vimeo.com/video/831639736?autoplay=1>

Total mesenteric excision surgical plane for the excision of severe endometriosis

George Goumalatsos¹, Arcot Venkatasubramaniam², Janani Sankar¹, Victoria Philippa Smith¹

¹Basingstoke Hospital NHS Trust, Endometriosis centre- Obstetrics & Gynaecology, Basingstoke, United Kingdom

²Basingstoke Hospital NHS Trust, Peritoneal Malignancy Institute, Basingstoke, United Kingdom

Background

The Total Mesenteric Excision surgical plane was first described by Professor RJ Heald in 1982 at Basingstoke Hospital and it has been demonstrated to minimise rectal cancer recurrence. In our endometriosis centre at Basingstoke Hospital, we perform our laparoscopic excisions of severe endometriosis in conjunction with the colorectal team of the Peritoneal Malignancy Institute, an internationally known and experienced team in the treatment of peritoneal disease. We routinely use the TME approach for complete excision of severe endometriosis with excellent results.

Methods

Using a compilation of operation footage of patients with severe endometriosis, requiring anterior bowel resection for transmural bowel involvement, we demonstrate the basic principles and steps of this technique. Using advanced video editing techniques we annotate the anatomical planes involved in the TME approach for excision of severe endometriosis on a step-by-step approach.

The TME begins by finding the entrance to Heald's "holy plane." The sigmoid colon is lifted to allow dissection of the mesenteric peritoneum and gain access to the plane between the Inferior Mesenteric Vessels and the gonadal vessels, ureter and nerves. The vessels are identified and ligated and the nerves around them are preserved. The dissection continues towards the pelvis in the plane anterior to the presacral fascia. The upwards traction of the mesorectum helps to identify the hypogastric plexuses and hypogastric nerves which travel to the lateral pelvic sidewalls. The mesorectum is divided and the rectum fully mobilised. Depending on the position of the endometriotic nodule/nodules, the rectum is divided, the disease is excised and the anastomosis ensues. Tips and tricks on tissue handling, angles of dissection, modes of electrosurgery used are clearly demonstrated.

Results

The TME plane is a haemostatic plane allowing clear identification of the important anatomical structures. Bowel resection is performed with excellent postoperative recovery as the nerves are being preserved. This leads to lower incidence of bowel and bladder control loss and vaginal lubrication. It also allows for 'en block' removal of the disease. Our patients have a quick recovery, are discharged home within 48-72 hours after surgery with significant improvement of their symptoms and quality of life.

Conclusions

The TME plane is the gold standard for rectal dissection for the treatment of bowel cancer. Its principles can be used in the gynaecological laparoscopic management of severe endometriosis where every opportunity should be taken to preserve normal function and minimise nerve damage with detrimental effects on bladder and bowel control and sexual function.

Consequences of a new national guideline advocating expectant management for benign-looking ovarian tumors

Esther Lems¹, Anna H. Koch², Sam Armbrust¹, Marlies Y. Bongers¹, Christianne A.R. Lok², Peggy M.A.J. Geomini¹

¹*Máxima Medical Centre, Department of Gynaecology & Obstetrics, Veldhoven, The Netherlands*

²*The Netherlands Cancer Institute/Antoni van Leeuwenhoek Hospital, Department of Gynaecologic Oncology, Amsterdam, The Netherlands*

Background

In recent years, increasing evidence shows that conservative management of specific benign-looking ovarian tumours is safe. Therefore, conservative management of benign-looking ovarian tumours was adopted as a treatment option in the Dutch guideline in 2013. The extend of implementation of the guideline is reflected by a change in number of surgically removed benign ovarian tumours.

Methods

The national Dutch pathology registration system PALGA (Pathologic-Anatomic National Computerized Archive) registers all tissue diagnoses in The Netherlands. All reports on surgically removed adnexal masses and tubes in 2011 (before guidelines change) and in 2019 (after adaptation of guideline) were requested. Reports on prophylactic removed adnexa were excluded. The histopathological diagnosis of all included reports was recorded. Interobserver variability between researchers was checked with Cohen's Kappa.

Results

A total of n=34,932 reports were retrieved of which 17,017 reports were included. In respectively 2011 and 2019 6,553 (83.9%) vs 4,956 (78.8%) reports on benign adnexal masses were recorded and 1260 (16.1%) vs 1331 (21.2%) borderline and malignant tumours. The number of surgically removed benign ovarian tumours declined with 24.4% (p<0.001). The most substantial decrease between 2011 and 2019 was seen in the number of surgically removed serous cystadenomas (-37%; n=1406 vs n=884; p<0.05), endometriomas (-29.7%; n=983 vs n=691; p<0.05), simple epithelial cysts (-57%; n=567 vs n=240; p<0.05) and corpus luteum cysts (-60.0%; n=272 vs n=108; p<0.05). Cohen's Kappa for the analysed variables was 0.96.

Conclusions

Despite a growing population, the number of surgically removed benign ovarian tumours has significantly decreased in the last decade in the Netherlands, suggesting that the new guideline has been implemented well and conservative management was chosen more often. Furthermore, no absolute increase in malignancies was observed. These findings support that implementing conservative management for benign-looking ovarian tumours has been successful.

**ES32-0631 -
Free Communication**

Step by step laparoscopic removing migrated intrauterine device involving ureter

Taisiia Melnychuk¹, Rocio Luna¹, Ignasi Montoro¹, Noelia Rams¹, Irene Mora¹, Ramón Rovira¹
¹Hospital de la Santa Creu i Sant Pau, Gynecology, Barcelona, Spain

Background

To describe and demonstrate step by step technique for laparoscopic removal of a perforating intrauterine device (IUD) involving ureter, and to provide key points to improve laparoscopic management.

Methods

Video presentation of the step-by-step technique for laparoscopic removal of a perforating IUD involving ureter.

Department of Gynecology, Hospital de la Santa Creu i Sant Pau. Barcelona. Spain.

Results

A 33-year-old woman, gravida 1, para 1, with a copper T IUD inserted by her gynaecologist 18 months before the surgery. The patient returned 3 month after IUD insertion complaining of abdominal pain. Transvaginal ultrasound revealed IUD strings inside the uterus while IUD perforating the left adnexa, which was confirmed by pelvic radiography. The patient underwent standard bowel preparation before the surgery. The surgical technique involves visualization of abdominal cavity, identification and extraction of perforating IUD, restoration of the anatomy of ureter developing Latzko's space and Okabayashi's space and, finally, extraction of IUD using endobag through umbilical access. Posteriorly, intraoperative leak test to ensure the integrity of colorectum was performed. The procedure was uneventful and the patient was discharged on the second day after the surgery.

Conclusions

The improvement of management of perforating IUD is based on prompt laparoscopic removal to diminish inflammatory response and adhesion formation. Preoperative assessment should include pelvic transvaginal ultrasound and pelvic radiography or computed tomography scan. Preoperative bowel preparation is advised in patients with suspicious of bowel involvement. Finally, knowledge of the anatomy and use of wound mobilization device facilitate the exposure for proper adhesiolysis.

<https://player.vimeo.com/video/831670244?autoplay=1>

Quality improvement project assessing patient views on the outpatient hysteroscopy service

Helen Stevenson¹, Sabita Nair¹

¹New Cross Hospital, Gynaecology, Wolverhampton, United Kingdom

Background

A one-stop see-and-treat outpatient hysteroscopy service has clear clinical and economic benefits for patients with more rapid mobilisation and similar patient satisfaction to the same procedure being performed with a general anaesthetic. We offer an outpatient see-and-treat hysteroscopy service 5 days/week that includes outpatient procedures such as coil insertion/retrieval, myomectomy, polypectomy and endometrial ablation. We aimed to assess patient satisfaction with this service and patient views on the information and analgesia offered to see if we are meeting the rcog greentop guideline recommended standards and if improvements can be made to the patient experience

Methods

A questionnaire was designed based on the standard patient satisfaction questionnaire set by the British Society for Gynaecological Endoscopy. This was offered to 80 patients after they had undergone an outpatient hysteroscopy +/- procedure. This included all clinics and consultants within our NHS trust.

Results

80% of women received written information before the procedure and of these 79% felt the information was clear. Of those who received information regarding analgesia, 22% did not

take any and 16% of these women wished they had.

97.5% felt the environment was excellent or good. 94% were happy they had been offered pain relief including a general anaesthetic. During the procedure 53% had none or slight pain and the average pain score was reported as 5.3 out of 10 compared with an average pain score of 5.6 for a normal period. 94% reported they would have the same procedure again.

Conclusions

Improvements can always be made, however overall the service is performing well with 100% of women who underwent an outpatient hysteroscopy at our trust rating the overall service as good or very good. Most felt comfortable throughout and that they were treated with dignity and respect. There were some women who did not receive information prior to the appointment and this is essential to ensuring they feel they have time to consider all options for the treatment including a general anaesthetic. It is difficult to send information in time for rapid access cancer referrals who are seen very quickly and we may need to look at alternative options such as online information received via text message the day before.

An outpatient hysteroscopy service should be available for all women referred for investigation of abnormal uterine bleeding. It appears to be acceptable with high patient satisfaction rates. Alternatives including a general anaesthetic should be offered to all women and information regarding the options ideally read prior to the appointment so they have time to make the decision and know what to expect. This would improve patient satisfaction further.

Hysteroscopic anaesthesia: validation and description of a new method in office hysteroscopy

Mariana Lourenço¹, João Maires², Patrícia Di Martino²

¹Hospital Vila Franca de Xira, Gynaecology, Lisbon, Portugal

²Hospital das Forças Armadas, Gynaecology, Lisbon, Portugal

Background

Office hysteroscopy is a safe and effective procedure for visualization and surgical approach of intracavitary diseases. Considered to be a standard technique, it allows to avoid risks and complications associated with patient's hospitalization. Pain is one of the primary reasons for not completing the procedure, so that the concern with its reduction has been the subject of many studies.

The purpose of this study was to describe an intracavitary anaesthetic technique and demonstrate its effectiveness and safety in controlling pain during office hysteroscopy.

Methods

This is a retrospective study with eight hundred fifty-nine patients who underwent office hysteroscopy at two specialized units. The total of patients was submitted to office hysteroscopy for diagnostic or surgical purpose. Those who reported pain during the procedure were offered anaesthesia, which was immediately performed. By using an endoscopic needle, hysteroscopic anaesthesia was administered in specific sites with precise application guidelines. After the hysteroscopy, the intensity of the patient's pain during the procedure was assessed by a numeric survey, regardless of having received hysteroscopic anaesthesia. The doctor responsible was also invited to rate patient's reported pain reliability by a numeric scale.

Results

When using hysteroscopic anaesthesia, office hysteroscopy was completed in 94.3% of the cases, however there were no significant differences regarding the number of completed procedures between those and the ones who didn't received. However, in women submitted to hysteroscopic anaesthesia, the reduction in reported pain was significant, with a more noticeable effect in those who reported a higher pain score before the technique. There were no complications related to hysteroscopic anaesthesia.

Conclusions

Hysteroscopic anaesthesia is an effective and safe method for pain control during office procedures and might be considered when performing this technique. Its use can provide a greater comfort to the patient and allows to avoid risks associated with the operating room.

Embryofetoscopy combined with hysteroscopic evacuation of first-trimester miscarriages with tissue removal device in outpatient setting: a pilot study

Maria Chiara De Angelis¹, Alfonso Manzi², Viola Vargiu³, Chiara Colucci⁴, Alessandra Gallo², Brunella Zizolfi²

¹*University of Naples Federico II, Department of Public Health, Naples, Italy*

²*University of Naples " Federico II", Department of Public Health, Naples, Italy*

³*University of Florence, Department of Health Sciences, Florence, Italy*

⁴*University of Florence, Department of Health Sciences, Florence, Italy*

Background

To evaluate the efficacy of outpatient embryofetoscopy in detecting genetic anomalies and the feasibility of subsequent outpatient hysteroscopic evacuation in cases of first-trimester miscarriage using Tissue Removal Device.

Methods

A prospective observational study was conducted at University of Naples "Federico II". Patients with ultrasonographic diagnosis of first-trimester miscarriage at a gestation age of below 11 weeks were enrolled. Multiple pregnancies were excluded. Patients underwent embryofetoscopy by hysteroscopic sampling of embryo, chorionic villi and gestational sac using a 5-mm Bettocchi continuous-flow hysteroscope and 5 Fr miniaturized instruments (bipolar electrode and grasping forceps). Samples were subsequently processed for karyotype analysis. After sampling of embryonic tissue, evacuation using TruClear 5C and Truclear Eliti Mini was carried out. At the end of the procedure, a transvaginal scan confirm the complete evacuation of uterine cavity. Both procedures were performed in outpatient setting, without any kind of sedation or anaesthesia and any dilation of cervix. Finally, patients were scheduled for ultrasonographic scan at 4 weeks and outpatient diagnostic hysteroscopic at 6 weeks to evaluate the presence of any retained product of conception (RPOC) and post-surgical adhesions.

Results

Ten patients were enrolled. In all cases the samples were adequate for genetic examination. All patients underwent a complete evacuation of uterine cavity, without any complication. The mean duration of the entire procedure was 30 minutes. At 4-weeks follow-up no endometrial thickness suggesting for RPOC was observed at ultrasonography; at 6 weeks follow-up diagnostic hysteroscopy was negative for the presence of adhesions in all cases. At karyotype analysis, chromosomal aberrations were identified in 70 % (7/10) of women, 3/10 (30%) cases showed a normal karyotype; in 5/10 (50%) of cases, the chromosomal abnormality was a trisomy. In 1 case (10%) was detected a monosomy and in 1 case (10%) a deletion. The mean maternal age was higher in patients with trisomy 15 (40 y.o) and trisomy 20 (41y.o).

Conclusions

Our data confirmed the detection rate of genetic anomalies in cases of spontaneous first-trimester miscarriages performing embryofetoscopy. Otherwise, outpatient hysteroscopy using Tissue Removal Device has proven to be a safe and feasible procedure, allowing to successfully obtain a complete evacuation of uterine cavity, avoiding recurrence of RPOC and post-surgical adhesions. Further studies are needed to define this new minimally invasive approach.

Comparative characteristics of the effect of mono and bipolar energy during hysteroscopy

Anna Novosad¹, Oleg Golyanovsky², Olexandr Voloshyn²

¹Oberig clinic, Women health department, Kiev, Ukraine

²Shupik National Healthcare University of Ukraine, Department of Obstetrics and Gynecology No.1, Kyiv, Ukraine

Background

Hysteroscopy is the main method of diagnosis and treatment of intrauterine pathology. Since the advantages of this technique are undeniable, the number of procedures increases every year, which leads to constant improvement of tools and techniques. The main types of energy used in hysteroscopy are mono and bipolar, which allows you to individually approach the choice of technique in each case and prevent possible complications and improve fertility. The monopolar electrode was the first electrode developed for resectoscopy, and required non-electrolyte solutions, that can cause changes in electrolytes. Mini-hysteroscopes with bipolar electrodes due to the physiological solutions can reduce the risk of electric burns due to the close location of the electrodes and a violation of the electrolyte balance.

Objective: The study was conducted to evaluate the results after hysteroscopic surgery using monopolar or bipolar electrodes.

Methods

80 patients participating in this study were divided into two groups: one for hysteroscopic surgery using a bipolar electrode and the other group using a monopolar electrode.

Operative complications; bleeding, perforation, fluidoverload, and hyponatremia were reported. The time of surgery and hospital stay is also taken into account.

Results

There were no statistically significant differences between the two groups in patient characteristics, ultrasound findings, preoperative serum sodium levels, perforation, and intraoperative bleeding. Fluid overload was significantly higher in the monopolar group (p value = 0.03), postoperative hyponatremia was significantly more pronounced in the monopolar group ($p < 0.05$), and changes in serum sodium levels were not significantly different in the monopolar group compared to the bipolar group ($p = 0.01$). The mean operative time was significantly shorter in the bipolar group compared to the monopolar group ($p = 0.01$), and the hospital stay was apparently shorter for patients in the bipolar group compared to the monopolar group ($p = 0.04$).

Conclusions

Operative hysteroscopy with the use of bipolar electrodes is accompanied by a significant reduction in hyponatremia, the duration of the operation and the stay in the hospital after the operation. Thus, it is a safe and effective method compared to the use of monopolar electrodes.

**ES32-0075 -
Free Communication**

Hysteroscopic removal of submucous myoma located at the uterine fundus using 12-Fr cold instruments

Dan Sun¹, Zengzi Zhou¹, Gloria Nuer-Allornuvor², Huan Huang¹, Dabao Xu¹

¹The Third Xiangya Hospital of the Central South University, Obstetrics and Gynecology, Changsha, China

²Cape Coast Teaching Hospital, Obstetrics and Gynecology, Cape Coast, Ghana

Background

To present a surgical technique using a combination of types of 12-French (Fr) cold instruments (scissors and forceps) to remove a type I submucous myoma located at the uterine fundus.

Methods

A case 44-year old woman, G₃P₁A₂, with two episodes of failed in vitro fertilization and embryo transfer (IVF-ET), has fertility desire. Preoperative magnetic resonance imaging (MRI) revealed a 15*15*18mm³ type I submucous myoma located at the fundus of uterus. First, a diagnostic hysteroscope was used to explore the uterine cavity, and separate the adhesions between the myoma and uterine wall. Next, we replaced it with an operative Z-shaped hysteroscope with an outer sheath diameter of 8.8 mm and a 12-Fr working channel. The surgical steps mainly included: (1) a 12-Fr single action scissors was used to cut the capsule on the surface of myoma, and to cut the myoma into four parts; (2) a 12-Fr single action Allis tissue forceps was employed to remove hard lobulated myoma tissues in pieces; (3) a 12-Fr double action blunt head grasping forceps, and a 12-Fr double action spoon-shaped forceps were used to remove soft residual myoma tissues; (4) hysteroscopic adhesiolysis was performed using a 12-Fr scissors; (5) a follow-up hysteroscopy was performed 3 months later.

Results

The submucous uterine myoma was totally removed without uterine perforation and any obvious bleeding, and the capsule was completely preserved. The 12-Fr cold instruments are powerful that the myoma was quickly (18'18") and safely removed. The operator can choose different types of instruments according to the complexity of each situation. The most important thing is that the endometrium has been well protected. The total amount of bleeding was about 20ml. The follow-up hysteroscopy 3 month postoperatively revealed the wound healed well with no recurrence of submucous uterine myoma and intrauterine adhesions (IUA). The patient finally achieved pregnancy.

Conclusions

Submucous uterine myoma located at the uterine fundus which may be difficult to remove using a resectoscope, can be removed quite easily using the 12-Fr cold instruments. The technique is simple, safe and effective. This new technique also helps in protecting the endometrium and worthy of further study.

<https://player.vimeo.com/video/825071700?autoplay=1>

**ES32-0304 -
Free Communication**

Office hysteroscopic treatment of early pregnancy loss

Tanvir Singh¹, Meeta meeta¹, Akanshi Singh¹

¹Tanvir Hospital, Obgyn, Hyderabad, India

Background

Hysteroscopic resection(HR) of retained products of conception has been well described in the literature. Here we would like to demonstrate HR of early pregnancy loss / missed abortion.

Methods

A step wise demonstration of the techniques for hysteroscopic resection of early pregnancy loss using 5fr mechanical instruments via a 5 mm Bettocchi hysteroscope and hysteroscopic tissue removal system in office without anaesthesia

Results

Case one is a 41 year old with early pregnancy loss of 7 weeks with Type 2 adhesion and diffuse adenomyosis. Preoperative transvaginal ultrasound showed minimal vascularity on doppler study and hence we chose to remove the products of conception using 5fr instruments via the working channel of the Bettocchi hysteroscope. Intrauterine pressure were maintained at 80 mmHg using a Hamou hysteromat with normal saline as the distension media. Hysteroscope was advanced by vaginoscopic technique, through the cervical canal into the uterine cavity. The products of conception were removed with 5fr scissors by excising it from the base and removing the tissue from the uterine cavity by a 5 fr tenaculum. The intrauterine adhesion (IUA) and a biopsy of 0.5 cm of an adenomyoma was obtained simultaneously. The visual analogue score (VAS) was pain was 2.

Case 2 demonstrates the use of truclear elite in a 28 year old with early pregnancy loss of 8 weeks ,with an transvaginal ultrasound showing a moderate flow of vascularity on doppler study.

6 mm truclear elite was advanced via vaginoscopic technique using normal saline via the Hamou hysteromat. A 2.9 mm incisor with a cutting and suction action to remove the products of conception. The VAS of pain was 0.

Conclusions

In both cases, targeted excision was achieved in the office without anaesthesia. In the first case, we were simultaneous able to diagnose adenomyosis and treat IUA. The rest of the endometrium was untouched by this technique.

<https://player.vimeo.com/video/826992789?autoplay=1>

Hysteroscopic transillumination as a guide for laparoscopic excision of rudimentary uterine horn: a winning duo

Agnese Virgilio¹, Stefano Ferla¹, Alessandro Arena¹, Paolo Salucci², Renato Seracchioli¹, Paolo Casadio²

¹Division of Gynecology and Human Reproduction Physiopathology- IRCCS Azienda Ospedaliero-Universitaria di Bologna- Bologna- Italy,

Department of Medical and Surgical Sciences DIMEC- University of Bologna- Bologna- Italy, Bologna, Italy

²IRCCS Azienda Ospedaliero-Universitaria di Bologna,

Division of Gynaecology and Human Reproduction Physiopathology- IRCCS Azienda Ospedaliero-Universitaria di Bologna-, Bologna, Italy

Background

Anatomic anomalies of the female reproductive genital tract affect about 5.5% of women. The Hemi-uterus or class U4 by the ESHRE/ESGE 2013 classification is a rare congenital malformation defined as a unilateral uterine development, with a contralateral part that could be either incompletely formed or absent. This class is divided into two sub-classes depending on the presence or not of a functional rudimentary cavity (U4a/U4b). Aim of this work is to share our experience performing an hysteroscopic and laparoscopic combined technique to surgically manage this uterine malformation exploiting the hysteroscopic transillumination.

Methods

A step-by-step explanation of the technique highlighting the anatomic landmark that guides the procedure is presented. A 32-year-old woman with severe dysmenorrhea and chronic pelvic pain was referred to our centre. A U4a uterine malformation was diagnosed by 2D/3D transvaginal ultrasound and confirmed by magnetic resonance imaging (MRI). Complementary diagnostic hysteroscopy was also performed. The patient was scheduled for laparoscopic removal of the right uterine horn and ipsilateral salpingectomy exploiting the contemporary hysteroscopic transillumination guidance. We selected this approach to avoid possible complications due to the anatomical anomalies that are very common in these cases. After coagulation and section of the right round ligament at the uterine angle and opening of the right broad ligament, the access to the retroperitoneum was obtained to direct visualize the entire course of ureter and the uterine artery. The right uterine artery was coagulated and sectioned at the uterus. Then, the right uterine horn was isolated and removed using a monopolar hook, taking care to preserve an adequate amount myometrium. A double layer running suture with barbed absorbable thread (V-Lock) for reconstructive-plastic purposes was carried out. The specimen was retrieved inside an endo bag to allow a safe extraction. Right salpingectomy was then performed.

Results

Intraoperative and postoperative periods were uneventful. Patient was discharged two days after surgery. At three months follow up no pain and regular menses were reported, an hysteroscopic evaluation of the left hemi-uterus was performed to assess the lack of distortion of the cavity. Considering the great anatomic variability of this condition, this type of surgery is not always simple: indeed, the borders between the uterus and the rudimentary uterine horn are often not perfectly recognizable; this can lead to accidental removal of healthy myometrium and increase the risk of perioperative bleeding. In our experience the combined hysteroscopic and laparoscopic combined technique allows the surgeon to better delimit the borders of the hemi-uterus, providing a more conservative and safer surgery.

Conclusions

Hysteroscopic transillumination offers the possibility to modulate the radicality in the resection of the rudimentary horn and in the final treatment of the dysmorphism.

<https://player.vimeo.com/video/831674502?autoplay=1>

**ES32-0429 -
Free Communication**

Hysteroscopic treatment of recidivant hematometra using a cervical stent

*Marta Tortajada¹, Meritxell Munmany¹, Cristian de Guirior¹, Maria Angels Martinez-Zamora¹, Mariona Rius¹,
Francisco Carmona¹*

¹Hospital Clinic Barcelona, Gynecology, Barcelona, Spain

Background

To describe the treatment of recidivant hematometra in a young patient with hysteroscopic approach

Methods

A 40-year-old patient came to our centre with recidivant hematometra due to cervical stenosis after uterine surgery (laparoscopic myomectomy in another centre). She had already a previous hysteroscopic surgery due to cervical stenosis causing hematometra and pelvic pain to the patient. Afterwards she was put under medical treatment (continuous contraceptive pills). However, the patient persisted with pelvic pain and she was referred to our unit.

Results

A transvaginal ultrasound scan (TVUS) was performed showing a AVF uterus with hematometra of 129x50x99mm. She also had a left hematosalpinx of 122x64x58mm. As the patient was unresponsive to the medical treatment, a hysteroscopic surgery was planned and a cervical stent was placed after opening the stenosis in order to avoid restenosis of the cervical canal. The stent we used is a Wallflex Fully Covered System of 60x8mm. The procedure was assisted by ultrasound guidance.

Conclusions

Placing a cervical stent in cases of recidivant cervical stenosis after a conservative approach (medical treatment, adhesiolysis with resectoscope) can be considered in symptomatic (pelvic pain).

<https://player.vimeo.com/video/827087418?autoplay=1>

**ES32-0497 -
Free Communication**

Surgical correction of intrauterine synechiae after fertility-sparing, abdominal radical trachelectomy as treatment for cervical cancer

Mariana Bohne¹, Caroline Batista Pinheiro¹, André Lopes de Farias e Silva¹, Paula Deckers¹, Gabriel Lowndes de Souza Pinto Lowndes de Souza Pinto¹, Mayara Galli Silva dos Reis¹

¹*Brazilian Institute for Cancer Control IBCC, Oncology, Sao Paulo, Brazil*

Background

To report the case of a 36 year-old woman who developed secondary amenorrhea after fertility-sparing, abdominal radical trachelectomy for FIGO 2018 stage IB1 cervical adenocarcinoma. After preliminary clinical investigation, the patient underwent diagnostic hysteroscopy with concomitant laparoscopy.

Methods

The surgical procedure began with diagnostic hysteroscopy using 2.9 mm optics and an operative hysteroscopy sheath. After entering the external ostium of the remaining cervical canal, stenosis of the internal ostium was overcome with continued infusion of saline solution and slow advancement of the operative sheath. Upon advancing, uterine adhesions were observed in the uterine cavity.

Laparoscopy was concomitantly performed as a means of visualizing the uterine fundus, avoiding uterine perforation and lesions to intrapelvic organs. The position of the hysteroscopic optics in the uterus was visible during laparoscopy through transillumination.

Blunt dissection of the region adjacent to the right tubal ostium, obliterated by fibrotic tissue, was performed. The white colour and thread-like texture of the adhesion bands were identified and the fibres of the adhesion bands were lysed.

Five-French scissors were used for probing and lysing the synechiae. Uterine cavity distention with saline solution also aided visualization of the lacunae formed between the fibrotic bands.

After removal of the intrauterine adhesions, methylene blue was injected into the uterine cavity to assess tubal patency. The methylene blue permeated the full extension of both uterine tubes and overflowed into the peritoneal cavity bilaterally.

Results

Using hysteroscopy and concomitant laparoscopy, the intrauterine adhesions were removed. The Cotte Test with methylene blue was performed. The result was a positive Cotte test bilaterally.

Conclusions

Surgical hysteroscopy with concomitant laparoscopy may be a good method for correction of intrauterine synechiae in technically challenging cases to avoid lesions to the myometrium and intrapelvic organs and to avoid creation of false passages in the cervical canal. Further studies are needed to determine the outcome of this approach.

<https://player.vimeo.com/video/831385316?autoplay=1>

**ES32-0503 -
Free Communication**

Complete uterine septum, cervical septum and longitudinal vaginal septum: a challenging differential diagnosis with double cervixes and an integrated approach for endoscopic treatment

Federica Bernardini¹, Filippo Maria Capomacchia², Federica Pozzati³, Antonia Carla Testa², Giovanni Scambia², Ursula Catena³

¹Fondazione Policlinico Universitario Agostino Gemelli IRCCS,

Department of Obstetrics and Gynecology- Division of Gynecologic Oncology, Rome, Italy

²Catholic University of Sacred Heart,

Department of Obstetrics and Gynecology- Division of Gynecologic Oncology, Rome, Italy

³Fondazione Policlinico Universitario Agostino Gemelli- IRCCS,

Department of Obstetrics and Gynecology- Division of Gynecologic Oncology, Rome, Italy

Background

A complete uterine septum, cervical septum and longitudinal vaginal septum is a complex and rare congenital genital tract anomaly. The diagnosis is often challenging and based on the combination of different diagnostic techniques and multiple treatment steps. We propose an ultrasound-guided endoscopic treatment of complete uterine septum, cervical septum and longitudinal vaginal septum anomaly.

Methods

stepwise demonstration with narrated video footage of an integrated approach management of a complete uterine septum, cervical septum and vaginal longitudinal septum treated by expert operators combining minimally invasive hysteroscopy and ultrasound. The patient was 23 years old and was referred to our clinic because of dyspareunia, infertility and the suspicion of a genital malformation.

Results

A complete evaluation of uterine cavity, external profile, cervix and vagina made through 2D-3D ultrasound combined with office hysteroscopy was performed and a U2bC1V1 malformation (according to ESHRE/ESGE classification) was diagnosed. The surgical procedure consisted in a totally endoscopic removal of the vaginal longitudinal septum, the cervical septum and the complete uterine septum under transabdominal ultrasound guidance. The procedure was performed in the Digital Hysteroscopic Clinic (DHC) CLASS Hysteroscopy in Fondazione Policlinico Gemelli IRCCS of Rome - Italy, under general anaesthesia (laryngeal mask) according to an ambulatory model of care. The procedure was successfully performed without complications and the patient was discharged three hours after the procedure.

Conclusions

Integrated ultrasound and hysteroscopic approach allows an accurate diagnosis and a totally endoscopic treatment of a complex congenital malformation using an ambulatory model of care with optimal surgical results.

<https://player.vimeo.com/video/831426124?autoplay=1>

**ES32-0549 -
Free Communication**

The role of diagnostic hysteroscopy in the diagnosis of recurrent pregnancy loss

Salem K Joseph², Omar M Abuzeid², Mostafa Abuzeid¹

¹IVF Michigan Rochester Hills & Flint- PC,

*Reproductive Endocrinology and Infertility- Michigan State University College of Human Medicine,
Rochester Hills- Michigan, USA*

*²IVF Michigan Rochester Hills & Flint- PC, Reproductive Endocrinology and Infertility,
Rochester Hills- Michigan, USA*

Background

The Role of Diagnostic Hysteroscopy in the Diagnosis of Recurrent Pregnancy Loss

Joseph Salem K, MS, MBA, BS Abuzeid Omar M, MD, Abuzeid Mostafa I, MD

IVF Michigan Rochester Hills & Flint PC, Rochester Hills, MI, USA

Objectives: The aim of this video presentation is to demonstrate the presence of a partial septate uterus (PSU) on hysteroscopy in a patient with recurrent pregnancy loss (RPL) and a normal transvaginal 3D ultrasound (TV 3D US) with saline infusion sonohysterogram (SIH).

Methods

Methods: This video describes the management of a patient who presented with unexplained RPL and a normal TV 3D US with SIH. Hysterosalpingogram study suggested PSU. A diagnostic hysteroscopy was performed to rule out PSU.

Results

Results: The diagnosis of PSU was made on during hysteroscopy and hysteroscopic metroplasty was performed at the same session.

Conclusions

Conclusion: In patients with RPL, a diagnostic hysteroscopy should be performed to rule out PSU even when TV 3D US/SIH is normal.

<https://player.vimeo.com/video/831584305?autoplay=1>

**ES32-0580 -
Free Communication**

A case of misdiagnosed angular pregnancy with retained product of conception successfully treated with hysteroscopic morcellation

Michela Dell'Aquila¹, Giuseppe D'Angelo¹, Maria Giuseppina Trinchillo¹, Alessandra Gallo², Brunella Zizolffi², Maria Chiara De Angelis²

¹*University of Naples Federico II,*

Department of Neuroscience- Reproductive Sciences and Dentistry- School of Medicine, Naples, Italy

²*University of Naples Federico II, Department of Public Health, Naples, Italy*

Background

To report a case of misdiagnosed angular pregnancy with retained product of conception (RPOC) successfully managed by conservative hysteroscopic approach by means of Tissue Removal Device (TRD).

Methods

A 27-year-old woman was referred to our Hysteroscopic Unit with a suspicion of RPOC in a septate uterus. The patient had two previous spontaneous abortions. Three months before, the diagnosis of a first-trimester miscarriage was made during her third pregnancy and dilation and curettage (D&C) was performed. Severe menometrorrhagia was referred immediately after D&C. Beta-HCG was negative. Our 2D and 3D transvaginal ultrasound scan revealed the presence of RPOC in the right angle of the uterus and a small indentation of the uterus. Outpatient hysteroscopy confirmed the small indentation and a 2 cm area of yellowish-white placental remnants protruding from the right tubal ostium. By vaginoscopy, without any cervical dilatation, a 5 mm tissue removal device was introduced and an hysteroscopic morcellation was carried out.

Results

The RPOC was completely removed using a TRD in an outpatient setting. A post-operative ultrasound revealed the complete removal of the pregnancy tissue. No intraoperative and postoperative complications were observed. The mean duration of the procedure was 10 minutes. Transvaginal ultrasound at 4 weeks follow-up showed a normal uterus without signs of injury to the uterine wall at the operative site. Histological analysis confirmed the diagnosis of chorionic villi and decidua tissue.

Conclusions

The minimally invasive option chosen by our centre using a TRD to remove RPOC in case of angular pregnancy allowed to successfully treat this condition by accomplishing it in a one-step procedure. Outpatient hysteroscopic morcellation can be considered a new, safe and effective alternative to traditional uterine curettage, considering the great advantage of direct vision, especially in cases where the risk of uterine perforation or incomplete evacuation is high as in angular pregnancy.

<https://player.vimeo.com/video/831635824?autoplay=1>

**ES32-0592 -
Free Communication**

Ultrasound-guided hysteroscopic management of endocervical atypical polypoid adenomyomas: a minimally-invasive approach for a fertility-sparing treatment

Eleonora La Fera¹, Giulia Zinicola², Andrea Scalera³, Francesco Fanfani², Giovanni Scambia², Ursula Catena²

*¹Fondazione Policlinico Universitario A. Gemelli- IRCCS,
Department of Woman and Child Health and Public Health, Rome, Italy*

*²Fondazione Policlinico Universitario Agostino Gemelli IRCCS,
Department of Woman and Child Health and Public Health, Rome, Italy*

³AOU Università degli studi della Campania L. Vanvi, Department of Gynecology and Obstetrics, Naples, Italy

Background

Atypical polypoid adenomyoma (APA) is a rare premalignant tumour of the uterus. The diagnosis is challenging. Final histological report is mandatory, even though the simultaneous use of hysteroscopy and ultrasound can help in the preoperative assessment. Conservative treatment has been proposed but it is not standardized. The best proposed option is complete hysteroscopic removal of the lesion, alone or in combination with hormonal therapy.

Methods

We retrospectively reviewed our dataset of patients that underwent conservative treatment for APA from January 2021 to March 2023. We identified 4 patients with an endocervical lesion. All procedures were performed in a one-stop approach, using hysteroscopy and transvaginal ultrasound (TV-US). The median age was 33 years old. In 3 out 4 patients a levonorgestrel intrauterine device was positioned after the procedure.

Results

We present a stepwise demonstration with narrated video footage of the technique used in our institution, in case of fertility-sparing treatment of endocervical APA. The lesion is removed according to these steps: 1) with a 90° angled loop of a 15 French bipolar mini-resectoscope the endoluminal portion of the lesion is removed, using the slicing technique; 2) with a straight cold loop, the intramural portion of the lesion is mobilized from the surrounding myometrium; 3) With the 90° angles loop the resection of the residual part is completed. Post-operative hysteroscopic control is performed 30 days after the primary procedure. Endocervical biopsy at the level of the previous lesion is always performed. Hysteroscopic controls were performed in all patients every 3 months with no evidence of recurrence at a median follow up time of 14 months.

Conclusions

TV-US guided hysteroscopic resection of endocervical APA appears to be a safe and effective minimally-invasive procedure in patients who want to preserve their fertility. Further studies are needed to define the reproductive outcomes of our population.

<https://player.vimeo.com/video/831647618?autoplay=1>

**ES32-0626 -
Free Communication**

Is there a place for endocervical block for pain relief in outpatient operative hysteroscopy?

Mihai Gherghe¹, Ajay Dhawle¹, Rishika Gidwani¹, Mohammed Allam¹

¹University Hospital Wishaw, Gynaecology, Glasgow, United Kingdom

Background

Outpatient (OP) hysteroscopy can be an anxiety inducing and painful experience for many women¹. This may be especially true when cervical dilatation is necessary. The use of a self-retaining speculum and a dental syringe at the paracervical block may by themselves increase patient anxiety, pain scores and lead to a negative overall experience. We propose an Endocervical block (ECB) as an alternative solution to provide pain relief during OP hysteroscopy.

Methods

A 56-year-old lady was listed for an OP hysteroscopy and endometrial polypectomy with endometrial biopsies. She had a stenosed cervix and a Mirena coil in situ. A zero-degree Omniscope diagnostic hysteroscopy showed an endometrial polyp and polypoidal looking endometrium.

We performed the ECB using a 23G disposable injecting needle (Cook Williams). Local anaesthetic Lidocaine 1% (8ml) was used. We used the Myosure operating sheath to introduce the needle and performed an endocervical block in 4 quadrants of endocervix. We used Myosure Lite device to dilate the cervix by taking down fibrous adhesions at the stenosed internal os.

Results

The lady underwent an endocervical block at her OP Hysteroscopy appointment. We were able to perform a Myosure Polypectomy and directed endometrial biopsies and the patient tolerated the procedure well with a pain score=3 and overall experience better than expectations and less painful than other outpatient local anaesthetic procedures (dental work or endoscopy).

Conclusions

The ECB reduces instrumentation, improves workflow and can be of significant benefit, especially in post-menopausal women with atrophic vagina, where a speculum examination is likely to be poorly tolerated.

<https://player.vimeo.com/video/833428431?autoplay=1>

**ES32-0221 -
Free Communication**

Office hysteroscopy for retained products of conception: our experience.

Leticia Delgado¹, Rocio Garcia-Berrio², Juan Jose Delgado², Juan Antonio Solano¹, Sofia Fenoll¹, Alvaro Zapico¹

¹Hospital Universitario Principe de Asturias, Obstetrics and Gynaecology, Alcalá de Henares, Spain

²Hospital Universitario Principe de Asturias, Obstetrics and Gynaecology, Alcalá de Henares, Spain

Background

The rate of retained products of conception (RPOC) is not well established, but its treatment has always been a challenge. For the last years, hysteroscopy has been used as a safer technique than the classical dilatation and curettage.

Methods

We performed a retrospective single-centre study of our experience between 2020 and 2022 with office hysteroscopy for the management of RPOC.

Results

19 patients were included in the study with a mean age of 33 years-old (24-40). The methods of pregnancy termination were: 43% vaginal delivery, 37% medical management of miscarriage, 15% surgical management of miscarriage after failure of medical management and 5% caesarean delivery. Mean time of procedure was 17 minutes (5-45). We removed the RPOC with TruClear® device in 15 cases (79%), scissors were used in 3 patients (16%) and VersaPoint® electrode in one patient (5%). Removal rate was 90% with only 2 patients needing a posterior operative hysteroscopy to complete the exercises. Nitrous oxygen was used as analgesic method in most patients (68%) with a mean Visual Analogue Scale (VAS) of 2,5 (0-6). Bleeding was the most frequent complication described (15%), not causing major problems during the technique.

Conclusions

We can conclude that office hysteroscopy is a safe and effective technique for the management of RPOC. More studies need to be carried out.

**ES32-0489 -
Free Communication**

Total utero vaginal septum resection using the new OHRab 24fr hysteroscope

Audrey Astruc¹, Philippe Descamps¹, Pierre Emmanuel Bouet¹, Guillaume Legendre¹
¹Angers University Hospital, Gynecology department, Angers, France

Background

Uterine septum is the most frequent uterine malformation. We aim to describe a minimal invasive approach of a total utero vaginal septum using the new OHRab hysteroscope developed by AB MEDICA

Methods

We report the case of a 23-year-old woman, nulliparous with a history of a miscarriage, addressed to our center after failing to insert a hormonal IUD. The 2D and 3D ultrasound found a total uterine septum with cervical duplicity and a vaginal longitudinal non obstructive septum (U2C1V1 type according ESGE/ESHRE Classification). The patient was asymptomatic.

Results

Under general anaesthesia and transabdominal ultrasound guided, we first performed the resection of the vaginal septum using classical monopolar scalpel. We then used a 24fr hysteroscope combining a bipolar curved electrode for conventional resection and an operating channel for 3.5 mm instruments (scissors, bipolar tip) in a single tool. Hyalobarriere Gel was inserted at the end of the procedure. The time procedure was 25 minutes. The patient was discharged on the same day with no post operative pain. The 6 weeks post operative hysteroscopy found a satisfying correction of the septum.

Conclusions

OHRad hysteroscope represents a practical and effective option for the management of utero vaginal septum.

<https://player.vimeo.com/video/831311339?autoplay=1>

**ES32-0257 -
Free Communication**

Hysteroscopic treatment of retained products of conception using see and treat hysteroscopy without anaesthesia

Merav Sharvit¹, Sharon Treger², Shiri Weinberg¹, David Nadav Sabag¹, Moti Pansky¹, Oshri Barei¹

¹Faculty of Health Sciences- Ben Gurion University- Israel,

Department of Obstetrics and Gynecology- Assuta Ashdod University Hospital- Asdod- Israel, Ashdod, Israel

²Faculty of Health Sciences- Ben Gurion University- Israel,

Department of Obstetrics and Gynecology- Assuta Ashdod University Hospital- Asdod- Israel, Asdod, Israel

Background

A clinical evaluation of office hysteroscopic treatment of retained products of conception (RPOC) without anaesthesia.

Methods

A retrospective cohort study in a tertiary medical centre. The cohort included patients with suspected RPOC that underwent see and treat operative office hysteroscopy without anaesthesia (SATHWA) in our outpatient clinic between April 2019 to March 2023. All patients had a diagnostic hysteroscopy to confirm the diagnosis. Those with RPOC completed SATHWA.

Results

185 cases of suspected RPOC were referred to our hysteroscopy clinic. Of them, 175 cases were confirmed on hysteroscopy. In 162 cases, the removal of RPOC by SATHWA was attempted, and in 154 cases, it was successfully completed (95%). In 13 cases, office operative hysteroscopy was not attempted, mostly due to pain during the diagnostic hysteroscopy.

The average size of RPOC for patients treated in the clinic was 14.7mm (range 4-49mm SD 8.7).

One hundred twenty-six cases were performed using a Truclear Elite 6mm device, and 36 cases using a mini-Bettocchi 4.2mm device. In 142 cases, the procedure was successful in the first attempt (87.6%). 107 out of 126 (84.9%) cases performed with the Truclear device resulted in complete resection of RPOC. Thirty-five cases performed with the mini-Bettocchi device were successful (97.2%). Cases performed with the Truclear device had significantly larger RPOC (16.4mm vs. 9.9mm P<0.005).

Twenty cases were unsuccessful in the first attempt, of which 12 underwent a second procedure in the clinic for completion of the procedure. The procedure was completed in 11 out of 12 of these cases (91.7%)

A hundred patients attended a repeat hysteroscopy. 16 patients required separation of adhesions or treatment of persistent RPOC that was done in the clinic, and only eight patients needed a referral for a surgical procedure under anaesthesia

Conclusions

SATHWA is feasible and highly effective for patients with RPOC.

**ES32-0050 -
Free Communication**

Using social media to enhance informed consent in the “One-Stop Services”

Ayman Ewies¹, Tiffany Jones¹, Sara Greenaway¹, Vanessa Wright¹, Charlotte Gordon¹, Anuji Evans¹
¹Sandwell and West Birmingham Hospitals NHS Trust, Gynaecology, Birmingham, United Kingdom

Background

The Faster Cancer Diagnosis Standard of October 2021 ensures that patients have cancer diagnosed or ruled out within a maximum of 28 days from referral. Postmenopausal bleeding (PMB) is the main symptom of endometrial cancer in 90% of cases. One Stop-PMB Services have been established in the many centres in the NHS to facilitate fast diagnosis. We aim to increase patients awareness and enhance the informed consent process since most patients predict they are invited only for initial consultation and assessment.

Methods

The Communications Department in Sandwell and West Birmingham NHS Trust produced a 2-minute video clip to inform patients about what to expect during the visit to the One Stop PMB Clinic. Individuals appearing in the video clip are the nurses working in the hysteroscopy unit who volunteered to produce it. They are included in the authorship list. The video clip is uploaded on the YouTube and a link is texted to patients prior to the appointment so that they can watch it on their smart phone.

Results

Excellent feedback is received from patients as they get the specific information they need directly from their own healthcare providers. The video clip enlighten patients that this contemporary service replaces the traditional 4-visit service to undergo history taking and examination, ultrasound scanning, diagnostic hysteroscopy, and hysteroscopic morcellation of polyps. A prospective patient survey is being distributed to patients and the results will be collated and briefly presented with the video clip.

Conclusions

Social media is a great way to connect with patients by sharing information and providing support. Patients can learn more about their condition and update their family and friends. Using social media platforms in health care can also help with patient engagement as they increase their awareness as well as keep them constantly informed and updated.

<https://player.vimeo.com/video/824223957?autoplay=1>

**ES32-0560 -
Free Communication**

I-shaped uterus hysteroscopic treatment with morcellator - new approach

Ana Gallardo Navarro¹, Covadonga Álvarez López¹, Elena Rodríguez González¹, Carmen Sánchez Cabezas¹, Tamara Ruíz Martínez¹, Alicia Hernández Gutiérrez¹

¹La Paz University Hospital, Hysteroscopic Unit, Madrid, Spain

Background

Mullerian duct anomalies include congenital malformation of uterine cavity with a frequency of 4-7%. Most of them are associated with subfertility or adverse pregnancy outcomes depending on the type of anomaly. According to ESGE classification, the dysmorphic uterus are named as U1 class. Thereafter, in 2019, Doctor Alonso described three subtypes inside dysmorphic uterus: T, I and Y-shaped uterus. The I-shaped uterus is described as a tubular morphology of the uterine cavity. The aim of this video is to show the use of hysteroscopic morcellator in the treatment of dysmorphic uterus like I-shaped uterus.

Methods

We present the case of a 34-year-old woman with a history of three failed artificial inseminations. During the sterility study, a I-shaped uterus was discovered.

Results

We performed two hysteroscopies. The first diagnostic hysteroscopy showed a uterus with tubular morphology, confirming the diagnosis of an I-shaped uterus and a second therapeutic hysteroscopy in which we used the morcellator on both uterine walls to enlarge the volume of the uterine cavity in case of a future pregnancy.

Conclusions

The diagnosis of I-shaped uterus is important because of the impact of uterine malformations on female fertility. Hysteroscopic morcellator treatment of dysmorphic uterus should be considered in patients with infertility as an alternative to bipolar electrode. The use of morcellator could improve pregnancy outcomes by enlarging the uterine cavity and reducing the risk of uterine adhesions.

<https://player.vimeo.com/video/831603508?autoplay=1>

**ES32-0555 -
Free Communication**

Predictive factors for electrocoagulation use in hysteroscopic residua removal

Emilie Ben-Ezry¹, Tzvi Leibovich¹, Ron Sagiv¹, Liat Mor¹, Ram Kerner¹, Ohad Gluck²

¹Wolfson Medical Center, Obstetrics and Gynecology, Holon, Israel

²Wolfson Medical Center, Obstetrics and Gynecology, Tel Aviv, Israel

Background

We aimed to identify pre-operative characteristics that may be associated with the need for electrocoagulation use during hysteroscopic residua removal.

Methods

This is a retrospective study. Patients who underwent residua removal by hysteroscopy at our institute between September 2019 and November 2022 were included in this study.

Background characteristics, previous pregnancy history, presenting symptoms, and pre-operative sonographic findings were obtained from the electronic medical files.

Hysteroscopic findings, as well as operative data (duration of the procedure, the need for electrocoagulation use and perioperative complications) were also reviewed. In order to find predictive factors for electrocoagulation use during the hysteroscopy we compared between patients for whom electrocoagulation was used and patients who underwent "cold" residua resection

Results

Preliminary results included 170 patients: group 1- residua removal using electrocoagulation (n=40), group 2- residual removal without using electrocoagulation (n=130).

The rate of past hysteroscopic residua removal was higher in the electrocoagulation group (10% vs. 2.3%, p=0.05), compared to the no electrocoagulation group.

Patients for whom electrocoagulation was used were more likely to present after vaginal delivery (62.5% vs. 35.4%, p=0.003) and after manual removal of the placenta (37.5% vs. 13.1%, p=0.001), and less likely to present after medical abortion (7.5% vs. 40%, p<0.001), compared to patients for whom electrocoagulation was not used. In addition, the residual size (by ultrasound) was larger in the electrocoagulation group (20.4cm vs. 16.6cm, p=0.05).

Post hysteroscopy emergency room visits were more common after hysteroscopic procedure in which electrocoagulation was used (10% vs. 1.5%, p=0.002).

Conclusions

Hysteroscopic residua removal after vaginal delivery are more likely to be performed using electrocoagulation, in contrary to residual removal after medical abortion. In addition, lager residua, and patients with history of hysteroscopic residua removal are also likely to undergo the procedure using electrocoagulation.

**ES32-0273 -
Free Communication**

Detection of past pregnancy implantation site during diagnostic hysteroscopy

Sevasti Koulouraki¹, Maria Papageorgiou¹, Emmanouil Kalampokas¹, Olga Triantafyllidou¹, Nikolaos Vlahos¹, Theodoros Kalampokas¹

¹Aretaieion University Hospital- National and Kapodistrian University of Athens, 2nd Department of Obstetrics and Gynecology, Athens, Greece

Background

Diagnostic hysteroscopy is a common investigational tool in the assessment of uterine pathologies in infertile women undergoing in vitro fertilization. Past pregnancy implantation site is an uncommon finding that should be in the differential diagnosis of ultrasonographic findings in women with a history of anembryonic pregnancy or miscarriage.

Methods

This case concerns a 40-year-old woman with a history of an anembryonic pregnancy after a fresh transfer of two Day 5 embryos. The blood measurements of human chorionic gonadotropin reached a maximum of 450 IU and a transvaginal ultrasound depicted an empty gestational sac of 25mm. The human chorionic gonadotropin measurement returned to zero, four weeks after the embryo transfer. Three months later, the patient was asymptomatic, and a transvaginal ultrasound depicted a heterogenous intracavitary vascular hyperechoic focal mass. The patient was then referred to our department for a diagnostic hysteroscopy, before proceeding to a new frozen embryo transfer.

Results

The patient underwent a diagnostic hysteroscopy. Intraoperatively a past pregnancy implantation site was observed at the right side of the uterine fundus, medially to the right ostium. Hysteroscopic scissors were used to excise the tissue. No bleeding was detected during the procedure. The rest of the endometrial cavity was visualized with no abnormalities. The excised tissue was sent for a histopathology analysis, that confirmed the clinical diagnosis. The patient was discharged later that evening and underwent a new transfer of two day 5 embryos that lead to a viable pregnancy.

Conclusions

Past pregnancy implantation site is a rare intraoperative finding in asymptomatic women undergoing in vitro fertility treatment. This video abstract provides a useful method and experience that might be helpful when a similar situation occurs in clinical practice.

<https://player.vimeo.com/video/826918688?autoplay=1>

Patient experiences of outpatient hysteroscopy: perspectives from a national benchmarking survey

Ayesha Mahmud¹, Prathiba De Silva², Paul Smith², T Justin Clark²

¹University Hospitals of North Midlands, Gynaecology, Stoke-on-trent, United Kingdom

²Birmingham Women's & Children's NHS Foundation Trust, Department of Obstetrics & Gynaecology, Birmingham, United Kingdom

Background

Patient perspectives have an important role in improving the quality of outpatient hysteroscopy (OPH) services. Understanding areas of improvement can help shape the process involved in the patient journey for OPH. We share qualitative insights, perspectives and reflections on the positive and negative experiences of patients that took part in a national benchmarking OPH survey. In addition, we explore the correlation between women's experience of OPH and reported pain scores.

Methods

Over a two-month period, 5151 women took part in the national OPH survey in the United Kingdom. Free text comments relating to women's OPH experience, collected as part of the survey, were subjected to qualitative analysis using NVivo 12 software to provide a better understanding of the OPH journey. In addition, correlations were drawn between the qualitative and quantitative data collected for pain scores and satisfaction using SPSS software.

Results

1720 (33.3%) women provided comments on their OPH experience. Qualitative thematic analysis generated themes that were divided into positive (82%) and negative (7%) experiences of care. Potential areas of improvement in relation to the OPH service were highlighted in 11% of themes. Most women regarded OPH as a safe, tolerable, and well delivered outpatient service. Quantitative analysis showed that 1829 (35.5%) women reported procedural pain between 70-100mm. These women reported equivalent quality of care on a 10cm visual analogue scale (9.71 [SD1.04] vs. 9.76 [0.73]; P = 0.06) but were more likely to decline having the procedure done in the same way again (19.4% vs. 3.1%; RR 6.30, 95% CI 5.06 to 7.83) compared to women with pain scores <70mm.

Conclusions

OPH remains a permanent fixture in ambulatory gynaecology. Qualitative data supports the usefulness, safety, tolerability, and acceptance of hysteroscopy in an outpatient setting by most women. However, the reasons for high procedural pain, poor tolerability and negative experiences warrant review and exploration of both individual patient and relevant institutional factors including training, equipment, and local processes.

Ultrasound-guided hysteroscopic resection of severe intrauterine adhesions (Asherman Syndrome)

Dianne Manzano¹

¹Ilocos Training and Regional Medical Center, Department of Obstetrics and Gynecology, Dagupan City, Philippines

Background

Intrauterine adhesion is a consequence when the endometrial basement membrane is damaged by surgery, infection, trauma, and other causes. It usually leads to decreased in menstrual flow, amenorrhea, lower abdominal pain, infertility and recurrent miscarriage. The management is generally hysteroscopic using a miniaturized instruments or the use of a resectoscope. The objective of this video presentation is to described the surgical procedure of managing severe intrauterine adhesion.

Methods

This was a case of a 33-year-old, G1P0 (0010), who complained about the decrease amount of menstrual flow and duration and desires future pregnancy. She had 2 histories of surgical procedures: dilatation and curettage for retained products of conception and hysteroscopic myomectomy for submucous myoma 4 weeks after the curettage. She was given GnRH agonist 3.75 mg IM injection for 3 months. Transvaginal ultrasound revealed a suspicion of intrauterine adhesion. Hysterosalpingogram showed filling defects on the endometrial cavity more on the central portion and patent bilateral fallopian tubes. On diagnostic hysteroscopy, there were fibrous adhesions seen in the central and marginal area on the lower endometrial cavity. An area free from adhesion was seen in the right lateral endometrial cavity. Under ultrasound guidance, using a microscissor, the adhesion was cut on the avascular median plane of the band of adhesion starting on the free area. Thermal energy was not used in this procedure to minimize trauma on the adjacent normal endometrium. After the procedure, an anti-adhesion barrier was placed inside the uterine cavity. Post-operative sequential estrogen-progesterone administration was initiated to minimize post-operative adhesion.

Results

Four weeks after the hysteroscopy, a second-look procedure was done and revealed a mild intrauterine adhesion seen on the right lower endometrial cavity. The endometrium was reddish pink in colour from the upper to lower uterine cavity. Hysteroscopic lysis of the mild adhesion with microscissor was done. Four months after, she got pregnant spontaneously which resulted in missed abortion.

Conclusions

A careful hysteroscopic surgical management of intrauterine adhesion can restore the normal volume and anatomy of the uterine cavity. Intraoperative ultrasound guidance in difficult hysteroscopic procedures is feasible to prevent intraoperative complications

<https://player.vimeo.com/video/831649604?autoplay=1>

Surgical and reproductive outcomes in patients with complete septate uterus with or without cervical anomalies undergoing hysteroscopic metroplasty: a multicentre study

Alfonso Manzi¹, Virginia Foreste¹, Paolo Casadio², Agnese Virgilio², Brunella Zizolfi¹, Alessandra Gallo¹

¹University of Naples "Federico II", Department of Public Health - School of Medicine, Naples, Italy

²IRCCS Azienda Ospedaliero-Universitaria di Bologna- S. Orsola Hospital,

Division of Gynaecology and Human Reproduction Physiopathology- Department of Medical and Surgical Sciences, Bologna, Italy

Background

Primary objective was to evaluate surgical outcomes in patients with complete uterine septa with or without cervical anomalies, undergoing hysteroscopic metroplasty. Then we compared reproductive outcomes of each group of patients, in relation to absence or presence of cervical anomalies and the different surgical techniques.

Methods

This multicentre prospective observational study was conducted between January 2018 and May 2023 at A.O.U. "Federico II" of Naples and Sant'Orsola Malpighi University Hospital of Bologna. Patients with hysteroscopic and 3D transvaginal ultrasound (TVUS) diagnosis of complete uterine septum (U2b according to the ESHRE / ESGE classification) were enrolled and divided into 3 groups based on the presence of associated cervical malformations. Group A: normal cervix (U2b C0); Group B: septate cervix (U2b C1); Group C: double normal cervix (U2b C2). All eligible patients underwent hysteroscopic metroplasty performed by two expert hysteroscopists in the operating room under general or loco-regional anaesthesia. Patients of the Group B were furthermore divided in Group B1, when the section of the cervical anomaly was performed and Group B2 if the cervical septum wasn't treated. In Group C, the approach was to exclude the cervical canal from any resection, thus initiating the resection from the isthmic portion of the septum. 3 months after surgery, a 3D-TVUS was performed to assess whether residual septum was present (when the value of Z exceeded 50% of the Y measurement). After 3D-TVUS, a second look office hysteroscopy was performed, and if residual septum was present, it was resected using miniaturized instruments in office setting.

Results

82 women were enrolled. Operative time in the subgroup B1 and B2 was similar, but statistically shorter in group A compared with group B and C (p-value < 0.01). Operative time was independent from instruments and technique used. Regardless of the surgical technique, 56% of patients required a second surgical intervention for the presence of residual septum without significant difference between the three groups. Reproductive outcomes were evaluated for 49 patients (mean follow-up of 36 months): Clinical Pregnancy Rate was higher in group A (65%) than in group B (60%) and C (39%), but the difference was not statistically significant (p = 0.187). Similarly, no statistically significant difference was reported between the three groups for Miscarriage Rate (respectively 8%, 17% and 11%) (p = 0,82088). A statistically significant difference (p= 0,047) in Live Birth Rate between group B and other groups (77%, 17% and 57% respectively) was reported. However, 4/6 pregnancies are still ongoing in this group, and this represents an important bias.

Conclusions

Hysteroscopic metroplasty is effective and safe procedure for treatment of complete septate uterus with or without cervical abnormalities. A second surgical step is often required for the optimal treatment regardless of cervical anomalies. The presence of cervical anomalies doesn't seem to significantly affect reproductive outcomes.

**ES32-0519 -
Free Communication**

"Beyond the polyp: unravelling the mystery of recurrent endometrial growth in a young woman with the help of the Storz Professional Image Enhancement System (SPIES)."

Ma. Liza Maramba¹, Regta Pichay², Melchor Dela Cruz- Jr.¹, Mary Jane Aquino³, Leonido Manalo- Jr.⁴

¹Southern Isabela Medical Center, Department of Obstetrics and Gynecology, Santiago City, Philippines

²St. Luke's Medical Center, Department of Obstetrics and Gynecology, Quezon City, Philippines

³Mount Carmel Diocesan General Hospital, Department of Obstetrics and Gynecology, Lucena City, Philippines

⁴Southern Isabela Medical Center, Department of Pathology and Clinical Laboratories, Santiago City, Philippines

Background

This presentation aims to enhance your understanding of endometrial pathology and challenge your current knowledge and perceptions of this intriguing and complex condition. A 25-year-old woman complained of pelvic pain and abnormal uterine bleeding and had a history of amenorrhea and cognitive delay. Upon examination, her uterus was enlarged to 20 weeks' size, had a doughy consistency, and was movable and non-tender.

On transvaginal ultrasound, the endometrium was thicker than usual at 6.86 cm, with irregular cystic spaces. The endometrial-myometrial junction had multiple areas of interruption with a colour score of 3, which suggested a possibility of hyperplasia or malignancy and a likelihood of a molar pregnancy. However, the serum beta-hCG levels were normal, ruling out gestational trophoblastic disease. It is worth mentioning that the patient had a benign endometrial polyp two years ago. As a result, a hysteroscopy was scheduled for the patient.

Methods

The uterine cavity contains complex structures with delicate, transparent, eggshell-like, fluid-filled sacs, stretched balloons, and a fern-like pattern. Blood vessels provide necessary growth, which is a unique and challenging condition.

The mass was removed using ultrasound-guided suction curettage, but the endometrial thickness remained thickened at 5.34 cm. In the gross appearance of the specimen, we found a polypoid mass with villous projections resembling a hydatidiform mole vs. carcinoma.

The ultrasound conducted a week after the operation revealed no alterations in the uterine mass. However, a follow-up ultrasound a month later showed a size reduction, a thinner endometrial thickness, and a smaller maximum diameter.

We conducted a follow-up diagnostic hysteroscopy using the Storz Professional Image Enhancement System (SPIES) to enhance visualization. This allowed us to accurately identify the blood vessels supplying the mass, contradicting the initial histopathology report of a Benign Endometrial Polyp. We are now leaning toward a diagnosis of polyploid endometrium with atypia.

Nonetheless, we confidently utilized suction curettage, Intrauterine Bigatti Shaver (IBS®), and transcervical resection of the endometrium and portions of the myometrium to remove the uterine lesion successfully. The balloon catheter was inserted to facilitate healing, with utmost precision provided by ultrasound technology to ensure accuracy throughout the procedure.

Results

Based on the analysis of slides from various hospital pathologists, it has been determined that the condition is a benign endometrial polyp. However, one pathologist identified it as Atypical Polypoid Adenomyoma after correlating it with our SPIES findings, later confirmed through immunohistochemistry staining.

A month later, a follow-up scan revealed a mere 8.46 ml fluid in the cavity, with no masses detected.

Conclusions

Diagnosing APA is complex, but SPIES endoscopy is a game-changer. It can be beneficial in rare cases and enhances visual contrast, making abnormal areas readily identifiable. SPIES reinforces histopathology findings, ensuring accurate diagnoses and appropriate treatment, ultimately leading to better outcomes.

**ES32-0518 -
Free Communication**

Bowel endometriosis standardized surgical management "made in Venezuela" - case report: Quevedo Kati, Castellano Jesus, Venezuela

Kati Quevedo¹, Jesus Castellano¹

¹Human Gynecology, Maracaibo, Zulia, Venezuela

Background

Deep endometriosis is the subperitoneal invasion by lesions that exceed 5 mm in depth. Disease affecting the intestine may be associated with severe pain. Most frequently located in the posterior compartment, where it may involve the ureters, uterine torus, uterosacral ligaments, bowel, and vaginal wall.

Bowel endometriosis usually presents as a single nodule, with a diameter greater than 1 cm, which normally infiltrates the intestinal musculature and fuzzy structures. Bowel involvement accounts for 5% to 12% of women presenting with the disease, with the rectum and sigmoid involved in up to 90% of all bowel lesions.

The more specific symptoms of bowel endometriosis, such as diarrhoea, constipation, dyschezia, rectal bleeding, and rarely, bowel obstruction, depend on the location of the disease, the size of the nodule, and the depth of involvement of the bowel wall.

The final decision about whether or not to have a laparoscopic bowel resection is usually only made during surgery; however, full preoperative staging should be performed to ensure a balanced discussion, weighing the risk of complications and outcomes allowing patients to make an informed decision. When planning surgery, the optimal goal is complete resection of all visible lesions while preserving pelvic organ function. The greater the radicality towards the disease, the greater the risk of complications and, in these cases, the wishes of the patient should be respected and a more conservative approach should be adopted. this procedure carried out in Venezuela through the minimally invasive approach,

All surgical techniques, therefore, must be individualized and will make attempts to preserve and restore organ function.

Methods

Laparoscopic Video

Results

Bowel Resection + anastomosis Primary by Endometriosis

Conclusions

Satisfactory Results

<https://player.vimeo.com/video/831483164?autoplay=1>

**ES32-0477 -
Free Communication**

Paracervical anaesthesia by vaginoscopy for office hysteroscopy

Carmen Sánchez Cabezas¹, Elena Rodríguez González¹, Ana Gallardo Navarro¹, Tamara Ruiz Martínez¹, Alicia Hernández Gutiérrez¹, Covadonga Álvarez López¹

¹La Paz University Hospital, Gynecology, Madrid, Spain

Background

This study presents the methodology of paracervical anaesthesia via vaginoscopy for office hysteroscopy, focusing on enhancing procedural tolerability.

Methods

By an illustrative video we explain the technique employed and materials used. We present retrospective results of cases where this technique was performed, obtained from patients' clinical history.

Results

The technique utilized a uterine paracervical block needle consisting of nine parts: handle, slide mechanism, retraction button, stainless steel guide with a 20 Ga needle, protective sheath, extension line, female Luer Lock connection, and protective cap. Mepivacaine 2% (10 ml) was used as a local anaesthetic, and hysteroscopy was performed via vaginoscopy. The procedure involved vaginoscopy, identification of the cervix's external orifice and the pouch of Douglas, locating the uterosacral ligament on one side (7/5 o'clock), introducing the paracervical block needle parallel to the hysteroscope, injecting 5 ml of Mepivacaine, and repeating the process on the other side. A 5-6 minute waiting period was needed before starting the procedure.

This technique was performed in 43 patients, with 67.4% (29) being nulliparous women. The most common pathologies treated were postmenopausal metrorrhagia (32.5%, 14 cases) and myomectomy with morcellator (20.0%, 9 cases). The mean visual analogue scale (VAS) score was 4.83 (SD: 2.01). 11 patients had previously undergone hysteroscopy without paracervical anaesthesia. The mean VAS score without paracervical anaesthesia was 7.54 (SD: 1.91), while with paracervical anaesthesia applied via vaginoscopy, it was 4.27 (SD: 1.91), showing statistically significant difference between the groups ($p=0.001$).

Conclusions

This technique is feasible and effective for enhancing the tolerability of office hysteroscopy. It reduces patient's stress by eliminating uncomfortable speculum placement for anaesthesia administration. It benefits patients with lower tolerance (nulliparity, menopause, large myomas) and improves tolerability and VAS scores during office hysteroscopy.

<https://player.vimeo.com/video/831275778?autoplay=1>

**ES32-0635 -
Free Communication**

Vaginoscopic – hysteroscopic removal of an intracervical embedded IUB: a case report

Francesco Scicchitano¹, Marta Gargiulo², Stefano Angioni¹, Nicoletta Biglia³, Gaetano Perrini⁴

¹*University of Cagliari, Department of Surgical science, Cagliari, Italy*

²*University of Cagliari, Division of Gynecology and Obstetrics AOU Cagliari - Dept of Surgical Sciences, Cagliari, Italy*

³*Gynecology and Obstetrics Unit - Umberto I Hospital, Department of of Surgical Sciences- University of Turin, Turin, Italy*

⁴*Gynecology and Obstetrics Unit - Umberto I Hospital, Hysteroscopy Service, Turin, Italy*

Background

Intrauterine devices (IUDs) are a worldwide used reversible contraceptive method. The IUDs are made of copper or plastic (LNG-IUS) and have different shapes. While highly effective, IUDs are associated with complications such as malposition, migration/perforation and expulsion and unplanned pregnancies. Commonly, symptoms related to these complications are abdominal pain and irregular bleeding. Anyway, the rarity of these undesired events is reassuring. A novel type of IUD is the intrauterine balls (IUB), a special shape memory IUD made of nitinol strings with copper beads, designed to minimize insertion discomfort and damage risk. Here we report a case of a mispositioned IUB embedded in the intracervical parenchyma and perforating the ectocervix.

Methods

An asymptomatic, healthy, 34-yo woman who had never undergone gynaecological/cervical surgery, presented to her gynaecologist for the removal of a copper-releasing intrauterine system with beads (IUB – intrauterine ball). The insertion procedure (in 2019) was interrupted twice before completion due to the severe pain complained by the patient. During the following 4 years, no symptoms were reported and no clinical or sonographic evaluations were conducted. Upon speculum examination, the IUD terminal threads emerged from the upper lip of the cervix, 2 cm above the external os, while the string with the copper beads pierced twice the cervical parenchyma. After a first usual but unsuccessful attempt to extract the IUB in the office setting, a 2D/3D ultrasound of the entire uterus and cervix was performed to precisely locate the device in the cervical parenchyma in order to assess the least invasive way to remove the IUB. Then the patient was referred to the hysteroscopy service of the Mauriziano Hospital in Turin. Plasma beta-HcG was negative. A 2.40 hrs-long hysteroscopy was performed. The intrauterine cavity was regular, while the cervix showed the IUB in the right anterolateral labium of the portio but it did not involve the cervical canal. No signs of cervicitis or canal stenosis/involvement in the fibrotic process were reported. Scissors, 5Fr bipolar electrode and diode laser were used to identify a cleavage plane between the parenchyma and the IUD beads/structure. Three-point cut was needed to open the parenchyma and free the IUB.

Results

An intact IUB was extracted with all its spheres. Minimal bleeding during the procedure and no infection or cervical canal stenosis were reported in the following 20 days after the procedure, with a good healing process.

Conclusions

IUD migration/perforation is an overall uncommon event. Cervical intraparenchymal incarceration of an IUB has not yet been described in the literature and this is the first case of a vaginoscopic-hysteroscopic technique for the removal of the incarcerated IUB. Minimally invasive surgery techniques should be mandatory to preserve anatomical integrity/fertility in a young woman.

**ES32-0558 -
Free Communication**

A combined approach to a double-layer uterine closure technique of the niche defect following caesarean

Akshara Sharma¹, Lina Antoun², Justin Clark²

¹Aston Medical School, Medical Student, Birmingham, United Kingdom

²Birmingham Women's Hospital, Gynaecology, Birmingham, United Kingdom

Background

To present the double-layer uterine closure technique of the niche defect in a 30-year-old woman. The aim was the surgical management of the uterine caesarean niche defect using a laparoscopic and hysteroscopic approach together to relieve the patient's symptoms and allow for uterine scar healing by the closure of the defect.

Methods

A combined Laparoscopic and hysteroscopic approach with imaging device thunderbeat and advanced energy device. Double layer closure using a combination of intracorporeal and extracorporeal techniques with Monocryl 0 followed by Vicryl 1.

Results

A 30-year-old woman had a previous caesarean section and later presented to the clinic with vaginal bleeding and pelvic pain. She was found to have a niche defect.

Intraoperatively, we first injected the vasopressor Argipressin 20iu/100 mls 0.9% normal saline in the sub-serosal area to reduce bleeding. Then using an advanced energy device, a transverse incision was made on the uterus and the niche defect area was excised and the cavity was breached. The myometrium was sutured back together to ensure they are symmetrical and in layers. The Uterus was closed by the double-layer closure technique using a combination of intracorporeal and extracorporeal techniques with Monocryl 0 followed by Vicryl 1. The first layer is sutured in a continuous unlocked suture including the endometrial layer. The second layer is also a continuous unlocked suture that imbricates the first.

Hysteroscopic trans-illumination was performed at the end to ensure complete excision of the defect area and that there was no escape through the closure.

The patient was discharged home day 1 postoperative.

Conclusions

To present our surgical technique for the niche defect closure

<https://player.vimeo.com/video/831609777?autoplay=1>

**ES32-0071 -
Free Communication**

Tackling the cervical stenosis and removal of retained products of conception by tissue retrieval system in office setting

Milind Telang¹, Pravada Telang², Jui Ponkshe³

¹Galaxy Care Hospital, OBGYN, PUNE, India

²Galaxy Care Hospital, Gynaecology and minimal invasive, Pune, India

³Galaxy Care Hospital, Gynaecology and minimal invasive surgery, Pune, India

Background

To see the feasibility of tissue retrieval system in office in negotiating internal OS and cervical canal stenosis

Methods

A 30 years women Gravida 3 para 2 Previous two caesarean section presented with persistent spotting for 8-10 days after taking mifepristone- misoprostone combination for termination of 7 weeks pregnancy. Her trans vaginal sonography revealed hyper echoic lesion on post wall with minimal vascularity(Type0-1 Gutenberg) . She was counselled for hysteroscopic removal with tissue retrieval system without any anaesthesia. Patient was explained in detail that she may experience pain while entering the cavity and she could stop the procedure if she felt uncomfortable. Truclear elite mini (6mm) with soft tissue shaver was introduced by vaginoscopy technique. The cervical canal was identified by the arbor vitae. In the upper one third of cervical canal stenosis was encountered and tackled with combination with bevel of scope and circumferential cutting of the white fibres with judicious use of suction thereby causing minimal pain.

Results

The stenosis of uterine internal orifice and cervical canal was negotiated with circumferential cutting the fibrotic tissue with judicious use of suction on hand piece thereby causing minimal pain to the patient. The visual analogue score was 4 and there was no bleeding . Retained product of conception could be completely removed under vision in single insertion.

Conclusions

It is feasible to tackle the uterine internal os stenosis and stenosis of upper cervical canal under vision using the tissue retrieval system by judicious use of suction and circumferential cutting of fibrotic tissue and enter the cavity.

<https://player.vimeo.com/video/839769694?autoplay=1>

**ES32-0628 -
Free Communication**

Virtual reality technology to reduce pain and anxiety in outpatient hysteroscopy

*Maria Giuseppina Trinchillo¹, Virginia Foreste¹, Michela Dell'Aquila¹, Maria Chiara De Angelis¹,
Alessandra Gallo¹, Brunella Zizolfi¹*

¹University of Naples Federico II, Department of Public Health, Naples, Italy

Background

To evaluate the feasibility and effectiveness of the use of virtual reality technology in improving pain and anxiety management during outpatient hysteroscopy, comparing it to standard outpatient hysteroscopy care.

Methods

Unblinded randomized controlled trial conducted from March to May 2023 at the hysteroscopy Unit of "Federico II" of Naples. Women aged between 18-70 undergoing outpatient hysteroscopy have been enrolled. Patients with a history of epilepsy, severe vertigo, significant hearing impairment and blindness were excluded. The Virtual Reality Technology (VRT) involves a computer-generated simulation providing the user with a realistic immersive virtual environment which can be interacted with, producing a non-invasive analgesic condition acting on pain and anxiety. The effectiveness of the use of virtual reality has been assessed by evaluating pain and anxiety with numeric rating scores (nrs) from 0 to 10 and by monitoring heart and respiratory rates.

Results

46 patients have been enrolled (twenty-five in the intervention group and twenty-one in the control group). Two patients in the intervention group have been ruled out, because they asked to remove visor before the end of procedure. Eighteen procedures (72%) have been operative in the intervention group, while only eleven (52,38 %) in the control group (p 0.17). The virtual reality group experienced significantly less pain during the procedure than the control group: there was significant difference in reported average pain (mean nrs 3.34. Versus 5.47, mean difference 2.130; 95% ci 0.4598 to 3.8002; p= 0.01). The mean difference between expected pain and perceived pain was -2.86 and -0.47 respectively (difference 2.390, 95% ci- 0.4470 to 4.3330; p = 0.01). There was no difference in time of procedure (mean 8.13 versus 5.28; mean difference -2.850 95% ci -5.8622 to 0.1622; p=0.06) or respiratory rate (mean 21,0 versus 20,85, mean difference - 0.150; 95% ci --2.3254 to 2.0254; p=0.89). The heart rate during procedure instead was lower in the virtual reality group, even if it doesn't reach statistical significance (mean 88 versus 92.61, mean difference 4,61; 95 % ci -5.9039 to 15.1239; p = 0.38). 23 of 25 women (91%) would use the headset again in the future and 21 of 21 (100%) women in the control group would like to use a source of distraction during the procedure if they could.

Conclusions

Women in the virtual reality group experienced significantly less average pain compared whit standard care. These encouraging results need to be confirmed and amplified by further evaluation, but VRT seems to be feasible and effective in a clinical setting as a distraction technique for the management of pain and anxiety in patients undergoing outpatient hysteroscopy.

**ES32-0038 -
Free Communication**

Vaginal repair of caesarean scar niche

Ali Mohamed¹, John Pardey²

¹Nepean Hospital- Sydney, Obstetrics and Gynaecology, Sydney, Australia

²Nepean Hospital- Sydney, Obstetrics and Gynaecology, Penrith, Australia

Background

The caesarean section rate is increasing worldwide. Hence, the incidence of cs defect is also on the rise. Caesarean scar defect is increasingly being reported nowadays. The reported incidence is up to 61% after just one caesarean section and can reach 100% after three or more caesareans. It can be diagnosed with hysterosalpingography, transvaginal sonography (TVS), saline infusion sonohysterography (SIS), hysteroscopy, and magnetic resonance imaging (MRI). Many of the patients will be asymptomatic. Pt may present with dysmenorrhea, dyspareunia, intermenstrual spotting, , chronic pelvic pain, and secondary infertility. Different repair techniques have been described including laparoscopic , hysteroscopic, combined, and vaginal approaches. We present our technique for caesarean section scar niche repair vaginally.

Methods

A stepwise video demonstration of our surgical technique

Results

N/A

Conclusions

We describe a simple technique for vaginal repair that is cost effective, and can be performed in a shorter surgical time.

<https://player.vimeo.com/video/822406100?autoplay=1>

Hysteroscopic resection for the primary management of early pregnancy loss: a case series

Letizia Li Pian¹, Liese Boudry¹, Shari Mackens¹, Christophe Blockeel¹, Herman Tournaye¹, Michelle Soares¹
¹Universitair Ziekenhuis Brussel, Brussels IVF Clinic, Brussels, Belgium

Background

Early pregnancy loss (EPL) management represents a concern, specifically in the fertility clinic, where least endometrial damage and rapid resumption of fertility treatments is a priority and where genetic analysis of the product of conception (POC) might be valuable, certainly in cases of multiple pregnancy loss. Among available management options, hysteroscopic resection (HSR) has been receiving mounting interest as an opportunity to reduce iatrogenic harm and retained product of conception (RPOC) risk as well as maximize cytogenetic analysis on POC. Our case-series is a pilot study aiming to analyse safety, feasibility and potential role of primary HSR of EPL in a fertility setting. Besides, we aimed to investigate its feasibility under local anaesthesia i.e. paracervical block (PCB).

Methods

Patients (n= 14) undergoing HSR for primary management of EPL at our tertiary fertility centre (Brussels IVF, UZ Brussel) between November 2022 to March 2023 were included. Local ethical committee approval was obtained. Patients with gestational sacs < 20mm were given the option to opt for a PCB (with back-up sedation if needed). For patients under PCB (n=5), a 16 Fr miniresectoscope was inserted without cervical dilatation; in case of sedation (n=9) 26 Fr hysteroscopes were preferred. In both cases, after detachment and removal of the gestational sac (GS) a sample was sent for genetic (microarray) analysis. Presence of RPOC was assessed by transvaginal ultrasound after the following menstrual period. A video of the procedure is available.

Results

The mean (\pm SD) age of the patients was 36,7 \pm 3,6 years and 50% had at least 1 previous curettage. Gestational age and GS dimensions were 9⁺¹ (\pm 1⁺⁴) weeks and 28,3 (\pm 17.4) mm respectively. Mean procedure time was 14.8 mins with no per- or postoperative complications. In case of PCB, the procedure was very well tolerated in 4/5 patients (GS 7 to 12mm), while in one case (GS of 19mm) conversion to sedation was necessary. Genetic analysis was conclusive in 10/ 11 (90,1%) cases (1 case of maternal contamination), with a 50% aneuploidy rate. At follow-up ultrasound, one patient presented with suspicion of RPOC and underwent a second look hysteroscopy, showing a well-organized cloth filling the cavity without real RPOC (confirmed at anatomopathological analysis).

Conclusions

Despite small sample size, our results show feasibility and safety of primary HSR in case of EPL, with low RPOC rate and high efficacy of genetic analysis on the POC, of particular advantage in infertile patients and those with repeated pregnancy loss. To our knowledge, it is also the first study to explore and show feasibility of primary hysteroscopic resection of miscarriage under local anaesthesia for selected cases, envisaging its use in outpatient settings for smaller GS. Larger long-term studies are required to establish intra-uterine adhesion and pregnancy rates.

**ES32-0226 -
Free Communication**

The use of pneumovaginoscopy for removal of vaginal septum

Justine Boinay¹, Patrice Crochet¹

¹*University of Rouen, Gynecologic surgery, Rouen, France*

Background

The creation of a pneumovagina with the application of a single-port device provides a view of vaginal structures and allows the application of laparoscopic techniques to perform vaginal surgeries. The objective was to describe and assess the feasibility of this novel surgical technique (pneumovaginoscopy) to perform removal of a vaginal septum.

Methods

A 22-year-old woman, gravida 1 para 0, presented with dyspareunia. Vaginal examination revealed a longitudinal vaginal septum up to the inferior third of the vagina. One cervix was seen on each side. Magnetic resonance imaging confirmed a congenital anomaly classified U2bC2V1 according to the ESHRE classification. We present the video of this single surgical procedure

Results

Diagnostic hysteroscopy was performed first to confirm that there was one cervix on each side leading respectively to its own uterine cavity, with no communication between the two. Secondly, a pneumovaginoscopy was performed. A GelPOINT V-Path (Applied Medical, Rancho Santa Margarita, California) with a inner ring of 7 cm in diameter, which is the device most often used to perform vNOTES adnexal procedures, was introduced into the vagina to create a pneumovagina. Monopolar scissors were used to section the septum at midline between anterior and posterior vaginal walls, up to the two cervix. The procedure was easily and efficiently performed using the pneumovaginoscopy technique and lasted less than an hour. The patient was discharged on postoperative day 1 without any postoperative complications. She was symptom-free at her postoperative visit at 2 months.

Conclusions

Compared to the classical vaginal approach, pneumovaginoscopy improves visualization through targeted lighting and close-up vision. This technique is particularly interesting in cases where the vaginal opening is narrow and for lesions located in the upper half of the vagina. We described this technique for vaginal septum removal and assessed its feasibility.

<https://player.vimeo.com/video/826867044?autoplay=1>

**ES32-0332 -
Free Communication**

Intrauterine adhesions and impaired reproductive performance: a systematic review

Angelo Hooker¹, Judith Huirne², Robert de Leeuw²

¹Zaans Medical Center ZMC, Department of Obstetrics and Gynaecology, Zaandam, The Netherlands

²Amsterdam UMC,

Department of Obstetrics and Gynecology- Amsterdam Reproduction & Development Research Institute, Amsterdam, The Netherlands

Background

Intrauterine adhesions (IUAs) are one of the main reproductive system diseases in women worldwide. The main clinical manifestations in case of IUAs are menstrual disturbances, cyclic pain and reproductive disorders. The reproductive outcomes of women with IUAs are inefficient compared to women without IUAs, even after adhesiolysis. An exact understanding of the underlying mechanisms to explain the compromised reproductive performance and outcomes in case of IUAs are lacking.

Methods

A systematic literature review until January 2022 was performed for studies reporting underlying causes, related mechanisms and processes to explain the association between IUAs and impaired reproductive performance, pregnancy and obstetric complications.

Results

A total of 58 articles were identified reporting underlying mechanisms to explain the association between IUAs and impaired fertility. Intrauterine scarring influences the process of fertilization, reproductive performance and ultimately reproductive outcome. IUAs can disturb sperm transport and result in an avascular and unresponsive endometrium with decreased receptivity and thickness. Abnormal decidualization and abnormal trophoblastic infiltration leads to placental attachment disorders. The risk for premature delivery, intrauterine foetal growth restriction and foetal anomalies is increased in case of IUAs.

Conclusions

The impact of IUAs on reproductive performance, even after adhesiolysis, is becoming more apparent. The postulated mechanisms to explain the association are related to sperm transport, embryo implantation and placentation. Prevention, by preserving the basal layer of the endometrium is essential. Effective and evidence-based strategies for the prevention of endometrial injury and formation of IUAs, are urgently needed.

The tip of the iceberg fibroid effect - a case report of 3D pelvic ultrasonography and laparoscopic enucleation of a moderate size type 2-4 submucosal fibroid

Alexandros Lazaridis^{1,2}, Stylianos Kogeorgos², Nikolaos Samer Al-Achmar², George Pistofidis²

¹Aretaieion University Hospital, Second Department of Obstetrics & Gynaecology, Athens, Greece

²Lefkos Stavros Athens Clinic, Gynaecological Endoscopy Unit, Athens, Greece

Background

Uterine fibroids constitute the most common benign solid tumours of the female pelvis. Their general population prevalence ranges widely from 4.5 – 68.6%, depending on ethnicity, genetic and other factors.

The majority of fibroids don't cause any issues, but when they become symptomatic they can manifest with painful periods (dysmenorrhea), heavy periods (menorrhagia), pelvic pain or pressure symptoms. Occasionally they may also contribute to subfertility. Ultrasonography and/or MRI are helpful tools for reliable fibroid diagnosis and pre-operative localization.

The surgical route for fibroid management depends on their anatomical position in the uterine body and grossly divided into hysteroscopic approach such as transcervical resection of fibroid (TCRF) and abdominal or laparoscopic myomectomy.

More recently, an attempt to further categorise their exact anatomical location according to FIGO guidelines has been achieved. Following that classification we have types of fibroids that may occupy a large part of the myometrial layer but also slightly protrude inside the endometrial cavity similar to the tip of the iceberg (types 2-5). The clinical implication of those fibroids is that the hysteroscopic visualisation of the tip of the fibroid may give the false impression about its accurate size and location.

As a consequence the surgeon may inappropriately engage in transcervical resection of such fibroid; which will not only be time consuming and incomplete but may also pose significant patient risks, such as bleeding or fluid overload.

Methods

3D ultrasound imaging to accurately identify the size and position of fibroid.

Hysteroscopic evaluation of the submucosal fibroid component, which may give false impression of its size and transcervical resection feasibility.

Results

This narrated video demonstrates the pre-operative assessment and surgical management with laparoscopic myomectomy for a type 2-4 fibroid demonstrated in simple reproducible steps.

The key pre-operative assessment steps include detailed 3D pelvic ultrasound imaging and diagnostic hysteroscopy.

The laparoscopic myomectomy steps include:

1. Adequate exposure of the surgical field with adhesiolysis.
2. Pitressin (synthetic vasopressin) injection to minimise intra-operative blood loss.
3. Monopolar hook to open the uterine serosa until the fibroid capsule is reached.
4. Enucleation of the fibroid with three instrument gentle traction-countertraction
5. Uterine defect intracorporeal suturing with interrupted Monocryl 1 sutures.
6. In-bag fibroid morcellation.
7. Final haemostasis and checks.

Conclusions

We have demonstrated the case of a type 2-4 fibroid removed with laparoscopic myomectomy. An international consensus on robust pre-operative assessment is necessary to avoid futile transcervical fibroid resections requiring prolonged operative time and/or multiple sessions.

<https://player.vimeo.com/video/827028815?autoplay=1>

Non-invasive ultrasound diagnosis of adenomyosis before pregnancy: correlation of type and localization of the disease and complications in pregnancy and at delivery

Giuseppe Gabriele Iorio¹, Sara Valeriani², Irene Colombi³, Elvira Nocita², Giorgia Soreca², Caterina Exacoustos²

¹University of Naples Federico II, Neuroscience- Reproductive Science and Odontostomatology, Naples, Italy

²University of Rome Tor Vergata, Surgical Sciences- Obstetrics and Gynecology of Unit, Rome, Italy

³Obstetrics and Gynecological Clinic-University of Siena, Molecular and Developmental Medicine, Siena, Italy

Background

The aim of this retrospective observational study was to investigate the correlation between the type, the localization and the degree of adenomyosis diagnosed by transvaginal-sonography (TVS) before pregnancy and reproductive outcomes and complications in pregnancy and at delivery.

Methods

In this retrospective observational study, we included all women attending the Gynaecological Ultrasound Unit of the University hospital Policlinico Tor Vergata from January 2018 to March 2023 with a non-invasive TVS diagnosis of adenomyosis followed by a pregnancy within 18 months from the scan. Adenomyosis was defined if at least one direct TVS sign was seen (MUSA,2022) and classify according to our previous published classification system (Lazzeri2018, Exacoustos2020). The type, the localization and degree of adenomyosis and all possible locations of endometriosis were correlated to pregnancy outcome evaluated in live birth, early pregnancy loss (miscarriage, ectopic pregnancy) and preterm delivery. Placentation, fetal growth and complications during pregnancy and at delivery were collected for each patient on medical charts and history and correlated to adenomyosis features.

Results

A total of 100 patients were included in the study group, all had a TVS-diagnosis of adenomyosis before their pregnancy. 62% patients had spontaneous pregnancy, while 38% underwent ART. Mean time from TVS-diagnosis of adenomyosis and pregnancy was 19.2±4.5 months (range 3-48 months). The average number of pregnancies and miscarriages were 1.54±1.26 and 0.47±0.99, respectively. Mean gestational age at delivery was 38.56±2.57 weeks. Regarding type of adenomyosis women showed more frequently diffuse lesions more than focal (70% vs. 30%, p<0.001). Adenomyosis localized only in the external myometrium more frequent than only of the junctional zone (67 % vs. 9%, p<0.001), in 24% the both myometrial layers were affected. 78% of patients had mild, 17% moderate and 5% severe grade of adenomyosis. Some pregnancy complications were observed in 34% of cases: 10% preclampsia, 12% preterm delivery and 12% fetal growth restriction. In all complicated pregnancy, the localization of adenomyosis was in the outer myometrium except for fetal growth restriction which was associated with focal adenomyosis of the inner myometrium. 33% of patients experienced postpartum haemorrhage: 12% between 500-1000 ml, 11% between 1000-2000 ml and 10% >2000 ml. Two patients were hysterectomised due to postpartum uterine atony. 20% of patients showed placental issues: 13 placenta previa, 6 abruption and 1 retention of the placenta. Caesarean section was performed in 62% of cases, while 38% of patients delivered spontaneously. Finally, endometriosis was observed in 69 patients (69%), particularly deep endometriosis in 90% of cases.

Conclusions

In patients with pregnancy desire, a non-invasive TVS-diagnosis of adenomyosis could be useful to identify risks of complications during pregnancy and at delivery. TVS-diagnosis should not only describe the presence of the pathology but attempt to classify it regarding type and localization in the myometrium layers.

Vaginal assisted NOTES hysterectomy in The Netherlands; a prospective cohort study

Ilse Bekkers¹, Rebecca Henschen¹, Nicol Smeets¹, Huib van Vliet², Anne Damoiseaux², Martine Wassen¹
¹Zuyderland Medical Centre, Gynaecology, Heerlen, The Netherlands
²Catharina Hospital, Gynaecology, Eindhoven, The Netherlands

Background

Hysterectomy is the most performed gynaecological surgery worldwide and when feasible, the vaginal hysterectomy is the preferred approach¹⁻⁴. In 2019 a new endoscopic approach was introduced in the Zuyderland Medical Centre; vaginal Natural Orifice Transluminal Endoscopic Surgery (vNOTES). NOTES uses the natural orifices of the body to gain access to the abdominal cavity and was first described in 2004⁵. vNOTES combines the benefits of laparoscopic and vaginal surgery. This abstract presents the results of the first vaginal assisted NOTES hysterectomy (VANH) during a learning curve of four gynaecologists in the Netherlands.

Methods

Patients who fulfilled the inclusion criteria were scheduled for a VANH from August 2019 to November 2022 in two non-academic teaching hospitals in the Netherlands. Exclusion criteria are history of more than one caesarean section, endometriosis, rectal surgery or pelvic radiation, suspected rectovaginal endometriosis, history of pelvic inflammatory disease (PID), virginity, pregnancy or a contraindication for general anaesthesia. Baseline characteristics and data of per- and postoperative surgical outcomes were recorded and analysed.

Results

A total of 171 patients underwent a VANH, with a mean surgical time of 61.5 minutes, mean blood loss of 90 ml and mean uterine weight of 149 gram. In 2.3% (n=4) of the cases a conversion was necessary. Same day discharge was possible in 79.5% (n=86) of the 109 patients who were planned to have the surgery in daycare setting. The mean reported NRS score (range 0-10) was 1, one hour post-operatively and 2 at discharge. In 1.8% (n=3) a per-operative complication- and in 9.9% (n=17) a post-operative complication occurred.

Conclusions

VANH is a feasible technique for performing hysterectomy with benign indications in a daycare setting, without increasing conversion or complication rates. These findings reflect the learning curve of four gynecological surgeons and provide further insight into the learning curve for VANH. Additional research is necessary to define the indications for vNOTES and determine its added value compared to other conventional surgical techniques such as laparoscopic hysterectomy and vaginal hysterectomy.

Literature

1. *Choosing the Route of Hysterectomy*. J Obstet Gynaecol India, 2015. **65**(4): p. 251-4.
2. *Global epidemiology of hysterectomy: possible impact on gynecological cancer rates*. Am J Obstet Gynecol, 2015. **213**(1): p. 23-29.
3. *Surgical approach to hysterectomy for benign gynaecological disease*. Cochrane Database Syst Rev, 2015(8): p. CD003677.
4. *Abdominal versus laparoscopic hysterectomies for benign diseases: evaluation of morbidity and mortality among 465,798 cases*. Gynecological Surgery, 2013(10): p. 5.
5. *Flexible transgastric peritoneoscopy: a novel approach to diagnostic and therapeutic interventions in the peritoneal cavity*. Gastrointest Endosc, 2004. **60**(1): p. 114-7.

**ES32-0520 -
Free Communication**

Multiple bowel deep endometriosis: when shaving finally meet bowel resection

Olivier Donnez¹

¹*Complex Endometriosis Center, Gynecology, Avignon, France*

Background

Multiple bowel deep endometriosis remains a difficult situation to manage as the goal is to remove all the visible lesions without increasing the complication rate.

Due to difference in diameter, thickness, anatomical landmarks and function, the rectum and the sigmoid should be differently managed when invaded by deep endometriosis

We present here our experience of multiple bowel endometriosis in associating shaving for rectal lesions concomitantly with bowel resection for sigmoid lesions.

Methods

43 patients present at least 2 bowel deep endometriosis lesions detected by MRI and colorectal imaging.

All surgeries were performed by laparoscopy associating shaving for the rectovaginal lesion and sigmoid resection with immediate anastomosis.

Surgical outcomes and post operative complications rates were prospectively reported.

Results

All surgeries were performed by laparoscopy without any conversion. In 2 cases, the sigmoidectomy could not be performed within the same procedure as the sigmoid lesion was too close to rectal lesion. In order to avoid an anastomosis in a shaved area, the sigmoidectomy was reported 3 months after the procedure

Hospitalisation stay was between 3 and 7 days.

No preoperative complication occurred as well as no rectovaginal fistula or anastomotic leakage.

Conclusions

The results of this small series suggest that shaving and bowel resection might associated to treat multiple bowel deep endometriosis with low complication rates.

**ES32-0591 -
Free Communication**

Laparoscopic isthmocele repair of a patient with Sheehan's syndrome prior to IVF treatment and its successful outcome: a video case report

Sofia Tsiapakidou¹, Georgios Kioussis¹, Eirini Iordanidou¹, Christos Anthoulakis¹, Themistoklis Mikos¹, Grigorios Grimbizis¹

¹Aristotle University of Thessaloniki,

1st Department of Obstetrics and Gynecology Aristotle University of Thessaloniki, Thessaloniki, Greece

Background

The presentation of a combined hysteroscopic and laparoscopic approach of a uterine isthmocele repair prior to IVF treatment in a patient with Sheehan's syndrome

Methods

A case report of a 35-year-old patient with a history of postpartum hypopituitarism due to massive blood loss during and after the emergency caesarean section two years before through a low transverse incision. Early diagnosis and appropriate treatment for Sheehan's syndrome were made. The patient immediately started hormone replacement therapy. The patient wished to become pregnant and was directed to an IVF service.

Results

Isthmocele was diagnosed incidentally on a transvaginal ultrasound examination that revealed a caesarean scar defect with a residual myometrial thickness almost absent and an abnormal uterine cavity. The patient was asymptomatic. The patient was counselled regarding the risks associated with this condition and the treatment options available and their complications. She opted for two-step surgical treatment. Written informed consent for reporting and publishing the case was obtained from the patient prior to the procedure. A laparoscopic isthmocele repair was performed. After a full uncomplicated recovery, she continued with the second-step approach, a diagnostic hysteroscopy with Asherman's syndrome as a finding. Hysteroscopic adhesiolysis was performed. She continued with IVF treatment. On the first cycle, the endometrium thickness was thin and was considered inadequate to continue and the cycle was cancelled. In the following cycle, performed infusion of platelet-rich plasma in the uterus to help in improving the thickness of the endometrium, and a frozen embryo transfer was done. Pregnancy was achieved. The antenatal period and screening were uneventful, and she delivered a healthy baby at 36 weeks. During the caesarean section, placenta accreta spectrum Grade 3A was first-time diagnosed, placental bed suturing and uterine compression sutures were done, and the uterus was preserved. The postpartum period for both mother and neonate were uneventful.

Conclusions

This is a rare case of a patient with Sheehan's syndrome due to massive intrapartum haemorrhage, who presented an isthmocele. The caesarean scar defect was successfully managed with a combined laparoscopic and hysteroscopic approach. After IVF treatment, the pregnancy continued uneventfully. A caesarean section was performed at 36 weeks due to medical indications, revealing a fully healed anterior uterine wall.

<https://player.vimeo.com/video/831645973?autoplay=1>

**ES32-0661 -
Free Communication**

Laparoscopic lateral niche repair

Nergiz Nagiyeva¹, Islam Magalov², Flora Huseynova¹, Gunel Mereyeva¹, Aygul Mamedova¹

¹Baku Health Center, Obstetrics and Gynecology, Baku, Azerbaijan

²Baku Branch of Sechenov Medical University, Obstetrics and Gynecology, Baku, Azerbaijan

Background

The caesarean scar defect or 'niche' has been reported as a consequence of improper healing of the uterine wound that is associated with future complications. Usually it is true about large defects determined as 'caesarean scar syndrome' including abnormal uterine bleeding, dysmenorrhea and secondary infertility (Pomorski,2017; Vervoort ,2018). Such cases along with quality of life worsening are associated with the high risk of PAS in subsequent pregnancies (Silver, 2015) and require timely surgical correction (Setubal, 2018, Rao, 2021).

Methods

The video demonstrates laparoscopic repair of large full of menstrual debris lateral niche located close to uterine vessels that was revealed by ultrasound. 28 years old patient complained of permanent bloody discharge alternating with heavy menstrual haemorrhage

Results

Total operative time was nearly two and half hours. Surgical intervention consists of adhesiolysis with resection of part of the omentum, opening of lateral spaces, ligation of uterine arteries, mobilization of the uterus, separation of the defect area from bladder and left bundle, resection of the protrusion, suturing of the wound and airtight re-peritonization. Amount of intraoperative blood loss was approximately 70 ml.

Conclusions

Excision of niche located close to the uterine vessels requires detailed dissection in retroperitoneal spaces, control of vessels and ureter to guarantee safe intervention.

<https://player.vimeo.com/video/835957768?autoplay=1>

**ES32-0669 -
Free Communication**

The first experience of reproductive function restoration in patients with Asherman's syndrome using autologous mesenchymal stem cells

Maksym Kozub¹, Mykola Kozub², Svitlana Gramatiuk³

¹Kharkiv National Medical University,

Department of Oncology- radiotherapy- oncologic surgery and palliative therapy, Kharkiv, Ukraine

²Kharkiv National Medical University, Obstetrics and Gynecology number 3, Kharkiv-, Ukraine

³Louisiana State University- USA., Department of Comparative Biomedical Sciences, Louisiana-, USA

Background

The main difficulties during the severe Asherman's syndrome treatment are to find effective ways to prevent adhesions that occurs after removal of intrauterine synechia and to restore the endometrium morphology in patients wishing to achieve pregnancy. The most promising technology in this area is the use of autologous endometrial stem cells.

Methods

New method of Asherman's syndrome treatment included hysteroscopic synechiolysis, subendometrial injection of autologous MSCs with an office hysteroscope; introduction of silver-IUD into the uterine cavity for 1 month, adjuvant oestrogen therapy for 3 weeks. The clinical case was a part of a clinical trial Clinical Trials.gov Identifier: NCT04675970. On the eve of the operative stage for uterine cavity synechia separation 20.0 ml of venous blood was taken. Mesenchymal stem cells (MSCs) were isolated from the patient's peripheral blood using the autoMACS Pro Separator (Miltenyi Biotec). The 6th passage MSCs were clinically used. MSCs were differentiated to endometrial cells, which was confirmed by cell matching markers in generations P0-P3 with the MicroBead Kit (USA). The operative stage of treatment included outpatient hysteroscopy, mechanical synechiolysis, introduction of a silver-containing intrauterine device. Subendometrial injection of 4 million autologous endometrial MSCs was performed at the end of hysteroscopy. High dose adjuvant oestrogen therapy followed for 3 weeks. In a month the patient B. underwent IUD removal, second-look office hysteroscopy, additional synechiolysis, subendometrial injection of 2 million of autologous endometrial cells.

Results

19 months after last procedure, as a result of spontaneous conception, patient B. gave birth to a live full-term girl weighing 3750 g, postpartum period without complications

Conclusions

The results of the clinical case indicate the prospects for the use of autologous blood stem cells converted into endometrial cells in the treatment of infertility in patients with Asherman's syndrome in the absence of effect from previous attempts to restore fertility by traditional therapy

<https://player.vimeo.com/video/839856504?autoplay=1>

**ES32-0248 -
Free Communication**

Difficult paraaortic lymphadenectomy and ovarian transposition in a patient with locally advanced cervical cancer

Nasuh Utku Doğan¹, Selen Dogan¹, Saltuk Bugra Arıkan¹, Tuba Metin¹

¹Akdeniz University, Gynecology, Antalya, Turkey

Background

Lymph node metastasis particularly in paraaortic region could be missed in more than 30 % of patients with locally advanced cervical cancer and these patients will be upstaged by surgical staging. By discovering metastatic lymph nodes in paraaortic region, the radian field is extended and in a number of studies, the progression free survival is increased by surgical staging (especially in stage IIB patients)

Methods

In this video presentation, a 31 years old multiparous woman was referred to our clinic with the complaints of abnormal uterine bleeding 8 months after the caesarean delivery of her last child.

Results

She was clinically stage IIB. The tumour diameter was 6 cm with an extension to parametria. In Pet CT scan, there was metastatic lymph nodes in pelvic lymph nodes. In multidisciplinary tumour board, laparoscopic paraaortic staging and ovarian transposition was recommended. Laparoscopic paraaortic staging along with removal of bulky lymph nodes was performed together with ovarian transposition. Total operation time was 185 minutes and with 50 cc blood loss without any complications. The patient was discharged on post-operative second day. In final pathology, 4/12 metastatic paraaortic lymph nodes were revealed and the patient was referred for extended field chemoradiotherapy.

Conclusions

By laparoscopic paraaortic staging, possible metastatic paraaortic lymph nodes are discovered and the extend of radiotherapy changes depending on the findings. Radiotherapy could be administered without any delay after laparoscopic staging. Particularly in stage IIB patients, laparoscopic staging contributes to disease free survival and these kind of patients should be surgically staged.

<https://player.vimeo.com/video/826775096?autoplay=1>

**ES32-0203 -
Free Communication**

Comparisons of single-site & SP daVinci robot lymphadenectomy

Sejin Kim¹, Keun Ho Lee¹

¹Seoul St. Mary's hospital, OBGYn, Seoul, Korea- Republic Of

Background

There are two single port robotic systems, single-site or SP daVinci, available in gynaecology. Here we submit the video that show the comparisons of two systems.

Methods

A 56 year-old woman came to our clinic because of bleeding. About 5.2cm sized endometrial mass lesion without definite deep myometrial invasion was found on pelvic MRI and endometrioid carcinoma was revealed on her endometrial biopsy. SP daVinci paraaortic lymphadenectomy as well as total hysterectomy and salpingoophorectomy was done.

Results

SP robotic system has an advantages to single-site robotics

Strong power identical to multiport

Various instruments developed

Applicable to various surgeries not only gynaecology

But compared to single-site robotics, SP daVinci move slowly and take a time to learn third arm manipulation.

Conclusions

Compare to single-site robotics, SP daVinci can use third arm to assist the operation. With SP daVinci system, paraaortic lymphadenectomy was safely done.

<https://player.vimeo.com/video/826780318?autoplay=1>

A real-world health economic study in China: using DNA methylation marker for triage of hrHPV-positive women in cervical cancer screening

Hsiang Yu Chuang¹, Le Li², Yuligh Liou³, Pei Liu⁴

¹Beijing OriginPoly Bio-Tec Co.- Ltd, Medical Department, Beijing, China

²Peking Union Medical College Hospital, Department of Obstetrics and Gynecology, Beijing, China

³The First Affiliated Hospital of Guangdong Pharmaceutical University, Clinical Precision Medicine Research Center, Guangzhou, China

⁴Beijing OriginPoly Bio-Tec Co.- Ltd, R&D Department, Beijing, China

Background

This study aims to evaluate the health economic impact of using DNA methylation markers for the triage of hrHPV-positive women in cervical cancer screening, based on a large-scale real-world dataset in China. It also explores approaches to reduce the usage of colposcopy.

Methods

A comprehensive health economic analysis was conducted using data from a population-based screening program in China, including cost-effectiveness and cost-utility analyses. A prospective study was conducted between 2020 and 2022 in China to assess the feasibility of opportunistic cervical cancer screening in outpatient settings. A total of 15,470 participants were enrolled in the study. Cervical brush sampling was performed on all participants to collect cervical exfoliated cells. These cells were then subjected to analysis using liquid-based cytology, HPV testing, and PAX1-JAM3 gene methylation detection (CISPOLY, China). The results obtained were compared with pathological findings. The positivity rate, sensitivity, specificity, and accuracy of all tests were calculated for statistical analysis. The performance of the DNA methylation marker in identifying cervical intraepithelial neoplasia grade 2 or worse (CIN2+) was assessed, and the potential economic benefits were estimated.

Results

Among all enrolled participants, women aged 30-60 accounted for 80% of the population. There were no significant age differences in the pathological sample results. The utilization of PAX1-JAM3 gene methylation detection achieved a 100% detection rate for squamous cell carcinoma (SCC) and adenocarcinoma (ADC) of the cervix, without causing any missed diagnoses across all age groups. DNA methylation markers demonstrated good accuracy in the classification of hrHPV-positive women, exhibiting high sensitivity and negative predictive value in identifying CIN2+ cases. Cost-effectiveness analysis indicated that incorporating PAX1-JAM3 methylation testing as a triage method for women with non-16/18 hrHPV infections could potentially reduce colposcopy rates by 28.68% and result in a cost savings of \$1.4 million per 10,000 individuals screened. Results: The DNA methylation marker demonstrated good accuracy in triaging hrHPV-positive women, with a high sensitivity and negative predictive value for identifying CIN2+ cases. The cost-effectiveness analysis showed that incorporating the DNA methylation marker into the screening program could significantly reduce unnecessary colposcopies and increase the detection rate of CIN2+ at an acceptable cost. The cost-utility analysis further demonstrated the long-term economic benefits of using the DNA methylation marker in terms of quality-adjusted life years gained.

Conclusions

The incorporation of a DNA methylation marker for triaging hrHPV-positive women in cervical cancer screening has the potential to improve the efficiency and cost-effectiveness of the screening program in China. This real-world health economic study provides valuable evidence to support the implementation of DNA methylation-based triage strategies in cervical cancer screening programs.

Posterior pelvic exenteration for a case of primary vaginal adenocarcinoma (intestinal type) laparoscopic-vaginal approach

Mohamed Nabil¹, Ahmed Alsibaie², Asmaa Abdelfattah³, Mohamed Shehta³, Sherif Soliman⁴, Haitham Fekry²

¹*Cairo university, obstetrics and gynecology, Cairo, Egypt*

²*Cairo university, surgical oncology, Cairo, Egypt*

³*Misr international hospital, obstetrics and gynecology, Giza, Egypt*

⁴*Armed Forces College of Medicine, obstetrics and gynecology, Cairo, Egypt*

Background

We report a case of a 49-year old female patient presenting with a vaginal mass, biopsy revealed vaginal adenocarcinoma. After excision, the histopathological assessment confirmed primary vaginal adenocarcinoma of intestinal type.

She presented with dyspareunia and sensation of vaginal swelling. Physical examination was done under anaesthesia, and it revealed a large solid mass that bleeds on touch, arising mainly from the right lateral vaginal wall located at 11'o clock introitus position.

By Digital rectal examination, the mass was indenting the anterior rectal wall 3 cm from the anal verge with intact overlying mucosa and sliding over the underlying mass.

Methods

Hysteroscopy using vaginoscope approach was done to assess the extensions, confirming their location more on the right side with direct contact with the cervix and narrowing of the vagina with high vascularity and irregular margins. There were no significant changes in the uterine cavity, showing normal endometrium in the secretory phase. Multiple punch biopsies were taken confirming the same pathology.

The patient underwent laparoscopic assessment to exclude any colonic masses or peritoneal disease; posterior pelvic exenteration and bilateral pelvic lymph node dissection were done laparoscopically. Mobilization of the left colon was done up to the splenic flexure to be used in restoring bowel continuity.

After completion of the abdominal part, complete excision of the vagina was done in lithotomy position with en-bloc resection of the infiltrated rectal segment, and the urethra was preserved as it was not grossly involved, with vaginal safety margins excised from the right side close to it for histological confirmation.

A colorectal hand-sewn anastomosis in end-to-end fashion was done. A diverting loop ileostomy was established with closure of the vulva in layers.

Results

The procedure and postoperative hospital stay went uneventfully, and the patient was discharged with silicon urinary catheter that was removed 10 days later.

Histopathological assessment revealed a posterior vaginal wall mass 4.5cm in the largest dimension, reaching rectal wall. vaginal, cervical, and rectal intestinal type adenocarcinomas all invaded by the same growth (pT4), free vaginal and rectal safety margins, with negative bilateral pelvic lymph nodes 0/7 .

Conclusions

The diagnosis of primary vaginal adenocarcinoma of the intestinal type is extremely rare, as vaginal adenocarcinoma is most frequently a metastatic lesion.

Currently, there are no guidelines or gold standards of management for the treatment of primary vaginal adenocarcinoma due to the rare occurrence of the disease. In the literature, radical surgery was done for resection of the tumour with at least 1cm safety margin. This has been proven to carry little morbidity.

In our case, posterior pelvic exenteration was done with clear surgical margins through a laparoscopic vaginal approach, which appeared safe, feasible and of low morbidity.

<https://player.vimeo.com/video/826905527?autoplay=1>

Clinical value of combined methylation of *CDO1* and *CELF4* genes and endometrial thickness detection in postmenopausal women with endometrial cancer

Lei Li¹, Xiaopei Chao¹, Linghua Kong¹

¹Peking Union Medical College Hospital, Department of Obstetrics and Gynecology, Beijing, China

Background

Endometrial carcinoma (EC) is the most common malignant tumour of the female genital tract in high income countries and the sixth most frequent in women worldwide. At present, 67% of women have diagnosed stage I or stage II EC, mainly due to vaginal bleeding in postmenopausal women. Given the prevalence of postmenopausal bleeding and its correlation with EC and benign diseases, it is essential to accurately quantify the EC risk of symptomatic women. Transvaginal ultrasound (TU) screening using endometrial thickness (ET) was also proposed for symptomatic postmenopausal women. Unfortunately, an ET cutoff of 5mm showed lower sensitivity and specificity. There is no effective non-invasive EC screening strategy for symptomatic women now. To explore the clinical value of combined methylation of *CDO1* / *CELF4* genes and endometrial thickness detected by TU in detection endometrial cancer in postmenopausal women.

Methods

From May 2020 to October 2021, 363 females were enrolled from the hysteroscopic clinic of Peking Union Medical College Hospital. The methylation tests were determined by CisEndo methylation (*CDO1* and *CELF4*) real-time system (Beijing OriginPoly Bio-Tec Co., China) using cervical exfoliated cells samples. ET (+) \geq 5mm was positive in postmenopausal women. The *CDO1* and *CELF4* methylation detection and TU alone and in combination were analysed. Standard guidelines for the diagnosis, treatment, and management of endometrial cancer were followed in all participants.

Results

The sensitivity and specificity of *CDO1* and *CELF4* methylation combination detection were over 87.5% and 90.8%, respectively. The sensitivity and specificity of TU examination in postmenopausal women were more than 81.1% and 39.5%, respectively. In the combination of the target methylation genes and TU examination, any positive result of each tests has 100% sensitivity, while the two full positive ones have 95.6% specificity. Non-invasive detection of cervical exfoliated cells by methylation test alone or combined with TU in a gynaecological outpatient are superior to the current detection results.

Conclusions

For postmenopausal women, *CDO1* and *CELF4* methylation detection has higher sensitivity and specificity than ultrasound. It can indicate high risk of endometrial cancer before hysteroscopy, reduce missed diagnosis and improve the accuracy of biopsy and hysteroscopy. The combined *CDO1* and *CELF4* methylation detection and TU examination could improve the non-invasive early detection rate of endometrial cancer in outpatient clinic, and to avoid repeated invasive examinations for women.

Laparoscopic vs. robotic-assisted laparoscopy staging in molecular era of endometrial cancer

*Emanuele Perrone¹, Vincenzo Tarantino¹, Giovanni Esposito¹, Luca Palmieri¹, Giovanni Scambia¹,
Francesco Fanfani¹*

¹*Policlinico Universitario A. Gemelli IRCCS - Rome, Gynecologic Oncology, Rome, Italy*

Background

Nowadays, robotic surgery (RS) and laparoscopy (LPS) are considered superimposable in endometrial cancer staging. Recently, supported by the comprehensive genomic analysis of The Cancer Genome Atlas (TCGA), the pathogenesis of endometrial cancer (EC) has been enriched by innovative genomic and molecular information. In this context, no recent evidences are available to assess the role of minimally invasive surgery in EC staging in this new way to intend this gynaecological cancer.

The aim of this study is to analyse and drawn potential differences between the robotic surgery (RS) and the laparoscopy (LPS) in endometrial cancer staging in the era of molecular classification.

Methods

In this single-institution retrospective study, we enrolled 1279 consecutive presumed uterine-confined EC patients undergone minimally invasive surgical staging. We compared patients treated by LPS and RS, on the basis of perioperative, histopathologic, molecular and survival outcomes (disease free survival, DFS).

Immunohistochemistry (IHC) analyses were performed to assess the presence/absence of oestrogen receptors (ER negative, ER- or ER positive, ER+) and other molecular factors (i.e., p53 mutation, p53abn; and mismatch repair mutational status, MMR-deficient, MMRd vs MMR-proficient, MMRp). The study population was stratified in MMRp\ER+, MMRp\ER-, MMRd, and p53abn. Then, we investigated the impact of the surgical rout in each of these 4 molecular EC classes.

Results

The two cohorts (753 treated by LPS and 455 by RS) were constitutive not homogeneous in terms of BMI, risk and molecular class and, adjuvant therapy ($p < 0.05$). Stratifying for molecular classes, the Kaplan-Meier survival curves for DFS demonstrated that LPS and RS were comparable in MMRp\ER+, MMRd, and p53abn EC patients ($p = 0.331$, $p = 0.916$ and $p = 0.725$ respectively), whereas resulted to be statistically different in MMRp\ER- EC patients, with the RS that demonstrated a clear advantage respect to LPS in terms of DFS ($p = 0.034$).

Conclusions

In our large retrospective analysis, we confirmed that the RS and LPS have similar efficacy and safety for endometrial cancer staging also stratifying according the new molecular classification. Further researches and longer follow-up are required to assess the role of surgical route in MMRp\ER- population, that represents the molecular EC class without a clear molecular signature and mostly of the time with unexpected clinical behaviour.

**ES32-0572 -
Free Communication**

Ovarian cancer staging: step by step

Maria Inês Nogueira E Sousa¹, Ana Almeida¹, Tiago Meneses², Hélder Ferreira²

¹CMIN - CHUPorto, Departamento da Saúde da Mulher e Medicina Reprodutiva, Porto, Portugal

²CMIN -CHUPorto, Departamento da Saúde da Mulher e Medicina Reprodutiva, Porto, Portugal

Background

Ovarian cancer is the second most common gynaecologic malignancy in high-income countries and the diagnosis is established in advanced stages of the disease in around 75% of cases. Minimally invasive surgery (MIS) currently is performed to stage and treat ovarian cancer at different stages of disease, representing a safe and adequate procedure for treating and staging early ovarian cancer. For this reason, its use has increased significantly in clinical practice. Major concerns with the use of MIS are related to minimizing tumour disruption or dissemination, removing the adnexal mass intact, adequate retroperitoneal staging and fertility-sparing surgery for young patients.

Methods

This video consists of a description of the surgical procedures that are included in the laparoscopic staging of a mucinous borderline ovarian cancer. These procedures can also be included in the surgical staging of other epithelial cancers, together with additional steps according to the situation.

Results

This video illustrates and describes the technique used to perform laparoscopic infra-colic omentectomy, appendicectomy and peritoneal biopsies. In this case, staging surgery was performed at the same operating time of the primary treatment: total hysterectomy with bilateral salpingo-oophorectomy, having the surgical products been sent to extemporane examination before completing the procedure.

Conclusions

MIS is not only feasible but also effective in the staging surgery if performed by a specialized and experienced oncologist with a well-trained operating team. The high sensitivity and specificity of this extemporane examination make it possible to consider a surgical management of staging during the same operating time of the primary treatment. However, further large-scale prospective studies are required to examine the long-term outcomes of this surgical procedure.

<https://player.vimeo.com/video/832449490?autoplay=1>

**ES32-0013 -
Free Communication**

Setting up a day case pelvic floor surgery service

Laura Horne¹, Eric Mutema¹, Zinal Salian¹

¹Blackpool Victoria Hospital, Obstetrics & Gynaecology, Blackpool, United Kingdom

Background

Pelvic floor surgery is a commonly performed area of gynaecology surgery and accounts of a large proportion of postoperative gynaecology admissions. Day cases pelvic floor surgery including vaginal hysterectomy is a subject of debate and in need of more evidence demonstrating safety and acceptability. For the past 5 years, our unit has safely implemented same day discharge for all our pelvic floor and vaginal hysterectomy procedures. This is a review of the outcomes and a guide of how to set up a day case pelvic floor surgery service.

Methods

A retrospective service evaluation of our last 100 patients was undertaken and discuss the pillars of setting up the service as well as the pitfalls to avoid.

Results

Due to the pandemic the number of surgeries undertaken were low. Complete records of 71 pelvic floor surgeries were obtained and reviewed. These were undertaken between June 2020- March 2022 by a single consultant at a district general hospital. 88% (63) of patients were sent home on the same day with 7% (5) discharged the following day, 3% (2) discharged after 2 days and only 2% (1) discharged 3 days later. Reasons for overnight admission anaesthetist preference, raised NEWS2 score postoperatively and social reasons.

Conclusions

Pelvic floor surgery can be successfully performed as a day case surgery for the majority patients. It is important to incorporate a multidisciplinary team approach to planning day case pelvic floor surgery and to ensure the patient's expectations regarding same day discharge are preoperatively addressed. Patients should be appropriately counselled preoperatively to ensure their expectations are paralleled. There is no increase in postoperative complications or adverse outcome associated with day case surgery.

**ES32-0300 -
Free Communication**

Lateral laparoscopic suspension using only an anterior mesh: our approach to this promising technique

Ángel Miguel González Aranda¹, Juan Antonio Solano¹, Juan Jose Delgado¹, Jerónimo González¹, Angela Maria Garcia¹, Álvaro Zapico¹

¹Hospital universitario Príncipe de Asturias, Gynecology, Alcalá de Henares-Madrid, Spain

Background

Pelvic organ prolapse (POP) affects up to 40% of women, especially with age. Apical prolapse requires anatomical correction of all vaginal compartments. Laparoscopic sacral colpopexy, gold standard treatment, is complex and has complications. Abdominal lateral suspension with mesh is a less complex alternative, involving a T-Shaped synthetic mesh anchored to the vaginal wall, cervix, and external oblique muscle. Lateral laparoscopic suspension with mesh involves implanting two meshes, but some recent series have used only the anterior mesh.

Methods

The patient in the video is a 68-year-old female who presented to our clinic with pelvic bulge symptoms that had worsened over the last four years. She had no urinary incontinence, and her CMI was 28. She had three previous pregnancies, weighed less than 4 kg, and had no major illnesses or prior surgeries. A grade II cystocele and grade IV isthmocele were observed, and she was referred to our hospital's pelvic floor unit for further evaluation. The initial examination confirmed these findings, and no urinary incontinence was detected.

Results

We utilized TiLOOP® LLS Dubuisson, a type 1a polypropylene mesh that is microporous and composed of monofilaments with a titanised surface that is hydrophilic. This type of mesh offers several advantages over simple polypropylene, which are already well-established in the use of titanised mesh implants for hernia surgery. These include reduced inflammation risk, hydrophilicity, decreased shrinkage, superior tissue integration, and reduced foreign body sensation.

In this video, we showcase our approach to LLS utilizing solely an anterior mesh. While retaining the essential elements of the original procedure, we have introduced the use of CapSure™ to aid in the initial fixation to the uterus isthmus. This has proven to enhance the precision and simplify the process of mesh fixation. Additionally, the mesh is sutured with a nonabsorbable, braided size 1 suture and finalized its fixation using a surgical glue (IFABOND®) that possesses haemostatic properties. Lastly, the vesicovaginal space closure is carried out using a barbed suture of 0 size. Skin-to-Skin time was 1 hour and 38 minutes.

Conclusions

Lateral laparoscopic suspension is a valid and effective surgical technique for correcting apical and anterior compartment defects. Compared to colposacropexy, it is a faster procedure and has been shown similar outcomes.

<https://player.vimeo.com/video/826982867?autoplay=1>

**ES32-0119 -
Free Communication**

**Laparoscopic sacrocolpopexy – an option to correct concomitant pelvic organ- and rectal-prolapse.
A surgical Video.**

Evgenia Bousouni¹, Dimitri Sarlos¹

¹Kantonsspital Aarau, Frauenklinik, Aarau, Switzerland

Background

Laparoscopic sacrocolpopexy has been demonstrated to be the gold standard of prolapse surgery in cases with apical defect. According to our data, we have a result in a subjective cure rate of 95% after laparoscopic sacrocolpopexy. By patients with concomitant pelvic organ- and rectal-prolapse, we offer the option to combine laparoscopic sacrocolpopexy with rectopexy in order to solve the combined problem.

Methods

The video demonstrates the case of a 63 years old patient undergoing laparoscopic sacrocolpopexy because of vaginal prolapse II° and rectal prolapse III°. The anterior dissection is started by opening the vesico-vaginal space. Lateral dissection is performed by opening the paravaginal space and exposing the lateral edge of the vagina. The distal part of both ureters is dissected from the anterior parametrium to the bladder to avoid ureteral damage. The transient fixation of sigma after loosening of adhesions to the pelvic wall with T-Lifts helps to have more space and a much better view of structures in the posterior compartment and gives an optimal approach to the rectovaginal space. We dissect the rectum gradually from the posterior wall of the vagina until the muscles of the pelvic floor for deep attachment of the mesh in the posterior compartment. The exposing of rectum is important in order to fix the mesh on it and to remove it in the right position. Posterior mesh is sutured on the levator ani muscle and additionally on the rectum with four non-absorbable sutures. Both meshes are fixed at the longitudinal ligament of the promontory. At the end a fully peritonealisation is performed. The preparation is anatomically not much difficult comparing with sacrocolpopexy but the experience of gynaecologist is decisive.

Results

The outcome of laparoscopic sacrocolpopexy in our patient group is excellent. We made in the last 2 years five cases of recurrence after laparoscopic sacrocolpopexy. As we are following all our patients after laparoscopic sacrocolpopexy, we have very good results at least in the short-term follow up.

Conclusions

Laparoscopic sacrocolpopexy seem to be feasible and safe and is an option to correct laparoscopically concomitant pelvic organ- and rectal- prolapse in order to avoid laparotomy. This method can be performed by experienced gynaecologists. Prospective anatomical and functional evaluation and data analysis must be done to scientifically verify these promising initial results.

<https://player.vimeo.com/video/826278698?autoplay=1>

**ES32-0166 -
Free Communication**

Advancing robotic platforms in pelvic floor reconstructive surgery: assessing feasibility and outcomes.

Giorgia Gaia¹, Margarita Afonina¹, Stefano Terzoni², Alessandro Morandi¹, Giovanni Francesco Leva¹, Anna Maria Marconi¹

¹San Paolo Hospital Medical School, Department of Obstetrics and Gynecology, Milan, Italy

²San Paolo Hospital Medical School, San Paolo bachelor school of Nursing, Milan, Italy

Background

Pelvic floor reconstructive surgery represents a challenging procedure. The techniques have undergone significant developments to manage the limited vision and the pelvic cavity access hurdle. The 2012 FDA ban on transvaginal prosthetic surgery prompted significant innovations. The introduction of minimally invasive surgery in urogynaecology has improved outcomes by reducing risks through better visualization. Reintroducing minimally invasive prosthetic mesh has bridged the gap between vaginal and open surgery. The Da Vinci[®] enhanced dexterity, 3D visualization, and faster recovery time has depicted cornerstones in this setting. Since 2019, new competitors have raised to maintain the advantages of robotics while cutting costs. HUGO[™] RAS and Versius CMR, used for urological, gynaecological, and general surgery procedures, present four fully independent carts to be docked individually and an open 3D console. We aimed to prove the feasibility of the prosthesis pelvic floor reconstructive surgery with the new robotic platforms operative at our tertiary referral centre: HUGO[™] RAS, Versius CMR, and Da Vinci[®].

Methods

We enrolled patients undergoing robot-assisted surgery for pelvic organ prolapse ≥ 2 , according to the pelvic organ prolapse quantification (POP-Q) system, between November 2021 and May 2023 at San Paolo University Hospital, Milan, Italy. Demographical, surgical set-up, intra-operative and peri-operative outcomes were collected. In addition, anatomical, functional, and quality of life outcomes were analysed by the validated questionnaires P-QOL, PFDI-20, and PISQ-12, administered before and six months after the surgery.

Results

65 procedures were carried out by the same expert robotic surgeon (>300 Da Vinci[®] procedures). All surgeries went uneventfully according to the Clavien-Dindo classification. Blood losses were negligible for all the patients. Surgical set-up, docking and console time, catheter removal, and length of stay were similar between the three platforms. At the time of abstract submission, the outcomes of 62 patients were available (age 63 ± 10 , BMI 27 ± 4 Kg/m², 40 first operations). 31 presented third-degree prolapse, 18 a fourth degree, with tri-compartmental ($n=22$), bicompartamental ($n=31$) and single hysterocele prolapse ($n=9$). Thirty-seven underwent robotic promontofixation (including 7 with Burch) or lateral suspension, according to Dubuisson ($n=25$). There were significant differences in quality-of-life scores (PQOL $p < 0.001$, $d=1,33$), symptomatology (PFDI-20 $p=0.008$, $d=1,33$), but not in sexual function (PISQ-12 $p=0.101$, $d=0.320$). Six patients (all undergoing lateral suspension according to Dubuisson) presented an anatomical recurrence in the six months of observation (13%), of which only 3 (6%) were symptomatic.

Conclusions

The feasibility of robotic reconstructive surgery for pelvic floor disorders remains consistent regardless of the platform used. The remarkable comparability of results achieved through these three platforms highlights the reproducibility of the technique, even when employing novel systems. Despite anatomical variations and the complexity of the disorders, robotic technology in urogynaecology has led to significant improvements in surgical approaches. Standardization of the technique requires appropriate training and knowledge.

**ES32-0353 -
Free Communication**

An uncommon cause of chronic pelvic pain: mesh fixation on the sacral nerve

Taner Usta^{1,2}, Gul Sema Can Akyol², Salih Yilmaz², Aysel Ozkaynak², Ahmet Kale³

¹Acibadem Altunizade Hospital- Mehmet Ali Aydinlar University, Obstetrics and Gynecology, Istanbul, Turkey

²Acibadem Altunizade Hospital, Gynecology and Obstetrics- Endometriosis and Pelvic Pain Center, Istanbul, Turkey

³University of Health Sciences, Gynecology and Obstetrics, Istanbul, Turkey

Background

Chronic pelvic pain (CPP) is described as pain in the pelvic region lasting over six months. CPP patients are mostly diagnosed with endometriosis, adhesions, irritable bowel, or interstitial cystitis. Mental health disorders are also accused. However, before attributing these symptoms to a psychological issue, the patient must be reassessed carefully to exclude rare causes of the pain.

Herein we report a case of mesh fixation on bilateral sacral nerves causing chronic pain.

Methods

Case: A 52-year-old female presented with unrelenting pelvic and perineal pain since the operation she had in 2016 for prolapse. She had undergone many examinations, imaging, colonoscopies, and even a hysterectomy four years ago for this pain. She could only sit on a cushion she made and was afraid to eat anything other than bread and lettuce because of the dyschezia.

A hypoechogenic structure was spotted between the vagina and the rectum on transvaginal and transrectal ultrasound. This area was very dense and tender with palpation. An MRI, performed to rule out any endometriotic lesion involving the region, showed no pathology.

The laparoscopic dissection of the vault from the rectum exposed the mesh. Following the mesh towards both lateral sides revealed bilateral ends of the mesh fixed on the sacral nerves with non-absorbable sutures. The mesh has been excised completely.

Results

The patient was discharged on the second postoperative day with no perioperative complications. Her symptoms were almost entirely resolved by her visit on the 6th week after surgery.

Conclusions

Fixation of mesh on the sacral nerve instead of the sacrospinous ligament may cause CPP due to the mesh itself and the sutures used for fixation. Thus, this relatively rare cause must be considered when evaluating CPP patients.

<https://player.vimeo.com/video/827031937?autoplay=1>

Modified plastron technique by vaginal natural orifice transluminal endoscopic surgery for anterior compartment repair

Luka Matak¹, Maša Šimičević², Branko Dukić³, Magdalena Matak⁴, Slavko Orešković⁵, Jan Baekelandt⁶

¹General Hospital Zadar, Gynecology and Obstetrics, Zadar, Croatia

²Zadar County Health Centre, Obstetrics and Gynecology, Zadar, Croatia

³General Hospital Zadar, Obstetrics and Gynecology, Zadar, Croatia

⁴General Hospital Zadar, Dermatovenerology- Internal Medicine Department-, Zadar, Croatia

⁵University Hospital Center Zagreb, Gynecology and Obstetrics, Zagreb, Croatia

⁶Imelda Hospital, Gynecology and Obstetrics, Bonheiden, Belgium

Background

The vaginal plastron technique is based on bladder support by a vaginal strip attached to the bladder, combined with suspension by fixation of the vaginal strip to the tendinous arch of the pelvic fascia with six sutures, three per each side. Presented in this article is a modified version of the abovementioned procedure with the intent of achieving a more physiological position.

Methods

A rectangular-shaped strip was marked on the anterior vaginal wall, 7x3cm in size. Hydro dissection was performed and the plastron patch margins were incised. The paravesical space was then developed using blunt dissection. A 7cm Alexis was placed in paravesical space with GelPOINT V-path transvaginal access platform. The paravesical space was subsequently insufflated to a pressure of 10 mmHg. A non-resorbable 1-0 green braided polyester (Ethibond) suture was placed on anterior part of arcus tendinous close to pubo-vesical ligament. A second suture was placed on sacrospinous ligament, 1 cm medial from the ischial spine. The same procedure was then repeated on the other side. The sutures were attached to the angles of the vaginal strip and the patch was fixated by their traction. The vaginal mucosa was closed using simple interrupted sutures.

Results

During her post-operative recovery the patient complained of lumbo-ischiatic pain on her left side, which she had also been experiencing chronically pre-operative. She was treated for three days with intravenous analgesics. No other complications were recorded. The patient was discharged on the 6th post-operative day without any complaints. After 7 months of follow up the patient was without any prolapse symptoms and no compartment defects were observed.

Conclusions

This approach, as described, uses two sutures at both lateral sides, and while the anterior is also positioned at ATRP, the posterior is placed on sacrospinous ligament with the intent of achieving a more physiological position. Research suggests that associating plastron with sacrospinous ligament fixation by an anterior approach (SSLF-A) leads to lower recurrence rate in comparison to isolated SSLF-A or associated with the anterior colporrhaphy, as it is allowing the repair and suspension of both anterior and apical compartment defects. A vNOTES approach allows direct visualization of operating field and structures and therefore serves as a solution for avoiding vascular and nerve damage. vNOTES presents itself as fast and efficient approach with good treatment outcomes, but there is still a need for larger studies to prove its efficacy.

<https://player.vimeo.com/video/827037633?autoplay=1>

**ES32-0440 -
Free Communication**

Indirect electrocoagulation through round ligament fragment for promontory bleeding control in laparoscopic colposacropexy surgery

Milenko Pavlovic¹, Cesar Sandoval¹, Marcelo González¹, Rodrigo Guzman¹, Marco Puga¹

¹Facultad de Medicina Clínica Alemana Universidad del Desarrollo, Obstetrics and Gynecology, Santiago, Chile

Background

Presacral and promontory venous bleeding is an uncommon but potentially life threatening complication of rectal and gynaecological surgery. Promontory bleeding control after passing the mesh fixation suture in colposacropexy surgery, may be challenging due the lack of soft tissue to perform electrocoagulation.

Methods

We present one case of indirect electrocoagulation through a round ligament fragment to control promontory diffuse venous haemorrhage after the placement of the mesh fixation suture in a subtotal hysterectomy plus colposacropexy procedure.

Results

After attempting to perform direct electrocoagulation with a bipolar forceps to achieve haemostasis in a promontory venous diffuse bleeding, without results, we decided to use autologous tissue to perform an indirect electrocoagulation to gain haemostatic control. It is described in the literature the use of muscle fragments to attain haemostasis in diffuse presacral venous bleeding in rectal surgery. In this case, the use of a round ligament fragment was chosen because of the fast access and simplicity to obtain the tissue sample. We performed a cold scissors section of a 1 cm right round ligament sample and held in place with a forceps over the bleeding area; electrocoagulation with a bipolar forceps is then applied to the round ligament fragment, welding the bleeding site.

Conclusions

The use of autologous tissue to achieve haemostasis in promontory diffuse venous bleeding, is an effective and reproducible technique. Round ligament tissue is easy to harvest in cases where an hysterectomy is performed simultaneously with the colposacropexy procedure. For previously hysterectomized patients, the use of an epiploic appendix may be an alternative.

<https://player.vimeo.com/video/828515077?autoplay=1>

Endoscopic minimally invasive treatment of pelvic organ prolapse

Andrei Manu¹, Bogdan-Catalin Coroleuca², Ciprian Andrei Coroleuca², Elvira Bratila²

¹Clinical Hospital of Obstetrics and Gynaecology "Prof. Dr. Panait Sârbu"-Bucharest- Romania, Obstetrics and Gynecology, Bucharest, Romania

²Clinical Hospital of Obstetrics and Gynaecology "Prof. Dr. Panait Sârbu"- University of Medicine and Pharmacy "Carol Davila"- Bucharest- Romania, Obstetrics and Gynecology, Bucharest, Romania

Background

Symptomatic pelvic organ prolapse has a relatively high prevalence and women have a 13–20% lifetime risk of having a surgical procedure to repair vaginal support defects. Despite the anterior vaginal compartment being the most common site of pelvic organ prolapse (POP), the loss of apical support is typically associated with defects that usually occur at the insertions of cardinal-uterosacral ligament complexes, pubocervical fascia, and rectovaginal fascia to the pericervical ring. Minimally invasive pelvic surgery to correct pelvic organ prolapse primarily includes laparoscopic or robotic assisted hysterectomy / sacrocolpopexy for defects that are more than grade III (grade III and IV) and the native tissue alternative of uterosacral ligament culdoplasty and suspension and or plication of pubocervical fascia for defects that are less than grade III (grade II or III) .

Methods

In this paper we will present several cases of pelvic organ prolapses through which we will highlight the techniques and advantages of the minimally invasive pelvic reconstructive surgery. 47 patients with POP were treated in our clinic by minimally invasive surgery.

Results

45 patients were treated by high uterosacral ligament plication associated or not with pubocervical fasciae plication and or sacrocolpopexy. In just 2 cases we have done the sacropexy procedure alone. In 9 cases we had to complete the laparoscopic surgical cure with the transvaginal posterior repair for rectocele and 11 patients needed posterior colporrhaphy and perineorrhaphy. In 13 cases a hysterectomy with bilateral salpingo oophorectomy was performed but not in order to treat the prolapse. Hysterectomy is not mandatory in the treatment of prolapses and there are no studies showing its effectiveness in the long-term success of suspensions. The laparoscopic or robotic repair techniques of a pelvic organ prolapse that is grade II or III must address reconstruction of the pericervical ring and its attachments to the cardinal-uterosacral ligament complexes, pubocervical fascia, and rectovaginal fascia by approaching the uterosacral ligaments together and reattaching to these ligaments.

Conclusions

Sacrocolpopexy is the "gold standard" repair for POP that are grade IV for those who desire to maintain their sexual function, and minimally-invasive approaches offer similar efficacy with fewer risks than open techniques. Laparoscopic or robotic uterosacral ligament culdoplasty and suspension associated or not with pubocervical fascia plication with reinforcing of the pericervical ring is a safe and effective native tissue option for grade II or III of defects.

<https://player.vimeo.com/video/831372038?autoplay=1>

**ES32-0530 -
Free Communication**

High uterosacral ligaments suspension for apical defects by Transvaginal Natural Orifice Transluminal Endoscopic Surgery (vNOTES): a pilot study on feasibility and short-term surgical outcome

Maria Lieta Interdonato¹, Francesca Massimello², Mariachiara Palucci¹, Paolo Mannella², Mario Giuseppe Meroni¹, Tommaso Simoncini²

¹*Ospedale Niguarda Ca' Granda, Gynecology and Obstetrics, Milano, Italy*

²*University of Pisa, Gynecology and Obstetrics, Pisa, Italy*

Background

The aim of this pilot study is to evaluate the feasibility, safety, and short-term surgical outcomes of high uterosacral ligaments suspension performed by Transvaginal Natural Orifice Transluminal Endoscopic Surgery (vNOTES) in two Italian institutions.

Methods

We perform a prospective multicentre analysis of 25 patients referring to our Urogynaecology department for symptomatic pelvic organ prolapse, enrolled between November 2021 to March 2023. All women underwent hysterectomy and adnexal surgery and high uterosacral ligaments suspension by vNOTES. We collected perioperative and postoperative data. During follow-up we collected data about pain and patient's satisfaction.

Results

Mean age was years 63.8 years. The mean BMI was 25.3 kg/m². The 36% of patients had apical POP only, 54% of patients had an anterior POP and 2 patients (9.1%) had elongation colli. Mean operative time was 95.8±21.4 min. In 12 (48%) patients we performed a concomitant anterior colporrhaphy. In one case (4%) we experience conversion to laparoscopy secondary to the presence of pelvic adhesions. we did not observe case of intra-operative complication, bladder, rectal or ureteral lesions. At 60-days follow-up, no patients had POPs recurrence.

Conclusions

vNOTES High uterosacral ligaments suspension can be considered a feasible and short-term effective alternative to vaginal USLS, in order to minimalized the risk of ureteral injuries.

**ES32-0539 -
Free Communication**

Recurrence repair of organ prolapse with Seratex L SlimSling Mesh

Pilar Alvarez Alvarez¹, M^a Luisa Loayza Escalante¹, Paula Salazar Lujan¹, Javier Liñayo Chouza¹, Paloma Lobo Abascal¹, Julio Alvarez Bernardi¹
¹Hospital Universitario Infanta Sofía, Obstetricia y Ginecología, San Sebastián de los Reyes. Madrid, Spain

Background

Laparoscopic colposacropexy is the treatment of choice for apical prolapse, with objective cure success rates of 70-100% and subjective rates of 79-98% with an average number of recurrent of 5.6%.

Surgical treatment using the Seratex L SlimSling Mesh system is presented that other technique of treatment of recurrence of pelvic organ prolapse after a first repair surgery using the laparoscopic sacrocolpopexy technique.

Methods

The clinical case of a recurrence of pelvic organ prolapse after a 1st surgical correction is presented. A 68-year-old woman attended post-surgical control after 6 months of surgery. The surgery performed was hysterectomy with bilateral adnexectomy and cervicosacrocolpopexy with laparoscopic mesh 1 St grade. By presenting a cystocele 2nd grade, hysterocele 3rd grade and rectocele 1 St grade.

Anamnesis: The patient describes that she has noted a genital lump and bleeding due to friction

Background: Asthma. High blood pressure. BMI 28,9. Surgery. Cystocele 2002. Menopause: 52 years old. G2 P2 macrosome 4200 gr

Examination:

- Genital atrophy
- Anterior compartment: cystocele 3º grade
- Apical compartment: cervix descends until introitus 3º grade

Supplementary tests:

Ultrasound: Para-cervical mesh cannot be identified

Diagnosis:

Recurrence of genital prolapse. Impress mesh detachment

Treatment proposed: Cervico-sacrocolpopexy with Seratex® L SlimSling® mesh by laparoscopy

Description of the technique

Cervical stump identification and dissection. (Visualization of the mesh from previous surgery)

Cervical stump exposure

Promontory opening

Adhesion release

Suture around of the cervical stump

Tunnelling

Suture to sacral promontory

Peritonization

Results

The Follow up was at 1-6-18 months.

After 18 months of the surgery with the combination of the mesh and suture the patient is still asymptomatic without sensation of vaginal lump

Examination:

Anterior compartment, a cystocele 1 St grade. Apical compartment with a cervix elevate. It doesn't observe signs of extrusion

Conclusions

The technique described is an effective and safe technique to correct POP after previous surgery. It is a basic minimally invasive surgery that it reduces huge surgical time and with short learning.

<https://player.vimeo.com/video/831566820?autoplay=1>

Real time haptic feedback laparoscopic grasper: validation of the performance in practice compared to the conventional grasper

Michael Vleugels MD PhD¹, Esther Spanjer²

¹*Hospital Clinica Benidorm, dept. obst and gynecology, Malden, The Netherlands*

²*DEMCON, advanced mechatronics, Enschede, The Netherlands*

Background

A grasper with real time haptic feedback (Optigrip) has been designed for detecting arterial pulsations and differences in tissue consistency. Haptic feedback is presented to the user through real-time kinaesthetic force feedback. The user experiences less or more force in the handle when grasping, meaning that the user directly feels the tissue stiffness or the pulsating artery. The handle is a front-hinged pistol grip to ensure that the index and middle finger receive the force feedback. The goal of this study was to investigate the subjective opinion of participants on different aspects of the Optigrip compared to conventional graspers .

Methods

Three simulation setups at the TechMED Simulation Centre (University of Twente, Enschede) were used 1) pulsation test of artificial arteries, 2) set up with different materials to feel the different resistances , 3) interventions in a Pulsating Organ Perfusion (POP) Simulator. After these three activities the participants filled out questionnaires (experience level; hand piece assessment; evaluation of functionality and performance). The answers were scaled on a five -point Likert scale (range: very poor to excellent 1-2-3-4-5) for the hand piece assessment and for the performance assessment. The average scores are presented in Table 1. Experienced surgeons also filled out a qualitative questionnaire on the potential effects for clinical application.

Results

25 subjects participated in this study: 13 laparoscopic surgeons , 4 operating room technicians and 9 medical interns. The 25 subjects rated the functionality of the grasper 4.2 out of 5 and the comfort 3.9 out of 5. All 25 participants rated their experience for the graspers regarding the feeling of tissue consistency, pulsations, applied pressure and muscular strain (table 1). On all items, the Optigrip scored higher than the conventional grasper, this was most clear for the assessment of arterial pulsations and feeling how much pressure they applied. 8 experienced surgeons were asked to give their opinion about possible clinical effects. They stated that the Optigrip has the potential to minimize tissue damage and reduce complications (score 4 and 3.8).

Conclusions

The participants judged that the haptic feedback of the Optigrip has an excellent performance which creates a better assessment of arterial pulsations and increases the feeling of how much pressure is applied to the tissue. The experienced surgeon subgroup felt that using the Optigrip could lead to less tissue damage and less complications.

Table 1. Average subjective opinion (N=25) on features for each grasper.

The tool allows me to:	Optigrip	Conventional grasper
feel the difference in tissue consistency	4,1	3,0
feel arterial pulse	3,9	1,2
feel how much pressure I apply	4,1	2,4
restrict the muscular strain in my hand	3,7	2,7

**ES32-0051 -
Free Communication**

Laparoscopic direct trocar technique for controlled drainage of large benign ovarian cysts

Tina Gao¹, Michael WH Suen¹

¹University of British Columbia, Obstetrics & Gynecology, Vancouver, Canada

Background

Adnexal masses are common in the general population. When they grow to large sizes, it can be challenging to drain and remove them laparoscopically, while minimizing cyst rupture and spillage. In this video, we demonstrate a laparoscopic direct trocar technique for controlled drainage of large benign ovarian cysts.

Methods

The first case is a 16-year-old G0 who presented with abdominal bloating, found to have a large 18.5x25 cm right adnexal mass. Her tumour markers were negative other than a minimally elevated Ca 19-9. She was suspected to have a benign cystic teratoma. The second case is 62-year-old G1A1 who presented with abdominal pain, with a large left 19x11x18 cm septate mass and normal tumour markers. Both patients were suitable candidates for our laparoscopic drainage approach.

The equipment required involves a 5mm inflatable balloon trocar, suction tubing, and a 5cc syringe. In both cases, direct entry with the trocar into the abdomen and cyst is performed, followed by rapid suction, removal of the sharp introducer, and inflation of the trocar balloon.

Results

Two successful cases of laparoscopic direct trocar drainage of large benign cysts are demonstrated. There was no spillage of cyst content, and the drainage was rapid and controlled. The trocar was able to penetrate different loculations. A mini laparotomy was avoided, and no additional hospital resources were required. The inflated trocar allowed for cyst manipulation, and was able to elevate the cyst away from the surgical field for the remaining salpingo-oophorectomies to be carried out. Both patients had uncomplicated intraoperative and postoperative courses. The final pathologies were benign.

Conclusions

This technique is a safe and feasible method of large benign cyst decompression and drainage without spillage. Compared to other techniques, the direct trocar approach is cost effective, quick, and prevents a laparotomy. We demonstrate two cases of oophorectomies, however a cystectomy after drainage can be performed if ovarian preservation is desired.

<https://player.vimeo.com/video/824243073?autoplay=1>

**ES32-0155 -
Free Communication**

Robotic bipolar cutting technique: a patient-friendly option in radical surgery

Masaaki Andou¹, Yoshifumi Ochi¹, Mari Sawada¹, Kiyoshi Kanno¹, Shintaro Sakate¹, Shiori Yanai¹
¹*Kurashiki Medical Center, Gynecology, Kurashiki-shi, Japan*

Background

This video presentation will show the technique of bipolar cutting in minimally invasive robotic gynaecologic surgery. The development of techniques will be described along with three cases where bipolar cutting has been applied.

Methods

We developed our minimally invasive surgical techniques as we were eager to find ways to make very radical surgery more patient-friendly. To meet this end, we initially developed techniques for laparoscopic surgery; 1732 pelvic lymphadenectomy cases which included 562 cases of radical hysterectomy/ radical trachelectomy, 914 cases of para-aortic lymphadenectomy, 197 cases of low anterior resection for rectal endometriosis, and 59 cases of ureteroneocystostomy for ureteral endometriosis or recurrent gynaecologic cancer. With the advent of robotic instrumentation, we sought an even more patient-friendly technique. This presentation will show the robotic techniques we have developed. The robotic bipolar cutting technique will be demonstrated through detailed explanation of the technique and case studies of three cases- a stage 1b1 cervical cancer case, a stage 1b endometrial cancer case, and a deep endometriosis case with rectal and ureteral involvement. Consent was gained to present and publish information on these cases on the condition of anonymity. In these cases, nerve sparing radical trachelectomy, extraperitoneal para-aortic and pelvic lymphadenectomy, and extensive deep endometriosis surgery including hysterectomy, low anterior resection and partial ureteral resection followed by reconstruction were performed robotically. The robotic bipolar cutting technique, originally pioneered by Dr Ichiro Uyama, uses pinpoint spark vaporization at the tip of Maryland forceps to perform small, step-wise dissection, minimizing the chance of thermal injury by minimizing thermal spread. The bipolar cutting technique enables very precise dissection, essential when working close to major organs and vessels in the narrow pelvic space.

Results

All cases could be operated safely without excessive blood loss or need for blood transfusion. All patients had a quick recovery. It can be expected that by utilizing the bipolar cutting technique, we can tissue damage was kept to a minimum.

Conclusions

The technique presented in this video allows for ultraprecise dissection with a minimization of the possibility of thermal injury. The robotic bipolar cutting technique is a patient-friendly approach to radical surgery.

<https://player.vimeo.com/video/826601583?autoplay=1>

Robotic docking time with the Hugo™ RAS system in gynaecologic surgery: a procedure independent learning curve using the Cumulative Summation Analysis (CUSUM)

Sara Mastrovito¹, Giovanni Panico¹, Giuseppe Campagna¹, Giorgia Monterossi¹, Francesco Fanfani¹, Giovanni Scambia¹

*¹Fondazione Universitaria Policlinico Agostino Gemelli IRCSS,
Department of Women- children and public health sciences, Rome, Italy*

Background

Robot-assisted surgery (RAS) has been proven to offer improvements in term of surgical learning curve and feasibility of minimally invasive surgery (MIS), but has often been criticized for its longer operative times compared to conventional laparoscopy. Additional times can be split into time required for system set-up, robotic arms docking and calibration of robotic instruments; secondly, surgeon's learning curve. One of the newest systems recently launched on the market is the Hugo™ RAS (MEDTRONIC Inc, United States). As some of the earliest adopters of the Hugo™ RAS system technology, we report our initial experience on robotic docking learning curve in gynaecologic surgery.

Methods

We present our data from a prospective observational study for the first 192 gynaecologic robotic cases performed with Hugo RAS at our institution. Robotic docking was always completed by the first bedside assistant, consisting of 6 senior residents. Data were analysed using SPSS. Means±SD, medians, ranges, and percentages were used as descriptive statistics. Univariate linear regression was performed of the docking time as a function of the number of performed cases. Statistical significance was considered at p value:0.01. The learning curve of docking time was assessed with cumulative summation analysis (CUSUM).

Results

Data on surgery type, robotic configurations, operative room timings and docking learning curve are summarized in Table 1. Mean docking time was 5,08 minutes (range 2-12), representing from 2 to 10% of the Operative Time. We individually analysed the learning curves of the 4 assistant surgeons who performed more than 25 procedures to allow the identification of individual trends. Univariate linear regression was performed showing a significant negative linear correlation between the decreasing operative time and the number of consecutive procedures for each resident (Resident 1: Pearson's r -0.535, p=0.002; Resident 2: Pearson's r -0.457, p<0.001; Resident 3: Pearson's r -0.525, p<0.001; Resident 4: (Pearson's r -0.711, p<0.001). The inflection point of the CUSUM curves, indicating the switch from the learning phase to the proficiency phase, is graphically represented at 13, 23,15 and 12 procedures respectively. Comparisons between mean times before and after the inflection points of the learning curves were statistically significant (p value < 0.01).

Conclusions

Our data indicates that robotic set-up and docking with the new Hugo™ RAS robotic surgical system can be performed time-effectively and that the specific robotic docking learning curve is comparable to preexisting data for other platforms. This preliminary insights into this recently released system may be worthwhile for other centers which may soon adopt this new technology and may need some relevant information on topics such as operative room times. Further studies are necessary to assess the different features of the Hugo™ RAS considering other technical and surgical aspects, to fully become familiar with this novel technology.

**ES32-0275 -
Free Communication**

Digital anatomic reconstruction and three-dimensional impression for an innovative technique in a case of cervico-vaginal agenesis

Antoni Pessarrodona Isern¹, Marta Hinarejos Companyó¹, Marcel Macarulla², Marta Martinez², Víctor Lozano Gimenez², Abdel Hakim Mustafa²

¹Hospital Universitari Mútua de Terrassa, Gynecology and Obstetrics, Terrassa, Spain

²Universitat Politècnica de Catalunya, Engineering, Terrassa, Spain

Background

We present you an innovative technique using digital anatomic reconstruction and three-dimensional (3D) impression for a complex case of cervico-vaginal agenesis in a 13-year-old patient, called the Lilium Project, developed by three expertise engineers from Polytechnical University of Barcelona, and four expert Gynaecologists from our centre.

We plan to design a technique that combines known surgical resources with anatomical reconstruction methods and 3D printing to create a specific anatomical vaginal mold for this patient.

Methods

The first objective was to create an anatomical model that fused the patient's malformation with a vagina reconstructed from a volunteer of the same height, using three-dimensional reconstruction of Materialise Mimics Viewer, based on CT scan and MRI of both patient and model. Both models were printed on the HP Jet Fusion 580 Colour 3D printer.

From the vaginal reconstruction, a 2-mm-thick silicone mold was designed using Autodesk Fusion360 and Rhinoceros 3D modelling software. Mold and mold core were manufactured using a fused filament fabrication-based 3D printer, using polylactic acid and polyvinyl alcohol. Once the molds were built, they were filled with vacuum degassed medical grade VI silicone, and crossed with a Foley catheter.

Several tests were performed on animal tissue to simulate the vagino-cervical anastomosis under ultrasound control, and to check that the prosthesis expanded correctly.

Results

Digital three-dimensional anatomical reconstruction and 3D impression allowed us to create a vaginal mold specifically designed for our patient, and to use a minimally invasive surgical strategy to accomplish anatomical collocation in a complex genital malformation.

Conclusions

We expect that this technique can help in the future other people with similar affectations.

<https://player.vimeo.com/video/857824107?autoplay=1>

**ES32-0392 -
Free Communication**

Eight step procedure for power morcellation of large uteri during vaginal natural orifice transluminal endoscopic surgery

Nathalie De Landtsheer¹, Amina Oussaifi¹, Deliar Yazdanian Masouleh¹, Sara Engels¹, Evy Gillet¹, Stavros Karampelas¹

¹CHU Brugmann, Gynecology, Brussels, Belgium

Background

To describe a surgical method for uterine morcellation in cases of hysterectomy for large uteri via vaginal natural orifice transluminal endoscopic surgery (vNOTES).

Methods

Presentation of a vNOTES hysterectomy with subsequent in-bag uterine morcellation using the power morcellator through the GelPOINT V-Path. The procedure is described in the following eight steps: Step 1. vNOTES hysterectomy performed using the GelPOINT V-Path; Step 2. Removal of the GelPOINT and installation of a 15mm trocar through the GelPOINT; Step 3. Installation of the GelPOINT and introduction of a large bag inside the abdominal cavity via the 15mm trocar and introduction of the uterus inside it; Step 4. Removal of the GelPOINT in order to place the bag around the retractor and securing of the bag by attaching the GelPOINT; Step 5. Partial in-bag uterine morcellation using a power morcellator via the 15mm trocar. The angled opening of the morcellator must be facing inwards in order to avoid contact of the circular knife with the bag; Step 6. After partial uterine morcellation, removal of the GelPOINT and extraction of the remaining uterus inside the bag via the vaginal opening; Step 7. Installation of the GelPOINT in order to verify haemostasis or any possible trauma to adjacent structures; Step 8. Removal of vNOTES material and vaginal suture.

Results

A video presenting eight steps for uterine morcellation of a large uterus in a bag using vNOTES.

Conclusions

Uterine morcellation in a bag via vNOTES is a promising technique for large uteri extraction. The presentation of this technique could broaden surgical indications for vNOTES hysterectomy as an alternative to laparoscopic morcellation or laparotomy.

<https://player.vimeo.com/video/827054523?autoplay=1>

**ES32-0472 -
Free Communication**

Intraoperative ultrasound- guided robotic excision of sacral plexus endometriosis nodule: a case-report

Laura Puma¹, Riley J. Young², Javier Salgado Pogacnik³, Kimberly A. Kho²

¹Ospedale Pietro Cosma, Gynecology and Obstetric Department, Camposampiero- Padova, Italy

²UT Southwestern Medical Center, Gynecologic Surgery, Dallas, USA

³UT Southwestern Medical Center, Colorectal Surgery, Dallas, USA

Background

Deep infiltrating endometriosis (DIE) surgery affecting sacral plexus is a challenging procedure. We want to show how robotic intraoperative ultrasound can be used to precisely localize the nodule and guide surgical dissection.

Methods

In this case report a patient underwent robotic excision of a DIE nodule of the sacral plexus. The procedure took place in a Tertiary care endometriosis unit. A Robotic Ultrasound assisted scanning probe was used to identify and isolate the nodule.

Results

A preoperative MRI showed a retroperitoneal mass compatible with endometriosis with the involvement of the sacral roots and edema of homolateral sciatic nerve. With a Robotic approach, retroperitoneum was dissected starting with the opening of pre-sacral space, development of avascular spaces, and identification and preservation of hypogastric nerves. Thus, nodule's borders were intraoperatively visualized with a Robotic Ultrasound integrated probe. The images showed that the mass was above the S2-S3 sacral roots without involvement of the lumbosacral trunk. With the aim of this useful tool, we limited the dissection at the level of the sacral roots and completely removed the nodule.

Conclusions

Minimally invasive excision of sacral plexus endometriosis requires advanced surgical retroperitoneal dissection. Intraoperative Robotic ultrasound may represent a novel tool in the surgeon's hands to tailor the surgical steps without compromising the radicality of the excision.

The patient signed a written consent for the study.

<https://player.vimeo.com/video/831204732?autoplay=1>

**ES32-0506 -
Free Communication**

Post laparoscopy pain reduction project II (POLYPREP 2): intraperitoneal normal saline instillation (INSI) vs intraperitoneal ringer's lactate (INRL) - a randomised controlled trial

Aizura Syafinaz Ahmad Adlan¹

¹University of Malaya, Obstetrics & Gynaecology, Kuala Lumpur, Malaysia

Background

In POLYPREP 1, we studied the effects of intraperitoneal normal saline (NS) instillation of 15 mL/kg body weight on postoperative pain after a gynaecological laparoscopic procedure (This paper was presented in ESGE 2022). Normal saline instillation (INSI) was beneficial in removing post laparoscopic CO₂ retention; therefore improving post laparoscopic pain.

There are no studies addressing the usage of other fluids. Crystalloid fluids like normal saline (NS) and Ringer's lactate (RL) solution, are both isotonic solutions with balanced electrolyte composition. NS has an average pH of 5.0 and an osmolarity of 308 mOsm/L, while RL has an average pH of 6.5, an a hypo-osmolarity of 272 mOsm/L. RL appears to be more physiologically compatible than NS.

Our objective in the Post Laparoscopy Pain Reduction Project II (POLYPREP 2) was to evaluate the post-laparoscopic pain relieve effects in the shoulder and abdomen by comparing the usage of INSI and INRL infusion .

Methods

Design: Randomised controlled trial.

Setting: University Hospital in Kuala Lumpur, Malaysia.

Participants: Patients aged 18–55 years, with American Society of Anaesthesiologists (ASA) classification I–II, scheduled for an elective gynaecological laparoscopic procedure for a benign cause.

Intervention: The patients were randomly allocated to two groups. 80 women who underwent benign laparoscopic gynaecological surgery were assigned to two groups (40 patients in each group). Group A received intraperitoneal normal saline (INSI) infusion and Group B received intraperitoneal Ringer's lactate (INRL).

Main outcome measure:

The intensity and incidence of post laparoscopic pain in shoulder, upper abdomen and lower abdominal area were measured at 24, 48, 72 hours after surgery; using a 0-10 numerical rating scales (NRS) : 0 = no pain and 10 = worst possible pain.

Occurrence of nausea, vomiting, abdominal distension; time to pass first flatus after surgery and additional analgesia required post-operative were recorded.

Results

A statistically significant reduction was seen in incidence of lower abdominal pain within 48 hours reported n=29 (72.5%) in INRL group as compared to n=36(90%) in INSI group with p = 0.045. The incidence of shoulder pain and upper abdominal pain over the postoperative three days among both intervention groups have no significant difference. There were no significant differences in the incidence of lower abdomen pain for postoperative 24 hours and 72 hours between the two observed group.

Conclusions

Intraperitoneal Ringer's lactate infusion did not showed any adverse events or complications to patients. It is safe and physiologically compatible to the human body. INRL can be considered as an alternative solution that provides pain relief of shoulder, upper abdomen and lower abdomen in the post laparoscopic period other than INSI.

With mouse studies suggesting that usage of INSI may lead to increased adhesion formations in the abdomen, INRL may be a better alternative. More studies looking into this would be required.

**The surgical and subjective outcomes of high uterosacral ligament suspension with vNOTES technique :
a median follow-up of 17 months**

Murat Yassa¹, Pinar Birol İlter², Cihan Kaya³

¹Bahçeşehir Medical Faculty, Medicana Atakoy Hospital, Clinic of Obstetrics and Gynecology, İstanbul, Turkey

*²2. University of Health Sciences Turkey Kartal Dr. Lutfi Kırdar Research and Training Hospital,
Department of Obstetrics and Gynecology-, İstanbul, Turkey*

*³Acibadem Bakirkoy Hospital- Acibadem Mehmet Ali Aydınlar University,
Department of Obstetrics and Gynecology-, İstanbul, Turkey*

Background

Vaginally Assisted Natural Orifice Transluminal Endoscopic Surgery (vNOTES) is one of the most innovative surgical techniques which is currently under the spotlight. vNOTES is improving its usage areas day by day towards gynaecology, pelvic floor and prolapse surgeries including hysterectomy, adnexial procedures, sacrocolpopexy, meshless anterior repair, posterior rectus fascia prolapse repair surgeries and high uterosacral ligament suspension (HUSLS)

Methods

This multi-centred prospective study investigated the postoperative objective and subjective outcomes of vNOTES high uterosacral ligament suspension (vNOTES-HUSLS) technique.

Results

A total of 102 patients with various benign gynaecologic indications underwent vNOTES-HUSLS following vNOTES hysterectomy between 1 January 2021 and 1 January 2022. All procedures were performed by or under the direct supervision of surgeons (M.Y. or C.K.) with an adequate experience in vNOTES. The median follow-up was 17.07 months with range of 12–27.5 months (IQR=4). Duration of total surgery was found 76.64±29.13 minutes.

vNOTES-HUSLS was performed in 56 (54.9%) patients due to apical prolapse. The prolapse level in apical, anterior and posterior compartments were found to be improved ($p<0.001$). In addition, apical prolapse was not detected in the follow-up of patients who performing prophylactic vNOTES-HUSLP after hysterectomy performed without the purpose of prolapse. The satisfaction rate was 98% at 1st year of follow-up in the all patients.

Intraoperative complications were detected in 3 (2.9%) patients, including bladder injury in 2 patients and haemorrhage from the colpotomy line in 1 patient. The bladder injury was repaired intraoperatively without a long-term complications. There was not any conversion to laparoscopy or laparotomy. Recurrence in apical prolapse was not detected in any patient. Colporrhaphy anterior was performed concomitantly in 2 (1.9%) patients due to anterior compartment prolapse and denovo urge incontinence was detected in 2 (1.9%) patients during the postoperative follow-up period. Sexual pain/dyscomfort was found to be improved at 1st year(FSFI pain subdomain score, $p<0.001$).

Conclusions

vNOTES has the potential to provide faster recovery and higher patient satisfaction. In recent years, some scholars have reported the advantages of vNOTES-HUSLS, which include no incisional pain and a better cosmetic outcome, as well as direct visualization of key structures, such as the ureters and rectum. Hence, vNOTES-HUSLS is associated with a reduced risk of ureteral obstruction, less incidence of intraoperative complications. Long-term results of vNOTES-HUSLS are unknown, but short-term results did not detect serious complications and prolapse recurrences.

vNOTES-HUSLS resulted in marked improvement in both anatomical prolapse without cases of conversion or severe complications. In addition, vNOTES-HUSLP is safely performed to support the vaginal apex prophylactically after a hysterectomy.

During the 'minimal mesh' era, vNOTES-HUSLS may be the first choice in either native tissue repair of apical prolapse for whom uterus needs to be removed, or as a prophylaxis technique following vaginal or vNOTES hysterectomy.

**ES32-0655 -
Free Communication**

Combined robotic-assisted laparoscopy with simultaneous hysteroscopy for isthmocele resection

*Anna Brox Martín¹, Laura Mañalich Barrachina¹, Eva Vila Escudé¹, Sonia Monreal Clua¹, M^a
Elena Suárez Salvador¹, Antonio Gil Moreno²*

¹Hospital Vall d'Hebron, Gynecological Endoscopy, Barcelona, Spain

²Hospital Vall d'Hebron, Gynecology Oncology, Barcelona, Spain

Background

This video aims to provide a step-by-step demonstration of the repair of an isthmocele using robotic-assisted laparoscopy with a simultaneous hysteroscopic view.

Methods

Video demonstration.

Results

A 36 year-old woman with secondary infertility following a caesarean section two years prior, without any other symptoms, was diagnosed with an isthmocele through vaginal ultrasound, diagnostic hysteroscopy and magnetic resonance imaging, revealing a residual myometrium thickness of 3mm. The patient was informed about the different alternatives, and their risks and benefits, of isthmocele reparation (hysteroscopic vs robotic assisted laparoscopic resection). Considering the thinness of the scar, the abdominal route with robotic excision was chosen as the preferred approach.

Surgery followed the next key steps: Adhesiolysis and dissection of the visceral peritoneal layer over the isthmus and cervix area, to develop the vesicouterine space, were performed using monopolar curved scissors, fenestrated bipolar forceps, and prograsp forceps. A simultaneous diagnostic hysteroscopy was carried out and, thanks to Tilepro adjustment of Da Vinci Xi system, the isthmocele defect was located with a good precision. The edges were marked to facilitate the robotic resection that was completed with monopolar cut and cold scissors minimizing the thermal damage of remaining myometrium, that was closed with two layers of V-Loc 2.0 barbed suture. A second diagnostic hysteroscopy confirmed the successful repair. Finally, the visceral peritoneal layer over the isthmus was stitched using 2.0 Vicryl sutures.

The surgery proceeded without any complications and she was discharged the following day. Six months after the surgery, a second-look diagnostic hysteroscopy confirmed the absence of recurrence. Two months later, the patient achieved gestation through in vitro fertilization and is currently pregnant.

Conclusions

In this case, robotic surgery offers, thanks to Tilepro adjustment, the possibility of obtaining a hysteroscopic simultaneous view, which could be an advantage to ensure a complete resection of the uterine defect.

<https://player.vimeo.com/video/832614748?autoplay=1>

**ES32-0033 -
Free Communication**

Anatomic nerve sparing endometriosis excision of pelvic sidewall and sacral nerve roots

Jon Einarsson¹

*¹Brigham and Women's Hospital - Harvard Medical School,
Obstetrics and Gynecology - Division of Minimally Invasive Gyn Surgery, Boston, USA*

Background

Endometriosis extending to the extreme lateral spaces of the pelvic sidewall as well as the sacral nerve roots present a challenge to the gynaecologic surgeon for safe and complete excision. The objective of this video is to demonstrate safe excision of an endometriosis nodule extending to the pelvic sidewall in a 41 year old patient with a 15 year history of right sided buttock pain and S2 and S3 radiculopathy.

Methods

The surgical video demonstrates an anatomic approach to safe excision of the nodule by identifying all pertinent surrounding structures. Tips and tricks for safe dissection and recognition of anatomy are given.

Results

Surgery was completed in 90 minutes with minimal blood loss. This included excision of several other endometriosis lesions in the pelvis. No complications occurred and the patient had immediate resolution of her buttock pain.

Conclusions

Excision of deeply infiltrative endometriosis requires intimate knowledge of pelvic anatomy for safe removal of large nodules. If at all possible, nerve sparing surgery is encouraged.

<https://player.vimeo.com/video/819231244?autoplay=1>

Laparoscopic nerve-sparing radical parametrectomy for deep lateral parametrial endometriosis

Kiyoshi Kanno¹, Shiori Yanai¹, Masaaki Andou¹

¹*Kurashiki Medical Center, Gynecology, Kurashiki, Japan*

Background

Lateral parametrial endometriosis (LPE) is defined as deep endometriosis which involves lateral compartment structures in the pelvis such as parametrium, ureter, internal iliac vessels, and sometimes pelvic autonomic and somatic nerves. Although LPE is not overly rare, isolation of the autonomic nerves from LPE cannot always be guaranteed. Thus, in cases where endometriosis lesions are embedded in the deep parametrium, nerve-sparing techniques are no longer considered feasible, except in cases with unilateral involvement. However, even one-sided radical parametrectomy may actually lead to pelvic organ dysfunctions. Therefore, the objective of this video is to demonstrate the anatomical and technical highlights of nerve-sparing radical parametrectomy for deep LPE(dLPE).

Methods

A 41-year-old woman, para 2, presented with five-year history of severe chronic pelvic and gluteal pain, all of which were resistant to pharmacotherapy. MRI revealed right ovarian endometrioma with LPE reaching deep lateral pelvic wall. We therefore planned laparoscopic nerve-sparing eradication of dLPE and decompression of somatic nerves with right salpingo-oophorectomy. The procedure was performed using 8 steps, as follows: Step 1, adhesiolysis and adnexal surgery; Step 2, complete ureterolysis; Step 3, identification and dissection of hypogastric nerve and inferior hypogastric plexus with development of pararectal space; Step 4, dissection of internal iliac vessels; Step 5, identification and dissection of sacral roots S2-S4 and pelvic splanchnic nerves; Step 6, complete removal of LPE; Step 7, haemostasis and assessment of tissue perfusion using indocyanine green (ICG); and Step 8, application of barrier agents to prevent adhesion.

Results

We achieved total removal of dLPE with complete sparing of pelvic autonomic nerves, decompression of somatic nerves and preservation of all branches of the internal iliac vessels. Tissue perfusion using ICG was assessed as good. The operative time was 128min and estimated blood loss was 50ml. The patient developed no perioperative complications, including postoperative bladder, rectal or sexual dysfunctions. Pain was completely resolved after surgery (VAS100 → 0). Dissection of the pelvic nerves before LPE excision revealed the relationship between lesions and pelvic innervation, thereby reducing the risk of nerve injury, whether by minimizing the risk of neuropraxia or by allowing as many nerve fibers as possible to be spared in cases with some invasion of the pelvic nerve system. We considered even partial preservation of these nerves as beneficial to the resumption of pelvic organ functions. In addition, step-by-step technique help to perform each part of the surgery in a logical sequence, making the procedure easier and safer to complete.

Conclusions

Laparoscopic nerve-sparing radical parametrectomy is technically safe and feasible for selected patients with LPE. Suitably tailored treatment should be provided for each individual, based on both the latest scientific evidence and life planning for the patient.

<https://player.vimeo.com/video/822281119?autoplay=1>

ES32-0116 –

Free Communication

Hysterectomy for deep infiltrating endometriosis: standardization in 10 steps

Margherita Renso¹, Pierre Collinet², Geraldine Giraudet²

¹University Hospital of Verona, Obstetrics and Gynecology, Verona, Italy

²Hopital privé Le Bois, Gynecological surgery, Lille, France

Background

Hysterectomy for deep infiltrating endometriosis is correlated to more complications than hysterectomy for others gynaecological benign diseases [1,2]. A problem is the lack of standardization. We would like to demonstrate a ten surgical steps approach and technical highlights used to standardize hysterectomy for deep infiltrating endometriosis (DIE).

Methods

Stepwise demonstration of the technique with video.

A 39-year-old patient who underwent hysterectomy and bilateral adnexectomy for adenomyosis, adnexal endometriosis and DIE resistant to medical therapy. We describe the following 10 steps to standardize the procedure: step 1-ureterolysis, step 2-adnexal surgery, step 3-transection of round ligament and dissection of broad ligament, step 4-dissection of the vesicovaginal space, step 5-dissection of medial and lateral pararectal spaces using the nerve sparing technique [3], step 6-identification and ligation of the uterine artery at its origin, step 7-dissection of the rectovaginal space, step 8-colpotomy, step 9-vaginal suture, step 10-resection of the rectosigmoid endometriosis nodule if necessary.

Results

The step-by-step technique should help surgeons, especially young surgeons, perform each part of the surgery in a logical sequence and that could reduce the risk of intraoperative complications and make the procedure safer.

Conclusions

References:

- 1) Uccella S et al. Impact of endometriosis on surgical outcomes and complications of total laparoscopic hysterectomy. Arch Gynecol Obstet. 2016 Oct;294(4):771-8.
- 2) Brunet M et al. Peri- and postoperative outcomes in patients with endometriosis undergoing hysterectomy. Eur J Obstet Gynecol Reprod Biol. 2022 May;272:104-109.
- 3) Ceccaroni M, Clarizia R, Bruni F, D'Urso E, Gagliardi ML, Roviglione G, Minelli L, Ruffo G. Nerve-sparing laparoscopic eradication of deep endometriosis with segmental rectal and parametrial resection: the Negrar method. A single-center, prospective, clinical trial. Surg Endosc. 2012 Jul;26(7):2029-45.

<https://player.vimeo.com/video/826236647?autoplay=1>

**ES32-0373 -
Free Communication**

Development of the medial and lateral pararectal spaces for excision of endometriosis

Abigail Barger¹, Michelle Bennett¹, Jessie Jones¹, Laura Haworth¹, Joseph Hudgens¹
¹Eastern Virginia Medical School, Advanced Gynecologic Surgery, Norfolk, USA

Background

To review medial (Okabayashi's) and lateral (Latzko's) pararectal space anatomy, and demonstrate reproducible dissection of the pararectal space for a nerve sparing approach for excision of endometriosis

Methods

We show a step-by-step surgical video demonstrating the dissection of the medial and lateral pararectal spaces for excision of deep infiltrating endometriosis with nerve sparing technique. The dissection starts with the development of Latzko's space, followed by the mobilization and lateralization of the ureter to develop Okabayashi's space. Then, we show the identification and lateralization of the inferior hypogastric nerve and nerve plexus. We also review the cardinal movements of dissection as key surgical techniques.

Results

Dissection of the pararectal spaces assists with nerve preservation for excision of posterior cul-de-sac endometriosis.

Conclusions

We present a nerve sparing approach to develop the medial and lateral pararectal spaces for excision of rectovaginal endometriosis. Pneumodissection aids in exposure of the microanatomical avascular spaces for access to retroperitoneal structures.

<https://player.vimeo.com/video/826756346?autoplay=1>

**ES32-0433 -
Free Communication**

Laparoscopic removal of a pelvic mass in a patient with congenital cervicovaginal malformation after subtotal hysterectomy

Keqin Hua¹, Yan Ding¹, Junjun Qiu¹

¹Obstetrics and Gynecology Hospital of Fudan University, Department of Gynecology, Shanghai, China

Background

The aim of this video article is to demonstrate a surgical procedure in which a cervical region mass was resected in a patient with congenital cervicovaginal malformation after subtotal hysterectomy

Methods

A 29-year-old patient complaint of abdominal pain for two months. She had a history of two surgeries, with vaginoplasty at the age of 18 when diagnosed as U5bC0V0, and laparoscopic subtotal hysterectomy and bilateral salpingectomy at the age of 27 when diagnosed as U5aC0V0 due to cyclic abdominal pain for 8 months. A solid mass of 4*2.7*1.9 cm was identified at the cervical region on ultrasound and MRI. Serum CA125 was higher. The patient underwent laparoscopy to remove the pelvic mass. There were extremely dense adhesions between bowel, ovaries, pelvic and the anterior abdominal wall. First, the dense adhesions were dissected. The lateral peritoneum was opened to identify bilateral ureters and expose them. Under the ultrasonic guidance, the previously pelvic mass behind the bladder was identified. The mass was separated from surrounding tissue and a laparoscopic removal of the mass was performed. The main feature of this operation was to check the relationship of tumor with adjacent structures, including ureters, bowel and vascular structures at every step to prevent unwanted injuries. After resection of the mass, the vaginal apex was soft, and ultrasound was further confirmed that there were no residual structures.

Results

The operation time was 100 minutes. There were no complications. The postoperative course was uneventful and the patient was discharged on the third postoperative day. Histopathological examination showed the mass was endometriosis. Postoperative oral contraceptives were given to prevent recurrence.

Conclusions

Patients with congenital reproductive tract malformations may have endometriosis even after hysterectomy. Laparoscopic removal is a safe treatment.

<https://player.vimeo.com/video/826856233?autoplay=1>

Thoracic endometriosis syndrome: a report of 6 cases with different clinical manifestations and managements

Marco Puga¹, Cesar Sandoval¹, Raul Berrios², Mariane von Muhlenbrock¹, Ignacio Miranda¹, [Milenko Pavlovic](#)¹

¹Facultad de Medicina Clinica Alemana Universidad del Desarrollo, Obstetrics and Gynecology, Santiago, Chile

²Facultad de Medicina Clinica Alemana Universidad del Desarrollo, Surgery, Santiago, Chile

Background

Thoracic endometriosis syndrome (TES) is a rare entity caused by thoracic implantation of endometrial tissue, manifesting as catamenial pneumothorax and hemothorax, non-catamenial endometriosis-related pneumothorax, catamenial haemoptysis, lung nodules and catamenial chest or shoulder pain. Although TES is the most frequent form of extraabdominopelvic endometriosis, literature is scarce and there is a lack of evidence based recommendations.

Methods

We present 6 cases of TES with different clinical manifestations such as pneumothorax, haemoptysis, shoulder pain and palpable 8 cm thoracic nodule and their resolution. We also perform a literature review of TES diagnosis and management. PubMed, Web of Science, and EMBASE were searched for publications pertaining to TES and a summary of diagnosis and managements recommendations was made.

Results

Exclusive hormonal management with full symptoms remission was performed in 2 patients with haemoptysis, one of them secondary to lung endometriosis nodule and the other to pleural and diaphragmatic endometriosis. Surgery approach was preferred in 2 patients with 3 cm diaphragmatic endometriosis nodules that presents right shoulder and right hypochondrium pain refractory to hormonal treatment. One patient with catamenial right pneumothorax was surgical intervened 3 times due to recurrence, 2 times by videothoracoscopy and 1 time with thoracic drainage. One patient was intervened by thoracotomy due to a massive endometriotic nodule of 8 cm that compromised distal breast bone, rib cartilage, diaphragm, pleura and pericardium. Histological diagnose of endometriosis was confirmed in all patients.

Conclusions

TES is a poorly recognized entity responsible of incapacitating symptoms for some patients. Symptoms of TES are nonspecific, so a high degree of clinical suspicion is warranted. A multidisciplinary setting that includes gynaecologist and thoracic surgeons is needed to diagnose and treat this patients. Medical management represents the first-line treatment approach and surgery often is reserved in cases of hormonal treatment failure or contraindication. A combined surgical approach with videothoracoscopy and laparoscopy allows to manage the thoracic, abdominal diaphragmatic and pelvic endometriosis. In cases with massive thoracic compromise, a thoracotomy approach may be performed. Postoperative hormonal treatment is advisable in all patients. Nevertheless, type, dosage and duration of treatment and interval to pregnancy are still controversial. Relevance of clinical judgement and expertise centre management cannot be overemphasized.

**ES32-0430 -
Free Communication**

Robotic-assisted versus conventional laparoscopic approach in patients with large rectal endometriotic nodule: the evaluation of safety and complications

Alexander Volodarsky-Pereh¹, Benjamin Merlot¹, Quentin Denost¹, Thomas Dennis¹, Isabella Chanavaz-Lacheray¹, Horace Roman¹

¹*Tivoli-Ducos Clinic, Franco-European Multidisciplinary Institute for Endometriosis, Bordeaux, France*

Background

Surgical treatment of rectal endometriosis is challenging, particularly in cases of large rectal nodules. Although a laparoscopic approach is widely applied as a mainstay of surgical treatment of endometriosis, robotic-assisted surgery has gained popularity in the last decade. The robotic assistance provides a high-definition three-dimensional stereoscopic view, seven degrees of instrument motion freedom, and complete tremor filtering. The safety profile of this approach in the surgical treatment of large rectal endometriosis was not adequately evaluated.

This study aimed to compare postoperative complications in patients undergoing the excision of rectal endometriotic nodules over 3 cm by robotic-assisted versus conventional laparoscopic approach.

Methods

We conducted a retrospective cohort study evaluating the prospectively collected data. Women managed by robotic-assisted surgery from January 2021 to January 2023 were compared to those managed by conventional laparoscopy from September 2018 to December 2020. All the surgeries were performed in one endometriosis reference institute. The main interventions included rectal shaving, disc excision or colorectal resection, and the surgical treatment of additional concomitant endometriotic lesions. To evaluate factors significantly associated with the risk of anastomosis leakage or fistula and bladder atony, we conducted a multivariate logistic regression model. The study protocol was approved by the Institutional review board.

Results

A total of 548 patients with rectal endometriotic nodules over 3 cm in diameter (#ENZIAN C3) were included in the final analysis. The demography and clinical characteristics of women managed by a robotic-assisted (n=97) approach were similar to those of patients who underwent conventional laparoscopy (n=451). The incidence of significant vaginal [30 (30.9%) vs. 97 (21.5%), p=.04] and uterosacral ligaments infiltration [35 (23.8%) vs. 62 (15.5%), p=.02] was higher in the robotic-assisted approach compared to the laparoscopy group. The multivariate logistic regression demonstrated that the surgical approach (robotic-assisted versus laparoscopic) was not associated with the rate of anastomosis leakage or fistula (adjusted odd ratio (aOR) 1.2, 95% confidence interval (CI) 0.3-4.0) and bladder dysfunction (aOR 0.5, 95%CI 0.1-1.8). The rectal nodule located lower than 6 cm from the anal verge was significantly associated with anastomosis leakage (aOR 4.1, 95%CI 1.4-10.8) and bladder atony (aOR 4.3, 95%CI 1.5-12.3). Anastomosis leakage was also associated with smoking (aOR 3.2, 95%CI 1.4-7.4), significant vaginal infiltration (aOR 2.7, 95%CI 1.2-6.7), and excision of nodules involving sacral roots (aOR 5.6, 95%CI 1.7-15.5).

Conclusions

The robotic-assisted approach was not associated with the increased risk of main postoperative complications compared to conventional laparoscopy for the treatment of large rectal endometriotic nodules. Due to the technical advantages provided by robotic assistance, this approach may be considered in the surgical treatment of complex endometriosis.

A consensus for research in FEMTECH and endometriosis

Afshin Fazel¹, Philippe Koninckx², Gaby Moawad³, Jean Philippe Estrade⁴, Arnaud Wattiez⁵

¹HOPITAL LARIBOSIERE, GYNECOLOGY AND OBSTETRICS, PARIS, France

²Latifa Hospital Dubai- UAE, Surgical Gynecological Department, Dubai, United Arab Emirates

³George Washington School of Medicine, Center for Endometriosis and Advanced Pelvic Surgery, Washington DC, USA

⁴Groupe ELSAN, Obstetrics and Gynecology, Aix en Provence, France

⁵The Latifa Hospital, Surgical Gynecological Department, Dubai, United Arab Emirates

Background

Management of research should be based on the best available evidence. Evidence-based medicine (EBM) is the clinical interpretation of these data by a group of experts. Unfortunately, traditional statistical inference can refute but cannot confirm a hypothesis and in EBM, clinical experience is considered a personal opinion. It seemed important to reach a consensus on how to conduct a clinical research when dealing with innovations and big data in the specific field of endometriosis, a multifaceted, multiethnic disease concerning 190 million women worldwide.

Methods

A consensus conference was held gathering several working subgroups based on a proof of concept to document the clinical experience by considering each diagnosis and treatment as an experiment with an outcome, which is used to update subsequent management. Experience and knowledge-based questions were answered on a 0 to 10 visual analogue scale (VAS) by research and surgery-oriented clinicians with an individual experience of over 50 surgeries for endometriosis or active scientific research on endometriosis. We present the results of the subgroup working towards a consensus on the minimal requirements to conduct a scientific and clinical research on endometriosis dealing with big data.

Results

The answers reflect the collective clinical experience of managing some 10.000 women with endometriosis. Experience-based management was similar for all participants as judged by >75% of answers rated $\geq 8/10$ VAS. Knowledge-based management was variable, reflecting debated issues and differences between experts and non-experts. Results did not have any conflict with EBM and constitute a Bayesian prior, to be confirmed, refuted or updated by further observations permitting to calculate a probability of truth. When dealing with Big Data the necessity for Valuable data (exclusive endometriosis with no bias with other diseases), Veracity of the data (proof of endometriosis), Volume of data (minimal number of patients per group of trial), Variety of Data (multicentric, multiethnic data collection), and Velocity of collection of those data reached a large consensus

Conclusions

Like in other fields managing Big Data on endometriosis needs to fulfil the minimal requirements of Value, Volume, Veracity, Variability, and Velocity of those data, to avoid bias of interpretation and hastily conclusions of poorly designed research on endometriosis

**ES32-0481 -
Free Communication**

Evaluation of heavy menstrual bleeding by self-perception and pictorial methods and correlation to uterine myometrial pathology

Mario Palumbo¹, Sabrina Reppuccia¹, Giuseppe Gabriele Iorio¹, Federica Iacobini², Giorgia Soreca², Caterina Exacoustos²

¹University of Naples Federico II, Department of Public Health, Naples, Italy

²University of Rome Tor Vergata, Department of Surgical Sciences- Obstetrics and Gynecology Unit, Rome, Italy

Background

The aim of the study was to correlate the amount of menstrual blood loss (MBL), evaluated by pictograms or subjective self-perception, with uterine pathologies, diagnosed by transvaginal sonography (TVS), in order to assess if the only subjective evaluation is adequate to define HMB in association uterine myometrial disorders.

Methods

In this observational prospective study, we include 25 patients for every 5-year range from 16 to 55 years for a total of 200 premenopausal women, not on hormonal therapy, who performed TVS scan in the Gynaecological Ultrasound Unit of the University Hospital Policlinico Tor Vergata and underwent an evaluation of MBL before the scan by different methods: SELF-perception of MBL (normal or heavy); PBAC (Pictorial blood loss assessment charts, Higham et al. 1990); Magnay MP (Magnay menstrual pictogram, 2014).

Menstrual bleeding was defined heavy if PBAC score was ≥ 150 and MP is ≥ 80 ml.

All patients first reported their SELF-perception, after completed the two questionnaires and then had the TVS scan.

We also evaluated whether awareness of uterine myometrial diseases (fibrosis or adenomyosis) affected the perception of women's menstruation.

Results

Of all patients who referred HMB, it was confirmed in 90% by MP and in 80% by PBAC; whereas in 5% and 15% respectively patients reached a normal score at both tests and overestimated the MBL. Of these who overestimated their condition 98% showed at TVS some myometrial pathology: 37% of these patients had intramural or submucosal fibroids, 43% showed adenomyosis and 20% had both diseases.

In patients who referred a normal MBL, it was confirmed in 65% at MP and in 85% at PBAC.

A high proportion of patient underestimate their MBL when it was referred as normal.

These patients who underestimate were often unaware of their uterine pathology before the TVS scan and the MBL evaluation.

Conclusions

Our results show that self-reported HMB are quite in accordance with pictorial system in 95% of cases by MP and in 80% of cases by PBAC. SELF-perception of normal MBL underestimates the intensity of the bleeding in 15% of cases by PBAC and 35% of cases by MP.

MP seem to have a better correlation to self-evaluation of HMB but is more difficult to compile by the patients.

In addition, women with unknown uterine diseases, have a lower self-perception of their MBL.

Robotic-assisted vs traditional laparoscopic surgery for deep endometriosis of the sacral plexus and sciatic nerve

Francesca Massimello¹, Tommaso Simoncini¹, Thomas Dennis², Benjamin Merlot², Horace Roman²

¹University of Pisa, Gynecology and Obstetrics, Pisa, Italy

²Institut Franco-Européen Multidisciplinaire d'Endométriose, Clinique Tivoli-Ducos, Bordeaux, France

Background

Deep infiltrating endometriosis involving sciatic nerve and sacral roots is a rare occurrence, producing severe symptoms as sciatic pain, perineal pain and refractory urinary, anorectal and sexual dysfunction. The aim of the study is to compare robotic-assisted vs conventional laparoscopic surgery for intraoperative and postoperative outcomes among patients undergoing eradication of deep infiltrating endometriosis involving sciatic nerve and sacral roots.

Methods

We perform a retrospective analysis of 90 patients referred to our department for deep infiltrating endometriosis involving sacral roots and/or sciatic nerve between October 2018 to May 2023. Patients underwent to surgery for endometriosis eradication by conventional laparoscopic (n=64) until 2021 and subsequently by robotic-assisted surgery (n=26). We collected perioperative and postoperative data. During follow-up we collected data about pain, urinary, anorectal and sexual function.

Results

In laparoscopy group deep infiltrating endometriosis involved sacral roots in 48 women (75%) and sciatic nerve in 18 cases (25%), meanwhile in robotic-assisted surgery group sacral root were involved in 20 patients (76.9%) and sciatic nerve in 6 cases (23.1%). Nerve dissection were performed in 51 patients (79.6%) in the laparoscopic group and in 19 patients (73.1%) in the robotic-assisted surgery group, meanwhile nerve shaving were performed in respectively 11 patients (17.2%) and in 7 patients (26.9%). Between patients treated by laparoscopy, two (3.1%) underwent to intra-nerve dissection. Mean operative time for laparoscopic and robotic-assisted surgery was respectively 164.5±93.3 min and 204.0±101.6 min (p= ns). In no case we experience conversion to other surgical technique. The intraoperative complication rate was 4.7% in laparoscopic group. No intraoperative complication was observed for robotic surgery (p= ns). We did not observe statistically significant difference post-operative complication rate between laparoscopy and robotic-assisted surgery (37.5% vs 30.8%, p=ns).

Conclusions

Robotic assisted surgery can be considered a feasible and effective alternative to laparoscopy in the treatment of deep infiltrating endometriosis involving sciatic nerve and sacral root.

**ES32-0493 -
Free Communication**

The malignant transformation of endometriosis: is there a left lateral shift?

Josh McMullan¹, Glenn McCluggage¹, David Hunter¹, Elaine Craig¹, Laura Feeney², Michael Graham¹

¹Belfast City Hospital, Gynaecology, Belfast, United Kingdom

²Queen's University Belfast, Patrick G Johnston Centre for Cancer Research PGJCCR, Belfast, United Kingdom

Background

Globally, endometriosis affects approximately 10% of women. Evidence suggests that endometriosis is associated with a 2-3 fold increased risk of developing epithelial ovarian cancer. In Northern Ireland (NI), on average, 22 cases of Clear Cell Carcinoma (CCC) or Endometrioid Carcinoma (EC) are diagnosed annually. The primary aim of this study was to determine whether a left lateral predisposition of ovarian CCC or EC exists in the malignant transformation of endometriosis. Secondary aims were to determine any pre-operative predictors of the stage of disease.

Methods

All patients diagnosed with ovarian CCC and EC in NI between March 2011 and June 2018. Data was collected electronically on patient demographics, symptoms, imaging, stage/grade and site of tumour, adjuvant treatment and survival. Statistical analysis was performed using one-way ANOVA (predictors of stage), t-test (compare means) and chi-squared (compare observed and external events) with $P < 0.05$ considered statistically significant.

Results

- Retrospective cohort study
- 158 patients identified - 95 (60%) EC, 55 (35%) CCC, 8 (5%) Mixed EC/CCC
- Median age 57years
- 8.8% had known endometriosis at presentation
- 69% presented at stage 1
- Mean CA125 (all stages) = 559 (P 0.850)
- Most common presenting symptom was an abdominal mass (37%) with mean abdominal mass size 14.12cm (P0.732). 51% had an abdominal mass >10cm.
- 51% of tumours present on left, 30% on right, 12% bilateral + 7% unknown. Statistical significance for left sided tumours in EC (P=0.002) but not for CCC (P=0.555).
- 67% had surgery in a regional gynae-oncology cancer centre
- Endometriosis noted on 67% of histopathology reports post-operatively
- Median 5 year survival for EC, CCC + mixed EC/CCC was 67months, 30months + 7 months respectively

Conclusions

Even with no known history of endometriosis pre-operatively, EC + CCC show a clear correlation with endometriosis, with 67% having confirmation of endometriosis on histopathology post-operatively. Ovarian EC, compared to CCC, is significantly more likely to develop on the left adnexal side which highlights a potential difference in disease pathogenesis. There is no statistically significant association of pre-operative CA125 and adnexal mass size on the stage of disease at presentation.

Laparoscopic cervical myomectomy during pregnancy

Sayed Elakhras¹, Bassem Sobhy², Mohamed Salama³

¹Omam Hospital, Dept. of Minimally Invasive Gynaecology, Cairo, Egypt

²Galaa Teaching Hospital, Obstetrics and Gynaecology, Cairo, Egypt

³Ain Shams University, Obstetrics and Gynaecology, Cairo, Egypt

Background

Uterine fibroid is the commonest benign tumour of the female reproductive tract. It occurs in 20–40% of women, whereas the estimated incidence in pregnancy is 0.1–3.9%. Uterine fibroid in pregnancy is usually asymptomatic with complications occurring in 10–30% of cases.

Most common tumours of the uterus are fibroids but cervical fibroid is rare during pregnancy with different management difficulties.

The first line of management is conservative with counselling for myomectomy after delivery. However, in the presence of intractable symptoms, both antepartum myomectomy and caesarean myomectomy have been reported to be successfully performed in carefully selected cases.

Methods

We report a case of large cervical fibroid in pregnancy that was referred to our centre at 15 weeks of gestation presented to us with spasmodic pelvic pain, heaviness, chronic constipation and urgent urinary incontinence. Thus, she was admitted and laparoscopic myomectomy at 15 weeks of gestation; the outcome was laparoscopic myomectomy was done successfully with preservation of pregnancy

Results

The patient presented with spasmodic pelvic pain, heaviness, chronic constipation, urinary incontinence and amenorrhoea of 15 weeks duration.

On examination, her vital signs were stable, mild pallor present. On per abdominal examination uterus size was consistent with 20wk pregnancy. A moderate degree of contraction and tenderness was presented and foetal heart sound confirmed with US. On per vaginal examination, there was a mass of 15×15 cm size felt in lateral side of cervix suggesting cervical fibroid.

Her all blood investigations were done all were within the normal range.

Abdominopelvic sonography showed a viable singleton intrauterine foetus of 15 weeks gestation. It also showed a large cervical fibroid measuring about 10cm × 9cm.

MRI showed gravid uterus with single foetus with large interstitial mass lesion centred upon the rt lateral aspect of the lower segment of uterus is seen compressing the cervix to the left side it measure about 8.7x9.1x9 cm

counselling of patient and her family was done regarding the condition and management options.

Laparoscopic excision of cervical posterior myoma about 9x10cm using harmonic and myoma screw, then suspension of left ovary to widen field for suturing of myoma bed using v-lock.

Intraoperative ultrasound was done for confirmation of viability of baby

Postoperative care was done with tocolytic and analgesia

Conclusions

Cervical fibroid in pregnancy is rare, so it is necessary to raise the patient's awareness towards the possible outcomes by obstetricians.

Obstetricians need to be more vigilant about the consequences and the challenges faced with cervical fibroid in pregnancy.

laparoscopic myomectomy of cervical myoma in gravid uterus can be safely performed in carefully selected cases

<https://player.vimeo.com/video/825136227?autoplay=1>

Thickened endometrium in asymptomatic postmenopausal women – when to intervene? A systematic review and meta-analysis

Harpreet Kaur¹, Shahin Qadri¹, Alan Nevil², Ayman Ewies¹

¹Sandwell and West Birmingham NHS trust, Gynecology, Birmingham, United Kingdom

²University of Wolverhampton, Education Health and Wellbeing, Wolverhampton, United Kingdom

Background

Endometrial cancer presents with postmenopausal bleeding (PMB) in $\geq 90\%$ of cases. Trans-vaginal ultrasound scan (TVS) is the first line of investigation to assess endometrium. Endometrial thickness (ET) threshold $>4\text{mm}$ is used to trigger further investigations in women with PMB to rule out endometrial atypical hyperplasia or cancer. The incidental finding of $\text{ET} > 4\text{mm}$ is a common cause of referral to secondary care for women with symptoms other than PMB although, there is lack of consensus and evidence-based guidelines on ET threshold for endometrial evaluation in this cohort of women. The aim of this work is to identify the optimal ET cut-off that should trigger endometrial evaluation in women with no PMB and $\text{ET} > 4\text{mm}$.

Methods

Literature search was performed by a librarian, and strategies were developed using a combination of standardised terms and keywords implemented in Medline, EmBase, CINAHL, PubMed and Cochrane. Case reports, case series and review articles, and article published in languages other than English were excluded. Studies included women on HRT or Tamoxifen were also excluded. The criteria used to select studies included: asymptomatic postmenopausal women, $\text{ET} > 4\text{mm}$, 2-D TVS used to measure ET, and endometrial biopsy was taken as a reference test. Pearson's correlation, linear regression, and a simple visual scan (scatter diagram) was used to explore the association between ET cut-off and the percentage of women diagnosed with endometrial atypical hyperplasia and cancer. SPSS Version 28 was used for data analysis.

Results

Out of 1498 studies retrieved on applying the search strategy, 23 observational studies including 6389 women were selected for the meta-analysis. There was a wide variation in the suggested ET cut-off ranging from 5mm to 14.5mm with 6 out of 23 studies found no optimal ET threshold to correctly rule out endometrial atypical hyperplasia and carcinoma. The heterogeneity in reporting and findings reduced significance of quantitative data synthesis; therefore, the data were not amenable to meta-analysis. We found no linear or curvilinear association between 17 ET cut-off points and the percentage of women diagnosed with endometrial atypical hyperplasia and cancer using either Pearson's correlation, linear or non-regression, or a simple visual scan/scatter diagram.

Conclusions

There is no evidence in the literature or consensus amongst investigators as regards the optimal ET threshold that triggers further investigations to rule out endometrial atypical hyperplasia or cancer. Given the heterogeneity of reporting and findings, it was not feasible to do a meta-analysis. Based on the available literature, we recommend an individualized approach in the management of asymptomatic postmenopausal women with incidental finding of $\text{ET} > 4\text{mm}$ taking into account women's views and co-morbidities. A well-designed multi-centre prospective study is planned to inform clinical practice.

**ES32-0193 -
Free Communication**

Patient experience of outpatient myosure hysteroscopic procedure in a district general hospital, Stockport NHS Foundation Trust in the United Kingdom

Mousumi Sadhukhan¹, Olivia Aurangzeb¹

¹Stockport NHS Foundation Trust, Obstetrics and Gynaecology, Manchester, United Kingdom

Background

MyoSure hysteroscopic tissue removal system is a hysteroscopic intrauterine procedure used to resect and remove tissue including submucous fibroids, endometrial polyps, and retained products of conception. The outpatient service in Stepping Hill hospital, Stockport, started in 2016 is now well established. This study aims to determine patient experience and tolerability of outpatient Myosure and explore any factors that might affect pain perceived during procedure which might assist effective counselling of future patients.

Methods

Descriptive study using survey methodology is used to capture the breadth of information from a large number of patients. Data collected from face-to-face interview using structured questionnaire following outpatient Myosure from consecutive patients under one consultant. All patients had intracervical local anaesthetic (LA) infiltration. All patients are advised to have pre-procedure analgesia and Entonox is offered to everyone. Information is collected from structured questionnaire focussing on patient experience during procedure and future recommendation to friends/family. Patients rate pain score during procedure using Likert scale 0-10 (with 0 being no pain and 10 being intense pain). Prospective data collected in excel spread sheet and simple statistical methods used for data analysis. Any relationship with pain experienced and categorical variables (menopausal status, number of vaginal deliveries, use of Entonox and request for General anaesthetic (GA)) using unpaired T-test to determine significance was explored.

Results

Between April 2016-April 2023, 392 patients who had outpatient Myosure performed by one consultant was included. The average pain score was 3.54 (SD=2.12). Although available, less than 1/3 patients used Entonox as additional pain relief during procedure and 27% did not take pre-procedure analgesic. Only 0.5% requested GA for future and most patients wanted to recommend the procedure to friends/relatives. This indicates that outpatient Myosure is a well-tolerated procedure. Patients with no previous vaginal delivery had an average pain score of 3.59 (SD=2.12) and patients with one or more vaginal deliveries had an average pain score of 3.25 (SD=2.12) (p-value 0.83). The average pain score of pre-menopausal patients was 3.41 (SD= 1.93) and those of post-menopausal was 3.61 (SD= 2.39) (p-value 0.37). Interestingly there was no significant difference in the pain experienced with menopausal status or previous vaginal deliveries in our patient cohort.

Conclusions

Myosure is a well-tolerated outpatient procedure. It has significant benefits for patients by avoiding GA, less time in hospital and quicker recovery. It is a safer alternative in patients who are high risk for GA. There are significant financial savings for National Health Service which is primarily funded by taxpayers and free. This study is limited as it is one consultant's data and numbers are limited. However, neither menopausal status nor previous vaginal delivery was a factor in pain perception, and this could help in patient counselling.

The role of pre-surgical tru - cut biopsy in the management of myometrial lesions - pilot study

Adela Richtarova¹, Kristyna Hlinecka¹, Zdenka Lisa¹, Filip Fruhauf¹, Michal Mara¹

*¹General University Hospital and First Faculty of Medicine of Charles University,
Department of Obstetrics and Gynaecology, Prague, Czech Republic*

Background

The main purpose of this study was to determine the accuracy of transcervical Tru-cut biopsy (TCB) as complementary diagnostic method in the preoperative management of patients with sonographically atypical uterine myometrial lesions.

Methods

Patients (symptomatic and asymptomatic) with atypical myometrial mass on preoperative Ultrasound (US) indicated for curative surgery either fertility preserving procedure or hysterectomy were included. The myometrial lesion was described using the MUSA (Morphological Uterus Sonographic Assessment) criteria.

Patients who met the entry criteria underwent US guided TCB. Transcervical approach without the disruption of the perimetrium was preferred to exclude the risk for dissemination of potentially maligning cells. Three tissue samples of the tumour were collected for histopathological analysis from each patient two to four weeks prior to surgery.

If the histology result from TCB was conventional leiomyoma we proceeded with laparoscopy and power morcellation as a method of extraction followed by abundant lavage. If the histology result from TCB was other benign variant of leiomyoma than conventional leiomyoma we proceeded with laparoscopy and enclosed morcellation. If the result was suspicious of malignancy we used open approach.

The histological results from TCB were then compared with the histological results from the planned procedure and the accuracy of TCB was determined.

Results

Forty patients were included in the study. The TCB was feasible in all included patients. In 38 patients (95%), the TCB was adequate and the material collected during TCB was sufficient for histopathological analysis. In these 38 patients we noted 29 conventional leiomyomas, 8 atypical benign leiomyomas (eg. cellular leiomyoma, leiomyoma with bizarre nuclei, epithelioid leiomyoma or adenomatoid tumour) and 1 case suspicious for malignancy. The histology results from TCB were concordant with the definitive histology results in 35 cases (92%).

We recorded one major complication, intraabdominal bleeding, that required intervention.

Conclusions

Our pilot data suggest that TCB could be an accurate, feasible and safe complimentary diagnostic method for patients with planned myomectomy or hysterectomy and abnormal US appearance of the uterine mass. TCB can thus provide reliable and precise histopathological data and may allow the surgeon to set up an adequate, mini-invasive, and still maximally safe treatment plan.

**ES32-0491 -
Free Communication**

Laparoscopic approach cervical fibroid myomectomy video presentation

Rasha Abdeldayem¹, Dimitrios Miligkos²

¹University hospital of Southampton, gynaecology department-university hospital of Southampton, Southampton, United Kingdom

²University hospital of Southampton, gynaecology department, Southampton, United Kingdom

Background

28years old lady

First presentation ,

PG,19 weeks pregnant, c/o lower abdominal pressure pain.

Was examined by the midwife

Speculum showed 8x8x10cm large mass protruding through the introitus likely fibroid polyp

U/S showed-cervical fibroid within the cervical body In view of the uncertainty of the origin of the fibroid. MRI was requested

she was managed conservatively throughout the pregnancy, delivered by LSCS

then patient was counselled for management options either UAE or laparoscopic myomectomy.

Methods

video presentation

Results

very good outcome, postop-patient recovered very well

Conclusions

laparoscopic approach of cervical fibroid management

<https://player.vimeo.com/video/831317278?autoplay=1>

**ES32-0512 -
Free Communication**

Preoperative screening of uterine leiomyosarcoma

Milana Dzeitova¹, Frédéric Goffin², Patricia Nervo², Michelle Nisolle³, Laurent De Landsheere³

¹Centre Hospitalier du Bois de l'Abbaye CHBA, Department of Obstetrics and Gynaecology, Liège, Belgium

²Centre Hospitalier Universitaire de Liège - CHU, Department of Obstetrics and Gynaecology, Liège, Belgium

³Centre Hospitalier Universitaire de Liège, Department of Obstetrics and Gynaecology CHR, Liège, Belgium

Background

The purpose of this study was to assess the preoperative screening methods specifically imaging techniques that best differentiate leiomyosarcoma (LMS) from leiomyoma to propose a management diagram for uterine lesions and to evaluate the diagnostic exactness of magnetic resonance imaging (MRI).

Methods

This multicentre retrospective study regards 1010 patients operated for a benign or malignant myometrial tumour by ten selected gynaecologists from CHU Notre-Dame des Bruyères and Citadelle in Liège from January first 2016 to January first 2022.

We retrospectively analysed 1010 medical files and gathered data concerning the preoperative investigation including MRI and ultrasound imaging criteria, the nature of the lesion (benign or malignant), the type of performed surgery (total or radical hysterectomy versus myomectomy), the type of extraction (with or without an endobag) and any ulterior surgical procedure if it's a recurrent lesion. We included any MRI performed in the year preceding the surgery and studied several criteria such as tumour size, T1 and T2 sequences signal intensity, enhancement, border appearance, endometrial involvement, restricted diffusion and ADC value. We also studied ultrasound imaging criteria. We collected information about the patients such as age, gestity, parity, hormonal status and their body mass index (BMI).

Results

Ultrasound (US) imaging was performed in all patients, but many protocols were lacking thus making the data statistically insignificant. Only 8% of US suspected lesions were indeed malignant.

50% of patients had an MRI screening prior to the surgery and 10,7% of these uterine tumours were labelled as suspected of malignancy. The MRI screening in our study has a high diagnostic performance with a sensitivity of 72%, a specificity of 92,5% and a negative predictive value (NPV) of 98,4% though the positive predictive value (PPV) is only of 33,3%. The size of the tumours in 60% of cases was superior or equal to 7cm. 56% of the suspected malignant tumours were single uterine lesions, 60% showed a heterogenous enhancement with irregular central areas lacking contrast due to necrosis. Usually, sarcomas present an irregular border which was not the case in our study. High diffusion weighted imaging and low ADC values are found in LMS. Indeed 72% of malignant tumour presented a low ADC value 36% of which was lower than $0,9 \times 10^{-3} \text{mm}^2 \text{s}^{-1}$. Therefore we confirm the new ADC cut-off value described by Wahab et Al in 2020.

Conclusions

So far MRI imaging is the best preoperative screening method for differentiating LMS, a highly aggressive tumour with poor prognosis, from leiomyoma. The great NPV of MRI allows the surgeon to dismiss the risk of LMS. However a tumour suspected of malignancy at MRI should be treated with caution and the patient provided with a close follow-up. In these cases the patient-physician communication must be optimum.

Towards a clinical consensus on the management of pregnancy and birth after laparoscopic myomectomy: a survey of UK obstetricians and gynaecologists

Anna McDougall¹, Sophie Strong², Alison Wonnacott³, Amelie Morin⁴, Rebecca Mallick⁵, Funlayo Odejinmi⁶

¹Homerton University Hospital, Obstetrics and Gynaecology, London, United Kingdom

²Royal London Hospital, Obstetrics and Gynaecology, London, United Kingdom

³Royal London Hospital, Obstetrics & Gynaecology, London, United Kingdom

⁴University College Hospital, Obstetrics & Gynaecology, London, United Kingdom

⁵University Hospital Sussex NHS Foundation Trust, Obstetrics & Gynaecology, London, United Kingdom

⁶Whipps Cross University Hospital, Obstetrics & Gynaecology, London, United Kingdom

Background

The primary aim was to assess if a clinical consensus regarding the management of pregnancy post myomectomy existed amongst consultant obstetricians and gynaecologists. Secondary objectives were to evaluate factors which influence the clinician's decision making in this group of women.

Methods

Electronic survey sent to all consultants working in the North Central and East London deanery, Kent Surrey and Sussex deanery and Imperial NHS Trust, United Kingdom to assess opinions on mode of birth post myomectomy, intervals advised to pregnancy post myomectomy, factors influencing the management of delivery in the scarred uterus post myomectomy, opinions on induction of labour and questions relating to operative notes.

Results

209 consultant responses received between 07/03/2022 - 07/05/2022 (44% response rate); 77% (161/209) practicing obstetricians and gynaecologists, 10% (21/109) pure gynaecologists and 13% (27/209) pure obstetricians. The majority would support a vaginal birth after laparoscopic myomectomy (79%). No consensus was found as to the optimal time interval between myomectomy and pregnancy. Higher frequency of performing myomectomy and a greater level of experience were significantly associated with a shorter interval to pregnancy advised. The most important operative factors influencing decision to support trial of labour post myomectomy were breach of uterine cavity; location of fibroids removed and number of incisions on the uterus. 77% believe women should be given a choice regarding mode of delivery post myomectomy in a similar way to previous LSCS. 82.8% would support enrolment of patients into a prospective trial to investigate delivery post myomectomy.

Conclusions

We present a comprehensive survey of clinician opinions on pregnancy post myomectomy demonstrating that the majority of consultant obstetricians and gynaecologists sampled would support vaginal birth post laparoscopic myomectomy; counselling patients in a similar way to VBAC; a standardised myomectomy operation note and enrolment of patients in a future prospective trial. Wide variation in opinion regarding interval to pregnancy post myomectomy has been highlighted. We believe this information will facilitate counselling discussions and empower women with subsequent pregnancies after myomectomy to make an informed decision on mode of birth post myomectomy.

**ES32-0630 -
Free Communication**

Hemi-uterus (U4bC0V0) with unilateral adnexal agenesis - a clinical case

Joana Simões¹, Ana Sofia Fernandes², João Cavaco Gomes², Jorge Beires²

¹Centro Hospitalar Universitário do Algarve - Unidade de Faro, Gynecology e Obstetrics, Faro, Portugal

²Centro Hospitalar Universitário São João, Gynecology and Obstetrics, Porto, Portugal

Background

Hemi-uterus, classified in the ESHRE-ESGE classification of female genital tract congenital anomalies as Class U4, is a formation defect defined as the unilateral uterine development. Class U4b is characterized either by the presence of non-functional contralateral uterine horn or by aplasia of the contralateral part.

Methods

An healthy 36-year-old woman, who had a previous pregnancy with a caesarean-section at 34 weeks for premature labour and pelvic presentation, was referred to our hospital after being diagnosed with left renal agenesis to exclude gynaecological malformations.

She had no symptoms and the gynaecological examination was normal.

The transvaginal sonography revealed an anteverted uterus measuring 37 x 31 x 28 mm (longitudinal, anteroposterior and transverse dimensions), with an endometrial thickness of 2,2mm. The right adnexa appeared normal. There seemed to be only one uterine horn and the left adnexa was not visible. We attempted to obtain a 3D image but it had poor quality due to the menstrual phase.

In the hysteroscopy, we observed a normal cervical canal and a wide hemi-cavity, with a normal left ostium but no right ostium.

Results

The diagnosis of a hemi-uterus without rudimentary cavity (U4bC0V0) with homolateral adnexal agenesis was made.

Conclusions

Hemi-uterus is often associated with poor obstetric outcomes, as preterm birth. Adnexa are usually normal in women with this uterine malformation. We report a rare case of hemi-uterus associated with unilateral adnexal and renal agenesis.

<https://player.vimeo.com/video/831669643?autoplay=1>

**ES32-0653 -
Free Communication**

Laparoscopic myomectomy - "degenerated fibroid"

Kunal Rathod¹, Yatin Thakur², Premilla Kollipara¹

¹Queens Hospital Romford, Gynaecology, London, United Kingdom

²Basildon and Thurrock University Hospital, Gynaecology, Essex, United Kingdom

Background

Leiomyomas are the commonest uterine neoplasm, occurring in around 20-30% of women in the reproductive age group. They are composed of smooth muscle and fibrous tissue and are benign in nature. The typical appearances of leiomyomas are easily recognized on imaging. However, the atypical appearances that follow degenerative changes may cause confusion in diagnosis. Appropriate clinical and sonographic examination followed by surgical management and good peri-operative care are necessary to obtain a good result after removal. While this surgery requires intensive training in surgical skills such as intracorporeal suturing and specimen extraction, patients can also expect less adhesion and a quick return to normal activity.

Methods

Patient was placed in the lithotomy position with a 10-degree Trendelenburg tilt and a uterine manipulator was inserted to control the position of the uterus. Verres needle was inserted supraumbilical for CO2 insufflation. 10 mm primary port with 10 mm 30 degree scope was used. Two ancillary ports were placed on surgeons side and one on contralateral side. Injection argipressin 20 IU in 100mls normal saline was used for prophylactic haemostasis along with 1 gm Tranexamic acid. Horizontal oblique incision was made over the fibroid. Correct plane was identified and 360 degree myometrial dissection was performed for enucleation of fibroid. Counter-traction was always employed and is of paramount importance. Four fibroids were removed and they were parked in right paracolic recess. Multilayered suturing of myometrium and serosa was performed. Fibroid was placed in morcellation bag and contained morcellation was performed.

Results

Complete removal of fibroids was performed in a contained bag. Blood loss was 250 cc and urine was clear at the end of the procedure. Drain was inserted to monitor bleeding postoperatively and antibiotics was given for 5 days. Drain was removed on day 1 and patient was discharged on day 2. Histopathology were suggestive of benign leiomyomas.

Conclusions

In laparoscopic myomectomy, there are three important steps—enucleation, repair, and extraction of fibroid. Each of them requires advanced laparoscopic skills. The role of speed in these basic skills is of extreme importance to reduce blood loss. Contained morcellation should be performed for degenerated fibroid if not for all which is extremely difficult to morcellate with risk of spread of leiomyomatosis and rarely cancer.

<https://player.vimeo.com/video/832463119?autoplay=1>

**ES32-0473 -
Free Communication**

Taking on Artificial Intelligence: doctor versus AI patient information leaflets - a randomised double blinded study

Edward Harrison¹, Ahmed Ellaboudy¹

¹University Hospital Wales, Gynaecology, Cardiff, United Kingdom

Background

Artificial Intelligence(A.I) is taking the world by storm. It's a highly controversial topic and requires strict legislation, however it may pave the way for our future. Historically in laparoscopic surgery world , advances have always taken a while to convince the more cynical minds amongst us, whether it be the technology wasn't quite there yet or it just seemed too outrageous. Should Open AI, an easily accessible, free data information and processing software be the next tool in our arsenal?

Methods

We proposed a head to head of doctor versus AI, to see who or what could generate the most effective patient information leaflet(PIL). The topic chosen was Pelvic Floor Physiotherapy for Chronic Pelvic Pain. A second year O&G Trainee and AI were given the same information to devise the leaflet.

"Please devise a patient information leaflet on pelvic floor physiotherapy for women with chronic pelvic pain at the reading age of a 12 year old."

To ensure a fair comparison of the content alone, all references were removed, the fonts, colours and images removed. 77 patients with confirmed endometriosis seen in clinic from Jan 2023 to present day were selected. The first half were sent the doctor PIL and second half the AI PIL. The patients were only made aware of the author after completion of the google form which assessed readability, comprehensibility and effectiveness. We performed a range of readability tests on the text and timed the authors on production.

Results

Six of seven validated readability calculators scored the Doctor PIL as easier to read, with AI 1-2 reading years older. Patient responses however, suggested a 3.6/5 readability vs 4.3/5 readability in favour of AI, with 33% of the doctor cohort reporting 'a few too many' jargon terms. The overall understanding of the content was felt be slight better in the AI group 4.3/5 vs 4.1. Use of headings and bullet points favoured AI 3.6 vs 3.3. 83% would recommend the AI leaflet to a friend vs 66% for the doctor PIL. 66% of both the AI and Doctor cohort thought the PIL was written by AI. AI wrote this in 5 minutes compared to 10 hours for the doctor.

Conclusions

Readability scores favour the doctor's leaflet, but the target audience felt the AI leaflet had better readability. AI scored better in every other outcome measure and generated the leaflet in less than 1% of the time taken by the doctor. Further evaluation is needed, however in this example AI is the clear winner. I propose we rethink how we approach generating information for patients. Perhaps we are not as good as we think we are.

Breast cancer in endometriosis: comparison of different types of both diseases

Aikaterini Selntigia¹

¹*Policlinico Tor Vergata, Gynecology and Obstetrics, Rome, Italy*

Background

Both endometriosis and breast cancer have high prevalence and common risk factors, based on abnormal hormonal and inflammatory environment, such as elevated BMI, early menarche age, late menopause age, nulliparity and infertility. The main purpose of this study was to investigate the association between subtypes of breast cancer and subtypes of endometriosis considering the risk predictors of developing breast cancer and the differences contributed on hormone receptors and menopausal status at diagnosis of breast cancer.

Methods

Our retrospective observational study included women affected from endometriosis and concomitant breast cancer (study group); endometriosis without breast cancer (group B) and breast cancer without endometriosis (group C) from 2018 to 2023. The diagnosis of breast cancer was confirmed by histological examination after surgical excision. The subtype based on the receptors and the histological examination was registered. All the included patients underwent 2D, and Power Doppler transvaginal ultrasound (US) pelvic examination. Medical history and symptoms were collected for each patient before the US examination. All possible locations of endometriosis were evaluated and recorded using a US dedicated mapping sheet. Pelvic endometriosis was diagnosed in all patients with transvaginal ultrasound examination or previous surgery and divided in deep infiltrated endometriosis and/or adenomyosis.

Results

Our study included 40 cases affected by endometriosis/adenomyosis (study group) and breast cancer matched (1:2) with 80 patients affected by only endometriosis/adenomyosis (group a) and 80 patients with only breast cancer (group B). Regarding the specific localization of endometriosis, the presence of posterior deep infiltrated endometriosis (DIE) was more detected in the group without breast cancer (79% vs 40%, $p=0,004$). Higher percentage of ER+/PR- hormone receptor profile in patients with cancer and endometriosis was observed (15% vs 5%, $p=0,07$). Furthermore, HER2 expression is significantly higher in the group of patients affected from only breast cancer (group B) (43% vs 15%, $p=0,03$). Therefore, luminal B HER2+ subtype is more represented in women affected from breast cancer without endometriosis (group b) (40% VS 5% $p=0,006$).

Conclusions

In our study a correlation between endometriosis and breast cancer subtype was observed: patients with endometriosis presented lower aggressive breast cancer and a tendency of higher expression of ER+/PR- receptor profiles. In order to confirm our preliminary results further prospective studies are needed.

Chronic pelvic pain: a pit stop in the road to diagnosis of endometriosis?

Shruti Saralaya¹, Pinky Khatri¹, Iryna Yuschenko¹

¹James Cook University Hospital, Minimal Access - Gynaecology, Middlesbrough, United Kingdom

Background

Chronic Pelvic Pain accounts for 10%-40% of all Gynaecological visits. Pelvic pain is the most common reason for Laparoscopy in the UK.

Methods

This was a Retrospective Case Note Analysis covering the time period of 18 months from Jan 2016 to June 2017. A total of 81 patients met the criteria to be included in the study.

Women who underwent laparoscopic evaluation for Chronic Pelvic Pain at James Cook University Hospital were included

- The specially designed Proforma was used to collect data.

The demographics, clinical presentation, TVUS examination and laparoscopic findings, pain score prior and post-surgery were included in proforma.

- Data entered on Microsoft excel and means and percentages calculated .

Results

Demographics:

Age range of patients included in our study is between 17-59 years. 42% of women were in age group of 20-29 years. nearly half of the patients were Multiparous. 71.6% (58) had no history endometriosis and 51.9% (42) had no prior history of abdominal surgery • 3.6% (11) had family history of endometriosis. 93.8% (76) had no history of PID.

Presenting Symptoms:

The commonest presenting symptom was non-radiating ,on and off lower abdominal pain. Additional symptoms of Dysmenorrhoea (Pain score of 1-4 in 65.4%) and dyspareunia (64.2%) were frequently seen, whereas rectal symptoms were less common.

Ultrasound and Laparoscopy:

Ultrasonography showed as normal in 33(57%) of patients followed by myoma in 14 (24.1%) of patients. Laparoscopy returned a diagnosis of Endometriosis in 54 (66.7%) of the patients. **Interestingly Ultrasound did not pick up endometriosis in any of the patients who had Endometriosis diagnosed on Laparoscopy.** In patients presenting with pain abdomen/back pain, out of 31 patients where Ultrasound was reported as normal, the Laparoscopy too co-related as normal in 26 patients. In the 23 patients presenting with rectal symptoms, 15 were found to have Endometriosis on Laparoscopy.

Conclusions

Pelvic pain is a syndrome in which biological and psychosexual factors play role. Accuracy of clinical examination is limited by the presence of objective physical signs and symptoms. Transvaginal Ultrasound Scans can be of value to diagnose or to exclude an ovarian endometrioma and myoma.

Laparoscopy is the gold standard for diagnosing endometriosis as recommended by ESHRE guidelines.

Endometriosis found in 66.7% of patients presented with CPP with stage 1 being the prevalent as 39% followed by stage 4 as 26%.

Ovarian cyst rarely causes CPP, only 7.4% cases were found in our audit.

- Stage 4 endometriosis found in 36.4% of patients with infertility.

- 78% of patients on long term suppression reported improvement in pain with 72.5% of patients not on long term suppression.

- Laparoscopy has a vital role in the diagnosis and management of patients with CPP resulting in significant symptomatic improvement.

**ES32-0274 -
Free Communication**

Pain, gastrointestinal function and fertility outcomes of modified nerve-vessel sparing segmental and discoid resection for deep colorectal endometriosis – a prospective cohort study

Gernot Hudelist¹, Daria Pashkunova¹, Ezgi Daric², Anna Rath¹, Bernhard Dauser³, Attila Bokor⁴

¹Center for Endometriosis- Hospital St. John of God, Department of Gynecology, Vienna, Austria

²University of Health Sciences Turkey- Zeynep Kâmil Women and Children's Diseases Training and Research Hospital, Department of Obstetrics and Gynecology, Istanbul, Turkey

³Center for Endometriosis- Hospital St. John of God, Department of General Surgery, Vienna, Austria

⁴Center for Endometriosis- Semmelweis University, Department of Obstetrics and Gynecology, Budapest, Hungary

Background

Deep colorectal endometriosis affects about 20% of women with endometriosis and has recently been shown to be prevalent in up to 12% of women attending a general gynaecology clinic. Colorectal deep endometriosis (DE) is commonly associated with more adverse pain and gastrointestinal outcomes. Although a large percentage of women with colorectal DE can be managed conservatively several studies have demonstrated a significant short- but also long-term decrease in pain symptoms following surgical resection of colorectal DE.

The aim of this study was prospectively to investigate pain, pre- and postsurgical GI function and fertility in women undergoing colorectal surgery for symptomatic DE either with a modified segmental resection technique, so-called nerve-vessel sparing segmental resection (NVSSR) or discoid resection (DR).

Methods

One – hundred and sixty two consecutive patients were included out of which 125 (77.2%) underwent NVSSR and 37 (22.8%) DR. Pain symptoms, endometriosis health profile (EPH-30) parameters, lower anterior resection syndrome (LARS) scores, gastrointestinal function related quality of life (GIQLI) were evaluated presurgically and following surgery in a final cohort of 121 patients.

Results

The overall grade III complication rate was 7/162 (4.3%) with no significant differences between NVSSR and DR groups. Overall EPH-30 and pain scores significantly decreased after a median follow-up of 41 (± 17.6) months (EPH-30 51.1, SD 21.5 vs. 12.7, SD 19.3, $p < 0.001$; dysmenorrhea, dyspareunia, dyschezia all $p < 0.001$ both cohorts, respectively). There were no differences between postsurgical prevalence of LARS in both surgery groups (14/98, 14.1% NVSSR; 2/23, 8.6% DR) with significantly decreased LARS scores and increased GIQLI values before versus after surgery in both groups ($p < 0.001$). The overall postsurgical pregnancy and life birth rate in infertile patients undergoing NVSSR and DR was 25/43, 58.1%; 5/9, 55.6%; 14/25, 56.0% and 5/5, 100%.

Conclusions

Colorectal surgery for DE with NVSSR confers similar complication rates, pain reduction and GI function outcomes compared to conservative techniques such as DR. Both techniques confer a significant amelioration of GI function reflected by decreased LARS symptoms and increased GIQLI scores.

Femoral neuropathy after a pectopexy: a clinical case

Erlan Mukanov¹

¹University Medical Center, Obstetrics and Gynecology, Uralsk, Kazakhstan

²Baku Branch of Sechenov Medical University, Obstetrics and Gynecology, Baku, Azerbaijan

Background

Surgical management of pelvic organ prolapse (POP) using laparoscopic non-mesh pectopexy (LNMCP) may be responsible for various complications, such as peripheral nerve injury. The aim of this study is to describe this unfavourable outcome and to estimate its frequency in the series of women managed by our team.

Methods

A 52-year-old woman, who presented with vaginal fullness, vaginal pressure, sagging sensation. She has only grade 3–4 uterine prolapsus by Pelvic Organ Prolapse Quatification System (POP-Q). Surgical treatment was performed by laparoscopic total hysterectomy and non-mesh pectocolpopexy, followed by relaparoscopy. Ultrasound, MRI, clinical and biochemical examinations were used. Quality of life inventories were (Prolapse Quality of Life: P-QOL; Urogenital Distress Inventory-6: UDI-6) recorded preoperatively and at the postoperative first, third and six month.

Results

Immediately after the LNMCP and getting out from anaesthesia, she complained about pain in the femoral and inguinal region and acute pain while lifting the right lower limb, that caused a suspicion of a femoral nerve injury. A patient with femoral neuropathy has pain that radiates into the anterior thigh and midcalf which is associated with weakness of the quadriceps muscle. This weakness can result in significant functional deficit, make the patient unable to extend the knee fully, which can allow the knee buckling, resulting in unexplained fall downs. A patient with femoral neuropathy also may experience weakness of the hip flexors, making walking upstairs quite difficult, what was observed in the immediate and long-term periods. Considering the clinic of femoral neuropathy, treatment was started and oriented at eliminating oedema, restoring the metabolism of the femoral nerve, and eliminating pain. Due to the lack of effect from the treatment and the persistence of complaints, on the 2nd day after the operation, a second laparoscopy was performed with a revision of the suturing area on the right side. A hematoma in the area of the obturator membrane was found, the hematoma was cleaned and ligatures were removed from the iliopectineal ligaments on the right side. Immediately after the second operation, patient felt a significant improvement and had no complaints. For a long time, up to 1 year, she noted weakness of the hip flexors, making it difficult to walk upstairs and sudden knee buckling while walking on a flat surface and leading to unexplained fall downs.

Conclusions

We also noted that the lesion has a tendency to recover with timely diagnosis, rapid elimination of the cause, pathogenetic therapy and mandatory rehabilitation.

Prevalence of caesarean scar disorder in women with one previous caesarean section

Saskia Klein Meuleman¹, Sanne Stegwee², Wouter Hehenkamp¹, Robert de Leeuw¹, Judith Huirne¹

¹AmsterdamUMC - location VUmc, Gynaecology, Amsterdam, The Netherlands

²Erasmus Medical Center, Gynaecology, Rotterdam, The Netherlands

Background

A long-term complication of a caesarean section (CS) is a uterine niche. Recently, a group of international niche experts reached consensus for a disorder caused by a symptomatic niche. The disorder was named Caesarean Scar Disorder (CSDi) and is defined as a condition with at least one primary or two secondary symptoms associated with a niche in the uterine CS scar (1). This study aims to assess the prevalence of Caesarean Scar Disorder in women with one previous CS.

Methods

An extra analysis was performed on the three years follow-up results of the 2Close study, a multicentre RCT that included 2292 women who underwent their first CS (2). Three months after their CS, a transvaginal ultrasound was performed to analyze the uterine scar for a niche. The digital questionnaire at three year follow-up included all primary and secondary symptoms of CSDi except odour associated with abnormal blood loss. For our analysis, we excluded pregnant women and women who were breastfeeding or using hormonal contraception.

Results

Out of the 1648 participants who completed the three-year questionnaire, a total of 670 women were included in this analysis. 434 women were excluded due to pregnancy or breastfeeding, 469 women due to the use of hormonal contraception, and 76 women because the ultrasound evaluations were missing.

Among the 670 women included, 42.5% (n=285) were diagnosed with CSDi. Of the women with a niche experiencing primary symptoms, 32.8% reported postmenstrual spotting, 9.2% pain during uterine bleeding, 0.7% experienced technical issues with a catheter insertion during embryo transfer and 0.2% secondary unexplained infertility combined with intrauterine fluid. Secondary symptoms included dyspareunia (16.4%), abnormal vaginal discharge (23.2), chronic pelvic pain (35.0%), avoiding sexual intercourse (4.6%), secondary unexplained infertility (14.4%), negative self-image (5%) and discomfort during leisure activities (6.1%).

Conclusions

Our study reported a prevalence of 42.5% of CSDi in women three years after their first CS. However, it is important to note that the timing of the questionnaire and exclusion of pregnant women and women using hormonal contraception introduce a potential selection bias. It is expected that the pregnant women are the patients with less symptoms. Additionally, it cannot be excluded that women with gynaecological symptoms are overrepresented in the hormonal contraception group.

Long-term follow-up after segmental colorectal resection in women with colorectal endometriosis: retrospective cohort study from a large teaching gynecological center

Sandra Coll Girona¹, Nuria Barbany¹, Antonia Lequerica², Laura Lázaro², Sandra García¹, Pere N Barri¹

¹Department of Obstetrics- Gynecology and Assisted Reproduction- Hospital Universitari Dexeus- Barcelona- Spain., Gynecology, Barcelona, Spain

²Hospital Universitari Dexeus, Quirúrgica Cirujanos Asociados-, Barcelona, Spain

Background

To describe the clinical and surgical characteristics and the evolution of patients who underwent a segmental colorectal resection to treat colorectal endometriosis and to describe the patients' characteristics who developed the low anterior resection syndrome (LARS) after the surgery.

Methods

We retrospectively analysed all patients with symptomatic colorectal endometriosis who underwent a segmental colorectal resection at our centre from 2008 to 2021. We described demographic, clinical, and surgical variables; we defined surgical success rate, assessing the resolution of symptoms after surgery and the pregnancy rate among patients with infertility or gestational desire.

All surgical procedures were performed by standardized technique. Continuous variables were described by means (SD), and categorical variables by N (%). Time to recurrence and time to pregnancy were estimated using Kaplan-Meier methods. The study was approved by the institutional research board and by the ethical committee.

Results

We included 152 patients; the mean age was 36 (5.8) y.o. and mean BMI was 22.8 (3.52) kg/m². 91 (59.9%) patients referred gestational desire. The 74.1% of patients had at least one previous surgery for endometriosis and the 20.6% of them had more than one. 151 (99.3%) cases were symptomatic, being most common symptoms dysmenorrhea (96%), dyschezia (66.2%) and dyspareunia (61.6%). 96% of procedures were performed by laparoscopy. Of all the segmental resections 61 were at the level of the rectosigma (40.1%), 39 at the rectum (25.7%), 34 at the sigma (22.4%), 11 at the ileocecal junction (7.2%) and 7 (4.6%) patients underwent double resection (ileocecal + rectosigma). In the 98% of cases the surgery included other localizations of endometriosis. The global surgical complications were 23%, being 15.8% minor and 7.2% major complications (Clavien Dindo III-IV). Median follow-up was 43 months. Only 7 (4.6%) patients developed LARS as a treatment sequela (5 cases were LARS major and 3 were minor). Of them, 3 underwent a parametrectomy, including hypogastric nerve excision or manipulation, during surgery. After surgery, 73% of the patients received medical treatment. However, the global radiological recurrence rate was 30.9%. Most recurrences occurred after the second year of surgery. Of those patients, only 14.9% required re-intervention for endometriosis and only one needed another colorectal surgery. 65 women became pregnant after surgery. Median time to pregnancy was 21 months and 77% of patients needed an IVF treatment. The live birth rate after surgery was 67%.

Conclusions

Segmental colorectal resection is a safe and effective technique for the treatment of colorectal endometriosis. LARS syndrome was infrequent after standardized surgery. Although more studies are needed to determine the associated risk factors in non-cancer patients, excision of the hypogastric nerve during surgery might play a role for the development of LARS syndrome.

**ES32-0327 -
Free Communication**

Single-handed laparoscopic retrieval of a lost drain from a minefield of dense bowel adhesions: just pray and do it!

Konstantinos Kypriotis¹, Michail Diakosavvas¹, Nikolaos Kathopoulos¹, Dimitrios Chaidopoulos¹, Charalampos Theofanakis¹, Athanasios Protopapas¹

*¹National and Kapodistrian University of Athens,
1st Department of Obstetrics and Gynecology- Alexandra Hospital, Athens, Greece*

Background

Adhesion formation is very common after abdominal and laparoscopic surgeries, being most prevalent secondary to midline abdominal incisions. The use of drains after cytoreductive abdominal operations is also a common practice to establish early diagnosis of intrabdominal haemorrhage and proper drainage of the abdomen from the serous discharge that could provoke pseudocyst formation or fever postoperatively. The surgeon stabilizes the drain to the skin using suture but it is not unusual that the draining tube is dislocated postoperatively most of the times outside the abdomen but sometimes unfortunately inside the cavity.

Methods

This video presents a case of inadvertently lost drainage into the abdominal cavity on the fifth postoperative day, secondary to cytoreductive surgery for advanced ovarian cancer. A laparoscopic approach was decided using two trocars to perform the operation. During surgery multiple adhesion formation was discovered between the bowel loops and the abdominal wall. After exploring the cavity the tube was located and a 10mm trocar was placed nearby its end to facilitate the retrieval. Subsequently, the scope was inserted in the secondary trocar to check for any possible injury during the primary trocar's insertion. Surprisingly the primary trocar was inserted through the omentum that was firmly adhered to the abdominal wall, though there was no sign of bowel injury.

Results

The patient had an uneventful recovery and left hospital the 2nd postoperative day.

Conclusions

Lost drainage into the abdomen secondary to abdominal operation is a common complication. Adhesion formation may happen as early as immediately postoperatively. Laparoscopy is a feasible option to obtain lost drainage but the insertion point of the primary trocar in case of adhesions should always be evaluated for possible bowel laceration before the end of the operation.

<https://player.vimeo.com/video/839835551?autoplay=1>

**ES32-0513 -
Free Communication**

Surgical challenges: expect the unexpected

Florence Britton¹, Benedetto Mondelli¹, Pavle Dimitrijevic¹, Vasileios Minas¹
¹NHS, Gynaecology, Surrey, United Kingdom

Background

Endometriosis has a natural aptitude to invade surrounding structures, with varied depth of infiltration. For this reason, surgical treatment of endometriosis is among the most challenging in the field of gynaecology.

Often, the clinical scenario and the surgical complexity can be exacerbated by concomitant factors such as previous surgical procedures and fertility treatments.

Methods

We present a case of a 46-year-old lady who presented with pelvic pain significantly affecting her quality of life. She was diagnosed by MRI with bilateral endometriomas and severe posterior compartment endometriosis. The MRI also suggested mild hydronephrosis, without signs of hydronephrosis.

The patient had previously extensive surgery which included a right hemicolectomy performed at the age of 18 years for Crohn's disease.

The case was discussed in the multidisciplinary team meeting and following extensive counselling, the patient was listed for total laparoscopic hysterectomy and bilateral salpingo-oophorectomy +/- segmental resection +/- ureteric stenting.

Results

Intraoperatively, the procedure was particularly challenging due to the complete distortion of the anatomy caused by the endometriosis. In addition, there were signs of chronic intrabdominal infection, adding further complexity to the operation. In particular, the right endometrioma was filled with chocolate material mixed with pus.

Intraoperative cystoscopy, retrograde studies and insertion of ureteric stents was performed. Bilateral uterolysis was achieved successfully without the need for ureteric reimplantation

The rectosigmoid colon was severely adherent to the back of the uterus. Cold scissors were used to minimise the risk of thermal injury and complete excision of the disease was achieved.

The surgical challenges encountered were certainly due to the extent of endometriosis and previous abdominal surgery. However, what was not expected, was evidence of chronic pelvic infection that undoubtedly contributed to the adhesions, further distorting the anatomy. In complex cases such as this one, the importance of having a structured approach cannot be overemphasised. We adopted the "SOSURE" technique which we believe is a technique that can help achieving a safe and effective treatment of the disease.

Conclusions

In conclusion, preoperative planning is imperative, but despite this we should be vigilant to the possibility of unexpected findings intraoperatively.

<https://player.vimeo.com/video/833836306?autoplay=1>

A clinical prediction model for risk of reintervention or postoperative bleeding following laparoscopy for benign gynaecological disease

Gaetano Riemma¹, Vesna Šalamun², Manca Pavec², Antonio Simone Laganà³, Helena Ban Frangež²

¹University of Campania "Luigi Vanvitelli", Department of Woman- Child and General and Specialized Surgery, Naples, Italy

²University Medical Centre Ljubljana, Department of Human Reproduction- Division of Gynecology and Obstetrics, Ljubljana, Slovenia

³University of Palermo, Unit of Gynecologic Oncology- ARNAS "Civico – Di Cristina – Benfratelli"- Department of Health Promotion- Mother and Child Care- Internal Medicine and Medical Specialties PROMISE-, Palermo, Italy

Background

Clinical prediction tools are useful instruments that help increase the accuracy of clinical assessments, simplify complex decision-making, and identify patients at risk for poor outcomes. However, following a laparoscopic procedure, it might be difficult to do early screening for complications that would necessitate a follow-up surgical procedure.

We aimed to develop a clinically applicable prediction tool to early seek major postoperative complications after laparoscopic surgery for benign pathologies.

Methods

A retrospective analysis was done on the anamnestic, intraoperative, and postoperative features of reproductive-aged women who had laparoscopy for benign diseases (total and supracervical hysterectomy, salpingectomy, salpingo-oophorectomy, deep infiltrating endometriosis resection) in a tertiary-care university hospital (Department of Human Reproduction, Division of Gynecology and Obstetrics, University Medical Centre Ljubljana, Ljubljana, Slovenia) from January 2019 to December 2021. Patients with postoperative complications (reintervention or postoperative bleeding) were matched in a 1:2 ratio with women with the same surgical indications without complications. By using multivariable logistic regression, a prediction model was produced by adding several independent modifying elements. The model's predictive accuracy was assessed using the receiver operating characteristic (ROC) curve, the goodness of fit was assessed using the Hosmer-Lemeshow (H-L) test, and predictive performance was confirmed using a calibration curve.

Results

A comparison of 39 complex procedures and 78 simple controls was made. There were no differences regarding the baseline characteristics of cases and controls. There were significant differences in intraoperative blood loss, pre- and postoperative Hb and Ht differences, CRP, 24-hour postoperative Hb, 24-hour postoperative urine volume, and peritoneal drainage volume ($p < 0.05$).

In women having laparoscopy for gynaecological benign illness, the results of multivariate analysis revealed that intraoperative blood loss, total urine output during the first 24 hours following surgery, and CRP were independently impacting indicators for postoperative problems ($p < 0.05$), as shown in Table 1.

Table 1. Multivariable logistic regression

Predictor	Adjusted OR (95% CI)	p-value
Blood loss	1.21 (1.10 – 1.29)	0.030*
Delta Ht	0.97 (0.85 – 1.12)	0.771
Delta Hb	1.01 (0.88 – 1.15)	0.908
Postop. Hb	1.00 (0.95 -1.05)	0.935
Urinary volume	0.94 (0.89 – 0.97)	0.042*
CRP	1.09 (1.03 – 1.11)	0.040*
Drainage	1.02 (0.98 – 1.05)	0.336

Therefore, we created a prediction model based on intraoperative blood loss, total urine output during 24 hours after surgery, and CRP. The prediction model's area under the ROC curve (AUC) showed high accuracy at 0.879, with sensitivity at 60.00% and specificity at 93.59%. The calibration curve and H-L test ($\chi^2 = 4.45$, $p = 0.931$) showed high goodness-of-fit and prediction stability.

Conclusions

In patients having planned gynaecological laparoscopy, this prediction model based on CRP, intraoperative blood loss, and 24-hour urine volume may be a valuable tool for anticipating reintervention and postoperative bleeding.

**ES32-0605 -
Free Communication**

Bladder injury during vNOTES hysterectomy: case report

Carla Escribano Posada¹, Marta L. Salgado¹, Sara Chao de Diego¹, Herminda Gil¹, Sara Quintana¹
¹Hospital Universitario A Coruña, Ginecología y Obstetricia, A Coruña, Spain

Background

The objective of this work is to make surgeons aware of the importance of correct knowledge of the available instruments, their management and indication, as well as the surgical technique before starting an emerging technique such as vNOTES to reduce its complication rate.

Methods

A 44-year-old woman, **c-section** 1, BMI 27.5 consulted in our service for abnormal uterine bleeding. The examination and the ultrasound revealed a 5cm posterior leiomyoma type 2-FIGO. The blood test showed 26% haematocrit. After some unsuccessful treatments with Mirena IUD, tranexamic acid and combined oral contraceptive pills we planned a surgery treatment by vNOTES hysterectomy and bilateral salpingectomy. Previously we solved the anaemia using decapeptyl and intravenous iron

The first steps of a conventional vaginal hysterectomy were done without difficulty and followed by endoscopic approach. Due to lack of 9.5 cm GelPOINT V-Path we started the endoscopy using the 7cm one which caused a poor vision, forcing us to keep the bladder high with a clamp. After some minutes we could see a little hole in the base of the bladder where urine was coming out. It was sutured and the surgery was finished successfully after obtaining and changing the GelPOINT V-Path for the correct size.

Results

The knowledge of the conventional vaginal surgery and the conventional laparoscopic surgery doesn't exempt from knowing the steps and specific devices required to do vNOTES procedures. This patient had some recognized risk factors for any pelvic surgery as previous c-section and overweight. If we add to this a wrong choice of the available devices to do a vNOTES hysterectomy the probability of having a complication increases.

Conclusions

The raising of VNOTEs surgeries makes knowledge of risk factors and correct management of the instruments necessary for this purpose essential.

<https://player.vimeo.com/video/831654821?autoplay=1>

**ES32-0328 -
Free Communication**

The SOSURE teaching method: a tool to improve laparoscopic surgical training

Pavle Dimitrijevic¹, Rakesh Thing¹, Benedetto Mondelli¹, Michael Adamczyk¹

¹Ashford and St Peter's Hospitals, Centre for Endometriosis and Minimally Invasive Gynaecology, Chertsey, United Kingdom

Background

We know that early, regular access to the operating theatre leads to better development of the necessary skills, dexterity and confidence in operating. Likewise, we appreciate that this is something that is difficult for trainees to achieve given the challenges in accessing adequate theatre and demands for service provision in other areas.

In addition, in modern gynaecology, we have witnessed a more conservative approach to conditions which in the past were treated mainly with surgery. Compounding this were the effects of Covid-backed up clinics and cancelled operating lists that have led to significant reduced opportunities for trainees aside from emergency surgery.

Methods

Our CEMIG Unit has devised the SOSURE technique for a systematic approach for laparoscopic excision of endometriosis. In this presentation we demonstrate, using this step-by-step approach to endometriosis, how we are able to divide the surgical case in different steps which can be performed by the different members of the team present in theatre based on their surgical skill and role. This gives the opportunity to every member of the team to gain experience.

Results

We show through videos taken of our trainees operating that as they develop their confidence and technique, they are able to advance from the early stages to more complex ones. We additionally show in this presentation that the SOSURE method can be adapted to various types of laparoscopic surgery.

Conclusions

We believe the implementation of this teaching system is reproducible across all units and most surgical cases leading to increased satisfaction, improved surgical skills and better understanding of anatomy in all gynaecology trainees.

Menstrual literacy and information needs of Dutch women: a qualitative focus group study

Lisa Zuidema¹, Eveline van Luik¹, Manna Alma², Peggy Geomini¹, Jaklien Leemans¹, Marlies Bongers¹

¹Máxima MC, Gynaecology, Veldhoven, The Netherlands

²University Medical Center Groningen UMCG, Applied Health Research, Groningen, The Netherlands

Background

Menstruation remains a taboo subject, despite the fact that nearly half of the world's population undergoes it at some point in their lives. Although women have many questions and information needs about this topic, it is rarely discussed openly. Studies have shown that women wish to have more information about possible treatments for menstrual complaints, managing their own symptoms and emotions, as well as gaining a sense of validation regarding what is considered normal or abnormal. It is thus critical to break the taboo and provide support for women in their quest for information. Therefore, this study aims to investigate menstrual literacy and informational needs of Dutch women.

Methods

This study used a qualitative exploratory design with focus groups discussions. Participants were recruited at the gynaecology outpatient clinic of Máxima MC and through social media. A total of 24 Dutch women (aged between 20 and 62 years), who currently menstruate or have menstruated, participated in three focus group discussions. The data was thematically analysed using ATLAS.ti version 23.

Results

Participants expressed that schools or family members had not provided them with adequate information about menstruation prior to their menarche. This lack of information results in shame, taboos, and bullying among some participants. Furthermore, participants reported difficulty communicating complaints during menstruation to friends, family, and medical professionals, which resulted in a lack of information about what kinds of complaints are normal and when to seek help. Participants suggested it would be ideal to have information on menstruation on an easily accessible platform, categorized according to life stage (for example, menarche, fertility, menopause).

Conclusions

This research serves as a call to action to improve menstrual literacy in the Netherlands. It is recommended to implement menstrual education in school to provide adequate information to all children in order to end the taboo. Besides, online information services should be combined in one practical, patient-oriented website with information categorized according to life stage. This website must provide clear information on what kind of complaints can be expected and when to seek help. By taking these steps, we can break down the taboos surrounding menstruation and empower women with the information they need to manage their menstrual health.

**ES32-0643 -
Free Communication**

laparoscopic entry methods; an audit of entry methods and associated complications in a UK regional endometriosis unit

Alexander Oboh¹, Christain Kremer¹, Nazima Parveen¹, Mahmuda Chowdhury¹

¹The Mid-Yorkshire Hospitals NHS trust, gynaecology, Wakefield, United Kingdom

Background

Laparoscopic surgery for treatment of women with endometriosis is safe with a low mortality and morbidity (3 to 4 per 1000 procedures). However, 50% of complications are related to initial entry technique, which includes injuries to bowel, bladder, and vascular structures in the abdomen.

There is currently no consensus on safest entry technique at laparoscopic surgery in gynaecology patients unlike in general surgery, where open Hasson entry is standard approach. In the United Kingdom, women undergoing laparoscopic surgery - diagnostic or therapeutic, for endometriosis are offered an entry technique depending on preference of surgeon and local guidelines in unit.

In our regional endometriosis service, the type of entry technique is variable, but is mainly based on the surgeon's preference and individual patient characteristics. This audit was a quality improvement project on the type and safety of laparoscopic entry techniques for women undergoing treatment of endometriosis in our unit.

Methods

We reviewed the laparoscopic entry techniques and immediate complications for all women who had laparoscopic surgery – diagnostic and therapeutic at the Mid Yorkshire Regional Endometriosis Centre between 2020 – 2021.

Results

Three hundred and forty-one patients had laparoscopic surgery. We had complete documentation on entry technique in all but 6 patients. 306 patients (89.7%) of patients had closed entry technique with Verres needle at umbilicus. 18 patients (5.2%) had Closed entry with Verres needle at Palmer's point. 10 patients (2.9%) had open Hasson entry technique and one patient has direct entry technique.

There were no complications from open Hasson technique, direct entry or Palmers point entry. Five patients (1.6%) had failed entry with closed entry at umbilicus. All were converted to Palmers point entry. Only one patient (0.32%) had injury to blood vessels on the omentum.

Conclusions

All patients in our endometriosis unit undergoing have safe closed entry technique with the majority of patient with closed entry technique -Verres needle at umbilicus. There were no visceral injuries in the 341 patients. One patient (0.32%) had vascular injury at laparoscopic entry with Verres needle and five patients (1.6%) had failed entry with closed entry at umbilicus, then safely converted to Palmers point closed entry.

Robotic-assisted Gynecological Surgery in Older Patients – a Comparative Cohort Study of Perioperative Outcomes

Anke R. Mothes¹, Angela Kather², Irina Ceperaga², Anke Esber², Anja Kwetkat³, Ingo B. Runnebaum²

¹St. Georg Hospital Eisenach- Academic Teaching Hospital of University of Jena, Department of Gynecology, Eisenach, Germany

²Jena University Hospital, Gynaecology and Reproductive Medicine, Jena, Germany

³Klinikum Osnabrück GmbH, Klinik für Geriatrie und Palliativmedizin Medizinische Klinik IV, Osnabrück, Germany

Background

Because of current demographic developments, a hypothesis was proposed whereby older female patients aged > 65 years can be safely operated using minimally invasive, robotic-assisted surgery, despite having more preoperative comorbidities. A comparative cohort study was designed to compare the age group ≥ 65 years (older age group, OAG) with the age group < 65 years (younger age group, YAG) after robotic-assisted gynaecological surgery (RAS) in two German centres.

Methods

Consecutive RAS procedures performed between 2016 and 2021 at the Women's University Hospital Jena and the Robotic Center Eisenach to treat benign or oncological indications were included in the study. The age groups were compared according to their preoperative comorbidities (ASA, Charlson comorbidity index [CCI], cumulative illness rating scale – geriatric version [CIRS-G]) and perioperative parameters such as Clavien-Dindo (CD) complications. Analysis was done using Welch's t-test, chi2 test, and Fisher's exact test.

Results

A total of 242 datasets were identified, of which 63 (73 ± 5 years) were OAG and 179 were YAG (48 ± 10 years). Patient characteristics and the percentage of benign or oncological indications did not differ between the two age groups. Comorbidity scores and the percentage of obese patients were higher in the OAG group: CCI (2.7 ± 2.0 vs. 1.5 ± 1.3; p < 0.001), CIRS-G (9.7 ± 3.9 vs. 5.4 ± 2.9; p < 0.001), ASA class II/III (91.8% vs. 74.1 %; p = 0.004), obesity (54.1% vs. 38.2 %; p = 0.030). There was no difference between age groups, even grouped for benign or oncological indications, with regard to perioperative parameters such as duration of surgery (p = 0.088; p = 0.368), length of hospital stay (p = 0.786; p = 0.814), decrease in Hb levels (p = 0.811; p = 0.058), conversion rate (p = 1.000; p = 1.000) and CD complications (p = 0.433; p = 0.745).

Conclusions

Although preoperative comorbidity was higher in the group of older female patients, no differences were found between age groups with regard to perioperative outcomes following robotic-assisted gynaecological surgery. Patient age is not a contraindication for robotic gynaecological surgery.

How to train a surgeon - transferability of surgical skill between laparoscopic, robot-assisted and open surgery: a systematic review and meta-analysis

Mona Wanda Schmidt¹, Carolyn Fan², Karl-Felix Köppinger², Johannes Vey³, Felix Nickel⁴, Karl-Friedrich Kowalewski⁵

¹University Medical Center of the Johannes Gutenberg University Mainz, Department of Gynecology and Obstetrics, Mainz, Germany

²University Hospital Heidelberg, Department of General- Visceral and Transplant Surgery, Heidelberg, Germany

³University of Heidelberg, Institute of Medical Biometry, Heidelberg, Germany

⁴University Medical Center Hamburg-Eppendorf, Department of General- Visceral and Thoracic Surgery, Hamburg, Germany

⁵University Medical Center Mannheim- University of Heidelberg, Department of Urology and Urological Surgery, Mannheim, Germany

Background

Mastering not only open surgery, but also laparoscopic and robot-assisted surgery has become a challenged posed to doctors in many surgical disciplines. However, these surgical modalities require vastly different technical skill sets and both efficient and effective training curricula have to be established to ensure patient safety. Thus, in this systematic review and meta-analysis we aimed to investigate to what extent technical surgical skills can be transferred between open, laparoscopic and robot-assisted surgery.

Methods

Three databases (Medline, Cochrane Central Register of Controlled Trials, Web of Science) were systematically searched for trials assessing the skill transfer between robot-assisted, laparoscopic and open surgery. To perform a meta-analysis outcome parameters were categorized into time, process, product or composite outcome. Subgroup analysis were performed to assess the influence of study design, use of virtual reality simulators and basic vs advanced surgical tasks.

Results

Of 14 120 screened trials, 30 were included in the qualitative synthesis and 26 in the quantitative synthesis. 29 trials focused on assessing skill transfer from laparoscopic to robot-assisted surgery and 10 trial for the opposite case. Skill transfer was shown from laparoscopic surgery to robot-assisted surgery and vice versa with regards to composite outcomes and time (laparoscopic to robot assisted surgery. The effect was stronger when using a real robotic system for skill assessment compared to virtual reality simulators. Only three studies assessed the skill transfer between open and robot-assisted surgery.

Conclusions

Technical surgical skills can be transferred between robot-assisted and laparoscopic surgery. This is not only of great importance when discussing credentialing requirements for surgeons in gynecology, urology and general surgery, but should also be a key consideration when designing new training curricula for future surgeons. While patient safety is the primary aim and requires effective training methods, time constraints and a constant pressure to optimized the use of available resources emphasize the need for efficient training strategies. The evidence provided in this meta-analysis highlights the great potential of shortening learning curves and training times by taking prior surgical training into account.

**ES32-0160 -
Free Communication**

Versius surgical system: tips and tricks for OR setting and port placement for pelvic surgery, initial experience in a multi-robotic referral centre

Margarita Afonina¹, Giorgia Gaia¹, Stefano Terzoni², Mauro Fellingine³, Alessandro Morandi¹, Anna Maria Marconi¹

¹San Paolo Hospital Medical School, Department of Obstetrics and Gynecology, Milan, Italy

²San Paolo Hospital Medical School, San Paolo Bachelor School of Nursing, Milan, Italy

³San Carlo Hospital, Department of Obstetrics and Gynecology, Milan, Italy

Background

The last decades have witnessed the spread of robotic surgery for several gynaecological indications. Recently, new robotic contenders have emerged to lower costs and enhance accessibility to robotics. These include the HUGO™ Robotic Assisted Surgery System (RAS, Medtronic, CA) and Versius (CMR Surgical, Cambridge, UK), which are currently being used at our tertiary referral multi-robotic centre. These platforms have become the main competitors of the Da Vinci® system. The use of Versius has also been reported in the fields of general surgery, urology, and gynaecology. Unlike the Da Vinci® system, Versius and Hugo™ RAS have four independent bedside units (BSU), which need to be individually positioned with adequate angles and distance from the operating field and the target organ to avoid collisions during surgery. While the manufacturers suggest positioning and angle of tilt for the Hugo™ RAS based on preclinical studies, data for the Versius system on the measures of such angles and distances still need to be included in the literature. Given this peculiarity, investigating BSU positioning and port placement is mandatory. Therefore, we report technical tips and tricks for operating room setup and port placement by analysing our initial series with the Versius system for benign gynaecological conditions to make the procedure easily reproducible.

Methods

We considered prospectively 16 patients undergoing robotic surgery for benign gynaecological diseases. Demographics, pre-surgical variables, intra-operative robotic events (number and characteristics of collisions, need to detach the instruments and move the trays during surgery), and peri-operative outcomes were collected. In addition, factors impacting the occurrence of high-priority collisions (requiring the disconnection of instruments and restarting of the port training) were analysed.

Results

All surgeries were carried out uneventfully and without conversion. Collisions of any type occurred in 13 out of 16 operations, including 9 High Priority Collisions. Angles between trocars, the distance between them and the target, and the third arm position - carrying the grasper - impact the need to restart the system.

Conclusions

Versius appeared to be a safe option for benign gynaecological surgery. Our experience suggests 150° as the ideal angle between trocars, 5 cm as the minimal distance between the target and the operative trocar, and 14-24 cm as the distance of the third arm to the table – trying to limit collisions and alarms. These suggestions may enhance the technology by establishing a reproducible port placement and surgical setting for gynaecological and pelvic surgery.

**ES32-0205 -
Free Communication**

The AMH level as a factor predicting ovarian reserve after robotic single-site ovarian cystectomy : a retrospective comparison

Hye-Sung Moon¹, So Yun Park¹, Eun Hye Cho¹

¹Ewha Womans University Medical Center, Dept of OB & GY, Seoul, Korea- Republic Of

Background

This study is aimed to investigate which factors are affected in the lowering of ovarian function after robotic single-site ovarian cystectomy.

Methods

Sixty-nine women underwent robotic ovarian cystectomy using the da Vinci® SP or Xi surgical system at Ewha Womans University Seoul Hospital, from November 2018 and February 2020, and we collected the clinical data retrospectively. The serum AMH test was checked in all cases preoperatively and six months after surgery and the cases were divided into two groups by lower and higher preoperative AMH levels (group A, B) than the median AMH value of each age group. All variables were statistically analysed in two groups and statistical analysis was also performed to compare the cases with increased AMH and decreased AMH after surgery which were regrouped into C, D.

Results

In group B, postoperative AMH reduction was more pronounced than group A (0.57 ± 0.73 vs 2.71 ± 0.98 , P-value < 0.01). There were no significant differences of the age of the patient, the size of the cyst or the presence of adhesions, bi-laterality, and the pathologic results between both two groups. There were no statistically significant differences of perioperative AMH level change comparison in both group C and D, with only slight difference in the preoperative AMH (1.89 ± 1.03 vs 2.94 ± 1.90 , p-value 0.16).

Conclusions

This study shows that the drop of AMH levels depends on the preoperative ovarian reserve or preoperative AMH levels. This could be helpful for consultation on preservation of ovarian reserve when ovarian cystectomy is considered in patients who desire pregnancy and childbirth in the future.

**ES32-0390 -
Free Communication**

Robot-assisted isthmocele repair: a case presentation and surgical approach

Kristen Calabrese¹, Kateryna Kolesnikova², Khashayar Shakiba²

¹St. George's University, School of Medicine, True Blue, Grenada

²Women's Pelvic Surgery of North Jersey, Gynecology, Hackensack, USA

Background

The objective of this video abstract was to demonstrate the stepwise surgical technique of robot-assisted isthmocele repair in a case study of a patient with infertility and a known uterine defect. A background of isthmocele including risk factors, clinical presentation, diagnosis, and management was also reviewed.

Methods

This was a single case study with step-by-step surgical technique. The patient in this case study was a reproductive-age female who presented for management of a uterine isthmocele. During the procedure, the patient was positioned in lithotomy position and 4 robotic ports were used in the following locations: umbilical, right and left upper quadrant, and left lower quadrant. The robotic system was docked in the usual right-sided fashion.

Results

The video abstract demonstrated the step-by-step surgical technique of robot-assisted isthmocele repair. The results showed that the uterine defect was fully re-approximated with minimal estimated blood loss and no intra-operative complications. Following the procedure, the patient recovered well and planned to undergo in vitro fertilization.

Conclusions

This video abstract showcases the effective application of robot-assisted surgery in the repair of isthmocele, yielding favourable patient outcomes. This contribution serves to augment the existing body of knowledge surrounding isthmocele, a frequently overlooked condition that has seen a rise in prevalence attributed to the escalating rates of caesarean births. Further studies are needed to confirm the correlation between isthmocele repair and impacts on future fertility.

<https://player.vimeo.com/video/827053931?autoplay=1>

**ES32-0399 -
Free Communication**

Robotic assisted myomectomy for a 28 week size fibroid uterus

Mickey Buckingham¹, Suruchi Pandey¹, Rami Issa²

¹St George's Hospital, Gynaecology, London, United Kingdom

²St George's Hospital, Urology, London, United Kingdom

Background

Robotic myomectomy has gained popularity in recent years for the management of large fibroids due to its ability to provide greater precision and dexterity during fibroid dissection and uterine reconstruction. Compared to the laparoscopic technique, the robotic approach has been shown to have a lower rate of conversions to open surgery.

Methods

This video presentation displays the surgical approach to myomectomy in a 28 week size fibroid uterus with a 13cm fundal subserosal fibroid and excision of bilateral 4cm endometriomata using the robotic approach in a 30-year-old patient presented with pelvic pain.

Results

Surgical steps displayed:

1. Supra-umbilical port for better visualisation with the fibroid uterus dominating the pelvic cavity
2. Coagulation of large veins supplying the fibroid using vascular clips
3. Use of intra-myometrial vasopressin to reduce blood loss
4. Careful dissection of the fibroid capsule
5. Meticulous repair of the uterine muscle and serosa in 3 layers using 3-0 V-Loc
6. Mobilisation of the ovaries and cystectomy performed, ovaries sutured with 3-0 V-Loc
7. Adhesiolysis to dissect the bowel from the uterus
8. 13cm fibroid placed in a specimen bag and brought to supra-umbilical port which was extended
9. Alexis retractor placed and ExCITE (Extracorporeal C-incision tissue extraction) morcellation performed

Conclusions

Large fibroid poses a surgical challenge for laparoscopic approach and most myomectomy for fibroids more than 10cm size are performed via the open approach. In this case, the use of a robot allowed a complex myomectomy to be performed, which would have otherwise required a midline laparotomy using the conventional open approach. Easier manoeuvrability of the wristed instruments allows for manipulation and meticulous closure.

<https://player.vimeo.com/video/827057230?autoplay=1>

**ES32-0478 -
Free Communication**

Robotic bilateral pectopexy with mesh - a new surgical procedure to be considered in pelvic organ prolapse?

Rita Torres¹, Artur Palmas², Luis Vieira Pinto¹, Henrique Nabais¹

¹Champalimaud Center for the Unknown, Gynaecology, Lisboa, Portugal

²Champalimaud Center for the Unknown, Urology, Lisboa, Portugal

Background

Pelvic organ prolapse (POP) can affect 30-50% of the female population. Surgery is indicated in women with symptomatic POP who have failed or declined nonsurgical treatment. Sacrocolpopexy has been the gold-standard for anatomical correction of apical prolapse since 1990s. Pectopexy has been introduced in 2007 as a new surgical procedure for isolated or combined apical suspension. The iliopectineal ligament is a stable structure for fixation of meshes and sutures, stronger than the sacrospinous ligament and arcus tendinous of pelvic fascia. With this procedure the lateral parts of iliopectineal ligament are used for a bilateral mesh fixation of the descended structures. This procedure respects the physiological direction and angulation of the vaginal axis.

Methods

We present a video of robotic bilateral pectineal suspension with mesh.

Results

The procedure was uncomplicated and the patient was discharged on day two. Intraoperative and three month postoperative follow-up POP-Q were 0-1 and the patient was overall very satisfied.

Conclusions

Robotic bilateral pectineal suspension with mesh is an effective and safe procedure to be considered in apical POP surgery.

<https://player.vimeo.com/video/831277472?autoplay=1>

The new robotic system HUGO RAS for gynaecological surgery: first European experience from Gemelli Hospital

Alessandro Gioè¹, Giorgia Monterossi¹, Giovanni Panico¹, Giuseppe Campagna¹, Francesco Fanfani¹, Giovanni Scambia¹

*¹Fondazione Policlinico Universitario Agostino Gemelli IRCCS,
Department of Women's and Children's Health and Public Health, Rome, Italy*

Background

To evaluate the safety and feasibility of the new surgical robot HUGO RAS in a series of gynaecological surgical procedures.

Methods

Between March and October 2022, 138 patients treated at Fondazione Policlinico Universitario A. Gemelli IRCCS, Rome, Italy were enrolled in the study. All patients suitable for the planned surgery using a minimally invasive approach were prospectively included. The exclusion criteria were the suspicion or diagnosis of a gynaecological malignancy that could not be treated with a minimally invasive approach and the indication of sentinel node mapping.

Results

Median age was 56.5 years (range 27 – 84 years), and median BMI was 24.5 kg/m² (19 – 36 kg/m²). Most patients underwent surgery for uterine fibroids (n=43, 31.2%) and pelvic organ prolapse (n=60, 43.5%). The enrolled patients were divided into two main groups: Group 1 (78 patients) made up of patients operated on for uterine and/or adnexal pathologies, and Group 2 (60 patients) made up of patients treated for pelvic organ prolapse. In Group 1, median Docking Time (DT) was 5 min (range 2 – 11 min) and median Console Time (CT) was 90 min (range 20 – 210 min). In two cases (2.6%) redocking was necessary. In two cases (2.6%), the surgeon continued the surgery laparoscopically. Only in one case (1.3%) a supra-umbilicus-pubic laparotomy was necessary due to the size of the adnexal mass. Intraoperative complications occurred in 2 surgeries (2.6%) and post-operative complications occurred in 6 patients (7.7%). The median time to discharge was 2 days. In Group 2, median DT was 4 min (range 2 – 12 min) and median CT was 134.5 min (range 49 – 235 min). In three cases (5%), redocking was necessary. In all cases, the surgery was successfully completed robotically and no intraoperative complications occurred. Post-operative complications occurred in 3 patients (5%) and the median discharge time was 3 days. During the 138 surgical procedures, a total of 34 errors of the robotic system were registered: 4 console errors (11.8%), 21 arm errors (61.8%) and 9 instrument breakdowns (26.4%). All the system errors mentioned were solved without complications for the patient and without any need of surgical conversion.

Conclusions

This study represents the first report in the literature on the use of the HUGO RAS system in gynaecological surgery. It demonstrates that the new system is safe with good results in terms of surgical efficacy and peri-operative outcomes. Further studies are needed to investigate the use of HUGO RAS in other technical and surgical aspects and to analyse the economic aspects of adopting this new technology in everyday practice.

Multi-port, robotically assisted (Da Vinci) laparoscopic myomectomy: a comparative systematic review and meta-analysis of surgical and fertility outcomes

Elias Tsakos¹, Emmanouil Xydias¹, Apostolos C. Ziogas², Felice Sorrentino³, Luigi Nappi³, Angelos Daniilidis⁴

¹Embryoclinic, Department of Robotic surgery, Thessaloniki, Greece

²University of Thessaly- School of Health Sciences, Department of Medicine, Larissa, Greece

³University of Foggia, Institute of Obstetrics and Gynecology, Foggia, Italy

⁴Aristotle University of Thessaloniki, School of Medicine, Thessaloniki, Greece

Background

Uterine fibroids are amongst the most frequent gynaecologic tumours in clinical practice and are most effectively treated with surgical methods. Minimally invasive surgery is nowadays the treatment of choice, with robotic assisted surgery being the latest option available to the gynaecological surgeon's arsenal. This study aims to assess whether robotic assisted laparoscopic myomectomy (RALM) is superior to conventional laparoscopic myomectomy (CLM) and to the simple abdominal myomectomy (AM), with regard to safety and surgical efficacy, in addition to any effects on fertility.

Methods

Relevant studies were systematically sought in peer-reviewed medical research databases. The initial pool of 955 studies was evaluated and reduced to 53, which adhered to the pre-established inclusion criteria, 25 of which were comparative ones. The studies were subsequently evaluated for risk of bias and statistical heterogeneity. A sensitivity analysis was conducted to verify the validity of the applied model. Outcomes were measured in weighted mean difference (WMD) or odds ratio (OR).

Results

The available comparative studies were compared using surgical outcomes, namely blood loss, complication rate, transfusion rate, operation duration, conversion to laparotomy and length of hospitalization. RALM was significantly superior to AM in all assessed parameters, other than operation duration. RALM and CLM performed similarly in most comparisons, with no statistical difference in length of stay, transfusion and complication rates. Operation duration was once more longer in RALM compared to CLM. There were no overall differences in blood loss overall, however RALM was associated with 33.51 ml less blood loss compared to CLM in patients with smaller myoma burden. Conversion to laparotomy rate was superior for RALM, however only marginally non-significant. RALM was shown to improve fertility parameters, with pregnancy rates 50-80% and live birth rates 25-100%.

Conclusions

The robotic approach for uterine fibroids management is a safe, effective and viable approach for uterine fibroids, which is superior to AM in almost every regard and offers significant risk reduction and safety over CLM. Robotic technology, as well as surgical skill is likely to further improve in the future, thus enhancing the benefits already offered by this technology. Further primary research should focus on establishing patient subgroups which would most benefit from this advanced methodology., which is constantly improving and in time may surpass its current drawbacks.

**ES32-0649 -
Free Communication**

Robot-assisted laparoscopic hysterectomy based on membrane anatomy

Yan Kuang¹, Yonglong Shen¹

*¹The First affiliated hospital of Guangxi Medical University, Gynecology Department,
Nanning- Guangxi province, China*

Background

Membrane anatomy (MA) is a surgical operation theory based on the embryonic development of tissues and organs. The key step of MA is to identify the correct space between adjacent organs and fascia by antagonistic traction during the operation. According to membrane anatomy, the operation is always carried out in the correct surgical space and has little bleeding and clear surgical field, which reduces the risk of organ injury and tumour recurrence. Huge uterine fibroids may encounter difficulties in traditional laparoscopic surgery, including the fibroids affecting the surgical field, and the difficulty of stripping and suturing due to the location of uterine fibroids. The high-definition vision and wrist operating instruments of the Da Vinci robotic system can cope with these difficulties well.

Methods

We performed robot-assisted laparoscopic hysterectomy based on membrane anatomy for a patient with giant uterine fibroids and excessive menstruation and secondary anaemia.

Results

Although the huge uterus made it difficult to expose uterine vessels and ureters during the surgery, the operation went smoothly and took 62 minutes. The estimated operative blood loss was about 20 ml. The patient recovered well after operation without surgical complications.

Conclusions

The application of membrane anatomy in robot-assisted laparoscopic hysterectomy has the advantages of reducing surgical bleeding, reducing organ damage and accelerating postoperative rehabilitation.

<https://player.vimeo.com/video/831856763?autoplay=1>

BEST SELECTED ePOSTER

ES32-0456 - P*001

Selected Posters

PARP-1, EpCAM, and FR α as potential targets for intraoperative detection and delineation of endometriosis: a quantitative tissue expression analysis

Anna Giorgiutti¹, Giovanni Di Lorenzo², Stefania Biffi², Beatrice Belmonte³, Alessandro Mangogna², Barbara Bortot²

¹University of Trieste, Department of Medical- Surgical and Health Sciences, Trieste, Italy

²Institute for Maternal and Child Health- IRCCS Burlo Garofolo, Gynaecology and Obstetrics, Trieste, Italy

³University of Palermo, Tumor Immunology Unit- Department PROMISE, Palermo, Italy

Background

Endometriosis is a debilitating gynaecological condition defined by the implantation of endometrial tissue in ectopic places and the manifestations of severe and usually associated persistent inflammation resulting in pain, organ dysfunction, and infertility. The complete surgical removal of endometriosis lesions can improve both pain symptoms and fertility outcomes, with the primary therapy goal being the removal of all visible lesions. The main goal of this study was to investigate the presence and distribution of PARP-1, EpCAM, and FR α to identify a potential target for image-guided surgery in endometriosis. As these three markers appear to have promising potential for targeted intraoperative imaging of endometriosis, we investigated their expression as both intensity signals and topographic distribution within endometriosis foci, comparing them with surrounding tissues.

Methods

Tissue samples from 11 consecutive patients were selected from a prospective database created by the IRCCS Burlo Garofolo, comprising specimens from patients who had undergone surgery for endometriosis. Immunohistochemical analysis for PARP-1, EpCAM, and FR α expression was carried out on FFPE human tissue sections. Ad-hoc image analysis tools were used to perform quantitative analyses of single and/or multiplex signals to evaluate the signal within the focus of endometriosis and the surrounding tissue.

Results

Qualitative analysis based on observation of the lesions in their tissue environment allowed appreciation of the contrast defined by PARP-1, EpCAM, and FR α . Surrounding tissues had lower levels of markers' expression, with higher levels of PARP-1 where there was a more robust immune response.

Conclusions

In this study is presented evidence, by means of immunohistochemical analysis, that in endometriotic lesions PARP-1, EpCAM and FR α are overexpressed compared to the surrounding tissue. This might be a starting point to revise the standard surgical approach of endometriosis, considering the chance of using intraoperative molecular imaging as a detection tool to increase specificity in delineation of endometriotic lesions during surgery.

ES32-0336 - P*002
Selected Posters

Use of alcohol - iodine solution as treatment alternative in sclerotherapy of ovarian endometrioma

Ketevan Tabutsadze¹, Ivane Mgaloblishvili¹, Anton Mgaloblishvili¹, Phatima Mgaloblishvili¹
¹Tbilisi Central Hospital, Minimally Invasive Gynecology Center - Gynneo, Tbilisi, Georgia

Background

organ-preserving treatment procedures in reproductive medicine is particularly important to ensure future fertility of the women. in this regard, removal of ovarian endometrioma using transvaginal ultrasound guided aspiration followed by sclerotherapy is an effective minimally invasive method. sclerotherapy allows aspiration and coagulation of the cyst with a sclerosing substance that is harmless to the health of patients, does not decrease ovarian reserve and is performed on an outpatient setting. the main matter of concern is to define which sclerosing agent is most effective.

Methods

after precise, fine-needle, transvaginal ultrasound guided aspiration drainage of the cyst, injection of the sclerotic agent was performed. in total 72 aspirations of cyst content were performed, as a result procedure was conducted in 64 women of reproductive age. size of endometriomas that were included in the study varied between 25mm - 40mm. ultrasound control was performed on ge, volusion e10.

after the aspiration, in 36 endometriomas 95% alcohol solution was injected, dwell time - 10 minutes. the volume of the injectable alcohol was defined as 80% of aspirated amount and in other 36 endometriomas we injected combined 95% alcohol - iodine solution with the proportion $\frac{1}{4}$ iodine and $\frac{3}{4}$ alcohol, after 10 minutes' solution was removed from cyst cavity.

Results

In our review 72 endometriomas were included. characteristics were compared between the two groups. in the first group 36 case of endometrial cysts underwent sclerotherapy with 95% alcohol solution and in the second group 36 cases of endometriomas underwent sclerotherapy with 95% alcohol - iodine solution with the proportion $\frac{1}{4}$ iodine and $\frac{3}{4}$ alcohol. after 4 month, ultrasound follow up revealed recurrent endometriomas in 4 cases who underwent alcohol only sclerotherapy and 1 recurrent endometrioma in case who underwent sclerotherapy with alcohol iodine solution

Conclusions

Conducted study showed a better result of sclerotherapy using alcohol - iodine solution. this method is simple, effective and safe alternative to surgical intervention for treatment of ovarian endometriomas. It is necessary to continue research for more accurate data.

Management of complete hydatidiform mole by TruClear[®]: case report and literature review

Armel Daenen¹, Sophie Schoenen¹, Katty Delbecque², Frederic Goffin¹, Florence Hanocq¹, Patricia Nervo¹

¹*Université de Liège, Gynécologie-Obstétrique, Liège, Belgium*

²*Université de Liège, Anatomopathologie, Liège, Belgium*

Background

Gestational trophoblastic diseases include a spectrum of rare placental pathologies ranging from benign fertilization anomalies (hydatidiform moles) to malignant lesions called gestational trophoblastic neoplasia (GTN). The diagnosis of post-molar GTN is based on FIGO biological criteria or on histological diagnostic. Tumours are classified in low- and high-risk according to the FIGO/WHO risk score. Gold standard treatment of low-risk diseases is single agent chemotherapy, whereas high-risk diseases are treated by multiagent chemotherapy. Curative effect of the second curettage for post-molar GTN has been described to avoid chemotherapy, especially when the hCG level is lower than 5000 IU/L. Hysteroscopy resection is not a standard treatment of GTN. The emergence of new mechanical energy (TRUCLEAR System[®]) allows outpatient hysteroscopic treatment without the use of energy. This technique has never been described in the literature for the management of trophoblastic diseases.

Methods

Description of a case report of complete HM managed by TruClear[®] hysteroscopy in our Gynaecological department of the University Hospital of Liège.

Results

We report the case of an asymptomatic 34-year-old patient with a suspected HM based on the ultrasound features and the human chorionic gonadotrophin (hCG) serum level (220.000 IU/L) at 8 weeks of amenorrhea. Ultrasound-guided suction curettage was performed. Histopathological result confirmed a complete HM. One month later, a post-molar GTN was diagnosed after an hCG level increase of more than 10% on three values recorded over a 2-week duration. After an imaging work-up, a FIGO/WHO risk score of 1 was attributed. Ultrasound evaluation showed no vascularization of the uterine trophoblastic retention. Two therapeutic managements were proposed to the patient: either the initiation of single agent chemotherapy by methotrexate, or the endometrial resection by TruClear[®]. The patient chose the second option. The procedure was realized in the operating room given the risk of haemorrhage. The histopathological result confirmed a complete HM retention. Monitoring of hCG levels showed a normalization within the three weeks after the procedure.

Conclusions

We report for the first time in the literature the case of a low-risk GTN treated by TruClear[®] hysteroscopic resection. This hysteroscopic technique seems to be a safe new approach for the management of low-risk GTN patients with fertility desire.

ES32-0500 - P*004
Selected Posters

Engraftment of self-renewal endometrial epithelial organoids promotes endometrial regeneration through differentiating into functional glands in rats

Yana Ma¹, Mengying Liu¹, Jingjing Qian¹, Xin Xu¹, Sijia Chen¹, Xiaona Lin¹

¹Run Run Shaw Hospital- Zhejiang University School of Medicine, Obstetrics and Gynecology, Hangzhou, China

Background

Serious endometrial trauma leading to disruption of endometrial regeneration thereby affects the embryo implantation. The newly emerging endometrial epithelial organoids (EEOs) and the widely used bone marrow mesenchymal stem cells (BMSCs) have been demonstrated to play a role in the regeneration and repair of the endometrium. In this study, we aimed to compare the effectiveness of EEOs and two-dimensional (2D) cultured BMSCs in repairing injured endometrium and to further investigate the endometrial repair mechanism of EEOs.

Methods

SD rats with endometrial injury were divided into Injury group, Matrigel group, BMSCs group and EEOs group according to different treatments. The uterine horns were collected at 7, 14 and 28 days after transplantation to assess the endometrial repair in each group, respectively. The fertility tests were conducted at 28 days after transplantation. Then, the GFP-labeled EEOs and RFP-labeled BMSCs were introduced and transplanted into the injured uterine respectively, the fate of transplanted cells was traced.

Results

We found that the transplantation of EEOs and BMSCs, respectively, could promote epithelial regeneration, neovascularization, restore the hormonal responsiveness of endometrium and ultimately improve fertility. Notably, the recovery of endometrium in the EEOs group was superior to the BMSCs group. Amazingly, we observed that the presence of multiple GFP-labeled cells from EEOs in the recipient endometrium and were able to form larger clones in the epithelial crypt gradually, eventually differentiate into functional endometrial glands. By contrast, no RFP-labeled cells were observed in the recipient rat uterus.

Conclusions

Transplantation of EEOs contributed more to the morphological and functional recovery of severe endometrial injury compared to BMSCs. Moreover, we concluded that cells from EEOs can restore damaged endometrium through differentiating into functional glandular epithelial cell. Our findings imply that in vitro expansion and transplantation of EEOs may be a promising option for restoring fertility in women with insufficient endometrial regeneration.

ES32-0253 - P*007
Selected Posters

Comparison of cosmetic results of transcutan polyglecaprone 25 3-0 and polyglactin 910 3-0 sutures skin incision in gynaecological laparoscopy cases: prospective randomized controlled study

Nasuh Utku Doğan¹, Selen Dogan¹, Zivar Eldarova¹
¹Akdeniz University, Gynecology, Antalya, Turkey

Background

Two suture materials, Polyglactin 910 and Polyglecaprone 25, frequently used for closure of skin incisions in gynecological laparoscopy cases, were compared in terms of wound healing parameters and cosmetic result for abdominal trocae closures.

Methods

Between March 2022 and July 2022, 137 patients aged 18-60 years, scheduled for laparoscopic surgery in the Department of Obstetrics and Gynecology of Akdeniz University Hospital, who underwent lower abdominal port Access were included. The patients were randomized into two groups of sutures. The patients were controlled in 7-12 days and 3 months after the operation with respect to wound healing, cosmetic results and wound complications with Cosmetic VAS score and HWES score.

Results

The mean age of the patients who completed the 3-month follow-up was 41.7 years, and the mean BMI was 26.3kg/m². The mean wound length was calculated as 6 mm. In third month, control, Cosmetic VAS score (p=0.697) and HWES score (p=0.369) were statistically similar in Polyglecaprone 25 and Polyglactin 910 groups. Hyperpigmented scar formation was higher in patients in the Polyglactin 910 group than in the patients in the Polyglecaprone 25 group (70.4% vs 44.7%; p=0.009). There was a trend towards more swelling in the Polyglactin 910 group (9.3% vs. 2.1%; p=0.211). No discharge or dehiscence was observed in the Polyglecaprone 25 group. In contrast, dehiscence was observed in 1 patient and wound discharge was observed in 3 patients in the Polyglactin 910 group. In addition, at the first control, hyperemia was observed at the wound site of 54 patients, 24 in the Polyglecaprone 25 and 30 in the Polyglactin 910 group. In the 3rd month control, wound sites in both groups were closed and there was no dehiscence, discharge, and hyperemia at any wound site. In addition, 24 patients, 8 in the Polyglecaprone 25 and 16 in the Polyglactin 910 group, had hyperemia at the wound site. Pain scores in both controls were similar between the two groups. Use of Polyglactin 910 independently increased the risk of developing hyperpigmentation in the postoperative period (OR: 2.626; 95% CI: 1.093-6.307; p=0.031).

Conclusions

Use of Polyglactin 910 caused more wound complications in the postoperative period and was associated with worse cosmetic results.

ES32-0418 - P*008
Best Selected ePosters

Clinical characteristics of hemorrhage-related post-partum hysterectomies: a retrospective focus on adenomyosis patients

Matteo Giorgi¹

¹*University of Siena- AOUS,*

Department of Molecular and Developmental Medicine- Obstetrics and Gynecological Clinic, Siena, Italy

Background

Post-partum haemorrhage (PPH) represents the most frequent cause of maternal death worldwide among peripartum complications. Major obstetrical complications such as placenta praevia spectrum disease, intrauterine growth restriction and preeclampsia are known to be related to adenomyosis.

Recently, association between PPH, post-partum hysterectomy and adenomyosis have been investigated, with non-conclusive data.

Methods

Multicentric retrospective case-control study. Patients underwent peri- or post-partum hysterectomy due to uncontrollable bleeding between January 2010 and November 2022 in three tertiary referral centers for endometriosis and adenomyosis were included in the study. Medical records were retrieved from respective institutional electronic databases. Peri- or postpartum hysterectomy performed due to other causes rather than PPH were excluded. According to WHO criteria, diagnosis of PPH was defined as a blood loss ≥ 500 ml after a spontaneous delivery, and a blood loss ≥ 1000 ml after a C-section.

The case group included patients with an histological diagnosis of adenomyosis; the control group included uteri without adenomyosis on pathological exam.

Primary outcome of the study was to evaluate the prevalence of adenomyosis among uteri specimen of patients who undergone peri- or postpartum hysterectomy due to uncontrollable bleeding.

Secondary outcome was to compare the prevalence of clinical and obstetrical characteristics, and postpartum complications in the adenomyosis group versus patients without adenomyosis.

Results

Fifty-one patients were included in the study, 22 (43.1%) of which were affected by adenomyosis and 29 (56.9%) without signs of adenomyosis at pathological examination.

Among the investigated clinical characteristics, the adenomyotic group had a lower fetal birth weight (2331.9 ± 642.8 vs 3093.2 ± 679.8 of non-adenomyosis uteri, $p < 0.001$).

Adenomyosis patients had a higher rate of urgent Caesarean section than control group (86.7% vs 41.7%, $p < 0.05$).

Gestational hypertension, pre-eclampsia and intrauterine growth restriction rates were significantly different among the two groups, with the adenomyosis group raising up to 45.5% of the patients (vs 17.2%, $p < 0.05$). Women affected by adenomyosis had also longer hospitalization time (14.5 ± 6.1 vs 10.5 ± 7.4 , $p < 0.05$). Placental diseases including placenta praevia and placenta accrete spectrum disorders were more frequently associated to the non-adenomyosis group (40.9% for adenomyosis patients vs 72.4% for healthy uteri, $p < 0.05$).

Conclusions

Our retrospective analysis demonstrates that adenomyosis is related not only to pregnancy comorbidities but also to postpartum complications. Early pre-conceptual ultrasound diagnosis of adenomyosis may lead to a tailored management of the pregnancy in this group of patients.

However, further larger multicentric studies are needed to confirm our data.

Qualified nutrition professionals and their importance in endometriosis management - a systematic review

Saima Farooq¹

¹Pooler Hospital Dorset, United Kingdom, Obstetrics and Gynaecology, Poole, United Kingdom

Background

Endometriosis is a painful condition where tissue like the uterus lining grows outside the womb, affecting millions of women worldwide. The success rate of medical and surgical treatment for endometriosis is limited.

Empowering patients suffering from endometriosis by giving them opportunities to positively influence their symptoms could result in increased quality of life. Changing diet is one of these self-management activities, but current endometriosis diets are mostly based on limited evidence.

To date, the role of qualified nutrition professionals in endometriosis care and in the literature has yet to be well-defined.

Aim of this study is to conduct a review of the literature (both quantitative and qualitative) to clarify the role of dietitians in endometriosis management for symptom control, fertility and recurrence of the disease.

Methods

PubMed and the Cochrane Database of Systematic Reviews were searched for relevant articles up to 1st February 2023. Search terms included endometriosis, Dietitians availability, diet, and 20 possible nutrients were identified after assessing available endometriosis diets in the literature. Records identified through data base searching were n= 111. Records after duplicate removed 102. Records screened were 102. Full text articles assessed for eligibility were 52. Full text articles excluded were 50. Five studies were included in analysis.

Results

1. Low FODMAP Diet: Six weeks of low FODMAP diet initiated with one-to-one consultation with a dietitian and reviewed afterwards to evaluate efficacy on abdominal symptoms. 75% of those with endometriosis and Irritable Bowel Syndrome experienced an improvement of 50% or more of their abdominal symptoms.
2. Low Nickel Diet: Alimentary nickel (Ni) may result in allergic contact mucositis (ACM), whose prevalence is >30% and may present with IBS-like and extra-intestinal symptoms. These symptoms are also frequent in endometriosis. Therefore, intestinal, and extra-intestinal symptoms in endometriosis may depend on a Ni ACM, and a low-Ni diet could improve symptoms. Low nickel dietary approach led by Nutrition specialist for 3-6 months with twice weekly follow up had statistically significant reduction in gastrointestinal, extra-intestinal and gynaecological symptoms.
3. Mediterranean Diet: The Mediterranean diet has proved capable of decreasing markers of inflammation. Unfortunately, there is no published data yet regarding role of Dietitian using Mediterranean diet for the management of endometriosis.

Conclusions

Overall, among studies included in analysis, only 5% were Dietitian-led interventions and in 95% no nutrition specialist was involved. Despite the significant under-representation and utilization of dietitians in nutrition research for endometriosis management. Qualitative and other quantitative data highlights the importance of a qualified nutrition professional in the multidisciplinary team and the impact that diet and nutrition can have for those living with endometriosis.

Future studies are necessary to gain evidence about which food products are effective and in which amounts and also utilization of dietitians in nutrition research for endometriosis management.

ES32-0421 - P*010
Selected Posters

The use of an enhance gynaecology recovery programme to improve the patient experience and promote the development of junior trainees counselling skills

Colm Coyne¹, Shaun McGowan², Michael Graham¹

¹Belfast Health and Social Care Trust, Gynaecology, Belfast, United Kingdom

²Belfast Health and Social Care Trust, Gynaecologyb, Belfast, United Kingdom

Background

The patient experience does not only encompass a good outcome with their surgery. It also includes the time leading up to their surgery and the post-operative period. Often patient complaints are focus on lack of knowledge about their surgery and their post operative recovery. Our aim is to guide trainees in the counselling of patients in the outpatient setting and to sign post them to key issues that affect the patients recovery.

Methods

A patient survey was undertaken to understand the key issues that affect patients in their journey to their surgery. This information was then used to develop patient information documents that inform them of key issues prior to their surgery such as lifestyle interventions and what would occur during their surgery and the post operative period.

A gynae recovery checklist was developed that would allow patients to track their progress and prompt junior trainees to focus on the key recovery issues.

Results

Patient feedback has indicated that the heightened level of information allowed patients to feel more in charge of their recovery and provided key information about the post operative period. This has led to increased levels of patient satisfaction.

Conclusions

With the long waiting times that patients are experiencing for surgery it is clear that involving patients in the pre-operative and post-operative period has led to increased patient satisfaction. Using this method of counselling has also allowed junior trainees to develop their counselling skills in the outpatient setting,

Medical and conservative management of deep pelvic endometriosis: an observational study on outcomes and regression of disease

Nisreen Fahmy¹, Maria-Cristina Talarico¹, Tom Setchell¹, Tariq Miskry¹
¹Imperial College Healthcare NHS Trust, St Mary's Hospital, London, United Kingdom

Background

Deep pelvic endometriosis (DPE) presents significant surgical challenges, and, as well as being associated with significant intra-operative complications, can result in both short and long-term morbidity, particularly in relation to ureteric and bowel dissection. Over the last 20 years, the aim of treatment has been complete excision of disease, which might include bowel resection. Medical management has largely been ignored, perhaps due to concerns regarding disease progression, despite small studies showing promising results. More recently, the default surgical approach has been questioned, not least because of the significant recurrence rate, and in view of this an RCT comparing surgical and medical treatment outcomes is currently ongoing.

At our unit, we have historically used medical management as our first line treatment option, particularly as the relationship between pain and endometriosis is complex. We report outcomes from our centre, which demonstrate that medical management is not only effective at providing symptom control but can also result in disease regression.

Methods

Patients discussed at our tertiary centre Endometriosis MDT between 2018 and 2021 were included. Options for management from the MDT were noted and patients were followed up to monitor for response to their chosen treatment, be it conservative, medical or surgical. Interval imaging was compared to the index imaging to monitor disease burden. Exclusion criteria included patients with evidence of ureteric stricture, or bowel obstruction.

Results

Of 270 patients discussed at the MDT 66% were found to have deep pelvic endometriosis on imaging review. Almost two thirds of our patients opted for medical or conservative treatment (45% medical, 15% conservative) whilst a third chose surgical intervention. 62% of patients who had medical management had stable disease at interval imaging, with a median imaging follow up of 18months. 20% of patients had reduction in disease. 7.5% had disease progression although most were due to a small increase in size of the endometriomas. Only one patient was found to have an increase in the size of a posterior endometriotic nodule on repeat MRI. Medical treatment comprised hormonal therapies in the majority of cases.

Conclusions

Medical management of endometriosis is a safe and effective alternative to surgery for patients with DPE, who have no current fertility desires. As well as providing symptom control, we have shown that it can also be associated with a reduction in disease burden. Most importantly, our data strongly suggests that we can reassure our patients that, in the absence of ureteric stenosis or bowel obstruction, the aim of treatment should be determined by symptoms rather than the presence of disease. Further investigation is needed regarding the optimum form of medical management although this is likely to remain patient dependant.

Bipolar coagulation during cystectomy as a harmful factor for the ovarian reserve-prospective study on patients undergoing laparoscopic surgery due to ovarian tumors or cysts

Rafal Moszynski¹, Marta Moszynska², Stefan Sajdak³

¹Poznan University of Medical Sciences, Division of Gynecological Surgery, Poznan, Poland

²Poznan University of Medical Sciences, Student Scientific Society, Poznan, Poland

³Poznan University of Medical Sciences,

Division of Gynecological Surgery- Department of Gynecology- Obstetrics- and Gynecological Oncology, Poznan, Poland

Background

Background: Laparoscopic ovarian cystectomy is considered a gold standard among therapeutic methods of treating ovarian cysts or tumours, which are a common and significant problem in gynaecology. Surgical removal is mostly used. There is proved, that any surgical intervention relative to the ovaries or uterus can affect the ovarian reserve, which is an indicator of the quality and quantity of ovarian follicles. During abovesaid gynaecological interventions, one of the methods of achieving haemostasis is bipolar coagulation, which has a depicted harmful impact on the ovarian reserve. The anti-Müllerian hormone (AMH) is reported as the most adequate ovarian reserve marker and the most verifiable time to measure it is 6 months postoperatively. The aim of this study was to investigate the impact of bipolar coagulation on the ovarian reserve in patients undergoing laparoscopic surgery due to ovarian tumours or cysts.

Methods

Methods: A clinical prospective trial was conducted in the Gynecological Surgery Department of Poznan University of Medical Sciences in Poland between March 2018 and March 2022. The study included 19 patients suffering from one-sided, benign tumours or ovarian cysts. These patients were qualified for laparoscopic tumour enucleation, in which bipolar coagulation was used. The ovarian reserve was analysed by the level of AMH 1-3 days before the surgery and about (+/- 7 days) 6 months after. The surgeries were performed by the same experienced gynaecologist. After the enucleation of the tumour, bipolar coagulation was applied only until the haemostasis was achieved.

Results

Results: The study showed that bipolar coagulation treatment has a statistically significant impact on patients and causes a decrease in AMH level compared to the preoperative assessment, which was from 3,34 (+/- 2,02) to 2,51 (+/- 1,39); (p = 0.049). Among patients, there were different histopathological diagnoses: endometrial cysts, adult teratomas, serous cysts, and haemorrhagic cysts. The study also demonstrated that, patients with endometrial cysts had a statistically significantly higher baseline level of AMH than the other groups.

Conclusions

Conclusion: Bipolar coagulation as a haemostatic method during laparoscopic ovarian cystectomy has a reducing influence on the AMH level, thereby decreasing ovarian reserve. It should be considered every time before the surgery, primarily among young women with reproductive plans.

Comparison between vaginal and laparoscopic cerclage in women with mid-trimester pregnancy loss or history of spontaneous preterm delivery

Pierandrea De Benedetti¹, Elisa Montaguti², Benedetta Orsini¹, Diego Raimondo³, Gianluigi Pilu², Renato Seracchioli³

¹Division of Gynecology and Human Reproduction Physiopathology- IRCCS Azienda Ospedaliero-Universitaria di Bologna- Bologna- Italy,

Department of Medical and Surgical Sciences- DIMEC- University of Bologna- Bologna- Italy, Bologna, Italy

²IRCCS Azienda Ospedaliero-Universitaria di Bologna- Bologna- Italy, Obstetric Unit, Bologna, Italy

³IRCCS Azienda Ospedaliero-Universitaria di Bologna- Bologna- Italy,

Division of Gynecology and Human Reproduction Physiopathology, Bologna, Italy

Background

Preterm birth affects about 7% of pregnancies and is a major cause of neonatal mortality and morbidity. One of the main risk factors is cervical insufficiency. Women with unfavourable obstetric history (mid-trimester pregnancy loss or history of spontaneous preterm delivery) are at higher risk of recurrent preterm birth and can benefit from prophylactic cerclage ("history indicated"), which can be performed vaginally or transabdominally with laparoscopic techniques. The transabdominal technique, due to its greater invasiveness, has so far been reserved for patients with previous failure of a vaginal cerclage, in case of congenital cervical hypoplasia or in patients with extensive amputations of the cervix after oncological procedures. The aim of our study is to evaluate and compare the effectiveness in preterm birth prevention of the vaginal technique (VC) and of the minimally invasive laparoscopic technique (TAC-LPS) in women with an unfavourable obstetric history.

Methods

This was a single centre retrospective cohort study examining elective cerclages performed from 2010 to 2020 in women with adverse obstetrics history. Patients were divided in two groups according to the surgical technique adopted (vaginal vs laparoscopic cerclage). The primary outcome was the rate of early preterm (between 24 and 33rd weeks of pregnancy) and second trimester (between 14 and 23 weeks) deliveries while other outcomes analysed were surgical complications, the time needed for cerclage procedures, live birth rate, gestational age at delivery, birth weight, Apgar score.

Results

Data from 64 women were analysed; among them, 14 underwent a laparoscopic procedure (22%) while 50 a vaginal cerclage (78%). The two groups were homogeneous in terms of demographic characteristics (age, BMI and ethnicity), but of course differed significantly in terms of obstetrics history, as well as for the surgical indications of cerclage procedures. The rate of early preterm deliveries and second trimester miscarriage was the same in the vaginal and laparoscopic group (8%), comparable to what was reported in literature. Considering the pregnancies that reached the epoch of foetal viability, the gestational period at delivery was comparable between VC and TAC-LPS groups (38 vs 37 weeks, p=0.080). The operative time was longer in the laparoscopic group (50 vs 20 minutes, p=0.001), but with similar duration of the hospital stay (1 vs 1 day, p=0.813). No intraoperative complications were reported in both groups.

Conclusions

As the laparoscopic procedure, usually reserved for women with a previous failed vaginal cerclage, has been proved to be equally safe and effective compared to the vaginal one, it could be proposed to a wider group of women. Prospective randomized studies are needed to provide new and conclusive data about this topic.

Pressurized IntraPeritoneal Aerosol Chemotherapy (PIPAC) applied to platinum-resistant recurrence of ovarian tumor: a single-institution experience (ID: PARROT trial)

Giuseppe Vizzielli¹, Maria Teresa Giudice², Barbara Costantini², Frediano Socrate Inzani³, Anna Fagotti², Scambia Giovanni²

¹*Santa Maria della Misericordia University Hospital - Azienda Sanitaria Universitaria Friuli Centrale, Clinic of Obstetrics and Gynecology, Udine, Italy*

²*Fondazione Policlinico Universitario Agostino Gemelli- IRCCS, Department of Woman and Child Health and Public Health, Rome, Italy*

³*University of Pavia, Anatomic Pathology Unit- Department of Molecular Medicine, Pavia, Italy*

Background

Pressurized intraperitoneal aerosol chemotherapy (PIPAC) combines the benefits of a minimally invasive approach (easier repeat application, lower morbidity, shorter hospital stay) with the pharmacokinetic advantages of intraperitoneal administration (higher intratumoral concentrations, less systemic toxicity) under pressurized vaporization (increased distribution and deeper penetration).

Primary endpoint is to investigate the safety of PIPAC in women with platinum-resistant recurrence of ovarian cancer and assess the peritoneal carcinomatosis according to Peritoneal Regression Grading (PRG) classification. Secondary endpoint is to determine the Quality Of Life (QOL) on the basis of European Organization for Research and Treatment of Cancer (EORTC) QOL questionnaire (QLQ-C30).

Methods

Women affected by first or second platinum-resistant recurrence of epithelial ovarian tumour, with an Eastern Cooperative Oncology Group (ECOG)-performance status ≤ 3 , after 1 or 2 previous regimens of chemotherapy, were prospectively recruited in our clinical trial. We obtained a written informed consent from each patient. In this open-label, single-arm phase 2 trial, patients underwent courses q28-42 days of PIPAC with doxorubicin 1.5 mg/m² followed by cisplatin 7.5 mg/m² via sequential laparoscopy. Capnoperitoneum with a positive pressure of 12 mm Hg was applied for 30 min/course at a temperature of 37 °C.

Results

98 PIPAC procedures were performed for 43 women (median age 58.5 years) from 2016 to 2020; we were not able to perform the procedure in three patients due to extensive intra-abdominal adhesions. Most of the patients (83.7%) were affected by serous carcinoma, 4 women were affected by clear cells cancers and only one by mucinous carcinoma. Three cycles of PIPAC were completed in 18 women (45%), 13 (32.5%) and 9 (22.5%) patients were subjected respectively to one and two cycles. During two procedures (2%) patients experienced an intraoperative intestinal perforation. The median of Fagotti's score was 10 (range, 8 – 12), and ascites was reported in 13 patients (30.2%).

The median length of hospital stay was 2 days (range, 1-10 days). Early postoperative complications were documented during 8 procedures (8.1%). According to Memorial Sloan Kettering Cancer Center surgical grading system, G2 complications occurred in 6 patients, including 2 patients with bowel obstruction that was managed with intra venous therapy, 1 case of anaemia, 2 patients with systemic infections and one with abdominal collection that required antibiotic therapy. There were two patients with intestinal perforation requiring operative laparotomy. There were no treatment-related deaths.

Partial pathological response and stable pathological response, according to PRG classification were observed in the 46% and 54% of women, respectively. EORTC QLQ-30 scores referring to global physical health scores, nausea/vomiting, appetite loss, diarrhea, and constipation didn't worsen during therapy.

Conclusions

Preliminary data suggest that PIPAC therapy is an effective and feasible approach for treatment of patients with platinum-resistant recurrence of ovarian cancer. Furthermore, PIPAC does not seem detrimental on QoL.

Genetic polymorphisms associated with endometriosis: a systematic review and meta-analysis

Mickey Buckingham¹, Imogen Barratt², Katherine Northall³, Suruchi Pandey¹

¹*St George's Hospital, Gynaecology, London, United Kingdom*

²*St George's Hospital, Obstetrics and Gynaecology, London, United Kingdom*

³*St George's- University of London, Medicine, London, United Kingdom*

Background

50% of risk of developing endometriosis is owed to genetics. Identification of patients with these risk factors allows earlier diagnosis and intervention. This systematic review and meta-analysis aims to analyse genetic polymorphisms associated with endometriosis.

Methods

We searched the MEDLINE and Embase databases for publications from January 2006 until October 2021. We only included case-control studies where endometriosis was confirmed on laparoscopy and controls had absence of endometriosis confirmed by scan or surgery. Genes were categorised according to their function. Random-effects meta-analysis was performed on the four most frequently reported genes in the categories of detoxification, immune system and hormone pathway.

Results

Our search produced 1814 abstracts, each of which were screened by two assessors. 729 full-text papers were reviewed. 322 studies met the criteria for inclusion of which 40 were selected for meta-analysis. A positive association with endometriosis is identified with GSTM1 (null genotype), AHRR rs2292596, IL10 rs1800872, ESR1 rs9340799, with pooled ORs of 1.33 [95% CI 1.06-1.67], I²=58%; 1.84 [95% CI 1.14-2.98], I²= 49%; 3.89 [95% CI 1.01-15.03], I² =94%; 1.47 [95% CI 1.03-2.11], I² =62% respectively. No association is observed with GSTT1, GSTP1, TNF, TGFB1, IL6, CYP17A1 and FSHR polymorphisms.

Conclusions

The genetic risk of endometriosis is attributed to a combination of polymorphisms including those associated with detoxification, immune system and hormone pathway. This should guide future research into development of screening tools and treatments, such as modification of inflammatory response.

NK cells in endometriosis - could basic research open new therapeutic tools?

José Reis¹, Catarina Martins², Miguel Dias², Luís Borrego², Jorge Lima¹
¹Hospital da Luz Lisboa, Ginecologia-Obstetrícia, Lisboa, Portugal
²NOVA Medical School, Immunology, Lisboa, Portugal

Background

Endometriosis is a chronic and debilitating disease, affecting 1 in 10 women of reproductive age. While the aetiology of endometriosis remains to be elucidated, the hypothesis that endometriosis pathogenesis is associated with immune dysfunction, particularly in NK cells, their receptors, and functions, is supported by a growing number of studies. Some works demonstrating the involvement of key molecules at several points of the immune cascade, leading to the compromise of immunocompetency in individuals with endometriosis. The authors intend to characterize the expression of NK receptors in women with endometriosis, to assess their potential clinical application.

Methods

Patients operated for endometriosis and control patients with benign gynaecological conditions were enrolled. All surgeries were laparoscopic. Peripheral blood (PB) and Peritoneal fluid (PF) samples were collected during surgery and analysed by flow cytometry, with CD45, CD3, CD8, CD56, CD57, activating receptors (CD16, CD96), inhibitory receptors (PD-1, KIR2DL1/CD158a, NKG2A, TIGIT, TIM-3, LAG-3, CD161) and cytokine receptor IL18R α . Data analysis was performed with Infinicyt and FlowJo software.

Results

In 35 endometriosis patients and 15 controls assessed, we identified two major NK subsets in the PB: the most abundant CD56^{dim}CD16^{hi} (57-99% in patients; 86-97% in controls), and a less represented CD56^{hi}CD16^{dim}. This more immature subset was significantly increased in patients ($p=0.04$). In PF 4 subsets were identified: the most abundant were CD56^{+/dim}CD16^{hi} (23-87% in patients; 23-73% in controls) and CD56^{hi}CD16⁻ (5-86% in patients; 10-77% in controls), with smaller amounts of CD56^{hi}CD16⁺ and CD56^{dim}CD16⁻ NK cells. Patients showed increased PF CD8⁺CD16^{hi} ($p=0.02$), CD56^{dim}CD16^{dim} ($p=0.01$), CD16⁺CD56 PD-1⁺ ($p=0.01$), CD56^{hi} CD96⁺ ($p=0.01$), CD56CD96⁺ ($p=0.04$), CD158a⁺ NKG2A⁺ ($p=0.01$). In PB patients we found a marked reduction in CD56⁺ CD158a⁺ ($p=0.04$) and in inhibitory receptor CD56TIM-3⁺ ($p=0.01$).

Conclusions

NK profiles are different in the compartments PB and PF. More interesting, we observed significant differences in profiles of endometriosis patients compared to control cases. Further investigation of immune checkpoint protein expression in the context of endometriosis may potentiate the devising of novel therapeutic strategies, adding immunotherapy as a potential targeted therapy.

Asymptomatic endometrial cancer with Lynch syndrome - in a woman with primary infertility, a case report

Nancy Noah¹, Ranitha Kumar¹

¹University Hospital Wishaw, Gynaecology, Glasgow, United Kingdom

Background

Objective – We report a case of asymptomatic endometrial cancer with Lynch syndrome that was accidentally discovered during the workup for primary infertility. This study is the first to highlight the asymptomatic presentation of endometrial cancer in patients with Lynch syndrome.

Methods

Case report – 34-year-old women presented to the infertility clinic at university hospital Monklands, UK with primary infertility for 2 years. During the workup, the transvaginal ultrasound showed a thickened endometrium of 14 mm, saline infusion sonography suggested the possibility of an endometrial polyp. Hysteroscopic polypectomy was performed, and the result revealed a complex endometrial hyperplasia in places amounting to endometroid adenocarcinoma FIGO grade 1. Genetic testing for the biopsy sample showed loss of nuclear staining for MSH6 which is consistent with the diagnosis of Lynch syndrome. Total laparoscopic hysterectomy and bilateral salpingoophrectomy and washing cytology performed. Pathology results were consistent with well differentiated endometroid adenocarcinoma stage 1A and peritoneal cytology showed no malignant cells.

Results

Discussion - In this case the main presentation was infertility, on reviewing literature there was no evidence that Lynch syndrome is associated with infertility. Around 3% of endometrial cancer are hereditarily related to Lynch syndrome. The recent NICE guideline, 2020 recommended screening all patients with endometrial cancer for Lynch syndrome regardless of their age and family history when resources are permitted.

Conclusions

Conclusion – This case represents atypical presentation of Lynch syndrome. Therefore, it is essential to have a systematic approach for managing gynecology patients. A Detailed family history is the key in identifying patients requiring screening for Lynch syndrome.

Postoperative outcomes and sexual quality of life following laparoscopic versus vaginal Natural Orifice Transluminal Endoscopic Surgery (vNOTES) hysterectomy

Stavros Karampelas¹, Dominique A. Badr¹, Sara Engels¹, Georges Salem Wehbe², Deliar Yazdanian Masouleh², Hripsime Hovsepyan³

¹CHU BRUGMANN, Gynecology, Brussels, Belgium

²CHU Brugmann, Gynecology, Laeken, Belgium

³Université libre de Bruxelles, Gynecology, Laeken, Belgium

Background

Hysterectomy is the most frequently performed surgery for benign gynecological pathologies. The surgical technique is a significant factor contributing to the morbidity of this procedure. vNOTES is an innovative approach that aims to combine the advantages of vaginal and laparoscopic surgery. Some studies have shown certain benefits of this new surgical technique. We evaluated and compared the postoperative results, particularly the sexual quality of life of patients treated with vNOTES versus conventional laparoscopy.

Methods

This study is a retrospective monocentric study that analyses and compares the postoperative results and sexual quality life of 141 patients who underwent total hysterectomy for benign conditions between September 2020 and October 2022. Various postoperative outcomes such as operative time, hospital stay, blood loss and postoperative pain were analyzed. The Female Sexual Function Index (FSFI) questionnaire was used to assess the sexual quality of life of 74 sexually active patients. Ethics Committee approval reference number B0772022000153.

Results

Patients who underwent vNOTES had shorter hospital stay and lower postoperative pain compared to those treated with laparoscopy. Chronic pathologies such as adenomyosis or endometriosis did not influence these results. The sexual quality of life in the vNOTES group was superior to the laparoscopy group. The median total FSFI score was 30 for the group vNOTES versus 26.25 for the group Laparoscopy and this difference was statistically significant. Furthermore, this study showed that the vNOTES technique had an adjusted odds ratio of 2.98(95% confidence interval: 1.02-8.67, p-value=0.045) for the absence of female sexual dysfunction. The results in favor of this new technique have been collected since the introduction of this approach to our department and the plateau of our learning curve had not been reached. We estimate that these results could increase the deference between the two groups.

Conclusions

The vNOTES technique demonstrates certain advantages over conventional laparoscopy and remains a safe option for total hysterectomies. Our study provides evidence that the sexual quality of life is not compromised when patients choose this surgical approach. In addition to that it has a lower probability of sexual dysfunction when compared to the Laparoscopic technique.

Lost and found in laparoscopic surgery

Mohamed SALAMA¹, Elakhras Sayed², Mohamed Abdel-Ghany³, Vasilios Tanos⁴

¹Ain Shams University, Obstetrics and Gynaecology, Cairo, Egypt

²Omam Hospital, O&G and Minimally-invasive Surgery, Cairo, Egypt

³Omam Hospital, Obstetrics and Gynaecology, Cairo, Egypt

⁴University of Nicosia Medical School, Obstetrics and Gynaecology, Nicosia, Cyprus

Background

Various foreign bodies are occasionally encountered during open or laparoscopic surgery. These may include surgical "leftovers", such as surgical needles, un-absorbed threads, towels, gauze, metal or plastic clips, or even strangers finds as we will report.

These may be inert, and cause no symptoms, or alternatively may cause immediate, intermediate or delayed complications.

Methods

We report a collection of very interesting and bizarre "lost and found" items that we have come across during laparoscopic surgery over many years of practice.

Results

Many unusual finds are displayed in this presentation. There seems to be various scenarios and reasons why such weird objects are left behind during various interventions.

These items may be just inert, lying in the pelvis in peace, or else may be a trigger for severe omental and peritoneal reactions.

Conclusions

A multitude of items could be lost or overlooked during laparoscopic or open surgical interventions. Meticulous attention to the surgical tools used during any intervention, along with towel and instrument counting and checks at the end of the procedures is essential.

Vague unexplained complaints or findings should prompt search for possible such "losts"

Practice of laparoscopic prolapse surgery in Europe – ESGE survey

Benjamin Lambert¹, Laurent de Landsheere¹, Günter K Noé², Rajesh Devassy³, Helder Ferreira⁴, Jean Dubuisson⁵

¹CHR Citadelle- Service de gynécologie - obstétrique, Service de gynécologie - obstétrique, Liège, Belgium

²University of Witten-Herdercke, Department of Obstetrics and Gynecology, Dormagen, Germany

³Dubai London Clinic and Speciality Hospital, Department of Obstetrics and Gynecology, Dubai, United Arab Emirates

⁴Unit of Centro Hospitalar Universitário do Porto,

Department of Minimally Invasive Surgery Unit of Centro Hospitalar Universitário do Porto, Porto, Portugal

⁵University Hospitals of Geneva, Department of Obstetrics and Gynecology, Geneva, Switzerland

Background

Sacrocolpopexy is considered as the “gold standard” for management of women with apical prolapse. Numerous technical variants are being practiced. Because of the recent events related to transvaginal mesh banning in Europe, laparoscopic management of pelvic organ prolapse (POP) has developed. Alternative techniques such as pectopexy or lateral suspension (LS) allow the management of POP in case of anatomical variations. First study aim is to determine the habits of practice of laparoscopic sacrocolpopexy (LSCP) in Europe. The second study aim is to determine whether surgeons who perform laparoscopic POP repair are familiar with the practice of alternative techniques and with mesh-less laparoscopic treatment of prolapse.

Methods

The questionnaire has been designed by the Urogynaecology Special Interest Group of the ESGE. All the ESGE members were invited by email to respond to this survey consisting in 54 questions divided in different categories: demographics, surgeon characteristics, concomitant surgery (hysterectomy, stress urinary incontinence) and characteristics of surgery. Finally, surgeons were questioned about attitude towards practice of pectopexy, lateral suspension and laparoscopic native tissue repair.

Results

Regarding the ESGE member's responses, we have highlighted great heterogeneity concerning the practice of LSCP, variation in following recommendations and important variability in performance of concomitant surgeries. Alternative techniques are currently little used in practice.

Conclusions

In lights of the results of the survey, we note a lack of standardization of many surgical steps of LSCP. In the current literature, there is a lack of overwhelming evidence of all of the surgical steps leading to no possibility of standardized recommendations. Furthermore, we recognize that the treatment of POP patients is usually an individualized approach depending on anatomy and presenting symptoms. In order to be efficient in every situation, there is a need to spread alternative techniques (LS, pectopexy and native tissue repair), which are currently still not widely used. In the same time, large randomized clinical trials evaluating any of these alternative techniques should be conducted to compare functional and anatomical results to the gold standard sacrocolpopexy.

The use of hysteroscopic guidance to facilitate resection of a uterocutaneous fistula: a case report

Georges Salem Wehbe¹, Mohammed Bennani², Deliar Yazdanian Masouleh¹, Sara Engels¹, Evy Gillet¹, Stavros Karampelas¹

¹CHU Brugmann - Université Libre de Bruxelles, Gynecology and Obstetrics, Brussels, Belgium

²Université Libre de Bruxelles, Gynecology and Obstetrics, Brussels, Belgium

Background

Uterocutaneous Fistula (UCF), which represents a pathologic communication between the uterine cavity and the skin surface, is a rare clinical entity. Although the etiology of UCF is still not clear, it has been mainly reported after delivery by cesarean section, uterine infection and surgeries such as dilatation and curettage and myomectomy. Post-operative complications have been also reported as predisposing factors for UCF. Herein we share our experience regarding an unconventional and successful surgical management of a complicated UCF using hysteroscopic guidance for the identification of the fistulous tract.

Methods

A case report of a patient with UCF managed in a tertiary care center.

Results

A 28-year-old lady, G2P1, seeking medical advice for chronic purulent discharge coming out from the middle of a midline sub-umbilical laparotomy scar. Five years prior to presentation, she underwent dilatation and curettage complicated by uterine perforation and followed by emergency laparotomy few days later. Another laparotomy was done one year later for textiloma removal. Abdomino-pelvic imaging showed an 8.5 cm fistulous tract between the uterine fundus and the abdominal Linea Alba and parietal skin. Exploratory laparotomy and fistulectomy were proposed and accepted by the patient. A diagnostic hysteroscopy was performed immediately before incision. It clearly showed an abnormal fundal orifice through which a double J stent has been gently inserted. The stent reached the abdominal wall and exited it through the cutaneous orifice. Thus, the fistulous tract was successfully identified and cannulated. The operation started by an elliptic incision resecting completely the fibrous skin around the fistulous orifice. An extensive parietal, intestinal and omental adhesiolysis were performed around the previously recognized fistulous tract, until reaching the uterine fundus. After dissection and isolation of the cannulated fistulous tract, a complete and safe fistulectomy was done up to the endometrial orifice of the fistula. The operation was completed by a two-layer myometrial suture at the site of the resection.

Conclusions

There is a lack of clear management guidelines for UCF and optimal treatment strategies are still not clear due to the rarity of this clinical entity. The diagnosis of UCF often implies surgical challenges with great risk of inadvertent organ injury. This case report demonstrates how advanced skills in minimally invasive surgery might serve the gynaecologic surgeon to safely solve surgical challenges and avoid complications even in the context of classic open surgery.

Impact of uterine weight and shape on vNOTES hysterectomy

Yannick Hurni¹, Colin Simonson¹, Daniela Huber²

¹Hôpital du Valais, Obstetrics and Gynecology, Sion, Switzerland

²Hôpital du Valais, Gynecology and Obstetrics, Sion, Switzerland

Background

The present study assessed the feasibility and safety of performing vNOTES hysterectomy for large uteri, comparing perioperative outcomes for different uterine weights and shapes.

Methods

We analyzed patients who underwent a vNOTES hysterectomy, with or without adnexal procedures, for benign conditions between May 2020 and April 2023. We excluded patients with concurrent perineal or intrabdominal procedures and those with gynecological malignancies. Patients were divided into 4 subgroups depending on uterus weight and shape. Uteri weighing < 280 g were classified as *Type 0*, while uteri of ≥ 280 g were categorized following the "Large Uterus Classification System" described by Uccella et al. in uterus *Type 1* (adnexal vascular pedicles and uterine vessels approximately at a normal level), *Type 2* (adnexal vascular pedicles cranially displaced, but with uterine vessels at a normal level), and *Type 3* (displaced uterine vessels with or without displaced adnexal vascular pedicles). The primary outcome was the composite of all perioperative complications, including intraoperative complications, the need to convert to conventional laparoscopy or laparotomy, and postoperative complications.

Results

We analysed data from 213 patients who presented a uterus *Type 0* in 153 cases (71.8%), *Type 1* in 27 cases (12.7%), *Type 2* in 21 cases (9.9%), and *Type 3* in 12 cases (6.5%). We observed no demographic differences. The mean uterine weight was 136.0 ± 60.7 (min-max: 36 – 277) g, 405.1 ± 179.1 (280 – 980) g, 616.5 ± 230.0 (311 – 1150) g, and 629.3 ± 267.6 (310 – 1200) g in uterus *Type 0*, *1*, *2*, and *3*, respectively. Operative time increased proportionally with uterus weight ($\rho = 0.270$, p-value < .05). Although not significant, operative time in uterus *Type 0* (66.7 ± 31.7) and *Type 1* (67.4 ± 25.5) appeared shorter than in uterus *Type 2* (101.2 ± 64.0) and *Type 3* (114.0 ± 41.8). We observed no significant difference in the composite of all perioperative complications and their subparts. The conversion rate to conventional laparoscopy was 1.3%, 0%, 4.8%, and 8.3% in uterus *Type 0*, *1*, *2*, and *3*, respectively. There was no conversion to laparotomy. Iatrogenic bladder injury was observed in 7 patients (4.6%) with uterus *Type 0*, while no intraoperative complications were observed in other groups. The postoperative complication rate was 2.6%, 3.7%, 9.5%, and 8.3% in uterus *Type 0*, *1*, *2*, and *3*, respectively. Vaginal cuff hematoma and wound infection were most frequently observed. We observed no difference in postoperative pain and length of stay.

Conclusions

We demonstrated the feasibility and safety of performing vNOTES hysterectomy for large uteri weighing even more than 1 Kg, independently from their shape. However, operative time increased proportionally with uterus weight. In addition, although not significant, large uteri *Types 2* and *3* could be associated with longer operative time, a higher conversion rate to conventional laparoscopy, and a higher postoperative complication rate.

ES32-0575 - P*023
Selected Posters

Caesarean scar endometriosis - clinical negligence or preventable complication: a case series and review of literature

Nazima Parveen¹, Alexander Oboh¹, Christian Kremer¹

¹The Mid Yorkshire Teaching NHS trust, Obstetrics and Gynaecology, Wakefield, United Kingdom

Background

Caesarean section (CS) scar endometriosis causes debilitating pain and suffering and is characterised by inflammation due to presence and growth of endometrial tissue outside uterine cavity. The prevalence is rare and reported between 0.03% - 0.5%. While the pathophysiology of endometriosis includes trans coelomic spread, transplanted by retrograde menstruation, or metaplasia, iatrogenic implantation at surgery appears to be most likely cause of CS scar endometriosis. This makes it a complication of CS birth, arguably clinical negligence which obstetricians need to be aware of.

Methods

We reviewed three cases, which were referred to our regional endometriosis centre at Mid Yorkshire Teaching NHS Trust between 2020-2023.

Results

All three cases had history of previous caesarean sections and presented with cyclical pain and gradually increasing tender nodule over caesarean scar. Patients were further investigated with Ultrasound /MRI scan which confirmed subcutaneous cystic lesion suggestive of endometriosis. One of the patients had negative diagnostic laparoscopy, and both had surgical excision of CS scar nodule proven on histology to be endometriosis. Patients had uneventful recovery and complete resolution of symptoms after surgical excision. Third patient with large lesion measuring 6.7 cm on MRI involving rectus abdominis muscle, is currently awaiting joint procedure with Plastics, General surgery and Gynaecology.

Conclusions

CS Scar endometriosis can cause significant morbidity affecting quality of life. It is a potentially avoidable condition and growing recognition as negligent complication of surgery. In addition to current recommendations of changing surgical gloves following uterine closure, we propose use of 'Alexis O C-Section retractor' at all caesarean section to reduce implantation of endometrial tissue into the wound.

Short neonatal treatment of female mice pups with tamoxifen induces severe adenomyosis in adult mice

Julie Vervier¹, Marlyne Squatrito², Michelle Nisolle¹, Carine Munaut²

¹University of Liège, Obstetrics and Gynecology, Liège, Belgium

²University of Liège, Laboratory of Tumor and Development Biology- Giga-Cancer, Liège, Belgium

Background

Spontaneous adenomyosis occurs in several animal species such as in CD1 mice. However, the natural occurrence of the disease is usually after 6 months of age and in a small percentage of the population. Inducing disease in laboratory animals allows to maximize efficiency in terms of number of mice affected and cost-effectiveness, but also more precise manipulation of experimental design and greater consistency of disease conditions.

Methods

Female neonatal mice were orally dosed via capillary tubing on day 2 to 5 after birth (day of birth is day 1) for 4 days consecutively with 2.7 μmol/kg tamoxifen in peanut oil/lecithin/condensed milk mixture (2:0.2:3 v/v) at a dose volume of 5 μl/g body weight. The mice were sacrificed at three months age and the diagnostic and grading of adenomyosis were performed by histological examination of hematoxylin-eosin staining section.

Results

Between January 2022 and May 2023, a total of 132 pups were treated (68 treated with tamoxifen – 64 with vehicle only). All were sacrificed at 3 months age. Histological analysis of our series showed that 97% of the tamoxifen treated mice developed the disease. In this same group, only two mice did not develop adenomyosis. The grading method was defined by assessing depth of lesions: two mice developed grade 1 adenomyosis (lesions up to the inner third of the myometrium), seven mice developed grade 2 adenomyosis (lesions up to the two third of the myometrium), and 57 developed grade 3 adenomyosis (lesions over two third of the myometrium). None of the control mice developed adenomyosis.

Conclusions

Among the available models, neonatal treatment of CD1 mice with tamoxifen, a selective oestrogen receptor modulator, reliably produces severe adenomyotic lesions in a high proportion of three months old mice. Since adenomyosis is often associated with endometriosis and/or uterine fibroids, using an experimental model will exclude bias of associated comorbidities and represent a unique opportunity for understanding the molecular basis of adenomyosis. It can also provide a translational analysis when compared with clinical studies.

Investigating the efficacy of combined cystoscopy and laparoscopy partial cystectomy

Yu Kawasaki¹, Shiori Takeuchi¹, Yukiko Okada¹, Keisuke Murakami¹, Mari Kitade¹, Atsuo Itakura¹
¹*Juntendo University Graduate School of Medicine, Department of Obstetrics and Gynecology, Tokyo, Japan*

Background

Patient age, childbearing desire, lesion site, symptoms, and other factors determine the bladder endometriosis treatment plan. A cure and postoperative bladder function considerations are essential when choosing surgical treatment. Retrospective surgical outcomes and treatment prognoses were evaluated using our laparoscopic removal technique in six cases of bladder endometriosis.

Methods

Bladder endometriosis originates and develops from the serosal side and often adheres to the vesicouterine pouch. Intraoperative observation alone makes determining surgical margins difficult. Combining cystoscopy and laparoscopy allows accurate lesion observation and complete resection. The surgical procedure comprises perivesicouterine pouch adhesion dissection, needle-and-suture-thread traction over the tumor area using the fishing method, cystoscopic monitoring of bladder endometriosis detachment from surrounding tissues, and bladder muscle layer incision and removal. The first bladder muscle layer is closed using interrupted 2-0 absorbable thread sutures. Running sutures are used to close the second layer and vesicouterine pouch peritoneum. An indwelling urinary catheter is inserted for one week post-operatively. The patient is discharged after cystography confirms no bladder leakage into the abdominal cavity.

Results

No perioperative complications were reported. Four patients received hormonal therapy to prevent postoperative recurrence. No postoperative recurrence or relapse symptoms were observed. Intraoperative cystoscope use facilitates lesion boundary identification and urethral orifice location. Furthermore, the fishing method accurately recognized dissection lines, avoiding residual lesions, hydronephrosis, and suture failure.

Conclusions

Combined cystoscopy and laparoscopic partial bladder resection for bladder endometriosis was considered an aggressive treatment method. However, this study demonstrates improved surgical outcomes and treatment prognosis in six patients with bladder endometriosis. Although a small sample size may limit these findings, larger study samples are needed to evaluate this improved efficacy.

Laparoscopic treatment of deep endometriosis affecting urinary tract; our surgical outcomes on large study group

Michael Fanta¹, Kvetoslav Novák², Michal Pešp, Lucia Hudeková¹, Zdenka Lisá¹, Kristýna Hlinecká¹

*¹1st Faculty of Medicine of Charles University and General University Hospital,
Dept. Of Gynecology and Obstetrics, Prague, Czech Republic*

*²1st Faculty of Medicine of Charles University and General University Hospital, Dept. Of Urology, Prague,
Czech Republic*

Background

Deep endometriosis (DE) affecting urinary tract presents 1-2% of women with endometriosis. Possible consequences can be very serious especially in ureter's affection leading to hydronephrosis and finally to loss of organ and usually underestimated cardiovascular risks as well. The aim of our analysis is to report laparoscopic management and long-term outcome with possible late consequences of the disease.

Methods

Retrospective evaluation of prospective follow-up of 113 women underwent surgery for DE affecting urinary tract.

Results

From 113 subjects of our study group surgically treated for DE affecting urinary tract in 56 women bladder, in 64 ureter were affected (in 7 cases combination of both organs was found). In patients with bladder endometriosis bladder resection, in ureter's affection advanced ureterolysis, ureter resection with anastomosis (ureterorrhaphy) or ureterocystoneoanastomosis (UCNA) was performed. In our study group is a large proportion of patients (n=8) underwent unilateral nephrectomy for complete loss of kidney fuction showing the problem of late diagnosis. In 10 cases bilateral affection has occurred. Overall postoperative outcomes are favourable with no complications in bladder resection. Recurrent surgery in three cases of patients with ureteral affection- once for hematuria 2 years after ureteral resection and anastomosis, once for restenosis after ureteral resection and anastomosis UCNA was performed, in third case 6years after resection and anastomosis ureterolysis was needed. In 8 cases arterial hypertension of renal etiology was diagnosed. Assymetry of the kidneys with reduced renal parenchyma on affected side has occurred in 7 cases in a long time period of follow-up.

Conclusions

Surgical outcomes of urinary tract endometriosis are generally satisfactory, but it should be early diagnosed before loss of kidney fuction or cardiovascular complications development (arterial hypertension) in case of ureter's affection. Adequate follow-up optimally by nephrologists skilled in doppler evaluation of renal function is important after surgery as well because of possible long-term impact of the disease on suffered kidney. Supported by grant of General University Hospital, project GIP-23-L-03-223.

Is inguinal endometriosis an uncommon localisation of deep infiltrating endometriosis? The usefulness of laparoscopic surgery

Catalin Bogdan Coroleuca¹, Andrei Manu², Ciprian Andrei Coroleuca¹, Diana Elena Comandasu¹, Alexandra Bausic¹, Elvira Bratila¹

¹Clinical Hospital of Obstetrics and Gynaecology "Prof. Dr. Panait Sârbu"- University of Medicine and Pharmacy "Carol Davila"- Bucharest- Romania, Obstetrics and Gynaecology, Bucharest, Romania

²Clinical Hospital of Obstetrics & Gynecology "Prof. Dr. Panait Sarbu"- Bucharest- Romania, Obstetrics & Gynecology, Bucharest, Romania

Background

Endometriosis is defined as the presence of endometrial glands and stroma outside the endometrial cavity and uterine musculature. Most common sites of endometriosis are within the pelvis, while unusual locations include bladder, intestine, surgical scars, diaphragm, umbilicus, and groin. Inguinal endometriosis is a rare presentation of extra-pelvic endometriosis that typically appears as a small-sized, tender and fixed inguinal mass. More specifically, the lesions can be found in the extraperitoneal portion of the round ligament, in the inguinal lymph nodes, in the subcutaneous adipose tissue, and even in the wall of sacs of inguinal or femoral hernias. Several challenges, including coexisting extensive endometriosis, minimal understanding of the long-term recurrence and consequences, as well as initial management by general surgeons, make this rare presentation of endometriosis an uncommon disease for gynecologists.

Methods

The aim of the paper is to raise awareness regarding inguinal endometriosis and the importance of laparoscopic usefulness in these cases. We present a series of 3 cases of patients diagnosed with deep infiltrating endometriosis with inguinal involvement which were managed by laparoscopic approach.

Results

All 3 cases presented with dysmenorrhea, dyspareunia and chronic pelvic pain that irradiated to the hip. At the physical examination in 2 cases, it was revealed an inguinal tender mass. In all the cases Magnetic resonance imaging was done and showed right inguinal masses and deep infiltrating endometriosis of the parametrium, ovaries, rectosigmoid or adenomyosis. Complete laparoscopic excision of the endometriotic lesions was done in each case. Rectal endometriosis was found in all 3 cases, so a segmental laparoscopic resection was done. In two cases the complete excision of the round ligament was done. After excision, in two cases we spread a mesh to cover the hernia gate. Recurrences are rare after adequate surgical treatment – we had no recurrence at 6 and 1 year postoperative.

Conclusions

Clinicians should not underscore the importance of a carefully taken history and physical examination, an increased recognition of this disease entity and a high index of suspicion in coming up with a correct diagnosis. Inguinal endometriosis requires a multidisciplinary approach guided by a multi-specialty team that can effectively manage all possible outcomes. Therefore, awareness of the full spectrum of the disease can facilitate communication between teams.

The role of bariatric surgery in fertility-sparing treatments for endometrial cancer

Mario Palumbo¹, Alessandra Gallo¹, Rossella D'Alisa², Serena Guerra¹, Maria Chiara De Angelis¹, Brunella Zizolfi²

¹University of Naples Federico II, Department of Public Health, Naples, Italy

²Sapienza University of Rome, Department of Maternal and Child Health and Urological Sciences, Rome, Italy

Background

Fertility-sparing treatment is a priority for young women with Endometrial Carcinoma (EC) who wish to preserve their reproductive potential. Several evidence indicate a strong relationship between weight and EC and the effect of weight loss on reducing the risk of EC. We report the case of a young obese women undergone "combined" fertility-sparing treatment for EC and achieved complete remission only after significant weight loss through bariatric surgery.

Methods

33-year-old women with a Body Mass Index (BMI) of 46.6 kg/m², had been diagnosed with atypical endometrial hyperplasia (AEH) at another centre by a blind curettage; absence of myometrial invasion and absence of pelvic or para-aortic lymph nodes and distant metastases had been detected with magnetic resonance imaging. She desired fertility-sparing management, so a fertility-sparing approach was performed using the combined technique consisting of hysteroscopic tumor resection followed by Levonorgestrel-Intra-Uterine System (LNG-IUS) insertion. Using an endo uterine Tissue Removal Device (TRD) with an outer sheath of 6.15 mm, a resection of the endometrium, which appeared diffusely thickened and hyper vascularized with pseudo polypoid areas, whitish colour, atypical vascularization and vascular densification, was performed under loco-regional anaesthesia. After surgery, a 52 mg LNG-IUS was inserted. Histology revealed intramucous G2 endometrioid EC, and the patient agreed to continue conservative treatment, having been informed of the absence of solid evidence on the efficacy and safety of fertility-sparing treatment in G2 EC.

Results

Multiple hysteroscopic endometrial biopsies performed at 3, 6 and 9 months-follow-up revealed only partial response with regression to endometrial hyperplasia with moderate atypia, despite additional therapy with GnRH analogues. She was then referred to the Bariatric Surgery unit, a sleeve gastrectomy was performed and two months after surgery she lost 30kg. 3 months after surgery and 15 months after combined treatment of EC, complete remission was achieved and maintained after another 6 months of follow up. Hysteroscopic appearance showed a macroscopically normal endometrium, and histologic study revealed progestin therapy-induced stromal decidualization.

Conclusions

To our knowledge, this is the first case of an obese patient undergoing fertility-sparing combined treatment for G2-EC and concomitant bariatric surgery. Previous literature suggests that surgical weight loss may be considered as adjuvant therapy in the fertility-sparing treatment of EC, with the goal of improving oncologic outcomes, in terms of increasing remission rates and reducing recurrence. In addition, it could be considered strategic for improving reproductive outcomes, especially given that achieving pregnancy is a major goal for women who choose fertility-sparing treatments. This evidence should encourage new prospective studies confirming the potential and positive effects of bariatric surgery in women affected by EC.

Surgical treatment of patients with early cervical carcinoma (Figo 1A1) by performing da-Vinci assisted sentinel node biopsy, abdominal cerclage insertion and vaginal trachelectomy

Hannes Frenz¹, Maximilian Klar¹, Ingolf Juhasz-Böss¹

¹Universitätsklinikum Freiburg, Klinik für Frauenheilkunde, Freiburg i.Br., Germany

Background

Holistic, fertility-preserving treatment for patients with early cervical cancer optimizes mental health protection and family planning. For young, childless women, the diagnosis of cervical carcinoma is associated with particular psychological distress [1]. In case of pregnancy taking place, the risk of preterm delivery increases if trachelectomy is performed [2]. The insertion of a transabdominal cerclage minimizes the risk of preterm birth without minimizing the success rate of natural conception [3].

Methods

We report a patient who presented to our clinic with a diagnosis of early cervical carcinoma (FIGO 1A1) after successful LEEP conization for original CIN III and adenocarcinoma in situ. The patient could not imagine vaginal delivery as her mode of delivery. Together with the patient, planning and complication-free performance of a da-Vinci assisted sentinel node biopsy (pN0(0/2)), abdominal cerclage placement, and trachelectomy took place with a prospective desire to have a child.

Results

Subsequently, the patient presented to our clinic with an intact pregnancy.

Conclusions

We are currently managing the pregnancy together with our colleagues in private practice and are pleased to report on the da Vinci assisted surgical procedure and the course of the pregnancy at the ESGE 32nd Annual Congress.

1. Herzog TJ, Wright JD. The impact of cervical cancer on quality of life—The components and means for management. *Gynecol Oncol.* 2007;107:572–7.
2. Bernardini M, Barrett J, Seaward G, Covens A. Pregnancy outcomes in patients after radical trachelectomy. *Am J Obstet Gynecol.* 2003;189:1378–82.
3. Marchand G, Taher Masoud A, Azadi A, Govindan M, Ware K, King A, et al. Efficacy of laparoscopic and trans-abdominal cerclage (TAC) in patients with cervical insufficiency: A systematic review and meta-analysis. *European Journal of Obstetrics & Gynecology and Reproductive Biology.* 2022;270:111–25.

Laparoscopic psychomotor skills proficiency of Filipino medical doctors in- training in a tertiary hospital

Maria Mikaela Comendador¹, Renee Vina Sicam², Ursula Catena³, Vasilios Tanos⁴, Rudy Leon De Wilde⁵

¹*Makati Medical Center, Obstetrics and Gynecology Department, Makati City, Philippines*

²*Makati Medical Center, Obstetrics and Gynecology, Makati City, Philippines*

³*Fondazione Policlinico Universitario A. Gemelli IRCCS. Rome - Italy,
Department Woman and Child Health and Public Health, Rome, Italy*

⁴*University of Nicosia Medical School, Obstetrics and Gynaecology, Nicosia, Cyprus*

⁵*University Hospital for Gynecology, Obstetrics and Gynecology, Oldenburg, Germany*

Background

The current trend in gynaecologic surgery is minimally invasive surgery due to its faster patient recovery, shorter hospital stays, decreased blood loss, lower infection rate, cost-effectiveness, and increased patient satisfaction. One of the tasks of a gynaecological surgeon is to acquire the knowledges to perform “the perfect hysterectomy”. Hysterectomies have multiple approaches such as vaginal, abdominal, or laparoscopic. These numerous techniques give both the surgeon and the patient the chance to plan the most beneficial and optimal approach to surgery. However, this creates the challenge of producing competent, well-trained physicians with modern surgical skills. The conventional teaching of laparoscopic surgery in many academic centres is the apprentice/mentor model but this is highly subjective and hardly reproducible. In the last decades, the acquisition of the correct psychomotor skills in a training lab, has become mandatory for young surgeons before entering the operating rooms to train the surgical skills. For this reason, the European Society for Gynaecological Endoscopy (ESGE) proposed a well-structured educational programme for Gynaecological Endoscopy, named GESEA (Gynaecological Endoscopic Surgical Education and Assessment) programme. The programme proposes a validated practical test, named LASTT (Laparoscopic Skills Training and Testing method), to measure the competence level of an individual in basic laparoscopic psychomotor skills.

Methods

To describe the pilot implementation of the LASTT method in medical internship students and surgical residents of Makati Medical Center (Manila, Philippines). Descriptive cross-sectional research design was used in the study. 19 medical internship students and 15 surgical residents (34 mentees in total) were included in the study. The basic information of all the participants involved (age, gender, hospital department, years of training, number of previous surgical procedures as assistant, exposure to hands-on activities, hand dominance) were collected. Assessment of the three LASTT exercises (Camera Navigation, Hand-Eye Coordination, and Bi-manual Coordination) were obtained for all participants.

Results

The majority of study participants were right-handed (30; 88.24%). There were only 4 (11.76%) study participants who were left-handed. Surgical residents showed a significantly shorter time to accomplish “camera navigation” exercise over medical internship students (84.05±19.34 vs. 105.92±11.81 respectively, 95% CI 21.87 [3.48-40.24] p .023 < .05). Similarly, surgical residents had significantly shorter time to accomplish “hand-eye coordination” exercise over their medical internship students’ counterparts (106.78±11.85 vs. 135.62±32.47 respectively, 95% CI 27.84 [9.56-46.13] p .004 < .05). Time to accomplish “bimanual coordination” exercise was statistically shorter among surgical residents than medical internship students (116.80±25.67 vs. 144.83±27.68 respectively, 95% CI 28.03 [7.30-48.77] p .010 < .05).

Conclusions

Surgical residents were found to be significantly superior to medical internship students in terms of laparoscopic psychomotor skills. This finding supports the concept that hands-on training and exposure to laparoscopic procedures improve the proficiency of medical professionals.

Multielemental profile of peritoneal fluid in endometriosis patients

Andrea López Botella¹, Raquel Sánchez², José Luis Todolí Torró², María José Gómez Torres³, Irene Velasco¹, Maribel Acién¹

¹*Service of Obstetrics and Gynecology, Unit of Human Reproduction- FISABIO—San Juan University Hospital, Alicante, Spain*

²*University of Alicante, Department of Analytical Chemistry Nutrition and Food Sciences, Alicante, Spain*

³*University of Alicante, Biotechnology Department, Alicante, Spain*

Background

Endometriosis is a chronic gynaecological disease affecting 10-15% of women in reproductive age. This disease causes chronic pain and is associated to infertility in 40% of the cases. Some studies have reported that environmental contaminants, as potentially toxic metal elements (PTMEs), are related to the endometriosis disease. The aim of this study was to compare the multielemental profile of peritoneal fluid (PF) between endometriosis and non-endometriosis patients.

Methods

Samples of PF were collected from 12 endometriosis patients and 12 non-endometriosis patients during a surgical procedure in the operating room. Ethics Committee approval was given by the Institutional Review Board of Hospital Universitario San Juan de Alicante (Committee protocol code: 19/344, date of approval: December 17th, 2019). An Agilent 8900 ICP-MS/MS (Agilent Technologies, Santa Clara, CA, USA) was used to analyse the randomized and double-blinded selected PF samples. The method was previously validated, achieving good recoveries ($\pm 10\%$). The quantified analytes

were: ¹³⁷Ba, ²⁰⁹Bi, ¹¹¹Cd, ⁵⁹Co, ⁵²Cr, ⁶³Cu, ⁵⁶Fe, ¹³⁹La, ⁷Li, ⁵⁵Mn, ⁹⁵Mo, ⁶⁰Ni, ²⁰⁸Pb, ⁸⁵Rb, ¹¹⁸Sn, ⁸⁸Sr, ⁵¹V, and ⁶⁸Zn.

Results

Concerning the elemental profile of PF, Cd and Co were quantified in just 4 and 3 patients from the endometriosis group, respectively. Mn, Li, Ni, Pb, Ba, Rb, Fe and Zn levels were higher in the PF of the endometriosis group. Other elements as V, Cr, Cu, and Sr were found in similar amounts in both groups. Finally, La and Bi were found in higher concentrations in the control group, being quantified in 7 and 3 patients respectively. According to the habits survey, there is no cause of occupational exposure or smoking habits in any patient to justify these levels. So, environmental exposure from unknown sources may be related to these results.

Conclusions

The preliminary results of our study show that some PTMEs as Cd and Pb are found in higher concentrations in the PF of women with endometriosis. Overall, this report reveals new insights regarding new potential biomarkers for endometriosis diagnosis and prognosis although additional research is needed to confirm these differences.

Laparoscopic multiple intestinal resection in patients with bowel deep infiltrating endometriosis

Andrei Manu¹, Catalin Bogdan Coroleuca², Ciprian Andrei Coroleuca², Rubin Munteanu³, Elvira Bratila²

¹Clinical Hospital of Obstetrics and Gynaecology "Prof. Dr. Panait Sârbu"-Bucharest- Romania, Obstetrics and Gynecology, Bucharest, Romania

²Clinical Hospital of Obstetrics and Gynaecology "Prof. Dr. Panait Sârbu"- University of Medicine and Pharmacy "Carol Davila"- Bucharest- Romania, Obstetrics and Gynecology, Bucharest, Romania

³Memorial Hospital, General Surgery, Bucharest, Romania

Background

Endometriosis occurs during the active reproductive period. It is estimated that up to 15% of all women of reproductive age have endometriosis. About one-third of infertile women suffer from endometriosis. Endometriosis affects the bowel in 3%-37% of all cases, and in 90% of these cases the rectum or sigmoid colon are also involved. The small bowel is involved in 2-16% of the cases, the appendix in 3-18% and caecum in 2-5%. The ileum is affected in 4% of women with bowel endometriosis frequently associated with rectosigmoid lesions. There is no high-precision imaging test for ileal endometriosis. Diagnosis of ileal endometriosis is usually made incidentally during surgery for other endometriosis sites or following direct complications of ileal involvement. At laparoscopy, typical ileal lesions are nodular in shape with transmural and endophytic growth and are often located on the ileocecal junction.

Methods

This study aimed to determine the laparoscopical management of multiple intestinal deep infiltrating endometriotic lesions which affects the rectosigmoid and the small bowel. We describe our surgical technique on how we managed the cases. This is a retrospective review of all patients who underwent laparoscopic bowel resection.

Results

214 patients underwent laparoscopic rectosigmoid resection with end to end anastomosis and from these 27 patients (12.55%) required a small bowel resection and/or appendectomy with side to side anastomosis. 55% (118) patients had a rectal endometriotic nodule classifiable as C3 (3 or more than 3 cm) and 26.63% as C2. Beside the rectal nodule, at laparoscopic inspection of the small intestine we had found in 10.74% cases an endometriotic nodule in the distal ileum and or ileocecal junction and in 5.14% appendiceal endometriosis. All patients were treated laparoscopically and the specimen was externalized by umbilical incision. After removal of the pelvic lesions, mobilization of the rectosigmoid and of the caecum and distal ileum was done and the affected bowel was resected. There were no conversions to laparotomy. There were no intraoperative complications, we had no anastomotic leakage, and no protective stoma was needed.

Conclusions

There is still a discussion about the optimal treatment of endometriosis involving the gastrointestinal tract. A standardized preoperative work-up for bowel endometriosis diagnosis is necessary. A multidisciplinary laparoscopic treatment, in an expert centre, should be planned in advance to ensure adequate patient counseling. Laparoscopy is the preferred approach, as it is associated with less postoperative pain and faster recovery.

Reproductive outcomes after operative hysteroscopy for uterine septum: a network meta-analysis

Dimitrios Rafail Kalaitzopoulos¹, Maria Zografou Themeli², Georgios Grigoriadis³, Maurizio Nicola D' Alterio⁴, Stefano Angioni⁴, Angelos Daniilidis⁵

¹Cantonal Hospital of Schaffhausen, Department of Obstetrics and Gynecology, Schaffhausen, Switzerland

²Evangelisches Krankenhaus Oberhausen, Department of Obstetrics and Gynecology, Oberhausen, Germany

³Aristotle University of Thessaloniki,

2nd University Department of Obstetrics and Gynecology- Hippokration General Hospital, Thessaloniki, Greece

⁴University of Cagliari, Department of Obstetrics and Gynecology, Monserrato- Cagliari, Italy

⁵Aristotle University of Thessaloniki,

1st University Department of Obstetrics and Gynecology- Papageorgiou General Hospital, Thessaloniki, Greece

Background

Septate uterus is a congenital malformation associated with adverse reproductive, pregnancy, and obstetrical outcomes. Although hysteroscopic metroplasty is recommended for treating septate uterus, it is unclear which method has the most favorable outcomes. The aim of this study is to conduct a network meta-analysis of studies comparing different hysteroscopic methods for treating uterine septum and their outcomes.

Methods

This systematic review and meta-analysis were conducted following PRISMA guidelines. Medline, Scopus, and Cochrane databases were searched up to April 2023, without language restrictions. Eligible studies must compare two or more different methods of hysteroscopic septoplasty in women with septate uterus and report on reproductive outcomes after a follow-up. Outcomes included fertility outcomes, pregnancy outcomes, and operative outcomes. Data were extracted by two independent reviewers using a standardized form, and the risk of bias was assessed using the Newcastle-Ottawa Quality Assessment Form and Revised Cochrane risk-of-bias tool.

Results

From 561 studies identified, 9 were included in the analysis. The comparison of different hysteroscopic septoplasty techniques according to the energy used showed higher pregnancy rates after mechanical septoplasty in comparison to electrosurgery, while miscarriage and live birth rates were comparable. Laser versus electrosurgery and mechanical techniques of septoplasty had comparable pregnancy, miscarriage and live birth rates. The network meta-analysis after comparing every different method used showed significantly higher clinical pregnancy rate in scissor group in comparison to resectoscope. As far as miscarriage rate and live birth rate is concerned no differences found between different techniques compared.

Conclusions

In summary, the systematic review and network meta-analysis conducted suggest that hysteroscopic septoplasty with scissors is associated with higher pregnancy rates compared to resectoscope. However, the limited evidence available and small sample sizes in the included studies indicate that these findings should be interpreted with caution. Future studies are required to determine the effectiveness of various hysteroscopic techniques and guide clinical decision-making in the management of this condition.

Adenomyosis impacts ovarian reserve and fertility outcomes in a murine model.

Marlyne Squatrito¹, Julie Vervier², Marie Timmermans², Michelle Nisolle², Laurie Henry², Carine Munaut¹

¹Université de Liège, Giga Cancer - Laboratoire de Biologie des Tumeurs et du Développement, Liège, Belgium

²Hôpital de la Citadelle, Department of Obstetrics and Gynecology, Liège, Belgium

Background

Adenomyosis is a benign uterine disorder characterized by the presence of heterotopic endometrial glands and stroma in the myometrium. Since adenomyosis was first thought to affect older women and diagnosed during histological examination of the uterus after hysterectomy, the association with infertility has not been studied in women of childbearing age. However, several recent studies have demonstrated that the presence of adenomyosis in young women may impair the fertility by altering endometrial function and receptivity. Adenomyosis also seems to have a detrimental impact on the results of in vitro fertilization although a confounding effect of associated endometriosis cannot be excluded. To date, fertility in women with adenomyosis without endometriosis has not been assessed.

Methods

To achieve fertility outcome analysis, we used a murine model of adenomyosis that consists in orally dosing CD1 mice from their first day of life for 4 consecutive days with tamoxifen (1mg/kg) (n=48) or vehicle control (n=39). Estrous cycle was analyzed at two months of age by performing vaginal smears during 14 days in all mice. Some mice were euthanized at 3 months old (n=14, control and n=14, adenomyosis-induced mice). Adenomyosis diagnosis was confirmed by histological analysis of uterus sections. Folliculogenesis was assessed on several ovarian sections and steroids hormones were quantified in blood. Some other mice (n=6, control and n=6, adenomyosis-induced mice) were mated with fertile proven males for the next three months to evaluate fertility outcomes.

Results

Estrous cycle of mice suffering from adenomyosis displayed disturbances. Indeed, tamoxifen-treated mice remained for a longer period in estrus and a shorter period in diestrus as compared to control mice. Since disturbances of estrus cyclicity could be related to ovarian dysfunction, we further performed analysis of all recovered ovaries and confirmed that folliculogenesis was different between adenomyosis-induced mice and control mice. An enhance follicle activation was observed in adenomyosis-ovaries indicating that fertility outcomes could be affected. Indeed, after fertility assessment by mating experiments, a decreased numbers of successive litters and number of pups/litter were found in mice affected by adenomyosis.

Conclusions

In mice treated perinatally with tamoxifen to induce adenomyosis, irregular estrous cycles as well as defects in ovarian function are observed. These disturbances are potentially responsible for the fertility outcomes observed. To go further in the understanding of the infertility associated with adenomyosis, without any confounding impact of endometriosis, we will focus next our research on characterization of the endometrial receptivity and the uterine immune environment necessary for a successful embryo implantation.

The role of out-patient hysteroscopy in the post-partum assessment and management of abnormally invasive placenta

Hema Nosib¹, Erika Manzo¹, Ciara Mackenzie¹

¹Hinchingbrooke Hospital- North West Anglia Foundation Trust, Gynaecology, Huntingdon, United Kingdom

Background

Abnormally Invasive Placenta (AIP) encompasses a spectrum of disorders from a small discrete area of focal placenta accrete to the invasion of the adjacent pelvic structures seen in placenta percreta. AIP is increasing in prevalence and gynaecologists are increasingly called upon by obstetrics colleagues to assist in the management of these complex cases intra and post-partum. This case demonstrates how helpful expert ambulatory gynaecological assessment is in guiding management and providing follow-up.

Methods

37-year-old patient presented with continuous vaginal bleeding and intermittent pain five weeks following her first caesarean section. No previous uterine surgery or risk factors for AIP. On examination uterus bulky, cervical os open but no heavy bleeding or retained products of conception seen. Mildly elevated inflammatory markers but clinically stable. Operation notes reviewed and caesarean complicated by massive obstetric haemorrhage of 3.2 litres secondary to adherent placenta which was removed piecemeal. Urgent assessment in ambulatory gynaecology with transvaginal ultrasound (TVUSS) confirmed retained products of conception (5x2cm) adherent to the uterine wall. Immediate out-patient hysteroscopy revealed blood and placental tissue within the uterine cavity. High suspicion of AIP therefore outpatient hysteroscopic resection of placental tissue not performed. Urgent multi-disciplinary team (MDT) discussion with tertiary centre conducted.

Results

With retained adherent placental tissue in-situ ongoing risk of infection or major haemorrhage. Management options considered by MDT included hysteroscopic resection under general anaesthesia, methotrexate, uterine artery embolization or conservative management. As patient clinically stable and family not complete consensus to manage conservatively with strict safety-netting. Repeat TVUSS two weeks later showed no reduction in size of placental tissue but increased calcification. Magnetic Resonance Imaging (MRI) seven weeks post-partum showed 4.7 x 3.7cm residual placenta at the fundus infiltrating the myometrium. As patient clinically stable and bleeding settled MDT decision to continue to manage conservatively. Repeat TVUSS and hysteroscopy six months post-partum confirmed 1x1.5cm placenta not breaching the cavity of the uterus. A further MRI showed a very small area at the fundus which did not require intervention.

Conclusions

The combination of ultrasound, hysteroscopy and MRI is necessary to fully assess the extent and severity of AIP and in the close follow-up of any patients being managed conservatively. Hysterosonography and three-dimensional ultrasound was not utilised in this case but may become more valuable in the future as a more readily available lower cost alternative to MRI. All hysteroscopists must understand the potential major risks of severe haemorrhage and visceral injury if hysteroscopic resection is attempted and manage all cases via a MDT approach. Any women with AIP must be counselled as to the risk of recurrence in future pregnancy.

Team brief online form: enhancing team communication and efficiency in pre-operative team briefings

Amr Magdi Mohamed Moneib¹

¹*Queen Elizabeth Hospital, Gynaecology, London, United Kingdom*

Background

To ensure patient safety and optimize surgical outcomes, teams in contemporary healthcare environments must effectively communicate and share information. The Team Brief Online Form, an innovative digital approach designed and used in this abstract, aims to gather crucial data during pre-operative team briefing sessions. Vital patient information is included on the form, such as the patient's age, BMI, blood type, blood group status, COVID-19 swab findings, and MRSA results. The form also allows for recording positioning plans and particular equipment specifications, such as energy sources and specialized retractor requirements.

Methods

The author developed the Team Brief Online Form to be used as a web-based interface, with input fields tailored to the specific information required during team briefing sessions. The form was designed to be user-friendly and intuitive, ensuring ease of completion by healthcare professionals. The form does not store any data but instead generates printable PDFs that can be emailed within the organization prior to surgical procedures.

Results

The form successfully collected the necessary information, including patient demographics, medical test results, and equipment requirements, with a high level of accuracy and completeness. The generated PDFs were promptly disseminated via email, allowing team members to review the information and prepare adequately before each operation.

Conclusions

The implementation of the Team Brief Online Form can demonstrate significant improvements in team communication, morale, and efficiency within our healthcare organization. By utilizing a standardized digital form, important information can be consistently captured, reducing the likelihood of miscommunication or oversight during team briefing sessions. The ability to share PDF reports in advance allowed team members to familiarize themselves with the details, ensuring a coordinated and well-prepared approach.

Moreover, the use of the online form can streamline the information-gathering process, saving valuable time and minimizing the risk of errors associated with manual data entry. The form's accessibility via a web-based interface enabled convenient completion and submission, enhancing user satisfaction and engagement. Furthermore, the digital nature of the form eliminated the need for physical storage and paper documentation, resulting in cost savings and promoting environmentally friendly practices.

In conclusion, the Team Brief Online Form offers a proof of concept for improving team communication, morale, and operational efficiency during pre-operative team briefing sessions. The positive outcomes observed within our healthcare team underscore the potential benefits of implementing such a solution on a broader scale, fostering enhanced patient safety, optimized surgical outcomes, and resource utilization across healthcare organizations. Further studies are warranted to explore the long-term impact and scalability of this innovative approach.

Gartner's duct cyst endometriosis

Rahul Savant¹, Somendranath Roy²

¹University Hospital of North Tees, Obstetrics and Gynaecology, Stockton-on-Tees, United Kingdom

²North Tees and Hartlepool Hospital, Obs & Gynae, Stockton on Tees, United Kingdom

Background

Case: A 30-year-old women presented with chronic pelvic pain. A vaginal mass was noted in the right fornix.

Investigations:

Trans vaginal ultrasound revealed a right adnexal lesion measuring 5.3x3.6x2.5 cm positioned posterior to the uterus.

MRI showed a subacute/chronic haemorrhagic cyst measuring 3.4 x 1.7 x 3 cm, within the right adnexa. This is well defined and is located within the wall of the right vaginal fornix. There is no communication with the lumen of the vagina. This has benign appearances, and could represent a vaginal mullerian cyst (+/- endometriotic component) or an atypical Gartner's cyst (with inflammation/haemorrhage)

Methods

She underwent laparoscopic drainage of paravaginal cyst and biopsy of the cyst wall and Hysteroscopy. Findings intraoperative.

On examination: Normal sized uterus with a cystic mobile mass in the Right fornix.

Hysteroscopy showed normal appearance apart from the presence of uterine niche.

Laparoscopy: Uterus, ovaries and fallopian tubes were normal.

POD/UV fold, pelvis, uterosacral were normal.

Cystic bulge noted lateral to the cervix, 15 ml of thick brown fluid was aspirated, suggestive of endometriotic or haemorrhagic cyst.

Results

Histology:

The appearances were of benign cyst with differential diagnosis being Gartner duct cyst and Mullerian cyst. Focal endometriosis was present. There was no atypia or malignancy.

Conclusions

Discussion:

Gartner's duct cyst represents mesonephric remnants and complicates diagnostic differentiation by location of the mass as it can be found in the anterolateral vaginal wall at varying depths. Endometriosis in Gartner's duct is a rare occurrence.

Awareness of the dangers of postmenopausal bleeding among Dutch women

Hilde Sluijter¹, Tamara Ouderkerk¹, Marlies Bongers¹, Peggy Geomini¹

¹Maxima Medical Center, Obstetrics and gynaecology, Veldhoven, The Netherlands

Background

Postmenopausal bleeding (PMB) affects approximately ten percent of women at least once in their lifetime. Of these women, ten percent are diagnosed with endometrial cancer. It is therefore advised that women with PMB seek medical consultation for further diagnostics. However, it is unknown how many women are aware of this advice, and how many seek medical consultation.

This study aims to determine how many women would seek medical consultation in case of PMB.

Methods

An online questionnaire was distributed in the Netherlands between January 2023 and April 2023. Women over 40 years old were included in the study. The primary outcome measure is the percentage of women seeking medical consultation for a first episode of PMB.

Results

A total of 1060 women completed the questionnaire. Forty percent of these women were 50 to 59 years old, 27% were 40 to 49 years old, and 26% were 60-69 years old. Seventy percent of these women were highly educated (college or university).

Results showed that 30% of women who experienced a first episode of PMB would seek medical consultation. Fifty-one percent of women would wait for recurrent bleeding before acting and 3% would take no action. Sixty-one percent of women would seek medical consultation if they experienced two or three episodes of PMB. Furthermore, 67% of women would be less concerned about PMB if their last cervix smear showed no abnormalities.

A comparison of the different levels of education revealed that the lower educational levels were significantly more likely to seek medical consultation after the first episode of PMB.

Conclusions

Thirty percent of women in the Netherlands would seek medical consultation after a first episode of PMB. Sixty-seven percent of women would be wrongly reassured if their cervix smear was normal. The results may be biased, due to the large number of highly educated women in this study. However, the subgroup analyses show that despite education level, only a small percentage of women seek medical consultation on a first episode of PMB. Therefore, it is imperative to increase awareness of the dangers of PMB.

Expression of extracellular matrix proteins in vaginal fibroblasts from women with pelvic organ prolapse with or without "connective tissue dysplasia" syndrome

Olha Proshchenko¹, Dmytro Govseev¹

¹Bogomolets National Medical University, Department of Obstetrics and Gynecology №1, Kyiv, Ukraine

Background

The term "connective tissue dysplasia" syndrome (CTDS) refers to pathology of connective tissue (CT) caused by point mutations of genes encoding CT synthesis and metabolism, characterised by lifelong manifestations and a variable clinical presentation (spinal deformity, hypermobility of the joints, excessive skin elasticity, cardiovascular manifestations). Pelvic organ prolapse (POP) is characterised by a weakness of the supporting function of the pelvic floor CT. This approach determines the feasibility of finding the relationship between CTDS signs and POP.

Methods

Vaginal tissue samples were taken from 18 patients with POP. Gene expression of proteins of CT were determined by real-time quantitative polymerase chain reaction. The relative abundance of transcripts of the studied genes was normalised by the level of GAPDH expression. Data were calculated using the $2^{-\Delta\Delta CT}$ method. Statistical analysis was performed using the statistical software R (ver. 4.0, r-project.org). Quantitative variables were tested for compliance with the normal distribution law using the Shapiro-Wilk test, as well as for equality of variances between groups using the Levine test. Homoscedasticity of variances was not observed, so a one-factor analysis of variance with Brown-Forsyth corrections was applied. The Games-Howell test was chosen as a post hoc test.

Results

The main group included 11 patients with POP and 2 clinical and anamnestic stigmas of CTDS (high palate, periodontitis, mitral valve prolapse, varicose veins of the lower extremities, scoliosis, flat feet, joint hypermobility) + "small" phenotypic signs of CTDS (reduced skin elasticity, stretch marks, freckles, red hair, etc.). Comparison group consisted of 7 women with POP and without CTDS. The mRNA expression level of CT protein genes is presented in Table 1. A decrease in gene expression was found: collagen type I-alpha-1(COL1A1) (t-value is -1.7; p-value is .044), Fibronectin (t-value is -1.66; p-value is .047.), Elastin (t-value is -1.75. p-value is .04.) and lysyl oxidase (LOX) (t-value is -1.8. p-value is .035) and the absence of difference in the transforming growth factor-beta 1 (TGF-b1) gene in patients with POP and CTDS.

Table 1 Level of mRNA expression of CT protein genes in patients with POP, n=18

	Main group, n=11	Comparison group, n=7
COL1A1	M 0.600	1.8087
	m 0.1058	0.6323
Fibronectin	M 1.5100	3.0871
	m 0.3668	0.8308
Elastin	M 3.1650	6.6946
	m 0.7310	1.2812
TGF-b	M 1.1862	1.2144
	m 0.2119	0.1805
LOX	M 10.4600	18.3501
	m 2.3840	3.0296

Notes. M - mean value, m - error of the mean.

Conclusions

The lower expression of genes for CT structural proteins and the gene for the regulatory protein LOX in patients with POP and CTDS is the evidence of the importance of genetically determined pathological remodelling of CT in aetiology of genital prolapse, and the clinical definition of CTDS signs can be considered as a potential predictor of POP.

Looking up in laparoscopy

Sayed Elakhras¹, Bassem Sobhy², Vasilios Tanos³, Mohamed Salama⁴

¹Omam Hospital, Dept. of Minimally Invasive Gynaecology, Cairo, Egypt

²Galaa Teaching Hospital, Obstetrics and Gynaecology, Cairo, Egypt

³University of Nicosia Medical School, Obstetrics and Gynaecology, Nicosia, Cyprus

⁴Ain Shams University, Obstetrics and Gynaecology, Cairo, Egypt

Background

Laparoscopic surgery not only provide minimal wound complications, rapid recovery, and better cosmetic results, more importantly, it offers wider exposure of the whole of the peritoneal cavity.

As gynaecologists, we tend to "look down" searching for different pathologies in the pelvis and lower abdomen. However, by not "looking up" towards the upper abdomen, important lesions, pathologies and diseases could be overlooked, and the benefits of laparoscopy missed.

Methods

We hereby present various findings from our "up looking" routine inspection of the peritoneal cavity, from many cases who, interestingly, presented with a wide spectrum of complaints.

Results

Important findings are encountered during upper abdominal inspection. Peri-hepatic adhesions, diaphragmatic endometriosis, peritoneal defects in the falciform ligament, and splenosis are just a few of many such findings.

Spotting these findings help explain and hence alleviate patients complaints, and also provide clues to lower abdominal pathologies

Conclusions

As laparoscopic surgeons, gynaecologists should not just focus on inspecting and operating in the lower abdomen and pelvis. Instead, they also should "look up" to identify and manage upper abdominal lesions.

The 4 A's of Actinomycosis; Anaemia, AKI, Altered Bowels & Abdominal Pain

Edward Harrison¹

¹University Hospital Wales, Gynaecology, Cardiff, United Kingdom

Background

Actinomycosis is rare pelvic infection condition with an incidence of 1:300000. It is caused by the gram positive, anaerobic, acid-fast bacteria *Actinomyces* spp. It presents insidiously, with a varied symptomology, causing gross morbidity and is known to mimic presentations of malignancy. It is notoriously challenging to treat, and treatment strategies must be individualised to the patient.

Methods

Case

A 39-year-old woman presented to ED following a haemoglobin of 56g/l discovered by her GP. She reported with a history of lethargy, altered bowel habits, abdominal pain, intermittent fever and menorrhagia. She had no past medical history with an IUCD in situ. She reported to be in a stable relationship with no history of sexually transmitted infections. Additional bloods results showed a leukocytosis(12.2) , neutrophilia(8.7) with concomitant elevated C-reactive protein(200). In addition the patient had an elevated creatinine (131) and suboptimal eGFR(39) consistent with acute on chronic renal failure.

The patient was transfused three units of packed red cells, the IUCD was removed and sent to microbiology along with an HVS and endocervical swabs. Following blood cultures, the patient was commenced on PID Antibiotic regimen. An US pelvis, CT and MRI were performed. The conclusion was felt to be a right tubo-ovarian abscess extending around the left ovary causing bilateral hydronephrosis with possible bowel perforation. Gynae oncology MDM suggested malignancy was less likely.

The patient was taken to theatre with urology and colorectal teams for bilateral ureteric stenting, diagnostic laparoscopy, drainage of abscess and washout. Stenting was performed without complication. Diagnostic laparoscopy showed a frozen pelvis with dense rectosigmoid and iliocaecal adhesions and unlikely perforation. Typical actinomycosis appearance of sulphur granules was visualised. The colorectal team felt there was significant risk of bowel perforation, and the procedure was abandoned.

Following one week of IV Ceftriaxone 2gOD and IV Metronidazole 500mgTDS the patient was commenced on oral Co-amoxiclav 625mgTDS for four weeks. The patient was discharged after seven days following improvement in pain, inflammatory markers and renal function. Follow up ultrasound was requested, with ureteric stent removal planned in five months.

Results

.

Conclusions

When there is evidence of a pelvic infection with suspicion of malignancy and concurrent anaemia or associated hydronephrosis, actinomycosis should be suspected and extended actinomyces cultures should be requested immediately. It is vital that a multidisciplinary approach with urology, colorectal surgeons, radiology and microbiology is taken early ensuring optimal management. Diagnostic laparoscopy is often useful to acquire pus samples and recognition of sulphur deposits is helpful to increase surgical suspicion. However, pelvic drainage and adhesiolysis is not always possible nor in the patient's best interests as a conservative approach with long term antibiotics is commonly all that is required to achieve clearance.

Advantages of robotic assisted surgery in advanced endometriosis

Diana Elena Soare¹, Andrei Manu¹, Elvira Bratila¹

¹Clinical Hospital Of Obstetrics and Gynecology " Prof. Dr. Panait Sirbu", Obstetrics and Gynecology, Bucharest, Romania

Background

Since the FDA approval of robotic surgery use in gynecological pathology almost 20 years ago, this approach became more and more popular among gynecologists. The main goal in endometriosis surgery is to restore anatomy and function, thus resulting in pain relief. This can sometimes prove to be difficult to obtain and complex surgery is required in cases of severe endometriosis, where extensive dissection, tissue sparing and a multidisciplinary approach is needed.

Methods

We conducted a systematic review in which we included articles comparing the use of robotic assisted surgery with laparoscopy in endometriosis, with case examples from our own experience.

Results

While robotic assisted surgery has not yet proven to be superior to laparoscopy in the management of endometriosis concerning blood loss, surgical time and hospital stay, one can assume that this may not be necessary the case for severe endometriosis (stage IV). Certain lesion locations, such as deep parametrium, rectovaginal septum, can definitely benefit from the improved features of robotic surgery such as 3D vision, better zooming in and better mobility due to the instrument articulation. There is often need for precise manoeuvres when excising lesions from delicate regions, such as proximity to the inferior hypogastric plexus or sacral roots and tremor elimination of the robot is of great assistance. Last but not least, the surgeon's comfort is greatly improved, leading to a greater capability of performing longer operations with the best outcome.

Conclusions

Although there is not enough data to support the superiority of robotic assisted surgery in the management of endometriosis, there are strong indicators that it soon may become so. With greater and greater interest in learning to operate with this system and together with the shorter learning curve compared to conventional laparoscopy we can assume that robotic assisted surgery is the feature of endometriosis.

Post radical hysterectomy ovarian torsion – a gynaecological emergency

Naomi Harvey¹, Jothilakshmi Nallathambi², Sonali Kaushik³

¹St Richards Hospital, Obstetrics and Gynaecology, Chichester, United Kingdom

²William Harvey Hospital, Obstetrics and Gynaecology, Ashford, United Kingdom

³Royal Sussex County Hospital, Gynaecological Oncology, Brighton, United Kingdom

Background

Ovarian torsion is a surgical emergency whereby the ovary twists, or torts, on its ligamentous supports and potential compromises vascular supply to both the ovary and fallopian tube. It accounts for 2-3% of all acute gynaecological emergencies. It is a condition that is reported to rarely present after hysterectomy. We present two cases to highlight that torsion post ovarian transposition suspension is a gynaecological emergency that warrants immediate surgical intervention, recognise its clinical presentation and to discuss laparoscopic techniques to reduce its occurrence.

Methods

We report a series of two cases of ovarian torsion post primary laparoscopic radical hysterectomy performed for cervical malignancy. Ovarian transposition suspension was performed at the initial procedure after considering the possible need for post-operative pelvic irradiation if surgically upstaged in premenopausal patients.

Results

Both patients underwent emergency laparoscopic detorsion, with one torsion due to disease reoccurrence.

Conclusions

Adnexal torsion is estimated that it occurs between 1 to 8% of post hysterectomy cases. It can be a difficult to diagnose gynaecological emergency, with prudent history taking, relevant investigations and a low threshold to consider laparoscopy forming essential clinical acumen. Suspension of the ovaries post hysterectomy does not exclude future ovarian torsion and consequently, further research is needed in techniques of ovarian conservation in operative treatment of cervical cancer.

EPOSTER STATION PRESENTATION

ES32-0321 - P081
ePoster Presentations

Opt-out day case hysterectomy – the solution to post pandemic waiting lists?

Naomi Harvey¹, Alistair Ward², Samantha Roberts¹, Charlotte Goumalatsou¹, Melanie Tipples¹

¹*St Richards Hospital, Obstetrics and Gynaecology, Chichester, United Kingdom*

²*Queen Alexandra Hospital, Obstetrics and Gynaecology, Portsmouth, United Kingdom*

Background

At St Richards Hospital, a day case hysterectomy (DCH) pathway was introduced as a quality improvement project in 2021. The aim of the pathway is to facilitate surgical planning and reduce wait times for patients undergoing gynaecology surgery. It was an overwhelming success and therefore, our unit now practises an 'opt out' policy. Therefore, when a patient is listed for a laparoscopic hysterectomy, all cases are enrolled on the day case pathway so it is viewed as the 'norm'.

Methods

To implement the change, patient selection and multidisciplinary team (MDT) work is essential. Patient selection is based on criteria to optimise chances of same day discharge; however there is no set exclusion criterion. There is no age limit and while it is desirable for BMI<35 and either ASA 1 or 2, this would not prevent recruitment to the pathway. It is ideal that the uterus is <16 weeks size and the patient is accompanied by a responsible adult for 24 hours postoperatively. The patient should be motivated and be able to communicate their health needs directly or through a translator or carer.

Engagement of key stake holders with feedback is actively encouraged and actioned from pathway leaders has facilitated DCH becoming a success. Support from nursing staff ensure patients felt supported and collaboration with pharmacy allows medications to take home rapidly available post-op.

Intraoperatively, using total intravenous anaesthetic (TIVA), combined with proactive use of prophylactic anti-emetics and/or steroids, reduced the risk of postoperative nausea and vomiting. Surgical steps such as aiming for an operating time under 90 mins, keeping an operating pressure of 12mmHg and removal of catheter in theatre facilitates a quicker recovery by reducing post-operative pain.

Results

From November 2021 to April 2023, the unit performed 131 DCH. The feedback has been overwhelmingly positive with 97% of patients being discharged on the same day and 90% recommending it in a follow up questionnaire.

The average operating time was 57 mins, with minimum operating time of 34 mins and average estimated blood loss of 117ml. Our ideal patient criteria provided no barrier to treatment, with 6% of patients having an ASA of 3 and the maximum BMI of 50 (average 29.9) and maximum age 83 (average 53). 81% of procedures were for benign indications and 19% of cases for malignancy.

Conclusions

The Royal College of Obstetricians and Gynaecologists have stated that 530,000 patients are on gynaecology waiting lists, thus recognising that health inequality has increased for women during the COVID-19 pandemic. DCH has been successfully initiated in our unit with data showing efficacy, safety, patient acceptability and cost effectiveness. The pathway can be adopted in units across the UK and Europe allowing patients to access gynaecological procedures independent of hospital inpatient bed occupancy.

Enhancing patient care and outcomes: lessons learned from implementing a short-stay laparoscopic hysterectomy service at a university hospital

Syeda Tahseen¹, Ayesha Mahmud¹, Gourab Misra¹

¹University Hospitals of North Midlands, Gynaecology, Stoke on trent, United Kingdom

Background

Short-stay laparoscopic hysterectomy (<24 hour stay) has emerged as a promising surgical approach for uterine removal, offering reduced hospital stays, faster recovery, and improved patient outcomes. This abstract explores the lessons learned from implementing a short-stay laparoscopic hysterectomy service at a university hospital, focusing on its impact on patient care and outcomes.

Methods

A retrospective analysis was conducted, reviewing 65 cases, to evaluate the implementation of the short-stay laparoscopic hysterectomy service at the university hospital. Patient data, including demographics, length of hospital stay, procedural details, surgical outcomes, post-operative complications, and re-admission rates, were collected and analysed.

Results

The implementation of the short-stay laparoscopic hysterectomy service demonstrated significant findings. Patients undergoing short-stay laparoscopic hysterectomy had significantly reduced hospital stays compared to traditional open hysterectomy, resulting in cost savings and improved patient satisfaction. Patients reported lower postoperative pain levels and a faster return to daily activities. Surgical outcomes, including successful procedures and complications, were notably favourable.

Lessons Learned: Implementing a short-stay laparoscopic hysterectomy service required a multidisciplinary approach and collaboration among gynaecologists, anaesthesiologists, nursing staff, theatre, and recovery personnel. Clear protocols and guidelines were essential for patient selection, preoperative preparation, surgical techniques, and postoperative care. Staff education and training played a crucial role in ensuring the service's success. Regular quality assessments and audits helped identify areas for improvement and refine service delivery.

Conclusions

The implementation of a short-stay laparoscopic hysterectomy service protocol at our hospital has shown promising results in enhancing patient care and outcomes. The reduced hospital stays, decreased postoperative pain, and faster recovery have improved overall patient experience and satisfaction. The lessons learned emphasize the importance of a collaborative, multidisciplinary approach, well-defined protocols, continuous staff education, and rigorous quality assessments. This experience has also informed the development of a same-day discharge pathway. Future research will focus on evaluating long-term outcomes with a transition to more same-day hysterectomy procedures.

ES32-0415 - P087
ePoster Presentations

Suggested algorithm for managing bowel interference (harassment) in vNOTES surgery with the using the surgical gauze as a third assistance; the Ray Fish technique

Oudai Ali¹, Zini Mudiaga¹, Haider Jan¹

¹Epsom and St Helier University Hospital NHS trust, Obstetrics and Gynaecology, London, United Kingdom

Background

Vnotes surgery combines vaginal and laparoscopic approach. Usually in the laparoscopic phase it has small operative space to achieve the target. Head down position usually clears the interference from the bowel when applying energy to seal and divide ligaments and blood vessels. Bowel interference is named here **bowel harassment** as it does delay the safe application of the energy device till the bowel is pushed safely away and consequently prolong the procedure.. Small bowel can be mobilised away easier than the large bowel. In reviewing 100 cases of vnotes in Epsom, South London it was observed that difficulty in clearing the bowel away from the field was associated with obesity, under anaesthesia, adhesions, inflated stomach, and comorbidity like in COPD. Here is a locally developed algorithm to manage bowel harassment with a demonstration of the swab ray fish technique as a third assistant,

Methods

25 Vnotes videos were analysed where the phenomenon happened and the operation and anaesthesia details were studied. These are the recommended recommendations in this order

- 1-increase head down >20 degree , consider lower pressure pneumoperitoneum and NG tube
- 2-position the omentum over the transverse colon *then* the small bowel in the right upper quadrant *then* manipulate large bowel out of the pelvis gently using epiploae when possible.
- 3- assess for under-anaesthesia and request further relaxation
- 4- think of introducing 9x9 inch swab/gauze with a tail to retract the bowel
- 5- consider 4th port dynamic assistance
- 6- evaluate for adhesions and consider adhesiolysis
- 7- Consider conversion

The swab technique was specially effective and it was standardised to fold and introduce in the pouch of Douglas similar to Ray fish after soaking it with instillagel. It was important not to include it in the activation of the energy devices and keep the tail out of the Gelpoint.

Results

It was observed that these steps are effective in ensuring the safety of the procedure and increased its efficacy. One case was converted to single port as bowel interference with adhesions prevented adnexal mass retrieval through the vagina. Under anaesthesia was a contributing factor in three superficial tears in the series of 100 cases. The fourth port dynamic assistance was exercised in difficult corners but not sustainable for long time due to sword fighting. Adhesiolysis was more useful in large bowel than the small bowel particularly to free the left adnexa.

Conclusions

These steps reflect experience of operating complex vnotes cases with the surgical difficulty was attributed to the bowel harassment. The sequence of the steps is essential to follow. It is not necessary to use the swab/gauze routinely in every case it was noted that it was frequently used when the BMI>50. Systematic structured approach to this phenomenon will help prevent complications and enhance procedure efficiency.

Laparoscopic hemi-hysterectomy of uterus didelphys complicated by hematometra: a case report

Theodoros Theodoridis¹, Eirini Iordanidou¹, Christos Anthoulakis¹, Tilemachos Karalis¹, Pinelopi Ioannidou¹, Grigorios Gkribizis¹

¹Medical School- Aristotle University of Thessaloniki, 1st Department of Obstetrics and Gynecology, Thessaloniki, Greece

Background

Uterus didelphys represents a rare congenital malformation where the embryogenetic fusion of the Müllerian ducts fails to occur, resulting in a double uterus with two separate cervixes. This report presents a fertility-sparing option for obstructive Müllerian anomalies.

Methods

An 18-year-old nulligravida presented with severe dysmenorrhea secondary to uterus didelphys with right cervical atresia complicated by ipsilateral hematometra. Laparoscopic hemi-hysterectomy of the right uterus and right Fallopian tube was performed successfully. The main operative findings can be summarized as follows: (i) grossly normal left uterus and adnexa; (ii) right hematometra with ipsilateral cervical atresia; (iii) grossly normal right ovary; and (iv) no obvious endometriosis. With respect to the surgical technique, a uterine manipulator was inserted in the left cervix and subsequently, following laparoscopic inspection, the right uterus and Fallopian Tube were removed. Ipsilateral round, broad, sacrouterine, cardinal ligaments, and uterine vessels cauterization and incision was performed. In view of the volume of solid benign tissue to be removed, the hematometra and right Fallopian tube were removed by laparoscopic morcellation.

Results

The post-operative period was uneventful, and the patient was discharged 3 days later. The patient continues to have regular menses without dysmenorrhoea, now 1 year postoperatively.

Conclusions

The case presented may help to elucidate Müllerian duct embryology further. Early and accurate diagnosis is important, as an unnecessary hysterectomy could be avoided and fertility preserved. Laparoscopic hemi-hysterectomy could be a fertility-sparing alternative to classic surgery, additionally ensuring uncomplicated menstruation.

Laparoscopic drainage of tubo-ovarian abscess - tips and tricks

Ayman Abdelkader¹, Ramy Gamea²

¹Consultant Endometriosis and Minimal invasive surgery at Homerton University Hospital, Obstetrics and Gynaecology, London, United Kingdom

²Homerton University Hospital, MTI clinical fellow in Obstetrics and Gynaecology, London, United Kingdom

Background

Tubo-ovarian abscess (TOA) is a serious complication of pelvic inflammatory disease (PID) characterized by the formation of a complex inflammatory mass involving the fallopian tubes and ovaries. Traditionally, open surgical drainage has been the standard treatment for TOA. However, with advancements in laparoscopic techniques, laparoscopic drainage has emerged as a viable alternative. This abstract aims to explore the effectiveness and benefits of laparoscopic drainage in the management of tubo-ovarian abscess.

Methods

The video demonstration will provide a visual guide to the steps of safe laparoscopy for two different cases of tubo-ovarian abscess (TOA) drainage. The first case presented with Ruptured right sided TOA and the second case with a localised TOA.

The aim from the presentation is to highlight the available evidence for safe laparoscopic entry technique in this situation, meticulous dissection contribute to minimising the risk of infection and injury. Careful identification and protection of surrounding structures, such as the bowel and major vessels, are paramount during abscess drainage.

Furthermore, safe laparoscopy in TOA management includes meticulous irrigation and suction to ensure adequate abscess cavity debridement. In some cases, adhesolysis may be necessary to improve access and facilitate drainage and insertion of drain for at least 24 hours.

Results
Numerous studies have reported successful outcomes with laparoscopic drainage of TOA, including effective resolution of the abscess, alleviation of symptoms, and improved fertility outcomes. Additionally, laparoscopic drainage has shown comparable efficacy to open surgery in terms of abscess clearance rates and complication rates, while offering the aforementioned advantages.

This abstract highlights the growing evidence supporting laparoscopic drainage as a safe and effective treatment modality for tubo-ovarian abscess. The incorporation of safe laparoscopic steps enhances patient safety and contributes to optimal outcomes.

Conclusions
In conclusion, laparoscopic drainage represents a valuable alternative to open surgical drainage in the management of tubo-ovarian abscess. Laparoscopic drainage has the potential to improve patient outcomes, enhance recovery, and contribute to the evolving field of minimally invasive gynaecological surgery.

Total laparoscopic hysterectomy tips and tricks for a large size uterus

Kunal Rathod¹, Yatin Thakur², Premilla Kollipara¹

¹Queens Hospital Romford, Gynaecology, London, United Kingdom

²Basildon and Thurrock University hospital, Gynaecology, Essex, United Kingdom

Background

Laparoscopic hysterectomy is the most commonly performed surgical procedure. There is generally a limitation in performing it for a large size uterus due to lack of training, inadequate space and problems related to specimen retrieval after the procedure is performed. Most studies have set an upper limit for uterine size, usually 15 to 16 weeks' gestation or weight more than 500 grams. The difficulties with enlarged uteri are limited access to uterine vascular pedicles depending on size and location of myomas, and high risk of complications such as haemorrhage. Other concerns of laparoscopic management of large uteri are the risk of bowel and urinary tract injury due to poor exposure, difficulty extracting the uterus, and duration of the procedure.

Methods

Patients were placed in a dorsal lithotomy position with pneumoboos. The arms were tucked at the sides and a foam mattress was situated directly under the patient to prevent sliding during steep Trendelenburg. Operating table was kept in a low position and a monitor was directly placed facing each surgeon to promote an ergonomic working environment. RUMI II with the tip size 10 cm and cup size 3 cm from Cooper surgical and a 5 mm myoma screw were used for the manipulation of uterus. Injection argipressin 20 IU in 100 mls normal saline was injected intramurally to prevent blood loss during surgery. Bilateral adnexa were coagulated and divided with bipolar (advanced bipolar device) with adequate traction on ligaments provided by myoma screw. Ureters were visualised transperitoneally before this step was conducted. Sharp dissection was used to open uterovesical fold of peritoneum and bladder was pushed caudally. Bilateral uterine vessels were sealed and transected after skeletonisation along with the cardinal ligaments. RUMI II cup was used as the guide mark to perform colpotomy. Myomectomy was performed and part morcellation was performed. Specimen was retrieved vaginally. A large 10 x 10 cm wet swab was used as pneumo occluder. Vault was closed with stratafix barbed suture.

Results

Procedure was performed uncomplicated with total duration of 84 minutes. Blood loss was approximately 50 mls and urine was clear. Hospital stay was for 24 hrs and recovery was uneventful.

Conclusions

To conclude if the uterus is large and requires manipulation with a tenaculum or myoma screw, consider injecting dilute vasopressin prior to applying traction to the uterus. This can reduce bleeding associated with pulling and tearing of the uterine serosa. To improve optical access a 30 degree scope should be used. Specimen can be retrieved through multiple ways, usually depends on the comfort of the surgeon employing it. Given adequate training in laparoscopic surgery and with proper technique, TLH can be performed successfully in most women with very enlarged uteri, with no increase in complication rates and short-term recovery.

Excess use of surgical supplies in minimally invasive benign gynecology surgery: an observational study

Aya Mohr-Sasson¹, Madison Aycock¹, Noel Higgason¹, Mason Hui¹, Asha Bhalwal¹, Alvaro Montealegre¹
¹McGovern Medical School at The University of Texas Health Science Center, Advanced Minimally Invasive Gynecologic Surgery, Houston, USA

Background

Single use materials and equipment are regularly opened by the surgical team during procedures but left unused, potentially resulting in superfluous costs and excess environmental waste. The aim of this study is to estimate the excess use of surgical supplies in minimally invasive benign gynecological surgeries.

Methods

This is a prospective observational study conducted at a single tertiary medical center. Designated study personnel were assigned to observe surgeries performed for benign indications between July-September 2022. Surgical teams were not informed of the purpose of the observation to avoid potential bias. Disposable materials and equipment opened and used during the procedure were documented. Excess supplies were defined as those opened but left unused before being discarded. Costs per item of excess supplies were estimated based on material and equipment costs provided by the hospital.

Results

99 surgeries were observed, including laparoscopic (32%), robotic (39%), hysteroscopic (14%), vaginal (11%) and laparotomy procedures (3%). Excess use of surgical supplies was documented in all but one procedure. Raytecs were the most frequently item used in excess, with a total of n=583 opened but unused (average n=5.95 per surgery). They contributed 44.19% of the total cost of excess surgical supplies that reached \$19,788 across all surgeries. The most expensive excess item was the Airseal Gas tube™ (Conmed Corp, \$77.25 per unit), which was used in excess in n=5 procedures. No significant differences were found in the number of excess supplies across the surgical approaches.

Conclusions

Excess use of disposable materials and equipment is common in minimally invasive benign gynecological surgeries and contributes surgical cost. It is predominantly attributed to opening of inexpensive materials that are left unused during the procedure. Increased awareness of costs and generated waste may reduce excess use of surgical supplies and will be explored in future research.

The environmental impact of a hysterectomy: strategies for reducing our carbon footprint

Kim Van Nieuwenhuizen¹, Frank Willem Jansen¹

¹Leiden University Medical Center, Gynaecology, Leiden, The Netherlands

Background

Healthcare workers must take action in response to climate crisis, as it poses a significant threat to our planet's ecosystems and indirectly endangers our own well-being. The healthcare industry is responsible for producing roughly 7-8% of both national and international carbon dioxide emissions. Despite the operating room (OR) occupying only 6% of a hospital's physical space, it contributes to 20-30% of the hospital's waste due to the excessive use of disposable products. The total hysterectomy is the second most common surgery performed on women, with various techniques available such as abdominal surgery, conventional laparoscopic surgery, and robot-assisted laparoscopic surgery. We examined existing literature to identify strategies to reduce the carbon footprint of performing a hysterectomy.

Methods

A systematic literature search was conducted using Pubmed, Embase, Web of Science, Cochrane and Emcare, regarding 'environmental sustainability' and 'operating techniques'. Life cycle assessments (LCAs) were included in the analysis to evaluate environmental impact. In total 3 articles were included for analysis.

Results

Among the three techniques for performing a hysterectomy, robot-assisted laparoscopic surgery had the greatest environmental impact, followed by conventional laparoscopic surgery and abdominal surgery. The use of disposable products was identified as the biggest environmental hotspot, presenting the most significant opportunity for improvement. Other factors that had a substantial impact included the use of inhalational anaesthesia and energy consumption. Plastic materials accounted for the majority of the waste generated, followed by paper and cotton.

Conclusions

To reduce the carbon footprint of hysterectomy procedures, several strategies can be employed. It's crucial to note that robot-assisted surgery has a more significant impact on the environment compared to other surgical techniques, primarily due to the increased use of energy and disposables. Therefore, if surgical techniques have similar clinical effectiveness, prioritize the most sustainable option. When surgery is necessary, carefully consider the appropriate technique, minimize the use of disposables, optimize the use of sustainable energy and energy-efficient equipment, and prioritize sustainability in the design of new and existing technologies. To achieve these objectives, it is key to collaborate with industry partners and to implement regulatory modifications.

Laparoscopic sentinel lymph node mapping in endometrial cancer, the most common areas to find it

Andreas Kavallaris¹, Antonios Gkoutzioulis¹, Ourania Kaiafa¹, Panagiotis Papandreou¹, Kopatsari Stergios¹, Dimitrios Zygouris¹

¹St. Lukes Hospital, Gynaecology Oncology and Laparoscopic Surgery, Thessaloniki, Greece

Background

SLN mapping is based on the concept that the lymph drains in a specific pattern, away from the tumour and therefore, if first node (the SLN), is negative for metastasis, then the nodes after the SLN should also be negative. Since 2017 we use the sentinel lymph node technique mapped with indocyanine green (ICG) dye for the treatment of endometrial cancer. For the first 40 cases between 02. 2017 until 10.2018 we performed always radical pelvic lymphadenectomy after the SLN mapping to evaluate the method and standardized our technique.

Methods

The following years between 11.2018 until 03.2023 we performed in 127 cases (101 endometrioid G1 and G2 and 26 high grades endometrial cancer) ultra-staging SLN mapping, explore the pelvic, the presacral and the paraaortic areas. The years between 11.2018 until 03.2023 we performed in 127 cases (101 endometrioid G1 and G2 and 26 high grades endometrial cancer) ultra-staging SLN mapping, explore the pelvic, the presacral and the paraaortic areas. The documentation of the location of the SLNs performed intraoperative and the follow up of the documentation performed using the video of the surgery.

Results

The overall detection rate of SLNs was for the low- and intermediate-risk patients 100%, and 98% for the high-risk patients. .The most common anatomical sites of SLs were the external iliac vessels (65.8%) and obturator regions (21.9%) and 4.4% presacral and paraaortic areas, 7.9% other area . Positive lymph-nodes were found in 8 (6.2%) patients.

Conclusions

We observed that SLN mapping is an acceptable alternative staging method for endometrial cancer without compromising oncological safety, presenting equal or even better detection rates to those of lymphadenectomy with significant less perioperative morbidity for the patients. However, obtaining sufficient and high surgeons experience (at least 20 cases per year) and standardized technique continues to be essential to preserving diagnostic accuracy. However, future studies are needed to support this suggestion by resolving potential areas of doubt and debate, especially for high-risk endometrial cancer cases

ES32-0261 - P069
ePoster Presentations

Marwah's confluence point, evaluating safety of insertion of veress needle just below the rib cage at the confluence of the 8th to 10th ribs

Vivek MARWAH¹, Surabhi Kedia¹, Rony Chakravarty², Kanika Gupta¹, Khusboo Tongaria¹

¹Max Superspeciality Hospital Saket - New Delhi, Division of Minimally Invasive Gynecology, New Delhi, India

²Command Hospital, Obstetrics & Gynecology, Kolkata, India

Background

The evaluation of the safety of Marwah's Confluence point, a new point for the first blind insertion of Veress needle just below the rib cage where the 8th 9th and 10th rib meet where the chances of adhesion is minimal.

Methods

Retrospective cohort study was done. Out of total of 1887 cases operated between 1st January 2020 to 31st December 2022 at a tertiary care centre; 431 cases had previous abdominal and gynaecological surgeries or had big pelvic masses reaching above the umbilicus or had peritoneal mesh. Only exclusion criteria was the case of gross splenomegaly.

Marwah's Confluence point has been used in these cases for blind and safe Veress needle entry.

Any bowel or vital organ injuries were noted.

Intervention involved Veress needle entry just at the subcostal margin at the meeting point of 8th 9th and 10th rib in cases with multiple previous abdominal or pelvic surgeries, big pelvic masses particularly in patients with small abdominal volume and previous abdominal adhesions.

Results

No case of bowel injuries were noticed in the 431 cases where the Marwah's Confluence point was used for entry including a case of mild to moderate splenomegaly.

Conclusions

With increasing number of complex surgeries being performed laparoscopically, bony landmark of subcostal margin (Marwah's Confluence point) can be a safe entry point in cases of expected bowel adhesions (previous surgeries) and big pelvic masses.

Higher odds of cervical incompetence in a pregnant woman with PCOS: the need for early identification to improve pregnancy outcomes

Sindhu Sekar¹, Sujeewa Fernando²

¹Wrexham Maelor Hospital, Obstetrics and Gynaecology, Wrexham, United Kingdom

²Wrexham Maelor Hospital, Obstetrics and Gynaecology, Wrexham, United Kingdom

Background

Insulin resistance may induce a glucose metabolism disorder could potentially cause cervical incompetence (CI), resulting in an adverse outcomes like preterm delivery and low birth weight babies. We aimed to determine the association between polycystic ovarian syndrome (PCOS) and CI.

Methods

We conducted a systematic review and meta-analysis of observational studies to summarise the evidence regarding the strength of the association of occurrence of CI in a PCOS pregnant woman compared to a non-PCOS pregnant woman. We defined PCOS as the presence of two of the three Rotterdam criteria, and a combination of clinical symptoms and ultrasound findings were used to diagnose CI. This review adheres to the Preferred Reporting Items for Systematic Reviews and Meta-Analyses (PRISMA 2020) reporting standards and the PROSPERO registration. We systematically searched PubMed and Embase to identify observational studies up to December 2022. We included studies in English that compared the PCOS and non-PCOS pregnant women who were diagnosed using Rotterdam criteria and subsequently developed CI in the same pregnancy. We excluded the studies which did not report CI as an outcome. Two reviewers independently screened studies, extracted data, and assessed the risk of bias (JBI critical appraisal tools). In the meta-analysis, effect estimates were pooled using the random effects model, and heterogeneity was measured using I^2 statistics.

Results

We identified 23 articles, of which 19 were screened, and three studies were included in the meta-analysis. Three observational studies reported the data of 3845 pregnant women with PCOS and 9449 pregnant women without PCOS. One hundred and forty-one (3.7%) pregnant women with PCOS developed CI compared to 58 (0.6%) non-PCOS pregnant women [Odds ratio: 5.3; 95% confidence interval: 1.9-14.6; I^2 : 89%]. Of the three studies included, two had a low risk of bias, and one had a moderate risk of bias.

Conclusions

Our findings suggest higher odds of CI in a pregnant woman with PCOS compared to those without. These findings emphasize the importance of early identification and intervention to prevent adverse maternal and neonatal outcomes in this population.

Exploring fertility preservation after uterine artery embolisation: a comprehensive case series of eight pregnancies (conceived post-procedure)

Rahul Gore¹, Mitalee Sawant², Saadia Saqib², Arun Sebastian², Kamran Safdar Rao²

¹*Colchester general hospital, Obstetrics and Gynaecology, Tunbridge Wells, United Kingdom*

²*Colchester general hospital, Obstetrics and Gynaecology, Colchester, United Kingdom*

Background

Aims and Objectives: To rigorously evaluate the fertility outcomes of eight women who underwent uterine artery embolization (UAE) for adenomyosis or fibroids and subsequently achieved pregnancy, and to compare these outcomes with the published literature on fertility following UAE procedures.

Methods

We conducted an in-depth case series on eight patients who attained pregnancy following UAE procedures for adenomyosis or fibroids at our institution. Pregnancy outcomes, conception methods, and any pregnancy-related complications were documented, meticulously analyzed, and compared with the published articles.

Results

Among the eight patients who became pregnant post-UAE, seven conceived spontaneously, while one necessitated in-vitro fertilization (IVF). The ages at conception spanned from 24 to 38 years, and the time interval between UAE and conception ranged from 4 weeks to 4 years. Pregnancy-related complications transpired in three cases, including pre-eclampsia in two patients and gestational diabetes mellitus (GDM) in one. Of the eight pregnancies, five culminated in full-term deliveries, two in preterm deliveries, and one is currently ongoing. One experienced postpartum haemorrhage (PPH) along with manual removal of the placenta. Two patients required emergency caesarean sections, one at 33.5 weeks with severe pre-eclampsia and placental abruption and another with preeclampsia, with intrauterine growth restriction (IUGR) at 35.4 weeks of pregnancy.

Overall, both maternal and fetal outcomes were good on long term follow up at 1 year.

Conclusions

1. Our case series accentuates that successful pregnancies can indeed be realized following UAE procedures for adenomyosis and fibroids, with the majority of patients conceiving spontaneously.
2. Our findings are congruent with published literature, which proposes that fertility can be preserved after UAE in a substantial number of cases, albeit complications such as pre-eclampsia, placental abruption, morbidly adherent placenta, IUGR and PPH may emerge. Further research is essential to better comprehend the long-term effects of UAE on fertility and pregnancy outcomes.
3. In the interim, UAE remains a pivotal treatment option for symptomatic adenomyosis and fibroids, particularly for patients who desire future pregnancies.
4. We recommend UAE procedures in multidisciplinary settings with meticulous patient selection along with evidence-based pre-procedure counselling for optimal outcomes and to improve patient safety and satisfaction.
5. We also recommend to provide multidisciplinary obstetric and neonatal input for this cohort of pregnant women and proactive management of any emerging obstetric complication, to ensure the optimal maternal and neonatal outcomes.

The effectiveness of prolonged downregulation with GnRH analogue treatment in women with adenomyosis undergoing IVF/ICSI: a systematic review and meta-analysis

Sania Latif¹, Stavroula Kastora¹, Bassel H Al Wattar¹, Ephia Yasmin¹, Ertan Saridogan¹, Dimitrios Mavrelos¹
¹University College London Hospital, Reproductive Medicine Unit, London, United Kingdom

Background

Adenomyosis can reduce the chance of clinical pregnancy in women undergoing assisted conception. Prolonged gonadotrophin-releasing hormone analogue (GnRHa) treatment prior to IVF/ICSI has been postulated to improve pregnancy outcomes. We aimed to determine the effectiveness and safety of prolonged GnRHa treatment (minimum 1 month) versus no pre-treatment in women with adenomyosis undergoing IVF/ICSI.

Methods

We conducted a systematic literature review according to the Preferred Reporting Items for Systematic Reviews and Meta-Analyses for relevant studies from inception til 27th of March 2023 across the following electronic databases: Embase (OVID), MEDLINE® (OVID), APA PsycInfo (OVID), Maternity & Infant Care Database (MIDIRS (OVID), HMIC Health Management Information Consortium (OVID) and ClinicalTrials.gov. We included women with adenomyosis receiving GnRHa to down-regulate the hypothalamic-pituitary complex for one to six months before IVF/ICSI. Two independent authors assessed studies against the inclusion criteria, extracted data and assessed risk of bias. A third review author was consulted, if required. A meta-analysis was conducted by computing the Odds Ratio (OR), random effects (RE) from the original data using Haensel-Mantel method with Review Manager Web. Statistical heterogeneity was quantified using I² statistics and Cochrane Q tests. Asymmetry was assessed by funnel plot, and asymmetry was assessed formally by rank correlation test (Begg's test; RevMan V. 5.4). Quality of evidence was assessed using the Newcastle-Ottawa Scale and GRADE criteria. Bias analysis was conducted via the Cochrane recommended tool (RevMan Web, Academic License).

Results

We included 8 retrospective studies in the meta-analysis, with a total of 2422 women, median age 34 years [IQR 31.95-35.05], BMI 21.30 kg/m² [IQR 21.05-23.55]. Median duration of GnRHa downregulation was 2.5 months [Range 1-4; IQR 1.37-3]. There was no statistical difference in median age, BMI and severity of adenomyosis (where stated) between groups. Women with adenomyosis receiving prolonged GnRHa treatment had a higher implantation rate (OR 0.77 [95%CI 0.60, 0.98], I²=0%, p=0.03) and clinical pregnancy rate (OR 0.70 [95%CI 0.50, 0.97], I² 70%, p=0.03). There was no difference in live birth rate (OR 0.89 [95% CI 0.56, 1.43], I²=78%, p=0.63), miscarriage rate (OR 1.09 [95%CI 0.78, 1.51, p=0.61, I² 0%) or mean number of oocytes retrieved (10 oocytes [IQR 8.95; 11.15] vs. 9.28 [IQR 8; 10.20], p=0.22) between groups. Only one study reported on ectopic pregnancy, multiple pregnancy, fetal abnormalities and complication rates, showing no difference between groups.

Conclusions

Prolonged GnRHa treatment in women with adenomyosis undergoing assisted conception treatment improves implantation and clinical pregnancy rates. Given the limited low-quality existing data, there is a need for well-designed, prospective randomised controlled trials to definitively determine the impact of prolonged GnRHa treatment in this population.

Comparison of second trimester surgical abortion complications in women with and without a history of a caesarean section

Yasmin Farhadian¹, Ron Sagiv¹, Ohad Gluck¹

¹*Wolfson medical center, obstetrics and gynecology, Holon, Israel*

Background

While previous cesarean delivery has been associated with hemorrhage and uterine rupture in second-trimester medical abortions, very few studies examined the effect of prior cesarean section on surgical termination of pregnancy morbidity, and they have reported conflicting results.

Methods

We conducted a retrospective cohort study comparing women who had a history of cesarean section with those who had none, thus examining the effect of a previous caesarean section on the risk of complications following a second-trimester surgical abortion - such as retained product of conception, uterine atony, hemorrhage, DIC, infection, cervical/vaginal laceration, uterine perforation, hysterectomy, or bladder/ureteral injury. Our objective was to estimate second-trimester surgical abortion complication rates and to determine the impact of past cesarean delivery on the risk for such complications.

Results

Our cohort included 898 women who underwent second trimester surgical termination of pregnancy, 118 (13%) of which had a prior caesarean section. These women were slightly older (28.9 vs. 32.3 years, $p < 0.01$), with a larger number of previous pregnancies (2.65 vs. 3.97, $p < 0.01$) and deliveries (0.999 vs. 2.05, $p < 0.01$). In terms of past medical history, no significant difference was found between the groups, as was median gestational age at the time of the abortion (111 [84,154] and 109 [91,147] days respectively $p = 0.77$), abortion cause and preparation method prior to the procedure. No significant difference was found between women who had a previous cesarean section and women who did not with regards to the primary outcome, complications following a second-trimester surgical abortion.

Conclusions

Our findings confirm the safety of surgical second trimester termination of pregnancy in women who had a previous caesarean section.

Endometriosis excision by laparoscopy and uterine cavity metroplasty of uterine anomalies hysteroscopic does improve the fertility and life style of women have infertility and DYS

Mohamed Mounir¹, Hassan Mansour², Ahmed Fawzy³

¹DR. MOHAMED SAMIR FOUAD, GYNECOLOGY, ALEXANDRIA, Egypt

²Faculty of medicine Alexandria University, Obstetrics and gynecology, Alexandria, Egypt

³Dr mohamed samir fouad mounir clinic and centre, Gynecology and reproductive medicine, Alexandria, Egypt

Background

The purpose of this study is to improve the fertility and life style of patients suffering from infertility , recurrent ivf failure and DYS syndrome within 6 months post operative by more than 85% success rate

Methods

16000 women suffering from infertility, recurrent ivf failure and DYS syndrome over a period of 5 years first assessment includes proper history taking then advanced ultrasound examination and MRI to confirm that they have abnormal uterine cavity mostly T shaped and subseptated and Endometriosis then counseling the patients to perform combined laparoscopy and hysteroscopy to do metroplasty of the uterine cavity and excision of endometriosis not cauterization under general anaesthesia in lithotomy position and then trendlenburg position during laparoscopic excision of endometriosis using bipolar and cutting monopolar with not more than 40 W power.

Results

85% of cases become pregnant spontaneously within 6 months post operative and the rest needed to do ivf because of their partner case and the success rate was 80% in the first ivf procedure and the rest became pregnant after the second ivf trial .regarding the life style 99% of cases became pain free and improved their lifestyle within 48 hours postoperative. 98% of cases had successfully got pregnant had well babies

Conclusions

Combined laparoscopy and hysteroscopy to do metroplasty of uterine anomalies and excision of endometriosis not cauterization for cases of infertility and DYS syndrome due to endometriosis and abnormal uterine cavity leads to 85% spontaneous pregnancy rate and the ivf success rate is 80% in the first trial and the rest become pregnant after the 2nd ivf trial.

Laparoscopic removal of a 10-cm-diameter cystic tumor located in the right tube from a 22 years aged patient with an important fertility sparing factor

Eleftherios Klonos¹, Christos F. Zymperdikas¹, Athanasios Tolkos¹, Tilemachos Karalis¹, Theodoros Theodoridis¹, Grigorios Grimbizis¹

¹Aristotle University of Thessaloniki, 1st.Dpt. Ob/Gyn, Thessaloniki, Greece

Background

This is a case report about a 25-year-old patient G0P0, who referred to our department due to chronic abdominal pain, especially located at the lower right abdomen. The patient revealed neither relation between the pain and the phase of the menstruation nor the presence of other co-existing symptoms.

Based on the clinical examination of the patient, a mild tenderness was noted during the palpation of the abdomen. The transvaginal ultrasound revealed a cyst Tumor located in the anatomic area of right Adnex. In the sequence, the patient underwent a magnetic resonance imaging (MRI) and the initial diagnostic hypothesis was cystadenoma of right Ovary. Finally, based on the blood examinations, a mild increase of CA-125 was reported.

Based on the formentioned findings, we decided to perform a laparoscopic procedure, in order to effectively remove the cystic formation.

Methods

A four-port laparoscopy was performed. After the initial inspection of the whole peritoneal cavity, we performed division of the sigmoid colon adhesions. The next step was to investigate the cystic formation. Using two laparoscopic forceps we found out that the cyst was originated from the wall of the right fallopian tube. Using laparoscopic scissors we attempted to detach the cyst from the fallopian tube. However, the wall of the cyst was erupted and the clear liquid of the cyst was removed with suction. Performing careful handlings in order not to damage the fallopian tube's wall, we managed to remove the remaining cystic wall. Because of the patient's nulliparity, we performed dye test by inserting saline with solution of blue de methylene, and the passability of both fallopian tubes was established. Finally, the retroperitoneal spaced was sufficiently washed by warm saline and an extended control of hemostasis was performed.

Results

The patient's recovery was uncomplicated. The patient was discharged 1 day post-operatively. The histopathological examination of the specimen revealed the presence of a simple paratubal cyst without malignancy being diagnosed.

Conclusions

Based on the fertility sparing factor of the patient it was of great importance to perform careful manipulation during the operation, in order to maintain the passability of both fallopian tubes, avoid increasing the complication rate and harm the patient's ability for fertilization.

Use of Endosketch© 3D models for counselling patients and training juniors on endometriosis, fibroids, ovarian disease, and hysteroscopy in virtual reality mode

Amr Magdi Mohamed Moneib¹

¹*Queen Elizabeth Hospital, Obstetrics and Gynaecology, London, United Kingdom*

Background

The use of three-dimensional (3D) models for patient counseling and surgical training has gained popularity in recent years. These models provide a better understanding of the patient's condition and assist in surgical planning. The author has developed Endosketch.co.uk a free customizable platform that allows users to use and manipulate 3D models of endometriosis, fibroids, ovarian disease, and hysteroscopy on a computer or mobile app interface. While the platform itself is free to use, the virtual reality mode that showcases the value of 6DoF is currently only a proof of concept and not yet available for other users. In the attached video, we demonstrate the value of 6DoF and how it can be used to enhance the learning experience and improve surgical planning and execution.

Methods

Method: This article is a review of the virtual reality platform developed by endosketch.co.uk. The platform allows users to create 3D models of endometriosis, fibroids, ovarian disease, and hysteroscopy using a variety of imaging modalities, including MRI and ultrasound. The models can be manipulated in 6DoF mode, allowing users to view the models from any angle and zoom in on specific areas of interest. The Endosketch.co.uk platform is free to use and can be accessed through a web browser or downloaded as a standalone application from the google play store.

Results

Results: The use of virtual reality in patient counseling and surgical training has several advantages. Virtual reality provides a more immersive and interactive experience compared to traditional two-dimensional images or physical models. This allows patients and trainees to better understand the anatomy and pathology of their condition. The ability to manipulate the 3D models in 6DoF mode also allows users to explore and visualize the models in a way that is not possible with traditional methods. This enhances the learning experience and improves surgical planning and execution.

Conclusions

Discussion: The concept of 6DoF refers to the ability to move in any direction and rotate around any axis in three-dimensional space. This allows users to interact with the 3D models in a more natural and intuitive way.

Conclusion: The use of virtual reality in patient counseling and surgical training has several advantages over traditional methods. Endosketch.co.uk's platform provides a customizable and interactive experience that allows users to create and manipulate 3D models of endometriosis, fibroids, ovarian disease, and hysteroscopy. This enhances the learning experience and improves surgical planning and execution. The platform is free and easy to use, making it accessible to a wide range of users.

Artificial Intelligence - guided surgery and carcinomatosis - moving towards a standardization of cancer evaluation

Eleni Karatrasoglou^{1,2}, Khadija Hader³, Adrien Bartoli⁴, Michel Canis¹, Nicolas Bourdel¹

¹estaing university hospital, department of gynecologic surgery, Clermont-Ferrand, France

²national and kapodistrian university of Athens, school of medical science, Athens, Greece

³surgar company, data science, Clermont-Ferrand, France

⁴university of Clermont-Ferrand, department of computer science, Clermont-Ferrand, France

Background

augmented reality (ar) is a technology that can allow a surgeon to see subsurface structures. this works by overlaying information from another modality, such as mri and fusing it in real time with endoscopic images. so far "ar" software has successfully been used for the automatic detection of myomas, but no "ar" software has been developed for gynecologic malignancies.

Methods

preliminary results

Results

augmented reality (ar) is a surgical guidance technology that allows key hidden subsurface structures to be visualized by endoscopic imaging. to date, previous publications have highlighted the success of "ar" in uterine surgery and myomectomy. inspired by that vision, we decided to integrate the "ar" technology in gynecologic oncology surgeries performed by minimally invasive methods. despite the various staging systems which have been widely used by medical society, the problem of standardization of evaluating cancer remains an unsolved issue. the optimal task of every gynecologic oncology surgeon is to subjectively evaluate the stage of cancer of the patient and proceed to complete exploration and excision of all malignant lesions in the peritoneal cavity. based on ar technology and scoring systems (for example figo score, pci score) we created an algorithm for the automatic detection of peritoneal carcinomatosis with real-time tracking. by annotating multiple frames from explorative laparoscopies of patients with primary and advanced gynecologic cancer, we successfully detected various peritoneal lesions (>0.5 cm) in real-time while suggesting anatomic planes for lesion excision. while these results represent only the preliminary stage, the outcomes of the real-time tracking are exceptionally encouraging. not only do these results provide the basis for future research, but they also set the stage for the development of an automatic detection system for all types of gynecologic malignancies.

Conclusions

we are hereby presenting an "ar" software system for the automatic detection of all malignant lesions on the peritoneal sheath of patients with primary and advanced gynecologic malignancies. the preliminary results are promising but massive data to test this new algorithm is needed. therefore, a clinical trial is required to assess the advantages of guided exploration of peritoneal malignant lesions and the quality of the results obtained.

Green is good - ureters and ICG

Andrew Kent¹, Samantha Kirkwood¹, Piers Johnston²

¹Royal Surrey County Hospital NHS Trust, Minimal Access Therapy Training Unit, Guildford, United Kingdom

²Royal Surrey County Hospital NHS Trust, Anaesthetics, Guildford, United Kingdom

Background

ICG is a tricarboyanine dye with both hydrophilic and lipophilic properties. When injected intravenously it rapidly enters the circulation when it remains for 20-30 minutes. It is not excreted by the kidneys.

It absorbs light in the near infrared spectrum at around 800nm causing visible fluorescence (NIRF). With the wider availability of laparoscopic camera systems capable of delivering near infrared light interest has grown with regard to laparoscopic surgery and in particular the excision of deep infiltrating endometriosis.

It has been suggested that it is useful for the identification of ureters during pelvic surgery but as ICG is not excreted in the urine the only way it get it into the ureter is by cystoscopy, cannulation and retrograde injection. Under the circumstances it is often simpler to place a double J ureteric stent.

Methods

A standard laparoscopic technique is used with the exception that you require an ICG capable imaging system and laparoscope along with a light source which can generate near infrared light. ICG is given by intravenous injection in concentrations ranging from 0.1-0.3 mg/kg. It is identifiable in the major vessels after about 20-30 seconds eventually entering the peripheral circulation. At these concentrations multiple boluses can be given during the procedure. The maximum daily dose for adolescents, adults and the elderly is 5mg/kg body weight. Severe allergic reaction is extremely rare occurring in fewer than 1:10,000 patients.

Results

It is not necessary to perform cystoscopy, cannulate the ureteric orifices and carry out retrogrades with high concentration ICG to identify ureters laparoscopically. We demonstrate the use of intravenous ICG to assist in ureteric identification and to determine ureteric vascular viability following close dissection during the excision of deep infiltrating endometriosis.

Conclusions

When used intravenously ICG clearly demonstrates the ureters without the need for catheterisation and retrograde insufflation. There may be a role in determining ureteric vascular viability providing an indication regarding the requirement for ureteric stents post surgery.

Tools, techniques and instrumentation: transvaginal laparoscopic surgery

Masaaki Andou¹, Yoshifumi Ochi¹, Mari Sawada¹, Kiyoshi Kanno¹, Shintaro Sakate¹, Shiori Yanai¹
¹Kurashiki Medical Center, Gynecology, Kurashiki-shi, Japan

Background

Transvaginal surgery is one of the cornerstones of gynecologic surgery. This presentation will detail the techniques and tools we use for transvaginal surgery in benign and malignant pathology cases.

Methods

Case studies of techniques will be presented from 305 cases who underwent our transvaginal laparoscopic surgery including: hysterectomy, myomectomy, retroperitoneal lymphadenectomy and adnexectomy. Consent was gained to present and publish information on these cases on the condition of anonymity.

Our vaginal access technique is based on our experience of over 8,000 vaginal hysterectomies. The technical development of our transvaginal laparoscopic techniques will be shown along with variations of transvaginal laparoscopic surgeries. Cases will show the use of a variety of surgical techniques and different instrumentation, as well as the use of a transvaginal platform. Techniques will be described step-wise for instructional purposes.

In the first phase of 149 cases, we employed a flexible vaginal endoscope with one or two manipulation ports in the abdomen. This provided an excellent view of the pelvis similar to standard laparoscopy, but the control of the scope was difficult and had a high learning curve. For this reason, further techniques were explored.

In the second phase of 156 cases, a 30-degree rigid scope was used with no abdominal ports. Camera control proved easier and with no abdominal ports, the surgery was less invasive.

Results

The recovery rate of patients was quick and no patient required a conversion to laparotomy. Six cases were converted to a standard laparoscopic surgery due to adhesion or difficult vaginal access to the peritoneal cavity. No cases suffered from post-operative severe complications which required reoperation or blood transfusion.

Conclusions

Innovations in techniques and instrumentation in transvaginal laparoscopic surgery are presenting new possibilities for this ultra-minimally invasive technique. Although challenging, transvaginal laparoscopy is a patient friendly alternative for selected cases.

Radiofrequency ablation of submucosal myoma (FIGO 2 or 2-5) in young patients: efficiency - safety - fertility and obstetrical outcomes

Margaux Jegaden¹, Elodie Debras¹, Anne-Gaelle Pourcelot¹, Perrine Capmas¹, Hervé Fernandez¹
¹Bicetre Hospital, Gynecology, Le Kremlin Bicetre, France

Background

Myomas are the most frequent benign tumors. There are found in 5-10% of infertile patients. For submucosal myomas, myomectomy is beneficial for fertility. For large size myoma FIGO 2 or myoma FIGO 2-5, the indication for operative hysteroscopy is not always convincing. New minimal invasive techniques are being developed as an alternative to surgery. The technique of radiofrequency ablation (RF) has emerged as a safe, mini-invasive and effective treatment. RF using bipolar or monopolar energy may be delivered by a laparoscopic, transvaginal, or transcervical approach into the myoma to induce coagulative necrosis with subsequent reduction of its size, its impact on uterine cavity and in fibroid-related symptoms. Recent findings reported on obstetrical outcomes after RF myoma ablation may offer a safe and effective alternative for women who desire future fertility. In our center, we have performed on fourteen patient's RF myoma ablation for training. We performed a RF transvaginal approach with a needle and a monopolar energy electrode. The average age of the patients was 42.3 years. We targeted myomas that asked the most difficulty to manage. We treated 11 type 2-5 myomas between 3 and 9 cm, 1 type 2 myoma of 4 cm, and 2 type 5 myomas of 8 cm. Patients were reevaluated at 2 months and 6 months with ultrasound and hysterosonography to evaluate the impact of the myoma on uterine cavity. At two months, we noticed a complete non-vascularization of the myoma and an improvement of the menorrhagia. The decrease in the size of the fibroid was significant at 6 months (around 45%). It should be noted that the evolution of the FIGO classification of the myomas is noteworthy, since from a FIGO 2-5, certain fibroids, by reducing in size, became purely intra-mural FIGO 3, 4 or 5 or purely intracavitary FIGO 2 type with possible and easy hysteroscopic resection.

Methods

Patients included will be between 18 and 38 years old and with a desire for pregnancy. They must have a myoma with impact on the cavity and therefore on fertility. Their myomas will have to be either FIGO type 2 and superior to 3 cm or FIGO type 2-5 with maximum size of 8 cm. The patients will benefit from either transvaginal RF or laparoscopy RF with monopolar energy. Patients will be assessed at 3 months, 6 months and 12 months by ultrasound and by questionnaire (Uterine Fibroid Symptom Health-Related Quality of Life Questionnaire (UFS-QoL)). Fertility outcomes will include delay to conception, spontaneous or ART pregnancies, spontaneous abortion and obstetrical outcomes.

Results

In process

Conclusions

This study would prove that RF allows young patients to restore fertility, in case of intracavitary myomas without simple surgical solution, with efficiency and safety.

Diagnostic potential of DNA methylation detection for endometrial cancer in reproductive-aged women presenting with abnormal uterine bleeding

Xingping Zhao¹, Jiezhhi Ma¹, Dabao Xu¹

¹Third Xiangya Hospital of Central South University, Department of Gynecology, Changsha, China

Background

With the increasing incidence and early onset of endometrial cancer, there is a need for improved diagnostic methods in reproductive-aged women presenting with abnormal uterine bleeding (AUB). This study aims to evaluate the diagnostic potential of DNA methylation detection compared to other non-invasive approaches for endometrial cancer screening.

Methods

A prospective study was conducted involving 517 reproductive-aged women with AUB, who underwent hysteroscopy at a tertiary hospital. Cervical exfoliated cells were collected for cytology, human papillomavirus (HPV) testing, and DNA methylation analysis. Clinical information and transvaginal ultrasound measurements were also obtained. Univariate logistic regression and receiver operating characteristic curve analysis were performed to assess the risk factors and diagnostic efficacy of DNA methylation detection.

Results

Age, body mass index (BMI) ≥ 25 kg/m², endometrial thickness ≥ 11 mm, CDO1 Δ Ct ≤ 8.4 , CELF4 Δ Ct ≤ 8.8 , and combined gene methylation showed significant associations with endometrial cancer in young women ($p < 0.05$). The highest diagnostic accuracy (AUC = 0.90) for endometrial cancer was achieved with CDO1/CELF4 methylation testing. Sensitivity and specificity were 91.7% and 88.8%, respectively. Combining transvaginal ultrasound with DNA methylation testing improved sensitivity to 95.8% but decreased specificity to 68.0%.

Conclusions

DNA methylation detection in cervical cells provides enhanced accuracy for endometrial cancer diagnosis in reproductive-aged women with AUB. The combination of CDO1 and CELF4 methylation testing with transvaginal ultrasound improves sensitivity, highlighting its potential as a valuable screening approach.

Use of a patented anti-adhesion intrauterine stent after hysteroscopic adhesiolysis with ploughing technique

Dan Sun¹, Zhenkun Guan², Zengzi Zhou¹, Huan Huang¹, Dabao Xu¹

¹Third Xiangya Hospital of the Central South University, Obstetrics and Gynecology, Changsha, China

²Baylor College of Medicine, Obstetrics and Gynecology, Houston, USA

Background

To present the use of a patented anti-adhesion intrauterine stent (ChiCTR1900023728) after hysteroscopic adhesiolysis (HA) with ploughing technique [1] using cold scissors.

Methods

A 34-year-old woman, G₂P₀A₂, two missed abortions suffered two times of dilatation and curettage (D&C) which caused intrauterine adhesions (IUA). She complained of decreased menstrual volume after two times of HA at a local hospital. Our three-dimensional transvaginal ultrasound (3D-TVUS) revealed recurrence of IUA with a thin endometrium. HA was done with ploughing technique using cold scissors. After HA, the uterine cavity was restored, and bilateral tubal ostia were visualized. American Fertility Society (AFS) score was 8, and a medium size patented stent was installed into the uterine cavity. The size and position of the stent matched the uterine cavity very good at hysteroscopy. A follow-up hysteroscopy was performed three months postoperatively.

Results

The HA was performed successfully with no surgical complications. The patient was followed up with 3D-TVUS which revealed the stent being in right position and the endometrium recovered well. The 3-month postoperative follow-up hysteroscopy revealed no recurrence of the adhesion, and the stent was pulled out at hysteroscopy. One month after the follow up hysteroscopy the patient got pregnant and she is now at 4-month gestational age with a healthy fetus.

Conclusions

The patented intrauterine stent can prevent recurrence of IUA very effectively own to its special design especially the shape of the stent, which is worthy of further study.

Reference:

1. Zhang A, Jamail G, Xue M, et al. Hysteroscopic Intrauterine Adhesiolysis Using the "Ploughing" Technique With Cold Scissors. J Minim Invasive Gynecol. 2015; 22(6):934-5.

Rare case of synchronous primary cervical and endometrial cancer with ovarian metastasis

*Bingxin Cai*¹

¹*Gansu Provincial Maternity and Child Care Hospital, First Department of Gynecology, Lanzhou, China*

Background

The prevalence of multiple primary malignancies has significantly increased from 0.7% to 11.7% over the past few decades. Recent studies in China have reported an incidence of approximately 1% for multiple primary tumors. However, it is important to note that the current prevalence in China might be underestimated due to regional variations and limited case numbers. Synchronous primary cancers of the endometrium and cervix with different histomorphology are particularly rare in the female reproductive system. This study presents a unique case of synchronous primary endometrial and cervical cancer with ovarian metastasis. It includes detailed records of the diagnosis and treatment process, as well as the surgical procedure undertaken.

Methods

A 73-year-old Han woman was admitted with complaints of vaginal bleeding for two weeks, occasional lower abdominal discomfort, and dizziness. Serological tests revealed elevated levels of carcinoembryonic antigen and CA-125. TVS showed abnormalities in the uterine cavity and cervical canal. Pathological biopsy revealed the presence of inflammatory cells, consistent with endometrial cancer. Surgical and pathological results confirmed the tumor sites as follows: invasion of the muscle layer in the uterine cavity, adenocarcinoma in situ, and chronic cervicitis. To further investigate whether the cancer sites were primary or metastatic, we utilized a dual-gene methylation detection system (CISPOLY, China) to analyze the pathological tissues from different areas.

Results

In this case, both gene methylation technology and traditional histopathology were employed for simultaneous detection. The results of gene methylation analysis may provide further insights and assist in determining whether the reproductive tract tumors originate primarily or secondarily. Additionally, we observed positive gene methylation results in other sites, indicating molecular-level changes that have not yet manifested as tissue alterations. Essentially, the presence of positive methylation in other areas may suggest a potential cancer progression within a specific timeframe, which can serve as a basis for assessing the likelihood of cancer metastasis. However, further clinical cases are needed to substantiate the role of methylation in considering the possibility of cancer foci metastasis.

Conclusions

Accurately distinguishing between primary and secondary tumors and identifying potential metastases significantly impact the formulation of treatment strategies for clinicians. Therefore, the correct and prompt determination of whether a malignant tumor is primary has become increasingly crucial. In this case, the presence of independent primary endometrial and cervical cancer accompanied by ovarian metastases was confirmed through surgical pathology and immunohistochemistry. However, the methylation results obtained during pre- and post-treatment suggest the presence of additional cancer foci. Further exploration and future studies, involving a larger number of cases, are required to determine the most appropriate detection method and gain a deeper understanding of these findings.

Comparison of diagnostic accuracy of endometrial cancer detection in cervical and uterine exfoliated cells and tissue samples using methylated CDO1/CELF4 gene: protocol and pilot study

Mian Huang¹, Zhang Shen¹, Qiong Jin¹, Jun Lin¹, SanShan Wu¹, YuQin Xue²

¹The First Hospital of Fuzhou, Department of Gynecology, Fuzhou, China

²The First Hospital of Fuzhou, Department of Pathology, Fuzhou, China

Background

Endometrial cancer (EC) is one of the most common gynecologic cancers in developed countries. We explored the possibility of using CDO1 and CELF4 DNA methylation markers from endometrial brush and cervical scrapes compared to tissues for early detection of EC.

Methods

This protocol is reported in accordance with Standards for Reporting of Diagnostic Accuracy Studies (STARD) guidelines. Eligible women will be required to collect cervical exfoliated cells, cervical canal cells, and endometrial cells during routine hysteroscopic surgery. One fifth of the samples were collected for DNA methylation detection, and the other four fifths of the samples will be for cytology. Pairs of specialist cytologists, blinded to participant cancer status, will assess, and classify samples independently, with differences settled by consensus review or involving a third cytologist. Compare the results with the clinical results of standard diagnostic tests. The pilot study is done before the standard study. This pilot study is aimed at women undergoing hysterectomy. First, the cervix, cervical canal, and uterine cavity cells are taken, and corresponding tissues are collected for histopathology after surgery.

Results

In the pilot study, compared with surgical tissue pathology, the positive rates of CDO1 and CELF4 in cervical, cervical canal, and uterine cavity cells of 5 EC patients were 100%, but only EC tissue was positive, while other tissues were negative. The consistency of cytopathological results in uterine cavity, cervical canal, and cervix is less than 50%. The results of DNA methylation detection by brushing cells from different parts of uterine cavity and cervix are consistent and more accurate than cytology.

Conclusions

DNA methylation detection of exfoliated cells may be a new and reasonable EC female method. Non- and minimally invasive studies will be conducted based on the pilot study evidence.

Evaluation of serum and peritoneal fluid mannose-binding lectin associated serine protease-3, adipsin, properdin, and complement factor H levels in endometriosis patients

Merve Didem Eşkin Tanriverdi¹, Ecem Kaya Sezginer², Esin Merve Erol Koç¹, Özlem Moraloğlu Tekin¹

¹Ankara City Hospital, Gynecology and Obstetrics, Ankara, Turkey

²Ankara University Faculty of Pharmacy, Department of Biochemistry, Ankara, Turkey

Background

By evaluating the levels of mannose-binding lectin-associated serine protease-3 (MASP-3), adipsin, properdin, and complement factor H (CFH) in serum and peritoneal fluid of endometriosis patients, to reveal the possible role of these essential regulators of the alternative complement pathway in the etiopathogenesis of the disease and/or their potential to be an important marker in the diagnosis of the disease, thus using non-invasive methods.

Methods

In this prospective study, those who applied to the gynecology and infertility clinics of our hospital, between the ages of 18-44, and were diagnosed with endometriosis by ultrasonography and/or magnetic resonance imaging, 32 patients who were staging according to the revised American Society for Reproductive Medicine (rASRM) classification after applying to our clinic were included. As the control group, 26 healthy women of the same age range who applied to our clinic, and did not have any other gynecological and/or systemic diseases were included. Demographic-clinical characteristics of both groups, serum complete blood count, routine biochemical analysis, basal hormone profiles, C-reactive protein (CRP), lipid profile, and cancer antigen 125 (CA125) levels were analyzed. Moreover, serum in the control group; results, sensitivities, and specificities of serum and peritoneal fluid MASP-3, adipsin, properdin, and CFH in the endometriosis group were analyzed.

Results

In two groups similar to each other in terms of age, height, weight, body mass index (BMI), smoking, and alcohol use ($p>0.05$, for all values); while serum adipsin and CFH levels in the endometriosis group were significantly higher than in the control group ($p=0.027$ and $p=0.04$, respectively). In addition, a significant difference was found between the control group and the endometriosis group in serum prolactin (PRL), CA125, and mean corpuscular volume (MCV) ($p<0.001$, $p<0.001$, $p=0.033$, respectively). There was a statistically significant positive correlation between serum adipsin level and the level of serum MASP-3, CFH, properdin, PRL, and CA125 ($r=0.449$, $p=0.001$; $r=0.705$, $p<0.001$; $r=0.481$, $p=0.001$; $r=0.267$, $p=0.049$; $r=0.320$, $p=0.015$, respectively). There was a positive correlation between serum CFH level and serum MASP-3, properdin, and neutrophil count ($r=0.402$, $p=0.004$; $r=0.433$, $p=0.003$; $r=0.285$, $p=0.045$, respectively). In addition, a statistically significant positive correlation was found between peritoneal fluid adipsin level and peritoneal fluid CFH level ($r=0.593$, $p<0.001$). While the threshold value for serum adipsin in endometriosis was 16.6 ng/mL, sensitivity and specificity values were 59% and 60%, respectively; the threshold value for serum CFH in endometriosis was 159.6 ng/mL, sensitivity and specificity values were 60% and 60%, respectively. ($p=0.009$, $p=0.016$, respectively).

Conclusions

The results of our study indicate that serum adipsin and CFH levels may have an important role in the etiopathogenesis and/or diagnosis of the disease. Further studies are needed for a better understanding of endometriosis disease and to reveal new options for diagnosis and treatment.

Is a covering stoma required following bowel surgery for endometriosis?

Ria Kamboj¹, Jonathan Lewin², Oscar Cordero Llana¹, Oliver O'Donovan³

¹University of Bristol, Bristol Medical School, Bristol, United Kingdom

²University College London Hospitals NHS Foundation Trust, Obstetrics and Gynaecology, London, United Kingdom

³University Hospitals Bristol and Weston NHS Foundation Trust, Gynaecology, Bristol, United Kingdom

Background

Up to one third of patients with endometriosis may develop bowel infiltrating endometriosis. Following surgical excision, a covering stoma may be used to prevent life-threatening complications of anastomotic leak (AL) and fistula. This decision making is often made based on evidence from other diseases, namely colorectal malignancy, due to a paucity of endometriosis specific data. The aim of this study is to ascertain the incidence of these complications in this endometriosis population and inform appropriate use of a covering stoma.

Methods

A retrospective cohort analysis of prospectively collected data from the British Society of Gynaecological Endoscopy (BSGE) was used to identify and quantify rates of AL and fistula, alongside quantifying ostomy procedures. Binomial logistic regression was used to identify patient predictors for the risk of these complications as reported odds ratios.

Results

9433 endometriosis patients underwent bowel surgery between 2012-2021. A population of 5468 of these patients identified low rates of AL and fistula, at 0.6% and 0.3% respectively. Significant differences were identified between a bowel shave vs disc or segmental resection for presence of either complication. An increased odds ratio for AL after segmental resection in comparison to a bowel shave was identified (OR=6.475, CI [2.636-15.906], $p < 0.001$), whereas increased age was the only significant predictor for fistula formation (OR=1.132, CI [1.040-1.232], $p=0.004$). Presence of an intra-operative stoma was not found as a significant predictor for either complication.

Conclusions

This study shows the low risk of AL and fistula after bowel surgery in the endometriosis population but emphasises the use of a covering stoma as an individualised patient-tailored decision. Further endometriosis patient specific studies are warranted.

The use of mixed reality headsets to plan surgery and counsel patients with holograms of endometriosis lesions and fibroid uteri

Amr Magdi Mohamed Moneib¹, Mohamed Mabrouk²

¹Queen Elizabeth Hospital, Obstetrics and Gynecology, London, United Kingdom

²Cambridge University Hospital, Obstetrics and Gynecology, Cambridge, United Kingdom

Background

The objective of this study was to demonstrate the potential use of mixed reality headsets, specifically the Magic Leap headset, in preoperative planning and patient counseling for endometriosis lesions and fibroid uteri. The 3D models were designed by the author.

Methods

This was a proof-of-concept study that involved the creation of 3D models of endometriosis lesions and fibroid uteri using computer-aided design software and made by the author. These models were then loaded onto Mixed reality headsets and presented to and patients for evaluation and feedback.

Results

As a proof-of-concept study, no formal measurements or results were obtained. The study aimed to demonstrate the potential value of mixed reality headsets in preoperative planning and patient counseling for endometriosis lesions and fibroid uteri. Feedback from both surgeons and patients was positive, indicating the potential usefulness of this technology.

Conclusions

This proof-of-concept study demonstrated the potential value of mixed reality headsets, specifically the Magic Leap headset, in preoperative planning and patient counseling for endometriosis lesions and fibroid uteri. Further research is needed to determine the effectiveness of this technology in improving patient outcomes and the potential for broader application in other surgical specialties and patient populations.

First cases of vNOTES hysterectomy with spinal anaesthesia in Wallonia

Milana Dzeitova¹, Vincent Goffiou¹, Catherine Galopin¹, Aude Beliard¹

¹Centre Hospitalier du Bois de l'Abbaye CHBA, Department of Obstetrics and Gynaecology, Liège, Belgium

Background

This report aims to provide evidence that spinal anesthesia (SA) is a good alternative for general anesthesia (GA) in vaginal natural orifice transluminal endoscopic surgery (VNOTES) hysterectomy.

Methods

We describe the first two cases of total hysterectomy with bilateral salpingoopheractomy performed under spinal anesthesia in Wallonia. The first patient 44 years old was operated for a persistent HSIL lesion with two prior cervical conizations. The second patient 51 years old underwent surgery for abnormal uterine bleeding with history of uterine myomatosis. SA was executed in both patients in a sitting position. The anesthesiologist injected 12mg of hyperbaric MARCAINE® 0,5%, 3µg of SUFENTA® 5µg/mL and 75µg of CATAPRESSAN®. Both patients received intraoperative sedation with 2mg of MIDAZOLAM®. After putting the patients in a lithotomy position the surgeon accessed the abdominal cavity by making anterior and posterior colpotomy. A VNOTES port was inserted to create a pneumoperitoneum with a pressure of 4mmHg for the first patient (P1) and 3mmHg for the second patient (P2). A 15° Trendelenburg position was requested, and the uterus was dissected using bipolar coagulation. Uteri were extracted through the vagina although the second extraction was slightly more complex due to the myomas. Both surgeries lasted 33 minutes from the incision to the vaginal suture. P1 expressed light shoulder discomfort and the other one had no complaint. None of them expressed abdominal pain or postoperative nausea and vomiting (PONV) in the immediate postoperative period. On the following day P1 expressed abdominal pain and shoulder discomfort that she estimated at 7/10 on the visual analogue scale (VAS) and P2 estimated hers at 5/10. They were discharge after 24 hours.

Results

GA is the gold-standard method for VNOTES hysterectomy though it can cause many side effects and is anxiety-inducing for some patients. So far, VNOTES hysterectomy under SA has only been performed in Belgium by Jan Baekelandt and his team.

Spinal anesthesia is associated with few side effects easily prevented by an experienced anesthesiologist. SA is fast, easy to perform and associated with a low rate of failure. It has many advantages compared with GA such as diminished PONV, less postoperative pain, lesser use of painkillers. It allows faster mobilization and recovery along with an earlier discharge.

Conclusions

VNOTES hysterectomy performed under SA is manageable and safe. It allows better comfort for patients with less postoperative pain and PONV, and diminished use of painkillers. This type of surgery could be done as a day-care procedure at lower expenses.

Gynecologic surgery by Vaginal Natural Orifice Transluminal Endoscopic Surgery (vNOTES): our centre's experience

Marta L. Salgado¹, Carla Escribano¹, Herminda Gil¹, Sara Chao¹, Sara Quintana¹, Belén L. Viñas¹
¹Teresa Herrera Hospital, Obstetrics and Gynecology Department, A Coruña, Spain

Background

vNOTES is an emerging minimally invasive technique that combines the advantages of the vaginal and laparoscopic route, thus expanding the indications for vaginal surgery. vNOTES achieves a high rate of patient satisfaction, has aesthetic advantages, reduces postoperative pain and hospital stay. The objective of this study is to analyze vNOTES procedures in our Department since its implementation.

Methods

Retrospective descriptive observational study that includes patients undergoing vNOTES surgery in the Department of Obstetrics and Gynecology at Teresa Herrera Hospital, A Coruña, from March 2021 to April 2023. Baseline patient characteristics and clinical outcomes were analyzed.

Results

We include a total of 77 patients (n)

The mean age of our patients is 54 years. 24.7% of them are obese, three of them with a BMI > 40.

76.7% of patients have had one vaginal delivery at least.

Indications of surgeries were persistent cervical dysplasia (23.4%), adenocarcinoma in situ of cervix (7.8%), pelvic organ prolapse (11.7%), endometrial pathology (15.6%), symptomatic myomatous uterus (14.3%), risk-reducing adnexectomy (19.5%), sterilization (6.5%) and gender dysphoria (1,3%).

75,4% underwent hysterectomy and in 24,7 %, only adnexal surgery was performed.

The mean surgical time was 94 min, influenced by BMI, with statistical significance ($p < 0.05$).

The average length of stay was 2.18 days. 18.2% of surgeries did not require admission.

In 80.5% no complications or technical difficulties were reported during the procedure.

All intraoperative complications were minor. We observed retained pneumoperitoneum (3), poor surgical field (7), absence of pneumoperitoneum in cavity (2), superficial vulvar burn (3) and bleeding (1).

More than half of the intraoperative complications (53.3%) occurred in obese patients, with statistical significance ($p < 0.005$). All patients with BMI > 40 presented intraoperative complications.

Conversion rate to laparoscopy was 2.6%, due to poor surgical field.

Postoperative complications were reported in 11.7% of cases.

According to Clavien-Dindo Classification, 77.7% were grade I or II minor complications, which did not require exceptional measures. Two cases of grade III major complications were recorded, reoperation by laparoscopy in the early postoperative period due to haemoperitoneum, and one case of rectovaginal fistula diagnosed in the late postoperative period, which required low anterior resection. No grade IV or V complications were recorded.

95% of patients with normal weight had a suitable postoperative course. Statistically significant differences were found between the occurrence of postoperative complications and the presence of obesity ($p < 0.02$).

Conclusions

vNOTES surgery adds advantages to traditional laparoscopic and vaginal hysterectomy, including lower intra-abdominal pressure and Trendelenburg, absence of trocar-related injuries, and easier surgical access in patients with morbid obesity or prior abdominal surgery. It also allows safer and easier adnexal surgery by vaginal route. vNOTES technique is a safe and effective alternative to laparoscopy or laparotomy. 97.4% of our patients underwent a successful vNOTES surgery.

Investigation of a full body support to improve ergonomics and to reduce surgery related musculo skeletal problems for laparoscopists

Bernhard Krämer¹, Juergen Andress², Sascha Hoffmann¹, Felix Neis¹, Sara Brucker¹, Benjamin Steinhilber³

¹University Hospital of Tuebingen, Women`s Health, Tuebingen, Germany

²University of Tuebingen, Dept. for Women`s Health, Tuebingen, Germany

³University Hospital of Tuebingen, Occupational Health, Tuebingen, Germany

Background

Medical disciplines with a large spectrum of operations including endoscopic gynecology will inevitably face a shortage of surgeons in the next decade. This is due to several reasons such as night shifts and long working hours. Yet, mental and physical stress also contribute to this problem.

In the past, advancements in endoscopic surgery have primarily focused on patient benefits, however compared with open surgery, laparoscopic surgery imposes greater ergonomic constraints on surgeons.

Recent reports indicate a 73% to 88% prevalence of physical complaints among laparoscopic surgeons, which is higher than in the general working population, supporting the need to address the surgeons' physical health and to improve their working conditions.

Amongst other options a full body support could help to reduce surgery related musculo skeletal problems during laparoscopy.

Methods

We investigated the NOAC assistance system (Hellstern Medical, Germany) during gynecological laparoscopic surgery in a proof of principle setting under study conditions. The system has recently be made commercially available for daily practice. Its main features are a dynamic sitting position in combination with a support for the spine and the trunk without compromising the range of freedom for arm and hand movements thus enabling the operator to perform the full range of open and laparoscopic procedures all across the various specialties.

According to our previously published SOS-study we evaluated a series of objective ergonomic parameters that are an indicator for physical stress, muscle activity and fatigue in a collaboration with our Dept. for Occupational Health. Different surgeons with different levels of laparoscopic experience were analyzed while performing standardized (sub) total hysterectomies with and without the support system. Additionally, a questionnaire was given to the surgeons to collect their individual feedback in terms of handling and satisfaction.

Results

With the NOAC system the analyzed parameters of physical stress, muscle activity and fatigue were lower in comparison to the procedures without the support system. Muscle blood flow and oxygenation were relatively close to baseline with the system, but increased without NOAC. This could be observed for all levels of experience. The questionnaire analysis also revealed a high score for satisfaction and handling in the study group.

Conclusions

The full body support NOAC shows promising results to reduce physical stress and muscle fatigue in this proof of principle study during laparoscopy. If these results can be validated in further investigations the system has the potential to reduce work related musculo skeletal disorders which will be beneficial both for current and future generations of surgeons as their active professional life span can be expanded. Consequently, it may represent a valuable tool for hospital directives to fulfill their fiduciary duties.

Surgical skills assessment on a vNOTES simulation box when compared with a conventional endoscopic simulation box model; the SAVE trial

Rebecca Henschen¹, Ilse Bekkers², Nicol Smeets¹, Anne Damoiseaux³, Huib van Vliet³, Martine Wassen¹

¹Zuyderland Medical Centre, Gynaecology, Heerlen, The Netherlands

²Maastricht University Medical Centre, Gynaecology, Maastricht, The Netherlands

³Catharina Hospital, Gynaecology, Eindhoven, The Netherlands

Background

In recent years, significant advancements have been made in benign gynaecological surgery, particularly with the introduction of vaginal Natural Orifice Transluminal Endoscopic Surgery (vNOTES) (1). While vNOTES offers several advantages, it presents challenges concerning the challenges of single-port surgery because of the lack of “triangulation” and the crossing and clustering of instruments (2,3). With increasing interest in vNOTES, training methods to stimulate the learning curve for gynaecologists and residents is essential. However, there is no data known regarding laparoscopic training boxes on the utilization of vNOTES. This quantitative prospective study aims to address the knowledge gap by comparing three distinct groups, each with varying levels of laparoscopic experience, in their performance of validated surgical tasks on a laparoscopic (conventional; multi-port) box and vNOTES (single-port) box.

Methods

Three groups with different laparoscopic surgical experience participated in this study, respectively a group of medical students and gynaecological residents without laparoscopic experience (n=15), a group gynaecological resident with laparoscopic experience (n=15) and finally a group of expert gynaecologists (n=15). All groups performed four laparoscopic standardized skill tests (Pipe cleaner, Letter B, Cut the circle and Rubber band) alternately on the laparoscopic and the vNOTES training box (4). The total task time, number of penalties and overall scores were measured per task, box and group. Questionnaires with baseline characteristics, the laparoscopic surgical experience and cognitive working load (NASA Task Load Index scores) of both simulation box models were completed by the participants (5).

Results

This study included 35 females (77.8%) and 10 males (22.2%), with a mean age of 34.2 years (range: 22-63). Overall, superior performances were scored on the laparoscopic box compared to the vNOTES box for all four tasks, considering time, penalties, and total score. Additionally, the conventional laparoscopic box was favored for depth perception (n=39; 86.7%), hand-eye coordination (n=41; 91.1%), and instrument usage (n=44; 97.8%). Furthermore, vNOTES had higher scores on all cognitive domains of the NASA Task Load Index.

Conclusions

This study highlights the difficulties encountered in vNOTES compared to conventional laparoscopy across three different groups with varying surgical experience. Despite limitations like interobserver and intra-observer bias, validated standardized laparoscopic box exercises are found to be more challenging in vNOTES regarding depth perception, instrument utilization, hand-eye coordination and consequently cognitive load. There is a need to develop standardized vNOTES simulation box exercises. This can facilitate the learning curve and training for gynecologists and residents to perform vNOTES, which results in improved patient outcomes, reduced operative time and enhanced surgical proficiency.

RIP bulky uterus - a trainee's standardised approach to a hysterectomy

Juneida Khodabocus¹, Carol Munyame¹, Richard Hadwin¹

¹Portsmouth Hospital University NHS Trust, Gynaecology, Portsmouth, United Kingdom

Background

As a gynaecologist, a hysterectomy remains one of the most basic operations. Today, a hysterectomy (TH) can be performed vaginally (VH), abdominally (TAH), laparoscopically (TLH) and robotic-assisted (TRH). However, a trainee in gynaecology now only gets to perform that operation in their more senior years and hence, their exposure to hysterectomies including the management of more complex cases is not optimal.

Speaking for myself, I am currently in my 6th year of training in the UK and I have found it difficult to have maximum theatre exposure amidst rota shortages, strikes and the covid pandemic. Initially, I found it tricky to grasp the steps of a hysterectomy.

I thus devised this 6 steps-approach to a hysterectomy and bilateral salpingo-oophorectomy (TLH/BSO) that I found really useful.

Methods

To make it more memorable, I devised the mnemonic RIP Bulky UteRUS which is explained as follows:

1. **R** (Round Ligament ligation/division)
2. **IP** (InfundibuloPelvic ligament ligation/division)
3. **Bulky** (Bladder reflection)
4. **Ute** (Uterine vessels skeletonisation & ligation/division)
5. **RU** (Remove Uterus - Colpotomy)
6. **S** (Suturing of vaginal vault)

Results

I have used this approach for both TLH and TAH. For a TLH, doing the IPs before the round ligaments works better. The mnemonic can be re-adapted for only TLH where instead of the IPs, we perform the salpingectomies and ligate/divide the ovarian ligament.

I would like to present 3 particular following cases of different indications and complexities using this standardised-approach:

1. 49F with heavy menstrual bleeding, no previous abdominal surgery, BMI 42
2. 47F with chronic pelvic pain alleviated by GnRH analogues, significant surgical history including caesarean, laparoscopic appendectomy, laparoscopic sterilisation and abdominoplasty, BMI 25
3. 73F with grade 1 endometrial cancer, no previous surgery, BMI 27

I will demonstrate how after performing a diagnostic laparoscopy and restoring the anatomy (post adhesiolysis if any) that this 6-steps approach can be used by any trainee to perform a TLH/BSO. (Videos of the 3 cases will be presented)

Conclusions

Hence, as I am walking in to theatre to perform a TLH/BSO, my focus is on the following: "RIP Bulky UteRUS"

This is undeniably a simple yet very effective way to memorise the steps of a hysterectomy and I strongly believe it could be useful for many other trainees especially junior ones who are now learning to perform this basic gynaecological procedure.

Robotic vs laparoscopic surgery- ergonomics and time frame

Hira Fatima¹, Pinky Khatri¹, Samantha Hancock¹

¹*James Cook University Hospital, Gynae, Middlesbrough, United Kingdom*

Background

1. Background : Robotic is the future of minimal invasive surgery however many gynae surgeons prefer laparoscopic surgery. This is a comparison of ergonomics and time frame of these 2

Methods

1. Methods : Its a combination of retrospective and prospective study in which data was collected regarding intraoperative ergonomics, time frame of surgery, intraoperative complication if any and discharge timing of patient. Intraoperative timings were noted, operative notes and notes from ward round were reviewed.

Results

1. Results : The timing for anesthesia was not much different in both types of surgery. The docking time was 2 to 3 minutes in most cases of robotic surgeries. Post-op pain was reduced by 25% in robotic surgery as compared to laparoscopic surgery along with quick discharge (0.75 days on average) as compared to laparoscopic surgery.

Conclusions

Conclusions: Robotic surgery has better ergonomics, with less intraoperative complications, less post op pain and quicker discharge as compared to laparoscopic surgery.

Robotic-assisted laparoscopic surgery applications in gynaecological surgery: initial experience of 100 cases from a single console surgeon in Greece

Elias Tsakos¹, Emmanouil Xydias¹, Apostolos C. Ziogas², Kanelina Bimpa³, Nikolaos Vlachos⁴

¹*Embryoclinic, Department of Robotic surgery, Thessaloniki, Greece*

²*University of Thessaly- School of Health Sciences, Department of Medicine, Larissa, Greece*

³*Embryoclinic, Department of Breast Surgery, Thessaloniki, Greece*

⁴*National and Kapodistrial University of Athens- School of Medicine, Department of Obstetrics and Gynaecology, Athens, Greece*

Background

Robotic surgery has been a rapidly developing field in recent years, particularly as far as Gynaecological Surgery is concerned. The robotic equipment was designed to surpass the limitation of conventional laparoscopy, providing superior, three-dimensional visualization of the surgical site, increased magnification of areas of interest, enhanced dexterity via highly articulating surgical instruments and absent tremor. Since the introduction of Robotic Gynaecological Surgery in Greece, public interest on the new technique has been growing. In this retrospective study, we present our experience with the first 100 cases that underwent robotic surgery on the ground of gynaecological pathology by a single, experienced surgeon in a private centre in Greece.

Methods

This is a retrospective case series including the first 100 patients treated using robotic-assisted surgery by our team. All patients operated on from January 1st, to May 20th 2023 were included. All procedures were conducted by the same, trained and certified lead Console Surgeon (E.T.), using the Da Vinci X Surgical System. Data was collected based on the hospital files and analyzed using the SPSS Statistical Processing Software.

Results

In total 40 hysterectomies for benign etiology, 37 myomectomies, 15 hysterectomies for malignant etiology, 5 subtotal hysterectomies and sacrocolpopexies and 3 oophorectomies and/or salpingectomies were included in the study. On average, patients were 48.35 years of age, with individuals ranging from 24.6 to 84.6 years. Patient mean BMI was 27.34 with patients ranging from normal weight to morbid obesity. Overall, for all patients, mean operative time was 155.23±46.5 minutes, mean estimated blood loss 64.3±48.04 ml, mean hemoglobin decrease 1.54±0.81 g/dl, mean length of stay 1.76±0.69 days, one patient required transfusion and 18 patients experienced complications, with only 2 of those being severe enough to require further intervention.

Conclusions

These findings are indicative of the effectiveness, safety and applicability of robotic surgery in multiple, various gynaecological surgical procedures. The precise control, elimination of tremours and 3D visualization allow for substantially decreased surgical trauma and lead to improved outcomes. In our experience, robotic surgery is the safest option for high risk patients, such as those with severe underlying pathology, comorbidities or those who refuse transfusions. The successful completion of the first 100 robotic surgery cases constitutes a stepping stone for further expansion and study of robotic surgery. Future research from our team will focus on comparative studies of robotic surgery and other minimally invasive options with regard to clinical and quality of life outcomes.

Effectiveness of relugolix combination therapy: clinical and surgical outcomes of an Italian real life experience

Fedora Ambrosetti¹, Fabiola Nardelli², Sabrina Reppuccia², Brunella Zizolfi², Alessandra Gallo², Maria Chiara De Angelis²

¹University of Modena and Reggio Emilia,

Department of Medical and Surgical Sciences for Mother- Child and Adult, Modena, Italy

²University of Naples Federico II, Department of Public Health, Naples, Italy

Background

The objective of this study was to evaluate the effectiveness, tolerability and surgical advantages of the recently released GnRH-antagonist combination therapy (RelugolixCT), containing estradiol 1 mg and norethindrone acetate 0.5mg, in patients with heavy menstrual bleeding (HMB) and uterine myomas.

Methods

we performed a retrospective observational study, enrolling premenopausal women of at least 18 years of age presenting with uterine myomas associated with HMB and referring to our outpatient clinic at University Hospital Federico II of Naples from Jun 1, 2022, to May 12, 2023. Clinical and pathological data were obtained from clinical records. Transvaginal ultrasound assessment was performed in all women. HMB was diagnosed with a score higher than 100 using the Pictorial Blood Assessment Chart scoring system and corresponding to >80ml of blood loss. Dysmenorrhea was registered using a visual analogue scale (VAS 0-10). Follow up visits were performed after 3 and 6 months of therapy.

Results

A total of 37 women who received pharmacological therapy with Relugolix-CT were initially included, while 2 patients were excluded from the final analysis. The mean age was 45.0 years old, ranging from 26 to 53 years, 20.0% of patients had previously been treated with GnRH-agonists and 42.9% of women had laparoscopic (LPS) or hysteroscopic (HYS) myomectomies in the past.

All patients reported HMB with a mean PBACscore was 292.5 (SD ± 73.6) and a hemoglobin value of 11,5g/dl (SD ±1.7).

After one month of therapy 23 out of 29 patients (79.3%) referred amenorrhea or spotting; the same was registered by 20 out of 25 patients (80.0%) after 3 and by 13 out of 13 patients (100%) after 6 months. Only two women reported HMB (PBACscore: 260 ± 180.6) at 3 months. Hemoglobin value was 12,6g/dl (SD ± 1.6) at 3 months follow up and 13.6g/dl (SD ± 1.4) at 6 months. A reduction in dysmenorrhea was registered as well, passing from a VAS of 6.8 in the 83.8% of patients to a VAS: 4 in the 40.0% of cases. 12 patients out of 27 (44.5%) referred minor adverse events, mainly mild vasomotor symptoms (18.5%) or mild headache (14.8%).

5 patients (20%) underwent LPS or HYS myomectomies after 3 months of therapy, with reduced intraoperatory bleeding and a promptly detachable fovea appearance. No patients required a second step myomectomy and they were all dismissed without post operatory complications.

Conclusions

our data confirm Relugolix-CT as a safe and effective therapy in women with uterine myomas suffering with HMB, with a promising clinical profile. Once it is becoming a widely available opportunity, further studies on larger populations are needed to evaluate the possible use of this drug as preoperatory treatment not only in perimenopausal women, but also for patients in their fertile age.

Hysteroscopic myomectomy and postoperative pain

Emilie Ben-Ezry¹, Shir Lev¹, Ram Kerner¹, Ran Keidar¹, Ron Sagiv¹, Ohad Gluck¹
¹Edith Wolfson Medical Center, Obstetrics and Gynecology, Holon, Israel

Background

To study the correlation between fibroid size and FIGO stage to post hysteroscopic myomectomy pain and opioid use.

Methods

A retrospective cohort study of patients who underwent hysteroscopic myomectomy at our institute between January 2008 and October 2022.

The number, size, location, and FIGO classification (0,1, and 2) of myomas were obtained.

Pain levels according to visual analog scale (VAS) and analgesia used at the recovery unit postoperatively were also reviewed.

We classified the population according to fibroid size, and also according to FIGO classification.

Postoperative pain, opioids use, and procedure time were compared between the groups.

Results

Overall, 158 patients were included: group 1- up 20 mm (n=57), group 2- 20-40 mm (n=148), and group 3, 40 mm and above (n=26). Group 3 had a higher VAS score (group 3- 1.9 , group 2- 1.4, group 1-0.8, p=0.03), longer procedure time (group 3- 27.3 min, group 2- 20.0 min, group 1-16.8 min, p=0.02) and higher rate of blood transfusion (group 3- 7.7%, group 2- 0%, group 1-0%, p=0.02) compared to groups 2 and 1.

Interestingly, group 3 did not had a statistically significant higher rate of opioid use nor complication rate.

The study population was similarly analyzed according to FIGO classification: there was no significant difference between the groups in VAS score, opioids use, duration of the procedure, blood transfusion or complication rate.

Conclusions

The level of postoperative pain after hysteroscopic myomectomy is associated with fibroid size but not with the FIGO classification

Reproductive outcome after operative hysteroscopy for intrauterine adhesions in women above 38 years: 10 years of retrospective observational data

Aysha Almentheri¹, Margaux Jegaden¹, Cecile Bleas¹, Elodie Debras¹, Perrine Capmas², Herve Fernandez³

¹Bicetre Hospital- GHU Sud- AP-HP, Gynecology and Obstetrics Department, Paris, France

²Bicetre Hospital- GHU Sud- AP-HP- 3.

Centre of research in epidemiology and population health CESP- UMR1018- Inserm- Paris Saclay University- Hôpital Paul Brousse- 16 avenue Paul Vaillant Couturier F-94816- Villejuif- France.,
Gynecology and Obstetrics Department, Paris, France

³Centre of research in epidemiology and population health CESP- UMR1018- Inserm- Paris Saclay University- Hôpital Paul Brousse- 16 avenue Paul Vaillant Couturier F-94816- Villejuif- France.,
Gynecology and Obstetrics Department- Bicetre Hospital- GHU Sud- AP-HP- 78 avenue du Général Leclerc- F-94276- Le Kremlin Bicetre- France. 2. Paris Saclay University- 78 avenue du Général Leclerc- F-94276- Le Kremlin Bicetre- France, Paris, France

Background

Despite Asherman's syndrome (AS) has been described a century ago, the prevention and the ideal treatment are not well established. The operative hysteroscopy is considered as the gold standard and aims to restore the intrauterine anatomy and potentially the physiology of the uterine cavity and reproductive function. Several procedures are sometimes needed.

The aim of this study was to assess the outcomes of operative hysteroscopy management of IUA in women over 38 years of age with a pregnancy desire.

Methods

This is a retrospective cohort study including 99 women over 38 years old who had undergone operative hysteroscopy for intrauterine adhesions (IUA) from January 2010 to May 2020, and had reproductive desire. Groups were defined according to the number of operative hysteroscopy performed as unique (n=63) or multiples (n=36). The main outcome was occurrence of intrauterine pregnancy and live birth rate after operative hysteroscopy

Results

The outcomes were analyzed according to the number of operative hysteroscopy performed, as unique or multiples (3.3±1.2). A total of 141 women were included and among those 42 were loss to follow-up (29%), 63 out of 99 women (63.6%) had a unique procedure, and 36 had two or more operative hysteroscopy. The general pregnancy rate was 30.3% and live birth rate was 14.1%. The pregnancy rates were higher in patients who had single procedure (38.1%) compared to multiple (16.7%, p=0.026). A logistic regression model confirmed the multiple operative hysteroscopy procedures was an independent factor inversely associated to pregnancy success, adjusted for women age.

Conclusions

We have demonstrated the operative hysteroscopy for women over 38 years of age with reproductive desire is an effective approach for treatment of intrauterine adhesions, which improve the chances of pregnancy and live birth. We obtained a pregnancy rate of 30.3% and live birth rate of 14.1% for women older than 38 years of age after operative hysteroscopy for IUA. However, women have a higher rate of miscarriage, and age and number of procedures are predictive factors of subsequent reproductive success.

This study is one of the most powerful currently published which specific data for the subgroup of women above 38 years.

10 Steps in the successful conservative surgical management of prolapsed submucous myoma

Margarita Cantor¹, Maria Rica Baltazar²

¹Quirino Memorial Medical Center, Obstetrics and Gynecology, Quezon City, Philippines

²Quirino Memoria Medical Center, Obstetrics and Gynecology, Quezon City, Philippines

Background

Leiomyoma are common benign smooth muscle tumors and have several types. The pedunculated submucous myomas have the chance of prolapse. Vaginal myomectomy has been the definitive surgical treatment of patients with prolapsed submucous myoma. However, there were incidences of hemorrhage, recurrence and non-puerperal uterine inversion due to remaining pedicle. The aim of this review is to present a standard and sequential minimally invasive procedure that can preserve the uterus. We enumerated the procedure in 10 steps that is clear and organized to be easily performed by surgeons.

Methods

The patient presented with a prolapsing submucous leiomyoma and opted for a conservative surgical management. She was admitted in a tertiary government hospital in the Philippines. The planned procedure was vaginal myomectomy followed by hysteroscopic resection of the remaining pedicle of the myoma.

Results

In this review, the author summarizes the technique which is a sequential approach on the conservative management of prolapsed submucous myoma. An easier and safer surgical procedure that is divided into 10 steps: 1. Assessment of the size and mobility of the prolapsed submucous myoma 2. Assessment of the accessibility of the pedicle of the prolapsed submucous myoma 3. Perform Diagnostic Hysteroscopy in order to identify the pathology and topography of the uterus 4. Devascularization of the prolapsed submucous myoma 5. Detachment (Figure 1) 6. Removal of the myoma 7. Sealing off the dilated cervix with nipple bottle (Figure 2) 8. Injecting vasoconstrictor to the cervical lip 9. Hysteroscopic resection of the remaining pedicle of the myoma (Figure 3) 10. Hemostasis

Conclusions

The stepwise procedure of vaginal myomectomy followed by Hysteroscopic resection of the remaining pedicle of the submucous myoma could be a standard surgical management for patients who opts to preserve their uterus. The 10 steps described may help other surgeons plan and perform their surgery easier and safer. Innovative materials like the use of silicone nipple bottle may be utilized to overcome the dilated cervix during hysteroscopy.

Patient's satisfaction considering office hysteroscopy using lidocaine termogel 4%: short-acting lidocaine technology (SHACT) – a multicentre study

Maria João Carvalho¹, Pedro Pinto², Irina Ramilo³, Fátima Faustino³, Margarida Martinho², Fernanda Águas⁴
¹*Centro Hospitalar e Universitário de Coimbra- University Clinic of Gynecology- iCBR- CIMAGO and CIBB- Faculty of Medicina- Coimbra University- Academic Clinic Centre of Coimbra., Gynecology Service, Coimbra, Portugal*
²*Centro Hospitalar e Universitário de São João, Gynecology Department, Oporto, Portugal*
³*Hospital dos Lusíadas, Gynecology Department, Lisbon, Portugal*
⁴*Centro Hospitalar e Universitário de Coimbra, Gynecology Service, Coimbra, Portugal*

Background

Hysteroscopy is considered the gold standard for intracavitary evaluation in both pre- and postmenopausal patients with abnormal uterine bleeding and in infertility patients with suspected cavity lesions. Office-based operative hysteroscopy integrates clinical practice into a “see and treat” modality, avoiding the risks of anaesthesia and inconvenience of going to the operating room. The evidence supports the use of some pharmacological strategies for reducing pain during office hysteroscopy but the recommended approach (or combined approaches) is not still established. The aim of this study was to evaluate patient's satisfaction regarding the new lidocaine termogel 4% short-acting lidocaine technology (SHACT) in office hysteroscopy.

Methods

This multicentre study included an exploratory questionnaire performed in office hysteroscopy patients under local anaesthesia with lidocaine termogel 4% (Lidbree™). The questionnaire included clinical and epidemiological data, as well as expected and experienced pain and global satisfaction rates. Pain was scored using visual analogue scale (VAS) from 1 to 10 and statistical analysis was performed with SPSS 29.0.

Results

A total of 34 patients were included, median age 51 [24-86], most with higher education level. This population was mainly overweighted, median BMI: 25,11 [19.8-37.9], had a history of vaginal delivery (61%, n=21) and around one-fourth were nulliparous. Participants mentioned dysmenorrhea in 75% (n=25) that most often caused pain of intensity 3-4 in VAS. Suspected intracavitary abnormalities were the main indication. Before the exam, many women mentioned expected pain above 5 (VAS). Most admitted intense and extreme anxiety associated with hysteroscopy (n=20). After performing the procedure, the experienced pain was distributed more frequently in values below 4 (VAS), only 3 cases reported lipothymia. The pain was equal or less than expected in 74% (n=25). The satisfaction rate was 85% (n=29) and the degree of satisfaction, was associated with BMI (p=0.02), anxiety (p=0.04) and experienced pain (p<0.001).

Conclusions

The study revealed a high satisfaction rate with the new lidocaine termogel 4%, namely influenced by technical difficulties and anxiety. We aim to define in the future the characteristics of the patient that will most benefit from lidocaine termogel and proof a strategy for failed procedures in office setting.

Proliferative endometrium in postmenopausal women: a survey of clinical practice amongst hysteroscopists

Sivanandana Korrapati¹, Sakunthala Tirumuru²

¹Royal Wolverhampton NHS Trust- Wolverhampton- UK, Gynaecology, SUTTON COLDFIELD, United Kingdom

²Royal Wolverhampton NHS Trust, Gynaecology, Wolverhampton, United Kingdom

Background

The endometrium becomes atrophic after the menopause due to lack of oestrogen. Estrogenic effect on the endometrium results in proliferative changes which are routinely seen in the premenopausal state but are not usually expected to be present in the postmenopausal period. Unspecified proportion of postmenopausal endometria which, despite being atrophic, retain a weak proliferative pattern for many years, probably as a response to continuous low level oestrogenic stimulation. There are few studies that reported development of endometrial atypia/cancer in the long term from proliferative endometrium.

As there are no national guidelines for management of proliferative endometrium in postmenopausal women, we conducted a short survey amongst hysteroscopists to evaluate the current clinical practice.

Methods

The survey was performed at BSGE ambulatory care network meeting in February 2023. Hard copy of survey forms was given to the hysteroscopists who attended the meeting and data was compiled from those filled forms.

Results

A total of 47 hysteroscopists filled the survey forms. 25 were consultant gynaecologists, 3 were specialty doctors, 5 were trainees, 14 were nurse specialists. Looking at their experience in gynaecology, 6 had ≥ 10 yrs, 19 people had 11-20 yrs and 9 had >20 yrs of experience in gynaecology. 13/27 (28%) did not mention their gynaecological experience. 28 hysteroscopists (60%) stated that they would treat proliferative endometrium using Mirena, one with oral progesterone and the remaining 18 would reassure and discharge the patient. Of the hysteroscopists who would offer treatment, the majority (71%) opted for a treatment duration of 6 months, 17% for 3 months, 11% for 5 years, 4% for 6 wks. 24 hysteroscopists would do a repeat biopsy and four wouldn't do a biopsy and leave the mirena in situ. Out of the 24 hysteroscopists who opted to offer follow-up, 15 would follow up these women in 6 months, 3 in 3 months, 2 in 4 months, 4 in a year. When asked about treating recurrent PMB, majority (26/47) said they would offer IUS, 8 would offer hysterectomy. Most of them (33/47) said they would counsel women of increased risk of endometrial pathology with proliferative endometrium. Only 9 (19%) hysteroscopists have encountered proliferative endometrium developing into cancer.

Conclusions

This survey reflects current trends in the management of proliferative endometrium in postmenopausal women and highlights lack of evidence-based guidelines in this area. A multicentre study is needed to review the management and outcome for these patients.

We recommend that postmenopausal women with proliferative changes in the endometrium are counselled about the increased risk of progression to hyperplasia and cancer. Decisions about treatment and follow-up should be made on case-by case basis, considering any additional risk factors for endometrial pathology and patient's wishes.

To evaluate the reproductive outcome and potential enhancement of using Intrauterine Bigatti Shaver for surgical management of RPOC in patients who desire subsequent pregnancies

Shahrzad Ansari¹

¹committee member of international department of National Iranian association of gynecologists and obstetricians, Day General Hospital-surgery unit, Tehran, Iran

Background

Retained product of conception complicates nearly 1% of pregnancies. Traditionally, the surgical treatment of placental remnants has been dilation and curettage (D&C). However, because of its 'blind' nature there is a risk of serious complications, such as infection, perforation and adhesion. For patients with infertility who desire subsequent pregnancies, all these risks should be avoided. The patient wants to get pregnant as soon as possible. Therefore, the importance of preserving fertility obliged infertility specialists to find the best treatment option.

In this study, we evaluated the efficacy and reproductive outcome of operative hysteroscopy, using the Intrauterine Bigatti Shaver (IBS®) for the treatment of placental remnants.

Methods
This unicentric retrospective study included 244 patients with retained products of conception (RPOC) some of whom desired subsequent pregnancies others suffered from infertility. They all underwent operative hysteroscopy using the Intrauterine Bigatti shaver. The study took place between December 2013 and March 2023 .

Placental remnants occurred after 225 early miscarriages, 15 terminations of pregnancy, 1 vaginal delivery and 3 cesarean deliveries.

86 patients had type 0 RPOC, 135 patients had type 1 and type 2 RPOC and 23 patients had type 3 RPOC.

All cases were diagnosed with transvaginal ultrasound and doppler study. All surgeries were performed and followed up by the same surgeon.

Results
The median interval between surgery and the end of pregnancy was 59 days (range, 15-90 days). The median total surgery time was 4.5 minutes.

Postoperative ultrasound confirmed complete evacuation of the retained products in all patients.

In total 228 (93.5%) patients became pregnant after surgery.

169 (69%) patients fell pregnant with IVF. Among them, 157 patients successfully delivered and 12 patients have ongoing pregnancy. 59 (24%) patients became pregnant spontaneously. Among them, 51 have delivered and 8 have ongoing pregnancies .

16 (6.5%) patients did not conceive until 8 months after surgery. 1 patient with type 3 RPOC developed Asherman syndrome after hysteroscopic removal of retained product, and didn't conceive even after hysteroscopic removal of adhesions. 15 patients did not follow up. However, their control ultrasound was normal. Intra uterine anomalies were diagnosed in 16 patients during the hysteroscopic procedure which were treated during the procedure. Those anomalies were the possible cause of miscarriage. 12 patients had polyps which were removed with the shaver at the same time as removing RPOC.

Conclusions

The IBS seems to be an effective and safe technique for removal of placental remnants in patients with infertility who desire subsequent pregnancies. It seems to enhance reproductive outcome. This technique has a high rate of complete removal and a low chance of intra uterine adhesion with the possibility to treat other intrauterine pathologies at the same time. Hence, it would be an ideal technique for management of RPOC specially for patients with infertility .

NMDA-receptor encephalitis in a 23 years old presenting with bilateral ovarian teratoma with a favourable outcome

Rasha Abdeldayem¹, Dimitrios Miligkos¹, Pandora Bibby¹

¹University hospital of Southampton, gynaecology department, Southampton, United Kingdom

Background

Anti-NMDA-receptor encephalitis is a severe neuropsychiatric disorder with autoimmune and paraneoplastic features. NMDA-Rs are found in the forebrain and hippocampus and are involved in learning and memory. Antibodies target the NR1 subunit of NMDA-Rs in this condition, resulting in NMDA-R internalisation and a progressive decrease in NMDA-R-associated synaptic activities. Individuals suffering from anti-NMDA-R encephalitis experience psychiatric symptoms such as agitation and severe central hypoventilation, which frequently necessitates ventilatory assistance. It can also cause oral facial dyskinesia, emotional disruption, psychosis, hallucinations, memory loss, seizures, vegetative dysregulation, and autonomic dysfunction.

An aetiology for this potentially fatal disease may be suggested by the availability of a novel assay to measure these antibodies; if caught early, surgery can be performed with a good likelihood of a positive clinical outcome.

Methods

The case of a 23-year-old nulliparous English female with no significant past medical history apart from reported learning difficulties, presented to Southampton General Hospital with bilateral ovarian teratomas and CSF NMDA Ab positivity who developed psychosis as a result. During the course of three weeks, she began experiencing symptoms. the course of the disease explained in details.

Results

The presence of a tumour, rapid treatment, and no need for intensive care unit admission are cited as positive prognostic indications.

The diagnosis may be delayed as primary psychiatric illnesses and infective encephalitis are more likely to be considered and cleared out before this condition is considered.

Conclusions

In conclusion, ovarian teratoma linked with autoimmune anti-NMDAR encephalitis is an extremely unusual and difficult case. Experts in gynaecology, neuroscience, psychiatry, and intensive care were needed for the clinical approach. The importance of early identification and interdisciplinary management is shown by the favourable response to both medicinal and surgical treatment.

In order to develop earlier and more consistent diagnosis and therapy, more multicenter research is required. Anti-NMDA-R encephalitis has been documented in more and more journals in recent years, but there is currently no accepted standard of care for postoperative rehabilitation; instead, patients are treated individually. Our patient's example highlights the need for interdisciplinary care in the treatment of this uncommon illness, as well as the development of innovative rehabilitation therapy regimens to facilitate full recovery.

The deep uterine vein: a re-appraisal for a crucial anatomical landmark for pelvic surgeon

Krystal Nyangoh Timoh¹, Fabien Robin², Ludivine Dion¹, Vincent Lavoue¹, Xavier Morandi³

¹CHU Rennes, Gynecology Obstetrics, Rennes, France

²CHU Rennes, digestive surgery, Rennes, France

³CHU Rennes, neurosurgery, Rennes, France

Background

Pelvic radical gynecological surgery can be a source of complications related to pelvic nerves injuries. The deep uterine vein (DUV) has been identified as a key anatomical landmark. However there is a lack of clear description in anatomical terminology. This study aimed to provide a precise description of the DUV

Methods

A systematic review of the literature was conducted using PUBMED and EMBASE according to the "PRISMA" guidelines. The anatomical study consisted of a dissection study on cadaveric subjects and a radio-anatomical study of subjects from the Anatomage table.

Results

Originating from the convergence of cervical, vesical, and vaginal veins, the DUV follows a path in the paracervix, downwards and backwards, until its termination in the internal iliac vein. The DUV divides the lateral region of the uterus into : an upper vascular part, including the uterine artery and the ureter, and a lower nervous part below the level of the DUV, corresponding to the autonomic nervous tract.

Conclusions

A deep anatomical knowledge of the subperitoneal space is essential for the pelvic surgeon to avoid postoperative complications. The vasculonervous relationships of the DUV confirm its relevance as a significant surgical landmark for nerve and ureter preservation.

Assesment of the quality of life after surgical colpoptosis for Kuster-Rokitansky-Mayer-Hauser syndrome

Alexander Pak¹, Kadirjan Ussenov¹

¹*Academy of Health Private Hospital, Gynecology, Almati, Kazakhstan*

²*Baku Branch of Sechenov Medical University, Obstetrics and Gynecology, Baku, Azerbaijan*

Background

The genital malformations are becoming more actual. According to the latest data, 1:5000 girls has congenital atresia or aplasia of the genital organs. Unfavorable ecology and many other teratogenic harmful factors lead to a steady increase in the rate of this pathology. Without threatening life, such lesions do not allow the patient to realize their sexual function and cause severe negative experiences. Our goal was to evaluate quality of life in early after surgical colpoptosis for Mayer-Rokitansky-Küster-Hauser syndrome.

Methods

11 patients with laparoscopic colpoptosis were included. Ten of them were operated by modified Davidov and in one case neovagina was created of colon.

All data, including a complete medical history, examination, laboratory and instrumental studies (ultrasound, CT, MRI), photo and video materials, were stored in a common database of patients. This served as an opportunity for a more thorough and complete review of the study and disclosure of this topic.

In order to evaluate their quality of life, the patients received questionnaire consisted of 6 points, which included issues concerning 1) any postoperative complications, 2) period of bougienage, 3) fear or embarrassment before the start of sexual life, 4) discomfort during intercourse, 5) self estimated rate of libido and 6) quality of life (QOL).

Results

There was only 1 (9%) case of a late postoperative complication such as an unpleasant odor (formation of neocolpoptosis from the descending colon). In 8 women (72%) bougienage lasted from 6 to 18 months until the onset of sexual activity. 3 (27%) continue to bougie to the present (no sexual activity). Fear and discomfort during the first sexual intercourse after surgery was observed in 8 cases (72%). The first sexual intercourse after the operation was painful in 5 (45%) patients. Afterwards none of them mentioned any discomfort or pain. The level of libidowas estimated from 5-9 points, but for those who were sexually active, it was significantly higher: 7-9 points vs 5-6 points. The QOL improved markedly in all 11 (100%) operated women: 6-8 points (sexually active) vs 4-6 points (no sexual life). The main disturbing problem for all of them 100% was impossibility of childbearing.

Conclusions

Based on the study it can be concluded that, according to all the criteria of the selected questions, the quality of life of all women operated for Mayer-Rokitansky-Küster-Hauser Syndrome has changed for the better, with the main positive goal achieved as an ability to have sex. The only sensitive problem for all respondents was the impossibility of reproductive plans in the future, with the exception of surrogate motherhood.

Metroplastics for isthmocele: our experience

Rustam Borzgaliev¹

¹*Daru Zharygy Clinic, Obstetrics and Gynecology, Aktobe, Kazakhstan*

²*Baku Branch of Sechenov Medical University, Obstetrics and Gynecology, Baku, Azerbaijan*

Background

Caesarean section is one of the most common surgical procedures in the world, while the frequency of its performance continues to increase. According to WHO recommendations, it is considered to be an ideal indicator of the frequency of cesarean section in the range of 10-15%. Failure of the scar after cesarean section can cause complications during pregnancy and childbirth, such as abnormal attachment of the placenta, pregnancy in the scar, bleeding and rupture of the uterus.

Methods

When each patient with isthmocele was admitted to the hospital for correction of isthmocele, a questionnaire was conducted, the purpose of which was to identify additional factors of the occurrence of isthmocele. In our department, corrections of the isthmocele by laparoscopic access and hysteroresectoscopy were performed.

Results

On the basis of the endovideosurgical department of the Daru Zharygy clinic in Aktobe for 2 years, from January 2021 to December 2022, 22 surgical corrections of the isthmocele were performed. Laparoscopic correction of isthmocele – 21, hysteroresectoscopy – 1. The average age of the patients was 32.1 years. The number of patients with isthmocele after a single cesarean section is 50% (n-11). The thickness of the myometrium in the scar area is from 0.59 mm to 2 mm. The number of patients with isthmocele who underwent cesarean section at full term and before labour was 59% (n-13). 36% (n-8) of patients after cesarean section had symptoms of purulent-septic infections. In 45% (n-10) of patients, cesarean section was performed by experienced obstetricians with more than 20 years of experience. After 21 laparoscopic and 1 hysteroresectoscopic correction of the isthmocele, 91% (n-20) patients had a positive result in the absence of symptoms of the isthmocele, 9% (n-2) patients had a relapse of the isthmocele

Conclusions

Based on the performed operations of laparoscopic correction of the isthmocele in our department, its high efficiency of 91% was revealed. Metroplasty surgery for isthmocele is indicated as a prevention of complications such as implantation of the fetal egg in the scar, rupture of the uterus along the scar, abnormal uterine bleeding, chronic pelvic pain, as well as to restore reproductive function and to prepare for the IVF program.

Management of tubal ectopic pregnancies with methotrexate: an effective treatment?

Maurine DUJARDIN¹, Marie Timmermans¹, François Closon¹, Laurent De Landsheere¹, Michelle Nisolle¹
¹CHU of Liege, Obstetrics and Gynecology Department Citadelle, Liège, Belgium

Background

Ectopic pregnancy (EP) is a gynecological emergency. Serum hCG (human chorionic gonadotropin) level, clinical status and ultrasound assessment remain the gold standard for diagnosis. The criteria tend to be more and more codified to decide the optimal treatment, however, there is no accepted consensus. In 2015, J. Lerouge described in her PhD thesis an algorithm to predict the failure rate of methotrexate (MTX) for EP. This formula is based on 4 variables: patient's age, serum hCG level, presence or not of an effusion in Douglas pouch, and the size of the ectopic mass (> 30 mm or not). The aim of the current study was to retrospectively compare the difference between the management of the EP and the predictive score.

Methods

A retrospective and monocentric study was performed at the Liege University Obstetrics and Gynecology Department on Citadelle Hospital. Between 2016 and 2022, 193 women were treated for suspected EP. Score was calculated by the formula, based on the medical files data.

We also discussed about first-line surgical treatment. This analysis allowed us to verify whether surgery was justified.

Results

Out of the 193 patients, 83 women (43%) received first-line treatment with MTX. The majority (n=70, 84%) was treated with a single injection, while 16% required multiple injections. First-line surgical treatment was opted for the remaining 110 patients (57%). Regarding our professional practice, the success rate of first-line MTX is 93%. If the formula had been applied, first-line MTX success rate would have increased up to 96%, more women (55%) would have benefited from MTX rather than from surgical treatment (45%).

Conclusions

We recommend the use of the formula as it could reduce the rate of first-line surgery by 12%. Moreover, it may be interesting and we encourage to correlate the prediction of the formula applied to the experience of the clinician. To our best knowledge, it is the first long term study on an innovative approach for EP treatment.

Laparoscopic Davydov's vaginoplasty for Mayer-Rokitansky-Küster-Hauser syndrome management: a centre's 10-year experience

Sofia Tsiapakidou¹, Eirini Iordanidou¹, Christos Anthoulakis¹, George Kioussis¹, Theodoros Theodoridis¹, Grigorios Grimbizis¹

¹Aristotle University of Thessaloniki- Greece,

1st Department of Obstetrics and Gynecology Aristotle University of Thessaloniki, Thessaloniki, Greece

Background

Davydov's Colpopoiesis is one of the management approaches for vaginoplasty and vaginal lengthening in patients with congenital vaginal or uterus absence (Mayer-Rokitansky-Küster-Hauser (MRKH) syndrome). This study retrospectively analyses the results of a single center's 10-year experience in treating MRKH using Laparoscopic Davydov's vaginoplasty.

Methods

This is a retrospective, single-center study, all patients diagnosed with MRKH syndrome between 2012 and 2022 were included. All patients were assessed, counselled, and followed-up by an experienced Gynaecological Endoscopist and a Pediatric and Adolescent Gynecologist. All participants had support from a Clinical Psychologist. Davydov's procedure was chosen for all patients for vaginal reconstruction. The hospital's electronic patient records were used for the demographics, the clinical, the operative, and the post-operative details. All data were stored and analysed in Microsoft Excel.

Results

A total of 24 participants were initially included. The mean age of 1st visit was 15 years and the mean vaginal length at presentation was 1.5 cm and the width was 2 cm. 20 patients underwent surgical treatment when they reached adulthood. 4 patients expressed concerns regarding possible surgical complications and preferred to be treated with vaginal dilators. One of them was unsatisfied with the result and decided to continue with the surgery. In total, 21 patients were included. Mean surgical time: 130±20 minutes and mean intraoperative blood loss: 300±100 ml. At the end of the surgery, the mean length of the newly formed vagina was 8±1 cm and the width was 3 cm. No intraoperative complications were recorded. The Foley catheter was removed on the 10th postoperative day. Two patients presented urinary retention after the removal, and repositioning was needed for another 7 days. No urinary tract infection was detected. One patient developed a rectovaginal fistula after an iatrogenic injury of the rectum during tissue preparation, which healed itself after a prophylactic ileostomy. The mean hospitalization duration was 10 days. Postoperative, three cases presented prolonged vaginal bleeding (more than 3 months). The mean follow-up was 60 months (range from 6 up to 84 months).

Conclusions

The laparoscopic Davydov vaginoplasty technique method is a safe and effective surgical technique and alternative for vaginal reconstruction in patients with MRKH.

Association between chronic endometritis and endometriosis: two sides of the same coin?

Dimitrios Rafail Kalaitzopoulos¹, Panagiotis Drakopoulos², Ursula Catena³, Nicolas Samartzis⁴

¹*Cantonal Hospital of Schaffhausen, Gynaecology, Schaffhausen, Switzerland*

²*Centre for Reproductive Medicine- Universitair Ziekenhuis Brussel- Vrije Universiteit Brussel, Department of Obstetrics and Gynecology, Brussels, Belgium*

³*Fondazione Policlinico Universitario Agostino Gemelli IRCCS, Department of Woman- Child and Public Health, Rome, Italy*

⁴*Cantonal Hospital of Schaffhausen, Gynecology and Obstetrics, Schaffhausen, Switzerland*

Background

This systematic review and meta-analysis aimed to assess the prevalence of chronic endometritis (CE) in women with endometriosis and to compare the frequency of CE between women with and without endometriosis.

Methods

An electronic search was conducted using the MEDLINE, Scopus and Cochrane databases up to May 2022.

Results

855 studies were identified, of which six studies were included in the systematic review and five in the meta-analysis. The prevalence of CE in women with endometriosis was 28%, with higher frequency observed in women with endometriosis rASRM stage III-IV (43%). The meta-analysis showed a significant higher CE in women with endometriosis in comparison to control group (OR 2.07 CI 95% 0.57-8.98, I² 43%, p=0.02).

Conclusions

The present meta-analysis showed a significantly higher risk of CE in women with endometriosis in comparison to the control group. Further investigation is needed to clarify the correlation between CE and endometriosis, as the existing studies exhibit a range of heterogeneity.

Evaluation of endometriosis in non-sexually active women by targeted trans-abdominal ultrasound

Maya Naor Dovev¹, Noa Feldman², Boris Beloshevski¹, Neta Eisenberg¹, Orna Levinsohn-Tavor¹, Noam Smorgick¹

*¹Sackler Faculty of Medicine- Tel Aviv University- Tel Aviv- Israel,
Department of Obstetrics and Gynecology- Shamir Medical Center Assaf Harofeh, Zerifin, Israel*

*²Sackler Faculty of Medicine- Tel Aviv University- Tel Aviv- Israel,
Department of Obstetrics and Gynecology- Tel Aviv Medical Center, Tel Aviv, Israel*

Background

Objective: Endometriosis is a common gynecologic condition affecting ~10% of women. The diagnosis and treatment of endometriosis are often delayed, causing significant impairment in women's quality of life and even infertility. To date, non-invasive diagnosis of endometriosis is possible by trans-vaginal targeted ultrasound (which could be associated with significant discomfort in non-sexually active women) or by magnetic resonance imaging (MRI) (which has limited availability and higher cost). In our department, a protocol for trans-abdominal targeted ultrasound was developed and used for screening non-sexually active (virginal) women with suspected endometriosis.

Methods

Methods: Retrospective cohort study including all women evaluated in the endometriosis clinic between 2016 and 2022 by trans-abdominal targeted ultrasound. The targeted ultrasound assessment included: (1) evaluation of uterus and adnexa for signs of adenomyosis and endometriomas, (2) sliding signs and mobility of the uterus and adnexa using a half-full bladder, and (3) prominent findings of deep infiltrating endometriosis (DIE). When available, the ultrasound findings were compared to laparoscopy and/or MRI.

Results

Results: 54 non-sexually active women were included in the study. Their mean age on admission was 21.6 ± 6.8 years, and their main symptoms were dysmenorrhea (in 46, 85.2%), gastrointestinal complaints (in 21, 45.6%) and chronic pelvic pain (in 15, 27.8%). On the targeted trans-abdominal ultrasound, abnormal findings were observed in 20 (37.0%) women, including endometriomas (uni- or bilateral) in 16 (29.6%) cases, DIE in 2 (3.7%) cases, and adenomyosis in 2 (3.7%) cases. In 18 (33.3%) cases, an additional evaluation by MRI and/or laparoscopy was done. Among those, the trans-abdominal ultrasound findings were confirmed in 15/18 (83.3%) cases. In 3/18 (16.7%) women, additional findings not detected by the trans-abdominal ultrasound were diagnosed by laparoscopy/MRI, including 2 cases of rectosigmoid DIE and one case of uterosacral DIE.

Conclusions

Conclusion: Targeted trans-abdominal ultrasound is a non-invasive, well-tolerated imaging modality which may be used as a screening tool in non-sexually active women with suspected endometriosis. However, additional imaging by MRI is necessary in cases of suspected DIE, especially for pre-operative planning.

endometriosis in young women: non-invasive ultrasound diagnosis and follow up of the disease and symptoms

Elvira Nocita¹, Consuelo Russo¹, Francesco Giuseppe Martire¹, Giulia Monaco¹, Chiara Paladino¹, Caterina Exacoustos¹

¹University of Rome "Tor Vergata", Department of Surgical Sciences Obstetrics and Gynecological Clinic, Rome, Italy

Background

the aim of the study was to assess in young women (< 25 years) with severe dysmenorrhea and non-invasive transvaginal sonographic (tvs) diagnosis of endometriosis, the developments of symptoms and disease, for both those who undergo a hormonal treatment and those who do not.

Methods

66 young patients <25 years old from our gynaecological ultrasound unit with severe dysmenorrhea as main symptom and an initial tvs diagnosis of endometriosis who underwent a clinical and tvs follow up were included in this study. all young patients had at least an tvs features of endometriosis and a follow up period of more than 12 months. medical history, symptoms, kind of therapy and tvs findings, performed each 6-8 months, were collected before and each follow up examination. amount of menstrual bleeding and painful symptoms (dysmenorrhea, dyspareunia, dyschezia, dysuria, bowel symptoms) were evaluated using visual analogue scale (vas). the control group included 48 young patients (< 25 years) with severe dysmenorrhea (VAS >7) without any tvs signs of endometriosis during a follow up period more than 12 months.

Results

all 66 young patients start hormonal therapy after initial tvs diagnosis of endometriosis and mean follow period was 32.3±30.2 (range 12-114) months. at baseline tvs examination, ovarian endometrioma was found in 33 cases and, among these, 75% had a significant decrease of volume, from 34.31±16.04 to 17.8±15.9 millimeters. utero-sacral ligament (usl) fibrotic thickening was detected in 36 (54.5%) cases and only 8 (12.1%) patients had rectal deep infiltrating endometriosis (die). during follow up 12 patients (33.3%) showed a non-significant reduction of usl lesions size while in 20 (55.5%) remained unchanged. rectal die remained unchanged. adenomyosis was detected in 43.9% (29/66) of patients and despite adenomyotic foci shrunk in 24.1% (7/29), the majority of cases did not get worse. concerning control group (48 cases) only 13 took hormonal therapy whereas 35 patients despite the severe dysmenorrhea did not. patients of the study and the control group on medical treatment showed a significant improvement of dysmenorrhea and heavy menstrual bleeding (hmb), whereas dyspareunia, dyschezia and dysuria symptoms improved, although not significantly. painful symptoms worsened in patients of the control group (35) who did not undergo therapy and in 3 cases tvs findings of endometriosis appears during follow up period.

Conclusions

in young women with severe dysmenorrhea an early non-invasive ultrasound diagnosis of endometriosis allows improvement of symptoms and prevention of the progression of disease by starting an adequate hormonal treatment. we observed a reduction size of 75% of the endometrioma while usl fibrotic thickening, rectal die and adenomyosis don't get worse. in young women with severe dysmenorrhea and initially no tvs findings of endometriosis who did not take any therapy, symptoms worsened and in 8.6 % endometriosis tvs signs appears.

Ureteral endometriosis: the silent renal loss

Subul Bazmi¹, Saad Amer¹, Simon Williams¹, Rathy Kirke¹
¹Royal Derby Hospital, Gynaecology, Derby, United Kingdom

Background

Endometriosis can affect 10-15% of the women in their reproductive age and it is characterized with the presence of the functional endometrium tissue outside the uterine cavity.

The ureter is the second most common site affected by urinary tract endometriosis, after the bladder, 1-1.5%.

Ureteral endometriosis is a rare disease affecting women of childbearing age which presents with nonspecific symptoms, and it may result in severe morbidity that can eventually lead to renal failure.

The aim of our study is to highlight this insidious disease resulting in disastrous effects. There is no current screening tool to monitor the renal function of women with endometriosis. However, having said that it is our duty as healthcare personnel to have a high degree of suspicion and approach women with severe endometriosis with caution and adopt a holistic mode of care. Renal imaging is essential and should be done routinely in women with severe endometriosis and concurrent risk factors. And it is this feature we wish to emphasize.

Methods

We present a case series of ten women with stage 4 endometriosis who were managed in our unit between 2021 and 2022. All these women were referred to our unit with severe endometriosis and/ or MRI diagnosis of ureteric / renal decompensation.

All the patients had Multidisciplinary management with gynaecologists , urologists and colo-rectal surgeons, in select cases. Joint decisions were made for nephrectomies, ureteric stenting and ureteric re-implantations depending on the location, severity and extent of ureteric involvement.

Results

Mean duration of symptoms prior to their referral was around 55 months. 5 patients had an incidental diagnosis of hydronephrosis. Interestingly 3 of these women had endometriomas all more 5cm in size. 2 patients were referred with hydronephrosis and ureteric strictures after having subtotal hysterectomies. 5 women had previous laparotomies, one for PID, 2 for hysterectomies, three for drainage of endometriomas/ ovarian cystectomies.

In terms of management, 2 patients had joint procedure with urologists. 4 patients were managed with ureteric stenting due to deranged renal function and to manage symptoms, till a more definitive plan is put in place. The others are awaiting nephrectomies due to irreversible damage to the kidneys.

The common theme with these women is the lack of imaging to screen for renal involvement.

Conclusions

Renal endometriosis albeit rare presents with devastation consequences. Majority of the women in our case series were either lost to follow up and/ or didn't have renal imaging to exclude disease. We have noted risk factors in our case series, namely women with previous PID, large endometriomas and those with subtotal hysterectomies and on oestrogen only HRT presenting with complex recurrence. This calls for clinicians to be wary and always raise suspicion of infiltration and offer women renal scans to look for hydronephrosis +/- hydronephrosis.

AAGL endometriosis classification and risk of operative complications

Pierluigi CELERINO¹, Anna Chiara Aru¹, Daniele Neola², Francesca Govoni¹, Diego Raimondo¹, Renato Seracchioli²

¹*Division of Gynaecology and Human Reproduction Physiopathology- IRCCS Azienda Ospedaliero-Universitaria di Bologna- Bologna- Italy,*

Department of Medical and Surgical Sciences DIMEC- University of Bologna- Bologna- Italy, Bologna, Italy

²*Department of Neuroscience- Reproductive Sciences and Dentistry- School of medicine- University of Naples Federico II- Naples- Italy,*

Department of Neuroscience- Reproductive Sciences and Dentistry- School of medicine- University of Naples Federico II- Naples- Italy, Napoli, Italy

Background

In patients affected by deep endometriosis (DE), surgical approach can be difficult and may lead to unpleasant complications. Recently, the American Association of Gynecologic Laparoscopists (AAGL) proposed a new classification and scoring system with the specific aim to assess surgical complexity. However, its association with the occurrence of operative complications has not been investigated yet. This study sought to assess if a higher AAGL score correlates with an increased risk of peri-operative complications in women submitted to surgery for DE.

Methods

This is a retrospective study conducted in a third level referral center. We collected data from consecutive women with DE submitted to complete surgical removal of endometriosis from January 2019 to December 2021. ENZIAN and rASRM classifications were documented in medical reports as usual clinical practice. AAGL total score was retrospectively calculated for each patients using detailed description of operative reports. Population was divided in two groups according to the occurrence or not of at least one peri-operative complication. Univariate and multivariate regression analyses were performed to identify independent risk factors of surgical complications. Our primary outcome was to evaluate the correlation between AAGL classification and occurrence of complications

Results

During study period we analyzed data from 282 eligible patients. Among them, 81 (28.7%) experienced peri-operative complications. No statistically significant difference was found between the two groups in terms of baseline characteristics, except for pre-operative hemoglobin, which was lower in patients with complications compared to control group ($p=0.03$). Surgical variables associated to occurrence of complications were presence of recto-sigmoid surgery ($p=0.002$) and ileocecal resection (0.04), and longer operative time ($p=0.001$). Furthermore, an higher ENZIAN B score ($p=0.007$), ENZIAN C score ($p=0.03$), and AAGL score ($p=0.004$) and stage ($p=0.02$) were found in the group of patients with complications compared to control group. The multivariate analysis only confirmed the significant association between the occurrence of peri-operative complications and lower pre-operative Hb level (OR 0.74, 95% CI 0.59 - 0.92, $p=0.008$), higher AAGL score (OR 1.04, 95% CI 1.00-1.07, $p=0.03$), and ENZIAN B3 (OR = 3.15, 95% CI: 1.33–7.45, $P = 0.009$).

Conclusions

According to our findings, an high AAGL score seems to increase the risk of peri- operative complications. Moreover, also low pre-operative hemoglobin and the ENZIAN B3 were identified as independent risk factors for the occurrence of peri-operative complications. Further studies are needed to confirm our preliminary findings.

Could spinal anesthesia represent an alternative to general anesthesia in the laparoscopic treatment of extrauterine pregnancy?

Luigi Della Corte¹, Maria Chiara Guarino², Michela Dell'Aquila², Dario Colacurci², Pierluigi Giampaolino², Giuseppe Bifulco²

¹University of Naples Federico II, Neuroscience- Reproductive Sciences and Dentistry, Naples, Italy

²University of Naples Federico II, Public Health, Naples, Italy

Background

To assess the feasibility and the intraoperative and postoperative outcome of laparoscopic surgery for ectopic pregnancy under regional anesthesia (RA) compared general anesthesia (GA) from the point of view of the surgeon, anesthesiologist and patient.

Methods

This is a retrospective cohort study performed at AOU Federico II of Naples. Eighty-two women undergone elective or emergency laparoscopic salpingectomy for ectopic tubal or ovarian pregnancy were included. The surgical procedure was performed in all women with ectopic pregnancy more than 3,5 cm diameter on transvaginal ultrasound, serum β hCG concentration more than 5000 IU/L, severe pelvic pain, haemoperitoneum with a visible fluid collection ≥ 4 cm, a hemoglobin drop > 3 g/L between two measurements or in case of failed medical therapy with metotrexate. Postoperative pain assessed through Visual analog scale (VAS) was the primary outcome. The main secondary outcomes included: postoperative nausea and vomiting (PONV), antiemetic/analgesic drugs usage and length of hospital stay. Further secondary outcomes were anesthesia complications, resumption of bowel motility, time to mobilization and patient satisfaction.

Results

Laparoscopy under regional (Group A) or general (Group B) anesthesia was performed in all patients. Baseline demographic and clinical data of the patients included in the study did not show significant differences between the two groups, except for BMI. All patients had tubal pregnancy, except for 2 (4.3%) in Group B with a diagnosis of ovarian pregnancy. No patients required laparotomic or anesthesia conversion. The surgeon managed to operate with a less degree of Trendelenburg's position in Group A compared to Group B. Despite the emergency condition, 14/35 (40%) patients underwent surgery under spinal anesthesia without intraoperative complications. Also, operative time was not significantly different between the two groups. Regarding the postoperative pain evaluated through VAS score, patients in Group A reported less pain at 0 h (adjusted meandifference: -1.5; 95% CI: -2.3 to -0.7; $p < 0.001$) and after 6 h (adjusted mean difference: -1.1; 95%CI: -2.0 to -0.3; $p = 0.01$) while no statistically significant differences between the two groups were noted at 12 and 24 h after surgery. Analyzing the intake of analgesics after surgery, no differences were observed among the type of analgesic and during the postoperative observation time. A faster resumption of bowel motility and patient's mobilization and a shorter hospital stay were observed in Group A compared to Group B. No significant differences were recorded in terms of PONV. A greater number of patients in Group A were satisfied with the entire procedure compared to those of Group B (33 (94.3%) vs 37 (78.7%).

Conclusions

Laparoscopic treatment of ectopic pregnancy under regional anesthesia has proven to be a safe and effective technique as an alternative to general anesthesia both in elective and emergency surgery.

Neovagina and cervico-vaginal anastomosis using digital anatomic reconstruction and three-dimensional impression in a case of complex genital malformation

*Antoni Pessarrodona Isern¹, Marta Hinarejos Companyó¹, Jordi Cassadó¹, Ana Paula Vélez Vintimilla¹,
Jordi Rodríguez González¹, Oriol Porta Roda¹*

¹Hospital Universitari Mútua de Terrassa, Gynecology and Obstetrics, Terrassa, Spain

Background

Thirteen-year-old patient affected with VACTERL association consulted in emergency room for cyclic abdominal pain of months of evolution. Ultrasound examination showed a cervico-hematometra and, suspecting an imperforate hymen, 300 cc of chocolate-like fluid is drained under ultrasound control. Postoperative examination with MRI showed a left hemiuterus with communicating rudimentary cavity cervical obstruction and vaginal aplasia, U4a C3 V4 in the ESHRE/ESGE classification.

Multiple techniques have been described both to create the neovagina and to perform the uterovaginal anastomosis, most of them in two surgical times. We plan to design a technique combining known surgical resources with 3D impression reconstruction methods to create an anatomical vaginal mold specific to this patient.

The aim of this presentation is to display the surgical approach of neovagina and cervico-vaginal anastomosis in a 13-year-old patient with cervico-vaginal agenesis using reconstruction methods.

Methods

Using digital 3D anatomical reconstruction and 3D impression, we created a silicon vaginal mold specifically designed for this patient, with minimally invasive surgical strategy to accomplish anatomical collocation in a complex genital malformation. To design the silicone mold, a CT scan with intravaginal contrast was performed on a volunteer of the same height as the patient. A three-dimensional reconstruction was performed with Materialise Mimics Viever, fused with the reconstruction of the patient's pelvis and uterus, and printed on 3D printer. A 2 mm thick silicone mold was designed based on these measures, and it was covered with a layer of cadaver skin of 1 mm thickness previously decellularized and microcut to create a net.

Several tests were performed on animal tissue to prove the adaptability of the system.

Using ultrasound control and laparoscopic supervision, we placed a silicon covered with cadaveric decellularized skin in a simple way. Medical silicon grade IV allowed us to maintain the mold for weeks, until we accomplished a cellular invasion of the cadaveric skin.

Results

Digital anatomical reconstruction and three-dimensional impression can be an innovative technique to approach complex genital malformation.

Conclusions

We expect that this technique can help in the future other women with complex genital malformations.

Systematic analysis of procedural laparoscopic robotic hysterectomy: what are the key steps trainees should focus on?

Krystal Nyangoh Timoh^{1,2}, Sonia Guerin³, Arnaud Hualmé², Vincent Lavoue¹, Pierre Jannin²

¹CHU Rennes, Gynecology Obstetrics, Rennes, France

²INSERM, Itsi, Rennes, France

³CHU Rennes, Gynecology, Rennes, France

Background

Laparoscopic robotic-assisted surgery is becoming increasingly popular. Yet, a curriculum based on objective clinical insight is lacking for robotic surgical simulation.

This study aims to analyze Robotic-Assisted Laparoscopic Hysterectomy (RALH) procedures for educational purposes.

Methods

Method: We collected 57 consecutive surgical videos of Robotic Assisted Laparoscopic hysterectomies (RALH) performed for benign disease between August 2020 and September 2021 in Rennes University Hospital. Videos were recorded with the dVLogger research device (Intuitive ©, USA). They were annotated following the surgical process methodology into 7 phases and 24 steps. Participants with more than 35 prior RALH formed the expert group (n=5) and others in the intermediary group (n=3). The endpoint was the time comparison of the precise phases and steps between both groups. The second endpoint was the analysis of the intra-group variability.

Results

Results: In a similar population of patients, experts were significantly faster than intermediates for four phases: operating site access (p=0.04), uterine vessel controls (p=0.03), colporrhaphy (p<0.01), and right adnexa dissection (if for bilateral salpingo-oophorectomy was performed) (p=0.02). They were also faster for five of the 24 steps like section of the right round ligament (p=0.04), coagulation of the right uterine pedicle (p<0.01), and colporrhaphy (p<0.01). For all these significant phases and steps, intra-group variability for each group was high.

Conclusions

Intermediates surgeons should focus on technical aspects such as managing the right side of the uterus and needle driving. Other factors and data are necessary to explain the high intra-group variability, such as kinematic data.

Percutaneous imaging-guided cryoablation of endometriosis scars of the anterior abdominal wall

Jouffrieau Charlotte¹, Victor Gabriele¹, Roberto-Luigi Cazzato², Ashin Gangi², Olivier Garbin¹, Emilie Faller¹
¹Centre Médico-chirurgical et Obstétrical, Bas Rhin, Strasbourg, France
²Service de Radiologie Interventionnelle- NHC, Bas Rhin, Strasbourg, France

Background

To evaluate the safety and clinical efficacy of percutaneous imaging-guided cryoablation for the management of anterior abdominal wall endometriosis.

Methods

Patients with abdominal wall endometriosis underwent percutaneous imaging-guided cryoablation and had a 6-months follow-up.

Data dealing with patients' and AAWE characteristics, cryoablation, clinical and radiologic outcomes, were retrospectively collected and analyzed.

Twenty-nine consecutive patients underwent cryoablation from June 2020 to September 2022.

Interventions were performed under US/computed tomography (CT) guidance or MRI guidance. Cryoprobes were directly inserted into the AAWE, and cryoablation was performed with a single 5-10 min. freezing cycle, which was stopped when the iceball expanded 3-5 mm beyond AAWE borders as assessed on intra-procedural cross-sectional imaging.

Results

Fifteen patients (15/29; 51.7%) had prior endometriosis, 28 (28/29; 95.5%) with previous cesarian section, and 22 (22/29; 75.9%) referred association between symptoms and menses.

Cryoablation was performed under local (16/29; 55.2%) or general anesthesia (13/29; 44.8%), and mainly in an out-patient basis (18/20; 62%). There was only one (1/29; 3.5%) minor procedure-related complication.

Complete symptoms relief was recorded in 62.1% (18/29) and 72.4% (21/29) patients at 1 and 6 months, respectively. In the whole population, pain significantly dropped at 6 months compared to the baseline (1.1 2.3; range 0-8 vs 7.1 1.9; range 3-10; $p < 0.05$). Eight (8/29; 27.6%) patients presented residual symptoms at 6 months, and 4 (4/29; 13.8%) had an MRI-confirmed residual/recurring disease.

Contrast-enhanced MRI obtained for the first 14 (14/29; 48.3%) patients of the series, all without signs of residual/recurring disease, demonstrated a significantly smaller ablation area compared to the baseline volume of the AAWE (1.0 cm³ 1.4; range 0-4.7; vs 11.1 9.9 cm³; range 0.6-36.4; $p < 0.05$).

Conclusions

Percutaneous imaging-guided cryoablation of AAWE is safe and clinically effective in achieving pain relief.

Intraoperative proctosigmoidoscopy evaluation after discoid bowel resection for deep infiltrating endometriosis: a pilot study

Stefano Ferla¹, Arianna Raspollini¹, Manuel Ianieri², Diego Raimondo¹, Paolo Casadio¹, Renato Seracchioli²
¹Division of Gynaecology and Human Reproduction Physiopathology- IRCCS Azienda Ospedaliero- Universitari a di Bologna- Bologna- Italy,
Department of Medical and Surgical Sciences DIMEC- University of Bologna- Bologna- Italy, Bologna, Italy
²Fondazione Policlinico universitario A. Gemelli, Department of Women's and Children's Health, Roma, Italy

Background

deep infiltrating endometriosis (DIE) is defined as an endometriotic lesions infiltrating pelvic organs' wall and retroperitoneal structures. surgery is the treatment of choice when medical therapy fails to be effective. among surgical techniques for rectosigmoid endometriosis (RSE) discoid resection has demonstrated good clinical and functional outcomes also at long term follow-up. however, several reports described a not negligible risk of perioperative complications related to the procedure. the purpose of this study was to evaluate the feasibility and safety of proctosigmoidoscopy after discoid resection during die surgery. secondary aim was to compare the incidence of post-operative complications within the first three months between the two groups.

Methods

this is an observational, cohort, prospective, multicentric, pilot study. we included all eligible patients underwent surgery for die with discoid bowel resection between March and September 2022 in two referral centers (IRCCS policlinico Sant'Orsola – Bologna and IRCCS policlinico gemelli – Roma). for study purpose patients were divided in two groups: those underwent to sigmoidoscopy (ip group) versus those who did not receive it (non-ip group). for each patient, demographic, clinical, and surgical data were collected, and a statistical analysis was conducted. eligibility to the study was confirmed by the surgeons at the time of laparoscopy.

Results

28 patients were enrolled during the study period and equally distributed in two groups. mean (+/- sd) age was 34±6.5 years and 37.5±6.1 years in the ip and non-ip groups, respectively ($p = 0.28$). mean (+/- sd) BMI was 22.7 ± 4.3 kg/m² and 22.5 ± 3.3 kg/m² in the ip and non-ip groups, respectively ($p = 0.92$). no statistical difference between the two groups was observed regarding parity, smoking habit, ASA, hormonal therapy, prior pelvic surgery, preoperative moderate-severe pain symptoms related to endometriosis. the mean (+/- sd) overall operative time was 200.2 ± 70.4 minutes and 169.8 ± 53 minutes for the ip and non-ip group, respectively ($p = 0.03$). in the ip group, the mean (+/- sd) operative time for proctosigmoidoscopy was 212.8 ± 141 seconds. in all cases except one, ip allowed an appropriate visualization of the anastomosis. no intraoperative complications related to ip were observed. no statistical difference in terms of intra-and post-operative complications between the two study groups was observed.

Conclusions

ip seems to be a feasible, safe, non-time-consuming procedure in women undergone surgery for DIE. further studies on larger samples with longer follow-up period are needed to confirm our data.

Future vision for European endometriosis data collection with the E-QUSUM: web-based rASRM, ENZIAN and EFI scoring system

Jeroen Metzemaekers¹, Rozemarijn de Koning¹, Andries Twijnstra¹, Frank Willem Jansen¹, Mathijs Blikkendaal¹
¹LUMC, Gynaecology, Leiden, The Netherlands

Background

The ESHRE guideline for endometriosis is for 40% authority based (GPP), due to different outcome measures, incorrect classification of disease and lack of patient reported outcome measures. We developed an objective web-based reporting system to improve uniform evidence based (big) data collection. The system is named EQU SUM (**Q**uality and grading instrument for **S**urgical perfor**M**ance in **E**ndometriosis) and can be used worldwide.

The E-QUSUM provides electronic synoptic operative reporting (E-SOR) and easy staging/classification with r-ASRM and ENZIAN of (deep) endometriosis by anatomical pictures. Furthermore, the endometriosis fertility index (EFI) is measured for fertility advice after surgery.

Methods

Web based system for collecting and classifying surgical endometriosis cases.

Results

Advantages of Big Data: The use of EQU SUM enables researchers to collect large amounts of data from endometriosis patients, facilitating a broader understanding of the disease. By analyzing data from thousands of patients, patterns, trends, and subgroups that would otherwise be challenging to detect can be identified. These extensive datasets may contain information pertaining to various aspects of the disease, such as genetic factors, symptom presentation, treatment effectiveness, and quality of life.

Potential for New Scientific Insights: EQU SUM offers the possibility of gaining new scientific insights by combining and analyzing data from different sources and studies. By pooling data from multiple studies, researchers can identify novel associations, discover hidden correlations, and uncover previously unrecognized risk factors or treatment approaches. The collective analysis of diverse datasets can provide a more comprehensive understanding of endometriosis and open avenues for further research and advancements in the field.

Data Uniformity: One crucial advantage of EQU SUM is the promotion of data uniformity. By establishing standardized data collection methods and variables, EQU SUM ensures that data from various sources are consistent and compatible. This uniformity allows for seamless integration and comparison of data, reducing potential biases and enhancing the reliability and validity of research findings. Moreover, it enables researchers to perform meta-analyses and systematic reviews with greater accuracy and confidence, further strengthening the evidence base in the field of endometriosis.

Conclusions

The utilization of EQU SUM in data collection from endometriosis patients provides numerous benefits. Leveraging big data allows for a comprehensive understanding of the disease, enabling the identification of patterns and subgroups that may have gone unnoticed. Furthermore, EQU SUM offers the potential for generating new scientific insights by combining data from multiple sources and studies. Lastly, the emphasis on data uniformity enhances the reliability and validity of research findings, promoting evidence-based advancements in endometriosis research and care.

Diagnosis of pelvic endometriosis: a systematic review and accuracy meta-analysis of non-invasive tests available in primary care

Thomas BAINTON¹, Sobanakumari Jeyapala¹, Javier Zamora², Khalid S Khan³, Amer Raza¹

¹Chelsea and Westminster Hospital, Obstetrics and Gynaecology, London, United Kingdom

²Hospital Ramon y Cajal IRYCIS, Clinical Biostatistics Unit, Madrid, Spain

³University of Granada, Department of Preventative Medicine and Public Health, Granada, Spain

Background

Endometriosis is a chronic, often debilitating condition with a current significant delay from symptom onset to diagnosis with much of this in primary care.

Methods

A systematic review and meta-analysis of the primary literature was conducted to investigate the accuracy of symptoms, clinical history and first-line non-invasive tests to predict pelvic endometriosis (PROSPERO: CRD42020187543). We searched Medline, Embase, Web of Science and Scopus from conception (1966; 1972; 1997; 2004 respectively) to September 2022 for primary test accuracy studies assessing non-invasive tests against reference standard diagnosis for endometriosis. Two authors independently conducted data extraction and quality assessment. Grading of evidence was performed using a novel visual pentagon model. Meta-analyses of test accuracy was estimated using bivariate random effects models.

Results

The 125 included studies (250,574 participants) showed mixed quality. Studies applying non-surgical (database/self-reporting) reference standard had a greater risk of bias. In 98 studies applying surgical reference standard, summary diagnostic odds ratios for endometriosis were: dysmenorrhoea 2.56 (95% confidence interval 1.99-3.29); pelvic pain 2.56 (1.73-3.74); dyschezia 2.05 (1.36-3.10); dyspareunia 2.45 (1.71-3.52); family history of endometriosis 6.79 (4.08-11.3); nulligravidity of 2.01 (1.62-2.50); body mass index (BMI) $\geq 30\text{kg/m}^2$ 0.37 (0.19-0.68); trans-vaginal ultrasound scan (TVUSS) endometrioma 91.2 (44.0-189); TVUSS invasive endometriosis 26.1 (9.28-73.5); and cancer antigen-125 (CA-125) $>35\text{U/mL}$ 16.0 (8.09-31.7). Sensitivity analysis excluding all high-risk studies found concordant results.

Conclusions

This meta-analysis collated the performance of non-invasive tests for endometriosis across a comprehensive and geographically varied population. Study quality was mixed, however results were consistent with high-risk studies excluded. These findings will inform future prediction models for triage in primary care.

A case report of endometrial osseous metaplasia

Lamya Alkadoushi¹

¹Birmingham Women's Hospital, Obstetrics and Gynaecology, Birmingham, United Kingdom

Background

Introduction: Endometrial Osseous Metaplasia is a rare condition with the presence of bone in the endometrial cavity. Most cases reported clinically present with secondary infertility following a termination of pregnancy.

Methods

Case description: A 29-year-old female presented with a 4-year history of secondary infertility, heavy menstrual bleeding, intermenstrual bleeding, and abnormal vaginal discharge following a surgical termination of pregnancy. She had 3 hysteroscopies to remove bone fragments prior to presenting to our unit. Under the care of our unit, patient had a diagnostic hysteroscopy and a biopsy was taken to confirm the diagnosis of endometrial osseous metaplasia. Patient was arranged to have 2 doses of prostaap injections 3 months prior to operative hysteroscopy under general anaesthetics to meticulously retrieve all bone fragments. 3 months later, patient had hysteroscopic adhesiolysis under fluoroscopic guidance, Copper coil was inserted, patient was started on 4mg oestradiol for 6 weeks in addition to norethisterone on weeks 4 and 5. Six weeks later the coil was removed after a repeat hysteroscopy that showed clear cavity. Further fertility investigations revealed normal AMH, subsequent TV USS showed regular endometrium, some bright classification in the myometrium and both ovaries appear normal. It was decided to proceed with assisted conception because of concerns over recurrence of the metaplastic process. She underwent a short down regulation protocol of 150iu/l of FSH until day 11. Ten eggs were collected and 7 out of 10 were fertilized. Endometrial thickness was noted to be suboptimal. Patient had 1 fresh cycle with single embryo transfer and one further frozen cycle with double blastocyst transfer, unfortunately both cycles resulted in negative pregnancy tests. Embryo transfers were difficult due to S shaped cervix and was advised to have hysteroscopy and cervical dilatation immediately before embryo transfers. She continues to remain under the care of fertility team.

Results

.

Conclusions

This case illustrates the complexity of managing endometrial osseous metaplasia. Being a rare condition, it is important to share and learn from steps taken of optimising the endometrial cavity for subsequent assisted contraception.

The forgotten “zero” generation of endometrial ablation

Rafal Watrowski¹, Stoyan Kostov², Salvatore Giovanni Vitale³

¹Helios Hospital Müllheim- Teaching Hospital of the University of Freiburg, Department of Gynecology and Obstetrics, Müllheim, Germany

²Saint Anna University Hospital- Medical University of Varna, Department of Gynecology, Varna, Bulgaria

³University of Cagliari, Division of Gynecology and Obstetrics- Department of Surgical Sciences, Cagliari, Italy

Background

Endometrial ablation (EA) is the targeted destruction of the endometrium to treat abnormal uterine bleeding in premenopausal women. The common classification into "first generation" (resectoscopic, REA) and "second generation" (non-resectoscopic, non-visually controlled, NREA) techniques is historically incorrect and mistakenly. Unlearned lessons from various NREA techniques and tools introduced as early as the late 19th century result in redundancy of treatment failures and inflated expectations due to novel NREA methods.

Methods

Narrative pictorial review.

Results

In our visual journey we recall the history of EA from its beginnings, starting in 1898 when Alfred Dührssen reported the first EA by intrauterine application of steam using a specially designed instrument in a 37-year-old woman. The scientific and technical innovations led to the development of NREA methods based on the destruction of the endometrium by superheated steam (atmocausis), hot water (vaporization), necrosis by contact with heat or chemicals (cauterisation) and coagulation (commonly used in the modern electrosurgery). The next milestone in the development of EA was Bardenheuer's "ball electrode" for electrocoagulation of the endometrium in 1937. The final technical innovation in the forgotten era of EA was cryoablation of the endometrium, first reported by Cahan and Brockunier in 1967.

Conclusions

In this pictorial review, we remember EA methods spanning almost 80 years that are almost completely forgotten but deserve to be considered the true first generation of EA.

Furthermore, the indications and limitations of this historical NREA are apparently similar to their contemporary counterparts and support the status of hysteroscopically controlled, REA as the still valid "gold standard" of EA.

Clinical impact of gynecological prediction models on decision making of both patients and doctors - a prospective survey study

Kelly Stevens¹, Elise Vander Donck¹, Steven Weyers¹, Dick Schoot²

¹*UZ Gent, Gynaecologie, Gent, Belgium*

²*Catharina Ziekenhuis, Gynaecology, Eindhoven, The Netherlands*

Background

Shared decision making is increasingly being used and promoted in clinical care. A prediction model can be used to support this decision-making process. However, it remains unclear in how far doctors and patients will use these predicted percentages by making their choice of treatment. Therefore, this study investigates how the outcomes of a prediction model influence the clinical decision making of both the patient and professional.

Methods

A multicenter prospective survey study was developed and data was collected between the 1st of February 2019 and the 1st of August 2020. Dutch-speaking females (age between 18-75 years) were asked to fill in a survey. This survey contained a fictional case about abnormal uterine bleeding. After reading this case, endometrial ablation (EA) was suggested as treatment with a general failure percentage about 15%. Patients were asked about their preference of treatment option (endometrial ablation vs. uterus extirpation (UE)). After using a prediction model, the failure percentage of EA was calculated to be 61%. Treatment preferences and motives were asked again. A similar survey, with the same fictional case, was developed for Dutch-speaking professionals involved in the gynaecological field.

Results

The primary outcome measure of the survey was the failure percentage of EA where both patients and doctors would no longer choose for EA. A total of respectively 585 and 102 surveys of patients and professionals were available for analysis. After reading the case, a total of 86.7% (N=508) of the women and a total of 86.3% (N=87) of the professionals preferred EA over UE. When the prediction of failure seemed to be 61% based on the fictive case, a total of 47.9% (N=243) in the patient group and a total of 48.9% (N=43) of the professionals significantly changed their choice from EA into UE (both p-value < 0.001). The accepted average failure percentage of EA was 56.7% (range 10-100) by patients and 53,6% (range 10-100) by professionals.

Conclusions

Patients and professionals significantly adapted their treatment preference after reading the personal failure percentage. Hereby we can conclude that it seems that a prediction model influences treatment choice. The extra information, gained by such a model, can contribute better patient counseling and optimize shared decision making.

Clinical and morphological assessment of the efficiency of outpatient hysteroscopic metroplasty for intrauterine septum

Arzu Ismailova¹, Khatira Zeynalova²

¹*Azerbyacan Medical University, Obsterics and Gynecology, Baku, Azerbaijan*

²*Azerbaijan Medical Univerity, Obsterics and Gynecology, Baku, Azerbaijan*

³*Baku Branch of Sechenov Medical University, Obstetrics and Gynecology, Baku, Azerbaijan*

Background

This is a retrospective comparison study with the objective to assess the efficiency of hysteroscopic metroplasty with pulsed diode laser for intrauterine septum dissection.

Methods

In 39 women (group 1) who were operated with the pulse diode laser, the efficiency of metroplasty, the specific characteristics of the operation, the postoperative period, the condition of the endometrium, and the reproductive function were compared as well as 19 patients who were operated on bipolar electrosurgery (group 2).

Results

Cutting up of the intrauterine septum was statistically many times optimal (82.05%) ($p < 0.001$) while using the proposed metroplasty method. In group 1 patients, the morphological structure of the endometrium after metroplasty was importantly more suitable with the stage of the menstrual cycle (86.36%; $p = 0.044$) and varied fewer because of manifestations of perivascular fibrosis (12 (54.55%)). 22; $p = 0.037$). In the majority of women of group 1, the pregnancy ended in 15 out of 21 (71.43%) with ended on time ($p = 0.013$).

Conclusions

The presented method of metroplasty has a positive effect on reproductive function and an efficiency and secure way of cutting up of the intrauterine septum,

Hysteroscopic management of RPOC with mechanical instruments - single centre experience

Elena Rodríguez González¹, Carmen Sánchez Cabezas¹, Tamara Ruiz Martínez¹, Alicia Hernández Gutiérrez¹, Covadonga Álvarez López¹

¹La Paz University Hospital, Gynecology, Madrid, Spain

Background

Hysteroscopic management of RPOC allows direct visualisation of uterine cavity, reducing the risk of myometrial injury, and therefore the rate of intrauterine adhesions. Mechanical hysteroscopic instruments (morcellator, grasper) can also reduce myometrial injury compared with bipolar energy instruments (resectoscope, electrode). We aim to evaluate efficacy and safety of mechanical instruments for hysteroscopic management of RPOC.

Methods

Retrospective, single-centre study, including patients who underwent hysteroscopic removal of RPOC in a tertiary hospital from 2019 to 2022. RPOC were classified according ultrasonographic patterns using Gutenberg Classification.

Results

38 cases. Mean age was 35.68 ± 2.09 (17-46). 94.73% (36) reported metrorrhagia as symptom at diagnosis. History of caesarean section was found in 18.42% (7), vaginal delivery in 39.74% (15) and abortion in 42.10% (16). 68.48% (38) had not received previous treatment, 26.31% (10) vaginal misoprostol and 5.26% (2) curettage. Mean time from antecedent to hysteroscopy was 49.39 ± 22.9 (8-90) days. Mean ultrasound size was 28.26 ± 14.48 (60-8) mm. Regarding Gutenberg Classification, 50% (19) were type 1, 44.73% (17) type 0 and 5.26% (2) type 2. Mean number of hysteroscopies until complete resection (CR) was 1.07 ± 0.27 (1-2). In 89.47% (34) of cases CR was achieved at first hysteroscopy. 10.52% (4) required 2 hysteroscopies, all of them with RPOC size greater than 30 mm at diagnosis. 92.10% (35) of procedures were performed in office and 7.89% (3) in operating room. Morcellator was used in 84.21% (32) of cases and grasper in 15.78% (6). Bipolar electrode was not employed in any of the procedures. Anaesthesia was not administered in office hysteroscopies, mean VAS was 4.23 ± 1.95 (1-8). No intraoperative complications were described. There were 2 post-surgical complications, both were heavy vaginal bleeding and were related to a small interval between antecedent and hysteroscopy and inadequate ultrasound classification. In both cases an aberrant vessel was detected on CT angiography and were resolved by interventional radiology techniques. 23.68% (9) of patients achieved gestation after the procedure, no miscarriages or pregnancy-related complications were described.

Conclusions

Mechanical instruments represent an effective and safe option for hysteroscopic treatment of RPOC. These instruments reduce myometrial damage that can be caused by other bipolar energy instruments. This is of particular importance in young patients with reproductive wishes, as in the case for many patients with RPOC. It is essential to make an adequate ultrasound diagnosis and classification before their hysteroscopic approach. For those classified as type 0 and 1, office hysteroscopy with morcellator can be considered of choice. For those classified as type 2 and 3, whenever possible, it is encouraged to wait between 6-8 weeks and perform new ultrasound examination. If a decrease in RPOC vascularisation is observed, they could be treated in office or operating room, depending on the degree of vascularisation. In cases where abundant vascularization persists, we consider that type 2 should be treated in the operating room and type 3 should undergo interventional radiology techniques prior to exeresis.

Complete uterine septum, double cervix and vaginal septum (U2bC2V1): diagnosis and endoscopic management - a case series

Federica Bernardini¹, Chiara Paglietti², Federica Pozzati³, Antonia Carla Testa⁴, Giovanni Scambia⁴, Ursula Catena³

¹Fondazione Policlinico Universitario Agostino Gemelli IRCCS, Department of Obstetrics and Gynecology- Division of Gynecologic Oncology, Rome, Italy

²University of Udine, Medical Area Department DAME, Udine, Italy

³Fondazione Policlinico Universitario Agostino Gemelli- IRCCS, Department of Obstetrics and Gynecology- Division of Gynecologic Oncology, Rome, Italy

⁴Catholic University of Sacred Heart, Department of Obstetrics and Gynecology- Division of Gynecologic Oncology, Rome, Italy

Background

The combination of complete uterine septum, double cervix and vaginal septum is an association of genital tract's anomalies whose diagnosis is often difficult and challenging due to its rarity and complexity. Several classifications have been developed, changed, or clarified in the last decades with the aim to improve detection, diagnosis, and treatment of such developmental disorders. With the evolution of technologies, diagnosis developed from invasive to minimally-invasive methods. Moreover, technologic advances in surgical equipments led to the spread of minimally invasive procedures also to correct these anomalies. Through our series, we want to describe the diagnostic process and the endoscopic ultrasound-guided technique used in the management of these complex cases in our Digital Hysteroscopic Clinic (DHC) CLASS Hysteroscopy.

Methods

This is a retrospective observational case series. Between August 2020 and May 2023, we diagnosed 21 patients affected by the combination of complete uterine septum, double cervix and vaginal septum at the Fondazione Policlinico Universitario A. Gemelli IRCCS in Rome, Italy. Among them, 15 patients underwent surgical treatment. Diagnosis was obtained combining 3D transvaginal ultrasound (3D TV-US) and office hysteroscopy. Hysteroscopic treatment was performed with 15Fr bipolar miniresectoscope under transabdominal ultrasonographic guidance.

Results

Correct diagnosis was obtained in 19 out of 21 cases by using 3D TV-US alone. Combining office hysteroscopy with 3D TV-US, a correct complete diagnosis was reached in all 21 women. Among the 15 patients who underwent surgery, transabdominal ultrasound was used as guidance technique in 11 cases. All patients were endoscopically treated without intra and/or postoperative complications. All cases were managed in our DHC in one single surgical step, according to an ambulatory model of care, with discharge 3 hours after the procedure.

Conclusions

3D TV-US is considered the gold standard tool for the assessment of simple uterine anomalies. Combining 3D TV-US with office hysteroscopy is recommended to reach a complete diagnosis in case of more complex anomalies involving cervix and vagina. A totally endoscopic approach with miniaturized instruments and under ultrasound guidance may be considered the best option to treat these types of developmental disorders. Future studies are needed to confirm the effectiveness of the surgical procedure and to correlate it with the reproductive outcomes.

The one-step outpatient diagnosis and treatment of congenital mullerian anomalies – class U1 and U2 according ESHRE/ESGE classification

Virginia Foreste¹, Sabrina Reppuccia¹, Giuseppe Gabriele Iorio², Maria Chiara De Angelis¹, Caterina Exacoustos³, Brunella Zizolfi¹

¹University of Naples Federico II, Department of Public Health- School of Medicine, Naples, Italy

²University of Naples Federico II,

Department of Neuroscience- Reproductive Science and Dentistry- School of Naples, Naples, Italy

³University of Rome- Tor Vergata, Department of Surgical Sciences- Obstetrics and Gynecological Unit, Rome, Italy

Background

To assess the feasibility of diagnosis and treatment of Congenital Mullerian anomalies (Class U1 and U2) in a single outpatient access.

Methods

Prospective observational, non-pharmacological study conducted at University of Naples Federico II, Naples, Italy. 100 patients aged between 18-45 years with a diagnosis of dysmorphic uterus (class U1 according to ESHRE/ESGE classification) or septate uterus (class U2 according to ESHRE/ESGE classification) and with at least one of the following conditions: history of long-standing unexplained infertility (UI), recurrent pregnancy loss (RPL) or severe preterm delivery.

All the patients underwent, in an outpatient setting, 3D preoperative transvaginal ultrasonographic (TVS-US) examination, see and treat hysteroscopy and immediate post-surgery 3D-TVS performed in a single access. A second look conducted by 3D ultrasound and outpatient hysteroscopy was performed 2 months after.

Results

A 100% of feasibility of the one step approach has been reported. At 2 months follow-up a statically significant improvement of morphology and volume of the uterine cavity after metroplasty were observed. Only six patients required a second surgical step.

Conclusions

Our results support the safety and efficacy of one step approach in diagnosing and treating uterine malformation in a single outpatient setting access, performing a save-time treatment for a patient looking for a pregnancy.

Patient vs operator experience of outpatient hysteroscopy as an acceptable diagnostic procedure

Matteo De Martino¹, Mohamed Ragab¹, Rishita Shah¹, Dilip Visvanathan¹
¹Whipps Cross Hospital, Obstetrics & Gynaecology, London, United Kingdom

Background

To observe the differing perception of the success of an outpatient hysteroscopy procedure between the patient and the operating surgeon

Methods

An audit of 100 outpatient hysteroscopy (OPH) procedures was undertaken across several practitioners, including Consultants, Registrars and Nurse hysteroscopists. The primary aim of the audit was to benchmark our outpatient service against the British society of gynaecology endoscopy's standards but to also collect data on the operator's experience allowing us to contrast this with the patient's experience. This was done using a modified version of the BSGE standardised Outpatient Hysteroscopy-Patient Satisfaction Survey. The patient experience was benchmarked by looking at information provided prior to the procedure and overall their experience of the service plus whether they would choose to have the procedure again the same way if they were in the same situation again. It was felt the latter question provided a good indicator of a patient's satisfaction as choosing to have it the same way again suggests a high level of satisfaction with the procedure

Results

Our unit performed well when benchmarked against BSGE standards for pre-consultation preparation with 93% of patients receiving written information ahead of the appointment and 94% of them finding it clear and understandable. 85% of patients scored the service as excellent and only 1% scored it as poor.

Of the entire cohort, 90% said they would choose outpatients hysteroscopy if they were in the same situation again. Out of the cohort who said they wouldn't have it the same way again, 66% of operators graded the procedure as not completed, with 50% of those graded as challenging and 33% as straightforward/average in difficulty. Of the 66% not completed, 80% were abandoned due to pain and 20% due to stenosis. The majority of this group were older than 70yrs and/or white British.

From the cohort that were happy to have an OPH again, only 2.4% weren't completed (one due to pain) and only 7% of the entire cohort were thought to be complex.

Conclusions

Our initial results suggest our unit is achieving a good standard of service and patient preparation when benchmarked using the BSGE tools but more importantly, especially in the current climate of media and societal interest in OPH, it also suggests that a significant majority of our patient's find the experience agreeable and would be willing to repeat it. Not only this but our operators and patients experienced the procedure in a similar manner with few of the straightforward procedures being graded as incomplete by the operator or not likely to be repeated by the patient, whereas a significant majority of those who said they wouldn't repeat it weren't completed as the patient's pain was recognised and the procedure considered difficult.

Complications of operative hysteroscopy according to hysteroscope diameter : an assessment of professional practices at Angers University Hospital

Camille Lesvenan¹, Mathieu Levailant², Guillaume Legendre¹

¹University Hospital Angers, Gynecology, Angers, France

²University Hospital Angers, Public Health, Angers, France

Background

There are several diameters of hysteroscope used in daily practice. The use of mini resectors is booming in comparison with conventional resectors. The main advantage of these tools is that they require less dilatation. There are no studies on the impact of miniaturization on complication rates, particularly during dilatation, or on surgical performance (rate of complete procedure, operating time). The primary objective was to determine the complication rate following operative hysteroscopy according to diameter. The secondary objectives were to evaluate the rate of complete surgery, operative time and postoperative pain in relation to diameter.

Methods

Prospective single-center observational study including all adult women undergoing operative hysteroscopy (endometrectomy, myoma resection or polyp resection) using bipolar Delmont Imaging® 18 French or 26 French hysteroscopes between 1/06/2020 and 1/06/2021. The primary endpoint was the occurrence of intraoperative complications such as cervical tears and uterine perforation. Secondary endpoints were rate of complete procedure, operative time and postoperative pain.

Results

Of 117 patients included, the hysteroscope used was an 18 French for 89 patients (76.1%) and a 26 French for 28 patients (23.9%). The populations were comparable according indication of hysteroscopies. Complications occurred in 6 cases (5,1%) with an 18 French hysteroscope and in 5 cases (4,2%) with a 26 French hysteroscope ($p < 0,05$). Surgery was complete in 79 (89,8%) cases with an 18 French hysteroscope and in 23 cases (85,2%) with a 26 French hysteroscope ($p = 0,51$). The average operative time was 18,2 minutes with an 18 French hysteroscope and 23 minutes with a 26 French hysteroscope ($p = 0,09$). Postoperative pain was reported in only 4 cases (3,4%) with an 18 French hysteroscope and in 1 case with a 26 French hysteroscope (0,85%) ($p = 0,88$).

Conclusions

Hysteroscopy is a procedure with a minor surgical risk, yet it is usually complete, rapid and painless, with a better risk-benefit ratio in favor of smaller diameter resectors.

HPV 16/18 E7 oncoprotein detection as a promising triage strategy for HPV 16/18-positive patients: a multicentre study

Yang Cao¹, Xiaoping Xiao¹, Ye Lu², Chongdong Liu³, Lan Zhu¹, Honghui Shi¹

¹National Clinical Research Center for Obstetric & Gynecologic Diseases- Department of Obstetrics and Gynecology- Peking Union Medical College Hospital- Chinese Academy of Medical Sciences & Peking Union Medical College, Department of Obstetrics and Gynecology, Beijing, China

²Peking University First Hospital, Department of Obstetrics and Gynecology, Beijing, China

³Beijing Chao-Yang Hospital- Capital Medical University, Department of Obstetrics and Gynecology, Beijing, China

Background

High-risk human papillomavirus (HPV) infection is considered to be the most important factor in the development of cervical cancer and cervical intraepithelial neoplasia (CIN). However, direct colposcopy referral of women with HPV 16/18-positive results tends to result in high rates of colposcopy referral due to the characteristics of "transient" infection and low specificity of HPV testing. Overexpression of E7 oncoprotein were found involved in the transformation and progression of CIN, which may be a potential marker for CIN. Therefore, we carried out this study to assess whether the detection of the HPV 16/18 E7 oncoprotein could serve as a promising triage option for HPV 16/18-positive patients in multiple centers in urban China.

Methods

We collected 915 exfoliated cervical cell samples from patients who tested positive for HPV 16/18 infections in the gynecological clinic of three tertiary hospitals in Beijing between March 2021 and October 2022; we conducted further analyses using the HPV 16/18 E7 oncoprotein assay before colposcopy and biopsy. The triaging effect of the HPV 16/18 E7 oncoprotein assay in HPV 16/18-positive samples was analyzed based on the gold standard of cervical pathology.

Results

The positivity rate of the HPV 16/18 E7 oncoprotein assay was 42.06% (249/592) in the inflammation/CIN 1 group and 85.45% (277/324) in the CIN2+ group ($P < 0.05$). For CIN2+ detection, using the HPV 16/18 E7 oncoprotein assay combined with HPV 16/18 testing, the sensitivity, specificity, positive predictive value (PPV) and negative predictive value (NPV) were 85.45%, 57.94%, 52.57% and 87.95%, respectively. Moreover, the longitudinal follow-up of seven patients showed that most HPV 16/18 E7 oncoprotein expression correlated well with cervical lesion grades.

Conclusions

As a triage method for high-grade CIN screening in HPV 16/18-positive patients, the HPV 16/18 E7 oncoprotein assay combined with HPV 16/18 testing improves the diagnostic sensitivity and specificity, which reduces the colposcopy referral rate and has the potential for long-term monitoring of high-grade CIN.

Unravelling neuronal progenitor cell states and reshaped immunosuppression in neuroendocrine carcinoma of the cervix: novel biomarkers and precise treatment insights

Qinqin Liu¹, Xinyu Qu¹, Junjun Qiu¹, Keqin Hua¹

¹*Obstetrics and Gynecology Hospital of Fudan University, Department of Gynecology, Shanghai- China, China*

Background

Neuroendocrine carcinoma of the cervix (NECC) is a highly aggressive subtype of cervical cancer (CC) with a worse prognosis than conventional CC subtypes. Yet the tumor microenvironment (TME) of NECC remains poorly understood. Here, we aimed to dissect the immune signatures and explore novel potential therapies specifically for NECC.

Methods

We conducted single-cell RNA sequencing (scRNA-seq) coupled with T cell receptor sequencing (TCR-seq) in two NECC, two squamous cell carcinomas (SCC), and two adenocarcinomas of the cervix (ADC) to explore their transcriptomic heterogeneity. Whole exome sequencing (WES) was performed on two NECCs and one paired blood sample to further investigate genomic oncogenesis of NECC. Moreover, multicolor immunohistochemistry (mIHC) helped validate the colocalization of intercellular crosstalk between tumor infiltrating lymphocytes (TILs).

Results

Within the NECC TME, we innovatively identified neuronal progenitor cells (NPCs) as the malignant origin of NECC, and their three differentiated states exhibited remarkable functional plasticity, providing important clues to improve treatment selections. Furthermore, we uncovered the DLL3-NOTCH1/2 signaling between tumor cells and TILs, as well as the positive feedback regulatory loop (T exhaustion-B/plasma recruitment-T further exhaustion) within lymphoid aggregates in NECC, which collaboratively leads to the immunosuppressive tumor immune microenvironment (TIME). As for clinical value, INSM1 and DLL3 were identified as potential diagnostic biomarkers to distinguish NECC from other CC subtypes, owing to their specific and remarkable expression in NPCs. Most importantly, we proposed promising strategies targeting five cancerous hallmarks of NECC. (1) **Targeting genome instability and mutation:** NECC with ALK, KDR, or BRCA1 gene mutations, may respond well to corresponding inhibitors. (2) **Targeting immune dysfunction:** Immune checkpoint blockade may benefit NECC with high expression of immune checkpoints, such as CD38, HAVCR2, CTLA4, LAG3, PDCD1, and TIGIT. (3) **Targeting tumor metabolism:** For FAM162A+PFKFB3+ NECC, glycolysis inhibitors could be considered. (4) **Targeting proliferative signaling:** Anti-proliferative drugs including platinum-based therapy and CDK inhibitors might effectively control CDKN3+MKI67+ NECC tumor. (5) **Targeting invasion and metastasis:** DLL3-targeted therapy can be regarded as a potent alternative for NECC featuring specific expression of DLL3.

Conclusions

Three differentiated NPC types showing an unconventional developmental trajectory, together with the dysregulated TIME significantly contribute to the extremely malignant phenotype of NECC. Most significantly, we pioneeringly depicted a precise treatment landscape for NECC, hopefully laying the groundwork for the

development of new combination-based therapeutic strategies (Figure 1).

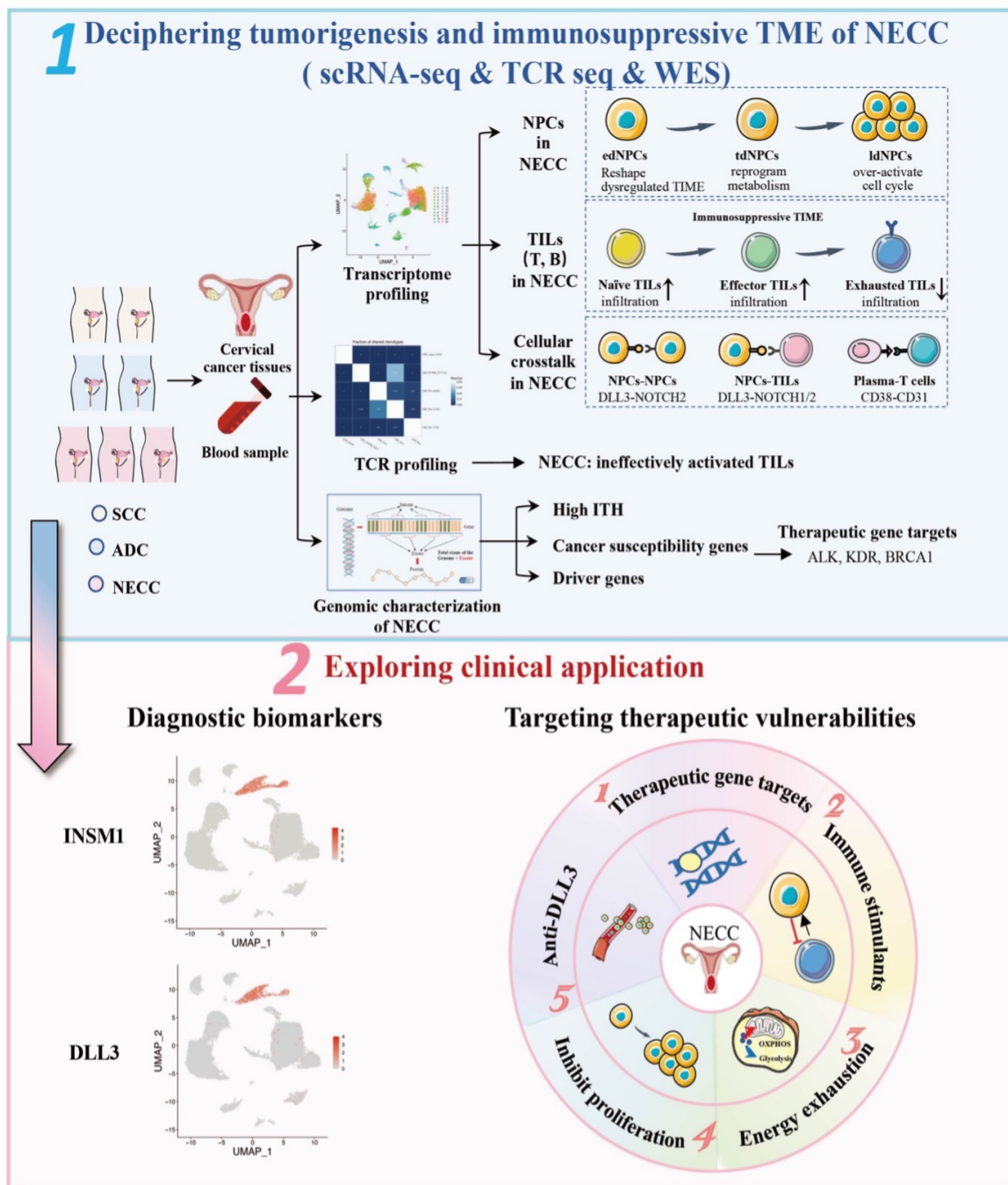


Figure 1. Schematic diagram exhibiting the main methods and significant findings

Differential expression of insulin growth factor 1 (IGF-1) isoforms in different types of endometriosis - preliminary results of a single-center study

Nikolaos Blontzos¹, Despoina Mavrogianni², Nikolaos Kathopoulos², Konstantinos Ntzeros², Ioannis Chatzipapas², Athanasios Protopapas²

¹University of Athens,

Endoscopic Surgery Unit- and Experimental Laboratory First Department of Obstetrics and Gynecology, Athens, Greece

²University of Athens,

Endoscopic Surgery Unit- and Experimental Laboratory- First Department of Obstetrics & Gynecology, Athens, Greece

Background

Endometriosis represents a heterogeneous clinical entity that could be categorized into three distinct subtypes: ovarian endometriomas, superficial peritoneal implants and endometriotic nodules deeply infiltrating the retroperitoneal space. Despite extensive research and numerous theories, the exact pathogenetic mechanism of the disease remains uncertain. Insulin growth factor 1 (IGF-1) is one of the factors implicated in the pathogenesis of endometriosis. Alternative splicing during gene expression allows coding of three isoforms: IGF-1Ea, IGF-1Eb, and IGF-1Ec or MGF. The exact physiological action of these isoforms in different subtypes of endometriosis has been poorly investigated.

The aim of this current study was to evaluate the differential expression of the IGF-1 isoforms in deeply infiltrating endometriotic lesions, in ovarian endometriomas, and in their eutopic endometrium, and compare it with their expression in the eutopic endometrium of women without endometriosis.

Methods

Our study included 45 patients: 30 patients with histologically-proven endometriosis, of whom 11 with endometriomas (EMAs-only group), 19 with deeply infiltrating endometriosis (DIE group), and 6 with concurrent DIE and ovarian endometriosis (EMAs+DIE group), as well as 9 patients without endometriosis comprising the control group. RNA isolation was performed and real time PCR was applied using the LightCycler480II instrument and LUNA Universal qPCR Master Mix (NEB) in order to detect the differential expression of transcripts.

Results

All isoforms were highly expressed in the eutopic endometrium of patients in the endometriosis group, and in all subgroups, when compared to the eutopic endometrium of the control group ($p < 0,01$). Detection of isoform 1Ea, showed a higher expression in endometriomas with DIE when compared to samples of endometriomas without DIE and to DIE samples. Similarly, samples from endometriomas with DIE showed a higher expression of 1Ec when compared to samples of endometriomas without DIE and to DIE samples. Concerning isoform 1Eb non-invasive endometriomas have the same expression levels as invasive endometriomas.

Conclusions

The current study is the first to identify the expression of all IGF-1 isoforms in DIE samples. We have noticed a similar pattern of expression between IGF-1 Ea and IGF-1 Ec, that differs from IGF-1 Eb. Our results are consistent with our primary hypothesis that differential expression of IGF-1 isoforms may indicate that DIE and ovarian endometriosis should be considered as completely different diseases. The above results indicate that studying the expression of the different isoforms of IGF-1, may provide valuable information on the pathogenesis and evolution of endometriosis

Impact of hysterectomy in women affected by adenomyosis and recto-sigmoid endometriosis: preliminary data from a prospective study

Martina Alessandrini¹, Alessandro Arena¹, Eugenia Degli Esposti¹, Benedetta Orsini¹, Michele Altieri¹, Renato Seracchioli¹

¹Division of Gynaecology and Human Reproduction Physiopathology- IRCCS- Azienda Ospedaliero-Universitaria di Bologna, Department of Medical and Surgical Sciences DIMEC- University of Bologna, Bologna, Italy

Background

Women affected by endometriosis and adenomyosis may experience painful symptoms that heavily affect their quality of life. Although the association between adenomyosis and recto-sigmoid endometriosis is known (co-existing in 27-90% of patients), few studies have focused on the impact of hysterectomy on the quality of life of these patients.

Hysterectomy in patients with endometriosis is often a complex procedure and current data about its impact on the improvement of symptoms are conflicting.

The main outcome of the study is the comparison between endometriosis-related symptoms before and 6 months after surgery.

Methods

In our prospective observational study, from January 2021 we enrolled 46 symptomatic women, older than 40 years old, affected by adenomyosis, scheduled for laparoscopic surgical removal of recto-sigmoid endometriosis, with or without hysterectomy.

We acquired data on anamnestic characteristics, pre-operative endometriosis-related symptoms through the validated questionnaire Endometriosis Health Profile 5 (EHP-5).

Women also received a transvaginal and transabdominal ultrasound to map endometriosis lesions.

Data about perioperative outcomes and endometriosis-related symptoms 6 months after surgery (measured through the EHP-5) were collected.

Results

Nineteen women underwent hysterectomy during surgery for recto-sigmoid endometriosis, while twenty-seven had only surgery for recto-sigmoid endometriosis removal.

Before surgery, both groups presented similar characteristics in terms of age, BMI, previous endometriosis surgery and ultrasonographic dimensions of the posterior endometriosis nodule (29.1 + 11.0 mm for the hysterectomy group versus 33.3 + 14.1 mm for the non-hysterectomy group, $p = 0.281$).

Moreover, the EHP-5 preoperative scores were comparable between the two groups: 56.1 + 12.9 for the hysterectomy group versus 48.3 + 14.3 for the non-hysterectomy group ($p = 0.65$).

After 6 months follow-up, women belonging to hysterectomy group had a significant improvement of their symptoms compared to women of non-hysterectomy group: the post-surgical EHP-5 scores were 24.3 + 18.2 for the hysterectomy group versus 32.4 + 17.0 for the non-hysterectomy group ($p < 0.05$).

Surgical approach for removal of recto-sigmoid nodule (shaving, disc excision, bowel resection) and perioperative surgical complications were comparable between the two groups, as well as the length of hospitalization

Conclusions

Women older than 40 years old with diagnosis of adenomyosis, who undergo laparoscopic surgery for recto-sigmoid endometriosis, seems to benefit from the addition of concomitant hysterectomy in terms of endometriosis-related symptoms, compared to those who preserve the uterus, without increased complications rates.

These data should be discussed during preoperative counselling.

Complex case of synchronous carcinoma

Reem Al Awadhi¹, Nazeha Al Ghuzi¹, Sara Al Kaabi¹, Ebtehal Al Ramsi¹, Muhieddien Seoud²

¹*Corniche Hospital, Obgyn, Abu Dhabi, United Arab Emirates*

²*Sheikh Shakhbout Medical City, Gyne-Oncology, Abu Dhabi, United Arab Emirates*

Background

Demonstration of the importance of personalization of patient care management and use of multidisciplinary team approach in complex cases.

Methods

A 67-year-old female with a history of recurrent abdominal wall hernia requiring repeated surgical repair. The most recent repair was on September 2021, where pre-operative work up included a CT scan of abdomen and pelvis that confirmed the recurrence of the abdominal wall hernia and partially visualized a left breast lesion. The patient's post-operative course was complicated by abdominal wall abscess and sinuses. She remained in hospital for 3 months post-operatively and had repeated wound exploration. In January 2022, the patient had a PET CT scan that showed a 4x3.8cm left breast mass consistent with multicentric breast cancer and an intensely FDG avid mass in the endometrium measuring 3.7x3.7cm, consistent with a synchronous malignancy in the uterus. Biopsy of the left breast lesion identified grade 2, ER-positive, PR-positive intraductal carcinoma with positive axillary biopsy. Endometrial biopsy demonstrated a grade 1 endometrial carcinoma. The patient was presented in the local and national tumor board. Considering the patient was a poor surgical candidate and unsuitable for chemotherapy due to repeated abdominal wall infections, the consensus was to delay surgical management and start hormonal therapy with aromatase inhibitor.

The patient continued to be followed up in our gynae-oncology department and on August 2022, repeated endometrial biopsy showed an inactive endometrium with no evidence of malignancy. During this time, she had repeated admissions due to the abdominal wall abscess with numerous courses of antibiotics. Her case was presented again in local tumor board and the breast cancer surgery was prioritized. In December 2022, the patient was finally deemed fit for surgery and underwent simple mastectomy and axillary clearance. She started adjuvant radiotherapy for breast cancer management and was continued on aromatase inhibitor.

Her most recent presentation to our gynae-oncology facility was in March 2023. Patient was stable after removal of abdominal mesh, and her abdominal wound was healing. The repeated endometrial biopsy showed minute fragments of glandular epithelium. Transvaginal ultrasound was still showing a thickened endometrial of 2.9 cm. The patient is currently planned for a hysterectomy via Vaginal Natural Orifice Transluminal Endoscopic procedure, considering her poor abdominal surgical history and absence of cervical descent on pelvic examination.

Results

Synchronous malignancies are rare to occur and in our case breast and endometrial cancer might indicate hormonal or environmental influences. Diagnosis of two primary carcinomas is difficult and requires high clinical suspicion. Management of complex cases with comorbidities also requires personalization of care and use of sound clinical judgment to avoid undue patient harm.

Conclusions

Advocate for patient centered care and use of multidisciplinary team approach when managing complex oncological cases.

Pelvic floor dysfunction and sexual dysfunction in women undergoing gynecologic cancer surgery

Krystal Nyangoh Timoh¹, Marie Allegrini¹, Vincent Lavoue¹, Jean Leveque¹
¹CHU Rennes, Gynecology Obstetrics, Rennes, France

Background

Recent improvements in the management of gynecological cancer have led to an increase in their life expectancy. However, there is little data on the prevalence of pelvic floor dysfunction among this population. The objective of this work was to evaluate the prevalence of pelvic floor disorders before and after surgery.

Methods

This is a prospective observational study at the University Hospital of Rennes and the University Hospital of Caen from December 2020 to January 2022. All patients operated on for ovarian, endometrial or cervical cancer were included. Patients received the following questionnaires: Bfluts, ICIQ-SF, PFDI-20, PFIQ-7, Wexner score, Obstruction Defecatory Symptoms (ODS), Irrico questionnaire, Female Sexual Functioning Index (FSFI), Hospital Anxiety and Depression scale (HAD), and finally the Euroqol 5 Dimensions (EQ5D) - (VAS).

Results

The comparative analysis of the pre and post operative group shows a significant improvement of prolapse symptoms (POPDI-6 score) in the post operative period. There was also a significant improvement in response to the VAS postoperatively. In the subgroup of severe anal dyschezia, there was an improvement of these symptoms postoperatively. Finally, in the subgroup of women who had no sexual dysfunction preoperatively, we found a significant worsening of their sexual life postoperatively ($p=0.02$).

Conclusions

A global pelvic-perineological management is necessary during the oncological management of patients with pelvic gynecological cancer.

Fertility sparing treatment in young women with early endometrial cancer: hysteroscopic resection followed by progestin therapy

Alina Hernández Fleury¹, Sonia Monreal¹, Silvia Cabrera¹, Eva Vila¹, Laura Mañalich¹, Antonio Gil¹
¹Hospital Vall d'Hebron, Gynecology and Obstetrics, Barcelona, Spain

Background

Although endometrial cancer (EC) is usually diagnosed after menopause, approximately 5% of the patients will be diagnosed between 35 and 44 years. The standard treatment for EC and Endometrial hyperplasia with atypia (EHA) is total hysterectomy with or without bilateral salpingo-oophorectomy and with or without pelvic and para-aortic lymph node dissection.

In young women with favorable prognostic features, wishing to preserve fertility, the conservative management must be taken into consideration. Recent evidence-based guidelines for the fertility-sparing treatment (FST) on EC suggest the treatment with hysteroscopic tumor resection followed by and hormonal therapy as the most effective FST.

The objective is to describe the oncologic and obstetric outcome in patients with early-stage EC who carry out a fertility sparing treatment in our hospital.

Methods

We performed a descriptive observational study in Hospital Vall d'Hebron, Barcelona. We included a total of 7 patients, aged between 35 and 42 years, with diagnosis of early-stage EC who wanted to preserve fertility during the period of 2013 and 2023.

Results

Seven patients with early-stage EC (stage IA, G1 endometrioid EC) or EHA and gestational desire were enrolled. EC was diagnosed during investigations for infertility in 4 cases, abnormal uterine bleeding in 1 case and 2 cases because of endometrial thickening.

Four patients were treated with hysteroscopic resection combined with LNG-IUD for 6 months or more, 2 with hysteroscopic resection combined with megestrol acetate and LNG-IUD and 1 just LNG-IUD. Hysteroscopic resection was used to resect the tumor, endometrium adjacent to the tumor and myometrium underlying the tumor. The follow up was every 3 months.

Two of seven patients achieved pregnancy through assisted reproductive techniques (ART) and 1 is still in ART. One patient gave birth at 37 weeks of pregnancy because of intrauterine growth restriction with no neonatal morbi-mortality. The other received a C-section because of chorioamnionitis. Once the desire for childbearing was achieved a definitive hysterectomy was carried out. Two of the patients have recently been diagnosed and have not yet had their first three-month follow-up.

Two women didn't achieve a complete response with FST. One case after 6 months follow up no response was observed therefore the patient received standard treatment for EC and is free of disease.

The other developed ovarian metastasis of EC in course of FST and received complete surgery. She died 2 years after diagnosis.

Conclusions

The conservative management with hysteroscopic resection followed by progestins and/or LNG-IUD of EHA and early-stage of EC is an option to consider if the patient has a desire for childbearing.

The molecular profiling of the tumor can open the way to a new line of research in these patients with the aim to individualize the treatment.

High-risk human papillomavirus-infected patients with high methylation levels of JAM3/PAX1 in cervical exfoliated cells are diagnosed with high-grade cervical lesions

Xingping Zhao¹, Dan Sun¹, Dabao Xu¹

¹Third Xiangya Hospital of Central South University, Department of Gynecology, Changsha, China

Background

Traditional screening methods for cervical cancer, such as hrHPV testing and cervical cytology, have limitations. This study aimed to investigate the diagnostic ability of JAM3/PAX1 methylation levels in cervical exfoliated cells for high-grade cervical lesions and cervical cancer classification. Additionally, we compared the predictive ability of JAM3/PAX1 methylation for high-grade cervical lesions with liquid-based cytology, also known as TCT, in order to explore new diagnostic models for cervical lesions and cancer and achieve the goal of "precision screening" for cervical cancer.

Methods

A total of 136 patients who underwent examination at the Department of Gynecology, Third Xiangya Hospital of Central South University, from June 2021 to June 2022 were included in this study. Among them, 122 patients had non-high-grade cervical lesions (control group) and 14 patients had high-grade lesions (study group). The variables studied included basic information (age, BMI, menopausal status), Thinprep cytologic test (TCT) results, high-risk human papillomavirus (hrHPV) status, cervical tissue pathology, vaginal microbiota results, colposcopy findings (cervical transformation zone type), Δ Ct values of JAM3 (Δ CtJ) and PAX1 (Δ CtP) gene methylation. Initially, univariate analysis was performed to identify factors associated with high-grade cervical lesions, followed by correlation analysis. Finally, meaningful variables identified in the univariate analysis were used to construct a conditional inference tree model.

Results

Univariate analysis revealed significant differences in Δ Ct values of PAX1 and JAM3 gene methylation and TCT results between the two study groups ($P < 0.05$). The conditional inference tree model showed that when Δ CtJ > 10.13 , all patients had non-high-grade cervical lesions. When Δ CtP > 6.22 , 97.5% of patients had non-high-grade lesions, while only 2.5% had high-grade lesions. When Δ CtJ > 8.61 and TCT showed atypical squamous cells of undetermined significance (ASC-US) or negative for intraepithelial lesions or malignancy, 99.1% of patients had non-high-grade lesions, with only one detecting PAX1/JAM3 high-grade lesions. When TCT indicated high-grade squamous intraepithelial lesions (HSIL), only 66.7% of patients had high-grade lesions, while 33.3% had non-high-grade lesions. However, when TCT indicated low-grade squamous intraepithelial lesions, ASC-US, or NILM, and Δ CtP > 6.22 , 97.5% of patients had non-high-grade lesions.

Conclusions

Gene methylation detection of JAM3/PAX1 can be independently used for stratified diagnosis of high-grade/non-high-grade cervical lesions in women with HPV infection, without relying on cervical cytology test results. It can also be combined with TCT to overcome the low specificity of TCT. Additionally, the application of methylation detection kits in large-scale cervical cancer screening, particularly in economically underdeveloped regions, is advantageous for identifying more patients with high-grade cervical lesions and achieving early detection and treatment of cervical lesions/cancer.

New horizons in gynecological surgery: our first-year experience with HUGO robotic assisted surgery system

Margarita Afonina^{1,2,3}, Giorgia Gaia¹, Koen Traen³, Claudia Collà Ruvolo^{4,5}, Anna Maria Marconi¹, Alex Mottrie^{4,6}

¹San Paolo Hospital Medical School, Department of Obstetrics and Gynecology, Milan, Italy

²Orsi Academy, Department of Obstetrics and Gynecology- training center, Melle, Belgium

³OLV, Department of Obstetrics and Gynecology, Aalst, Belgium

⁴OLV, Department of Urology, Aalst, Belgium

⁵Orsi Academy, Department of Urology- training center, Melle, Belgium

⁶Orsi Academy, Department of Urology, Melle, Belgium

Background

Over the past few decades, robot-assisted surgery has gained ground in gynecology thanks to its higher mobility, precision, and enhanced 3D visualization. Da Vinci® surgical system dominated the field until 2019 when new contenders emerged to reduce costs while maintaining benefits. The HUGO™ Robotic Assisted Surgery System (RAS, Medtronic, CA), approved in 2021, presents a new 3D open console, four independent carts, and an integrated laparoscopic and robotic tower. Several studies have already reported results for urological and general surgery procedures. However, data in the gynecological field are scarce. The aim of our study is to report our first-year experience with this new system for gynecological procedures in two tertiary referral multiplatform robotic centers.

Methods

We prospectively collected and retrospectively analyzed data from patients underwent gynecological robot-assisted surgery with the HUGO™ RAS system, between March 2022 and April 2023 at San Paolo University Hospital (Milan, Italy), and Onze Lieve Vrouw (OLV) Hospital (Aalst, Belgium), performed by three expert robotic surgeons. Demographics, intra-operative settings, and peri-operative outcomes were investigated.

Results

A total of 32 procedures were performed: 20 (62.5%) hysterectomies, 7 (21.9%) adnexal surgeries, and 5 (15.6%) pelvic floor reconstructive surgeries. In 2022 and 2023, 13 (40.6%) and 19 (59.4%) procedures were carried out, respectively. The overall patients median age was 51.5 (IQR 40.8-61.8). The median total operative time was 87.5 minutes (IQR 70.2-127), with a median docking time of 20 minutes (IQR 10-30) and a median console time of 62.5 minutes (IQR 41.2-113.2). No intra-operative complications occurred. Two conversions to laparoscopy due to system malfunction were recorded. Both procedures were managed without any additional complications. One post-operative complication (unilateral hydronephrosis) was observed.

Conclusions

To the best of our knowledge, this is the first global series of gynecological procedures performed with the HUGO™ RAS. Our initial findings showed the platform's feasibility reporting promising results from two centers characterized by different equipments and various expertise. The uneventful conversion to laparoscopy, facilitated by the integrated tower, highlights the technology's remarkable versatility. Additionally, the observed upward trend in the total number of procedures performed during the analyzed period is encouraging. Further studies are needed to assess a standardized method in the gynecological field with the new platform.

Practice variation in the care for women with idiopathic heavy menstrual bleeding: preliminary results from a Dutch multicenter real world evidence study

Daniëlle Huijs¹, Maarten Vink², Peggy Geomini¹, Jaklien Leemans¹, Marlies Bongers¹

¹*Máxima Medical Center, Obstetrics and Gynaecology, Veldhoven and Eindhoven, The Netherlands*

²*Meander Medical Center, Obstetrics and Gynaecology, Amersfoort, The Netherlands*

Background

Heavy menstrual bleeding (HMB) is a common health problem that significantly affects quality of life. According to the Dutch guideline, the levonorgestrel intra-uterine system (LNG-IUS) is preferred over surgical treatment such as endometrial ablation (EA) as treatment for idiopathic HMB. However, a recently published study indicated that practice patterns differ among hospitals. This variation most likely reflects guideline non-adherence. Nevertheless, detailed information of practice variation is missing due to limitations regarding data acquisition. Hence, the aim of this study is to assess practice patterns in the care for women suffering from idiopathic HMB that visited the gynaecology outpatient clinic in the Netherlands. The study's findings could identify areas for improvement, ultimately helping to avoid overtreatment or undertreatment and develop strategies to increase adherence to the guidelines.

Methods

This is a retrospective real world evidence study in six large teaching hospitals in the Netherlands. Data concerning diagnosis and treatment from all women that visited a gynaecologist for idiopathic HMB in 2019 is currently being collected by a clinical data collector (CDC) (CTcue, Amsterdam, The Netherlands). Both structured and unstructured data can be collected by the CDC. Outcomes include the number of treatments before and after index treatment (medication, LNG-IUS, EA or hysterectomy), a specification of treatment(s) before or after index treatment and logistic features of the diagnostic en therapeutic process. Data for each participant was collected starting on the date of the first consultation and ended December 31st 2022.

Results

To date, preliminary raw data from three hospitals has been collected. In total, 1045 women were included. The mean number of treatments for HMB was 0.7 (range 0.6-0.9). Mean percentage of women that did not receive any treatment was 36.3% (range 34.6-37.7%). A considerable difference in the percentage of women that had undergone EA was observed: mean 17.1%; range 13.3-21.9%. The proportion of women that needed an additional treatment after EA ranged from 15.3-27.3%. Procedural sedation and analgesia during EA was applied in approximately half of the cases in two hospitals (44.1% and 56.1%). In the other hospital the vast majority of women (83.7%) was treated under general anesthesia. Diagnostic hysteroscopy was performed in almost all women (96.6%) before/after EA in one center, while in the other two hospitals no diagnostic hysteroscopy was executed before/after EA. The mean hysterectomy rate was 4.6% (range 3.7-6.3%) and the proportion of laparoscopic hysterectomy varied from 57.1-86.7%.

Conclusions

These preliminary results demonstrate that significant practice variation in the care for women with idiopathic HMB is present in the Netherlands. After study completion, our results will be an essential entry point to explore the cause of the observed practice variation, which will lead to further standardization and optimization of care for women with idiopathic HMB.

Laparoscopy is competent to do it !

Mohamed Salama¹, Elakhras Sayed², Vasilios Tanos³

¹Ain Shams University, Obstetrics and Gynaecology, Cairo, Egypt

²Omam Hospital, O&G and Minimally-invasive Surgery, Cairo, Egypt

³University of Nicosia Medical School, Obstetrics and Gynaecology, Nicosia, Cyprus

Background

Laparoscopic surgery is increasingly gaining momentum as an advantageous approach to perform complex surgeries. As is the case with any intervention, it is not without complications.

Traditionally, conversion to laparotomy was the conventional approach to the management of laparoscopic complications. However, in this presentation, we hope to show the competence of laparoscopy in managing its own complications.

Methods

We present a wide spectrum of laparoscopic complications, from our own cases as an advanced referral centre for minimally-invasive surgery. Through these cases we show that laparoscopy can be used for management of complex and complicated situations that resulted as complications of laparoscopic interventions. Such cases were traditionally thought of as indication for conversion to laparotomy.

Results

A wide range of laparoscopic complication, including cases of intestinal obstruction, internal and external herniation, pelvic and generalised septic peritonitis and even major vascular injuries, were managed by laparoscopy without the need for conversion to laparotomy.

We hope to deliver a message of confidence in the competence of laparoscopy, in the hands of appropriately trained and skilled hands, and in suitably equipped settings, in dealing with its own complications.

Conclusions

Laparoscopy can be trusted as a competent enough tool to manage its own complications. This necessitate appropriate training and well equipped settings. This concept of thought hopefully will alleviate the anxiety, especially encountered by young laparoscopic surgeons, while dealing with such complications or disclosing them to their patients.

Hysteroscopic camera skills can be transferred to laparoscopic surgery but not vice versa – results of a prospective, randomized controlled trial

Mona Wanda Schmidt¹, Charlot Sittig¹, Linda Battling¹, Christine Skala¹, Annette Hasenburg¹, Katharina Anic¹
¹University Medical Center of the Johannes Gutenberg University Mainz,
Department of Gynecology and Obstetrics, Mainz, Germany

Background

Hysteroscopic and laparoscopic surgery are key skills for any gynecologic surgeon. Despite both being minimally invasive surgery, it remains unclear whether acquired skills can be transferred between both surgical modalities. Thus, we aimed to investigate the transferability of surgical camera navigation skills between laparoscopic and hysteroscopic surgery.

Methods

66 medical students were recruited for this prospective, randomized-controlled cross-over trial. All students performed 10 repetitions of a laparoscopic and a hysteroscopic camera navigation task with a 30 degrees camera optic (Camera handling/camera navigation task of the Gynecological Endoscopic Surgical Education and Assessment (GESEA) program). The order of surgical modalities was randomized. Average task time, as well as the learning curve was compared between participants with prior experience in the other surgical modality and those without. The correlation of visuospatial skills (assessed by the Mental rotation test A) with laparoscopic and hysteroscopic performance was also assessed.

Results

All participants completed the trial. On average, those with prior experience in the hysteroscopic task performed the laparoscopic task quicker (prior hysteroscopic experience: 108.2s [93-134] vs. no prior hysteroscopic experience: 140.2s [118-176], $p < 0.001$). This significant difference was seen in all 10 tries. In contrast, no difference was seen for the average hysteroscopic task time between those with prior laparoscopic experience (129.9s [113-148]) and those without (138.9s [112-164], $p = 0.462$). A significant difference between both groups was only seen on the very first hysteroscopic try ($p = 0.005$). A good correlation was seen between mental rotation abilities and total training time on both surgical modalities (laparoscopic surgery: -0.377 , $p = 0.002$; hysteroscopic surgery: -0.385 , $p = 0.001$). The correlation was greater if no prior surgical experience in the other surgical modality existed (laparoscopic surgery: -0.478 , $p = 0.005$; hysteroscopic surgery: -0.427 , $p = 0.013$).

Conclusions

Acquired camera skills in hysteroscopic surgery can be transferred to laparoscopic surgery. However, hysteroscopic camera navigation seems to require an additional skill set not learned from laparoscopic surgery. Thus, to ensure efficient and safe surgical procedures, focused hysteroscopy training should be an integral part of any training curriculum for gynecologic surgeons, even if prior laparoscopic surgical experience exists. Furthermore, mental rotation abilities can predict the initial surgical learning curve and could be used to personalize training curricula based on individual needs.

Retrospective data analysis in patients after organ-preserving myomectomy in women having a prospective desire to conceive

Felix Neis¹, Sara Brucker¹, Bernhard Kraemer¹, Konrad Schneider¹

¹University of Tübingen, Gynecologie and Obstetrics, Tübingen, Germany

Background

Uterine fibroids are the most common tumour in the pelvis and the most common benign tumour in women. Uterine fibroids affect the chances of a successful pregnancy. The extent depends mainly on the location and size of the fibroids.

Methods

Patients who underwent myomectomy (hysteroscopic, laparoscopic, open surgical and combination) between 2005 and 2014 were retrospectively enrolled for this trial. A total of 1931 applicable patients were identified and interviewed by letter about the onset of pregnancy, persistent symptoms and repeat surgery.

Results

In a total of 232 cases, a statement on the postoperative pregnancy rate could be made. In the missing cases, either incomplete data were available or there was no desire to conceive. 65 % of the patients who wanted to conceive successfully carried at least one pregnancy to term. If the fibroid weight was less than 100g, 76% of the women became pregnant after the surgery. If the weight of the enucleated fibroids was over 100g, only 58% conceived. A large difference in the rate of pregnancies was also found in relation to the age. Women aged 35 years and younger became pregnant in 70.3%, women older than 36 years only in 28.6%. No significant difference could be shown for a subsequent pregnancy regarding fibroid location. In IVF patients with myomectomy under 35 years of age, 59% had a successful birth.

Conclusions

In young patients with fibroids <100g, myomectomy seems to have a positive effect on subsequent pregnancy. Myoma weight of >100g has a significantly stronger negative impact on subsequent pregnancy, therefore surgical intervention should be indicated as early as possible in cases of fertility problems and fibroids with growth tendencies. Counselling in prospective wish to conceive and asymptomatic fibroids should therefore already be considered in patients younger than 35 years of age and in case of smaller fibroids.

ES32-0364 - VP034

Video in Poster

Cervical cyst mimicking scar defect after cesarean section

Kristyna Hlinecka¹, Zdenka Lisa²

¹Grant NU23-06-00327 AZV MZ ČR,

Department of Obstetrics and Gynecology- General Faculty Hospital and 1st Medical Faculty of Charles University, Prague, Czech Republic

²General Faculty Hospital and 1st Medical Faculty of Charles University,
Department of Obstetrics and Gynecology, Prague, Czech Republic

Background

This video demonstrates extensive laparoscopic adhesiolysis and resection of cervical cyst, sonographically mimicking cesarean scar defect (niche).

Niche forms due to poor healing of cesarean scar. Lower uterine incision towards the cervix results in poor healing. Mucus could increase the niche size.

Methods

It's usually diagnosed ultrasonographically, preferably by 2 D ultrasound. The ultrasound evaluation should be performed by highly educated examiners. 3D ultrasound is more sensitive and specific and should be used for further investigation.

Results

This case represents 38 years old primiparous women after cesarean section in advanced labour with two years infertility, pelvic, suprapubic pain and the plan to undergo embryo transfer. She was sent to our clinic with large niche, 3 cm in diameter. Our 2 D ultrasound revealed post-cesarean scar defect with the communication to the cervical canal. 3 D ultrasound showed cervical cyst with no communication. The patient was referred to hysteroscopy and laparoscopic adhesiolysis due to persistent pain. Hysteroscopy showed normal uterine cavity with no scar defect. Laparoscopy revealed massive adhesions of the uterus to the anterior abdominal wall. Extensive adhesiolysis with cervical cyst resection was performed.

Conclusions

Post-caesarean uterine niche is a relatively newer clinical entity, and its diagnosis requires high index of suspicion. Emerging evidence has emphasized on careful selection of patients requiring surgical correction. 3 D ultrasound could help us to evaluate the finding and distinguish the cyst from the large cesarean scar defect.

<https://player.vimeo.com/video/838443309?autoplay=1>

ES32-0570 - VP047

Video in Poster

Laparoscopic sacrocolpopexy and hysterectomy in a patient with uterine leiomyomas and concomitant ureterohydronephrosis

Catalin Bogdan Coroleuca¹, Andrei Manu², Ciprian Andrei Coroleuca¹, Diana Elena Comandasu¹, Elvira Bratila¹

¹Clinical Hospital of Obstetrics and Gynaecology "Prof. Dr. Panait Sârbu"- University of Medicine and Pharmacy "Carol Davila"- Bucharest- Romania, Obstetrics and Gynecology, Bucharest, Romania

²Clinical Hospital of Obstetrics and Gynaecology "Prof. Dr. Panait Sârbu", Obstetrics and Gynecology, Bucharest, Romania

Background

Pelvic organ prolapse (POP) is a condition affecting up to 40% of an outpatient setting and causes impaired body image and decreased quality of life. By the age of 85, 19% of women will have undergone a surgical cure for their prolapse. The aim of prolapse surgery is to restore the normal anatomy of the vagina and descended organs to improve or even relieve symptoms and to restore regular physiological function. Sacropexy is an abdominal-prolapse surgical procedure that restores pelvic anatomy by attaching graft material between the vagina and sacrum. Hysterectomy is one of the most performed surgical procedures in gynaecology. Laparoscopic sacrocolpopexy combines the advantage of the abdominal approach with low postoperative morbidity.

Methods

In this paper we will present a case of a 56 years old patient diagnosed pelvic organ prolapse grade IV and uterine leiomyomas and concomitant ureterohydronephrosis that underwent laparoscopic total hysterectomy with bilateral salpingo oophorectomy and sacrocolpopexy .

Results

Firstly, the total laparoscopic hysterectomy was performed and after that the sacrocolpopexy procedure. The polypropylene mesh was attached at the level of the promontory of the sacrum and at the level of sutured vaginal cuff using 0 multibraided nonresorbable material. Later, the peritoneum that was opened up along the right pelvic wall was closed using 2/0 polyglycolic sutures. Intraoperatively we discovered an enlarged uterus with multiple fibroids and the ureters dilatated. The diameter of the ureters have improved significantly during the intervention. The total operating time was 140 minutes. The mean blood loss was around 25 ml. The mean hospital stay was two days. There was no conversion to laparotomy. There were no intraoperative complications. The patient evolved well in the post-operative period. At 6 months postoperative there is no recurrence.

Conclusions

Laparoscopic sacrocolpopexy is as effective as the abdominal approach, with the main advantage being reduced recurrence, reduced morbidity associated with the procedure and low morbidity. Regarding the long-term result we can say that it provides same efficacy as the abdominal approach, better cosmetic effect, shorter hospital stay and less blood loss.

<https://player.vimeo.com/video/831532869?autoplay=1>

ES32-0646 - VP058

Video in Poster

Ureterolysis in severe endometriosis, a challenge situation intraoperatively

Luiza Placintescu¹, Nadine Di Donato²

¹QAH- Portsmouth- UK, Gynaecology Department, Portsmouth, United Kingdom

²QAH, Gynaecology, Portsmouth, United Kingdom

Background

Endometriosis affects globally approximately 10 % of all females of reproductive age. Our case study has a unique presentation due to the complexity of the disease and distorted anatomy, the challenging intraoperatively findings, and the exquisite surgical technique approach to achieve the best outcome.

Methods

In our Endometriosis Centre, we are focused on cases with advanced endometriosis coming to us from different sources such as primary or secondary care or self-referral for a second opinion or patients with recurrent disease. In this case report we are focused on the surgical approach in the treatment of endometriosis and the challenging intra-operative technique applied with robotic-assisted surgery.

Our case is a 47-year-old, multiparous woman, with two normal vaginal deliveries, cholecystectomy at age 25 and hypertension. She initially had an incidental finding of a 3 cm simple right ovarian cyst found on an early pregnancy scan in 2018. This was addressed to the gynaecology consultant and a repeat pelvic scan at 6-month interval showed consistency of the cyst size and structure being described as dermoid cyst. Conservative management with surveillance approach was decided in agreement with the patient for a six-monthly review as the patient remained asymptomatic and there was no suspicion of any concerning futures. In June 2021 patients underwent elective RSO and left salpingectomy due to the persistence of the complex ovarian mass marginally increased Ca125. In September 2021 she was presented with severe LIF pain and left hydronephrosis due to indentation of the distal left ureter caused by an 11 cm left complex ovarian cyst. This was released by an emergency laparoscopic drainage of the left ovarian cyst and left ureteric stent insertion. Following MDT and a repeat MRI, patients underwent robotic pelvic clearance in May 2022.

Results

Intraoperatively the presentation of the frozen pelvis with extensive dense adhesions and fibrotic tissue was initially noted. The grossly dilated left ureter from the pelvis brim to the bladder and a 10 cm left adnexal cyst was the most challenging part of the surgery when ureterolysis was performed. The left ureter was carefully identified by dividing the scarred tissue millimeter by millimeter using robotic monopolar scissors, fenestrated bipolar forceps, and suction irrigation. The procedure was successfully completed as planned, without perioperative complications.

Conclusions

This was a challenging case which made the case be a unique presentation intra-operatively and imposed a highly skilled technique to obtain the maximum accuracy on ureterolysis for the best possible outcome.

<https://player.vimeo.com/video/831679553?autoplay=1>

ES32-0662 - VP061

Video in Poster

Different variants for mesh readjustment in cases of failed previous sacro- or pectopexy

Islam Magalov¹, Nargiz Nagiyeva², Aygul Mamedova², Gunel Mereyeva², Flora Huseynova²

¹Baku Branch of Sechenov Medical University, Obstetrics and Gynecology, Baku, Azerbaijan

²Baku Health Center, Obstetrics and Gynecology, Baku, Azerbaijan

Background

Laparoscopic mesh placement for pelvic organ prolapse considered difficult but effective method of pelvic organ prolapse correction. Nevertheless, besides with complications there is a rate of recurrence ranging from 1.5 to 11.2% observed by this type of surgery according to the literature. Reoperation by the same route after the failure is challenging but still suitable choice.

Methods

There is a video presentation of 5 variants of recurrence correction after sacro- or pectopexy: 1 – a case of previous mesh de novo re-attachment to the promontorium; 2 – a case of the new y – shape prosthesis implantation with total excision of previous mesh; 3- resacropexy +pectopexy ;4 – implantation of the new mesh around the cervix of the preserved uterus with its suturing to the detached distal part of the previous one which proximally retained adherent to the promontorium; and 5 – sacropexy after failed pectopexy with LASH/

Results

The mean duration of surgery according to video records was 144,98 min (min- 66,59 – max 277.24) with the most labor-intensive part related to adhesions release and bladder mobilization, especially in patients with a history of subtotal hysterectomy during initial intervention. There was no intra – and postoperative (major) complication registered. All five patients were satisfied during postoperative period within follow-up period from 6 months to 2 years.

Conclusions

Redo laparoscopy can be safe and suitable for recurrence correction after sacro- or pectopexy. Different mesh readjustment methods are suitable tailored to the peculiarities of the previous surgery.

<https://player.vimeo.com/video/835965813?autoplay=1>

ES32-0120 - VP008

Video in Poster

Diagnosis and outpatient hysteroscopic treatment of hypermenorrhoea in a patient with submucous myoma: apropos of a case.

Gabriel Molinero Mena¹, Marta Yagüe Medina¹, Sofía Fenoll Gil¹, Rocío García Berrio¹, Leticia Delgado Espárrago¹, Álvaro Zapico Goñi¹

¹Hospital Universitario Príncipe de Asturias, Gynecology and Obstetrics Service, Alcalá de Henares- Madrid, Spain

Background

Uterine fibroids are the most prevalent benign tumors in the uterus. Related symptoms include heavy menstrual bleeding, pelvic pain, infertility, or compressive symptoms.

Abundant uterine bleeding is the most frequent symptom and is related to the location of the fibroid, with submucosal bleeding (type 0, 1 and 2) being the most frequently associated.

The objective is to evaluate the effectiveness and technical complexity of hysteroscopic treatment with a morcellator for submucosal fibroids on an outpatient basis.

Methods

A 46-year-old patient was referred to a gynecology clinic due to hypermenorrhea. Vaginal ultrasound revealed a 3-cm submucosal myoma on the anterior face. Diagnostic hysteroscopy revealed a 2.5 cm type I submucosal fibroid on the anterior face, for which reason diagnostic-therapeutic hysteroscopy was indicated on an outpatient basis for excision.

For this procedure, the OMNI 30^o® hysteroscope and the Myosure® Mechanical morcellator were used with the cutting window at 100% in close contact with the fibroid surface to avoid reducing intracavitary pressure due to fluid aspiration. During the technique, a saline infusion pump at 100 mmHg was used to distend the cavity, thus minimizing bleeding due to vascular collapse. To reduce bleeding and favor vision, intermittent clamping of the suction tube was used to try to increase the pressure and thus increase vascular compression.

Inhaled Kalinox® was used as an analgesic method, with continuous monitoring of heart rate and oxygen saturation.

Results

The patient reported a pain VAS scale of 1. The test was performed in 35 minutes. Heart rate and oxygen saturation always remained in the normal range.

There were no complications during the technique or afterwards.

The follow-up of the patient was satisfactory; After 6 months of treatment, she reported cessation of hypermenorrhea, with normal menstrual cycles and recovery of quality of life. Vaginal ultrasound reflected a reduction in the size of the fibroid to 1 cm and without deforming the endometrial midline.

Conclusions

Outpatient diagnostic-therapeutic hysteroscopy with a morcellator is a safe, effective, and easy-to-perform technique for the treatment of hypermenorrhea caused by submucosal uterine fibroids up to 5 cm.

<https://player.vimeo.com/video/826299068?autoplay=1>

ES32-0185 - VP016

Video in Poster

A challenging laparoscopic hysterectomy in a woman with multiple previous caesarean sections

Maria Papageorgiou¹, Kalliopi Kordopati-Zilou¹, Theodoros Kalampokas¹, Olga Triantafyllidou¹, Nikolaos Vlahos¹, Emmanouil Kalampokas¹

¹2nd Department of Obstetrics and Gynecology- Aretaieio University Hospital, National and Kapodistrian University of Athens, Athens, Greece

Background

The presence of adhesions during a laparoscopic hysterectomy can make the procedure particularly challenging and increase the risk of injury to adjacent organs such as the bladder and the ureters or the bowel. Given the constantly increase on c-section rates the possibilities for such findings are very high, making the knowledge of retroperitoneal anatomy an essential tool for every surgeon.

Methods

This case concerns a sixty-nine-year-old woman with past surgical history including four cesarean sections, all of which were performed with a vertical midline incision. The patient was referred to our department due to an incidental finding of a five-centimeter cyst of the right ovary. Magnetic resonance imaging (MRI) findings and tumor markers were consistent with a benign disease.

Results

The patient underwent a total laparoscopic hysterectomy. Intraoperatively, the uterus was found to be strongly attached to the anterior abdominal wall. Adhesions between the mesentery and the abdominal wall were also present. Firstly, the uterus was detached from the abdominal wall. Then, both ureters were identified following development of the retroperitoneal space. Both uterine arteries were coagulated at their origin. The uterus and the ovaries were removed without rupture of the ovarian cyst. The patient was discharged the day after following an uneventful postoperative course.

Conclusions

In this video we present a challenging case of a laparoscopic hysterectomy due to the solid attachment of the uterus in the abdominal wall in a woman with multiple previous laparotomies. Overall, the management of such patients requires careful consideration and expertise in order to ensure the best possible outcome.

<https://player.vimeo.com/video/826704733?autoplay=1>

ES32-0145 - VP012

Video in Poster

Laparoscopic segmental resection combined with distal shaving for extensive bowel endometriosis treatment

Elena Rodríguez González¹, Emanuela Spagnolo¹, Violeta Romero Camacho¹, Ana López Carrasco¹, Isabel Pascual Miguelañez², Alicia Hernández Gutiérrez¹

¹La Paz University Hospital, Gynecology, Madrid, Spain

²La Paz University Hospital, Colorectal Surgery, Madrid, Spain

Background

Surgical approach to bowel endometriosis can be challenging due to the impact that extensive bowel surgeries sometimes have on patients' quality of life.

Methods

This video illustrates a case of bowel endometriosis with extensive involvement of rectosigmoid in a 31 years old patient who, despite hormonal treatment, complains of moderate-severe dysmenorrhoea, dyspareunia, dyschezia and catamenial haematochezia. Ultrasound scan revealed adenomyosis, kissing ovaries, 32 mm nodule infiltrating muscularis propria of the rectum and 14 mm nodule involving torus and right uterosacral ligament. Therapeutic decision was oocyte vitrification and laparoscopic surgery: bilateral cystectomy, bilateral salpingectomy and deep endometriosis nodules excision.

Results

Before laparoscopy, cystoscopy was performed and ICG was injected into both ureters. In a first surgical step we performed ovarian mobilisation and adhesiolysis, followed by dissection of both medial pararectal spaces and bilateral ureterolysis. This was followed by rectovaginal space dissection. Given the extensive involvement of rectosigmoid it was decided to perform shaving of the nodule involving distal rectum, retrocervix and both uterosacral ligaments, as infiltration of rectal wall at this level was limited to serosa. Subsequently, segmental resection of 3 cm nodule infiltrating rectosigmoid mucosa was performed. Termino-terminal rectal anastomosis was performed at 10 cm from the anal margin. The specimen was extracted through a 4 cm suprapubic incision. Two tests were performed to check the anastomosis: air leak test and ICG rectoscopy with the same laparoscopic tip balloon placed in the anus to check anastomosis vascularization. Patient was discharged on day 5, there were no postoperative complications. Two months after surgery the patient reported no pelvic pain or dyschezia.

Conclusions

Surgery for bowel endometriosis should be limited to patients who are symptomatic despite of conservative hormonal treatment. When extensive rectosigmoid involvement is observed it is crucial to intraoperatively plan its management to avoid extensive resections and the risk of postoperative LARS.

<https://player.vimeo.com/video/826522151?autoplay=1>

ES32-0171 - VP015

Video in Poster

Hysterectomy for large uteruses by transvaginal natural orifice transluminal endoscopic surgery (vNOTES) – the beginners' experience

Mihaela Gotseva¹, Amelie Benbara¹, Marion Fermaut², Lionel Carbillon¹

¹Jean Verdier Hospital, Obstetrics and Gynaecology, Bondy, France

²Jean Verdier Hospital, Obstetrics and Gynaecology, Bondy, France

Background

- vNOTES is a novel minimally invasive surgical technique, which in the recent years has been gaining increasing popularity. It allows performing a variety of procedures, including hysterectomy, adnexal surgery, sacrocolpopexy, uterosacral ligament suspension and myomectomy by avoiding the need for abdominal incisions. This video presentation includes a surgical video of a vNOTES hysterectomy for an enlarged uterus, shares our very initial experience with the technique and discusses the potential benefits from using this surgical approach.

Methods

This is an overview of our first experience with the vNOTES technique, a surgical video of a hysterectomy for an enlarged uterus. We have also performed a brief literature review on the safety profile of the vNOTES technique.

Results

Between September 2022 and February 2023 we performed 6 vNOTES hysterectomies, all except for the first one with an indication enlarged uterus (fibroids/adenomyosis) and menorrhagia. All patients were multiparous and most of them had a BMI>30. We did not observe any important complications. All patients were discharged on day 1 of surgery. The main disadvantage for the moment are longer operating times, however they have a trend of decreasing with our increasing experience. We also performed a brief literature review of the safety profile of the technique, which although very limited to date, may represent some advantages vs laparoscopic hysterectomy.

Conclusions

vNOTES hysterectomy is a relatively new technique with so far limited published data on the potential benefits and risks vs traditional minimally invasive techniques. It does provide the benefit of less post-operative pain, and possibly fewer surgical complications in the experienced hands. It may be also a better option for patients with high BMI and older patients due to the lower insufflation pressures and less use of Trendelenburg position. In our limited experience it can be easily applied in patients with enlarged uteruses and raised BMI by surgeons, experienced in vaginal and minimal access surgery

<https://player.vimeo.com/video/826674503?autoplay=1>

ES32-0223 - VP021

Video in Poster

Surgical treatment of focal adenomyosis - case report

Laia Pons¹, Pere Barri¹, Núria Barbany¹, Mireia Arenas¹, Clara Platón¹

¹Hospital Universitari Dexeus, Gynecology, Barcelona, Spain

Background

We present a case of 39-year-old patient, that was referred to our center for moderate dysmenorrhea since menarche, but mostly for 6 year history of infertility.

In the ultrasound examination we could identify an 44 x 38 x 36mm nodule of adenomyosis. The abdominal pelvic MRI inform about 6cm nodular image compatible with big focus of adenomyosis (adenomyoma).

We decided to perform a laparoscopic adenomyomectomy with temporally occlusion of uterine arteries (TOUA).

Methods

After the pneumoperitoneum is created and the trocars are placed, we identify the big focus of adenomyosis at the fundus of the uterus.

We proceed to the TOUA. The first step is to identify uterine arteries. We perform a posterior approach identifying the obliterated umbilical ligament and the ureter. We open the peritoneum lay and take advantage of the gas to perform the dissection till we identify the uterine artery. The isolated uterine artery is occluded with an endoscopic vascular clip. We perform the same procedure on the other side.

We design the adenomyomectomy making landmarks on the uterus surface.

The uterus is incised with a monopolar cutting electrode until the identification of the adenomyoma, which is difficult because there is no clear cleavage plane.

We proceed to the adenomyomectomy with scissors until we get to the normal myometrium. We use tactile and visual sensations for complete excision.

The defect area after excision is sutured in 2 layers, including a deep, continuous barbed suture and a single interrupted suture.

After hemostatic checking we removed the uterine arteries clips without complications.

Results

The follow up after the surgery was satisfactory.

Conclusions

After 9 month of the procedure the patient get pregnant spontaneously. The pregnancy is going fine and the deliver is arranged to be an elective caesarean section at 38 week.

<https://player.vimeo.com/video/826712283?autoplay=1>

Ureteral surgery in endometriosis: correlation between preoperative assessment and intraoperative decisions

Violeta Romero Camacho¹, Emanuela Spagnolo¹, Elena Rodriguez², Cristina Redondo¹, Ana Lopez¹, Alicia Hernandez¹

¹La Paz University Hospital, Gynaecology department. Endometriosis Unit, Madrid, Spain

²La Paz University Hospital, Gynaecology Department, Madrid, Spain

Background

Surgical approach in deep infiltrating endometriosis (DIE) involving ureters remains as a challenge. We aimed to analyze if preoperative assessment can be predictive of the intraoperative decision of ureteral repairing approach. We aimed to compare two case reports affected by deep endometriosis with high likelihood of ureteral involvement and the correlation in both cases of the preoperative assessment and surgical proposal and the intraoperative findings which led to the final surgical approach.

Methods

In the first case report, we present the excision of a ureteral nodule by ureterolysis, despite the preoperative consideration of probable ureteral reimplantation necessity. Meanwhile, in the second case report, a good correlation was found between the preoperative decision of ureteral resection and the surgical findings and decisions.

Results

In the first surgical video, we describe a case of a 37-year-old woman with severe pelvic pain associated with a silent IV grade hydronephrosis. In the preoperative ultrasound scan (US) bilateral endometriomas were described, as well as two DIE nodules: one of the infiltrating sigmoid colon-rectum of 31x16x15 mm and another one affecting right parametrium of 28x22x26mm. Due to the localization and size of the nodule, an ureteroneocystostomy was preoperatively proposed. Regarding the second case report, we present a 42 years-old woman with three previous surgeries due to endometriosis, two of them being laparoscopic cystectomy and, the last one, a bilateral adnexectomy and left ureterolysis performed by open surgery. Our patient presented repeated urinary infections and colic pelvic pain. In the preoperative assessment, left kidney obstruction secondary to the left ureter distal third affectionation was observed, in correlation with a 16 mm left parametrial nodule visualized by US. Left ureteral reimplantation was preoperatively proposed.

As we observed during the video, direct visualization of the lesions was essential to develop the final surgical decision. Nevertheless, individualized, and comprehensive preoperative study of each case allowed the surgeons to suspect the lesions and to provide the patients with important information about the level of radicality they could expect.

Conclusions

Adequately preoperative assessment helps surgeons to inform patients properly about the likelihood of ureteral involvement, as well as the different surgical options that might be necessary. However, intraoperative findings remain as the final evaluation that leads to a surgical approach over another.

<https://player.vimeo.com/video/831666742?autoplay=1>

ES32-0012 - VP001

Video in Poster

Resection of a retrocervicale endometriosis lesion

Françoise Fletcher¹, Mathilde Lapointe², Cherif Akladios², Emilie Faller²

¹CH Moulins-Yzeure, Allier, Moulins sur Allier, France

²CHRU Hautepierre, Bas Rhin, Strasbourg, France

Background

Objective: to show the case of a retrocervical endometriosis lesion in a 25-year-old patient. The surgery took place in CHRU Hautepierre, Strasbourg France.

Methods

The patient was 25-year-old women, she had a vaginal endometriosis nodule located in the posterior vaginal pouch. It was discovered after metrorrhagia requiring hospitalization. She had no dyspareunia no dysmenorrhea but intense bleeding.

The MRI showed a moderate posterior endometriosis lesion and a thickening of the posterior vaginal pouch.

During the exploration of the abdominal and pelvic cavity we found a vesico-uterin endometriosis lesion that was not seen on the MRI. We decided to do a resection.

We then began the dissection of the vaginal nodule. We started by the dissection of the ureters on both sides, then the dissection of the Okabayshi spaces and the recto-vaginal space.

Once the nodule was freed from the rectum, we took out the uterine manipulator and filled the vagina with a glove filled with compresses. The glove placed in the vagina had two functions: to avoid losing air when the vagina was open and unfold the vaginal to facilitate the resection. The nodules resection was done with a monopolar hook.

The vagina was sutured with 3 X points with a Vicryl 1 thread. The vaginal touch was found a correct closer of the vagina.

To avoid an internal hernia with closed the gap in the broad ligament with 1 stitch.

After correct coagulation, we ending the surgery by applying a not adhesion and hemostatic powder.

Results

The patient was not painful after surgery. She left the hospital the next day. The post operative exam found a correct healing.

Conclusions

The laparoscopic approach for a vaginal endometriosis is essential. As seen on this video, the adhesions and tissue retraction are major in endometriosis case.

<https://player.vimeo.com/video/807047005?autoplay=1>

ES32-0104 - VP007

Video in Poster

Laparoscopic management of an endometrioid cystadenoma originating from the uterus

Kalliopi Kordopati-Zilou¹, Nikoletta Mili¹, Theodoros Kalampokas¹, Olga Triantafyllidou¹, Nikolaos Vlahos¹, Emmanouil Kalampokas¹

¹2nd Department of Obstetrics and Gynecology- Aretaieio University Hospital, National and Kapodistrian University of Athens, Athens, Greece

Background

Endometrioid cystadenomas are rare benign tumors lined by benign endometrioid epithelium without endometrial stroma. These uncommon tumors are often seen in postmenopausal women and sometimes are associated with endometriosis. They mainly originate from the ovary but can arise from endometriosis lesions in other locations. Endometrioid cystadenomas may cause abnormal vaginal bleeding and abdominal pain.

Methods

Our case concerns a forty-year-old patient who presented with heavy menstrual bleeding for the last two years. Her past surgical history included two cesarean sections, one laparotomy-myomectomy, and one laparoscopic myomectomy. Pelvic MRI demonstrated a mass with smooth borders, arising from the anterior uterine wall and containing at least three areas with hemorrhagic elements. The pelvic mass measured 7.3 x 8.4 x 9.5 cm and had grown in size compared to two years ago. The mass dislocated the right ovary and could not be adequately visualized. No lymphadenopathy or ascites were present. Pipelle endometrial biopsy was negative for malignancy.

Results

Intraoperatively we identified a 12-centimeter mass arising from the anterior uterine wall and communicating with the uterine cavity. Both ovaries appeared normal. Solid adhesions between the uterus and bladder were observed. The patient underwent a laparoscopic total hysterectomy with bilateral salpingectomy. Uterine arteries were coagulated at their origin following retroperitoneal space development. Extended adhesiolysis of the vesicouterine pouch was performed. En-bloc tumor resection was achieved. Recovery was unremarkable, and the patient was discharged the day after. The pathology report revealed an endometrioid cystadenoma originating from an endometriosis lesion of the anterior uterine wall.

Conclusions

Endometrioid cystadenomas, especially those arising from locations other than the ovaries, are rare, and preoperative diagnosis is uncommon. In this video, we showcase a minimally invasive approach for a large pelvic mass with retroperitoneal space development and development of the vesicouterine pouch.

<https://player.vimeo.com/video/825986478?autoplay=1>

Endometriosis can still surprise us

Amr Gehad¹, Ayman AbdelKader¹, Nikola Sambandan²

¹Homerton University Hospital, Obstetrics and Gynaecology, London, United Kingdom

²Barnet Hospital, obstetrics and gynaecology, London, United Kingdom

Background

Endometriosis is a condition which we would frequently encounter in our daily practice. It is not uncommon to see patients with suspected endometriosis without a laparoscopic diagnosis which is the gold standard tool. Nonetheless, we often manage patients surgically with treatments ranging from mild endometriosis ablation to extensive resection. Unfortunately, despite the awareness of the problem, it can often get missed and may take years in some patients to be diagnosed and treated appropriately.

Methods

We hereby present a rare case of fimbrial cyst endometriosis which was delayed in diagnosis for more than a year. At the age of 30, the patient presented to the accident and emergency department for severe right side abdominal pain.

An US scan showed an right adnexal avascular simple cyst measuring 45 x 47 x 47 mm in diameter. Even though the white cell count was 18 and she had history of vomiting, appendicitis was not the primary diagnosis. A repeat ultrasound scan was performed under the care of the gynaecology team which showed a right adnexal cyst with septations with the same measurements however it appeared to be separate from both ovaries.

6 months later she had another appointment where she had a repeat scan as a follow-up for her cyst and an outpatient appointment which showed the cyst was in the right ovary with simple features. And agreed plan for this to be removed electively which was performed a few months later

On diagnostic laparoscopy, both ovaries had been seen with normal appearance however the left ovary had endometriotic spots whilst the right fallopian tube was torted more than 360 degrees and attached to a peritoneal structure along the right uterosacral ligament.

Results

Careful dissection of the structure showed an endometriotic fimbrial end cyst which had attached itself to the right uterosacral ligament as well as the posterior aspect of the cervix. There were also fluid-filled flimsy peritoneal adhesions typical of endometriosis picture.

Due to the torsion of the fallopian tube the blood supply of the endometriotic cyst has been impaired which caused this cyst to adhere to the surrounding peritoneal structure to maintain the blood supply as well as due to the endometriosis. The unfortunate event of late diagnosis had lead to damage of the right fallopian tube which had been removed.

Conclusions

High suspicion of endometriosis and low threshold to review patients and possibly perform a diagnostic laparoscopy to rule out ovarian/adnexal pathology is crucial. A culture of proactive treatments should be embedded in our junior doctors Training

<https://player.vimeo.com/video/826971827?autoplay=1>

ES32-0483 - VP041

Video in Poster

Laparoscopic management of vascular complication

Cristina Redondo¹, Ana Lopez², Emanuela Spagnolo², Violeta Romero², Alicia Hernández²

¹Hospital Universitario La Paz,

Department of Gynecology and Obstetrics- Hospital Universitario La Paz- Madrid, Madrid, Spain

²Hospital Universitario La Paz, Ginecología y Obstetricia, Madrid, Spain

Background

We present the laparoscopic management of a vascular complication, using the case of a vascular injury that took place during surgery for deep infiltrating endometriosis.

Methods

Surgical video presenting an accidental injury to one of the main pelvic vessels, during the surgical treatment of a deep endometriosis nodule affecting the posterior compartment.

Results

By presenting and reviewing this case, we aim to revise the optimal endoscopic management of vascular complications.

Conclusions

Vascular injuries are perhaps the most challenging complications that a pelvic surgeon will face. In order for said complications to be handled successfully, it is indispensable to have perfect knowledge of the anatomy and function, as well as to train in the adequate manouvers needed to solve these potentially severe situations.

By showing the case of an accidental injury to one of the main pelvic vessels, during the surgical treatment of a deep endometriosis nodule, and reviewing its correct management, we hope to bring light on the optimal way to react when confronted with these situations.

<https://player.vimeo.com/video/840108770?autoplay=1>

ES32-0018 - VP002

Video in Poster

A pelvic complex mass that turn to be a subserosal fibroid with myxoid degeneration

Bassem Skaff¹

¹New Mazloum Hospital - Tripoli- Lebanon, Obstetrics and Gynecology, Tri, Lebanon

Background

Typical appearances of uterine leiomyoma using different imaging studies are well established, and diagnosis is usually easy. However, cases that, are extremely difficult to differentiate from other conditions are occasionally faced.

Unusual appearances can be classified into 3 categories: degeneration and other histopathologic findings, specific types of unusual leiomyomas, and unusual growth patterns. The common types of degeneration are hyaline (>60% of cases), cystic (approximately 4%), myxoid, and red.

Specific types of unusual leiomyomas include lipoleiomyoma and myxoid leiomyoma, which may have MR imaging features characteristic enough to allow differentiation from other gynecologic and nongynecologic diseases. Intravenous leiomyomatosis, metastasizing leiomyoma, diffuse leiomyomatosis, and peritoneal disseminated leiomyomatosis represent unusual growth patterns; other unusual growth patterns are retroperitoneal growth, parasitic growth, and the pattern that may occur in cervical leiomyoma.

Methods

A 29-year-old single lady presented with chronic back pain and diffuse dull pelvic pain with difficulty in defecation.

She has a medical history of mild intermittent asthma and nasal turbinectomy

No previous abdominal surgeries

She had irregular menstrual cycles in the form of polymenorrhea, no dysmenorrhea

Ultrasound evaluation showed a right 10 cm adnexal homogenous cystic lesion suspicious of right ovarian cyst: endometrioma versus cystadenoma

CA125 was elevated reaching 87.8

Repeated ultrasound by another radiologist showed a giant 9 cm right ovarian cyst homogenous with a thick lining of 0.8 cm with mild fluid collection in the Douglas

A third radiology opinion revealed a chocolate cyst of regular contour and a thick wall, with no vascular activity on Doppler study

MRI with gadolinium injection showed a 10 cm cyst suspicious of right cystadenoma of the ovary with no lymphadenopathies or other notable pelvic lesions

Results

Laparoscopic exploration, showed a right huge mass of thick lining loosely adherent to the bowels, cul de sac, uterus as well as the right ovarian fossa with diffuse inflammatory process.

Dissection was done solely with suction tube and an atraumatic forceps till complete freeing of the mass from the underlying structures

The right ovary was masked underneath the mass which was completely normal looking, the mass had no vascular supply, and no energy source has been used during the surgery.

In sac morcelation was done and the lesion was removed through the left accessory laparoscopic port.

The final pathology revealed a leiomyoma with myxoid degeneration.

Fibroids that have undergone myxoid degeneration are filled with a gelatinous material and are hard to distinguish from uterine cystic degeneration; however, they typically appear as more complex cystic masses. They appear hypocellular with a myxoid matrix.

Conclusions

It is always of utmost importance to correlate imaging with laparoscopic findings and histopathologic studies to diagnose and manage such unusual presentations and to distinguish them from other significant gynecologic and non-gynecologic diseases.

<https://player.vimeo.com/video/813340665?autoplay=1>

ES32-0476 - VP040

Video in Poster

Title: a novel surgical technique in removal of multiple fibroids in laparoscopic myomectomy

Emily Fox¹, Lina Antoun¹, Yousri Afifi¹

¹Birmingham Women's Hospital, Obstetrics and Gynaecology, Birmingham, United Kingdom

Background

Background: Laparoscopic myomectomy is a minimally invasive, fertility sparing method in which to remove fibroids. The main steps in laparoscopic myomectomy involves injection of vasopressors, incision to the uterus and enucleation of the fibroids. In cases where the uterus is multi-fibroid, many incisions are made for the removal of the many fibroids. We propose a novel method in which multiple fibroids are removed through one uterine incision.

Objective: To describe a new surgical technique in laparoscopically removing multiple fibroids using one incision on the uterus, without breaching the endometrial cavity.

Methods

Case Description: This was a 30 year old patient, who underwent laparoscopic myomectomy of multiple type 2-5 fibroids for management of her subfertility. Argipressin 20IU in 100ml of 0.9% NaCl solution is injected in the subserosal area overlying the fibroids. A longitudinal incision was made using an advanced energy device on the uterus. Then, the fibroids were enucleated with careful attention to avoid breaching the endometrial cavity. The enucleated areas of the uterus was closed in 2 layers using a combination of intracorporeal and extracorporeal technique. Haemostasis was confirmed.

Results

Post operatively, the patient made good recovery and was discharged home the following day.

Conclusions

Conclusion: This novel technique effectively and successfully ensures removal of multiple fibroids using a single incision, which minimises trauma to the uterus.

<https://player.vimeo.com/video/831252647?autoplay=1>

ES32-0412 - VP037

Video in Poster

Hysteroscopic treatment of recidivant hematometra using a cervical stent

Marta TORTAJADA¹, Meritxell Munmany¹, Cristian de Guirior¹, Maria Angels Martinez-Zamora¹, Mariona Rius¹, Francisco Carmona¹

¹*Hospital Clinic Barcelona, Gynecology, Barcelona, Spain*

Background

To describe the treatment of recidivant hematometra in a young patient with hysteroscopic approach

Methods

A 40-year-old patient came to our centre with recidivant hematometra due to cervical stenosis after uterine surgery (laparoscopic myomectomy in another centre). She had already a previous hysteroscopic surgery due to cervical stenosis that caused hematometra and pelvic pain to the patient. Afterwards she was put under medical treatment (continous contraceptive pills). However, the hematometra relapsed and the patient persisted with pelvic pain and because of that, she was refered to our unit.

Results

A transvaginal ultrasound scan (TVUS) was performed showing an anterverse uterus with hematometra of 129x50x99mm. She also presented a left hematosalpinx of 122x64x58mm. As the patient was unresponsive to the medical treatment, a hysteroscopic surgery was planned and a cervical stent was placed after opening the stenosis in order to avoid restenosis of the cervical canal. The stent we used is a Wallflex fully covered system of 60x8mm. The procedure was assisted by ultrasound guidance.

Conclusions

Placing a cervical stent in cases of recidivant cervical stenosis after a conservative approach (medical treatment, adhesiolisis with resectoscop) can be considered in symptomatic patients (pelvic pain).

<https://player.vimeo.com/video/857828068?autoplay=1>

ES32-0574 - VP048

Video in Poster

Bladder injury during NOTES hysterectomy

Alice Moïse¹, Michèle Nisolle¹, Francois Closon¹

¹CHU liege, gynecocology obstetric, Liege, Belgium

Background

Dissection of utero vesical space is a primordial step at the beginning of vaginal hysterectomy, this step can be complicated by previous c section, obesity or non prolapse uterus. The per operative rate of complication for NOTES hysterectomy compare with classical hysterectomy is the same. Nevertheless, complication by cystotomy is known during NOTES (1,2%) but is rare during vaginal hysterectomy.

Bibliography

Baekelandt, J., & Kapurubandara, S. (2021). Benign Gynaecological procedures by vaginal Natural Orifice Transluminal Endoscopic Surgery (vNOTES): Complication data from a series of 1000 patients. *European journal of obstetrics & gynecology and reproductive biology*, 256, 221-224. <https://doi.org/10.1016/j.ejogrb.2020.10.059>

Methods

This video shows access to peritoneal cavity after a misdirection during dissection of the utero vesical plane. After suturing the vesical wound, we were able to continue the surgery.

After hysterectomy urologist performed a second suture and a cystoscopy.

Results

Despite a complication at the beginning of the surgery we were able to continue the surgical procedure with the same NOTES technique.

The patient has been discharged from the hospital at day one after surgery with a foley catheter for 10 days.

Unfortunately, the patient developed a urinary infection at day 4 which was treated by oral antibiotics for a week.

Ten days after surgery the urologist removed the foley catheter and get control cystoscopy and cystography.

No residual lesion had been notified.

Conclusions

Dissection of utero vesical plane is a tricky step during vaginal surgery, moreover with previous C section.

Despite this complication, NOTES offers a good access for dissection of this plane and allows a suture of the bladder.

Nevertheless, NOTES remains a relatively new approach in vaginal surgery and training is the key point to be able to manage complications.

<https://player.vimeo.com/video/831631293?autoplay=1>

ES32-0597 - VP050

Video in Poster

Isthmocele surgical repair - step-by-step laparoscopic approach

María Cuadra¹, John Peay¹, Alicia García¹, Marina Gallardo¹, Beatriz Bueno¹, Jose Rubio Valtueña¹
¹Hospital Universitario Infanta Sofía, Ginecología y Obstetricia, Madrid, Spain

Background

Uterine isthmocele is a dilatation of the uterine cesarean scar and functions as a reservoir collecting blood during menstruation. Sonographically is defined as an anechoic area in the myometrium of the lower uterine segment or as an indentation at the location of the cesarean section scar of at least 2 mm.

Isthmocele surgical repair. Step-by-step laparoscopic approach along with recommended tips and tricks accompanied by a narrated video. We propose a double laparoscopic-hysteroscopic approach in a patient with secondary infertility before embryo transfer.

Methods

Vaginal ultrasound is considered the gold standard for diagnosis. The measurement should be made in a sagittal plane that includes the niche length, depth, and residual myometrial distance (RMT). It is a standardized measure. 100% of the experts approve of this measure. Other ultrasound measurements that help us in surgical orientation are the adjacent myometrium thickness (AMT) and the distance from the niche to the OCI.

We propose a double laparoscopic-hysteroscopic approach in a patient with secondary infertility before embryo transfer.

We start with the laparoscopic approach with a 30° optics and uterine manipulator. The latter increases the tension and allows us to dissect the vesicouterine pouch from the medial to the lateral part with cold scissors. Simultaneous hysteroscopic transillumination helps us to locate the entire defect. It is important to perform the complete resection of the granulation tissue under hysteroscopic control.

We used a dissecting forceps, cold scissors and monopolar energy, so as not to damage the adjacent myometrium. After the resection of the granulation tissue is complete, it is recommended to withdraw the stem of the uterine manipulator (Rumi II) into the vagina to facilitate suturing of the defect. We use a double-layer barbed suture to guarantee correct closure, firstly a horizontal layer and then, ending with a second vertical suture. Peritonization is performed to conclude the surgery.

Results

Surgery was performed using a hysteroscopic-laparoscopic approach, allowing a safer dissection of the isthmocele. 3 weeks after surgery, complete dissolution of the isthmocele was observed on ultrasound.

Conclusions

We propose a double laparoscopic-hysteroscopic approach. Simultaneous hysteroscopic transillumination helps us to locate the entire defect. It is important to perform the complete resection of the granulation tissue under hysteroscopic control.

<https://player.vimeo.com/video/831652532?autoplay=1>

Laparoscopic uterosacral ligament fixation: can laparoscopic approach enhance safety?

Mihai Gherghe¹, Ajay Dhawle¹, Adam Burns¹, Mohammed Allam¹

¹University Hospital Wishaw, Gynaecology, Glasgow, United Kingdom

Background

Management of Apical vaginal prolapse remains a challenge. Sacrocolpopexy and sacrospinous ligament fixation (SSLF) are commonly performed procedures but carry inherent risks. Uterosacral ligaments (USL) provide a strong and anatomical site for suspension of the vaginal apex. The traditional vaginal approach for uterosacral ligament suspension (USLS) however, carries higher risk of complications. A retrospective analysis of 983 patients showed an adverse event rate of 31.2%, including urinary tract infection in 20.3%. There was no intraoperative ureteral injury, but 4.5% of patients required suture removal due to ureteral kinking¹. The aim of this video is to describe an alternative laparoscopic approach to reduce possible nerve injury and ureteral complications.

Methods

A 63 year old woman with grade 3 of uterocervical descent underwent a Total laparoscopic hysterectomy and bilateral salpingo-oophorectomy (TLH/BSO) for atypical endometrial hyperplasia. One stay suture was placed on the distal half of the mid part of the uterosacral ligament to demarcate them prior to hysterectomy. The needle tip is always directed medially to avoid ureteric injury. The vaginal vault was sutured using 2-0 PDS after routine TLH/BSO was performed. After vault closure, both the vaginal angles were suspended from their ipsilateral USL using 2-0 PDS using extracorporeal suturing technique. Both USL were placated and fixated to anterior wall of the vaginal vault using a purse string suture technique, starting and ending at the anterior wall of the vaginal vault.

Results

The lady underwent a successful laparoscopic USLS at her TLH/BSO without any complications. She remains asymptomatic at 6 months of follow up.

Conclusions

Laparoscopic USLS is a useful technique and can be used at TLHs for prevention as well as treatment of apical prolapse. The laparoscopic approach allows better visualisation of the ureteric course and provides an added layer of safety during the operation.

<https://player.vimeo.com/video/833405933?autoplay=1>

ES32-0158 - VP013

Video in Poster

Tight chest tight pelvis!

Mohamed Salama¹, Elakhras Sayed², Bassem Sobhy³

¹Ain Shams University, Obstetrics and Gynaecology, Cairo, Egypt

²Omam Hospital, O&G and Minimally-invasive Surgery, Cairo, Egypt

³Galaa Teaching Hospital, Obstetrics and Gynaecology, Cairo, Egypt

Background

Post-surgical adhesions are common in almost all surgical areas and are associated with significant rates of morbidity, mortality, and increased healthcare costs, especially when a patient requires repeat operative interventions.

Methods

We report a case of 29 years previous 1 caesarean with history of abdominal exploration with vertical incision for resection anastomoses who presented to our hospital with secondary infertility, chronic pelvic pain, chest tightness and easy fatigability

Transvaginal US showed adhesions between anterior surface of uterus and linea alba scar

Results

Video assisted operative laparoscopy was done. Entry through Palmer point revealed pelvic adhesions and colonic adhesions to anterior abdominal wall which were mirrored by extensive peri-hepatic adhesions

Secondary ports were inserted under vision, then careful adhesiolysis was done using both harmonic and sharp dissection until uterus, tubes and ovaries were cleared from the pelvic walls and both hepatic lobes cleared from the diaphragmatic copulae

Conclusions

We can therefore say that perihepatic adhesions are a mirror to pelvic adhesions.

Therefore gynecologist should explore abdominal cavity with 360 degree view and have the ability to do surgery in upper abdomen, releasing of perihepatic adhesions

<https://player.vimeo.com/video/826613946?autoplay=1>

ES32-0522 - VP044

Video in Poster

World standard of surgical management in endometriosis "frozen pelvic": a case report

Kati Quevedo¹, Jesus Castellano¹

¹Human Gynecology, Maracaibo, Zulia, Venezuela

Background

Frozen pelvic is a condition in which the pelvic organs are distorted and attached to each other as a result of adhesive processes. This can obscure normal anatomic landmarks and surgical planes, making dissection extremely difficult and increasing the risk of intraoperative and postoperative complications. Although it is an infrequent surgical condition, it is not uncommon to find it in clinical practice and even more so in patients with endometriosis, which is a challenge for surgeons, since infertility associated with endometriosis is frequent. It is important that surgeons are able to recognize the relevant anatomy and have the knowledge to open adequate pelvic avascular spaces in the pelvis to mitigate these risks. Follow-up step by step in this video you can see how it is possible to restore the pelvic anatomy for planned surgical interventions under the premises of globally accepted strategies led by Dr Wattiez

Methods

Laparoscopic Video

Results

Adherenciolysis of Frozen pelvic

Conclusions

Execution of a laparoscopic surgical technique carried out in Venezuela

<https://player.vimeo.com/video/831489536?autoplay=1>

ES32-0211 - VP020

Video in Poster

Single port laparoscopic hysterectomy with articulating laparoscopic instrument

Geunyoung Kim¹, Keun Ho Lee¹

¹Seoul St. Mary's hospital, OBGYn, Seoul, Korea- Republic Of

Background

Several articulating laparoscopic instrument is developed recently. But not so many video was reported. Here we present a case of single port hysterectomy with articulating laparoscopic instrument.

Methods

Single port surgery with articulating instrument is most difficult surgery because of narrow spaces. Artisential, double joint wrist laparoscopic instrument was used

Results

A 60-year-old woman came to our department for a hysterectomy. She had a history of CIN 3 and conization was performed 1 year earlier. A re-evaluation of the cervix revealed she had CIN 3 recurred. Single port hysterectomy with salpingo-oophorectomy was performed with conventional laparoscopic monopolar & bipolar as long with articulating laparoscopic instrument.

Conclusions

Single port laparoscopic hysterectomy was safely performed with articulating laparoscopic instrument without any event.

<https://player.vimeo.com/video/826808321?autoplay=1>

ES32-0660 - VP060

Video in Poster

Case of bladder endometriosis excision in combination with cesarean scar reparation

Islam Magalov¹, Emil Mukhtarov², Nergiz Naghiyeva³, Zulfiya Abbasova³, Aygul Mamedova³

¹Baku Branch of Sechenov Medical University, Obstetrics and gynecology, Baku, Azerbaijan

²Yeni Hospital/ Baku Health Center, Urology, Baku, Azerbaijan

³Baku Health Center, Obstetrics and Gynecology, Baku, Azerbaijan

Background

Bladder endometriosis is the most common site of urological endometriosis. The mechanisms of its development is not so clear and there is a question whether it is related to iatrogenic factor the same as abdominal wall endometriosis (Donnez, 2000; Lily, 2020), since the lesions are located close to the uterus and typically affect the detrusor in trigone area and bladder apex (Charatsi, 2018) .

Methods

The video demonstrates excision of bladder endometriosis in patients with history of two cesarean sections presented with periodic menouria and urinary incontinence in combination with severe dysmenorrhea and dyspareunia. Both ureters were catheterized before the start of laparoscopy. Approach to endometrial foci was achieved by modified transvesical technique that we use in our clinic for vesical fistulas.

Results

The duration of intervention was approximately 3 hours with blood loss less than 100 ml. The amount of time spent was explained by the advanced adhesiolysis, dissection, suturing of bladder and repair of uterine scar. The initial diagnosis of bladder endometriosis was proven by pathologic examination of the resected specimen.

Conclusions

Most likely, there is certain subtype of bladder endometriosis caused by improper healing of uterine scar or some technical mistakes made during cesarean section. This should be taken into consideration and included in the list of cesarean section complications.

<https://player.vimeo.com/video/835942990?autoplay=1>

ES32-0651 - VP059

Video in Poster

Demonstration on performing a perfect diagnostic laparoscopy

Kunal Rathod¹, Prashanti Swamiselvaraj¹, Yatin Thakur², Premilla Kollipara¹

¹Queens Hospital Romford, Gynaecology, London, United Kingdom

²Basildon and Thurrock university Hospital, Gynaecology, Essex, United Kingdom

Background

Laparoscopy is a very important auxiliary diagnostic method in the study of many gynaecological pathologies. Diagnostic laparoscopy is a common diagnostic procedure in the workup of patients with pelvic pain, generally attempting to identify endometriosis. A junior trainee is the one who will start the learning process by performing simple uncomplicated diagnostic laparoscopies. A thorough theoretical knowledge supplemented with practical demonstration increases confidence in performing procedures.

Methods

An in and out catheter was inserted into the urinary bladder, CO₂ insufflation was created with the verrees needle insertion through umbilicus, a 5-mm trocar was introduced via the umbilicus. The abdomen was inflated with CO₂, and a zero degree laparoscope was utilised to inspect the abdominal cavity and pelvis. Thorough systematic inspection of the pelvis and abdomen was performed and this video demonstrates important landmarks that should be visualised.

Results

Diagnostic laparoscopy was performed uncomplicated. Pelvic and abdominal findings were documented in clinical notes

Conclusions

Laparoscopy is able to achieve the final diagnosis and provide tissue diagnosis without any significant complication and less operative time. It can be safely concluded that diagnostic laparoscopy is a safe, quick, and effective adjunct to diagnostic modalities, for establishing a conclusive diagnosis

<https://player.vimeo.com/video/832047337?autoplay=1>

ePOSTERS

ES32-0014 - P042 ePoster Presentations

Latrogenic uterine perforation at 23 weeks of gestation by direct trocar entry managed to deliver at 28 weeks

Bassem Skaff¹, Rawane El Assad²

¹New Mazloum Hospital - Tripoli- Lebanon, Obstetrics and Gynecology, Tri, Lebanon

²New Mazloum Hospital, Obstetrics and Gynecology, Tripoli, Lebanon

Background

A ratio of 1 in 500 to 1 in 635 pregnant women presenting with acute abdomen is attributed to non-obstetrical abdominal surgeries (1). Overall, 1%- 2% of pregnancies undergo non-obstetric related surgeries (2;3). Acute cholecystitis is one of the most common causes (1;2;3;4). Laparoscopic cholecystectomy can be done safely with appropriate attention to the altered anatomy and physiology of pregnancy (1;2). Possible risks of laparoscopy performed in pregnant patients include miscarriage, preterm labour (1;3;4). Inadvertent uterine perforation of gravid uterus is a rare complication as cited in the literature (3).

We discuss a case of incidental iatrogenic second trimester uterine perforation by a trocar during laparoscopic cholecystectomy ending in a smooth pregnancy course.

Methods

32-year-old lady, G4P3 presented to the Emergency Department at 22+6/7 weeks of gestation with epigastric pain, radiating to the Right upper quadrant. Upon presentation, vital signs were normal.

Laboratory test results were significant for Hyperglycaemia: 207 (74-106mg/dl), SGOT: 78.2 (<31 UI/L), phosphatase alkaline: 235.4 (35-104 UI/L), lipase: 1524 (13-60 UI/L), and amylase: 781 (20-100 UI/L).

Abdominal ultrasound showed a distended thin wall gallbladder, with several biliary stones of different size. The CBD diameter was found to be of 0.4 cm.

normal AFI, baby with positive foetal heart beats, EFW: 680 grams. A decision for laparoscopic cholecystectomy was taken when the patient was at 23 weeks of gestation.

Intra-operative iatrogenic laceration of 1 cm in diameter in the uterine fundus induced by the umbilical trocar, cholecystectomy done, amniotic fluid leak noted, repair of the uterine laceration by "polyglactin figure of 8" sutures.

Post op obstetrical ultrasound done showing: EFW 1000 g, placenta fundal, anterior (no signs of retroperitoneal hematoma or abruption), cephalic presentation, amniotic fluid increased in volume with cloudy appearance.

Patient received steroids and antibiotics (cephalosporin 300 mg bid for 14 days) and was started on progesterone (Autogestion T1D), Biogest 100 mg q 3 days. Then the patient was closely monitored with serial ultrasounds, and foetal heart monitoring.

Results

At 28 weeks of gestation, she presented with mild preterm contractions and received a second course of steroids, then discharged after complete resolution of uterine contractions. One week later, she developed labour, she was transferred to the operating room for urgent caesarean section.

Healing of the site of perforation was noticed, and lower transverse uterine segment showed near-dehiscence. Baby's APGAR was 7-8 at 1 and 5 minutes transferred to neonatal intensive care unit.

Conclusions

Iatrogenic trocar injury in pregnancy is a rare situation, the surgeon should be aware of possible complications especially during late trimesters of pregnancy. Though many patients can benefit from conservative management taking into consideration possible complications that might occur during laparoscopic surgery in pregnancy. Indications for surgery during pregnancy should be considered carefully.

A rare case of atraumatic chylous ascites in a patient misdiagnosed with rupture of corpus luteum

Eleni Karatrasoglou¹, Anastasios Tsechpenakis², Aristeidis Mpakas³, Ioannis Rigos¹

¹Euroclinic Hospital, Department of Gynecologic Surgery, Athens, Greece

²Euroclinic Hospital, Department of General Surgery, Athens, Greece

³Euroclinic Hospital, Department of Anaesthesiology, Athens, Greece

Background

a 27-year-old female patient was admitted to the emergency department (ed) with intense lower abdominal pain during the last 8 hours. during surveillance the patient presented a progressive decrease in haemoglobin levels and an increase in free intra-abdominal fluid, detected by the computed tomography scan. the patient underwent an exploratory laparoscopy resulting to an identification of a milky-looking peritoneal fluid. the diagnosis of hylous ascites was confirmed by the determination of increased triglyceride levels in the peritoneal fluid.

Methods

case report

Results

Chylous ascites refers to the accumulation of lipid-rich lymph in the peritoneal cavity due to disruption of the lymphatic system secondary to traumatic injury or obstruction. the reported incidence of ca is approximately 1 in 20,000 admissions at a large university-based hospital over a 20-year period. as per a recent systematic review including 131 studies from developing and developed countries (with a total of 190 patients) who had atraumatic chylous ascites, the most common causes in adults were malignancy (25%), cirrhosis (16%), mycobacterium infection (15%), and a variety of uncommon causes (23%), including surgical trauma, radiotherapy, and other atraumatic, including congenital, inflammatory, and systemic disorders.

our patient underwent diagnostic laparoscopy as rupture of corpus luteum was suspected as possible aitiology. perioperatively, the uterus and ovaries were intact, and a presence of a milky, creamy appearing ascitic fluid was observed. chylous ascites was suspected so cytology samples were sent to clinical lab. the diagnosis of chylous ascites was confirmed by the determination of increased triglyceride levels in the peritoneal fluid.

the responsible lesion of the chylous ascites was detected by tracking the stream. the lesion was ligated twice with clips. a low-fat diet, with a restriction of long-chain triglycerides, was started in the post-operative period and the patient presented a progressive decrease in abdominal drainage. no congenital, inflammatory, and systemic disorders were detected post-operatively. the patient had a favourable clinical and analytical evolution and was discharged on the fifth post-operative day. the patient is completely free of symptoms for 6 months.

Conclusions

this experience indicates the usefulness of laparoscopic surgery in investigating the aetiology of unknown chylous ascites and treating it.

ES32-0034 - P045
ePoster Presentations

Defining a uterine extraction score based on a volume/access ratio in total hysterectomy: a retrospective cohort study

Sophie Schoenen¹, Laurent de Landsheere²

¹*Université de Liège, Gynécologie - Obstétrique, Liège, Belgium*

²*Université de Liège, Gynécologie - Obstétrique, Liège, Belgium*

Background

We aim to determine a predictive score of uterine extraction feasibility in total hysterectomy to optimise surgical planning. Secondary objectives were to find a correlation between the uterine volume that can be predicted by preoperative ultrasound and the final weight of the hysterectomy specimen, and to analyse uterine extraction modalities impact on operative and hospitalisation times.

Methods

We defined a Uterine Extraction Score (UES) based on the ratio between uterine size and vaginal access. This score aims to predict the feasibility and to guide the strategy of uterine extraction, i.e., the route of extraction and the need for tissue morcellation. We applied the UES to 178 consecutive patients who were hysterectomized for benign conditions between January 2019 and December 2022 in a retrospective cohort study. The UES defines three groups of decreasing feasibility of vaginal extraction, identified by traffic light colours: green - vaginal extraction without morcellation, orange - vaginal extraction but morcellation needed, red - abdominal morcellation by mini-laparotomy or primary laparotomy.

Results

The results show agreement between the predicted and the observed routes in 92% of cases (κ concordance coefficient 0,73). The correlation between estimated volume and final weight is strong ($r = 0,9 - P < .0001$). This study shows that uterine morcellation lengthens the operative time and the hospital stay ($P < .0001$), independently of the morcellation route.

Conclusions

Based on a retrospective chart review, the Uterine Extraction Score seems to be a reliable tool to predict the feasibility, ease and route of uterine extraction during total hysterectomy for benign conditions and therefore help the surgeon to anticipate the difficulty of the procedure and its impact on operative time and hospital stay. These results are worth to be confirmed in a larger prospective study.

Cutaneous endometriosis: a large cohort study

Aya Mohr-Sasson¹, Amber Gadson¹, Randa Jalloul¹

*¹McGovern Medical School at The University of Texas Health Science Center,
Advanced Minimally Invasive Gynecologic Surgery, Houston, USA*

Background

Cutaneous endometriosis is a rare disease with a limited number of cases reported in the literature. The aim of this study is to report the presentation, diagnosis, and management of large cohort of women with scar endometriosis.

Methods

This is a retrospective study including all women operated due to suspected cutaneous endometriosis that was confirmed on histopathology, between February 2008 to July 2022. Women's demographics, medical history, obstetrical and gynaecological characteristics were collected from the women's electronic medical files. Data regarding presenting symptoms and duration, associated symptoms, imaging findings, size of the lesion, associated pelvic endometriosis or additional pelvic pathology were collected from the pre-surgical clinical evaluation. Management, operation characteristics and histopathological diagnosis for confirmation were collected from the operative and the pathological reports.

Results

A total of 69 women met inclusion criteria. Median age was 36(IQR30-40) years with median BMI of 29(IQR26-33) kg/m². 62 (90%) of the women did not have previous diagnosis of endometriosis. Most of the women sought intervention due to cyclic pain (n=63,91%). All patients except two presented with lesion suspected at the caesarean scar, among them 38%(n=26) were status post one surgery. The median time from last Caesarean delivery was 72(IQR43-96) months. The median estimation of the lesion maximal diameter was comparable between ultrasound, CT and MRI examinations. Sub-analysis by the number of previous caesarean deliveries revealed similar patient's and lesion's characteristics. Median follow up was 18(12-25) days post-surgery. Complete resolution of symptoms was reported in 50% of the women.

Conclusions

Cutaneous endometriosis should be suspected when characteristics symptoms are present even in the absence of previous diagnosis of endometriosis. Caesarean delivery is a known risk factor, and the number of previous surgeries was not found to be associated with difference in the lesion characteristics.

Pain following vaginal natural orifice transluminal endoscopic surgery (vNOTES) in obese compared to non-obese women

Aya Mohr-Sasson¹, Mason Hui¹, Miguel Bonilla Moreno¹, Asha Bhalwal¹, Alvaro Montealegre¹

¹McGovern Medical School at The University of Texas Health Science Center, Advanced Minimally Invasive Gynecologic Surgery, Houston, USA

Background

vNOTES seems as the favourable approach for obese women undergoing gynaecological benign surgeries, as it avoids the major challenges of abdominal entry of conventional laparoscopy. Due to higher burden of omental fat in obese women, sub-diaphragmatic entrapment of air could potentially lead to higher frequency of post operative pain. Therefore, the aim of this study was to learn whether BMI influences pain perception following vNOTES surgeries.

Methods

This is a prospective observational study including all women following hysterectomy and adnexal surgery using the vNOTES approach between July 2021 to July 2022. Study group included obese women (BMI ≥ 30 kg/m²) that were compared to controls (BMI < 30). An internet questionnaire was sent to all women meeting inclusion criteria 24 hours after operation. Questions assessed pain using the visual analogue scale (VAS) at discharge and 24 hours post-surgery, and the use of medication for pain control. Demographics, clinical characteristics, and operative and post-operative data were collected from women's medical files.

Results

Study population included 59 women of them 41(69%) were obese and 18(31%) controls. Median operation time was significantly longer in the control group [116(89-162) vs. 78(53-127) minutes; $p=0.03$]. Only one case was converted to laparoscopy from the obese group. Pain scores on discharge and at 24 hours following discharge were comparable between the groups [3(2-6) vs. 5(3-7); $p=0.33$, 4(2-6) vs. 5(2-8); $p=0.31$, for the controls and obese group, respectively]. In both groups the most common medication used to control pain was NSAID, with no significant difference in the consumption rate of pain medication 24 hours following surgery ($p=0.95$). Post-operative complication was low and included one woman with urinary retention in the controls and one woman with urinary tract infection in the obese group.

Conclusions

BMI is not associated to post- operative pain nor complication rate following benign gynaecological surgeries in vNOTES approach.

Vaginal natural orifice transluminal endoscopic surgery (vNOTES) for gender affirmation

Aya Mohr-Sasson¹, Mason Hui¹, Miguel Bonilla Moreno¹, Alvaro Montealegre¹
*¹McGovern Medical School at The University of Texas Health Science Center,
Advanced Minimally Invasive Gynecologic Surgery, Houston, USA*

Background

The process of transitioning from female to male in transgender persons usually includes medical treatment as well as surgical interventions, including removal of the uterus and ovaries. Nulliparity and prolonged exposure of the vaginal mucosa to testosterone, which are common among transgender men, may present challenges to performing a vaginal hysterectomy with salpingo-oophorectomy, which is commonly performed only for multiparous individuals. Here we describe outcomes of using a vaginal assisted natural orifice transluminal endoscopic surgery (vNOTES) approach to perform hysterectomy among transgender men as part of their gender-affirming care.

Methods

This is a case series observational study including all patients undergoing hysterectomy with bilateral salpingo-oophorectomy by vNOTES for gender affirming care between February 2022 to April 2023 in a single tertiary medical centre. Primary outcome was defined as compound complication rate including intraoperative (organ damage, bleeding, conversion to alternative approach) and post-operative (urinary tract infections, surgical site infection and vascular complications).

Results

Patients' demographic, medical history, obstetrical and gynaecological history, operative and post-operative follow up (24 hours post-surgery) were collected from the electronic medical files. Pain at post-operative follow up was evaluated using visual analogue scores, which ranges from 0 (no pain) to 10 (worst pain possible). The study population included 8 transgender men, all of whom were nulliparous and had undergone testosterone treatment for more than a year. Median age at surgery was 24 years and median BMI was 30 kg/m². Mean operative time of the surgery was 111 min (range: 91-143 min) and none required converting from vNOTES to an alternative approach. No extensive bleeding or organ damage was reported. For one patient, there was one small vaginal laceration requiring suture. All but one patient was discharged the same day. The patient requiring next-day discharge was complicated by post-operative urinary retention. On post-operative follow up, median pain score was 3 (range 1-5).

Conclusions

Outcomes from this case series suggest that a vNOTES approach to hysterectomy among transgender men can be performed without surgical complications and with low self-reported pain.

Overly aggressive surgical strategies during hysterectomy for endometriosis

Hiroyuki Kobori¹, Tomoko Hagiwara¹, Yuko Kumakiri¹, Noriko Yamamoto¹, Chihiro Noji¹, Noriko Kato¹
¹Medical Topia Soka Hospital, Gynecology, Tokyo, Japan

Background

The treatment of endometriosis has undergone a major transition over the past decade or so with the development of drugs that can be used long-term. It has evolved from a surgery-centred approach to a combined approach that incorporates both surgery and drug therapy. On the other hand, extensive resection surgery, including deep lesions, is still widely discussed in endometriosis surgery. While such surgeries offer promise in terms of a cure, there are concerns about complications such as nerve damage and intestinal injury. In this study, we report on the surgical techniques and outcomes of a less aggressive surgical strategy that we use in endometriosis surgery involving hysterectomy in the present era when medical treatment options have expanded.

Methods

We included 339 patients who underwent laparoscopic hysterectomy and adnexectomy for endometriosis between October 2012 and June 2021. The patients' age was 45.2 ± 3.8 years. As a rule, all patients underwent preoperative false menopause therapy. At the time of surgery, a colpotomy cup was used in addition to the usual uterine manipulator, and the dissection of adhesions was limited to the level at which the posterior vaginal canal could be deployed. Except for two cases in which large nodules were observed, no deep lesion resection was performed.

Results

Total hysterectomy and bilateral adnexectomy were performed in 113 cases, and total hysterectomy and unilateral adnexectomy were performed in 226 cases. The operating time was 108.0 ± 26.8 minutes, and intraoperative blood loss was 110.8 ± 126.0 g. There were no postoperative complications such as intestinal injury or nerve damage. Postoperative ERT was performed in 53 of the bilateral adnexectomies. Four of the unilateral adnexectomies had contralateral adnexal enlargement and were treated with dienogest. Two patients had postoperative abdominal pain, but they declined drug therapy and were followed up.

Conclusions

In Japan, cases of deep lesions with large nodules are rare. Considering the characteristics of these cases, it is suggested that appropriate resection of the uterus and adnexa may be sufficient to ensure patient quality of life without taking the risk of deep lesion resection at the time of radical surgery.

Hemoperitoneum due to arteriovenous malformation of the right infundibulopelvic ligament contextual to ipsilateral tubal ectopic pregnancy: is there a correlation?

Alessandro Zecchin¹, Michela Zorzi², India Turcatel³, Martin Steinkasserer¹, Giovanni Negri⁴, Matteo Bonatti⁵

¹*Azienda Sanitaria dell'Alto Adige - Bolzano Hospital, Gynecology and Obstetrics, Bolzano, Italy*

²*University of Padua - Padua University Hospital,*

Department of Women and Children's Health - Clinic of Gynecology and Obstetrics, Padua, Italy

³*University of Bologna - Sant'Orsola Hospital, Gynecology and Human Reproduction Physiopathology, Bologna, Italy*

⁴*Azienda Sanitaria dell'Alto Adige - Bolzano Hospital, Pathological Anatomy, Bolzano, Italy*

⁵*Azienda Sanitaria dell'Alto Adige - Bolzano Hospital, Radiology, Bolzano, Italy*

Background

To demonstrate the possible correlation between an infundibulopelvic ligament's arteriovenous malformation (AVM) and a tubal ectopic pregnancy (EP) considering the known correlation between a pregnancy event and the possible onset of acquired uterine AVMs.

Methods

05/01/23: 32-year-old woman, negative anamnesis for pathologies and previous surgery, G1P1, accesses the emergency room of Bolzano Hospital for abdominal pain and hypovolemic shock.

Transabdominal ultrasound and abdomen computed tomography (CT) scan: hemoperitoneum ascribable to the right ovary. Presence of conglomerate of irregular vessels affecting the right ovarian plexus.

Blood tests: Haemoglobin 6.1 g/dl, Serum beta-human chorionic gonadotropin (beta-HCG) negative.

06/01/23 emergency laparoscopic surgery: hemoperitoneum (3500 cc), active bleeding from the right salpinx, intact but dilated and congested in its intermediate section and in apparent communication with a vascular malformation in the right infundibulopelvic ligament's site. Aspiration of the hemoperitoneum is performed. Subsequent opening of the right parietocolic peritoneum with exposure of the vascular malformation extending from the right ovary approximately 5 cm from its insertion into the inferior vena cava. Considering the poor haemostasis due to the fragility of the vascular anomaly, right salpingo-oophorectomy and the removal of the ipsilateral ovarian vascular pedicle is performed. Three clips (Grena Model) are applied to the proximal section of the infundibulopelvic ligament to ensure safe haemostasis. The operative sample is sent for definitive histological examination.

09/01/23 patient discharge: Haemoglobin 8.8 g/dl after the transfusion of three units of red blood cells (RBC) and intravenous administration of ferric carboxymaltose 1 g, post operative gynaecological examination programmed ten days after and subsequently six weeks after.

Results

Histological examination: AVM of the right infundibulopelvic ligament. Right Fallopian tube sites of chorionic villi compatible with unknown previous tubal pregnancy/tubal abortion. Optimal postoperative recovery. Spontaneous intrauterine pregnancy arising two months after surgery.

Conclusions

Considering the presented case report and the literature about the cause-effect relationship between pregnancy and the possible onset of acquired uterine AVMs, it is plausible to hypothesize a causal relationship between tubal ectopic pregnancy and an infundibulopelvic ligament's AVM, however it has never been described before.

In our case, since there were no previous CT images preceding the acute event, it was not possible to exclude a congenital vascular malformation.

Due to the lack of anamnestic information about a previous ectopic pregnancy, the negative beta-HCG and the acute clinical situation, it was not possible for us to suspect an AVM before surgery.

In conclusion, in case of the presence of conglomerate of irregular pelvic vessels on CT scan, it is reasonable to investigate the possibility of an ongoing or previous ectopic pregnancy and to take into consideration the coexistence of an acquired AVM.

Fallopian tube prolapse through the vaginal vault after total abdominal hysterectomy

Hema Nosib¹, Erika Manzo¹, Tarang Majmudar¹, Ciara Mackenzie¹

¹Hinchingbrooke Hospital- Northwest Anglia Foundation Trust, Gynaecology, Huntingdon, United Kingdom

Background

Fallopian tube prolapse is a rare complication following hysterectomy with adnexal preservation. The diagnosis can be challenging and can only be confirmed definitively by histopathology. We describe the presentation, investigation and surgical management of this condition.

Methods

A 48-year-old asymptomatic patient presented nine years after Total Abdominal Hysterectomy with adnexal preservation for benign disease with an incidental finding of a 'vaginal polyp' at speculum examination. On assessment there was a 2x2cm polypoidal lesion which appeared to be protruding through the vault and macroscopically appeared to be the fimbrial end of a fallopian tube. On traction patient reported pain in the left iliac fossa. Biopsy obtained in clinic, Magnetic Resonance Imaging (MRI) and previous operation notes requested. Findings discussed at Multi-Disciplinary Team (MDT) meeting. Alongside prolapsed pelvic viscera the differential diagnosis included malignancy, endometriosis, granulomas and mesonephric cysts. Biopsy confirmed fimbrial end of the fallopian tube with focal reactive atypia on the surface but no dysplasia or malignancy. MRI showed normal vaginal vault with some postoperative scarring and tethering. No features of malignancy. Colon diverticulosis was noted with thickening of the peritoneal reflections and adhesions around the left ovary. The MDT recommendation was for a joint laparoscopic and vaginal procedure to perform bilateral salpingectomy if possible. In view of the potential bowel involvement this required general surgeons on standby.

Results

We present the intra-operative findings and post-operative histology following a joint vaginal and laparoscopic procedure.

Conclusions

A high index of suspicion is essential when investigating patients with vaginal vault lesions post-hysterectomy. Although modern practice is increasingly to offer bilateral salpingectomy for the prevention of fallopian tube malignancy at the time of hysterectomy for benign disease, this was not the case in the past. Elderly patients may be unclear exactly what surgery they had and operation notes from decades earlier are often not readily available. There is a wide differential diagnosis for vaginal vault lesions for which the management varies according to the suspected/confirmed pathology. All lesions should be biopsied and discussed in an MDT meeting. If surgical management is considered a joint laparoscopic and vaginal approach is strongly recommended due to the risk of bladder or bowel involvement.

Urinary bladder dissection using tunnelling approach in cases of previous caesarean sections undergoing total laparoscopic hysterectomy

Vivek Marwah¹, Surabhi Kedia¹, Kanika Gupta¹, Khushboo Tongaria¹, Rony Chakravarty²

¹*Max Superspeciality Hospital, Division of Minimally Invasive Gynecology, New Delhi, India*

²*Command Hospital, Obstetrics & Gynecology, Kolkata, India*

Background

Patients with past caesarean section have vesico-uterine adhesions which puts them at risk of bladder injury during conventional total laparoscopic hysterectomy (TLH). The present study aimed to devise a technique which is less traumatic, without use of energy devices and safer for urinary bladder dissection in patients undergoing TLH who have history of previous Caesarean sections.

Methods

This retrospective cohort study included 342 patients with previous caesarean section who underwent TLH without use of energy devices for urinary bladder dissection at a tertiary care centre (Max Super Specialty Hospital, Saket) from July 2017 to March 2023.

This technique demonstrates the dissection of urinary bladder using the tunnelling approach without the use of energy devices during total laparoscopic hysterectomy especially for patients with previous caesarean sections.

The dissection starts with a nick in the anterior leaf of broad ligament just anterior to the left round ligament which is then extended towards the uterovesical fold stretched over the cervical cup of the Marwah's uterine manipulator. Bladder is usually adherent to the anterior uterine wall at the level of isthmus with the avascular dissectable plane below the level of internal os. The irrigation suction canula is slid over the cervical cup in this plane creating a tunnel to facilitate the separation of uterovesical fold and bladder from the anterior uterine wall with minimal blood loss. No energy devices are used during the bladder dissection and uterine vessels are skeletonised for intracorporeal ligation thus proceeding for TLH.

Results

Total of 342 patients underwent TLH using this technique. One case of bladder injury was reported.

Conclusions

The tunnelling approach of urinary bladder dissection without use of energy sources is a viable option being safer, less traumatic for adherent urinary bladder dissection during total laparoscopic hysterectomy.

Uterine artery sparing laparoscopic partial hysterectomy: a novel technique which retains the ovarian function post-surgery

Vivek Marwah¹, Surabhi Kedia¹, Kanika Gupta¹, Khushboo Tongaria¹, Rony Chakravarty²

¹Max Superspeciality Hospital, Division of Minimally Invasive Gynecology, New Delhi, India

²Command Hospital, Obstetrics & Gynecology, Kolkata, India

Background

Conventional total laparoscopic hysterectomy (TLH) leads to a decline in ovarian function as the uterine artery, which provides a partial supply to ovary, is ligated. The present study aimed to devise an ovarian sparing method for patients requiring hysterectomy (for benign indications) who are unresponsive to medical management and levonorgestrel implant.

Methods

This retrospective cohort study included 69 patients who underwent uterine artery sparing laparoscopic partial hysterectomy at a tertiary care centre (Max Super Specialty Hospital, Saket) from July 2018 to March 2023.

The procedure involved sparing half to one cm of margins of the myometrium from the level of internal os up to the ovarian pedicles keeping lateral and parallel to the ascending branch of uterine artery.

Procedure started with identifying the ascending branch of uterine artery on both sides along with the demarcation of level of internal Os with aid of cervical cup of Marwah's uterine manipulator.

Ultracision was used to create a line of margin of half to one cm of blanched myometrium from ascending branch of uterine artery, bilateral cornual ends and the isthmus going to the level of internal os both anteriorly and posteriorly. Using the ultracision blade the margins were deepened anteriorly and posteriorly with traction and counter traction from uterine manipulator, tooth grasper and 10mm tenaculum till the internal Os was visualized. The vertical limb of uterine manipulator was withdrawn after detaching the major portion of uterus including the entire uterine cavity.

The endocervical lining was then cauterized with bipolar forceps. The endocervical canal was closed with the barb suture followed by base ball suturing for haemostatic approximation of the remnant flaps.

The patients were followed up for 6 weeks after surgery, and their follicle stimulating hormone (FSH) was assessed at 6 weeks post-surgery.

Results

Total of 69 patients underwent this surgery (age range 35 to 42 years). The most common indication for surgery was adenomyosis, followed by myoma uterus and endometriosis. The mean FSH levels were similar pre- and post-surgery indicating preserved ovarian function.

Conclusions

Uterine artery sparing laparoscopic partial hysterectomy does not cause a decline in ovarian function, and can be an alternative option in young patients requiring hysterectomy.

The impact of postoperative gum chewing on bowel motility following laparoscopic gynaecological surgery - a systematic review and meta-analysis of randomized controlled trials

Athanasios Douligieris¹, Michail Diakosavvas¹, Nikolaos Kathopoulos¹, Konstantinos Kypriotis¹, Ioannis Chatzipapas¹, Athanasios Protopapas¹

¹1st Department of Obstetrics & Gynecology- "Alexandra" General Hospital- National and Kapodistrian University of Athens, Endoscopic Surgery Unit, Athens, Greece

Background

The efficacy of postoperative gum chewing has been widely established in stimulating bowel mobility and decreasing time to bowel function return in abdominal surgery, caesarean sections and colorectal surgery. However, studies investigating the impact of postoperative gum chewing in gynaecologic laparoscopic surgery are scarce. The present meta-analysis investigates the impact of postoperative gum chewing on bowel function in women following laparoscopic gynaecological surgery for benign indications.

Methods

We screened 5 major databases (Medline, Scopus, Google Scholar, Cochrane Central Register of Controlled Trials and Clinicaltrials.gov) from inception till February 2023. No language restrictions were applied. We included randomized controlled trials comparing the postoperative bowel function between patients who chewed and patients who did not chew gum postoperatively after laparoscopic gynaecological procedures for benign indications. Meta-analysis was performed with RevMan 5.4 software (Copenhagen: The Nordic Cochrane Centre, The Cochrane Collaboration, 2020), with mean differences (MDs), pooled risk ratios (RR) and random-effects model. Subgroup analysis according to the type of laparoscopic surgery was also investigated. The methodological quality of the included studies was assessed by two independent reviewers using the risk of bias 2 tool.

Results

Data from 5 studies on 670 patients were extracted and analysed by 3 independent reviewers. Postoperative gum chewing significantly reduced the time to first bowel sounds and the time to first passage of flatus (MD -2.58 hours 95% CI -4.12 to -1.04 p = .001 and MD -3.97 hours 95% CI -6.26 to -1.68 p < .001, respectively). The time to first defecation, the time to first postoperative patients' mobilization, the length of hospital stays and the risk of postoperative bowel obstruction showed no statistically significant difference between the two groups. When subgroup analysis was performed according to the type of the laparoscopic procedure, it failed to reveal a positive impact of postoperative gum chewing in both the times to first passage of flatus and first defecation following laparoscopic hysterectomies (MD -5.35 hours 95% CI -10.93 to 0.23 p = .06 and MD -15.93 hours 95% CI -40.13 to 8.28 p = .20, respectively).

Conclusions

The outcomes of the present meta-analysis support that postoperative gum chewing following laparoscopic gynaecological procedures seems to have a positive effect on the early mobilization of the gastrointestinal tract. However, these results should be interpreted with caution due to the small number of the included RCTs.

Case report: ovarian torsion in second trimester pregnancy - diagnosis and management

Nazeera Alghuzi¹, Reem Alawadi¹, Ebetehal Eramsi¹, Fatema Alharmi¹, Sara Alkaabi¹, Hanan Alyammahi¹
¹SEHA, resident OBGYN, Abu Dhabi, United Arab Emirates

Background

Objective: The objective of this article is to present a case of OT in second trimester pregnancy and to review diagnosis, and treatment.

Case report:

A 21 -year-old woman primigravida at 20 weeks gestational age presented to the Emergency Department (ED) with 2 h duration of abdominal pain, nausea, and multiple episodes of vomiting. The patient was not on ovarian stimulation treatments. on ED ultrasound showed pregnant (**20 weeks 6 days**). **The right ovary was normal. The left ovary contained a simple cyst anechoic; Size 15.6 x 11.6 x 17.48 cm.** Immediate obstetric consultation was initiated. Eventual radiology ultrasound showed **A live 20 weeks intrauterine pregnancy was seen. The left ovary was enlarged with a large simple cyst. with no suspicious features. above the uterus and occupying the right upper abdomen reaching xiphisternum.**

Methods

The patient underwent emergent laparoscopic surgery, Laparoscopy +Left ovarian cystectomy & correction of ovarian torsion.

Intraoperative surgery per palmer point incision and visual entry technique was undertaken using 5 mm port and scope visual entry gasless (cyst reaching xiphisternum). - entry into the cyst cavity by the trocar visually, scope removed and suction used, drained 1700mls of fluid from the cyst

then scope re introduced, further 11 mm umbilical trocar inserted under direct vision using applied medical trocar. 2x5 mm ports (both paraumbilical) were inserted under vision.

Results

Intraabdominally:

-left ovarian Dermoid cyst 17-20 cm, torsion with tube 5 times, blackening of the tube

-Right ovary and tube looked normal

-Uterus looked under umbilicus

-Liver surface looked smooth.

no adhesions,

using graspers the ovary untwisted, cyst wall dissected off the ovarian wall with difficulty due to oedema of ovarian tissue, very adherent and no appropriate planes, hair and caseous material drained. small healthy ovarian tissue left at endo of the procedure, ovarian cyst wall removed in 15 mls endo bag from umbilicus and sent to histology.

Minimal blood loss, EBL less than 30ml

Gas removed, Port sites removed under vision Umbilical port site closed with J needle 3-0 vicryl rapid to the skin. foetal heart check at end of the procedure by USS, NAD

Upon his topathologic examination after surgical excision **Ovarian cyst confirm**

- Mature cystic teratoma.

She had antenatal care regularly and anomaly scan after 2 weeks postop normal.

Conclusions

Large ovarian masses are usually rare during pregnancy. Although diagnostic ultrasound is a frequently used imaging tool in patients with suspected OT, the mere presence of blood flow on Doppler ultrasonography of the

adnexa has a poor negative predictive value. A high clinical suspicion and early laparoscopic management correlate with favourable maternal and foetal outcomes.

It is necessary to properly evaluate the case of ovarian masses during pregnancy, to decide the appropriate line of management.

Laparoscopic cervical cerclage after trachelectomy for mullerian adenocarcinoma and successful pregnancy outcome: a rare case report and review of the literature

Eleftherios Zachariou¹, Pantelis Trompoukis², Al-Ahmar Samer Nikos², Aris Antsaklis¹

¹National and Kapodistrian University of Athens,

1st Department of Obstetrics & Gynecology- Alexandra General Hospital, Athens, Greece

²IASO General Hospital- Athens, IASO Endoscopic Surgery Department, Athens, Greece

Background

Laparoscopic cervical cerclage (LCC) is a minimally invasive procedure used for managing cervical insufficiency. The treatment of early stages of invasive cervical carcinoma involves trachelectomy for fertility preservation but also is a main reason of complications due to short "cervix". The role of laparoscopic cervical cerclage on these cases is very important and in the case report we are presenting, a 35-year-old woman with history of trachelectomy due to mullerian adenocarcinoma underwent LCC before in vitro fertilisation. The pregnancy outcome was successful, giving birth, via caesarean section on 34 weeks of pregnancy, a healthy baby. The review of the literature showed only 18 cases of laparoscopic cerclage after trachelectomy, with impressive pregnancy result of 18 births and one miscarriage of the first and one of prelabour rupture of foetal membranes on 19 weeks following termination of pregnancy due to poor perinatal outcomes.

Methods

We performed a systematic literature review of 5 major databases (Medline, Scopus, Google Scholar Cochrane Central Register of Controlled Trials and Clinicaltrials.gov) from inception till April 2023. All comparative studies present cases of women with history of trachelectomy for early-stage cervical cancer and desire for fertility who underwent laparoscopic cervical cerclage due to an ongoing pregnancy or willing of childbearing. These cases include information about the pregnancy outcomes and possible complications of LCC.

Results

Data from 5 retrospective cohort studies and case reports on 18 patients with 20 pregnancies were extracted and analysed. The pooled results revealed that laparoscopic cervical cerclage after trachelectomy has a significant rate of successful pregnancy outcomes (18/20 healthy infants - 90%, 1/20 first trimester miscarriage, 1/20 prelabour rupture of foetal membranes following termination of pregnancy). Of these cases 11 pregnancies were spontaneous, 6 with in vitro fertilisation and 2 with intrauterine insemination. The laparoscopic cervical cerclage was placed before pregnancy on 17 of 20 cases and on 3 cases during pregnancy (Mean Gestational Age: 12.6 weeks). The incidence of complications after the installation of the cerclage was impressively low, with 1 case of intrauterine infection. Even if there were 7 cases of prelabour rupture of foetal membranes with mean GA of 33 weeks, the pregnancy outcomes were significant, 6/7 healthy infants and only one termination of pregnancy.

Conclusions

The laparoscopic cervical cerclage is an exceptional choice of high-risk pregnancy with great danger of cervical insufficiency and has already been used on specific cases to improve pregnancy outcomes. This case report with the review of the literature aims to underline the use of LCC as a useful option especially after trachelectomy due to cervical cancer, where the remaining "cervix" is too short for cervical access and suturing. The pregnancy outcomes seem to be very promising, with low-rate complications.

How big is too big an adnexal tumour for a minimally invasive treatment? Case presentation and review of literature

Razvan Socolov¹, Tudor Butureanu¹, Ana Apetrei²

¹University of medicine Gr T Popa Iasi, 3rd Obstetrics and Gynecology Clinic, Iasi, Romania

²Hospital of Obstetrics and Gynecology Elena Doamna, Gynecology Department, Iasi, Romania

Background

Paraovarian cysts are common but are usually small in size. They might also be called paratubal cysts or hydatid cysts of Morgagni. These cysts usually don't cause any symptoms and often aren't discovered unless they are discovered during surgery or cause pain. Enlargement or torsion of paraovarian cysts has been reported but is a rare cause of acute lower abdominal pain.

Methods

A 21-year-old nulliparous, virgin woman presented in gastroenterology with acute onset of upper abdominal pain. She had no medical history. Her menstrual cycle was regular and normal, and the last menstrual period was 3 weeks previously. Full blood count was normal. Abdominal and bimanual pelvic examination showed a whole distended abdomen mimicking a term pregnancy. An ultrasound scan revealed a simple cystic mass difficult to measure. No Doppler flow was detected, no vegetation or septum in the cyst and there was no ascites. The left ovary appeared normal with a 20mm follicle. CA125, CEA, and CA 19-9 levels were within normal limits. An MRI was performed that showed a simple ovarian cyst of 150/300/360 mm.

Results

We performed a laparoscopically adnexectomy after the tumour was emptied through the umbilical open laparoscopy incision. The clear fluid inside was estimated at 11 liters. After emptying it, it revealed a partially twisted, large, right sided paraovarian cyst. Cystectomy was technically impossible, and the adnexa was removed. Pathologic frozen section diagnosis revealed a benign fallopian cyst, and a definitive histological diagnosis will soon be available.

Conclusions

Our case was impressive in terms of symptoms, size, and occurrence in a nulliparous virgin patient. The minimally invasive approach ensured fast recovery and reproductive function conservation.

Clear cell carcinoma arising from an endometriosis cyst during in vitro fertilization process: a case report

Marta Camacho Sanchez¹, Marta Valdes¹, Mariona Rius¹, Francisco Carmona¹, Berta Diaz Feijoo¹
¹Hospital Clinic, Gynecology, Barcelona, Spain

Background

The estimated prevalence of the association between endometriosis and ovarian cancer ranges between 0.03% and 0.08%. Transvaginal ultrasound is nowadays a well-established imaging tool for the diagnosis and follow-up of pelvic endometriosis.

Methods

We present a case of a 35-year-old female affected of endometriosis, with diagnosis of a clear cell ovarian tumour arising from an endometriotic cyst after ovarian stimulation for in vitro fertilization. Due to short-term changes in the ovary sonographic appearance, malignancy was suspected. The patient was followed up in our centre due to endometriosis. She had prior history of surgery in 2018 (intestinal resection due to deep endometriosis affecting the rectum) and multiple hormonal treatment until January 2020.

The transvaginal ultrasound (TVUS) performed during the ovarian stimulation process in January 2021 showed a cystic adenomyoma, both ovaries adhered to the uterus and increased size due to the presence of multiple follicles and left hydrosalpinx that was newly identified. Left ovary presented a follicle with an hypoechogenic level inside suggesting a haemorrhagic focus in context of the stimulation process. After an embryo transfer attempt in May 2021 without achieving pregnancy, the case was reassessed in June 2021 in our multidisciplinary committee, agreeing to carry out a new IVF cycle and bilateral salpingectomy prior to a new transfer.

In the preoperative TVUS performed in October 2021, some changes in the sonographic appearance of the left ovary were noticed: it increased in size at the expense of various antral follicles, two atypical endometriomas measuring 18x8mm and 11x9mm and a cystic image with hyperechoic content of 28x19x26mm, suggestive of haemorrhagic follicle. After three weeks the cyst persisted and increased in size (36x36x31mm) and presented a solid hyperechogenic area with central vascularization. The patient was asymptomatic, and the physical examination was normal. The CA125, CA 19.9, CEA and HE4 levels were normal.

Diagnostic laparoscopy with left ooforectomy, bilateral salpingectomy and peritoneal biopsy was performed. Pathological examination of the left ovary demonstrated an endometriosis cyst with an area of clear cell carcinoma, with no assessable capsular invasion due to ovarian fragmentation. No histological signs of malignancy were identified in the tubes of peritoneum. Then, staging surgery conserving uterus was performed by laparotomy, including contralateral adnexectomy, pelvic and para-aortic lymphadenectomy, omentectomy and peritoneal washing; all histological results were negative.

During the follow-up the patient presented persistent bleeding and Ovarian remnant syndrome was diagnosed with TVUS, so surgery was indicated again. Radical staging surgery was performed with hysterectomy, sigmoid resection and diaphragmatic dome extraction of disease.

Results

.

Conclusions

Endometriosis can undergo malignant changes. TVUS is a well-established imaging tool for the diagnosis and follow-up of pelvic endometriosis. Short-term changes in the ovary sonographic appearance may be considered for malignancy suspicion, particularly solid vascularized new components.

Investigation of the usefulness and perinatal outcome of laparoscopic surgery for 18 patients with juvenile cystic adenomyoma (JCA)

Mari Kitade¹, Keisuke Murakami², Yukiko Okada², Yu Kawasaki², Shiori Takeuchi², Atsuo Itakura²

¹*Juntendo University Faculty of Medicine, Obstetrics and Gynecology, Tokyo, Japan*

²*Juntendo University Faculty of Medicine, Obstetrics and Gynecology, Tokyo, Japan*

Background

Juvenile cystic adenomyoma (JCA) is a disease that has a cystic lesion composed of endometrial-like cells in the myometrium independent of the endometrial cavity, and even if small, repeating bleeding into the cyst causes severe menstrual pain.

In this presentation, we retrospectively examined the efficacy of laparoscopic surgery for JCA.

Methods

From January 2000 to December 2022, 18 patients who underwent laparoscopic surgery for JCA at our hospital were targeted. Patient background, surgical findings, surgical results, therapeutic effects, and perinatal outcome were examined.

Results

Patient age was 25.6 ± 5.1 years, cystic tumour diameter was 3.2 ± 0.8 cm, and chief complaints were dysmenorrhea in 18 cases (100%) and chronic pelvic pain in 5 cases (29.4%). Examination of surgical findings revealed that 7 cases (41.2%) had pelvic endometriosis, and the r-AFS score was 14.5 ± 13.4 . For 7 cases (41.2%), cystic tumours located near the right circular ligament. Examination of the surgical results showed that the operation time was 82.2 ± 26.6 min, the estimated blood loss was 42.2 ± 31.9 ml, and no perioperative complications were observed. The painful score evaluated by the Numerical rating system (NRS) clearly declined after surgery for all cases. No recurrence or relapse of symptoms was observed in all cases. Pregnancy was achieved in 7 patients (46.7%) of the 15 patients who wanted to conceive, all of them had live babies, and there were no perinatal complications.

Conclusions

Laparoscopic surgery is quite effective and could be the first choice for JCA treatment regardless of tumour size.

Laparoscopic sacrocolpopexy for advanced pelvic organ prolaps (descensus uteri III-IV, cystocele III-IV, rectocele III-IV) using DynaMesh (PVDF)

Andreas Kavallaris¹, Antonios Gkoutzioulis¹, Ourania Kaiafa¹, Panagiotis Papandreou¹, Sofia Papadimitriou¹, Dimitrios Zygouris¹

¹St. lukes Hospital, Gynecology Oncology and Laparoscopic Surgery, Thessaloniki, Greece

Background

Description and evaluation of the Technique in 122 Patients treated laparoscopically to repair advanced (III-IV) genital prolapsed. A non-randomised prospective analysis of 102 women, who underwent laparoscopic genital prolapse repair at st. loukas hospital in Thessaloniki, Greece and at Mother and Child medical centre in Nikosia, Cyprus.

Methods

The patients with Descensus uteri underwent total laparoscopic hysterectomy with BSO and then laparoscopic sacrocolpopexy using two different kinds of mesh. PRR for either zytocele or rectocele and PRS for both.

Results

All the patients were reviewed at 1 month, 3 months, 9 months and then every 6 months after the surgery for a period of 3 years. The follow-up was between 3 months and 84 months (2015-2023). There were no major intraoperative or postoperative complications, and we had no mesh exposure or erosion. The mean hospitalization stay was 2.1 days.

Conclusions

The laparoscopic sacrocolpopexy using DynaMesh ((PVDF) is an effective and safe technique to repair the pelvic organ prolapses. The long term anatomical functional results are very satisfactory with no major complications.

Challenges of laparoscopic approach for managing ovarian torsion in pregnancy – case study

Ayman Abdelkader¹, Heba Abdelaziz², Thabet Peter³, Sayantana Patra-Das⁴

¹Consultant Endometriosis and Minimal invasive surgery at Homerton University Hospital, Obstetrics and Gynaecology, London, United Kingdom

²Senior specialist at Nasser Specialised Hospital, Obstetrics and Gynaecology, Cairo, Egypt

³MTI clinical fellow at Homerton University Hospital, Obstetrics and Gynaecology, London, United Kingdom

⁴Consultant at Homerton University Hospital, Obstetrics and gynaecology, London, United Kingdom

Background

It comes as no surprise that the use of laparoscopy in emergency gynecological surgeries is becoming more popular, especially when it comes to managing adnexal cysts accident including cyst rupture, hemorrhage, and torsion. This popularity is attributed to various factors, but primarily, to the quicker recovery and shorter hospital stay compared to laparotomy.

To date, the evidence on laparoscopy in pregnancy remains scarce, especially in the rare event of ovarian torsion in pregnancy which is estimated as 1:4000. The British society of gynaecological endoscopy (BSGE) published a comprehensive guidance based on the available evidence related to laparoscopy in pregnancy.

Methods

The presentation will discuss a case of ovarian torsion in a 10 weeks' pregnant woman. Demonstrating images of the ultrasound scan findings and Step by step video of the operative findings and surgical technique. The ovary was found to be gangrenous necessitating adnexectomy. Step by step video of the operative findings and surgical technique.

Results

The aim from this case discussion is to take you through the tips and tricks of laparoscopy in pregnancy, such as safe entry, port positions and pressure at entry and while operating. It will highlight techniques to overcome the obstacles of poor vision in cases of advanced gestation and the safety of electrosurgery in pregnancy.

Conclusions

In order to provide women with proper counselling and obtain an informed consent, gynaecologist should be aware of possible complications of laparoscopy in pregnancy including the risk of miscarriage, anaesthetic concerns and teratogenicity in early pregnancy.

Laparoscopic vesicouterine fistula repair following caesarean section

Ligia Balulescu¹, Simona Brasoveanu¹, Cristina Secosan¹, Marilena Pirtea¹, Laurentiu Pirtea¹

¹University of Medicine and Pharmacy "Victor Babeş" Timișoara, Department of Obstetrics and Gynecology, Timisoara, Romania

Background

Vesicouterine fistula, first described as a clinical entity by Youssef in 1957, is an abnormal communication between the bladder and the uterus. It represents a rare urogenital complication (1-4% of genitourinary fistulas), whose main cause is lower segment caesarean section. A surgical excision of the fistula remains the mainstay of treatment. Laparoscopic repair is becoming more feasible, and it is an alternative to the traditional open procedure.

Methods

A 32-year-old female patient was referred to our department with intermittent vaginal leakage of urine. She underwent a first elective cesarean section at 39 weeks of pregnancy. A magnetic resonance imaging and transvaginal ultrasound was performed. The cystoscopy revealed a fistulous opening with a diameter 1,5 cm in the posterior bladder wall.

Results

Surgery was performed by mobilization of bladder and wide anterior uterine dissection. Bladder parietal defect was repaired in two layers and the defect in the lower uterine segment was identified and was closed. The operating time was 80 min with a reduced blood loss (50mL). After 6 months of taking contraceptives, a successful pregnancy was obtained.

Conclusions

Minimally invasive techniques started gaining ground as an alternative approach to traditional open surgical repair. Laparoscopic repair of vesicouterine fistula is a safe and effective procedure, with successful outcome.

Primary ovarian carcinoid: a case report

Dr. Madhumathi Degapudi¹, Saradha Nallayagounder somu¹

¹SIMS Hospital - Vadapalini, obstetrics and gynaecology, Chennai, India

Background

Primary ovarian carcinoid tumours are rare neuroendocrine tumours representing less than 0.1 % of all ovarian carcinomas and 5% of all carcinoid tumours. The diagnosis is often difficult since they are rare and most often made until the patient undergoes a histopathological examination. Despite imagery with CT and MRI preoperatively which recognizes solid characteristics, the differential diagnosis with other ovary malignancies is very difficult. We report a similar case where preoperatively was suspected to have adnexal mass with pelvic endometriosis and the histopathological examination showed bilateral primary ovarian carcinoid.

Methods

61 years old female, postmenopausal with complaints of pain in the anal region, difficulty in bowel evacuation for 3 months. History of lower back pain and increased bowel habits 4-6 times/day. Imaging studies showed adnexal mass with pelvic endometriosis with mechanical compression of sigmoid and rectum. Patient was planned for total laparoscopic hysterectomy with bilateral salpingo-oophorectomy.

Results

Total laparoscopic hysterectomy with bilateral salpingo-oophorectomy done and the intra-operative findings showed to be frozen pelvis with bilateral adnexal mass. Post-operative histopathological examination showed primary ovarian carcinoid with lymphovascular invasion. PET CT done showed soft tissue lesion in the vaginal wall with multiple enhancing peritoneal deposits and mild uptake enhancing distal end of appendix. Medical oncology opinion was obtained was started on Chemotherapy with SUNITINIB + SANDOSTATIN LAR. Planned for 6 cycles of chemotherapy.

Conclusions

Primary ovarian carcinoid is a rare disease, and usually with a satisfactory outcome. The prognosis is related to tumour grading, local invasion, presence of metastases and time of diagnosis. The basic treatment of these tumour remains surgical. Although these tumours are rare, they should be well known by gynaecologists to offer to the patient with solid ovarian tumour the better management.

“ALL THE TOOLS IN THE BOX” a comprehensive and ethical approach to caesarean scar ectopic pregnancy a case report

Priscilla Alameda¹, Doris Benavides²

¹University of the Philippines College of Medicine - Philippine General Hospital, Obstetrics and Gynecology, Manila, Philippines

²University of the Philippines College of Medicine - Philippine General Hospital, Obstetrics and Gynecology- Division of Gynecologic Oncology, Manila, Philippines

Background

Cesarean scar ectopic pregnancy is a complication in which an early pregnancy implants in the scar from a previous cesarean delivery. The incidence ranges from 1 in 1800 to 1 in 2656 of overall pregnancies and therefore is a rarity on its own. In the Philippines, there are even more limited reports as to the actual number. In our institution alone, there have been only four (4) cases in the past 2 years.

Methods

This case report is in a 30-year-old, Gravida 5 Para 3 (3013), who had three (3) prior cesarean sections and presented with a transvaginal ultrasound finding of cesarean scar pregnancy. The patient expressed desire for a conservative approach and still desired future childbearing. However, consent was gained in performing a hysterectomy if with complications necessitating such a procedure. The approach to diagnosis was comprehensive involving a transvaginal ultrasound supplemented with MRI. Careful deliberation with a multispecialty surgical team was done, arriving at a decision which was both time sensitive and ethically bound. The operative plan was preoperative cystoscopy, bilateral ureteral stenting, laparoscopic resection of the cesarean scar ectopic pregnancy, possible cystorrhaphy vs partial cystectomy, possible exploratory laparotomy, total hysterectomy under general endotracheal anaesthesia. A vertical 1.2 cm incision was done on the skin at the lower part of the umbilicus and carried down to the peritoneum. Primary 11-12 mm blunt trocar was inserted followed by a laparoscope with the entry site then inspected. The placenta and gestational sac were extracted from the site of incision intact. The placental tissue measured 6x3 cm. The 1.5 cm gestational sac contained a 1x 2 cm foetus.

Results

A laparoscopic approach with ultrasound and hysteroscopic guidance was performed all leading to the successful excision of the cesarean scar ectopic pregnancy. Postoperative serum diluted beta-hCG was done which showed 20, 935.91 mIU/ml (82.5% decrease) and 1 week postoperatively was 3,636.79 mIU/ml (82.6% decrease). Histopathology results showed embryonic tissue, immature placental tissues and decidua. Weekly monitoring of beta-hCG showed steady decreasing trends and reached less than 5 mIU/ml 6 weeks postoperatively.

Conclusions

With the increasing rates of cesarean sections, developing this complication may be more common in the future. Therefore, this paper aims to provide clinicians on a comprehensive and ethical approach on managing this rare form of ectopic pregnancy.

Results in the first year after the introduction of the vaginal natural orifice transluminal endoscopic surgery surgical technique in a gynaecology department

Jone Paredes Goenaga¹, Miren Lore Barinaga-Rementeria Zabaleta¹, Annie Bumstead Vujcic¹, Ruben Ruiz Sautua¹, Maria Arantzazu Leukona Artola¹
¹Hospital Universitario Donostia, Servicio de Ginecología y Obstetricia, Donostia, Spain

Background

To describe the results of vaginal natural orifice transluminal endoscopic surgery (vNOTES) surgical technique in the Gynaecology and Obstetrics Service of the Hospital Universitario Donostia, Spain, one year after its introduction for the first time.

Methods

The medical records of all patients operated on in our service using vNOTES access from May'22 to April'23 were reviewed.

Two members of the service undertook a previous training course, and the technique was subsequently disseminated among the rest of the members of the team. A protocol for pre-, intra- and post-surgical management was drawn up, and was shared with all members of our service, as well as the anaesthesia service and the operating theatre and hospital ward nurses and assistants.

All patients received antibiotic coverage with vaginal clindamycin, intravenous cefazoline and metronidazole. Cervical infiltration with bupivacaine and epinephrine was done. The platform chosen for access was GelPoint V-Path of Applied and the advanced clamp that was used was Enseal X1.

Results

56 surgical interventions have been performed with vNOTES access, distributed in 25 total hysterectomy (TH) and double adnexectomy; 27 TH and prophylactic bilateral salpingectomy, 1 simple TH and 3 adnexal surgeries.

The indications have been: 23 myoma, 14 hyperplasia with atypia/endometrial adenocarcinoma, 8 cervical pathology and 11 others (oncological risk reduction surgery, sterilization).

Average duration of the intervention: 98 min.

Conversion: 1 strategic conversion to laparoscopy to complete adnexectomy (obesity and adhesions).

Intraoperative complications: 3 moderate bleedings (all controlled via vNOTES).

Post-surgical complications: 1 vaginal vault haematoma (conservative management), 1 fever and suspicion of a bowel injury which was not confirmed, 1 bladder injury (conservative management with permanent catheter).

Reinterventions: 0.

Mean hospital stays (except for the 3 patients with complications): 21.2h.

Conclusions

The laparoscopic vNOTES approach is an interesting alternative for gynaecological procedures for surgeons who are experienced in laparoscopic and vaginal surgery, as it has a low complication rate without requiring a large learning curve.

The main difficulties identified were: severe obesity, large uterine volume and a previous c-section.

Patients with suspected endometriosis and a fixed non-prolapsed cervix were excluded for this surgical access. Avoiding patients with such characteristics may be useful for surgeons who want to initiate their journey with this technique.

The average hospital stay we have identified has been longer than the desired, which we aim to improve by raising awareness of the specific protocols of intensive post-surgical recovery among the medical professionals and patients.

Videolaparoscopy in neovaginal creation surgery for Mayer-Rokitansky-Kuster-Hauser Syndrome: a comprehensive review

Danielle Costa Nazareth¹, Juliana Romano¹, Juliana Cerqueira¹, Debora Fonseca¹, Marina Bartolomeu¹, Nicole Oliveira¹

¹Hospital Israelita Albert Einstein, Gynecology and Obstetrics, São Paulo, Brazil

Background

To describe the practice of videolaparoscopy in neovaginal creation surgery for patients with Mayer-Rokitansky-Kuster-Hauser Syndrome (MRKHS).

Methods

We conducted a review of studies published in the English language that provided high-level evidence on the use of videolaparoscopy in neovaginal surgery for MRKHS patients. A search was performed in the PubMed database using the search phrase "Surgical Neovaginoplasty" "Mayer-Rokitansky-Kuster-Hauser Syndrome" and Laparoscopy.

Results

After analysing studies published in the last 10 years, we selected 5 relevant studies. Yang et al., 2021 described the minimally invasive single-port laparoscopic Vecchietti procedure with positive outcomes in a 22-year-old patient with confirmed vaginal agenesis by magnetic resonance imaging. The same author, in 2022, compared the modified techniques of laparoscopic Vecchietti and Davydov in a retrospective cohort of 53 women with MRKH syndrome. Both techniques were effective in treating vaginal agenesis, but the modified Vecchietti technique was considered simpler. Origoni et al., 2021 investigated the clinical, morphological, and ultrastructural aspects of peritoneal neovaginal mucosa after laparoscopic Davydov neovaginoplasty, showing comparable results to native vaginal mucosa. Zhang et al., 2018 presented the combination of laparoscopic cervicovaginal reconstruction and Wharton-Shears-George using a small intestinal submucosa (SIS) graft in a patient with MRKH syndrome and rudimentary cavity. Gweon et al., 2016 described a rare case of Mullerian agenesis with inguinal ovaries and primary ovarian insufficiency successfully managed with laparoscopy and modified Davydov procedure.

Conclusions

Videolaparoscopy has proven to be a safe and effective approach in neovaginal creation surgery for MRKHS patients. Different techniques have been described, providing satisfactory anatomical and functional outcomes. The laparoscopic approach offers advantages such as shorter surgical time, minimal blood loss, and good aesthetic results. These findings reinforce the importance of videolaparoscopy as a viable option in neovaginal creation surgery for MRKHS patients.

An audit of oophorectomy following hysterectomy with ovarian conservation

Tom Coia¹, Mohamed Elsheikh¹, Zeiad El-Gizawy¹

¹University Hospitals of the North Midlands- NHS, Obstetrics and Gynaecology, Stoke on Trent, United Kingdom

Background

The decision for oophorectomy at the time of hysterectomy is complex and must be individualised. Subsequent oophorectomy following hysterectomy may be performed for a number of indications but carries increased surgical risks due to adhesions.

In this audit we aimed to examine the characteristics, indications, route and outcomes of patients in a single unit undergoing oophorectomy following a previous hysterectomy with ovarian conservation.

Methods

Clinical records were examined for cases of unilateral or bilateral oophorectomy following hysterectomy with ovarian conservation from 2018-2023 in a large, teaching hospital in the UK. Data were collected on the initial indication and route of hysterectomy with ovarian conservation. Data were also collected on the subsequent oophorectomy, including the route, indication, time interval from hysterectomy, length of stay and improvement in pain (if pain was the indication for oophorectomy).

Results

In the time period (2018-2023), 49 individuals were identified as undergoing unilateral or bilateral oophorectomy following a hysterectomy with ovarian conservation.

There was a large range of ages at the time of oophorectomy, from 26 to 82 years old. As expected, there were multiple indications for both the initial hysterectomy and subsequent oophorectomy, with the majority of oophorectomies being performed with a minimal access approach (92%). Most oophorectomies found were performed within 5 years of the initial hysterectomy.

Further analysis has been performed by subdividing the cohort of patients by indication for subsequent oophorectomy. For those undergoing an oophorectomy for pain, patients were divided dependant on the presence or absence of adenexal pathology demonstrated on pre-operative imaging. Improvement in symptoms of pain have been demonstrated in this group following oophorectomy.

A total of 9 patient underwent a hysterectomy with ovarian conservation for pain alone and subsequently had an oophorectomy (bilateral or unilateral) for pain without any adenexal pathology demonstrated on imaging. Of these patients, 7 showed improvement in their pain symptoms (78%).

Conclusions

From this audit we are able to demonstrate a heterogenous group of patients undergo oophorectomy following hysterectomy with ovarian conservation. A minimally invasive (laparoscopic or robotic) approach is used for the majority. Although numbers in this audit are limited, these data do show that persistent pain does respond to interval oophorectomy. This information will be of use to clinicians when making individualised decisions with patients on ovarian conservation at time of hysterectomy.

Laparoscopic left adnextomy due ovarian torsion during the 11th week of pregnancy at a patient with a previous laparoscopic right adnextomy before 1 year

Eleftherios Klonos¹, Eleni Bili¹, Theodoros Theodoridis¹, Leonidas Zepeiridis¹, Christos Zymperdikas¹, Grigorios Grimbizis¹

¹Aristotle University of Thessaloniki, 1st.Dpt Ob/Gyn, Thessaloniki, Greece

Background

This is a case of a 26 years old pregnant patient, G1P0, who referred to our emergency department due to severe acute abdominal pain located at the left inferior region of the abdomen, during the 11th week of her pregnancy. Based on her medical history, she underwent a laparoscopic ovariectomy one year ago, due to torsion of a cyst located at her right ovary. During clinical examination, enhanced tension of the anterior abdominal wall was revealed. In the sequence, the patient underwent ultrasonographic examination, that revealed the presence of a positive heart function of the foetus and the biometry of the foetus kept up with the gestational age. Moreover, plenty of haemorrhagic liquid at the space of Douglas and a cyst formed respectively to the left ovary were also revealed.

Based on the (clinical and ultrasonographic) evidences and the gestational age, we decided to perform a laparoscopic procedure in order to remove the left ovary and fallopian tube.

Methods

This is a case of a 26 years old pregnant patient, G1P0, who referred to our emergency department due to severe acute abdominal pain located at the left inferior region of the abdomen, during the 11th week of her pregnancy. Based on her medical history, she underwent a laparoscopic ovariectomy one year ago, due to torsion of a cyst located at her right ovary.

During clinical examination, enhanced tension of the anterior abdominal wall was revealed, whereas the “rebound sign” was also found while releasing the pressure of the peritoneal cavity. In the sequence, the patient underwent ultrasonographic examination, that revealed the presence of a positive heart function of the foetus and the biometry of the foetus kept up with the gestational age. Moreover, plenty of haemorrhagic liquid at the space of Douglas and a cyst formed respectively to the left ovary were also revealed.

Based on the (clinical and ultrasonographic) evidences and the gestational age, we decided to perform a laparoscopic procedure in order to remove the left ovary and fallopian tube.

Results

The recovery of the patient was uncomplicated. Progesterone supplements were prescribed to the patient up to the end of pregnancy. The pregnancy remained under regular surveillance from our department, and the patient gave birth to a healthy newborn during the 40th week of pregnancy. After the delivery of the foetus, hormone replacement therapy was prescribed to the patient.

Conclusions

Several pathologic conditions during pregnancy might require surgical procedure in order to diminish the possible severe consequences on both mother and foetus. Laparoscopic approach is an alternative, that enhances the possibility of a safe procedure (especially during the second trimester of the pregnancy) and the continuity of a vital pregnancy.

Evaluation of a laparoscopic sacropexy technique: the Y shape method

Suzy Fleur Fopa Mafomena¹, Bonomo Iris¹, Luyckx Mathieu¹, Squifflet Jean Luc¹, Jadoul Pascale¹, Gerday Amandine¹

¹Cliniques Universitaire Saint Luc, gynécologie, Bruxelles, Belgium

Background

to review the feasibility, the efficacy, and the safety of laparoscopic promontofixation with a Y shape mesh "trouser technic", with a systematic supra-cervical hysterectomy.

Methods

this is a one centre retrospective analysis. We include all the women who underwent a laparoscopic sacropexy with a Y shape mesh between June 2005 to February 2020. Professor Jean-Luc Squifflet set the technic in our department. A supracervical hysterectomy is systematically perform during the same procedure if the uterus is still present. Preoperative evaluation, operative technics, complications, short- and long-term outcomes were assessed.

Results

185 patients had a laparoscopic promontofixation, associated with a subtotal hysterectomy or with a history of subtotal hysterectomy, with the trouser technic. The mean operative time for a laparoscopic sacrofixation with supracervical hysterectomy was 119 minutes, and for a patient who already had supracervical hysterectomy was 105 minutes. We had 4 intra-operative complications (3 vesical breach, 1 vaginal perforation and 1 pulmonary embolism). The hospital stay was 3.1 days. 94% of the patients said they were totally satisfied during the post-operative consultation. We have seen 95 patients in long term post-operative consultation. We found 2 relapses and 12 patients who were complaining of constipation. 1 patient had a mesh erosion.

Conclusions

Laparoscopic sacropexy with a Y shape mesh is a feasible, safe technique and rapid technique with a low rate of complication and relapse.

Inadequacy of endometrial sampling and clinical outcomes

Elhami Ebeid¹, Kerry Sargant¹, Peter Hanna¹

¹*East Sussex Hospitals, Gynaecology department, East Sussex, United Kingdom*

Background

Endometrial sampling is one of the standard diagnostic procedures in gynaecology for uterine abnormalities. Endometrial pipelle biopsy is widely used in women with postmenopausal bleeding (PMB), particularly because of its high sensitivity for detecting endometrial hyperplasia and endometrial cancer. However, it might not detect other intracavitary lesions such as polyps and fibroids.

In patients with PMB, not on hormone replacement therapy (HRT), a TVS endometrial thickness cut off of ≥ 4 or 5 mm are used to offer further tests such as an outpatient endometrial biopsy.

Inadequate endometrial samplings can be frequently encountered in up to 30% of cases, this can complicate decision making process.

In addition a wide variation exists among specialist gynaecological pathologists regarding what would define an adequate endometrial biopsy.

Methods

Data were collected between October 2020 until October 2021 from the histology department. Excel sheet was created and data analysis was undertaken.

Results

Case notes from our electronic data base of 102 patients were examined.

During this year, the laboratory processed 1171 endometrial biopsies of which 184 cases were reported as inadequate.

17% of the outpatient endometrial pipelle inadequate samples had to undertake either outpatient hysteroscopy or hysteroscopy under general anaesthesia, only one patient was diagnosed with endometrial cancer. This patient had initially suspicious looking endometrium on ultrasound. The later finding has reiterated the overall high sensitivity of the endometrial pipelle to detect uterine malignancy.

Result of specimen's inadequacy should be individualised in management, as 68% of patients were correctly diagnosed as atrophic on clinical ground.

Conclusions

Endometrial inadequacy rate was found to be less than 12%, which is within the recognised range in medical literature.

Good medical practice during the procedure of obtaining endometrial pipelle biopsy is recommended and encouraged in counselling about the benefits, risks and alternative options.

Case report: T-shaped uterus and surgical hysteroscopic treatment in an infertile patient

Khaleda Sajjadi Maeder¹, Christos Tsaousidis², Susanne Rohner², Rothmund Ralf²
¹Lindenhofhospital, Gynecology and Obstetrics, Bern, Switzerland
²Lindenhofhospital, Obstetrics and Gynecology, Bern, Switzerland

Background

Referral of a 38-year-old female patient with a desire to have children to our clinic for hysteroscopy. The patient had four miscarriages in early pregnancy after spontaneous pregnancies. A large laboratory chemistry workup was already performed with exclusion of thrombophilia and many antibodies as well as karyotyping of both partners.

Methods

Sonographically, a submucosal myoma was seen at the fundus, and in addition, a T-shaped uterus was suspected. This was well visible especially in 3D sonography. The patient then immediately had a surgical hysteroscopy and simultaneous laparoscopy, where the suspected diagnosis of the sonography was confirmed. In the operation, surgical hysteroscopic lateral metroplasty is first performed under laparoscopic control. For this purpose, the monopolar hook is used to split the endometrium successively longitudinally, first on the left side. The myometrium is cut from the isthmus to the left tubal ostium to such an extent that the left tubal ostium is completely visible. Then follow the same procedure on the right side. All in all, a completely unfolded uterine cavity is now visible. Subsequently, the submucosal myoma is resected with the bipolar snare.

Results

2 weeks after the operation, another sonography is performed, where the cavum is larger and the T-shape is completely absent. The tubal ostia seem to be open and free, so that the fertility therapy can be continued.

Conclusions

T-shaped uterus is considered a congenital uterine malformation resulting from the failure of later embryological development of the uterus.

It typically exhibits a narrowed uterine cavity with lateral indentations, with the shape of the endometrial cavity resembling the letter T instead of a triangle. Three-dimensional ultrasound (3D-US) allows detailed visualization of the uterine cavity, uterine walls and external contours of the uterus.

Hysteroscopy, a minimally invasive method, enables visualization of the inside of the cervical canal and endometrial cavity besides allowing treatment of T-shaped uterus.

The prevalence of T-shaped uterus and its impact on reproductive outcomes remain unknown.

With the hysteroscopic Metroplastic, we nevertheless enable our patients who wish to have children to better implant the fertilized egg and thus achieve a successful pregnancy through a simple surgical procedure.

How to deal with a preoperative diagnosis of OHVIRA syndrome ?

Laurie Naa¹, Pierre Bonnet², Michelle Nisolle¹

¹CHR Citadelle Liège, Gynécologie-Obstétrique, Liège, Belgium

²CHU Liège, Urologie, Liège, Belgium

Background

The obstructed hemivagina and ipsilateral renal agenesis (OHVIRA) syndrome is a rare congenital malformation generally known as a triad: didelphys uterus, obstructed hemivagina and unilateral renal anomaly. Diagnosis is usually made shortly after menarche because of the pelvic pain caused by a hemi retention of the menses. Actually, it appears to include a large spectrum of urogenital anomalies. Some recommend classifying the syndrome into two types of clinical presentation depending on a complete or incomplete obstruction, which is related to an early versus delayed diagnosis, as we will present.

Accurate diagnosis of the defect and its relationship with symptoms such as pelvic pain, dysmenorrhea, dyspareunia, infertility or miscarriages are the first and most crucial step in order to treat it appropriately and prevent complications.

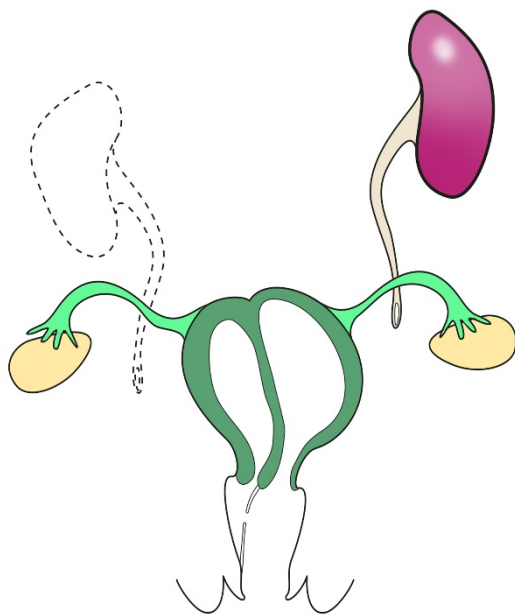
Methods

A patient in her thirties was addressed to our centre with a suspected diagnosis of a right rudimentary horn on a transvaginal ultrasound (TVS) during a pre-conceptional visit. She had a history of right nephrectomy for renal atrophy.

First, magnetic resonance imaging described a right rudimentary horn and a left hemi-uterus. The latter communicated with a cervix and a vagina while the right cavity had no communication with a vagina. In addition, hysterosalpingography showed only one cervix and catheterization revealed only one small left uterine cavity with no communication with the second one. Then, a 3D TVS classified the patient's malformation as a bicorporeal uterus with no uterine septum and with two distinct cervixes, U3bC2Vx according to ESHRE/ESGE classification.

Results

Surprisingly, laparoscopy showed a single enlarged uterus suggesting a septate uterus rather than a bicorporeal one. The previous indication of removing the right rudimentary horn was not confirmed and a fistula was suspected, explaining the late diagnosis of this Müllerian anomaly. Under general anaesthesia, deep gynaecological examination allowed to visualize a latero-vaginal fistula on the right to the left cervix, which was surgically enlarged. The vaginal septum was entirely resected and revealed a right cervix. The diagnosis obtained by surgery was a complete septate uterus with a cervicovaginal septum and a vaginal fistula (U2bC2V2) (Figure 1). We therefore performed the surgical resection of the cervical septum using scissors while the uterine septum was resected using hysteroscopic bipolar.



Conclusions

Because of the heterogeneity of this anatomic disorder, diagnosis can be delayed and patients suffer from the complications due to retrograde menstruations, such as pelvic inflammatory disease, endometriosis, infertility. Pre-operative explorations are sometimes insufficient because of distorted anatomy and the diagnosis is made during surgery. Reported experiences of this syndrome will help practitioners to perform the diagnosis and establish the basic management protocol since the goal of therapy appears to be to correct the obstruction as early as possible to preserve the reproductive function.

Outpatient novasure: patient experience and cost-effectiveness in a district general hospital in Manchester

Mousumi Sadhukhan¹, Olivia Aurangzeb¹

¹Stockport NHS Foundation Trust, Obstetrics and Gynaecology, Manchester, United Kingdom

Background

Novasure is a second-generation endometrial ablation for premenopausal women with heavy periods due to benign causes who completed childbearing. It is a well-established procedure under general anaesthetic (GA). In 2016, Stepping Hill Hospital, Stockport was one of the very few centres in England where the outpatient service was started. This study aims to determine patient experience of outpatient Novasure and explore factors that can affect pain perception which might help future patient counselling.

Methods

Survey methodology used to gather information from face-to-face interview using structured questionnaire from patients after having outpatient Novasure. All patients are advised to take pre-procedure analgesic and offered Entonox during the procedure. Every patient had intracervical local anaesthetic (LA) infiltration. Patients score their perceived pain during the procedure and 30 minutes after (if they used Entonox) on a Likert scale of 0-10 (0 being no pain and 10 being intense pain). Patient experience is explored by asking if they would recommend it to friend/family and if they would have preferred general anaesthetic (GA). Information on number of previous vaginal births is collected to explore any relationship to perceived pain. Intraoperative and post-operative complications are recorded. National Health Service tariff used to check cost-effectiveness of outpatient compared to inpatient procedure under GA. Simple statistical methods used for data analysis and T-test for significance tests.

Results

Between September 2016 and April 2023, 79 patients had outpatient Novasure performed by one consultant at Stepping Hill Hospital. The average pain score was 5.46 (SD 2.26) and 59% patients used Entonox during the procedure. Patients who did not have a vaginal birth experienced a pain score of 7.14 (SD 1.77) compared to 5.31 (SD 2.04) with one or more vaginal births (p-value 0.27). There was not much difference in pain experienced by patients who had 4 vaginal births (average pain score 5.33 (SD 1.97)) and those who had one vaginal birth (average pain score of 5.55 (SD 1.25)). Most patients agreed to recommend outpatient Novasure to friend/family and would prefer to have it under LA compared to GA in future. There were no intraoperative/post-operative complications. There is a cost saving of £997 per patient when done under LA compared to GA. The main limitations of this study were the small number and data from one consultant.

Conclusions

Outpatient Novasure is well tolerated by patients as majority agreed to recommend to friend/family and have it under LA in future in spite of an average pain score of 5.46. Patients with one or more vaginal births experience less pain compared to those without any previous vaginal births. Outpatient Novasure is safe and cost-effective. The next steps would be exploration of additional analgesia like fundal block which is routine in some centres.

Hysteroscopic metroplasty in an asymmetric septate uterus with a non-communicating blind cavity (Robert's uterus)

Ömer Erbil Doğan¹, Onur Yavuz¹, Asli Akdoğan¹, Eyuphan Özgozen¹

¹Dokuz Eylül University Faculty of Medicine, Obstetrics and Gynecology, Izmir, Turkey

Background

Robert's uterus is a rare uterine anomaly with a complete septate uterus and a blind ending functional uterine cavity, which may cause severe pelvic pain and dysmenorrhea from the beginning of menarche. We report a case of an adolescent girl with this anomaly presenting with severe symptoms who was diagnosed and conservatively treated with hysteroscopy.

Methods

The patient was a 15-year-old girl referred to our clinic because of severe primary dysmenorrhea and a pelvic mass. We performed a three-dimensional (3D) abdominal ultrasound and magnetic resonance imaging (MRI) in which there was a single uterus with a normal external fundal contour with 2 endometrial cavities. The right sided cavity was distended due to hematometra. There was a single cervical canal connected to the left side of the endometrial cavity. With these findings the diagnosis was an asymmetric septate uterus with a blind ending right functional endometrium. Informed consent for corrective surgery was obtained from the patient and her family.

Results

Hysteroscopic septum resection under transrectal ultrasound guidance was performed. During hysteroscopy, a longitudinal incision was made with a Collin's needle cautery to the septum, thereby the contralateral endometrial cavity was entered, and the right tubal ostium was visualized. After extending the incision to the level of cervical ostium and a unified uterus is obtained the procedure was completed. Postoperative period was uneventful, and the patient's symptoms were completely resolved. Three months later control MRI and 3D ultrasound showed a unified uterine cavity.

Conclusions

The European Society of Human Reproduction and Embryology–European Society for Gynaecological Endoscopy classification system categorizes this uterine anomaly as U2bC3V0, which means that there is a complete septate uterus (U2b), unilateral cervical agenesis (C3) and normal vagina (V0). In this case report we have shown that correct diagnosis of Robert's uterus can be made with 3D ultrasound and confirmed with MRI. Thereby, conservative hysteroscopic surgical treatment can be made. Primary aim of the surgery for this uterine anomaly is to eliminate the obstruction in the blind hemi-cavity to relieve the pain. Secondary aim must be to preserve the functional capacity of the uterus. Robert's uterus may be misdiagnosed as uterus unicornis with a non-communicating rudimentary cavity, thereby leading to unnecessary hemi-hysterectomy and reducing the future reproductive potential of these young patients. We conclude that combination of 3D US and MRI are adequate for the differential diagnosis and laparoscopy may be avoided. Hysteroscopic septum resection under transrectal US guidance must be the preferred method for surgery.

Can hysteroscopy be used to evaluate endometrioid carcinoma?

Juichiro Saito¹, Kaoru Tejima¹, Yoshiko Goseki¹, Mari Fukuoka¹
¹Juntendo Tokyo Koto Geriatric Medical Center, Gynecology, Tokyo, Japan

Background

Abnormal genital bleeding or endometrial thickening may indicate the presence of Endometrioid carcinoma. In some cases, benign endometrial polyps may be pre-operatively diagnosed but result in pathological histological diagnosis of endometrial cancer after hysteroscopic resection.

Methods

Between 2012 and 2022, our institution performed 1037 hysteroscopic surgeries, with 17 cases resulting in post-operative pathological diagnoses of Endometrioid carcinoma following pre-operative diagnoses of endometrial polyps.

We analysed pre-operative endometrial cytology, post-operative pathological histology, pre-operative flexible hysteroscopic findings and intra-operative rigid hysteroscopic findings performed on 17 cases. The results were evaluated using the Hysteroscopy Cancer Scoring System (HYCA). We examined the possibility of diagnosing endometrial cancer by hysteroscopic findings.

Results

Pre-operative endometrial cytology was performed in 15 out of 17 cases, with 2 patients having abnormal endometrial cytology.

Of the 15 cases in which pre-operative flexible hysteroscopy was performed, the examiner suspected intrauterine malignancy grossly in only 4 cases. In this examination allowed for HYCA evaluation in 11 cases. Although the HYCA tended to detect surface irregularities and abnormal vascular branching and distribution, three of the seven patients with post-operative pathological histology of endometrial cancer did not meet the diagnostic criteria of the HYCA.

Contrast the HYCA score for intra-operative rigid hysteroscopic findings with post-operative pathological histology, Endometrioid carcinoma was found to have at least 3 items in all cases. Two of the three cases of endometrial hyperplasia with atypia had at least three items. Simple endometrial hyperplasia with atypia had prominent vascular findings but no other findings.

Conclusions

Pre-operative endometrial cytology is a blinded test, and false-negative results can be obtained depending on the location and size of the lesion.

To pick up complex endometrial hyperplasia with atypia or worse, hysteroscopic endometrial biopsy should be performed with a pre-operative flexible hysteroscopy HYCA score of at least 2.

The HYCA is designed for the diagnosis of endometrioid cancer and does not cover complex endometrial hyperplasia with atypia. However, the HYCA has the advantage of being easy to apply in clinical practice because of its clear observation items and simple score tabulation.

In cases in which pre-operative hysteroscopic findings show multiple findings such as irregular tumour margins and abnormal vasculature, endometrial tissue biopsy should be performed with the possibility of endometrioid carcinoma.

The place of hysteroscopic septoplasty in ART

Laetitia Rousseau¹, Habran Cecile², Nisolle Michelle², Henry Laurie²
¹CHR Citadelle, Gynecology, Liège, Belgium
²Citadelle, Gynecology, Liege, Belgium

Background

The aim of this study was to determine the reproductive outcomes after HS of septate uterus of women undergoing intrauterine insemination (IUI) or in vitro fertilization/ intracytoplasmic sperm injection (IVF/ICSI).

Septate uterus is a malformation often found in women with poor reproductive history seeking assisted reproductive techniques (ART). This uterine anomaly can lead to infertility or recurrent pregnancy loss. Hysteroscopic septoplasty (HS) is a safe intervention to restore the uterine cavity surgically in such Mullerian anomalies.

Methods

This monocentric retrospective study included women with symptomatic septate uterus undergoing ART treatment after HS in our fertility centre.

Main outcomes were the pregnancy and first live birth rate after septoplasty. Further, the results were analysed depending on the need of IUI or FIV-ICSI.

Results

Thirty-six patients were identified with 3 lost to follow-up. The treatment has resulted in an overall pregnancy rate (PR) of 60% (20/33) and a cumulative pregnancy rate of 78% (26/33). The overall first live birth rate (LBR) is 39.4% (13/33) and the cumulative live birth rate is 48.4% (16/33). Eight patients out of the 33 used IUI resulting in 50% of pregnancies (4/8) and 25% of live births (2/8). For the women needing IVF/ICSI, the PR is 64% (25 patients with 16 pregnancies) and the LBR is 44% (11/25). It should also be noted that in 42% of the patients a male factor was involved in the infertility.

Conclusions

In our experience hysteroscopic septoplasty is a safe and effective procedure in patients presenting a symptomatic septate uterus prior to ART treatment. It might increase the reproductive outcome for both the IUI and the IVF/ICSI patients. However, the debate is still open whether to operate or not, pending prospective studies with more patients.

Pyometra in postmenopausal women, it's varied presentation and management: a case series

Sivanandana Korrapati¹, Anurada Subramaniam², Sakunthala Tirumuru²

¹Royal Wolverhampton NHS Trust- Wolverhampton- UK, Gynaecology, Wolverhampton, United Kingdom

²Royal Wolverhampton NHS Trust, Gynaecology, Wolverhampton, United Kingdom

Background

Pyometra is characterized by accumulation of pus in uterine cavity. It's reported incidence is 0.01% - 0.5%, increases with age. Main cause of pyometra is genital tract malignancy, prior pelvic radiation, in addition, benign conditions, specifically leiomyomas, endometrial polyps, congenital anomalies, occlusion of cervix after surgery and retention of IUD (intrauterine device), or idiopathic.

Methods

We present two cases who presented at New Cross Hospital which is gynaecology cancer referral centre. Our hospital protocol is to investigate thickened endometrium/bleeding in postmenopausal woman by hysteroscopy and endometrial biopsy based on underlying risk factors and endometrial thickness on scan.

Results

A 74-year-old lady was referred to gynaecology outpatients for abdominal bloating and mildly elevated Ca125. She has background of uterovaginal prolapse, has gelhorn pessary insitu. She reported no postmenopausal bleeding/discharge. Ultrasound (USS) pelvis confirmed endometrial thickness of 12mm & ovaries were not identified. She was referred to fast-track hysteroscopy. Hysteroscopy revealed pyometra with poor views. Drained pus, sent it for microbiology & taken pipelle biopsy. Removed pessary, given oral antibiotics for week. Histology revealed endometritis. Microbiological testing grew anaerobes & gram-negative bacilli. She had repeat hysteroscopy 8 weeks later, pyometra has cleared, endometrium appeared atrophic. Endometrial biopsy was repeated. Histology then showed chronic endometritis with no evidence of active inflammation as well as no evidence of hyperplasia, atypia or malignancy. Patient was reassured and discharged.

Case 2-72-year-old postmenopausal lady referred to gynaecology fast track clinic with postmenopausal bleeding intermittently for month associated lower abdominal cramps. History of hormone replacement therapy usage briefly many years ago. Her body mass index was 36. Incidentally, she was investigated year ago for postmenopausal bleeding. At that time, her initial pipelle biopsy was suspicious of endometrial cancer, however, repeat biopsy under general anaesthetic excluded cancer and she was discharged. When she attended for second time to fast-track clinic, she had pipelle biopsy which brought up purulent material. It was sent for microbiological testing as well as for histopathological examination. She was given 7-day course of Oral Co-amoxiclav. Histology revealed Grade 1 endometrioid endometrial adenocarcinoma in a background of atypical hyperplasia. She underwent total laparoscopic hysterectomy and bilateral salpingo-oophorectomy. Final histology confirmed endometrial adenocarcinoma.

Conclusions

Our case series has confirmed that etiology of pyometra can be either benign or malignant. There have been reported cases of pyometra in literature, were managed either conservatively with antibiotics or required major surgery, similar to cases mentioned in our case series. There are no evidence-based guidelines for management of pyometra, decisions about treatment and follow-up should be made on case-to-case basis.

We recommend repeating hysteroscopy/biopsy to ensure resolution of pyometra and to avoid missing possible diagnosis of endometrial cancer. Adequate patient education is key and patients should be encouraged to seek medical opinion if symptoms persist/recur.

Chronic endometritis and infertility - a case report

Marta Yague Medina¹, Sofia Fenoll Gil¹, Angela María Garcia de la Chica¹, Leticia Delgado Espárrago¹, Rocio Garcia Berrio¹, Álvaro Zapico Goñi²

¹Hospital Universitario Príncipe de Asturias, Gynecology and Obstetrics, Madrid, Spain

Background

Chronic endometritis is characterized by the infiltration of plasma cells in the endometrial stroma causing a chronic and continuous inflammatory process. It is mainly attributed to the presence of bacterial pathogens in the uterine cavity, although there is no consensus as to which the most frequent microorganism is. It is mostly asymptomatic, but it is a frequent cause of infertility.

Hysteroscopy is a fundamental test that can provide diagnostic suspicion, based on the presence of signs such as micropolyps, stromal edema or hyperaemia. Diagnosis is histological and immunohistochemical and involves identifying plasma cells by expressing the CD138 marker.

There is no established treatment regimen but Doxycycline is considered the standard treatment, with a cure rate of up to 94% in monotherapy. In case of histological confirmation, appropriate treatment and confirmation of resolution by subsequent hysteroscopy are required.

Methods

A review of the literature of recent years was carried out and the patient's clinical history has been accessed, obtaining her consent, in order to present a clinical case of chronic endometritis diagnosed and treated in our hospital.

Results

A 36-year-old female patient with no relevant personal history came to the Reproduction Department for infertility of two years of evolution, and in vitro fertilization treatment was indicated. After four failed embryo transfers, a diagnostic hysteroscopy was requested to complete the study of implantation failure. The hysteroscopy showed a proliferative endometrium with the presence of micropolyps, mainly on the posterior aspect. A directed biopsy was taken for anatomopathological study, with histological and immunohistochemical findings compatible with non-specific chronic endometritis, showing plasma cells and positive staining for CD138.

After the diagnosis of chronic endometritis associated with infertility, antibiotic treatment with a single dose of Ceftriaxone 500 mg administered intramuscularly and Doxycycline 100 mg/12 hours orally for 14 days was indicated. The diagnostic hysteroscopy was repeated two months after the end of treatment, visualizing a proliferative endometrium without the presence of micropolyps, and the cure was confirmed with a new biopsy.

With the result of chronic endometritis resolved, another cycle of in vitro fertilization was started and finally a pregnancy was achieved.

Conclusions

Chronic endometritis is a pathology with a high prevalence in infertile women, especially in those with repeated miscarriages or repeated implantation failures, so it is important to rule it out in patients with unfavourable reproductive history.

Hysteroscopy can provide suspicion of chronic endometritis by observing the uterine cavity and taking samples in a targeted manner, aiding in its diagnosis. Diagnosis and correct treatment are important since better live birth rates are obtained in those patients with cure after treatment than in those with persistent chronic endometritis.

Hysteroscopy in treating interstitial (cornual) pregnancy - a case report and review of literature

Razvan Socolov¹, Ioana Pavaleanu¹, Crauciuc Eduard¹, Tudor Butureanu¹, Mona Akad¹, Ana Apetrei²
¹University of medicine Gr T Popa Iasi, 3rd Obstetric and Gynecology Clinic, Iasi, Romania
²Hospital of Obstetrics and Gynecology Elena Doamna, Gynecology Department, Iasi, Romania

Background

Interstitial pregnancy refers to the implantation of the trophoblast in the interstitial portion of the fallopian tube, where the proximal tubal segment is embedded within the muscular wall of the uterus. The term "cornual pregnancy" is also widely used (but less preferred) to describe a pregnancy at this location.

Methods

Here, we report a 36-year-old woman who suffered a medical termination of pregnancy followed by abdominal pain, bleeding, and abnormal β hCG values. The ultrasound examination revealed a hyperechoic, well-vascularised eccentric intrauterine structure located near the tubal ostia, in the proximity of the serosa.

Results

Interstitial pregnancy was suspected and a hysteroscopy was performed. The hysteroscopic examination revealed trophoblastic tissue, which was removed via resectoscopy. The uterine wall was left intact, therefore there was no need for the laparoscopic guidance. Postoperatively, the evolution was favourable, with a resolution of symptoms and a progressive decrease of β hCG.

Conclusions

Interstitial ectopic pregnancy is a life-threatening condition associated with high morbidity. Prompt diagnosis and management are necessary in order to avoid complications and minimally invasive procedures are recommended if preservation of fertility is envisaged.

Retained products of conception: our experience and look into the future

Gregor Prša¹, Tamara Serdinšek², Branka Žegura Andrič²

¹General Hospital Murska Sobota, Department of Gynecology and Obstetrics, Murska Sobota, Slovenia

²University Hospital Maribor, General gynaecology and urological gynaecology, Maribor, Slovenia

Background

Retained products of conception (RPOC) occur in approximately 1% of all deliveries and their occurrence is even higher after miscarriages or pregnancy terminations. Their management is still challenging due to lack of evidence-based guidelines and treatment protocols. The aim of our study was to investigate management trends of RPOC, management success and prevalence of complications.

Methods

In this retrospective study, we included women treated in our gynaecology clinic because of RPOC after delivery, pregnancy termination or miscarriage. We included patients from the year 2003 to 2021 in three-year intervals.

For each patient, the following data were obtained and analysed: age, form of RPOC (after delivery, medical termination of pregnancy (MTP), surgical termination of pregnancy (STP), spontaneous miscarriage, medical treatment of miscarriage, surgical treatment of miscarriage), RPOC management (hysteroscopic removal, dilatation and curettage (D&C), medical treatment, expectant treatment), treatment complications, success rate of primary treatment, histopathological examination results, and need for blood transfusion.

Results

We included 590 women. Their average age was 31.6±6.2 years (range 16–44 years). Most RPOC occurred after MTP (38%). A statistically significant decrease in D&C with increase in other less invasive treatment options can be observed throughout the years ($p<0.001$). Only 9.7% of women needed secondary treatment due to failure of the first treatment option. As a primary treatment, dilatation and curettage was successful in 94.3%, hysteroscopic removal in 96.9%, medical management in 58.6%, and expectant management in 79.2%.

While 88.2% of women did not experience any complications, the complications that did occur were mild. Complication rate and number of blood transfusions did not increase throughout the years. Histopathological examination report was available for 257 women. RPOC were confirmed in 86.8% of cases and there was one case (0.4%) of partial molar pregnancy.

Conclusions

Our study shows that our transition to less invasive treatment of RPOC was not associated with increased complication rate. According to our results, hysteroscopy is a highly effective option of surgical treatment. Literature shows that it also carries a smaller risk of complications compared to D&C. In conclusion, minimally invasive treatment of RPOC is plausible, especially for treatment of asymptomatic patients. Hysteroscopic, medical, and expectant management of RPOC offer the advantage of outpatient treatment, avoid the need for general anaesthesia, reduce the cost of treatment, and decrease the probability of intrauterine adhesions formation.

Differences in pain perception during hysteroscopic morcellation at our center: a retrospective cohort study

*Sofía Fenoll Gil¹, Gabriel Molinero Mena¹, Marta Yagüe Medina¹, Rocío García Berrio¹,
Leticia Delgado Esparrago¹, Álvaro Zapico Goñi¹*
¹Hospital Príncipe de Asturias, Gynecology and Obstetrics, Madrid, Spain

Background

Kalinox is a mixture of nitrous oxide 50% and oxygen 50% which is indicated for short-term painful operations. Although it belongs to the analgesic group, at this concentration it has no anaesthetic effect.

In 2017, a randomized clinical trial at Hospital Príncipe de Asturias showed that the overall pain assessment obtained with the use of nitrous oxide during hysteroscopies showed significant differences compared to patients in whom no analgesic technique was used.

The aim of this study was to evaluate the effects of analgesic medication on pain reduction during the hysteroscopic morcellation procedure from January 2020 to May 2023.

Methods

Observational retrospective cohort study including women underwent hysteroscopic morcellation at the Hospital Príncipe de Asturias in Madrid. The main outcome was the measurement of pain during the morcellation process according to the use or non-use of Kalinox as an analgesic method. A total of 163 patients who experienced hysteroscopic morcellation during this time period were asked about pain as measured by the visual analogue scale (VAS score). Patient characteristics such as age, menopausal status, indication for hysteroscopy, parity, duration of hysteroscopy and complications were collected in a database.

Results

104 patients were given Kalinox as analgesia, while 59 women did not receive analgesia, either because they refused it or because they were not offered nitrous oxide due to SARS-COV2-related restrictions.

The percentage of premenopausal and postmenopausal women in the Kalinox-treated group was 57.7% vs. 42.3%. Up to 15 (14%) were nulliparous, and of the remainder, 75 has previously experienced a vaginal delivery. While the group that did not receive analgesia, 57.6% of them were postmenopausal and 42.3% premenopausal. The number of nulliparous women in this subgroup was 12 (18%) and of women with a history of vaginal delivery 40.

The most prevalent indication for hysteroscopic morcellation was endometrial polyp 129 (79.1%). Indications such as endometrial alterations (12.2%), abortive remnants (6.1%) submucous myomas (1.8%) and uterine malformations (0.6%) were also described.

18 intraoperative complications were reported, in which 66.7% occurred among women who used Kalinox and 33.3% among those who did not. The complications described were major bleeding (50%), cavitory collapse (39%) and vasovagal response (11%). In 11 of them the technique could not be completed successfully.

Statistically significant differences in pain management were found between the two procedures ($p=0,032$). The mean perceived pain in VAS score in the Kalinox group was 3.53 versus 4.32 in the no analgesia group. No subgroup analysis was performed.

Conclusions

This study shows that there are differences in the pain experienced during hysteroscopic morcellation by prior administration of Kalinox. However, a subgroup analysis should be considered in this cohort to provide further conclusions.

Atypical adenomatous polyp - a case report

Marta Yague Medina¹, María Teresa Buergo Ramírez¹, Sofía Fenoll Gil¹, Leticia Delgado Esparrago¹, Rocio Garcia Berrio¹, Álvaro Zapico Goñi²

¹Hospital Universitario Príncipe de Asturias, Gynecology and Obstetrics, Madrid, Spain

Background

Atypical adenomatous polyp (AAP) was first described as a rare, focal polypoid lesion, usually occurring in premenopausal women. The most common symptom is abnormal uterine bleeding. It has a glandular component of complex architecture and cytologically atypical that could be confused with a well-differentiated endometrial adenocarcinoma.

The pathogenesis of this lesion is unknown. Many authors consider it to be a non-neoplastic proliferation, possibly secondary to prolonged estrogenic stimulation of a stromal endometrial progenitor cell. However, a systematic review by Raffone et al. including 11 retrospective studies with a total of 237 patients, shows that AAP coexisted with atypical hyperplasia in 5.5% of cases and with endometrial cancer in 5.9%.

Over the years, cases of AAP associated with, or even anticipating, complex endometrial hyperplasia with and without cytologic atypia, as well as with endometrial adenocarcinoma and even endometrioid adenocarcinoma have been described. For all these reasons, it has been suggested that APA is a preneoplastic lesion.

Methods

A review of the literature of recent years was carried out and the patient's clinical history has been accessed, obtaining her consent, in order to present a clinical case of atypical adenomatous polyp diagnosed in our hospital.

Results

A 33-year-old woman, with 45 BMI and nulligesta, consulted for abnormal uterine bleeding with hypermenorrhoea. On examination, a 4 cm exocervical polyp was visualized and removed by torsion. A transvaginal ultrasound was performed in which a somewhat irregular 12mm endometrium was visualized, and an endometrial biopsy was performed.

Both samples were sent for histological study. The result of the exocervical polyp was: AAP with foci of metaplasia. The result of endometrial biopsy was: foci of complex endometrial hyperplasia with atypia and fragments suggestive of AAP with squamous metaplasia.

Since the patient has not fulfil her reproductive wishes, a conservative treatment with progesterone is agreed with her. A hysteroscopy was performed to morcellate the entire polypoid uterine cavity to complete the study and an intrauterine device was subsequently placed. Despite hormonal treatment, after 6 months, progression to endometrial carcinoma of endometrioid pattern, well differentiated, papillary pattern, was observed in a wide sample taken by hysteroscopy. Pelvic MRI reports FIGO stage IA endometrial neoplasia. Finally, surgical treatment was agreed and a simple hysterectomy (infiltrates <50% of endometrial thickness) with double adnexectomy and bilateral pelvic sentinel node (negatives) was performed.

Conclusions

The importance of AAP lies in the fact that more and more studies have demonstrated its malignant potential and a possible relationship with atypical endometrial hyperplasia and endometrial cancer, as in our case.

The decision on treatment will depend on the age of the patient, the desire for pregnancy and the individual circumstances of each patient, and it is essential to perform a hysteroscopy to confirm the characteristics of the lesion and its complete resection.

Are mechanical tissue removal systems the best tool to remove submucosal fibroids and treat heavy bleeding?

Nancy Noah¹, *Mihai Gherghe*¹, Mohammed Allam¹

¹University Hospital Wishaw, Gynaecology, Glasgow, United Kingdom

Background

In 2009, the FDA approved MyoSure tissue removal system (Hologic, MA) as a suitable hysteroscopic tissue removal system for treating submucous fibroids. Myosure (Hologic, MA) is characterized by being rapid, safe, suitable for outpatient treatment with a short learning curve. The procedure carries less risk of complications compared to loop resection devices.

Objective

To evaluate the clinical effectiveness of hysteroscopic submucosal myomectomy for Figo Type 0, 1 and 2 fibroids using tissue removal device (MyoSure) in outpatient setting.

Methods

The data was collected prospectively in accordance to NICE recommendation for safe practice, from January to December 2021 from outpatient clinics in a single University Hospital in NHS Lanarkshire. A total of 30 women treated by 4 different gynaecology Consultants training and experience in outpatient operative hysteroscopy. Hysteroscopic myomectomy was performed using tissue removal device (MyoSure) in outpatient setting under local anaesthetic for Figo Type 0, 1 and 2 submucosal fibroids and patients were followed up for a minimum of 12 months.

Results

The average age of women at treatment was 46. 24 women out of 30 were symptomatic of heavy menstrual bleeding, 5 patients were referred with intermenstrual bleeding and one had an incidental finding on scan. 87% of patients had the procedure done under vaginal Instillagel analgesia only with a mean pain score of 3. The mean operative time was 16 minutes and there were no intra or post-operative complications. In 27 women (90%) the fibroid was successfully removed to the level of endometrium in one clinic appointment. The largest fibroid was estimated at more than 3cm with majority of fibroids measuring 1-3cm. Bleeding resolved in 23 women (77%) with no further referral to gynaecology clinic up to current date. There was no malignancy diagnosed on pathology analysis.

Conclusions

Hysteroscopic myomectomy using MyoSure is an effective tool for removal of submucous fibroids allowing complete resection of Type 0 fibroids and partial to complete resection in Type 1 and 2 fibroids. The procedure is safe with no recorded post-operative complications and is well tolerated in outpatient setting. Given adequate ultrasound screening prior to procedure, the risk of disseminating a malignancy in this age group is low. Resolution of bleeding in 77% of patients represents a significant change to quality of life and avoidance of higher risk procedures such as hysterectomy.

Surgical management of Isthmocele – our results and complications

Branka Verdnik Golob¹, Ana Ranc¹, Helena Šavc¹

¹General Hospital Slovenj Gradec, Department of Gynecology and Obstetrics, Slovenj Gradec, Slovenia

Background

The incidence of caesarean section (CS) has increased in past decades in most regions of the world up to 20% and more. One to three quarters of these patients may develop a defect in uterine scar or isthmocele as the consequence of incomplete healing, which is the further reason for associated gynaecological complications as intermenstrual spotting, dysmenorrhoea, dyspareunia, chronic pelvic pain and infertility. Surgical treatment of isthmocele can produce further iatrogenic consequences. Our aim is to represent our results of surgical treatment in symptomatic women with an emphasis on complications.

Methods

The isthmocele was evaluated clinically with transvaginal ultrasound and hysteroscopy in 24 patients between 2017 and 2022. 15 patients underwent hysteroscopic surgery, in 9 patients laparoscopic isthmocele operation was performed. The cut off value for hysteroscopic resection was residual myometrium thickness (RMT) ≥ 2 -3mm and < 2 -3mm for laparoscopic operation. The results were evaluated after 1 and 3-6 months and later (after 1-3 years).

Results

9 patients underwent hysteroscopic surgery were free of symptoms, in 2 patients results were not known, but they have not returned with symptoms; 1 patient complained of occasional intermenstrual spotting with cervicitis but was free of pain. In 1 patient the stenosis of cervical canal and firm adhesions of isthmus region of uterus were diagnosed 3 years after hysteroscopic surgery with the symptoms of dysmenorrhoea and hypomenorrhoea, hysteroscopic adhesiolysis and dilatation of cervical canal were performed, the result of treatment is awaited. Hysteroscopic treatment was unsuccessful in 3 patients, after almost one-year laparoscopic hysterectomy was done. 8 patients after laparoscopic surgery are asymptomatic with improved residual myometrium, 1 patient in this group also complained of occasional intermenstrual spotting with cervicitis, medical treatment was successful. One patient suffered a minor bladder injury without consequences.

Conclusions

Hysteroscopic and laparoscopic procedure are efficient and, in most patients, safe methods of treatment for women with symptomatic isthmocele. Accurate assessment of patients and good preoperative preparation are crucial for good treatment results. Patients need to be given complete information before treatment decision is made, including immediate and late possible complications.

Fertility sparing treatment in patient with early-stage endometrial cancer

Milena Petrovic¹, Konstantinos Lamprou¹

¹University College London Hospital, Gynaecology, London, United Kingdom

Background

Introduction

Endometrial cancer is one of the commonest gynaecology cancers with 4% of women being younger than 40 years and over 70% nulliparous¹. Fertility sparing techniques are still not widely used, and usually include medical management (levonorgestrel-LNG intrauterine system (IUS) with/without oral medroxyprogesterone acetate) rather than operative hysteroscopy with adjuvant progestogens. We're presenting the case of fertility sparing surgery in patient with early-stage endometrial cancer.

Methods

Clinical Description

Young nulliparous woman with BMI >30kg/m² was referred with a history of irregular and postcoital bleeding over the several months. Transvaginal ultrasound showed thickened, echogenic, cystic endometrium, and endometrial biopsy confirmed the atypical hyperplasia with a focus of early grade 1 endometrioid adenocarcinoma. There was no myometrial invasion nor further spread visualised on MRI. Hysteroscopy showed abnormal endometrium with polypoid appearance. Careful complete excision with basal layer preservation was performed using resectoscope and levonorgestrel intrauterine system (IUS) was inserted. Follow up hysteroscopy with endometrial biopsy was scheduled in 3 months' time. **Results**

Discussion

Laparoscopic hysterectomy and bilateral salpingo-oophorectomy are the surgical technique of choice for women with early stage endometrial cancer². Conservative management is still uncommon. Hysteroscopic resection with adjuvant progestogen is associated with significantly higher regression rates (98.06%), better live birth rates (52.57%) and lower recurrence (4.79%) than progestogens alone (77.20%, 33.38%, and 32.17% respectively)³

Conclusions

Conclusion

There is increasing requirement in fertility sparing techniques especially in view of the rising age of the first conception⁴ and its increasing risks of cancer. Available evidence is showing promising success rates; however, use of fertility sparing treatment is still infrequent and requires further research and guidelines development.

For caesarean scar pregnancy, hysteroscopic surgical intervention could be a successful treatment modality with evidence of complete resolution and no need for any additional intervention

Ruvana Tabassum¹, Amna Malik¹, Raphael Laiyemo¹

¹Sherwood Forest Hospitals NHS Foundation Trust, Obstetric and Gynaecology, Mansfield Road- Sutton-in-Ashfield, United Kingdom

Background

Background and Objectives: Caesarean scar pregnancy is described as implantation of pregnancy into the myometrium of a dehiscence scar secondary to previous caesarean section and represents a potentially life-threatening situation. The purpose is to present a case of caesarean scar pregnancy that was managed successfully by hysteroscopic surgical intervention with evidence of complete resolution of caesarean section niche which was confirmed by a follow up pelvic scan as well as undetectable Bhcg after 4 weeks postsurgical intervention with no additional intervention.

Methods

Case Presentation: A rare case of caesarean scar pregnancy in a 33-year-old gravida 4 para 3, woman with a history of 3 previous caesarean sections and 1 miscarriage, had transvaginal ultrasound with a history of 7 weeks amenorrhoea. Ultrasound scan showed caesarean section scar ectopic pregnancy with rising serum Bhcg (442,986,8497,7848). In view of the severity of condition, treatment was offered as soon as the diagnosis was confirmed without delay. As she was haemodynamically stable, we discussed in detail about medical treatment with methotrexate systemically and/or local injection or surgical treatment with aim of preservation of future fertility. As per her wishes, Hysteroscopic excision of caesarean section scar ectopic was performed by resectoscope with the repair of the caesarean section scar niche under laparoscopic guidance, using the technique describe by Chang et al and fabres et al as it offers both removal of the ectopic pregnancy and simultaneous treatment of the caesarean section niche.

Results

She was discharged from hospital after hysteroscopic surgical intervention for caesarean scar pregnancy without any postoperative complications with evidence of gradual drop in serum Bhcg levels (2411,117,10.9) along with complete resolution of caesarean section niche at 4 weeks follow up pelvic scan without any additional intervention.

Conclusions

A wide variety of treatment modalities are available for the management of caesarean scar pregnancy but there is no definite consensus about which option is best. The management needs to be individualised, as in our case, serum Bhcg normalised after appropriate surgical intervention of resectoscopic excision of Type1 (endophytic) caesarean scar ectopic under laparoscopic guidance without further intervention. We were able to diagnose her case of scar ectopic pregnancy promptly and subsequently managed successfully without any intraoperative or postoperative complications. However, we feel as demonstrated by this case that hysteroscopic resection should be used as first line treatment option in haemodynamically stable patient with myometrial thickness more than 3mm between the base of the niche and the uterine serosa wall anteriorly as it is less invasive than laparoscopic technique especially as it also offers treatment of the niche simultaneously.

Juvenile polypoid adenomyoma

Pierre Carvelli¹, Marie Timmermans¹, Michelle Nisolle¹
¹Citadelle- CHU Liège, Gynécology-Obstetrics, Liege, Belgium

Background

Polypoid adenomyoma (PA) is a rare uterine endometrial polypoid tumour of mixed epithelial and mesenchymal origin, composed of atypical endometrial glands along bundles of smooth muscle fibres.

If clinical and pathologic features of PA have been well described and is characterized by irregular vaginal bleeding in women of reproductive age, imaging findings for these tumours have not been frequently reported in the literature.

PA has the potential of malignant transformation but does not metastasize. Diagnosing PA is important because it impacts the quality of life. It can be managed by hysteroscopic resection, unlike an ordinary form of adenomyosis.

The pathophysiology of juvenile cystic adenomyosis is uncertain. Some authors consider this juvenile variant as a rare cystic form of adenomyosis, while others suggest that it is a congenital malformation caused by a developmental defect of the Müllerian duct and that estrogenic stimulation of the Mullerian remnants leads to severe dysmenorrhea.

Methods

We describe a case of juvenile PA in a 17-year-old adolescent girl presenting with menorrhagia and dysmenorrhea lasting for 20 months. A complete medical check-up did not explain this condition. The heavy bleeding period led her to a severe anaemia which required blood transfusion. MRI performed in an external centre only described a possible uterine septum. The patient was not sexually active and had a hormonal oral 5 mg no megestrol acetate with moderate relief of her symptoms. She had no therapeutic proposal and was asking for another medical opinion.

Results

At our Physical examination: PA was visible and tangible like an intravaginal mass.

The review of MRI revealed a structure inserted on the anterior wall of the uterus and delivered through the cervix. This observation was confirmed by diagnostic hysteroscopy. No haemorrhagic cystic aspect was found, contrary to usually described features of PA.

At the operative hysteroscopy, the intra cervical pedicle was cut. Adenomyosis crypts were visible at the insertion area which was resected with bipolar loop. The rest of the cavity is normal. Macroscopic aspect was unusual, and histopathology described a PA.

After resection by hysteroscopy the young patient did not suffer from abnormal bleeding anymore.

Conclusions

PA is a rare condition with potential severe consequence. Imaging interpretation is crucial and must be called into question when it do not match with the clinic.

Hysteroscopy is adequate to cure PA, but as there is a high incidence of recurrence, a clinical follow up with ultrasound or MRI should be realized in case of abnormal bleeding.

Evaluation of pain in patients undergoing diagnostic hysteroscopy at a gynaecological endoscopy teaching outpatient clinic

Danielle Costa Nazareth¹, Gustavo Barison¹, Mariano Gomes¹, Nicole Oliveira¹, Carolina Resende¹, Debora Fonseca¹

¹Hospital Israelita Albert Einstein, Gynecology and Obstetrics, São Paulo, Brazil

Background

To assess the intensity of pain during hysteroscopy examinations in patients treated at a gynaecological endoscopy teaching outpatient clinic.

Methods

A total of 1556 patients who underwent hysteroscopy examination were evaluated, of whom 761 responded to the assessment of pain intensity during the procedure. Data were collected through a review of patient records from September 2019 to March 2020, after approval by the institution's Research Ethics Committee. The procedure was performed by residents and experienced gynaecologists using a rigid hysteroscope and warm saline solution without analgesia or anaesthesia, without vaginal speculum. The Visual Analog Scale (VAS) was used to evaluate pain threshold, along with individual clinical, anatomical, and imaging data.

Results

The most prevalent indications for hysteroscopy were endometrial thickening and polyps, accounting for over 70% of cases. Polyps were described in 50.8% of cases, fibroids in 7.7%, and synechiae in approximately 6%, as reported in the examination reports. The mean age was 54 years, with a significant sample of menopausal women, approximately 60%, which could explain greater difficulties during the examination due to hypoestrogenism and consequently, lower pain tolerance. Nonetheless, the median VAS score reported by the participants was 4.0, consistent with Brazilian literature and not significantly different from European studies. In order to correlate the variables studied with the variation in pain intensity during hysteroscopy, a cross-analysis was conducted between these variables and the VAS score. Considering statistically significant results, patients with a straight cervical canal had an estimated 21.3% lower pain score (0.787-1) compared to those with a tortuous canal. Patients with decreased uterine volume had an estimated 20.2% higher VAS score (1.202-1) compared to those with normal volume. Lastly, patients with reported polyps had an estimated 13.5% lower pain score (0.865-1) than those without polyps.

Conclusions

Hysteroscopy is a valuable procedure for the diagnosis and treatment of various gynaecological conditions. Despite many studies assessing ways to manage pain during the examination, pain remains the main reason for discontinuation of the procedure. Therefore, it is essential for gynaecologists to be able to plan measures aimed at improving the chances of success. To achieve this, it is fundamental to understand pain as a multifactorial subjective sensation, through prospective studies that respect the individualities of each population of women.

The use of augmented reality and objective metric tracking in hysteroscopy training: a proposed study summary

David Rawaf¹, Rebecca Mallick²

¹NHS / Inovus Medical, Clinical Excellence, London, United Kingdom

²University Hospitals Sussex NHS Foundation Trust- St Richards Hospital- Chichester, Surgery, Haywards Heath, United Kingdom

Background

The objective of this study is to evaluate the effectiveness of augmented reality (AR) and objective metric tracking in improving hysteroscopy training outcomes. Specifically, the study aims to assess the impact of simulation-based training on surgical confidence and objective surgical skills of trainees, and to explore the feasibility of integrating simulation training into the Obstetrics and Gynecology (O&G) curriculum. Latest TEF (Training Evaluation Form) survey published in 2021 suggested 18.8% and 50.2% of trainees had not met their basic and intermediate surgical competencies. 46% trainees felt they had no had adequate exposure and experience in outpatient procedures.

Methods

A cohort of 10 trainees with varying experience and expertise, including nurse hysteroscopists, will participate in the study. The initial data collection will involve the use of an augmented reality platform for hysteroscopy training. Each trainee will dedicate 5 hours of training on the augmented reality system over a 4-week period. The training exercises will be repeated at the end of the period. Trainees will also assess their own skills, hand-eye coordination, and confidence using Likert scales.

Results

The study will analyse the impact of augmented reality training on surgical confidence and objective surgical skills of the trainees. Objective metrics will be tracked to measure improvements in skill performance. Additionally, self-assessment scores provided by the trainees will be analysed. The results will be presented, highlighting the potential benefits of augmented reality and objective metric tracking in hysteroscopy training.

Conclusions

Simulation-based training using augmented reality and objective metric tracking holds promise for improving hysteroscopy training outcomes. By integrating such training methods into the O&G curriculum, it may be possible to bridge the gap between trainees' surgical competencies and the requirements of this common surgical procedure. The findings of this study contribute to the evidence supporting the integration of simulation training in hysteroscopy education, with the potential to enhance surgical outcomes and patient experience.

Hysteroscopic diagnosis of endometrial cancer using the grasp technique or tissue removal device. Comparison of two minimally invasive approaches

Maria Chiara De Angelis¹, Anna Michela Pacilio¹, Mario Ascione¹, Danilo Borrelli², Alessandra Gallo¹, Brunella Zizolfi¹

¹University of Naples Federico II, Department of Public Health, Naples, Italy

Background

The aim of our study is to investigate the diagnostic accuracy of hysteroscopic biopsy performed with miniaturized instruments comparing the grasp technique to the tissue removal device one, in an office setting for evaluation of histotype and grading of Atypical Endometrial Hyperplasia (AEH) and Endometrial Cancer (EC).

Methods

This was a retrospective study conducted on 38 women affected by AEH and EC and treated at our Department from January 2020 to December 2022. We included in a dedicated database the patients' information from the time of diagnosis until the date of hysterectomy. All the patients underwent office hysteroscopy performed by vaginoscopic approach, followed by a targeted biopsy using the grasp technique or the "visual D&C" as a diagnostic procedure, and received total hysterectomy as final treatment. "Visual D&C" consisted of a type of atraumatic curettage performed using Tissue Removal Device (TRD).

Results

In all cases the endometrial specimen obtained in office setting with both grasp technique or visual D&C was adequate for an histological evaluation.

Among the 38 cases, 16 biopsies were performed using the grasp technique, the other 16 were performed with tissue removal device. An agreement of 100% (38/38) was obtained for the histotype in both groups.

Among the TRD group, regarding tumour grade, the concordance between preoperative and postoperative findings was lower for the G3, while for G2 and G1 biopsies we obtained an agreement rate of 50% (1/2 cases) and 60% (3/5 cases) respectively. We found the highest concordance (5/8 cases, 62,5%) in case of AEH. Of 3 samples originally graded as AEH, 3/8 (37,5%) were upgraded to G1. In two cases G1 was upgraded to G2, while 1 G2 was downgraded to G1. No cases of G3 were downgraded to G1 and only 1 G3 was downgraded to G2.

In the group of patients where grasp technique was used, the concordance between preoperative and postoperative findings was lower for the G1 (1/2 cases, 50%), while for G2 and G3 biopsies we obtained an agreement rate of 75% (3/4 cases) and 80% (4/5 cases) respectively. We found the highest concordance regarding AEH (4/5 cases, 80%). Of 5 samples originally graded as AEH, one was upgraded to G1. In one case G1 was upgraded to G3, while the only G2 was upgraded to G3; regarding G3, 1 was downgraded to G1.

Conclusions

According to our findings, preoperative hysteroscopic-guided "grasp" biopsy and "visual D&C" technique allow an adequate amount of tissue available for examination to be taken, in order to provide a correct histotype diagnosis.

Moreover, our preliminary results demonstrate a high degree of concordance between the preoperative histological diagnosis on hysteroscopic guided biopsy and the postoperative one on hysterectomy specimen in EC in both groups.

When surgery is not the solution: what happens if uterine sparing is the only option?

*Maria Chiara De Angelis¹, Mario Ascione¹, Anna Michela Pacilio¹, Giuseppe D'Angelo¹, Brunella Zizolfi¹,
Alessandra Gallo¹*

¹University of Naples Federico II, Department of Public Health, Naples, Italy

Background

To assess the effectiveness of conservative treatment in women diagnosed with atypical endometrial hyperplasia (AEH) or G1 and G2 endometrioid endometrial carcinoma (EEC) not eligible for surgery due to a high anaesthesiologic risk.

Methods

A prospective observational study was conducted at Hysteroscopy Unit, Department of Gynecology and Obstetrics of University of Naples "Federico II". Patients with histological diagnosis of AEH and G1 or G2 EEC, obtained by office hysteroscopic grasp biopsy, not eligible for demolitive surgery, were enrolled.

American Society of Anaesthesiologists classification of physical status (ASA PS) was used for categorizing the preoperative status of women. After careful counselling, conservative treatment was offered to patients belonging to ASA Classes III, IV and V. All patients signed a specific informed consent for Conservative Treatment. It consisted of endometrial resection using the "visual D&C" or the "Three Steps technique", depending on whether we had a diffuse or focal lesion respectively. At the end of each treatment, a levonorgestrel-releasing intrauterine system (IUS) was inserted into the cavity.

Patients' information was included in a dedicate database from the time of diagnosis until the last follow -up. Multiple office hysteroscopic endometrial biopsies were performed with IUS in situ, at 3,6,12 and 24 months follow-up. Rate of response was assessed and classified as: Complete Response, Partial Response, Stable Disease and Progression.

Results

Forty-one patients were included, 35/41 belonged to an ASA Class of 3 to 5; 6/41 refused surgery in order to preserve their reproductive potential. Thirty-two out of 41(78%) were diagnosed with AEH, 8/41(19.5%) with G1 EEC, 1/41(2.5%) G2 EEC. Only three patients underwent the three-step technique, 38/41 underwent visual D&C with tissue removal device.

At 3 months follow-up, 34/41(82,9%) patients achieved a Complete Response, 7/41 (17.1%) patients were non-responders (3 stable disease and 4 progression). At 6 months follow up, 29/41(72.5%) patients had a Complete Response, 2/41(5%) a Partial Response, 4/41 (7,5%) had a progression. Six patients have not yet achieved the six-months follow up. Only one patient died after the 6 months follow up. At 12 months follow up, 23/40 (57,5%) achieved a Complete Response, 2/40 (5%) patients had a progression, 15/40 (37,5%) patients have not yet performed the 12 months follow up. At 24 months follow up, 16/40 (40%) had a Complete Response, no patients had progression, 24/40 (60%) patients haven't reached this step yet.

Conclusions

Although surgery remains the gold standard treatment for EC, conservative approach can be a feasible alternative for patients not eligible for surgery, not only in the fertility sparing approach. According to our results, disease-free rate using conservative treatment is reasonable in these patients. Further results are required to confirm these preliminary data.

Tunnel clusters, a rare type of nabothian cysts

Julie Alaert¹, Antonino Buonomo²

¹Gynecology, Chu tivoli, La Louvière, Belgium

²Chu tivoli, Gynecology, La Louvière, Belgium

Background

The differential diagnosis of a mass involving the uterine cervix are the followings: cervical polyp, leiomyoma, lymphoma, invasion from a uterine or vaginal malignancy, adenoma malignum, metastases to the cervix and cervical ectopic pregnancy. Clinical exam and complementary exams as colposcopy and imaging methods and biopsies should complete the diagnostic steps. Nabothian cysts are benign and very common among women in reproductive age; they are filled with mucus secreted by cervical glands and are present at the surface of the uterine cervix. They communicate between the vagina and the uterus. When mucus is stagnating inside the cyst, they can grow and cause symptomatology but frequently they are not relevant and have no clinical significance. Tunnel cluster is a type of nabothian cyst and is a benign pseudoneoplastic glandular lesion of the cervix. It can be characterized by non cystic (type A) and cystic (type B).

The main objective of this case report is to update the evidence in the literature concerning unusual presentation of nabothian cysts and their differential diagnosis.

Methods

A Case reports.

Results

A nulliparous 34-year-old female with abnormal uterine bleeding using an oestrogen-progestative contraceptive pill. On physical examination, a cervical necrotic mass was found. The ultrasound reported a cervical mass of 2cm not communicating with the uterine cavity. Magnetic resonance imaging confirmed the development of an anterior cervical mass of 22mm, with regular borders, T2 weighed signal not typical of carcinomas but presents a restricted diffusion, which is highly suspect. Cervix biopsies and endometrial curettage resulted in haemorrhagic a necrotic tissue and were negative for carcinoma. Hysteroscopy was performed finding two openings in the cervix. The anterior opening lead to a little cavity. The central orifice lead into the uterine cavity, which appeared normal. We decided to perform biopsies in the little anterior cavity and the histopathological reported haemorrhagic and necrotic tissue without evidence of malignancy. We concluded that the cervical mass is probably a Nabothian cyst that ruptured into the anterior part of the cervix. A follow up by magnetic resonance imaging is scheduled in 3 months.

Conclusions

Nabothian cysts are benign and usually of no clinical significance but can sometimes present in an atypical form and be considered as a suspicious mass, therefore complementary exams as colposcopy, MRI, and hysteroscopy and biopsies can help to exclude malignancy.

Hysteroscopic treatment of Robert's uterus under ultrasound guidance- case report

Zsolt Farkas¹, Beáta Vida¹, Szabolcs Molnár¹, Zoárd Tibor Krasznai¹

¹University of Debrecen Faculty of Medicine, Obstetrics and Gynecology, Debrecen, Hungary

Background

Robert's uterus is a quite rare müllerian anomaly, there are only a handful case report about it in the literature so far. It is actually an asymmetric form of the septated uterus and it has a complete uterine septum that split the uterine cavity asymmetrically from the fundus up to the internal cervical ostia. As result of this anomaly the uterus has two hemi-uterine cavities a non-communicating hemi-uterine cavity and another hemi-uterine cavity with unicorn uterus appearance, meanwhile the uterus has a normal external morphology. Patient suffering from Robert's uterus probably has dysmenorrhoea caused by the hematometra in the blind hemi-uterine cavity, endometriosis and recurrent pregnancy loss. To diagnose this anomaly the MRI is the best diagnostic tool in the coronal view, however 3D ultrasound can provide similar diagnostic accuracy. According to the literature one of the best treatment options is hysteroscopic septum resection under ultrasound guidance. Our objective is to present a case of a 13 years old girl, who suffered from Robert's uterus and treated with hysteroscopic septum resection under ultrasound guidance.

Methods

A 13 years old girl visited our paediatrics and adolescent gynaecology outpatient care with severe dysmenorrhoea. We performed a transabdominal ultrasound examination resulting müllerian anomaly with two hemi uterine cavities containing a hematometra in the right one. We sent the patient to MRI and the result was Robert's uterus. To treat the pain symptoms of the patient we performed the hysteroscopic septum resection under ultrasound guidance. Before the surgery we discussed the advantages and the possible consequences of this approach with the patient and her parents.

Results

After the surgery the patient's pain symptoms vanished and her quality of life improved significantly.

Conclusions

Robert's uterus can cause severe symptoms (dysmenorrhoea, recurrent pregnancy loss, endometriosis) which can deteriorate the patient's quality of life. To diagnose this anomaly MRI in coronal view is the method of choice. Hysteroscopic septum resection under ultrasound guidance is an optimal minimal invasive approach to treat this rare müllerian anomaly.

Clinical and microbiological characteristics and features of hysteroscopic intervention in cases of infertility and intrauterine pathology

Iryna Yarmola¹, Anna Novosad²

¹*Danylo Halytsky Lviv National Medical University,*

Department of Obstetrics- Gynecology and Perinatology- Faculty of Postgraduate Education, Lviv, Ukraine

²*Oberig clinic, Women's health department, Kiev, Ukraine*

Background

One of the main problems determining the demographic situation in society is infertility. According to the latest data from the World Health Organization, the incidence of infertile marriages among couples of childbearing age ranges from 10 to 15 percent and has a steady upward trend. It is known that today, the uterine factor in the structure of female infertility occupies a prominent place and can reach 30%. The most common pathological conditions of the uterus are hyperplastic processes of the endometrium. The study of various aspects of the pathogenesis of hyperplastic processes of the uterus is one of the main in modern medicine. In the structure of intrauterine pathology, according to the literature, chronic endometritis is more than twice the prevalence of other diseases. Modern diagnostic methods, which include, ultrasound and endoscopy, allow to detect and treat various pathological processes in the uterine cavity with high accuracy.

Methods

increasing the effectiveness and prevention of complications of hysteroscopic interventions in women with intrauterine pathology and infertility by improving diagnostic and therapeutic measures based on the study of clinical, microbiological, ultrasonographic, hormonal, and morphological characteristics of patients

Results

Intrauterine pathology occupies the main place in the structure of female infertility. The cause of endometrial polyps is the influence of infectious and immune factors. Today, the main methods of diagnosing endometrial pathology are: ultrasound, endometrial aspiration biopsy, endometrial hysteroscopy with targeted biopsy and further pathohistological, immunohistochemical and microbiological studies. Hysteroscopy is the gold standard for assessing the condition of the endometrium and uterine cavity. Intrauterine intervention is one of the causes of inflammatory diseases of the internal genital organs, which adversely affect the reproductive function of the female body. It is necessary to prevent and develop an algorithm for reducing postoperative complications in order to improve the percentage of pregnancy and reduce the frequency of relapses.

Conclusions

Improving and carrying out a systematic analysis of prognostic criteria with an assessment of their impact on the onset of pregnancy will in the future make it possible to reduce postoperative complications and obtain the expected consequences of hysteroscopic intervention, such as normalization of the menstrual cycle, reduction of pain syndrome, onset of pregnancy, etc. It is also necessary to develop and implement a diagnostic-treatment algorithm to improve the early and long-term consequences of hysteroscopic intervention in women with infertility and intrauterine pathology.

Cesarean scar pregnancy treatment: management by hysteroscopic tissue removal system after systemic methotrexate, a case report

Aurélie Simon¹, Florence Hanocq¹, Katty Delbecque², Frederic Kridelka³, Patricia Nervo¹

¹*Université de Liège, Gynécologie-Obstétrique, Liège, Belgium*

²*Université de Liège ULiège, Gynécologie-Obstétrique, Liège, Belgium*

³*Université de Liège ULiège, Gynécologie-Obstétrique, Liège, Belgium*

Background

The management of caesarean scar pregnancy is usually carried out on a case-by-case basis according to the habits of the gynaecologist and the hospital. There is no gold standard. The aim is to demonstrate the efficacy and safety of treatment by hysteroscopic tissue removal system after systemic methotrexate injection.

Methods

We report the case of a 27 years old patient (G3P1), with a previous caesarean section and an abortion by D&C. She presented herself to the emergency room with pelvic pain and metrorrhagia. The human chorionic gonadotrophin (hCG) serum level was of 3099 Ui/L. The exploration revealed an ectopic pregnancy on the caesarean scar. She benefited of 4 systemic injections of Methotrexate over the course of two weeks, due to an elevation of hCG, which went up to 26379 Ui/L. As the hCG became negative, endovaginal ultrasound confirmed the avascular nature of a mass of 46x41mm. Surgical resection by mechanical morcellation hysteroscopy was performed under general anaesthesia. The choice of material was TruClear Elite 6mm with soft tissue shaver mini. The procedure was performed under an intrauterine visual control and ultrasound-guidance.

Results

Hysteroscopic resection by mechanical morcellation (TruClear[®]) of an ectopic pregnancy on a caesarean scar was successful. Resection time was 20 minutes. There were no intra- or post-operative injuries. This procedure was performed ambulatory.

Conclusions

To our knowledge, this is the first time in Belgium that TruClear[®] procedure has been used to treat a caesarean scar pregnancy after systemic methotrexate with a fertility conservation. We report that this hysteroscopic technique seems to be safe for the patient and surgeon and could become a new approach for CSP management.

Ultrasonic versus electro-surgical laparoscopic ovarian drilling for patients with PCOS

Mohamed Salama¹, Sayed Elakhras², Mohamed Kandeel³, Vasilios Tanos⁴

¹*Ain Shams University, Obstetrics and Gynaecology, Cairo, Egypt*

²*Omam Hospital, O&G and Minimally-invasive Surgery, Cairo, Egypt*

³*Ain Shams General Hospital, Obstetrics and Gynaecology, Cairo, Egypt*

⁴*University of Nicosia Medical School, Obstetrics and Gynaecology, Nicosia, Cyprus*

Background

Laparoscopic ovarian drilling (LOD) is a surgical alternative to medical treatment. There are risks associated with surgery, such as complications from anaesthesia, infection, and adhesions.

Laparoscopic ovarian drilling has been widely accepted as the second line of choice for induction of ovulation in CC-resistant PCOS women in preference to gonadotrophin therapy. In addition to its proven efficacy, LOD offers several advantages over gonadotrophins such as avoiding multiple pregnancies and OHSS.

Using a monopolar needle applied at right angle to the antimesenteric surface of the ovary with penetration of the ovary to a depth of 7-8 mm at four points with a power setting of 30 W for 5 s per puncture seems to be an optimum approach that maximises effectiveness and safety.

However, various complications still do occur despite all the precautions.

Ultrasonic energy has been used in gynaecological laparoscopy for the combined cutting and vaporisation of tissues. It is deemed to be more safe than electro-surgery, especially mono-polar diathermy

Methods

we report a case series of ladies with PCOS, who underwent LOD using Ultrasonic energy, rather than mono-polar diathermy. we observed pregnancy rates, and the occurrence of tubo-ovarian and ovarian fossa adhesions in these patients

Results

LOD using Ultrasonic energy, rather than mono-polar diathermy was associated with high pregnancy rate, less tubo-ovarian and ovarian fossa adhesions.

Conclusions

Ultrasonic energy should be considered as a safer alternative to mono-polar electro-surgery for LOD.

Further RCT's should be conducted to investigate and validate this proposed advantage

Is there a correlation between anti-müllerian hormone, body mass index and assisted reproductive treatment?

Julie Collée¹, Michelle Nisolle¹, Frédéric Chantraine¹, Laurie Henry¹
¹Hôpital de la Citadelle, Gynecology and Obstetrics, Liège, Belgium

Background

The aim of this retrospective cohort study is to evaluate the correlation between antimüllerian hormone (AMH) and the type of assisted reproductive treatment (ART) for infertile women and for women with polycystic ovarian syndrome (PCOS) who were pregnant.

Methods

This is a retrospective cohort study that includes 442 patients. These are patients who obtained a pregnancy in the ART centre and whose pregnancies were followed in the Department of Obstetrics of the University of Liege from January 2018 to December 2022. The ART centre database was compared with the delivery unit database to determine the cohort of patients who delivered after ART.

Among these 442 patients, there were 88 pregnancies obtained by intrauterine insemination (IUI) and 352 after in vitro fertilization (IVF): 156 after fresh embryo transfer (ET) and 198 after frozen embryo transfer (FET).

The association between two quantitative variables was measured using the correlation coefficient of Pearson. The results are considered significant at the 5% uncertainty level ($p < 0.05$).

Results

This study showed that patients who benefited from IUI have a mean age of 31.7 years old (IC 22; 35), patients with fresh ET 33.76 years old (IC 30; 37) and patients with FET 32.9 years old (IC 29; 36). Patients who benefit from fresh ET are older than patients who benefited from IUI (p -value 0,002).

Concerning AMH, patients who benefit from IUI have an AMH mean rate of 3.70 ng/ml (IC 1.62; 4.82), patients with fresh ET 1.87 ng/ml (IC 0.73; 2.71) and patients with FET 3.46 ng/ml (IC 1.39; 4.46). Patients who benefit from fresh ET have a lower AMH than other assisted reproductive treatment with a $p < 0.0001$.

The mean body mass index (BMI) of patients with fresh ET and IUI is 25.6 and 25.3 for FET.

There is a negative correlation between the rate of AMH and the age. There is no correlation between the body mass index and the AMH. Patients with polycystic ovarian syndrome (PCOS) are younger and have a higher rate of AMH.

If we considered obstetrical complications, in our population, 23.9% of the patients with a lower rate of AMH (< 1) developed diabetes and 8.5% developed preterm birth. Nevertheless, it is not significantly different. 18.3% of the patients with a lower rate of AMH (< 1) developed hypertensive disorders with a p -value of 0.16.

Conclusions

In conclusion, our study confirms that AMH is lower in older women and women with PCOS have a higher rate of AMH. BMI doesn't influence the rate of AMH in our population. Fresh embryo transfers are more frequent for women with low rate of AMH and for older women.

Patients with low rate of AMH seem to have a higher rate of hypertensive disorders and it could be related with the older age of those patients.

How endocervicoscopy can impact obstetric outcomes in women undergoing LEEP for CIN2+: a retrospective cohort analysis.

Luigi Della Corte¹, Mario Ascione², Valeria Cafasso², Maria Chiara Guarino², Giuseppe Bifulco², Giada Lavitola²

¹University of Naples Federico II, Neuroscience- Reproductive Sciences and Dentistry, Naples, Italy

²University of Naples Federico II, Department of Public Health, Naples, Italy

Background

To assess the impact of preoperative endocervicoscopy on obstetric outcomes and complications in women undergoing LEEP for CIN2+

Methods

This was a retrospective cohort study carried out between October 2012 and April 2018. All women had undergone cervical length measurement at T0 (before LEEP), T1 (6 months after LEEP) and T2 (at 20 weeks of pregnancy) through transvaginal ultrasound examination after LEEP for CIN2+. A total of 528 patients fulfilled our inclusion criteria and contributed to the final analysis: 288 had undergone endocervicoscopy before the excisional procedure (Group A) while the remaining 240 (Group B) did not. This was a retrospective cohort study carried out between October 2012 and April 2018. All women had undergone cervical length measurement at T0 (before LEEP), T1 (6 months after LEEP) and T2 (at 20 weeks of pregnancy) through transvaginal ultrasound examination after LEEP for CIN2+. A total of 528 patients fulfilled our inclusion criteria and contributed to the final analysis: 288 had undergone endocervicoscopy before the excisional procedure (Group A) while the remaining 240 (Group B) did not.

Results

Patients who did not undergo endocervicoscopy showed a greater amount of tissue excised at LEEP compared to those of Group A (6,7% vs 31,9% in Group A and B, $p < 0.01$, respectively). A statistically relevant difference was detected in the lesion margins involvement: negative in 93,8% in Group A compared to 65,6% in Group B. The cervicometry before the treatment resulted in similar between the two groups while a statistically significant difference was noted after 6 months (37.5 ± 2.9 mm in Group A vs 35.1 ± 3.8 mm in Group B, $p < 0,01$) and at 20th weeks pregnancy (36.9 ± 5.3 mm in Group A vs 33.5 ± 5.6 mm in Group B, $p < 0,01$). The number of pregnancies after LEEP as well as the difference in the elapsed time (in months) did not result in a statistical significance between the two groups. The threatened preterm labour (TPL) and the threatened miscarriage showed a statistically significant difference in incidence between the two groups (4,2% and 4,2% in Group A vs 15,3% and 25% in Group B, $p < 0,01$, respectively).

Conclusions

Endocervicoscopy reduces the size of the LEEP sample and in particular its depth, saving healthy cervical tissue, and guarantees the total eradication of the lesion as the resection margins are negative in almost all cases, allowing for a reduction of the rate of TPL and threatened miscarriage in women with CIN2+, especially with Type 2 or 3 cervical squamocolumnar junction (SCJ).

Laparoscopic metroplasty for unicornuate uterus with a functional noncommunicating uterine horn: a report of 22 cases

Yan Ding¹, Junjun Qiu¹, Xuyin Zhang¹, Keqin Hua¹

¹Obstetrics and Gynecology Hospital of Fudan University, Department of Gynecology, Shanghai, China

Background

To evaluate surgical outcomes and reproductive outcomes in patients with unicornuate uterus and a functional noncommunicating uterine horn after laparoscopic metroplasty.

Methods

This was a retrospective study of 22 patients who were diagnosed with unicornuate uterus and a functional noncommunicating uterine horn and underwent laparoscopic metroplasty between January 2013 and March 2023 at the Obstetrics and Gynecology Hospital of Fudan University, Shanghai, China. Clinical characteristics, perioperative data, post-operation complications, resumption of menstruation, and pregnancy outcomes were assessed.

Results

The average age of all patients was 22.0±7.88 years old (ranges12-33). Ten out of them were unicornuate uterus and a functional noncommunicating uterine horn, two bicornuate uterus, two uterus duplexes. Six patients companied with cervicovaginal dysplasia and underwent reconstruction of cervix and vagina as well as placement of intrauterine device and vaginal mould to prevent adhesion or stenosis. Nine patients companied pelvic endometriosis, and underwent ovarian cystectomy. Three patients had a history of recurrent spontaneous abortion. The operative procedure lasted 145.00±66.67 min, with a haemoglobin decrease of 11.00 g/dl. All surgery was completed successfully except one patient had rectal injury. At a median follow-up of 33.00±29.16 months, all patients were relieved of pain and resumed menstruation. One patient complained repeat abdominal pain after 7 years of metroplasty and cervicovaginal reconstruction due to cervical stenosis, and underwent second operation to replace the intrauterine device. Another patient complained repeat abdominal pain after 8 months of metroplasty due to intrauterine adhesion in the previous uterine horn, and underwent second operation to reopen the adhesive scar and place intrauterine device. Those who had a desire of pregnancy were suggested to do after two years of metroplasty. Three patients have pregnant without complications. One patient delivered twins at 33 weeks and 5 days with 2150g and 2350g. One patient delivered a baby at 33 weeks and 6 days with 2270g. The other one is still in pregnancy at 10 weeks.

Conclusions

Reconstructive laparoscopic metroplasty is safe and efficient to management of congenital unicornuate uterus and a noncommunicating functional uterine horn with good surgical outcomes and reproductive outcomes.

Surgical management of endometriomas: impact of various surgical techniques on reproductive outcomes and fertility parameters

Angelos Daniilidis¹, Georgios Grigoriadis², Dimitra Dalakoura², Dimitrios Rafail Kalaitzopoulos³, Horace Roman^{4,5}, George Pados¹

¹Aristotle University of Thessaloniki,

1st Department of Obstetrics and Gynecology- Papageorgiou Genral Hospital, Thessaloniki, Greece

²Aristotle University of Thessaloniki,

2nd University Department of Obstetrics and Gynecology- Hippokration General Hospital, Thessaloniki, Greece

³Cantonal Hospital of Schaffhausen, Department of Obstetrics and Gynecology, Schaffhausen, Switzerland

⁴Clinique Tivoli-Ducos, Franco-European Multidisciplinary Institute for Endometriosis, Bordeaux, France

⁵Aarhus University, Department of Obstetrics and Gynecology, Aarhus, Denmark

Background

Ovarian endometrioma (OMA) is a common manifestation of endometriosis, often associated with infertility. The aim of this review is to describe the various surgical methods of managing OMA and investigate their impact on fertility parameters and chances of conception, spontaneous or through artificial reproductive technology (ART).

Methods

Relevant search on Pubmed/Medline, including original research items published in English language and between 2010 and present day.

Results

Presence of OMA itself appears to lead to a reduction in anti-mullerian hormone (AMH) levels. Surgical management options of OMA, through minimally invasive techniques, include cystectomy, simple drainage of OMA, drainage of OMA with vaporisation of the cyst wall by laser, plasma energy or bipolar electrocoagulation, drainage of OMA with ethanol sclerotherapy and combination of the aforementioned techniques. Cystectomy remains the most commonly performed approach and may be associated with an increase in the chances of spontaneous conception. It also leads to a smaller risk of OMA recurrence, compared to other techniques. However, it often leads to excision of healthy ovarian tissue and the greatest post-operative depression in AMH levels, albeit this effect might be transient and related to factors such as surgeon's experience and cyst size. Reduction of ovarian volume and reduced response to ovarian hyperstimulation post- cystectomy have been described. Use of sutures, vasopressin or various sealing agents for haemostasis may reduce the need for use of bipolar energy, albeit their protective effect on ovarian reserve has not been clearly demonstrated. Various studies have reported an increase in the antral follicular count (AFC) post- cystectomy. Compared to bipolar energy, vaporisation of the OMA wall by laser or plasma energy produces a more superficial effect, thus causing less damage to underlying healthy ovarian cortex. The aforementioned alternative approaches to cystectomy may lead to a smaller post-operative reduction of ovarian reserve, useful in the ART setting, however, are generally associated with smaller chances of spontaneous conception and higher risk of recurrence. The post-operative reduction on ovarian reserve parameters is, logically, higher in women operated on for bilateral endometriomas and, in case of bilateral OMA cystectomy, may even lead to an earlier age of menopause.

Conclusions

Various approaches are available in the surgical management of OMA. Cystectomy, generally, leads to a smaller risk of recurrence and higher chances of spontaneous conception, however, at an expense of greater post-operative reduction in ovarian reserve. Alternatives to cystectomy, as described above, may cause less reduction in ovarian reserve and may, therefore, be more appropriate in certain groups, such as women with low pre-operative AMH levels. Whatever technique is chosen, meticulous surgical technique remains of paramount importance.

Role of extended letrozole treatment duration in inducing ovulation in women with polycystic ovarian syndrome and letrozole resistance

M. Abhigna¹, Sumana Manohar², Kirthika KS², Kanimozhi k²
¹Apollo womens hospital, Obstetrics and gynecology, Chennai, India
²Apollo womens hospital, Obstetrics and gynaecology, Chennai, India

Background

The commonly used letrozole regimen for ovulation induction in women with polycystic ovarian syndrome (PCOS) is 2.5mg daily for 5 days. If initial dose fails to initiate follicular development, its often increased to 5mg in succeeding cycle after a progesterone withdrawal period. In accordance with the theory that the FSH window is as important as the FSH threshold during selection of dominant follicles, we hypothesized that longer treatment with letrozole could extent the FSH window, there by inducing follicular growth in patients who initially do not respond to routine treatment. In our study, considering ovarian hyperstimulation and multiple pregnancies, the FSH window was widened in a stepwise manner by extending the letrozole treatment duration step by step. We defined leteozole resistance as failure of ovulation after a 5-day regimen of 5mg letrozole per day for at least one cycle. For women with PCOS and letrozole resistance a 7-day regimen of 5mg letrozole daily was prescribed in the first ovulation induction cycle and if ovulation did not occur, a 10-day regimen was given in the subsequent cycle. Such a method of extending letrozole treatment duration was called 2-step extended letrozole regimen in the present study. Here in the present study, we reported the ovulation rates and clinical pregnancy outcomes in women with PCOS and letrozole resistance who underwent ovulation induction using 2-step extended letrozole regimen.

Methods

This was a retrospective study conducted at tertiary care centre, Apollo womens hospital, Chennai, India. The study period was for 3 years (May 2019-May 2022). Inclusion criteria were women less than 40 years of age, normal semen analysis for male part ers and a diagnosis of PCOSbased on modified Rotterdam criteria. Exclusion criteria were women with any contraindications to pregnancy, those who received other pharmacologic agents for ovulation induction such as gonadotropins or those who did not undergo a subsequent cycle after failure of ovulation induction with 7-day regimen of 5mg letrozole daily. A total of 276 women with PCOS and Letrozole resistance were included.

Results

Ovulation rate was the primary outcome. Pregnancy rate, live birth rate, spontaneous ovulation rate and ovarian hyperstimulation syndrome rate were secondary outcomes. Out of 276 patients, 192 ovulated after the 7 day and 84 after the 10-day regimen. Overall, the cumulative ovulation rate reached 92.65% after the 2-step extended letrozole regimen, with cumulative clinical pregnancy rate og 31.99% and a cumulative livebirth rate of 24.64%. All patients ovulated spontaneously without external trigger agents and none experienced ovarian hyperstimulation syndrome.

Conclusions

Extending letrozole treatment duration is a feasible method for inducing ovulation in women with PCOS and letrozole resistance. Furthermore, studies involving multicentre and large patient numbers are required to derive a specific algorithm for management of PCOS patients

The experience and management of complex female genital malformations: a single tertiary centre's experience

Sofia Tsiapakidou¹, Eirini Iordanidou¹, Christos Anthoulakis¹, Theodoros Theodoridis¹, Grigorios Grimbizis¹
¹Aristotle University of Thessaloniki- Greece,
1st Department of Obstetrics and Gynaecology Aristotle University of Thessaloniki, Thessaloniki, Greece

Background

Congenital uterine anomalies are common, affecting 3–8% of reproductive-age women. Complex female genital tract malformations, although with a lower prevalence, can have great clinical bothersome and negative impacts on a woman's quality of life in addition to affecting her reproductive health. This study retrospectively analyses the experience of a single centre's experience in treating complex female genital malformations.

Methods

This is a retrospective, cross-sectional single-centre study of all patients diagnosed with complex cervical and vaginal anomalies according to ESGE/ESHRE consensus. All patients were assessed, counselled, and followed up by an experienced Gynaecological Endoscopist and a Paediatric and Adolescent Gynaecologist. All participants had support from a Clinical Psychologist. Surgical treatment was performed on all. The hospital's electronic patient records were used for the demographics, the clinical, the operative, and the post-operative details. All data were stored and analysed in Microsoft Excel.

Results

A total of 47 participants were included. 37 were diagnosed with a complex genital malformation with a mean age of first consultation at 19.3±6.2 years old, and the reason for consultation was 54% for primary amenorrhea, 21.6% for abdominal pain/discomfort, 8.1% for subfertility, 5.4% for vaginal discomfort and 10.8% was an incidental finding. In detail, 30 patients were diagnosed with malformations in all three organs, two with a malformation only at the uterus, two with a combination of malformation at the uterus and cervix, and two with a combination at the uterus and vagina. The recommended surgical treatment plan for each patient to correct genital malformations depended on the type of anomaly, its complexity, the patient's symptoms, and the correct embryological interpretation of the anomaly. Nine other patients were diagnosed with a transverse vaginal septum and/or imperforate hymen [U0C0V3], and one with vaginal aplasia [U0C0V4]. The continuity of the genital tract was surgically restored. The postoperative period was uneventful. One patient with cervical aplasia [U0C4V0], and a direct uterovaginal anastomosis was performed. Postoperatively, she needed repetitive review hysteroscopies to evaluate the outflow tract. Sexual function and normal cyclical menses were established for all these ten patients.

Conclusions

Knowledge of genitourinary embryology is essential for the understanding, diagnosis, and subsequent treatment of complex genital malformations. Detailed imaging of the reproductive tract is essential to make the correct diagnosis, determine if surgical intervention is recommended, and educate the patient about the condition with an individualized approach.

An intriguing case of an interstitial ectopic pregnancy with the clinical features of a gestational trophoblastic disease

Osaretin Pamela Aigbogun¹, Martine De handschutter¹, Fiona Avau¹, Frederic Buxant¹
¹HÔPITAL IRIS Sud, Gynecology and obstetrics, Brussels, Belgium

Background

The patient was a 24-year-old female, G2P1 and at 9 weeks of gestation when she was referred to our team after her first early ultrasound showing a mass located in the right uterine cornua, without any intrauterine gestational sac. She was healthy and had a prior caesarean section for her first pregnancy. She wasn't presenting any symptoms, as abdominal pain or vaginal bleeding. Her pelvic examination revealed an approximately 8 week-sized uterus and a lack of pelvic pain. We performed another transvaginal ultrasound that demonstrated a 40X10 mm heterogeneous mass in the right uterine cornua, strongly vascularised, with multiple anechoic spaces described as a "Swiss Cheese pattern". The ultrasound didn't show an intrauterine gestational sac or an hemoperitoneum. The laboratory evaluation indicated an elevated HcG level of 100 283 mIU/mL. At this stage, our initial diagnosis was a right interstitial ectopic pregnancy associated with a highly suspected gestational trophoblastic disease (GTD) because of the location of the pregnancy, the level of HCG and the appearance of the mass during the ultrasound. The patient underwent a laparoscopic surgery to respect the right uterine cornua associated with a right salpingectomy. The decision of a laparoscopic surgery was led by the location of the pregnancy that didn't enable a uterine evacuation as recommended in the management of GTD. The intraoperative abdominal evaluation revealed a strongly vascularised mass in the right uterine cornua as priorly seen in the ultrasound and matching with our initial diagnosis of a right interstitial ectopic pregnancy. We performed a resection of the mass with an endo GIA stapler for minimal intraoperative bleeding and a right salpingectomy. However, the histological evaluation didn't corroborate our suspicion of a gestational trophoblastic disease and demonstrated an ectopic pregnancy with rare chorionic villi and without any signs of a GTD or a gestational trophoblastic neoplasia. An immunohistochemical analysis was also performed and was positive for the P57, P63 and the CKAE 1/3. A laboratory evaluation was repeated after two and four weeks (before the results of the pathology) to evaluate the postoperative HCG level. The HCG level after two weeks dropped to 805 mIU/mL and to 65 mIU/mL after 4 weeks. We stopped the HCG monitoring after the results of the pathology.

Methods

0

Results

0

Conclusions

Gestational trophoblastic disease is a histological diagnosis, and the chorionic villi may degenerate and develop hydropic changes in non-molar missed abortions and thereby appear as molar in ultrasound

Sentinel lymph node detection and accuracy in vulvar cancer: meta-analysis and systemic review

Jae Kwan Lee¹, Sohyeon Jeong¹, Hyun Woong Cho¹, Jin Hwa Hong¹

¹Korea University Guro Hospital, Department of Obstetrics & Gynecology, Seoul, Korea- Republic Of

Background

Based on previous publication including randomized controlled trials and meta-analysis, sentinel lymph node (SLN) biopsy in women with early vulvar cancer is considered as a safe and effective procedure which is alternative to inguinofemoral lymph node dissection. However, near infrared imaging with indocyanine green (ICG) injection has emerged recently. Moreover, meta-analysis has not been updated for six years. We conducted a meta-analysis to evaluate the accuracy of SLN biopsy in vulvar cancer.

Methods

Relevant studies were identified using the PubMed, MEDLINE, and Cochrane databases. The outcomes of this study were detection rate, false negative rate and clinical accuracy of SLN biopsy with radiocolloid tracer, blue dye or ICG.

Results

Of the 887 references, 51 studies were included. Pooled per groin detection rate for SLN biopsy using radiocolloid tracer, ICG and blue dye were 0.96 (0.93-0.98), 0.90 (0.83-0.98) and 0.72 (0.62-0.81), respectively. In meta-regression, SLN biopsy using radiocolloid tracer or ICG or both is significant moderator for detection of SLN ($p=0.013$). Pooled sensitivity of SLN biopsy was 94% (95% CI 91-96%) and false negative rate was 8% (95% CI 5-11%).

Conclusions

SLN biopsy using radiocolloid tracer, ICG is highly reliable and accurate in selected patients under strict protocol. The utilization of ICG for SLN sampling is feasible and promising in future.

Exploring the impact of surgical interventions and identifying risk factors for recurrence in borderline ovarian tumours

Seon Mi Lee¹, Sanghoon Lee¹, Hyun Woong Cho², Kyung Jin Min³, Jae Kwan Lee², Tak Kim¹

¹Korea University Anam Hospital, Obstetrics and Gynecology, Seoul, Korea- Republic Of

²Korea University Guro Hospital, Obstetrics and Gynecology, Seoul, Korea- Republic Of

³Korea University Ansan Hospital, Obstetrics and Gynecology, Seoul, Korea- Republic Of

Background

Despite the low incidence and favourable prognosis of borderline ovarian tumours (BOTs), standardized surgical treatments and risk factors remain debated. This study aimed to evaluate the influence of different surgical interventions on the outcomes of BOTs and to identify risk factors that contribute to their recurrence.

Methods

BOT patients at Korea University Anam Hospital from March 2006 and March 2023 were grouped based on recurrence. Therapeutic surgical interventions were classified as conservative, comprehensive, or staging surgeries. Each group's characteristics, clinicopathological factors, surgical interventions, disease-free survival (DFS), overall survival (OS), and recurrence risk factors were compared and analysed. Statistical analyses included student's t-test, chi-square test, Fisher's exact test, Kaplan-Meier analysis, and Cox regression analysing using SPSS.

Results

Of 177 patients, 170 were in the non-recurrence group and 7 in the recurrence group, with an average follow-up of 54.7 months. Among relapsed patients, 4 had borderline recurrence and 3 had malignant transformation, with respective DFS of 43 and 18 months. There were no significant differences in DFS and OS on surgical interventions (DFS, $p = 0.592$; OS, $p = 0.807$) (Figure 1.). Increased risk of BOT recurrence was observed with positive washing cytology and intraoperative iatrogenic rupture (Positive washing cytology, HR, 30.02, 95% CI, 3.084, 292.210, $p = 0.003$; Intraoperative iatrogenic rupture, HR, 5.19, 95%CI, 1.006, 26.765, $p = 0.049$), but no significant OS risk factors were identified.

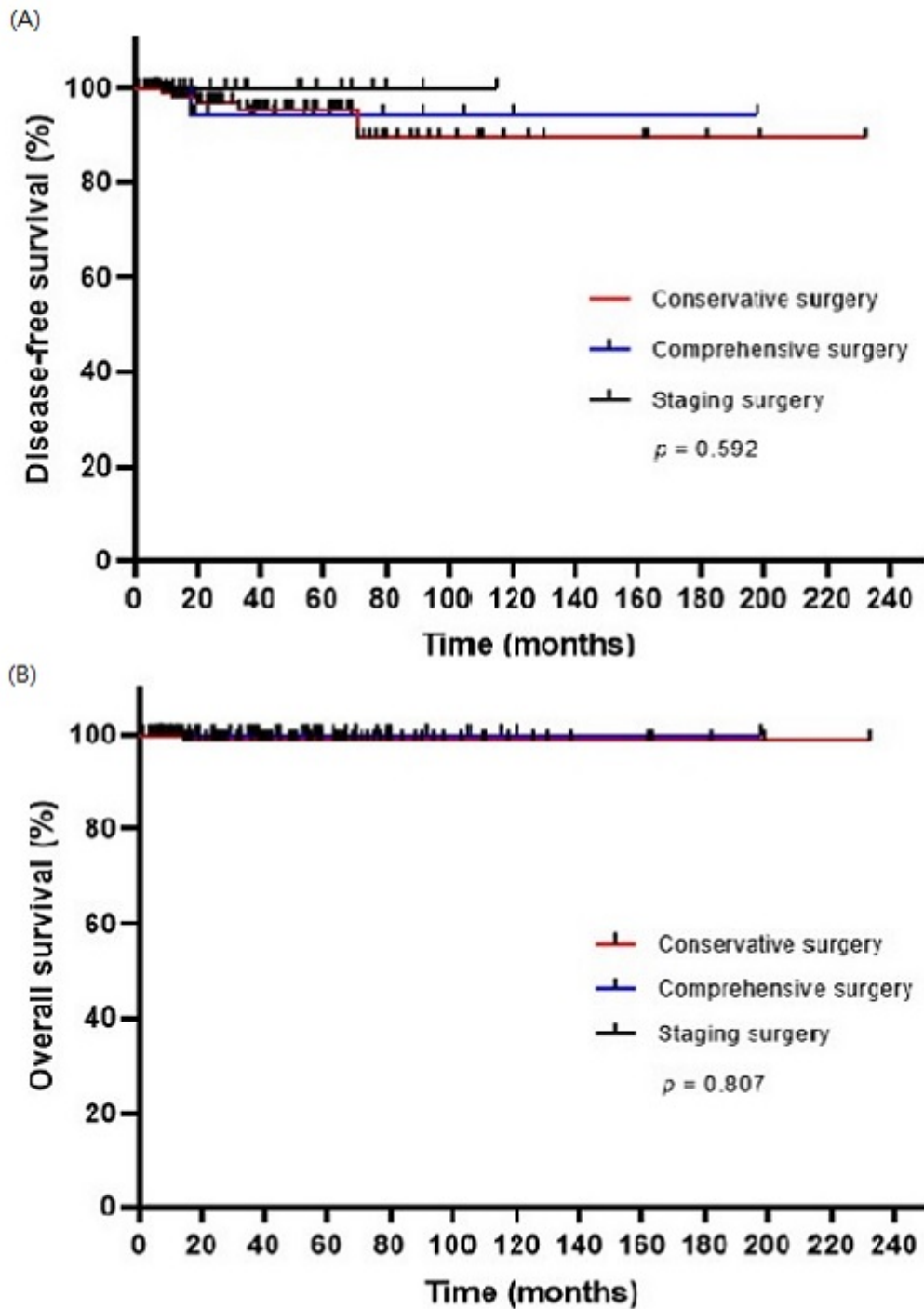


Figure 1. Survival plot by type of surgical interventions according to Cox proportional hazard model. (A) Disease free survival plot and (B) overall survival plot.

Conclusions

In BOT treatment, surgical intervention differences didn't affect outcomes or DFS and OS. Conservative, comprehensive, and staging surgeries are variable options based on patient age and fertility preservation. To reduce BOT recurrence risk, it is crucial to avoid rupture during surgery and closely monitor postoperative patients with positive washing cytology.

The primordial follicle pool is preserved using the mTOR inhibitor rapamycin during ovarian tissue cryopreservation

Jules Bindels¹, Marlyne Squatrito¹, Michelle Nisolle², Laurie Henry², Carine Munaut¹

¹*Université de Liège, GIGA-Cancer - Laboratory of Biology of Tumour and Development, Liège, Belgium*

²*Université de Liège, Hôpital de la Citadelle - Department of Obstetrics and Gynecology, Liège, Belgium*

Background

Ovarian tissue cryopreservation followed by auto transplantation (OTCTP) is currently the only fertility preservation option for prepubertal patients or patients requiring urgent therapy for aggressive malignancies. Once in remission, auto transplantation of frozen/thawed tissue is performed when patients want to conceive. This attractive approach, which can both restore the endocrine function of the gonads and natural fertility, has already allowed more than 200 live births. However, it can be improved as there are still some problems limiting its use. Amongst the main issues of the procedure is the follicular loss directly after grafting, mainly due to ischemia, apoptosis, and primordial follicle activation.

To improve follicular survival during the OTCTP procedure, we inhibited the mTOR pathway involved in follicle activation, *in vivo*, using rapamycin, an mTOR inhibitor. Next, we used an alternative new non-invasive heterotopic transplantation model, namely between the skin layers of the ears, and compared this new model to the more conventional transplantation under the kidney capsule.

Methods

Four-week-old C57bl/6 mice ovaries, either fresh, slow-frozen, or slow-frozen with rapamycin, were auto transplanted under the kidney capsule of mice and recovered 3 weeks later for immunohistochemical analysis. As transplantation to the kidney capsule is an invasive transplantation model and local treatment administration to this site is difficult, we also evaluated a less invasive site recently described, namely between the skin layers of the ears. Both sites were compared by auto transplanting fresh four-week-old C57bl/6 mice ovaries and recovering them 3 weeks later.

Results

Immunohistochemical analyses of ovarian grafts collected 3 weeks after transplantation under the kidney capsule showed that rapamycin counteracts slow-freezing/transplantation-induced follicle proliferation, as well as Akt and mTOR pathway activation.

Analysis of ovarian grafts transplanted under either the kidney capsule or between the skin layers of the ears showed both sites are suitable for analysing follicle proliferation and activation after transplantation.

Conclusions

Our results indicate that adding the mTOR inhibitor rapamycin during the OTCTP procedure is able to transiently maintain primordial follicles in a quiescent state. Limiting the massive follicle activation of the primordial follicle pool constitute a promising way to improve the longevity of the ovarian graft for fertility restoration.

Mature teratoma of the ovary presenting with torsion and significantly elevated levels of CA 19-9 antigen

Maria Sakellariou¹, Nikolaos Machairiotis¹, Christos Koratzanis¹, Sofoklis Stavrou¹, Peter Drakakis¹

*¹Attikon University Hospital- National and Kapodistrian University of Athens,
3rd Department of Obstetrics - Gynecology, Athens, Greece*

Background

Ovarian teratomas are common benign tumours of the ovarian germ cells and their diagnosis usually relies on typical radiological characteristics. However, tumour markers unspecific for gynaecological malignancies may appear elevated in patients with ovarian tumours complicating the diagnosis. We herein describe a rare case of an ovarian teratoma presenting with torsion and significantly increased levels of CA19-9 antigen.

Methods

A 38-year-old female presented in the emergency department complaining of pelvic pain. The patient was evaluated by ultrasound in which a 6cm cystic mass of mixed echogenicity arising from the right ovary was shown, as well as free fluid in the lower abdomen. The presence of a Whirlpool sign during Doppler examination of the ipsilateral ovarian vessels rendered high suspicion of torsion. During the preoperative work-up significantly elevated levels of CA19-9(7984.0 U/ml) and moderately elevated levels of CA125(226.0 U/ml) were found. A computed tomography ordered to assess the gastrointestinal tract (GI) showed a multilocular tumour of the ovary with typical characteristics of mature teratoma and no abnormalities from the GI were depicted.

Results

Due to the possible benign nature of the ovarian mass an exploratory laparoscopy was performed. The right ovary was found bearing an enlarged cystic mass and having sustained a triple torsion. Adhesions of the ovary with the small intestine were present. A laparoscopic right adnexectomy was performed. The histologic report confirmed the presence of a mature teratoma of the ovary with elements of mucinous glands, fatty tissue, squamous and respiratory-like epithelium, and cartilage. In the adjacent ovarian parenchyma, a mucinous cystadenoma was also found. The postoperative course of the patient was uneventful, while the serum concentrations of the CA19-9 and the CA125 antigens dropped significantly immediately after the operation and normalized one month after surgery.

Conclusions

We present one of the few cases reported in the literature showing a relation between a mature ovarian teratoma and increased levels of CA19-9. The mechanism of CA19-9 production from ovarian teratomas is not clear. Possible pathophysiologic mechanisms are the antigen secretion from the bronchial glands and mucosa of the tumour; absorption of CA19-9 by adjacent tissues after thinning and inflammation of the tumour wall of large or torped tumours, depicting a relation between larger sized teratomas and higher incidence of torsion with increased levels of CA 19-9. Lastly, literature has suggested that although the isolated rise of CA19-9 levels could appoint to the diagnosis of torsion of an ovarian teratoma, the synchronous increase in CA19-9 and CA125 antigens can suggest a malignant nature of the tumour. Contrary to this, the concurrent elevation of the tumour markers in our case could be attributed to the torsion of the adnexa and the subsequent peritonitis which could rise the levels of CA125 antigen.

Ovarian leiomyosarcoma: a rare ovarian pathology

Alessandro Zecchin¹, Valentina Weger², India Turcatel³, Michela Zorzi⁴, Martin Steinkasserer¹, Giovanni Negri⁵

¹Azienda Sanitaria dell'Alto Adige - Bolzano Hospital, Gynecology and Obstetrics, Bolzano, Italy

²AOUI Verona - University of Verona, Obstetrics and Gynecology, Verona, Italy

³University of Bologna - Sant'Orsola Hospital, Gynecology and Human Reproduction Physiopathology, Bologna, Italy

⁴University of Padua - Padua University Hospital,

Department of Women and Children's Health - Clinic of Gynecology and Obstetrics, Padua, Italy

⁵Azienda Sanitaria dell'Alto Adige - Bolzano Hospital, Pathological Anatomy, Bolzano, Italy

Background

The aim of the article is to evaluate the possibility to develop standardised diagnostical and management procedures in recognising Ovarian Leiomyosarcomas (LMS).

Methods

A 55-year-old woman, PARA 1001, BMI 24, in good health, underwent pelvic ultrasound to check for two months earlier detected adnexal cyst.

The right adnexa showed a solid formation with a diameter of 44x46x51 mm, irregular margins and colour-score 4; the left ovary of 31x18 mm was irregular.

Chest CT: negative. In the abdomen a 5x4.2x4 cm wide solid mass in the right adnexal region was confirmed in which the right adnexus did not appear recognisable, characterized by a discrete and nonhomogeneous impregnation of contrast.

Tumour Markers: CA 125, Ca 19-9, CA 15-3 were negative.

Laparotomy: total hysterectomy, bilateral adnexectomy, infracolic-infragastric omentectomy and peritoneal washing was performed.

The right ovary was the site of a cystic formation of increased consistency and irregular surface, with a diameter of about 5 cm; other organs were regular. The intraoperative histological examination of the right adnexa suggested a mesenchymal neoplasm: macroscopically, the tuba was normal while the ovary was mostly replaced by a greyish neof ormation, fasciculated when cut, measuring 5x3.5x2.8 cm.

Results

Histological examination diagnosis: primary fusocellular leiomyosarcoma of the right ovary. The mesenchymal neoplasm measured 5 cm, had marked and diffuse nuclear atypia and mitosis and arrived focally on the serosal surface. Tuba and fimbriae were negative.

Immunophenotypic analysis: positive reactions for smooth muscle Actin, Caldesmon and Desmin.

pTNM: T1c Nx G unknown V0 L0, FIGO Ic2.

Tumorboard decision: follow-up, without adjuvant chemotherapy or radiotherapy. Post-surgical staging PET-CT: negative.

Conclusions

LMS are rare tumours of the smooth muscle tissue and the Primary Ovarian LMS accounts for less than 0,1% of all gynaecologic disorders. As tumour source sites there were proposed: the smooth muscle of the blood vessels in the attachment points of the ovarian ligaments, in the cortical stroma and in the corpus luteum. Due to its low prevalence no standardised diagnostical and management procedures have been defined. CT defines the location of the mass but is unable to differentiate between leiomyoma and leiomyosarcoma. Pelvic US and MRI offer a more detailed imaging, but it remains difficult to distinguish between a degenerative leiomyoma and a leiomyosarcoma. Aspects that may be indicative of LMS are: nodular borders, intralesional haemorrhage and T2 dark and non-enhanced central areas.

PET-CT before surgery, provides a high accuracy in diagnosing leiomyosarcoma and both functional and anatomic data are obtained in a single examination.

In conclusion, if Primary Ovarian LMS is suspected, the pre-operative investigation with MRI and PET-CT, is adequate. Surgery with a complete resection should be attempted and the role of adjuvant therapy for early stage LMS cannot be strongly recommended given the associated toxicity with little evidence of benefit.

ES32-0251 - P202
ePoster Presentations

Endometriosis and the risk of ovarian cancer: a review of the epidemiological data

Angelos Daniilidis¹, Kyriaki Mitta², Georgios Grigoriadis³, Dimitra Dalakoura³, Dimitrios Rafail Kalaitzopoulos⁴, George Pados¹

¹Aristotle University of Thessaloniki,

1st University Department of Obstetrics and Gynecology- Papageorgiou General Hospital, Thessaloniki, Greece

²Aristotle University of Thessaloniki,

3rd University Department of Obstetrics and Gynecology- Hippokration General Hospital, Thessaloniki, Greece

³Aristotle University of Thessaloniki,

2nd University Department of Obstetrics and Gynecology- Hippokration General Hospital, Thessaloniki, Greece

⁴Cantonal Hospital of Schaffhausen, Department of Obstetrics and Gynecology, Schaffhausen, Switzerland

Background

Endometriosis is a common gynaecological disease. The aim of our review was to study a possible association between the presence of endometriosis and a higher risk of ovarian malignancy.

Methods

A comprehensive search of the PubMed/Medline, Embase, Cinahl electronic databases for all studies reporting on the association between endometriosis and ovarian cancer published in English, using numerous search terms.

Results

The first large epidemiological studies came from Sweden, with two big registries (20,686 and 64,492 patients, respectively) and both showing an increased risk for ovarian cancer in patients who were hospitalized for endometriosis (SIR: 1.9, 95% CI: 1.3–2.8 and SIR: 1.43, 95% CI:1.49–1.71, respectively). Large-scale epidemiological studies in the last years showed an association between endometriosis and ovarian cancer, as well. The association of endometriosis and ovarian cancer showed to be stronger for laparoscopically confirmed endometriosis (OR 2.14, 95% CI 1.45–3.15) by Poole et al. A meta-analysis (1990-2012) showed that endometriosis increases the risk of ovarian cancer, associated with stage I–II disease, nulliparity and with the histology of endometrioid and clear cell carcinomas. No difference was shown by progression-free survival, optimal debulking surgery, the histology of mucinous carcinoma, and the high-grade serous and borderline carcinoma. Mogensen et al. in a cohort study of 45,790 patients, observed increased risk after 1–4 years (SIR 1.51, 95% CI 1.00–2.18) and 5–9 years of follow-up (SIR 1.78; 95% CI 1.30–2.37) but not ≥ 10 years after the first diagnosis of endometriosis. Matalliotakis et al. found that the proportion of women with a positive family history of ovarian cancer was significantly higher in endometriosis cases (OR = 10.5, 95% CI 2.5–44.2). Regarding the pathophysiology of endometriosis and oncogenesis, the involvement of certain mutations in the tumour suppressor gene ARID1A, mutations of transcription factor HNF-1beta, and PIK3CA may play an important role; PTEN, KRAS, CTNNB1 genes mutations are major genetic alterations in endometrioid ovarian cancer and ERa represents an independent prognostic factor in endometrioid as well.

Conclusions

In the majority of the studies, the most common subtypes associated with endometriosis are endometrioid and clear-cell ovarian cancer. Monitoring for ovarian cancer in endometriosis patients through transvaginal ultrasound or CA-125 measurements does not reduce mortality. Bilateral salpingo-oophorectomy to prevent ovarian cancer in endometriosis patients is associated with higher risks of cardiovascular diseases. Overall, no sufficiently robust data are available to justify systematic risk-reducing salpingo-oophorectomy.

ES32-0259 - P203

ePoster Presentations

The role of cytological DNA methylation in hospital opportunistic screening for cervical cancer: a prospective multicentre study in China

Lei Li¹, Yu-ling Liou², Pei Liu³, Hsiang Yu Chuang⁴

¹Peking Union Medical College Hospital, Department of Obstetrics and Gynecology, Beijing, China

²The First Affiliated Hospital of Guangdong Pharmaceutical University, Clinical Precision Medicine Research Center, Guangzhou, China

³Beijing OriginPoly Bio-Tec Co, R&D Department, Beijing, China

⁴Beijing OriginPoly Bio-Tec Co, Medical Department, Beijing, China

Background

The purpose of this study was to explore the possibility of using the methylation level of methylated *PAX1* (*PAX1^m*) or *JAM3^m* as molecular marker to detect high-grade squamous intraepithelial lesion (HSIL) and cervical cancer in hospital opportunistic screening (HOS).

Methods

This study collected 18920 samples for cervical cancer in the outpatient department of 7 multi-centre hospitals from May 2019 to April 2022. Cervical exfoliated cells were collected for liquid-based cytology, high-risk human papillomavirus (hrHPV) genotyping, *PAX1^m*, and *JAM3^m* tests. The diagnostic accuracies of various tests and screening strategies for definitive pathology and for cervical intraepithelial neoplasia (CIN) 3 or worse (CIN3+) were compared.

Results

In total, 18920 women were successfully screened, and the overall positive rate of cytology was 8.1%, hrHPV was 14.6%, HPV16/18 was 4.8%, *PAX1^m* was 3.4%, *JAM3^m* was 3.0%, and *PAX1^m* or *JAM3^m* was 3.9%. 3689 samples with cervical histological pathology. The mean age was 45.6±12.4 years. The positive rate of *PAX1^m*, *JAM3^m*, and *PAX1^m / JAM3^m* for SCC / AD were 99.9% / 81.0%, 97.0% / 100%, and 100% / 100%, which was higher than hrHPV (91.9%) and HPV16/18 (74.7%), respectively. The positive rate of normal pathology was hrHPV at 64.5%, HPV16/18 at 16.2%, and *PAX1^m / JAM3^m* at 6.1%, respectively. The combined detection of CIN3+ by HPV16/18 and *PAX1^m / JAM3^m* has better clinical sensitivity and specificity at 85.3% and 88.5% than other single or combined tests in the study. In these tests. The immediate CIN2+ risk was highest in *PAX1^m / JAM3^m* (73.95%), higher than hrHPV (25.09%) and cytology (27.81%).

Conclusions

PAX1^m/JAM3^m combined with HPV16/18 can progress to improve detection efficiency in CIN3 and malignancies.

ES32-0326 - P207

ePoster Presentations

Minimally invasive surgery in recurrent endometrial cancer a multicentre study

Virginia Vargiu¹, Andrea Rosati¹, Valerio Gallotta¹, Luca Palmieri¹, Giovanni Scambia², Francesco Fanfani²

¹Fondazione Policlinico Universitario A. Gemelli IRCCS,

Department of Woman and Child Health and Public Health, Rome, Italy

²Fondazione Policlinico Universitario A. Gemelli IRCCS- Università Cattolica del Sacro Cuore,

Department of Woman and Child Health and Public Health, Rome, Italy

Background

Secondary cytoreductive surgery (SCS) is gaining increasing interest in the treatment of endometrial cancer (EC) recurrence. Although the role of minimally invasive surgery (MIS) is well recognized in the initial treatment of EC, there is no data about its safety, in terms of oncological outcomes, in relapsed disease.

Methods

Multicentre retrospective study including patients with first EC relapse subjected to SCS between January 2010 and May 2022. Primary outcome was to compare oncological outcomes of patients subjected to MIS or open SCS. Secondary outcome was to assess factors that could be favourably associated with MIS. Survival was determined from date of first recurrence to last follow-up or cancer-related death and estimated using Kaplan-Meier method. Differences in survival were analysed using Log-rank test. Binomial logistic regression was performed to evaluate factors that could predict MIS.

Results

Data from 210 patients were retrieved. No differences in terms of post relapse and post relapse free survival were highlighted (log-rank test $p=0.235$ and $p=0.628$ respectively). Body mass index (BMI) ≥ 30 , early FIGO stage at diagnosis, single site relapse and the hematogenous pattern of relapse (parenchymal relapse) were positively associated with MIS (respectively BMI ≥ 30 OR 2.216, 95% CI: 1.109-4.430, $p=0.024$; early FIGO stage: OR: 4.294, 95% CI: 1.571-11.737, $p=0.005$; single site relapse OR: 2.757, 95% CI: 1.059-7.178, $p=0.038$; hematogenous pattern of relapse OR: 4.322, 95% CI: 1.711-10.918, $p=0.002$). In contrast, patients who received adjuvant radiotherapy at first diagnosis were less probably operated through MIS (OR 0.444, 95% CI 0.213-0.925, $p=0.030$).

Conclusions

MIS for recurrent EC did not affect surgical outcomes. The early-stage disease at diagnosis, the single site relapse, the evidence of a single parenchymal metastasis (hematogenous pattern) and a BMI over 30 were positively associated with the minimally invasive approach. In contrast, previous radiotherapy was identified as negative predictor.

Adult granulosa cell tumour of the ovary: an unexpected diagnosis

Fernanda Cristina Alves¹, Mario Moura¹, Beatriz Ferreira¹, Inês Sa¹, Ana Moreira¹, Osvaldo Moutinho¹
¹Centro Hospitalar de Trás-os-Montes e Alto Douro, Ginecologia/Obstetrícia, Vila Real, Portugal

Background

Ovarian sex cord-stromal tumours (SCTs) are a group of benign and malignant neoplasms that develop from different types of cells (granulosa, theca, Sertoli, Leydig cells, among others), mostly specialized in the production of steroid hormones; so, these tumours are often functioning and associated with endocrine manifestations. Specifically, granulosa cell tumours comprise 2-5% of all ovarian malignant neoplasms and 90% of malignant SCTs.

In contrast to the more common epithelial ovarian malignant neoplasms, most patients with malignant SCTs are diagnosed with early-stage disease. Histology is generally low grade; lymph node metastases are rare and prognosis is usually good.

Methods

To present a clinical case of an unexpected diagnosis of an adult granulosa cell tumour of the ovary with review of the literature.

Results

A 37-year-old woman was admitted to the emergency department with abdominal pain with one day of evolution and progressively worsening, with no other associated complaints. The patient did not have any relevant medical history. From gynaecological and obstetrical history: gravida 4, para 3 (2 vaginal births and 1 caesarean section). As a contraceptive method, the patient used the subcutaneous implant with etonogestrel, not menstruating because of its use.

On physical examination, she had pain and tenderness on the right iliac fossa; besides, the uterus was painful on mobilization during vaginal exam. The transvaginal ultrasound demonstrated a 6cm ovarian cyst on the right side (with regular walls and anechoic content) but with decreased doppler flow. The blood work revealed light leucocytosis with no other changes. Faced with a possible diagnosis of adnexal torsion, the patient was then proposed for diagnostic laparoscopy.

She was submitted to a diagnostic laparoscopy that had to be converted to laparotomy due to extensive pelvic adhesions – the surgery confirmed the adnexal torsion and she underwent right adnexectomy and left salpingectomy given that the patient's family planning project was complete. The anatomopathological examination of the surgical specimen confirmed that it was an adult granulosa cell tumour of the ovary. As the patient didn't want any more children, she was then submitted to total hysterectomy + contralateral oophorectomy and surgical staging.

Conclusions

With the presentation of this case, the authors intend to emphasize that even in the face of ultrasound aspects of an adnexal mass suggestive of benignity, we must always bear in mind the possibility that we are facing a borderline or malignant tumour.

Uterine transposition versus uterine ventrofixation before radiotherapy as fertility sparing option in young women with pelvic malignancies: systematic review of the literature and dose simulation

Matteo Pavone^{1,2,3}, Rosa Autorino⁴, Nicolò Bizzarri⁵, Maria Antonietta Gambacorta⁶, Giovanni Scambia³, Denis Querleu⁵

¹*Institute of Image-Guided Surgery- IHU Strasbourg- Strasbourg, ihu, Strasbourg, Italy*

²*IRCAD- Research Institute Against Digestive Cancer IRCAD France-, Ircad, Strasbourg, France*

³*Fondazione Policlinico Universitario A. Gemelli- IRCCS- Roma- Italy, UOC Ginecologia Oncologica- Dipartimento per la salute della Donna e del Bambino e della Salute Pubblica, Rome, Italy*

⁴*Fondazione Policlinico Universitario A. Gemelli- IRCCS- Roma- Italy., UOC Radioterapia Oncologica- Fondazione Policlinico Universitario A. Gemelli- IRCCS- Rome- Italy, Rome, Italy*

⁵*Fondazione Policlinico Universitario A. Gemelli- IRCCS- Roma- Italy., UOC Ginecologia Oncologica- Dipartimento per la salute della Donna e del Bambino e della Salute Pubblica, Rome, Italy*

⁶*Fondazione Policlinico Universitario A. Gemelli- IRCCS- Roma- Italy., UOC Radioterapia Oncologica- Fondazione Policlinico Universitario A. Gemelli- IRCCS, Rome, Italy*

Background

Neoadjuvant (chemo)radiation may be required treatment of pelvic malignancies in female patients of reproductive age. Irradiation may result in a damage to ovarian and uterine function, compromising the ability of those patients to conceive. While ovarian transposition is an established method to move the ovaries away from the irradiation field, similar surgical procedures regarding the uterus remain investigational. The aim of this study was to carry out a systematic review of the literature on uterine displacement techniques (ventrofixation/transposition) and to simulate the radiation dose received by the uterus in different heights place after the procedures.

Methods

The systematic review was conducted in accordance with the PRISMA guidelines. The study protocol was registered on PROSPERO (CRD42023391278). Retrospectively, a dosimetric study was performed to assess the dose received by the uterus according to hypothetical different displacement positions taking the case of irradiation for rectal or anal cancer as model.

Results

A total of 187 studies were included in the initial research, after the screening 9 studies were selected for qualitative synthesis. Data from the dose simulation revealed that in the anatomical position the maximum and median doses were for the rectal cancer 46.5 and 25.2 Gy and for the anal cancer 58.4 and 34.5 Gy respectively. The transposition approach was the most protective with a maximum dose of about 3 and 8 Gy for anal and rectal cancer. None of the simulated US ventrofixation positions, in both cases, received a Dmean surpassing 14 Gy, and the US volumes receiving 14 or 20 Gy for all simulated ventrofixation positions were remarkably small.

Conclusions

According to the literature review and the simulation results of the present study we may conclude that simple elevation of the uterus by ventrofixation of the fundus could be considered as a fertility sparing approach in young rectal/anal cancer patients.

ES32-0428 - P212
ePoster Presentations

Intra operative mass containment in vNOTES surgery for borderline ovarian tumour with management of adhesions

Oudai Alij¹, Zini Mudiaga¹

¹Epsom and St Helier University Hospital NHS trust, Obstetrics and Gynaecology, London, United Kingdom

Background

Vnotes is an innovative technique with growing evidence of efficacy and safety in benign gynaecology. Extended application in oncology cases are potential benefits to achieve less traumatic surgery in well vetted cases. This a case demonstration of Vnotes surgery for the indication of adnexal lesion suspicious of borderline ovarian tumour. It is important to adhere to the oncologic principles and avoid spillage and mass rupture resulting in upstaging. This a case of serous borderline exophytic tumour which was contained in a bag before continuing with procedure, all performed through the Vnotes approach.

Methods

This is a case of 61-year lady with past history of stable chronic lymphoid leukaemia who had previous two normal deliveries and presented with incidental finding of 4cm suspicious left ovarian mass with a normal ca125 of 25iu. She had a previous appendectomy and was of normal BMI Operation started by accessing the anterior and posterior compartments after securing the uterosacral ligaments. Laparoscopic vaginal view indicated left friable 4cm ovarian mass and dense adhesions on the POD and the right adnexa. The intraoperative decision was to immediately contain the mass with the Inzii retrieval system before progressing with other steps and perform adhesiolysis. Voyant energy device was used and the pneumoperitoneum pressure was maintained at 8mmHg.

Results

The mass was retrieved contained and intact. The procedure duration was 60min and the patient made an excellent immediate recovery but later had new overactive bladder symptoms which was managed and responded to VESicare. The final histology was borderline exophytic ovarian tumour stage 1C2 She was discussed the regional cancer network and the recommendation was for no further treatments and regular follow up.

Conclusions

This case demonstrated the advantage and the feasibility of containing suspicious adnexal lesions at the start of the laparoscopic phase of the procedure. This did not interfere in the flow of the operation and ultimately achieved a successful result Vnotes application for suspected ovarian cancer should be done in well vetted cases with thorough preoperative assessment. It was also possible to do adhesiolysis for more than expected adhesions. It is important to seek patient feedback and register ant side effects of the procedure and improve experience and outcomes.

ES32-0461 - P213
ePoster Presentations

A very rare case of emergency hysterectomy for acute postmenopausal bleeding in a woman with challenging medical co-morbidities

Shereen Ibrahim¹, Radhika Padmagirison¹

¹Lister hospital - East and north Hertfordshire NHS trust, Obstetrics & gynaecology, Stevenage, United Kingdom

Background

Postmenopausal bleeding with multiple medical comorbidities had emergency hysterectomy.

Methods

Case report

Results

A 57-years old postmenopausal woman with a BMI of 40kg/m² presented to the emergency department with heavy vaginal bleeding. She reported to have on and off vaginal bleeding in the last 12months and occasionally this was heavy with passage of clots.

She was known to have multiple fibroid uterus and she had an open myomectomy at the age of 30. She was nulliparous and had not had a smear for a long time now. She also has a history hypertension, and atrial fibrillation for which she was on rivaroxaban. She was also recently diagnosed with a stable Type an Aortic dissection mild Aortic regurgitation, mild Tricuspid regurgitation, moderate to large pericardial effusion, probable pulmonary hypertension.

Her haemoglobin was 79gm/dl on admission, with a normal coagulation profile. Ultrasound scan showed large fibroid uterus and unable to comment on endometrial thickness.

Despite receiving 6units of packed red blood cells her haemoglobin was not improving and had dropped further to 68gm/dl. She started to become more unwell and hence the decision was made for an emergency hysterectomy.

An MDT discussion about the case was done with haematologist, anaesthetist, and cardio-thoracic team (under whom she is for Aortic dissection). We gave her the octaplex to potentially reverse the effects of rivaroxaban.

A major haemorrhage protocol was initiated prior to taking the patient to theatre with 4units of packed RBC, FFP, Octaplex, and tranexamic acid. Explained to the patient the possible risks with octaplex which are thrombosis, stroke, but these risks were outweighed by the risk of she bleeding to potential death.

Cardiothoracic team had advised that stable aortic dissection should not be contraindication to surgical procedure required to stop ongoing bleeding.

Prior to the surgical intervention, we also discussed with the interventional radiologist about possible uterine artery embolization however on balance they felt this is not an ideal option in view of the aortic dissection.

After detailed counselling to the patient for risk of surgery, a total abdominal hysterectomy and bilateral salpingo-oophorectomy was performed. Intra-operatively uterus was enlarged to 18weeks size, with multiple fibroids with ovaries appearing normal. There was no evidence of intra-abdominal bleeding or any other obvious pathology.

Histology results no features of a leiomyosarcoma but showed moderate to severe atypia suggesting the possibility of a uterine smooth muscle tumour of uncertain malignant potential (STUMP).

Conclusions

This is a rare and interesting case needing an emergency hysterectomy which is not a very common emergency gynaecology procedure.

This case was also complicated in view of patient's BMI and medical co-morbidities. The final histology was reported as possible STUMP fibroid tumour for which patient has been referred to the Sarcoma centre and we are awaiting the formal outcome at this time.

ES32-0487 - P214
ePoster Presentations

Impact of hormone therapy on hysteroscopic and histological findings in breast cancer women and endometrial anomalies: is there a correlation with uterine bleeding?

Mario Palumbo¹, Antonio Mercurio¹, Paolo Serafino¹, Pierluigi Giampaolino¹, Attilio Di Spiezio Sardo¹, Maria Chiara De Angelis¹

¹University of Naples Federico II, Department of Public Health, Naples, Italy

Background

The primary aim of this study was to examine the endometrial diseases associated or not with abnormal uterine bleeding (AUB), in women with previous breast cancer treated with the first-line hormone therapy.

Methods

A retrospective observational study was conducted. Patients with a history of breast cancer were included and divided in Group 1, with AUB, and Group 2, without AUB.

Both of the group were divided in 4 subgroups: treated with selective estrogen receptor modulators (SERMs), aromatase inhibitors (AIs), GnRH analogues or SERMs + GnRH analogues. All patients had undergone office hysteroscopy for clinical or ultrasonographic suspicion of endometrial pathology. All data were collected in a dedicated database.

Results

A total of 60 patients were included for the statistical analysis, 25 (42%) in Group 1 and 35 (58%) in Group 2: 42/60 (70%) patients used SERMs in monotherapy; 4/60 (6.7%) combined with GNRH analogues. GnRH-analogues as monotherapy were administered in 8/60 (13.3%) patients; 6/60 (10%) patients were treated with AIs.

Histological diagnoses did not recognize a statistically significant difference between Group 1 and Group 2. Patients in Group 1 treated with AIs presented more atrophic or normal endometrium respect the patients that used SERMs and didn't present AUB.

Only one patient in group 2, treated with SERMs, had an adenocarcinoma of the endometrium.

Conclusions

Different hormone therapies after breast cancer did not impact the endometrial pathology onset between the group of women with or without AUB.

ES32-0501 - P215
ePoster Presentations

Extensive IVC thrombus secondary to large benign ovarian cyst

Shereen Ibrahim¹, Sihem Imessaoudene¹

¹Lister hospital - East and north Hertfordshire NHS trust, Obstetrics & gynaecology, Stevenage, United Kingdom

Background

A rare case of extensive IVC thrombus secondary to a large benign ovarian cyst in a healthy young patient.

Methods

Case report

Results

25Years old presented to emergency department with sudden onset of left leg pain and swelling. Patient reported abdominal pain, bloating and distention, for one month. She is known to have a large ovarian cyst awaiting surgery. She had a normal BMI and had no comorbidities.

CT-abdomen and pelvis showed 20x11x23cm right adnexal cystic lesion causing mass effect dilating the proximal ureters and renal pelvis bilaterally. There was significant mass effect with posterior displacement of the pancreas and kidneys. The small bowel loops were displaced to the left.

MRI pelvis showed 24cm encapsulated right ovarian cyst. The cyst showed benign features on MRI. All tumour markers were normal. MRI also confirmed acute left iliofemoral deep venous thrombosis.

CT-Angiogram revealed mass effect on the infrarenal IVC causing attenuation and dilation of the left common and external iliac vein and common femoral vein in keeping with thrombosis. The arterial vessels remained patent.

Opinion from haematology was sought, advised starting treatment dose of LMWH and inserting a suprarenal IVC filter.

Urology team was involved in her care due to post renal AKI1 and mildly raised creatinine of 89 caused by bilateral compression of ureters. The advice was to manage renal function conservatively and to consider bilateral ureteric stenting if renal function deteriorates or patient develops uro-sepsis.

The patient was reviewed by the vascular team locally and at tertiary centre; as there was no phlegmasia, thrombolysis was possible. They advised to continue anticoagulation with LMWH, to wear above knee compression stockings and to elevate the legs to help reduce the swelling. Given that the DVT was secondary to extrinsic compression from extensive right ovarian cyst, they have recommended fitting of an IVC filter prior to removal of the cyst to reduce thromboembolic risk. Since patient was not fit for surgery, cyst drainage under ultrasound guidance by interventional radiology considered.

After involving the whole MDT, the decision was for placement of an IVC filter prior to ovarian cystectomy. However, venogram showed large thrombus at L4 to L3 renal vein level with no room to deploy the IVC filter, the procedure was abandoned. In view of the significant risk of pulmonary embolism the patient was urgently transferred to the tertiary centre for further management. The MDT decision made by the vascular team at the tertiary centre is to switch from therapeutic LMWH to direct oral anticoagulants for 12 weeks before performing ovarian cystectomy/oophorectomy.

Conclusions

MDT approach adopted in view of to the complexity of the case and lack of general consensus. Delaying surgical removal of large ovarian cysts can lead to serious complications such as VTE, ovarian torsion, serious morbidity and mortality.

Association of single nucleotide polymorphisms within the Interleukin-16 gene (rs4778889, rs4072111, rs11556218, rs1131445) with ovarian cancer risk

Rafal Watrowski¹, Eva Obermayr², Eva Schuster², Robert Zeillinger²

¹*Helios Hospital Müllheim- Teaching Hospital of the University of Freiburg, Department of Gynecology and Obstetrics, Müllheim, Germany*

²*Medical University of Vienna, Molecular Oncology Group- Department of Obstetrics and Gynecology, Vienna, Austria*

Background

Single nuclear polymorphisms (SNPs) of the IL-16 gene have been reported to influence the risk of nasopharyngeal, colon and renal cancers, but their role in ovarian cancer (OC) has never been studied.

Methods

By analysing the restriction fragment length polymorphisms (PCR-RFLP) method, we examined four common SNPs within the IL-16 gene: rs4778889 (T>C), rs4072111 (C>T), rs11556218 (T>G) and rs1131445 (T>C) in blood samples from 413 women of Central European descent.

Results

Within this homogeneous cohort, 201 women were diagnosed with OC and 212 were healthy controls, with 125/201 (62%) patients and 115/212 (54%) controls being postmenopausal. Regarding OC cases, 170/201 (85%) were diagnosed in late stages of the disease (FIGO IIb-IV) and the histological type was high grade serous OC (HGSOC) in 146/201 (76%). The mean minor allele frequencies (MAF) observed among the control groups of the selected SNPs were 13.68% for rs4778889 (C allele), 9.2% for rs11556218 (G allele), 10.38% for rs4072111 (T allele), and 32.31% for rs1131445 (C allele).

As the first to report these associations, we found that the presence of rs11556218 (T>G) and rs4778889 (T>C) influenced the risk of developing OC. In the co-dominant model, the association between IL-16 rs11556218 and OC risk was highly significant for the entire cohort ($p < 0.001$) as well as for the separately analysed premenopausal ($p < 0.001$) and postmenopausal ($p = 0.004$) subgroups. These associations remained significant in other models examined (dominant $p < 0.001$, over-dominant $p < 0.001$, recessive $p = 0.04$). The IL-16 rs4778889 was associated with a risk of OC predominantly in premenopausal women (co-dominant model $p = 0.014$, dominant model $p = 0.008$). With respect to the whole cohort, the association of IL-16 rs4778889 did not reach significance ($p = 0.067$) in the co-dominant (basic) model, but was still significant in the dominant ($p = 0.023$) and over dominant ($p = 0.038$) models. Notably, within the cases, rs4778889 (T>C) was significantly associated with the increased chance to be diagnosed with a HGSOC ($p = 0.027$). In contrast, we could not find significant associations between the variants IL-16 rs4072111 and IL-16 rs1131445 and the risk of OC ($p = 0.79$ or 0.42 , respectively).

Conclusions

Our pioneering study contributes to the understanding of the role of IL-16 genetic variants in the development of OC in European women. In particular, our results demonstrate a strong association of rs11556218 and rs4778889 with premenopausal OC and the aggressive HGSOC subtype.

Retrospective review of management of Endometrial Hyperplasia (EH)

Sabita Nair¹, Preetha Gunasegaran¹, Ahmed Elshahawy¹, Mohamed Elmezaien¹

¹The Royal Wolverhampton NHS Trust, Gynaecology, Wolverhampton, United Kingdom

Background

Introduction: Endometrial hyperplasia is irregular proliferation of the endometrial glands with increase in gland to stromal ratio. EH classified as hyperplasia with atypia and without atypia based on WHO 2014 revised guidelines.

Objectives: To review the management of EH and compare practice with RCOG standards at our hospital – Regional oncology centre. The study also aims at analysing the feasibility in setting up a database and streamlining the follow up pathway.

Methods

A retrospective observational study of all cases of endometrial hyperplasia from 2014 – 2020. Data on demographic characteristics, menopausal status, risk factors, clinical presentation, method of initial diagnosis, histological type of hyperplasia, subsequent mode of management and follow up were analysed.

Results

A total of 94 cases of endometrial hyperplasia were identified during the study period. Women were aged from 34 – 87 yrs. with a mean age of 60.28 yrs. Majority of the women were postmenopausal (79.8%) and post-menopausal bleeding (72.3%) was the most common presentation. Obesity was seen in 87.22% of women, 39.36% belonging to severely obese (BMI 35 – 39.9) category. Out-patient hysteroscopy was the commonly used modality for diagnosis in 37.2% cases. A histological diagnosis of EH with atypia was seen in 48.9% cases and EH without atypia in 51.1%. Treatment of EH: medical management (60.41%) was the preferred treatment in EH with no atypia and surgical management – hysterectomy (73%) in EH with atypia. 21% of women with EH - atypia opted for medical management and there was no clear documentation for the reason behind the preference, they subsequently went on to have hysterectomies for persistence of endometrial abnormality. There were multiple instances where RCOG standards for follow up were not met, 46% of EH without atypia were discharged only after 1 negative biopsy with no long term follow up.

Conclusions

There was no standard timeframe or clearly documented plan for follow up for women with BMI > 35 or those who opted medical management. This audit stresses the importance of clear documentation and MDT involvement in managing women with EH - atypia who prefer medical management. Adopting a holistic approach and individualized care based on risk factors can help provide effective care in women with EH. We recommend setting up a database and recalling system, to develop inhouse guidelines and reaudit in 1 year to improve patient safety and provide effective care.

Fertility-sparing treatment in women with grade 2 endometrial cancer: a retrospective single-centre study

Giorgia Dinoi¹, Nicoletta D'Alessandris², Alessia Piermattei², Francesco Fanfani³,
Giovanni Scambia³, Ursula Catena³

¹Fondazione Policlinico Universitario Agostino Gemelli- IRCCS,
Department of Obstetrics and Gynecology- Division of Gynecologic Oncology, Rome, Italy

²Fondazione Policlinico Universitario Agostino Gemelli- IRCCS,
Department of Woman and Child's Health. Pathology Unit, Rome, Italy

³Catholic University of Sacred Heart, Department of Obstetrics and Gynecology-
Division of Gynecologic Oncology, Rome, Italy

Background

Endometrial cancer is the 6th most common cancer in women and the 15th most commonly occurring cancer overall. The standard treatment consists in total hysterectomy, bilateral salpingo-oophorectomy, with or without lymph node assessment. However, in the last two decades, the mean age of women at childbirth and at birth of the first child progressively increased. Therefore, the need to preserve fertility is strikingly growing. Until recently, candidates for conservative management were considered women younger than 40 years with diagnosis of complex atypical endometrial hyperplasia or well-differentiated endometrioid endometrial cancer, without myometrial invasion, with no evidence of extrauterine disease at pre-operative work up, highly motivated to preserve their reproductive function after an adequate counselling. The preferred treatment consisted in hysteroscopic resection followed by progestin therapy. On the other hand, there were very few published data on patients with stage IA grade 2 endometrioid endometrial cancer without myometrial invasion. A group of international multidisciplinary experts nominated by ESGO/ESHRE/ESGE developed the new guidelines lately. According to this recommendation, the combined treatment consisting of endometrial hysteroscopic resection followed by either oral and intra-uterine-released progestins in patients stage IA grade 2 endometrioid endometrial carcinoma appear feasible and safe.

We aimed to evaluate the oncologic and obstetrics outcomes of fertility-sparing treatment in these patients.

Methods

This is a retrospective single-centre study of all consecutive patients with diagnosis of grade 2 endometrioid EC without myometrial invasion, who underwent fertility-sparing treatment. The conservative treatment consisted of hysteroscopic resection of the lesions followed by a combined progestin therapy (oral megestrol acetate (MA) 160 mg/die and levonorgestrel intrauterine device (LNG-IUD)). Patients were enrolled between June 2019 and July 2022 at Fondazione Policlinico Universitario Agostino Gemelli IRCCS.

Results

A total of 11 patients were included in the study, with a median follow-up time of 17 (IQR 12-39) months. The median age was 34 years (IQR 28 - 38). Complete response (CR) was obtained in 9/11 patients (81,8%) at six months, and 2/11 (18,2) had partial response (PR). All patients achieved CR at a median time of 6 (6-9) months. Seven patients discontinued progestin therapy to attempt to conceive. One of them (14,2%) achieved spontaneous pregnancy. Three out of the 11 (27,3%) patients recurred 6 months after the progestin therapy discontinuation and all of them underwent definitive surgery. All patients were mismatch repair (MMR) proficient except one (10/11, 90,1%). No patient was p53-mutated. The expression of estrogen and progesterone receptor was high (70% and 90%, respectively). No treatment-related complications were registered.

Conclusions

Our study showed encouraging results of hysteroscopic resection followed by combined oral MA/LNG-IUD treatment as effective and safe fertility-sparing method for grade 2 EC without myometrial invasion, with high complete response rate. Further studies are warranted to clarify long-term oncologic and obstetric outcomes.

Comparison of Ti-Knot devices with extracorporeally tied sutures in laparoscopic sacrocolpopexy

Khaleda Sajjadi Maeder¹, Christos Tsaousidis², Karoline Aebi-Popp³, Ralf Rothmund²

¹Lindenhofhospital, Gynecology and Obstetrics, Bern, Switzerland

²Lindenhofspital, Gynecology and Obstetrics, Bern, Switzerland

³Lindenhofspital, Gynecology and Obstetrics, Bern, Switzerland

Background

Descensus surgery aims to correct descensus symptoms and improve the function of affected organs such as the vagina, bladder and rectum.

Laparoscopic Sacrocolpopexy with MESH fixation is more recommended for younger, physically and sexually active women with mainly mid-compartment descensus.

The fixation of the mesh with several single button sutures on the anterior and posterior vaginal walls as well as on the apex takes a lot of time, so that the operation time is about 2-3 hours and the patients therefore also have a long anaesthesia time.

That is why surgeons are always trying to shorten this operation time.

Methods

In our pilot study we compare the duration of suturing in each of 10 patients who received either mesh fixation with extracorporeal knotted PDS 2-0 sutures or mesh fixation with the Ti-Knot Divice using the same sutures.

Results

The study is currently still ongoing. The Results so far confirm our hypothesis that the suture time with the TI-Knot Divice is much shorter compared to extracorporeally tied sutures

Conclusions

The Ti-knot Divice could be a good alternative to conventional suturing in the future.

On the one hand, for patients who are polymorbid and can't be kept in the head position for a long time.

On the other hand, it could be a good alternative for patients in whom we expect long operating times due to many previous operations and adhesions.

Beyond traditional approaches: bridging the gap between surgery and regenerative therapies in the management of pelvic organ prolapse.

Giorgia Gaia¹, Margarita Afonina¹, Vera Donati², Stefano Izzo¹, Carlo Alboni³, Anna Maria Marconi¹

¹San Paolo Hospital Medical School, Department of Obstetrics and Gynecology, Milan, Italy

²San Paolo Hospital Medical School, Department of Maxillo-Facial Surgery, Milan, Italy

³University of Modena and Reggio Emilia,

Department of Medical and Surgical Sciences for Mother- Child and Adult, Modena, Italy

Background

Pelvic organ prolapse (POP) is a frequently reported female condition associated with aging, traditionally treated by conservative or vaginal approach. Owing to an increasing lifespan, with a lifetime recurrence rate of 13-19%, new treatment options are required to enhance the quality of women's life. Following the FDA ban on vaginal mesh, minimally invasive techniques, such as laparoscopic or robotic sacrocolpopexy, have become more popular due to their improved dexterity and 3D visualization, resulting in comparable anatomical and functional outcomes with reduced complications. Nevertheless, mesh exposure, remains one of the most challenging hurdles, with no established guidelines for management. Partial or complete mesh removal is recommended to reduce the potential associated risks, despite promoting clinical prolapse relapse. To prevent or handle mesh erosion, innovative therapies aimed at thickening the vaginal wall have been proposed, with increasing interest in mesenchymal stem cells (MSCs). Micro-fragmented adipose tissue with an intact stromal vascular niche, as a source of MSCs, offers high regenerative capacity, essential for the integrity and functionality of pelvic organs. We present a successfully treated case of recurrent pelvic prolapse, starting from vaginal surgery, progressing to robotics, and ultimately utilizing mesenchymal stromal cells (Lipogems®), highlighting the potential of this cutting-edge technology.

Methods

44 years old G2P2 woman, BMI 30,5 kg/m² and no other comorbidities treated for a multiple recurrent stage IV pelvic organ prolapse according to Pelvic Organ Prolapse Quantification (POP-Q) system between 2020 and 2023 at San Paolo University Hospital, Milan, Italy.

Results

In 2020, the patient underwent vaginal colpohysterectomy, followed by a laparoscopic colposuspension, with proline mesh, for the first recurrence in 2021. After the second relapse, in 2022, the previous mesh was removed, and a robot-assisted promontofixation was performed. At three months follow-up, a vaginal mesh erosion was detected, requiring partial and then total excision in February 2023. Finally, autologous fat was harvested, processed in a closed system Lipogems®, and injected into the mucosal and muscular layers of the vaginal cuff. At one- and three-month follow-up assessments, no erosion was observed, and the vaginal cuff was closed, soft, and thick. No complications were reported after sexual intercourse.

Conclusions

Pelvic organ prolapse remains a fascinating and complex topic. Minimally invasive surgical techniques and the reemergence of mesh have undeniably improved the quality of women's life. Nevertheless, the persistent risks of erosion and recurrence of pelvic organ prolapse require inventive solutions. MSCs, characterized by optimal handling ability and a great regenerative potential, show promise. In dealing with pelvic organ prolapse, a personalized and multidisciplinary approach within a specialized referral centre should be encouraged. By combining surgical expertise and medical research, up and coming frontiers can be unlocked. Further clinical trials are needed to establish the safety, efficacy, and long-term outcomes of this method.

Effects of intravaginal estrogenization in treating women with stress urinary incontinence after mini sling implantation

Rafal Moszynski¹, Aleksander Frackowiak¹, Paulina Adamska-Owczarzak¹, Stefan Sajdak¹, Dariusz Szpurek²
¹Poznan University of Medical Sciences, Division of Gynecological Surgery, Poznan, Poland
²Private Medical Practice Dariusz Szpurek-, 32/4 Szychalskiego St, Poznan, Poland

Background

The aim of this study was to assess the impact of local postoperative estrogenization on the satisfaction in patients after surgical treatment of stress urinary incontinence with the use of the mini sling (Ophira).

Methods

A group of 119 patients aged 35 to 72 with diagnosed stress urinary incontinence without accompanying prolapse of the anterior vaginal wall and without a neurogenic component was qualified for this study at the Division of Gynecological Surgery Poznan University of Medical Sciences in the years 2016-2022.

Results

The results were obtained on the basis of surveys conducted with patients qualified for the study. The use of postoperative local estrogenization was considered to be the intravaginal application of commercially available estriol drugs. In 108 (90.75%) patients there was an improvement in symptoms related to stress urinary incontinence, and the effect of full continence was achieved in 91 (76.47%). Only 87 patients (73.1%) from the study group used postoperative local estrogenization, but as many as 82 patients from this group noticed an improvement in stress urinary incontinence. One patient who was not using estrogen therapy developed tape erosion.

Conclusions

The use of postoperative local estrogenization has a significant impact on the satisfaction of patients treated for stress urinary incontinence and should be used routinely in each patient, provided that there are no contraindications.

Comparing the outcomes and effectiveness of laparoscopic and vaginal uterosacral ligament suspension in the treatment of pelvic organ prolapse - a systematic review and meta-analysis

Athanasios Douligeris¹, Eleftherios Zachariou¹, Nikolaos Kathopoulos¹, Konstantinos Kyriotis¹, Ioannis Chatzipapas¹, Athanasios Protopapas¹

¹1st Department of Obstetrics & Gynecology- "Alexandra" General Hospital- National and Kapodistrian University of Athens, Endoscopic Surgery Unit, Athens, Greece

Background

Uterosacral ligament suspension (USLS) is one of the most commonly performed operations for the restoration of apical support in women with pelvic organ prolapse. Nowadays, with the increasing application in clinical practice of laparoscopic techniques uterosacral ligament suspension can be performed either laparoscopically or vaginally. However, studies investigating which of the aforementioned surgical access route is superior, are still inconclusive. The aim of the current study was to compare the efficacy and safety of laparoscopic uterosacral ligament suspension (L-USLS) and vaginal uterosacral ligament suspension (V-USLS) through an updated systematic review and meta-analysis.

Methods

We performed a systematic literature review of different databases and related references from their inception until April 2023 without language restrictions. All comparative studies that compared L-USLS and V-USLS for the management of pelvic organ prolapse were finally included. Meta-analysis was performed with RevMan 5.4 software (Copenhagen: The Nordic Cochrane Centre, The Cochrane Collaboration, 2020), with mean differences (MDs), pooled odds ratios (OR) and random-effects model. The methodological quality of the studies which were finally included was assessed by two authors using the Risk of Bias in Non-Randomized Studies of Interventions (ROBINS-I) tool.

Results

Data from 5 retrospective cohort studies on 856 patients were extracted and analysed. The pooled results revealed that L-USLS was associated with a significantly decreased incidence of ureteral compromise (705 patients; OR, 0.19; 95% CI 0.04 to 0.89; $p = .04$) and significantly lower composite prolapse recurrence rate (856 patients; OR, 0.49; 95% CI 0.27 to 0.88; $p = .02$). There were no significant differences between the rates of postoperative pain from USLS sutures, the incidence of postoperative pelvic hematomas, the suture exposure/granulation tissue rates and the prolapse recurrences retreated with surgery rates among the two groups.

Conclusions

The current study showed comparable efficacy between L-USLS and V-USLS. Though L-USLS was associated with less ureteral compromise rates and a lower composite prolapse recurrence rate. However, large-scale randomized studies are still needed to determine the superiority of laparoscopic over the vaginal approach thus, the choice of surgical procedure with either L-USLS or V-USLS is according to surgeon discretion and patient preferences.

Laparoscopic Lateral Hysteropexy for apical and anterior pelvic floor prolapse: short term experience in our centre.

Ángela María García De La Chica¹, Juan Antonio Solano¹, Juan José Delgado¹, Jerónimo González¹, Ángel Miguel González¹, Álvaro Zapico¹

¹Hospital Universitario Príncipe de Asturias, Gynecology and Obstetrics, Alcalá de Henares. Madrid, Spain

Background

The aim of the study was to describe our experience and to evaluate the efficacy in short-term follow-up in patients that underwent Laparoscopic Lateral Hysteropexy for apical and anterior compartment prolapse in our centre.

Methods

A database was made including all women that underwent a Laparoscopic Lateral Hysteropexy with TiLoop® mesh in our hospital. We have retrospectively analysed patients with symptomatic apical and anterior compartment pelvic organ prolapse from December 2021 to March 2023. Prolapses were classified by Baden-Walker system.

Different items such as age, Body Mass Index, parity, newborns with >4000g weight, previous pelvic floor surgery, tobacco, presence/absence of urinary incontinence were included in our database. All surgical procedures were performed by trained surgeons in laparoscopy by a standardized technique.

Results

A total of 21 patients were included in our study. The mean age was 64 years old (47-78 years old) and mean Body Mass Index was 25 (21-35). According to previous obstetrics background, the mean parity was 2 (0-3) and only 1 patient (4.8%) had a newborn that weighted >4000g at born. The delivery was via caesarean section in only 1 patient (4.8%).

All cases were symptomatic and had an apical or anterior or both pelvic floors prolapse. 14 patients (66%) had an IV grade and 7 patients had III grade prolapse. 3 patients (14.3%) had also posterior compartment prolapse which was a perineal tear in 2 patients (9.5%) and a rectocele grade I in 1 patient (4.8%) that were surgical repaired at the same time via vaginal. 2 patients (9.5%) had a vaginal cuff prolapse. 3 patients (14.3%) had a previous pelvic floor surgery: 2 patients had a vaginal hysterectomy and 1 patient had a posterior compartment surgical repair.

Regarding surgical process in 13 patients (61.9%) lateral laparoscopic hysteropexy was performed, in 3 patients (14.3%) lateral laparoscopic hysteropexy and double adnexectomy was performed, in 5 patients (23.9%) lateral laparoscopic hysteropexy and perineoplasty was made. Mean surgical time was 152 minutes (100-170 minutes). Only 2 patients (9.5%) had complications: 1 patient (4.8%) had a surgical wound infection and the other had a vesical perforation. Re-intervention was only needed 1 patient with multiple abdominal surgeries due to intestinal obstruction in an acute diverticulitis, but not because of failure of the technique.

Mean follow up was 7 months. None of the patients had an apical compartment prolapse or urinary incontinence.

Conclusions

Lateral laparoscopic hysteropexy with TiLoop® mesh is a surgical option to repair apical and anterior compartment pelvic floor prolapse in patients in which uterine-sparing technique is desired. Not only for the anatomical restoration but also for the patient's sexual function and the improvement in quality of life. In our study, recurrence rate was not described but longer follow up is required.

Gehad's modified sacrohysteropexy

Amr Gehad¹, Ayman AbdelKader¹, Ramy Gamea¹, Nikola Sambandan¹

¹Homerton University Hospital, Obstetrics and Gynaecology, London, United Kingdom

Background

Female genital prolapse is a global burden affecting the quality of life of a significant number of earth's population. It can be as high as 40-50% of women at different ages but more common after the age of 50. Up to 10 percent of women are symptomatic and the rest were diagnosed on examination. Uterine prolapse is the most common type of uterine prolapse accounting for nearly 50% of prolapse cases. Moreover, uterine preservation surgery is becoming more frequently done.

Methods

Traditionally the uterus could be fixed using either a vaginal or an abdominal approach. The vaginal approach is widely accepted as there is no use of a mesh. The standard techniques involve a longitudinal posterior vaginal wall incision starting from the posterior fourchette up to the posterior fornix. Lateral dissection in the ischioanal fossa is performed to reach the sacrospinous ligament. Suture are subsequently placed to fix the cervix to the lateral part of the ligament at least 2.5cm from the ischial to avoid injury of the vessels and nerves.

A modified access has been adopted which involves a transverse incision in the vagina at the cervicovaginal junction after vasoconstrictor injection. Posterior peritoneum should not be incised. Lateral dissection of the vagina is performed to reach the sacrospinous ligament is performed. Using Capiro Slim two sutures are placed in the ligament and the other end is sutures in the posterolateral aspect of the cervix at the distal most part of the cervix to achieve maximum elevation of the prolapsed uterus. Closure of the vaginal wall is performed using continuous underrunning sutures. The Sacrospinous sutures are then tied to lift the uterus to be attached to the ligament,

Results

The procedure was performed as a day case for all cases. As the procedure avoids incision in the skin and the perineum, patients have reported minimal pain relief required. There is also a reduced need for low molecular weight heparin as the procedure did not exceed 60 minutes. Follow up in 3 months post-surgery showed improved POP-Q score and QoL score.

Conclusions

The modified access provided equivalent prolapse correction results with lower pain scores and smoother recovery due to avoidance of perineal skin and muscles incision in cases not requiring posterior vaginal wall repair. Blood loss was not increased as the access did not involve significant vaginal tissue dissection as well as avoiding rectal fascia damage, hence vaginal packing was not required.

Vaginal and abdominal routes in the treatment of apical pelvic organ prolapse

Alexandr Popov¹, Ivan Klyushnikov¹, Seldzhan Gadzhieva¹, Elena Efremova¹, Svetlana Tiurina¹
¹Moscow Regional Institute of Obstetrics and Gynecology, Gynecology, Moscow, Russia

Aim

Comparative study for the long-term outcomes of transvaginal sacrospinous fixation using polypropylene tape with the laparoscopic and robot-assisted sacrocolpopexy. According to evaluated results, some points for surgical preference were obtained.

Background

Although cystocele appears to be the most frequently recognized type of POP, most women who suffer from cystocele at or beyond the hymen typically also have a component of apical support loss concomitantly. There are many surgical alternatives for the treatment of pelvic organ prolapse of each compartment. Methods evolved through autologous fascia reinforcement to graft implantation, but now it's being prohibited in many countries for specific and hard treatable complications. Many gynaecological surgeons nowadays prefer to minimize the number of allografts to combine its effectiveness while lowering potential risks. And since there are no guidelines for which an apical support procedure should be performed more studies should be made to make it clear.

Materials / Patients

Multicentre longitudinal study was conducted on 160 patients with III-IV grade apical prolapse (excluding vault prolapse) with absence or grade I-II anterior or posterior prolapse, that underwent genital prolapse surgery during 2013-2022 yy. Women were divided into two groups: in 1st group (n=80) anterior sacrospinous fixation using polypropylene tape was performed; in 2nd group (n=80) performed sacrocolpopexy by mini-invasive route – laparoscopically or robotically in a standard fashion. Long-term assessment included observation of patients each year after surgery including bimanual examination and international validated questionnaires (PFDI-20, PFIQ-7, PISQ-12) for anatomical and functional outcomes respectively.

Methods / Results

Average follow-up was 15,4±3,6 and 50,0±9,3 months in I and II group respectively. There was no recurrence of apical prolapse in sacrospinous fixation group and 1,3% in patients after sacrocolpopexy. According to questionnaires and their minimal clinical important difference results, both groups showed comparable sexual life improvement (66,7% and 94,3% according to PISQ-12 questionnaires in I and II group respectively) and I group showed better pelvic floor dysfunction symptom relief and social life improvement (71.3% for the PFDI-20 and 80.2% for the PFIQ-7) comparing to results in II group (82,5% for the PFDI-20 and 78,8% for the PFIQ-7).

Discussion

Early outcomes illustrate that sacrospinous fixation has comparable anatomic and functional results providing apical suspension with lower amount of polypropylene.

Conclusion

Patient stratification for the route selection should be considered according to the next points:1) Co-morbidity that can serve as contraindications for patient positioning or anaesthesia type during the intervention.2) Prior genital prolapse surgery. It's preferable to perform secondary POP surgery by a different route, if the previous one was failed.3) Patient's intentions for preserving the uterus.4) Age of the patients and their social status and sexual activity.

Impact to Patients' Health

No negative impact to Patients Health

Feasibility and safety of vNOTES for gynaecological procedures in obese patients

Colin Simonson¹, Yannick Hurni¹, Daniela Huber¹
¹Hôpital du Valais, Obstetrics and Gynecology, Sion, Switzerland

Background

Obese patients are increasingly encountered in gynaecological surgery, representing a challenge for both surgeons and anaesthesiologists. Obesity does not seem to represent a contraindication to vNOTES [7], but little is known about its impact on the feasibility and safety of this surgical approach. This study aimed to determine the feasibility and safety of transvaginal natural orifice transluminal endoscopic surgery (vNOTES) to treat benign and malign gynaecological conditions in obese patients.

Methods

We analysed data from 79 obese patients with a body mass index > 30 Kg/m² operated by vNOTES for gynaecological conditions between May 2020 and April 2023. We analysed demographic features, as well as clinical and perioperative information. The primary outcome was the feasibility of performing the surgery as initially planned, considering the conversion rate to other approaches than vNOTES, and the rate of uncompleted procedures for any reason. Secondary outcomes included the duration of the surgery; the intraoperative complications rate and type; the postoperative complications rate and type; the length of hospital stay; and the postoperative pain evaluation. Data were presented for subgroups of patients with obesity class I, class II, and class III. Differences between the subgroups were analysed.

Results

The median age was 51 (32 – 79) years, and the median body mass index was 35.2 (30.1 – 49.4) kg/m². Patients presented obesity class I in 39 cases (49.4 %), class II in 27 cases (34.2 %), and class III in 13 cases (16.4 %). Fifty-two patients (65.8 %) underwent vNOTES hysterectomy, 26 patients (32.9 %) underwent procedures limited to the adnexa, and 1 patient (1.3 %) underwent myomectomy. The median operative time was 91 (44 – 193) minutes for vNOTES hysterectomy and 51 (18 – 56) minutes for adnexal surgeries. All procedures were successfully performed, but conversion to conventional laparoscopy was necessary to complete the intervention in 4 cases (5.1 %). The conversion rate was 0 %, 11.1 %, and 7.7 % in obesity class I, II, and III, respectively. Intraoperative complications were observed in 3 cases (3.8 %), with bladder injury in 1 (1.3 %) obesity class I patient and rectal serosal tear in 2 patients (2.5 %), 1 obesity class II patient, and 1 obesity class III patient. Postoperative complications were observed in 6 patients (7.6 %), with 3 cases (3.8 %) of wound infection (CD grade 2), 2 cases (2.5 %) of cystitis, and 1 case (1.3 %) of deep vein thrombosis (CD grade 2).

Conclusions

This study demonstrated the feasibility and safety of performing gynaecological vNOTES procedures in obese patients. This surgical approach could be a valuable alternative to conventional laparoscopy. However, obesity could be associated with longer and more complex interventions, especially in obesity class II and III patients.

Uterine contractility during intra-uterine device (IUD) insertion and patient pain experience

Connie Rees^{1,2,3}, Sophie Thomas¹, Liselot Wagenaar^{1,3}, Yizhou Huang², Massimo Misch², Dick Schoot^{1,2,3}
¹Catharina Hospital, Gynaecology and Obstetrics, Eindhoven, The Netherlands
²Eindhoven University of Technology, Electrical Engineering, Eindhoven, The Netherlands
³Ghent University Hospital, Reproductive Medicine, Ghent, Belgium

Background

Patient pain experience can vary largely during IUD placement. It is unknown if differences in uterine contractility may explain these variations in patient pain experience. To this end, we aimed to assess the effect of IUD insertion of uterine contractility (UC), and to assess the relationship between UC and patient pain experience.

Methods

This ongoing prospective observational cohort study is taking place in a non-academic teaching hospital in the Netherlands. We included 28 patients undergoing IUD insertion in our outpatient clinic. Each patient underwent a 4-minute transvaginal ultrasound (TVUS) of the uterus in mid-sagittal section directly prior to, and directly after, IUD placement. VAS scores for pain were collected at time of placement. TVUS recordings were analysed using an automated 2D speckle tracking method for: uterine contraction frequency (CF, contractions/minute), amplitude, velocity (mm/sec), and coordination. Patients were included regardless of hormonal therapy and cycle phase. Between-subject analysis was conducted using the independent t-test and/or shapiro-wilk test, and within-subject analysis using the paired t-test. Patient VAS scores were stratified to mild and/or moderate pain (VAS below 7) and severe pain (VAS of 7 or higher).

Results

Mean age was 31.6 years (SD \pm 11.3), most patients were nulliparous (17/28). 17/28 patients were using oral hormonal contraception at time of IUD insertion. Mean uterine length was 67.2mm (SD \pm 12.0). Median reported VAS was 7.00 (IQR 3.00). Only CF increased after IUD placement (pre-IUD 1.50 (SD \pm 0.35) vs. post-IUD 1.70 (SD \pm 0.30), $p < 0.001$). No other UC features were affected by IUD insertion ($P > 0.05$). Patients with a severe VAS showed higher CF (1.64 (SD \pm 0.56) vs. 1.48 (SD \pm 0.20), $p = 0.025$) and a lower contraction amplitude (35.9 (SD \pm 3.0) vs. 25.7 (SD \pm 11.3)), $p = 0.013$.

Conclusions

UC is affected by IUD insertion, with initial analyses pointing towards (changes in) specific uterine features and patient pain experience. Namely uterine contraction frequency and amplitude difference may be most involved in pain experience associated with IUD insertion. Future studies should investigate the effect of cycle phase, parity and potential uterine pathologies on pain sensation, and confirm these findings in a larger population.

Uterine contractility of adenomyosis patients normalises under hormonal contraception use

Sophie Thomas¹, Connie Rees¹, Cynthia Klaassen¹, Yizhou Huang², Brunella Zizolfi³, Dick Schoot¹
¹Catharina Hospital, Gynaecology and Obstetrics, Eindhoven, The Netherlands
²Eindhoven University of Technology, Electrical Engineering, Eindhoven, The Netherlands
³University of Naples - Federico II, Medicine, Naples, Italy

Background

Previous studies have shown that uterine contractility differs between adenomyosis patients and patients with healthy uteri without symptoms. Hormonal therapy is the first line treatment for adenomyosis symptoms, with generally good results. It is not yet clear however if these aberrant contractions normalise under hormonal therapy, and if they may thus be a potential therapeutic marker for medicinal adenomyosis treatment.

Methods

In this ongoing multicentre prospective observational cohort study, we aimed to compare of uterine contractility (UC) in adenomyosis patients (AP) with and without hormonal contraception (HC) to healthy controls with HC, measured by transvaginal ultrasound (TVUS).

36 women with sonographic suspicion of adenomyosis without HC, 15 women with sonographic suspicion of adenomyosis with HC and 17 women with healthy uteri with HC were included from participating centres. HC included oral combined hormonal contraception, progesterone only pill, and hormonal IUD. Uterine contraction frequency, amplitude, velocity, and coordination were assessed by applying a dedicated speckle tracking and strain analysis to 4-minute TVUS recordings in midsagittal section. AP with HC were compared to AP without contraception and healthy controls with HC.

Results

Age, BMI, parity and uterus volume were significantly higher in the women with adenomyosis compared to the healthy controls ($p < 0.05$). The adenomyosis group with contraception compared to without hormonal contraception treatment showed a lower amplitude (0.46 ± 0.02 vs. 0.60 ± 0.03 , $p = 0.022$) and reduced contraction coordination (0.22 ± 0.12 vs 0.28 ± 0.13 , $p = 0.049$) compared to the adenomyosis group without hormonal contraception treatment. There were no significant differences in UC between the adenomyosis group with HC compared to the healthy control group with hormonal contraception treatment.

Conclusions

The normalisation of UC under therapeutic use of HC compared to untreated AP, and the lack of differences in UC between AP and healthy controls with HC, confirms the therapeutic effect on adenomyotic symptoms. This presents a new therapeutic efficacy marker for adenomyosis.

Clear cell carcinoma on endometriosis in surgical scar

Cristian De Guirior¹, Meritxell Gracia¹, Mariona Rius¹, Isabel Matas¹, M^a Ángeles Martínez-Zamora¹, Francisco Carmona¹

¹Hospital Clínic Barcelona, Gynecology, Barcelona, Spain

Background

Endometriosis in surgical scars or incisional endometriosis, is a rare condition characterized by the presence of endometrial tissue within surgical scars. Scar endometriosis occurs when endometrial tissue becomes implanted within the scar tissue that forms after a surgery, such as a caesarean section, hysterectomy, or laparoscopic procedure. It is believed to arise from the accidental transfer of endometrial cells to the surgical site during the procedure. These cells can subsequently implant and grow within the scar tissue, leading to scar endometriosis.

Scar endometriosis typically presents as a nodular or raised lesion within the surgical scar. It is commonly associated with symptoms such as cyclic pain that coincides with the menstrual cycle, localized tenderness, swelling, and the presence of a palpable mass. In some cases, scar endometriosis may also be asymptomatic.

The treatment of scar endometriosis typically involves surgical excision of the lesion. Complete removal of the endometriotic tissue along with the surrounding scar tissue is crucial to prevent recurrence. In some cases, hormonal therapy may be prescribed to suppress the growth of endometrial tissue and alleviate symptoms.

Methods

A 34-year-old woman with a history of a caesarean section in 2012 was subsequently diagnosed with endometriosis due to the presence of deep endometriosis (nodule in the rectovaginal septum) and adenomyosis 2 years later. In addition, an endometriosis nodule was identified on the scar of the previous caesarean section within the fascia measuring 18x8x12mm. Hysterectomy, double salpingectomy by laparoscopy and the excision of the endometriosis scar nodule by laparotomy was performed. The pathological anatomy report confirmed the adenomyosis and endometriosis on the caesarean scar. Subsequent ultrasound scans were negative.

In 2023 (9 years later) the patient reconsulted due to palpation of a nodule on the caesarean scar again. An MRI was performed which reported a 61x43x53mm intramuscular mass protruding into the subcutaneous fat without intraabdominal extension suggesting endometriosis in surgical scar again.

Results

Further surgery was performed to remove the nodule which was firmly attached to the fascia and muscle with no extension into the abdominal cavity or skin. The result of the pathological anatomy was clear cell carcinoma over adenofibroma.

Conclusions

Clear cell carcinoma is a specific type of ovarian cancer that has been found to have a strong association with endometriosis. The relationship between endometriosis and clear cell carcinoma has been the subject of extensive research, although the exact mechanisms underlying this association are not fully understood but chronic inflammation, hormonal factors, and genetic alterations are believed to play a role. Understanding this association can aid in early detection and appropriate management strategies for women with endometriosis, potentially improving patient outcomes.

Current practice in the management of endometriomas: what should you do?

Pavle DIMITRIJEVIC¹, Benedetto Mondelli¹, Michael Adamczyk¹

¹Ashford and St Peter's Hospitals, Centre for Endometriosis and Minimally Invasive Gynaecology, Chertsey, United Kingdom

Background

Endometriosis is thought to be prevalent in up to 15 percent of women with an estimated 176 million people worldwide affected. Of these, it is estimated that between 17-44% will have the presence of endometriomas. Many of these patients who present are in reproductive age, therefore, proper consultation regarding the implication of surgery on endometriomas is vital. Laparoscopic management of endometriomas has evolved during the last few years with more techniques now available.

Methods

This presentation will discuss the various surgical techniques currently used in the laparoscopic management of endometriomas (Drainage, Excision, Sclerotherapy and Laser Ablation). The benefits and complications of each technique, rate of reoccurrence of endometriomas, fertility rate, as well as the impacts of each technique on ovarian reserve will be highlighted.

Results

We completed a review of global literature using articles on PubMed that addressed the management of endometriomas. Retrieved articles were hand searched to identify other suitable literature that might have been missed in the initial search.

Conclusions

By completing this literature review we have been able to create an easy-to-use presentation detailing the current laparoscopic options available. We believe that a personalised approach to the selected choice of laparoscopic treatment of endometriomas in women should be used. This involves taking into account the age of the patient, their previous surgical history as well as their desires for fertility.

Patient, Perioperative Planning...Perfect Outcome? The 3 Ps of deep infiltrating endometriosis

Pavle Dimitrijevic¹, Benedetto Mondelli¹, Rakesh Thing¹, Ahmed Abdullahi¹, Michael Adamczyk¹, Pasha Nisar²
¹Ashford and St Peter's Hospitals, Centre for Endometriosis and Minimally Invasive Gynaecology, Chertsey, United Kingdom

²Ashford and St Peter's Hospitals, Colorectal Surgery, Chertsey, United Kingdom

Background

1-2% of women affected by endometriosis present with deep infiltrating disease (DIE). Often there is a degree of involvement of the rectosigmoid colon that can vary from superficial disease involving the POD peritoneum to full thickness bowel disease. There is general consensus that excision is the gold standard for the treatment of DIE, however, intraoperatively it is often difficult to assess the depth of invasion of endometriosis.

Methods

We believe pre-operative planning plays a fundamental role in the successful management of deep endometriosis. When dealing with disease which infiltrates different structures it is vital to have a clear plan regarding the type of procedure that will be performed before the day of the operation.

This involves arranging appropriate imaging, discussing the case with different members of the multidisciplinary team and informing the patient. In this presentation we highlight the different steps that are required to plan surgery for full thickness bowel disease.

Results

In our case, following extensive investigations the patient underwent transanal disc resection for full thickness bowel endometriosis.

The review of the images in a multidisciplinary team setting and discussion between specialists is paramount to successfully discriminate patients that can be treated with shave rather than a segmental bowel resection or a disc resection.

Conclusions

Through this presentation we show the importance of early planning and how a structured MDT approach to deep infiltrating endometriosis can lead to a personalised and coordinated surgical strategy. This ensures that the appropriate surgery is performed and ultimately leads to improved outcomes.

The natural history of endometriosis in pregnancy: an ultrasound study of the morphological features of deep endometriosis (DE) and ovarian endometrioma

Elisabeth Bean¹, Jure Knez², Thulasi Setty¹, Amos Tetteh¹, Davide Casagrandi¹, Davor Jurkovic¹

¹University College London Hospital, Women's Health, London, United Kingdom

²University Hospital Maribor, Gynaecology, Maribor, Slovenia

Background

Deep endometriosis and endometrioma subtypes are thought to affect approximately 5% of women in pregnancy. Pregnancy has a major effect on the size and morphological features of endometrioma, with published studies reporting a tendency for cyst regression. Decidualization of endometriomas, a hormonally induced pregnancy-related phenomenon, may raise suspicion of an ovarian malignancy. The behaviour of deep endometriosis in pregnancy is poorly understood and there is limited available literature. Our aim was to study the morphological features and behaviour of ovarian endometrioma and deep endometriotic nodules during pregnancy.

Methods

This was a prospective observational cohort study conducted over three years at University College London Hospital. We included 65 women with a viable normally-sited pregnancy and concomitant ultrasound features of deep and/or ovarian endometriosis. All women were invited for surveillance ultrasound examinations at the time of their routine scans in pregnancy. All scans were performed by a single operator to minimise interobserver error. The change in size of endometrioma and nodules were reported as change in their mean diameter. Endometrioma with irregular thick inner walls, hyperechoic papillary projections and/or high vascularity and hyperechoic nodules with moderate to high vascularity were reported as decidualized.

Results

Sixty-five women were included in the study. Their median age was 34 years (23-44), 47/65(72%) were nulliparous, 48/65(74%) had a background of endometriosis and 19/65(29%) conceived following IVF. There were 10/65(15%, 95%CI 7-24) women with endometrioma alone, 28/65(43%, 95%CI 31-55) with nodules alone and the remaining 27/65(42%, 95%CI 30-54) had both.

29/34(85%, 95%CI 73-97) women with endometrioma experienced cyst regression, 2/34(6%, 95%CI 0-14) experienced cyst growth and in 10/34(29%, 95%CI 14-45) there was complete resolution of all cysts. 43/51(84%, 95%CI 74-94) women with nodules experienced nodule regression, 2/51(4%, 95%CI 0-9) experienced nodule growth and in 4/51(8%, 95%CI 0-15) there was complete resolution of all nodules. 5/37(14%, 95%CI 3-25) women who attended postnatal follow-up, experienced complete resolution of all endometriotic lesions during pregnancy.

In 10/34(29%, 95%CI 14-45) women with endometrioma and 27/51(53%, 95%CI 39-67) with nodules, a pattern of growth was observed in the first and second trimesters, which preceded regression in later pregnancy. Features of decidualization were observed in 17/34(50%, 95%CI 33-67) women with endometrioma, most commonly in the 1st trimester, and 25/51(49%, 95%CI 35-63) women with nodules, most commonly in the 2nd trimester.

Conclusions

For the majority of women, despite features of decidualization being common in the first and second trimesters, endometrioma and deep nodules will regress during pregnancy. Sonographic changes of endometriosis in pregnancy are difficult to differentiate from characteristics of malignant lesions. Better understanding of the appearance of endometriosis in pregnancy is vital to reduce unnecessary surgical procedures, associated morbidity to mothers and babies and will help clinicians to counsel women regarding the significance of their condition.

Is there a correlation between histological diagnosis of adenomyosis and TCGA molecular classification in patients with endometrial cancer? An observational retrospective double-centre cohort study

Agnese Virgilio¹, Diego Raimondo², Francesco Mezzapesa¹, Emanuela Spagnolo³, Renato Seracchioli¹, Paolo Casadio²

¹Division of Gynecology and Human Reproduction Physiopathology- IRCCS Azienda Ospedaliero-Universitaria di Bologna- Bologna- Italy,

Department of Medical and Surgical Sciences DIMEC- University of Bologna- Bologna- Italy, Bologna, Italy

²Division of Gynecology and Human Reproduction Physiopathology- IRCCS Azienda Ospedaliero-Universitaria di Bologna- Bologna- Italy,

Division of Gynecology and Human Reproduction Physiopathology- IRCCS Azienda Ospedaliero-Universitaria di Bologna- Bologna- Italy, Bologna, Italy

³La Paz University Hospital, Gynecologic Oncology Unit, Madrid, Spain

Background

The most recent studies suggested that patients with endometrial cancer (EC) and adenomyosis showed a decreased risk for unfavourable histological prognostic, the presence of specific molecular signature was proposed to explain the better survival outcomes and less unfavourable histological factors among women with EC and adenomyosis. The principal aim of this study was to assess the prevalence of The Cancer Genome Atlas (TCGA) Research Network molecular groups classification, through Proactive Molecular Risk Classifier for Endometrial Cancer (ProMisE), in EC patients with adenomyosis and to evaluate the association of TCGA prognostic groups among these, trying to clarify the mechanisms at the basis of better prognosis reported in EC patients with adenomyosis.

Methods

This was a double centre, observational, retrospective, cohort study. Medical records and electronic clinical databases were searched for all consecutive patients who underwent surgical staging for EC, according to ProMisE classifier evaluation on final surgical specimen, at two tertiary level referral centres for gynaecological cancer (S. Orsola Hospital, University of Bologna, Bologna, Italy; University of Bologna, Italy and at the Oncology Gynecology Unit of La Paz University Hospital - IdiPAZ, Madrid, Spain) from September 2020 to September 2022. EC patients were divided into two groups based on presence of adenomyosis on final surgical specimen: patients with adenomyosis (adenomyosis group) and patients without adenomyosis (no adenomyosis group). The two groups were compared in terms of demographic, clinical, surgical, pathological and molecular data.

Results

During the study period 147 EC patients were included in the study: 38 (25.8%) in the adenomyosis group and 109 (74.1%) in the no adenomyosis group. No statistically significant difference between adenomyosis and no adenomyosis group was found in terms of clinical data, tumour characteristics, positive sentinel lymph node, pelvic and paraaortic lymphadenectomy, adjuvant treatment. Median age (range) at surgery was 62 (38-84) years in the adenomyosis group and 64 (28-92) years in the no adenomyosis group. Most of EC were early FIGO (Federation of Gynecology and Obstetrics) stage (89.5% in adenomyosis group and 82.6 % in no adenomyosis group), low grade (78.9% in both groups) and showed endometrioid histotype (89.5% and 84.4% in adenomyosis and no adenomyosis respectively). The most frequent molecular signature among EC patients with coexistent adenomyosis was NSMP (No Specific Molecular Pattern) (i.e., copy-number low group) (52.6%). No significant association between TCGA molecular prognostic groups and adenomyosis in EC patients was found

Conclusions

To the best of our knowledge, this may be the first study to investigate the TCGA molecular signature of EC with coexistent adenomyosis. NSMP was the most frequent molecular signature found of EC with adenomyosis. However, no statistically significant correlation between TCGA prognostic group and adenomyosis was reported. Future larger studies are needed to confirm and further investigate these findings.

Ethanol sclerotherapy for ovarian endometrioma: to whom and when?

Alexandr Popov¹, Maya Ovsiannikova¹, Yulia Sopova¹, Anton Fedorov¹, Svetlana Tiurina¹, Anastasia Bespalova¹
¹Moscow Regional Institute of Obstetrics and Gynecology, Gynecology, Moscow, Russia

Aim

To assess the impact of operation on ovarian reserve, serum anti-Müllerian hormone and antral follicle count was measured before surgical treatment and 3 months after that.

Background

Ethanol sclerotherapy is effective and safe method of surgical treatment for ovarian endometrioma. Destruction with 95% ethanol solution of the capsule allows minimal impact on the ovarian reserve. However, this method should be thoroughly evaluated for the possibility to be used more frequently in practice.

Materials / Patients

46 patients aged 24 to 43 years with endometrioma were operated in the Moscow Regional Research Institute of Obstetrics and Gynecology. Group I included 35 patients - traditional laparoscopic cystectomy. Group II - ethanol sclerotherapy included 11 patients, 5 of which were performed by transvaginal access with ultrasound control, 6 - by laparoscopic access. 15 (32.6%) of patients had been previously operated because of OMA. Clinical manifestations included pelvic pain (71.7%), dysmenorrhea (73.9%), dyspareunia (32.6%), bowel symptoms (32.6%) and infertility (76.0 %).

Methods / Results

Mean difference of serum AMH was 2.41 ng/ml before and after surgery in the cystectomy group. In second group it was 0.75 ng/ml. Mean difference of antral follicle count in the both ovaries were 2.5 after surgery in stripping-group and 1.3 in sclerotherapy-group. 44 out of 46 women were on anti-recurrent hormone therapy after surgery: dienogest (85.3%), combined oral contraceptives, which included dienogest (5.8%), GnRh-agonists (5.8%), Levonorgestrel IUD (3.1%). In the group I there was 2 recurrences (5.7%) of endometrioma. While in the group II with ultrasound control after 3, 6 and 12 months there were 4 relapses (36.3%). The diameter of these cysts did not exceed 26 mm and remained the same after 12 months of control observation. Symptoms returned in 5 (14.2%) women in the stripping-group and 3 (27.2%) women in the sclerotherapy-group. No intraoperative complications were noted.

Discussion

What's about recurrence? Nevertheless, it must be understood that the cyst wall cannot completely disappear on ultrasound after sclerosing in some cases.

Conclusion

Preliminary results allow us to recommend the following options for the use of sclerotherapy:

1. For the OMA in women of reproductive age and patients planning pregnancy by ART with a reduced ovarian reserve. The application of the technique is possible transvaginal with ultrasound control and laparoscopic accesses
2. Recurrent, previously histologically confirmed, endometriomas. Transvaginal access is applicable for cysts of small diameter from 3 to 7 cm, laparoscopic access is applicable for cysts of larger diameter from 5 to 12 cm because of visual control of the area of contact between the capsule and the ethanol
3. Transvaginal access is applicable for women with symptomatic endometriomas and big number of operations in the past.

Impact to Patients' Health

No negative impact to patients' health

Diagnostic and treatment of ileocecal endometriosis

Alexandr Popov¹, Vlada Troshina¹, Konstantin Puchkov², Yulia Sopova¹, Anton Fedorov¹

¹Moscow Regional Institute of Obstetrics and Gynecology, Gynecology, Moscow, Russia

²Swiss Clinic, Gynecology, Moscow, Russia

Aim

Objective of the study: to upgrade the results of surgical treatment of ileocecal endometriosis by improving the methods of diagnosis and surgical technique.

Background

Nowadays in diagnosis and treatment of deep infiltrative endometriosis many issues remain unresolved. Ileocecal endometriosis is often asymptomatic and is not always visualized with ultrasound and MRI. Thus, thorough preoperative diagnosis of lesions in this area raises difficulties.

Materials / Patients

From 2013 to 2023, 76 patients with ileocecal endometriosis were operated in the Moscow Regional Research Institute of Obstetrics and Gynecology and the Swiss University Clinic. All surgeries were performed by laparoscopic or robot-assisted laparoscopic access.

Methods / Results

48.6% of patients had been previously operated because of various forms of endometriosis including deep infiltrative ones. Performed: appendectomy 24 (42,9 %), resection of the cecum 9 (16,1 %), shaving of the ileum 7 (12,5%), ileocecal resection 3 (5,4 %), right hemicolectomy 6 (10,7%). The observation group (patients who did not have radical surgical treatment) includes 21 patients (27,6 %). The idea is to understand whether the coagulation of heterotopia and/or shaving with continued conservative therapy is feasible in asymptomatic cases. Appendectomy and resection of the cecum were performed with the usage of endoscopic staplers. End-to-end anastomosis was used to carry out intestinal resection. Shaving was conducted by mandatory suturing of the wound in the transverse direction with seromuscular sutures.

Discussion

Difficulties of diagnostic of ileocecal endometriosis: asymptomatic, not always visualized with ultrasound and MRI, can mimic other gastrointestinal diseases. Preoperative differential diagnostics is needed. It is necessary to improve ultrasound examination and MRI. Pay attention on right bowel sides during surgical treatment of endometriosis. It is necessary to improve the diagnosis endometriosis of ileocecal localization. The surgical team must have skills to perform to perform surgeries for deep infiltrative endometriosis.

Conclusion

In the vast majority of cases, we diagnosed ileocecal endometriosis intraoperatively.

The most frequent localization was isolated lesions of appendix 23 cases (41,1 %), followed by ileum 11 cases (19,6 %), appendix + ileum + cecum 9 cases (16,1 %), lesions of appendix and cecum 6 cases (10,7%), in 3 cases appendix + ileum (5,4 %) and, 2 cases of endometriosis of ileum and of the cecum (3,6 %) and 2 cases were found isolated lesions of the cecum (3,6 %).

Impact to Patients' Health

No adverse effects on women's health have been identified

Giant and infiltrating solitary fibrous tumour of the pelvis: a case report

Alessandro Zecchin¹, Michela Zorzi², India Turcatel³, Martin Steinkasserer¹, Giovanni Negri⁴, Matteo Bonatti⁵

¹Azienda Sanitaria dell'Alto Adige - Bolzano Hospital, Gynecology and Obstetrics, Bolzano, Italy

²University of Padua - Padua University Hospital,

Department of Women and Children's Health - Clinic of Gynecology and Obstetrics, Padua, Italy

³University of Bologna - Sant'Orsola Hospital, Gynecology and Human Reproduction Physiopathology, Bologna, Italy

⁴Azienda Sanitaria dell'Alto Adige - Bolzano Hospital, Pathological Anatomy, Bolzano, Italy

⁵Azienda Sanitaria dell'Alto Adige - Bolzano Hospital, Radiology, Bolzano, Italy

Background

Solitary fibrous tumours (SFT) comprise a histologic spectrum of rarely metastasizing fibroblastic mesenchymal neoplasms that are commonly divided into pleural and extra pleural forms, the latter being considered uncommon.

With this article we want to share our experience about diagnosis, treatment and follow up of this controversial entity.

Methods

Patient: 58-years-old woman, PARA 2002, in 2013 laparoscopic supracervical hysterectomy for uterine fibroids.

Magnetic Resonance (MRI): diagnosis of a pelvic mass (11x13x14,5 cm) of probable right adnexal origin without clear cleavage plane with sigma and "ab extrinsic" compression and dilatation of right ureter.

Ultrasound evaluation: pelvic mass of 114x96x102 mm in size with regular margins and inhomogeneous echotexture. Power Doppler showed a moderate vascularization (colour score 3). On dynamic evaluation the mass appeared attached to the sacrum and compressing the bladder and the right ureter. Neither ascites nor pelvic or abdominal carcinomatosis were seen.

CT scan: confirmation of the pelvic mass of probable right adnexal origin with no evidence of pathological lymph nodes or ascites.

Tumour markers: Negative, HE4 81,0 pmol/l.

Laparotomy with a xipho-pubic incision: in the removal of the neoformation it was necessary to excise the right ureter with subsequent ureter cystostomy with Psoas Hitch and to respect the sigma-rectum incorporated in the neoformation. Then we performed a colostomy. Furthermore, it was necessary to partially remove the right external iliac vein infiltrated by the neoplasm. We reconstructed it with the placement of a vascular endoprosthesis. It was difficult to dissociate the mass from the right lateral pelvic wall.

Results

On macroscopic evaluation, the mass was 15x11x12 cm in size, separated from the right salpinx and ovary, with a tense-elastic consistency, white with yellowish areas, and polylobate margins.

The microscopic finding showed a spindle cell mesenchymal neoplasm with focal areas of myxoid degeneration, devoid of significant atypia and mitosis. Immunohistochemistry showed positivity for CD34, STAT6 and were negative for actin, desmin, inibin, calretinin. The Ki67 proliferation index was expressed at 2%.

Follow-up every three months for 2 years was proposed, no evidence of residual disease.

Conclusions

SFT is a controversial entity, mainly benign; however, some of them have an aggressive clinical course with recurrence, invasion and distant metastases.

Our patient had an intermediate risk of malignancy (Metastatic Risk Score = 4), because of age of the patient and tumour size.

To preoperative evaluation both MRI and ultrasound suggested a diagnosis of malignancy, even if regular margins and absence of ascites and tumour markers were not supporting the diagnosis.

The differential diagnosis was between a pathology of the uterine cervix (leiomyoma or leiomyosarcoma), or an adnexal pathology (sex cord-stromal tumours such as fibroma/fibrothecoma, adult granulosa cell tumour).

Concluding, immunohistochemistry was fundamental to define the histological diagnosis, mainly in consideration of the positivity of STAT6 and CD34, which are not represented in the other histotypes mentioned above.

Surgery-to-pregnancy time in women undergoing myomectomy according to surgery indication

Ohad Gluck¹, Dror Raif Neshet¹, Ram Kerner¹, Ran Keidar¹, Ron Sagiv¹, Mikhail Babin¹
¹Edith Wolfson Medical Center, Gynecology, Holon, Israel

Background

The standard of care for symptomatic uterine fibroids in women interested in future fertility is myomectomy which may be done either by hysteroscopy, laparoscopy, or laparotomy, depending on the size, location, and number of fibroids. There is controversy regarding the impact of laparoscopic and open myomectomy on reproductive outcomes. The latter is of special interest in patients with history of infertility undergoing fertility treatments. This study aimed to assess reproductive outcomes in women who underwent laparoscopic and open myomectomy for fertility-related indications compared to other indications.

Methods

This is a retrospective cohort study that included women who underwent laparoscopic and open myomectomy in our hospital between 2008 and 2022. The primary outcome was surgery-to-pregnancy time in women who underwent surgery for fertility-related indications (infertility, recurrent implantation failure, recurrent pregnancy loss). Secondary outcomes included pregnancy rate, the need for fertility treatment, and live birth rate.

Results

Of 117 patients, 37 (31.6%) underwent myomectomy for fertility-related indications and 80 (68.4%) – for other indications (abnormal uterine bleeding, abdominal pain, urinary symptoms). Age and background characteristics were similar in both groups. Surgery-to-pregnancy time was longer in patients who underwent the surgery for fertility-related indications (36.6 months vs. 15.8 mo, $p=0.02$). Pregnancy, assisted reproductive technology (ART) use, and live birth rates were similar between the groups. In subgroup analysis, no difference was found in surgery-to-pregnancy time between women who conceived using fertility treatments as compared to women who conceived spontaneously (25.1 mo vs. 29.5 mo, $p=0.63$). Finally, when compared between surgical approach (laparoscopy vs. laparotomy), there was no difference in pregnancy, ART use, and live birth rates as well as surgery-to-pregnancy time between groups.

Conclusions

Surgery-to-pregnancy interval was longer in women who underwent myomectomy for fertility-related indications compared to those who were operated for other indications. However, the need for ART, pregnancy rate, and live birth rate were similar regardless of the indication for myomectomy.

Necrotic fibroid as a complication of uterine artery embolization for large submucosal fibroid: a case report

Amna Malik¹, Mickey Buckingham¹, Hugh Byrne¹

¹St George's Hospital, Gynaecology, London, United Kingdom

Background

Uterine artery embolization (UAE) is an alternative to surgical interventions for the management of uterine fibroids. Infection is an important complication of UAE, with a reported incidence ranging from 1.2% to 17%. While the majority of cases are self-limiting, intrauterine infection can be severe, necessitating emergency hysterectomy in approximately 0.7% of cases. This case report aims to highlight the occurrence of necrotic fibroid as a complication of UAE for large submucosal fibroids and explore the therapeutic challenges associated with this condition.

Methods

We present the case of a 50-year-old female with a history of heavy menstrual bleeding and radiological evidence of a multifibroid uterus with a dominant submucosal fibroid measuring 16 x 8 x 13cm in size, who opted for UAE. Diagnostic investigations including magnetic resonance imaging (MRI) were utilized to evaluate the extent of necrosis and monitor the therapeutic response.

Results

Three months following UAE, the patient experienced fevers and malodorous vaginal discharge, which led to hospital readmission and intravenous antibiotic therapy. Imaging studies revealed necrosis of the dominant submucosal fibroid with surrounding fluid and gas within the cavity, along with a left pyosalpinx. Despite antibiotic treatment, the patient remained febrile, necessitating a hysteroscopy with an attempt at transcervical resection of the fibroid and drainage of pus. The patient improved but represented with persistent vaginal discharge one month later. Signs of sepsis prompted an examination under anaesthesia, during which significant necrotic fibroid material weighing over 400g was removed from the uterus. Following this intervention, the patient exhibited an excellent recovery, with a subsequent MRI demonstrating a substantial reduction in fibroid size from 16cm to 2cm.

Conclusions

Our findings underscore the complexity of managing necrotic fibroids following UAE for large submucosal fibroids. Moreover, our case highlights large uterine volume and fibroid size as potential risk factors for infective complications after UAE. Gynaecologists should carefully consider these risk factors when evaluating patients for UAE and provide appropriate counselling and close post-procedure monitoring for individuals with large fibroids. Timely surgical intervention can optimize patient outcomes and reduce morbidity in cases of infective complications after UAE. Further research is necessary to evaluate the effectiveness of transcervical resection of fibroid in management of necrotic submucosal fibroid post UAE.

Conjoined twins detected at first trimester scan

Sevasti Koulouraki¹, Vasileios Paschos¹, Emmanouil Kalampokas¹, Olga Triantafyllidou¹, Nikolaos Vlahos¹, Theodoros Kalampokas¹

¹Aretaieion University Hospital- National and Kapodistrian University of Athens, 2nd Department of Obstetrics and Gynecology, Athens, Greece

Background

Conjoined twins are a rare type of monoamniotic twins, estimated to occur in 1.5 per 100,000 births worldwide. Female twins are affected more often than males. The diagnosis should be suspected in first trimester monoamniotic twin pregnancies when the embryonic or foetal poles are closely associated and do not change in position with respect to each other.

Methods

This case concerns a 29-year-old woman with a history of two uncomplicated single pregnancies, who underwent first trimester ultrasound at 12 weeks and 6 days. The scan revealed conjoined twins with dicephalus, fused abdomen, two hands, two lower limbs, exomphalos and increased nuchal translucency of 4.4 mm and a CRL of 37mm dating the pregnancy 10 weeks and 4 days.

Results

The patient was counselled about the non-separability of the conjoined twins and the increased neonatal morbidity and mortality. The patient underwent dilation and curettage with the diagnosis of ventral caudal parapagus. The pregnancy contents were sent for histopathological analysis. The procedure was uncomplicated, and the patient was discharged later that evening.

Conclusions

The diagnosis and management of conjoined twins during the first trimester of pregnancy can be a challenging task for healthcare providers. Although a first-trimester scan can identify multiple pregnancies, it is unlikely to detect conjoined twins due to the small size of the fetuses and the physical connection between them. The diagnosis is typically made during the second-trimester ultrasound, which can provide a more detailed view of the fetuses and their shared organs. This information is crucial in determining the best course of medical management for the pregnancy, including the feasibility and risks of surgical separation and the viability of the neonates. While the diagnosis and management of conjoined twins can be complex and challenging, early recognition and timely intervention can improve outcomes and provide the best possible care for the twins and their families. Overall, the successful diagnosis and management of conjoined twins require a collaborative approach involving a multidisciplinary team of medical professionals, including obstetricians, foetal medicine specialists, and paediatric surgeons.

Incidental finding of ascites during laparoscopic hysterectomy for recurrent cin leading to diagnosis of ovarian malignancy

Naomi Harvey¹, Melanie Tipples¹

¹St Richards Hospital, Obstetrics and Gynaecology, Chichester, United Kingdom

Background

66-year-old patient underwent a laparoscopic hysterectomy, bilateral salpingoopherectomy and pelvic floor repair as a routine procedure to help address both her pelvic prolapse and her recurrent Cervical intra-epithelia neoplasia (CIN) which had persisted despite multiple cervical treatments.

On camera entry via the umbilical port, 800ml of purulent offensive fluid was noted in the abdomen of unknown aetiology. Her planned laparoscopy went without complication and due to the unexpected suspicious ascites, the histology was sent as urgent.

It returned a finding of borderline mucinous tumour of the right ovary with a ruptured capsule and classified the lesion as FIGO 1c.

Methods

A case report of unexpected ascites during a routine laparoscopic hysterectomy with images.

Results

To date, her treatment is dependent on further imaging and she is under MDT follow up.

Conclusions

Ovarian cancer is a heterogeneous disease with different types of tumours derived from varying cell lines and clinical-pathological characteristics. Borderline tumours are an intermediate epithelial tumour that are neither strictly benign nor malignant, and are described as having 'low malignant potential' by FIGO. Unlike in this case, borderline tumours usually occur in women of reproductive age. Surgeons may encounter unexpected pathology during any laparoscopy or laparotomy and should retain a high clinical suspicion when encountering unexpected pathology as highlighted by this case.

Sequential learning for vaginal cuff closure – a prospective, randomized-controlled trial

Mona Wanda Schmidt¹, Valeria Laufs¹, Linda Battling¹, Charlot Sittig¹, Valerie Linz¹, Christine Skala¹
¹University Medical Center of the Johannes Gutenberg University Mainz,
Department of Gynecology and Obstetrics, Mainz, Germany

Background

Laparoscopic suturing and knot tying is a key component of many surgical procedures and is often considered an advanced skill. The vaginal cuff closure after total laparoscopic hysterectomies is especially difficult due to the surgical angle in the pelvis. Thus, we aimed to assess the possible benefits of training laparoscopic suturing and knot tying on a standardized suture pad before attempting to operate on a vaginal cuff training model.

Methods

In this prospective, randomized-controlled trial 66 medical students were randomized to either train on a standard suture pad followed by a vaginal cuff model or to train directly at the vaginal cuff model. A standardized square knot (suture plus 3 knots) was required. Students trained in pairs of two until reaching predefined proficiency criteria consisting of a time limit (<2:30 min), as well as quality and performance scores. Training time, as well as performance and quality scores were evaluated.

Results

65 students finished the trial (suture pad/vaginal cuff group: n=31; vaginal cuff group: n=34). The total training time to reach proficiency on the vaginal cuff model did not significantly differ between both groups (suture pad/vaginal cuff: 4118s ± 1419s vs vaginal cuff: 3847s ± 1383s, p=0.439). No difference in performance scores and knot quality were seen after reaching proficiency (p>0.05). The suture pad/vaginal cuff group needed an average of 8 attempts on the vaginal cuff model to reach proficiency, with a total training time of 1457s ± 637s. In comparison, 14 attempts were needed in the vaginal cuff group. However, on average 3 more overall suture attempts were needed in the suture pad/vaginal cuff group (p=0.011). The initial learning curve (first three attempts) was quicker on the suture pad compared to the vaginal cuff model (1264s ± 61 vs 1508s ± 96s, p=0.040) and the proficiency level was achieved earlier on the suture pad than the vaginal cuff model (2662s ± 1175s vs 3713s ± 1383s, p=0.002).

Conclusions

To ensure patient safety and good operative outcomes the laparoscopic closure of the vaginal cuff as the crucial step should be trained outside the operating room. We were able to show that standard training models (suture pads) do not adequately reflect the difficulty of the vaginal cuff closure as the challenging point might be the tilted position in the female pelvis. However, the skill of laparoscopic suturing and knot tying on the suture pad can be mastered quicker and acquired skills can partly be transferred to the vaginal cuff model. While the sequential learning approach did not shorten the total training time to reach proficiency for laparoscopic suturing on a vaginal cuff model, prior training on standard suture pads can shorten the learning curve when more advanced vaginal cuff models are not readily available.

Robotic approach of cervicosacropexy and colposacropexy: a single centre experience

Rodrigo Guevara-Peralta¹, José Manuel Martínez-García¹, Marc Barahona-Orpinell¹, Miriam Campos-Delgado¹, Paula Ledesma-Díaz¹, Jordi Ponce¹

¹Hospital Universitari de Bellvitge, Gynecology Department, Barcelona, Spain

Background

Currently, the Gold Standard technique for colposacropexy/cervicosacropexy is the laparoscopic approach. However, this minimally-invasive technique alone considerably minimizes the view of the surgical field and makes manoeuvrability difficult for the surgeon. The use of robotic surgery has shown to facilitate the surgical act allowing the surgeon to reach a considerable degree of precision. These and many other advantages place the robotic surgery in the spotlight for many specialized surgeons when performing high complexity pelvic floor interventions. However, there is not enough evidence regarding the surgeons' experience with both sacropexies separately to prove its surgical success.

Methods

We designed a retrospective observational study which included patients colposacropexy or cervicosacropexy at Bellvitge University Hospital during 2010-2022. The aim was to describe the operating time, conversion rate, hospital stay, intraoperative and postoperative complications, recurrence rate and degree of satisfaction. Every patient with symptomatic apical compartment prolapses to which a robotic approach of colposacropexy or cervicosacropexy was indicated were included. We used the SAP database to collect information about demographic, clinical and anatomical characteristics before and after the surgery and also the intervention related-aspects of all patients to estimate the rate of POP recurrence and operative complications. The degree of satisfaction after surgery was assessed using the Pelvic Floor Impact Questionnaire (PFIQ-7) validated questionnaire.

Results

Of the total of patients initially included, 36 women with a mean age of 62 years were finally considered for analysis. All patients completed a 12-month follow-up evaluation. Of these, 29 (80,56%) underwent a colposacropexy and 7 (19,44%) a cervicosacropexy. The mean operating time was 190 minutes, with a hospital stay of 1,25 days. Among the intraoperative complications, only 1 patient (2.8%) had a bladder perforation and 1 patient (2.8%) had an immediate colpocele recurrence with rupture of the sacral sutures when performing a waltz in post-surgical awakening that needed a conversion to laparotomy (2.8%). During follow-up, we observed only 1 prolapse recurrence (2.8%). 14 patients (38.9%) referred urinary symptoms (UUI, EUI, UI or dysuria) and 6 patients (16.7%) referred fecal temporary symptoms. Only 3 patients (8.4%) in our series underwent a subsequent surgery: 1 liberation of previously vaginal mesh, 1 vaginal vault granuloma, and 1 supraumbilical hernia and second cervicosacropexy. Afterwards, PFIQ-7 mean score was of mean 8.9/300, showing an important rate of satisfaction after surgery regarding daily activities or emotional disturbances caused by urinary, fecal or vaginal difficulties.

Conclusions

The robotic approach for treatment of apical compartment prolapse is a safe, effective and long-lasting technique, with a short hospital stay, low rate of complications and high rate of satisfaction, improving women's quality of life with no need for subsequent surgeries.

Robotic radical hysterectomy versus laparoscopic radical hysterectomy in cervical cancer patients : a retrospective comparison of surgical outcomes

Aeran Seol¹, Tak Kim¹, Lee Jae-Kwan², Song Jae-Yun¹, Min Kyung-Jin³, Lee Sanghoon¹

¹Korea University Anam hospital, Department of Obstetrics and Gynecology, Seoul, Korea- Republic Of

²Korea university Kuro hospital, Department of Obstetrics and Gynecology, Seoul, Korea- Republic Of

³Korea University Asan Hospital, Department of Obstetrics and Gynecology, Gyeonggi-do, Korea- Republic Of

Background

The aim of this study is to compare the surgical outcome of laparoscopic radical hysterectomy and robotic radical hysterectomy.

Methods

We retrospectively analysed patients newly diagnosed as cervical cancer and underwent radical hysterectomy either laparoscopically or robotically. Progression-free survival (PFS) and Overall survival (OS) were calculated using Kaplan-Meier method to compare laparoscopy-assisted radical hysterectomy group and robotic-assisted radical hysterectomy group.

Results

125 patients were evaluated for comparison. 43 patients were undergoing laparoscopic radical hysterectomy and 82 patients were underwent robotic assisted radical hysterectomy. Patients' characteristics such as diagnostic age, body mass index (BMI), histologic type, stage, preoperative SCC, etc were not significantly different between two groups. In the comparison of surgical results between two groups, there was no difference in operation time, postoperative Hb change, and estimated blood loss (EBL). When the analysis of survival outcome was performed between the two groups, the PFS did not reach the median in both groups. In analysis of PFS at 36 months, disease free survival rate of laparoscopic surgery group and robotic surgery group were 95.0% and 93.9%, respectively($p=0.942$). The OS also did not reach the median in both groups. In analysis of OS at 36 months, survival rate of laparoscopic surgery group and robotic surgery group were 94.9% and 96.6%, respectively($p=0.776$).

Conclusions

Robotic radical hysterectomy for cervical cancer is safe and feasible without major difference from conventional laparoscopic surgery.

Advantages of robotics in conservative uterine surgery for benign diseases

Andrei Manu¹, Bogdan Catalin Coroleuca², Ciprian Andrei Coroleuca², Diana Elena Soare¹, Diana Elena Comandasu², Elvira Bratila²

¹Clinical Hospital of Obstetrics and Gynaecology "Prof. Dr. Panait Sârbu"-Bucharest- Romania, Obstetrics and Gynecology, Bucharest, Romania

²Clinical Hospital of Obstetrics and Gynaecology "Prof. Dr. Panait Sârbu"- University of Medicine and Pharmacy "Carol Davila"- Bucharest- Romania, Obstetrics and Gynecology, Bucharest, Romania

Background

Minimally invasive surgery has become the preferred route over abdominal surgery. Robotic gynaecologic surgery has demonstrated feasibility, safety, and equivalent clinical outcomes in comparison with laparoscopy and better clinical outcomes compared with laparotomy. The robotic surgical device was developed to circumvent limitations of laparoscopy and has expanded the surgical armamentarium with technology that improves visualization with three-dimensional technology and increased magnification; enhances dexterity with articulating instruments increasing the degrees of freedom; provides the ability to scale motion and eliminates physiologic tremor and the fulcrum effect.

Methods

In this paper we will present several cases of myomectomy and adenomyomectomy through which we will highlight the techniques and advantages of the robotic conservative surgery. 24 patients with uterine leiomyomas and adenomyosis were treated in our clinic by robotic surgery.

Results

Laparoscopic surgery is still the mainstream surgical method for myomectomy, but due to the limitations of laparoscopic technology itself, there are many drawbacks. Technological advances such as three-dimensional capabilities have demonstrated decreased error rates and quicker task performance time when compared with laparoscopy. There have also been reports of decreased physical and mental strain compared with laparoscopy and improved surgeon ergonomics, especially in morbidly and super obese patient population. All cases of uterine fibroids were cases with large myomas (mean diameter of 8 cm) or multiple myomas (with a mean of 4 myomas/patient). In all cases, after excision of the uterine fibroids or adenomyosis we repaired the myometrium layer-by-layer interruptedly. For meticulous suturing without dead space, we sutured the myometrium to a sufficient depth with enough tissue to prevent laceration. After completion of the myometrial sutures, we repaired the serosal layer with a baseball suture to prevent adhesion formation after surgery. The mean operating time is 89 minutes. The mean blood loss is 81 mL and the mean hospital days is around 3.48 days. We had no recurrence, no intraoperative complications, no postoperative complications and no conversion to laparotomy.

Conclusions

Robotics in benign gynaecologic surgery is continuing to evolve. How to perfectly combine robot-assisted surgery and myomectomy or adenomyomectomy, maximize the advantages of minimally invasive surgery, and achieve the best surgical results are urgent clinical problems that need to be solved. With development of competing robotic devices, and continued technological innovation, robotics in gynecology has the potential to transcend current challenges and capabilities of existing minimally invasive approaches, including the current robotic platform.

Radical robotic trachelectomy with sentinel lymph node using indocyanine green -safe and feasible-

*Catalin Bogdan Coroleuca¹, Andrei Manu¹, Ciprian Andrei Coroleuca², Diana Elena Comandasu²,
Alexandra Bausic², Elvira Bratila²*

*¹Clinical Hospital of Obstetrics & Gynaecology "Prof. Dr. Panait Sarbu"- Bucharest- Romania,
Obstetrics & Gynecology, Bucharest, Romania*

*²Clinical Hospital of Obstetrics and Gynaecology "Prof. Dr. Panait Sârbu"- University of Medicine and Pharmacy
"Carol Davila"- Bucharest- Romania, Obstetrics & Gynecology, Bucharest, Romania*

Background

With nearly 570,000 new cases/year and 310,000 deaths/year, cervical cancer is the second most frequent cancer in women and the third leading cause of cancer-related deaths in females. Cervical cancer continues to affect young patients that desire to preserve their fertility. In selected cases, this procedure offers a good outcome for the patient. Although the procedure was initially performed via vaginal and laparoscopic route, radical robotic trachelectomy with bilateral pelvic lymphadenectomy can be a safe alternative for the treatment of early cervical cancer in patients who desire to preserve fertility.

Methods

This study aimed to determine the safety and feasibility of robotic radical trachelectomy with bilateral pelvic lymphadenectomy and sentinel lymph node using indocyanine green. We also describe our surgical technique. This is a retrospective review of all patients who underwent robotic radical trachelectomy in 2021-2022. We analysed our data to evaluate the safety and feasibility of this surgery.

Results

This analysis included 5 patients with early-stage squamous cell carcinoma of the cervix. Three patients had in situ carcinoma; 1 patient had stage IB1 adenocarcinoma and 1 patient had stage IA1 carcinoma. All patients received radical robotic trachelectomy with bilateral pelvic lymphadenectomy and sentinel lymph node procedure using indocyanine green (ICG). The mean operating time was 188 minutes. The mean blood loss was around 90 ml. The mean hospital stay was two days. There were no conversions to laparotomy. There were no intraoperative complications. No patient required blood transfusion. No patient had residual tumour in the trachelectomy specimen, and no patient underwent adjuvant therapy. There were no recurrences, at 1 or more than 1 year the patients are disease free.

Conclusions

Robotic radical trachelectomy and bilateral pelvic lymphadenectomy is feasible and safe and should be considered for patients desiring fertility-sparing surgery.

Is it really a niche ectopic pregnancy? Think twice, or more!

Sayed Elakhras¹, Mohamed Salama²

¹*Omam Hospital, Dept. of Minimally Invasive Gynaecology, Cairo, Egypt*

²*Ain Shams University, Obstetrics and Gynaecology, Cairo, Egypt*

Background

With the rising incidence of caesarean deliveries (CD), increasing numbers of caesarean scar defects (uterine niches) are encountered. Consequently, niche ectopic pregnancies are becoming more and more encountered.

Owing to the grave consequences of such condition, on both short and long terms, early detection and rapid management are crucial.

Niche ectopic pregnancies are diagnosed mainly by ultrasound scanning, and can further be confirmed by MRI scanning. However, any diagnostic modality has its false positive and negative results. Hence, clinical vigilance is necessary to guide decision making and intervention strategies in cases of such fallacies.

Methods

We present a case that was diagnosed as a caesarean niche ectopic pregnancy, by repeated ultrasound examinations at a tertiary centre, and further confirmed by MRI.

The patient was counselled for combined laparoscopic and hysteroscopic removal of the niche ectopic, which she underwent.

Results

Laparoscopy revealed uterovesical adhesions, that were dissected by sharp scissors. However, there was no bulging or increased vascularity at the lower uterine segment as expected in such cases of niche ectopic pregnancy.

Hysteroscopic examination was then resorted to before further steps were to be taken. It revealed that the gestational sac was clear of the niche, as seen through meticulous hysteroscopic inspection.

Intra-operative ultrasound was performed giving a better image of the interior of the endometrial cavity, after fluid distension following the hysteroscopic examination. The sac was clearly outside the uterine niche!

We decided to stop further interventions, and allow pregnancy to proceed after counselling the patient about all these details.

Surprisingly, pregnancy continued smoothly until elective CD was performed at 39 weeks. Ultrasound scanning throughout pregnancy confirmed the intra-uterine location of the pregnancy, which was not complicated by placenta previa or accreta.

Conclusions

All diagnostic modalities have their false positive and negative results. Hence, clinical vigilance is necessary to guide decision making and intervention strategies in cases of such fallacies>

Furthermore, this case presentation adds to the few published reports of pregnancies proceeding safely after hysteroscopy in early gestation.

Rare case of cystic degenerated leiomyoma of the fallopian tube mimicking ovarian mass and causing torsion of the tube - review of the literature

Nikolaos Papadopoulos¹, Angelos Daniilidis², Pavlos Papadopoulos³, Georgia Poupnara⁴, Grigorios Grimbizis²

¹PAPAGEORGIU HOSPITAL, 1st OBS/GYNAE, Thessaloniki, Greece

²Papageorgiou Hospital- Aristotle University Thessaloniki- Greece, 1st OBS/GYNAE, Thessaloniki, Greece

³Veroia General Hospital- Veroia- Greece, Obs/Gynae, Veroia, Greece

⁴Genesis Hospital- Thessaloniki- Greece, Obs/Gynae, Thessaloniki, Greece

Background

Leiomyomas of the fallopian tube are rare and their exact preoperative diagnosis is not always easy. They are usually found during surgery for an otherwise unspecified pelvic mass.

Methods

In our case a 44-year-old woman presented with mild intermittent lower abdominal pain. Transvaginal ultrasound scan revealed a 7cm cystic mass of the right adnexa initially setting the diagnosis of an ovarian cyst with benign sonographic characteristics.

Results

At laparoscopy, a large cyst located at the right pelvic side wall was identified, causing torsion of the ipsilateral fallopian tube at the ampullary-isthmic junction. During the following exploration the cystic mass was found to originate from the tubal wall having no connection with the uterus and right ovary. The tube macroscopically appeared mildly oedematous. Correction of torsion performed prior to cystectomy. The procedure was completed laparoscopically by "shaving" the tubal wall, leaving it intact and removing the cyst unruptured in an endoscopic bag. Fibrous tissue was recognized during removal of the cyst from the peritoneal cavity, suggesting that the concluding histology would divert from the initial clinical hypothesis of a simple ovarian cyst.

The histological examination established the diagnosis of a benign leiomyoma with extensive cystic degeneration and areas of hyalinization.

Conclusions

Fallopian tube leiomyomas are a rare and most patients present with a pelvic mass that requires clinical examination, imaging and usually surgical exploration and treatment preferably by laparoscopy.

Adenomyosis with predominance of the posterior myometrium is associated with rectovaginal and rectal deep endometriosis on magnetic resonance imaging (MRI): a retrospective study

Konstantin Schawlochow¹, Laurin Burla², Markus Eberhard², Nicolas Samartzis², Dimitrios Kalaitzopoulos²

¹Cantonal Hospital Schaffhausen, Radiology, Schaffhausen, Switzerland

²Cantonal Hospital Schaffhausen, Gynecology and Obstetrics, Schaffhausen, Switzerland

Background

Various theories of the origin of endometriosis have been described. For deep endometriosis some authors in the literature proposed a direct progression from the uterus, also called adenomyosis externa. Aim of our study was to assess the association between the localization of adenomyosis and deep endometriosis (DIE) on magnetic resonance imaging (MRI).

Methods

This retrospective study includes 155 patients with adenomyosis diagnosed by magnetic resonance imaging (MRI) at the Cantonal Hospital of Schaffhausen between 2011 and 2022. We classified all patients into three groups according to the predominant asymmetric localization of adenomyosis: adenomyosis predominantly in the anterior myometrium (group 1), predominantly in the posterior myometrium (group 2), and indifferent without asymmetry (group 3). Endometriosis was classified according to the #ENZIAN classification.

Results

32 women were in group 1, 97 women in group 2, and 26 women in group 3. The mean age was 34.7, 34.5 and 36.4 years in group 1, 2 and 3, respectively ($p=0.66$). We found significantly deeper endometriosis in the rectovaginal septum (ENZIAN A) in group 2 and 3 compared to 1 (77.3%, 73.1%, and 37.5%, respectively, $p<0.001$). ENZIAN B left and right showed no significant difference in group 1 (40.6% and 43.8%), group 2 (45.4% and 49.5%), and group 3 (38.5% and 23.1%), $p=0.777$ and $p=0.056$, respectively. Rectal involvement (ENZIAN C) was significantly more frequent in group 2 compared to group 3 and 1 (70.1%, 50.0%, and 31.3%, $p<0.001$, respectively). No significant difference in the occurrence of endometriosis in the bladder (ENZIAN FB) was detected among the group 1, 2 and 3 (56.3%, 62.9%, and 42.3%, respectively, $p=0.166$).

Conclusions

We found significantly deeper endometriosis in the rectovaginal septum (ENZIAN A) and rectum (ENZIAN C) in women with adenomyosis with asymmetric posterior wall compared to anterior wall thickening. This association should be taken into account when planning a surgery.

Laparoscopic surgery for a unicornuate uterus with noncommunicating and functional uterine horn

Onur Yavuz¹, Eyuphan Ozgozen¹, Asli Akdoner¹, Omer Erbil Dogan¹

¹Dokuz Eylul University Faculty of Medicine, Obstetrics and Gynecology, Izmir, Turkey

Background

Unicornuate uterus with a non-communicating and functional uterine horn (UUNFH) is one of the extremely rare congenital uterine anomalies (CUA) caused by the partial fusion of the Müllerian ducts. Generally, it is difficult to diagnose it in even symptomatic patients from adolescence to the reproductive period. In this case report, we present the diagnosis of a patient with UUNFH anomaly and its surgical treatment by hysteroscopy and laparoscopy.

Methods

Thirty-one-year-old married patient suffering from severe dysmenorrhea and having unexplained infertility for 5 years was referred to our clinic. Magnetic resonance imaging revealed a uterus with normal cavity. There was a rudimentary horn on the left side of uterus which did not connect directly with cervix and vagina. The patient underwent diagnostic hysteroscopy and laparoscopy. The informed consent about the procedures was obtained.

Results

On diagnostic hysteroscopy, a single cervix and a small-volume single uterine cavity were observed. Right tubal ostium was present, but the left was absent. No communication was detected between the right uterine cavity and the rudimentary horn. Laparoscopy was subsequently performed on which there were dense adhesions between the corpus uteri, sigmoid colon, omentum and both tubas uterine. There was peritoneal endometriosis on the peritoneal surfaces of the round and sacrouterine ligaments. Adhesiolysis was performed. There was a rudimentary horn bulging on the left side of the corpus uteri. The left tuba communicated with the rudimentary horn. The right tuba, which had the appearance of a hydrosalpinx, was communicated to the right uterus. Both ovaries were normal. The horn was completely resected with the left tuba. The myometrial defect was closed with a polyglactin absorbable suture. Then, chromopertubation was done, in which methylene blue spillage from the right tuba was not observed. Right salpingectomy was performed. Histopathological evaluation confirmed rudimentary horn with functional endometrium. Postoperative period up to one year was uneventful and the patient's symptoms were completely resolved.

Conclusions

UUNFH is defined as U4aC0V0 according to the ESHRE/ESGE classification. Diagnosis of UUNFH is a challenge, due to low prevalence and lack of awareness among clinicians. Often, the patient's medical history is completely normal, and symptoms depend on the presence of an obstructive anomaly, with the possibility of developing pain due to hematometra or endometriosis. This condition is usually associated with infertility, urinary tract abnormalities, recurrent abortions and adenomyosis. Excision of the horn reduces clinical symptoms and possible pregnancy-related complications. Laparoscopy and hysteroscopy, which are minimally invasive surgical approaches, are the gold standard methods in the treatment of these cases.

Total laparoscopic hysterectomy for virgins: case series

Mohamed Magdy¹, Mohamed Nabi², Mahmoud Soliman³, Hossam El-Mansy⁴

¹Ministry of Health, Gynecology, Cairo, Egypt

²Cairo University, Gynecology, Cairo, Egypt

³Ministry of Health, Gynecology, Mansoura, Egypt

⁴Helwan University, Gynecology, Cairo, Egypt

Background

Virginity is a crucial issue in the Eastern countries. Some patients remain virgin till late ages. When for example 45 years old virgin is indicated for hysterectomy, it is a real challenge. The classic procedure in these cases is to do subtotal hysterectomy. In this series we present our practice to perform total Laparoscopic hysterectomy (TLH) in virgins.

Methods

We reviewed our laparoscopic hysterectomy database for cases of hysterectomy in a virgin patient.

The patient was put in the dorsal position. Myoma screw was inserted in the uterus through the suprapubic port as an alternative to the uterine manipulator. Classic TLH was proceeded till the step of colpotomy.

Two small openings were performed by the monopolar hook in the lateral wall of the vagina after adequate traction to the other side. Colpotomy was continued using Ligasure® all around till complete detachment of the uterus. The uterus was put in a big sized endobag and pulled through the umbilical port after dilatation. Cold morcellation with a knife within the endobag was done till complete removal of the uterus without opening in the abdomen. Facial closure was ensured for the umbilical port.

Results

From December 2018 to March 2023, out of 650 TLH 6 were virgins above 40 years. All of them had fibroids. The median uterus length was 11 cm (9-14 cm). Mean operative time was 75 (± 11) minutes. Mean operative blood loss was 150 (± 30) ml.

No major postoperative complications were reported. No need for conversion in any case. All specimens were found histologically benign.

Conclusions

Laparoscopic hysterectomy in virgin patients seems to be feasible and safe. Larger trials are needed.

Laparoscopic vaginal pectopexy using a cervical cerclage tape instead of mesh: an alternative to sacro-colpopexy in the treatment of pelvic organ prolapse?

Athanasios Protopapas¹, Konstantinos Kypriotis¹, Nikolaos Kathopoulos¹, Michail Diakosavvas¹, Kyveli Angelou¹, Ioannis Chatzipapas¹

*¹National and Kapodistrian University of Athens,
1st Department of Obstetrics and Gynecology- Alexandra Hospital, Piraeus, Greece*

Background

Pelvic organ prolapse (POP) is a common clinical condition, causing significant morbidity, compromising patients' quality of life. Laparoscopic sacro-colpopexy using synthetic mesh is considered the gold standard technique to achieve good apical support and concurrently correct anterior and posterior compartment defects. Suspension of the anterior vaginal wall to the pectineal ligament with mesh (pectopexy) has been described as an alternative procedure in obese patients and those with difficult access to the promontory. Our objective is to present an alternative technique for laparoscopic pectopexy without use of a mesh, combined with laparoscopic native tissue correction of anterior and posterior defects.

Methods

A 56-years old patient with a stage 2 apical prolapse, and cystocele, underwent a laparoscopic pectopexy. Instead of a mesh a permanent cervical cerclage tape was used to suspend the vagina from the iliopectineal ligament. The tape was sutured to the vaginal wall using permanent sutures, over a re-enforced anterior fascia after native tissue correction of the cystocele, so reducing the surface of attachment of the synthetic material to the vagina. Subsequently, a Moskowitz procedure was performed.

Results

The operation lasted 80 minutes with a blood loss of 50mls. The patient was discharged after 48 hours. No intraoperative or postoperative complications occurred. At 6-months follow-up no recurrence of the POP was observed, and the patient reported complete satisfaction with the results of surgery.

Conclusions

Laparoscopic pectopexy using a cervical cerclage tape for vaginal vault suspension can be considered instead of a mesh in the treatment of POP. Native tissue laparoscopic procedures can concurrently address effectively antero-posterior vaginal wall defects. This combination represents a safe procedure with a lower cost than sacro-colpopexy, avoiding mesh and its potential complications, mainly due to a considerably reduced surface of attachment of the synthetic material to the vagina.

Role of hysterectomy in the management of gestational trophoblastic diseases

Sophie Schoenen¹, Frédéric Goffin - Kridelka¹, Delvenne Philippe Delbecq Katty², Van Bockstal Mieke Marbaix Etienne³, Jean-Christophe Noël⁴, Van Rompuy Anne-Sophie Han Sileny - Vergote Ignace⁵

¹Université de Liège, Gynécologie - Obstétrique, Liège, Belgium

²Université de Liège, Anatomopathologie, Liège, Belgium

³Cliniques universitaires Saint-Luc UCLouvain, Anatomopathologie, Bruxelles, Belgium

⁴Hôpital Erasme ULB, Anatomopathologie, Bruxelles, Belgium

⁵KU Leuven, Gynécologie-Obstétrique / Anatomopathologie, Bruxelles, Belgium

Background

Hydatidiform moles are managed by uterine evacuation and the follow-up of human chorionic gonadotropin levels, while gestational trophoblastic neoplasia (GTN) is most often treated by chemotherapy. Despite its excellent clinical efficacy, chemotherapeutic treatments are also associated with adverse events and chemoresistance problems. Hysterectomy is therefore a surgical alternative that should be proposed in women without fertility desire.

Methods

From 2012 to 2022, the French-speaking centre of the Belgian Gestational Trophoblastic Diseases Registry was solicited to advice on 1065 cases. Referral pathologists systematically reviewed all initial histological diagnoses. We retrospectively analysed the data of 36 patients who underwent a hysterectomy for the management of trophoblastic disease.

Results

Post-molar GTN and histological GTN were the hysterectomy indications respectively in 55,56% (n=20) and 19,44% (n=7) of patients. Five additional hysterectomies were performed for a suspicion of GTN based on imaging work-up and biological results before histological confirmation. The four remaining cases were hysterectomized for complete hydatiform moles (n=3) and an atypical placental site nodule.

The pathology results of hysterectomy specimens were as follows: 11 invasive moles, 7 complete hydatidiform moles, 3 placental site trophoblastic tumours, 3 epithelioid trophoblastic tumours, 3 gestational choriocarcinomas, 7 cases had no molar residue and 2 pathological results were not available.

In the 21 cases of histologically confirmed GTN, hysterectomy allowed a remission in 76,2% of cases (n=16), while 5 patients received chemotherapy after the surgery, including one for pulmonary relapse.

Conclusions

In selected patients, without fertility desire, hysterectomy is a good therapeutic option for the treatment of GTN. It allows to avoid chemotherapy in 76% of cases, particularly in non-metastatic diseases.

It wasn't a fibroid after all! A case of a very rare large abdominal tumour during pregnancy with behaviour similar to Leiomyoma

Amin Abdelmagied¹

¹*Danat Alemarat Hospital, Gynaecology, Abu Dhabi, United Arab Emirates*

Background

A case of large abdominal mass thought to be large Fibroid/ Parasitic Fibroid that grew in size during pregnancy from (7x9x13cm) at 9 weeks of gestation to (22x22x28 cm) at term. The mass shrunk postpartum with the use of Gonadotrophin Releasing Hormone Agonist (GNRH) x 12 months to (16x22x23 cm), was removed laparoscopically to reveal a rare diagnosis. It weighted 1.9 Kg.

Methods

The presentation will demonstrate the clinical findings, management strategy to reach term and subsequent Laparoscopic management of the large mass after delivery with essential clinical and surgical tips. It will also summarise the literature review about this rare and potentially fatal condition with high recurrence rate and potential serious morbidity. Ultrasound scan, Magnetic Resonance and Computed Tomography images will be shown during pregnancy, post-delivery and post shrinkage of the mass by GNRH.

A surgical video will be shown as well (please accept my apologies for not being able to upload the video at this stage due to technical difficulties)

Results

The presentation will demonstrate the clinical findings, development during pregnancy, the chosen management strategy to monitor the pregnancy closely until term with save delivery of the baby and subsequent interval Laparoscopic management of the large 1.9 Kg mass. There are many essential clinical and surgical tips to share.

Conclusions

Thorough clinical assessment and remaining open for rare possibilities are essential clinical skills that come with experience. There is a high educational value about Intra-abdominal aggressive Fibromatosis tumours which can have a clinical course so similar to uterine fibroids/ parasitic fibroids but can come with very different natural history, serious morbidity and, indeed, can be fatal.

Peri-operative bladder care guidance for minimal access surgery as a pillar for successful daycase laparoscopic hysterectomy protocol

Mohamed Shahin¹, Mohamed Emeira¹, Ahmed Elshahawy²

¹NHS England, University Hospitals of North Midlands NHS Trust, Stoke on trent, United Kingdom

²NHS, Obstetrics & Gynaecology, Wolverhampton, United Kingdom

Background

Failure to successfully void after laparoscopic surgery is one of the common reasons for overnight stay after such procedures. The purpose of this study was to present the importance of peri-operative bladder care guidance as a fundamental element in a comprehensive protocol for achieving successful outcomes in daycase laparoscopic hysterectomy. WE present our local protocol which was devised based on the best available evidence.

Methods

We reviewed the available literature, developed a local protocol, assessed all possible scenarios with a local flowchart to easily followed by the nursing team. This study examined the implementation of peri-operative bladder care guidance within the protocol, which encompassed pre-operative preparation, intra-operative techniques, and post-operative management. The guidance involved a multidisciplinary approach, incorporating the expertise of gynaecologists, anaesthetists, urologists, and nursing staff.

Results

The implementation of peri-operative bladder care guidance can demonstrate a significant improvement in surgical outcomes. Pre-operative bladder assessment, including bladder diaries, helped identify patients at risk of urinary dysfunction and facilitated personalized management strategies. Intra-operative techniques such as careful bladder handling, optimal patient positioning, and the use of intra-operative bladder catheterization led to a reduced incidence of bladder injuries and improved bladder preservation. Post-operative care involved immediate catheter removal, early mobilization, regular voiding assessments, and prompt intervention for urinary retention or other urinary complications. As a result, the overall incidence of urinary complications can be decreased, enabling successful same-day discharge for the majority of patients.

Conclusions

The integration of peri-operative bladder care guidance into the daycase laparoscopic hysterectomy protocol is instrumental in achieving successful outcomes. By adopting a multidisciplinary approach and implementing evidence-based practices, we can optimize bladder function, minimize complications, and enhance patient safety and satisfaction. This comprehensive protocol, encompassing pre-operative assessment, intra-operative techniques, and post-operative care, serves as a vital pillar in the successful implementation of daycase laparoscopic hysterectomy. The findings highlight the significance of considering bladder care as an integral component of minimal access surgery, emphasizing the need for standardized guidance and multidisciplinary collaboration to ensure optimal outcomes in daycase laparoscopic hysterectomy procedures.

Effectiveness and benefits of laparoscopic hysterectomy

*Shayman Gadimova*¹

¹Azerbyacan Medical University, Obstetrics and Gynecology, Baku, Azerbaijan

²Baku Branch of Sechenov Medical University, Obstetrics and Gynecology, Baku, Azerbaijan

Background

Currently, operations such as hysterectomy (HE), myomectomy, cystectomy, adnexectomy, and many others are less and less performed in the traditional "open" way. Given the sufficient experience in performing laparoscopic HE (LHE), such issues as choosing the optimal tactics for performing the operation, determining the necessary indications and contraindications for these operations, and complications of LHE are little studied.

Methods

To study the results of the treatment of surgical pathology for the period from 2020 to 2022, 96 women with comorbidities aged 45 to 55 years (mean age 49.52 ± 1.15) were examined. They were observed at the Department of Obstetrics and Gynecology II AMU. Taking into account the method of surgical intervention, all subjects were divided into two groups. The main group included 57 patients (59.37±5.0%) who underwent minimally invasive operations based on a differentiated choice of the operation method and improvement of the technique. The comparison group consisted of 39 women (40.63±5.0%) who underwent surgical interventions using traditional methods

Results

The developed algorithms of surgical treatment have made it possible to increase the efficiency of surgical treatment. In comparison with laparotomic HE the operative time for laparoscopic HE decreases from 68 ± 6.4 min. up to 56 ± 8.4 min., blood loss - from 314 ± 8.8 ml. up to 128 ± 4.2 ml., postoperative bed-day from 8.6 ± 0.5 days. up to 4.2 ± 0.5 days. No thromboembolic complications were observed in the postoperative period.

Conclusions

The advantages of LHE included: minimal invasiveness and intraoperative blood loss, ease of reaching the vaginal vaults and ensuring complete haemostasis, removal of blood clots during the sanitation of the abdominal cavity, lower incidence of infectious complications and bowel obstruction, less pronounced postoperative pain syndrome, short hospital stay, cosmetic effect, etc. The proposed differentiated approach to the choice of the method of surgical treatment of gynaecological patients in combination with the developed improvements in the technique of some minimally invasive operations makes it possible to prevent surgical complications during hysterectomies from 8.28% to 1.6%, myomectomy from 4.2% to 2.8 %.

Hysteroscopic electromechanic morcellation for outpatient removal of retained products of conception (RPOC): an Italian experience

Gianluca Raffaello Damiani¹, Daniele Di Gennaro¹, Pierpaolo Nicoli¹, Antonio Pellegrino², Ettore Cicinelli¹, Amerigo Vitagliano¹

¹*Policlinicodi bari-azineda ospedaliero consorziale universitaria -university of bari aldo moro, gynecology and obstetrics, BARI, Italy*

²*Asst lecco, gynecology, lecco, Italy*

Background

Retained products of conception (RPOC) in the uterine cavity represent a pathologic condition that complicates about 6% of miscarriages and voluntary termination of pregnancy, 15% of medical abortions as well as 1% of full-term vaginal or caesarean deliveries. The most common clinical signs patients show is abnormal uterine bleeding or anomalous vaginal discharge often associated with fever and diffuse abdominal pain. RPOC may cause severe long-term complications, such as endometritis and intrauterine adhesions formation, potentially leading to secondary infertility. The main treatment options aiming to evacuate RPOC from the uterus are expectant management, surgical treatment using vacuum aspiration or dilatation and curettage, and medical treatment using prostaglandins with a possible pre-treatment with mifepristone. The inpatient hysteroscopic resection of RPOC using the electro-cauterization (usually a cutting loop) is an efficient alternative too. **The purpose** of this prospective study was to demonstrate that the office hysteroscopic morcellation by means of TruClear™ 5C System, Medtronic, Hysteroscopic Tissue Removal System (HTRS) is a valid and safe method to remove placental remnants.

Methods

From February 2021 to July 2022, 16 women with sonographic suspect of RPOC were enrolled in the Gynecology and Obstetrics Department at Bari University Hospital, in Italy. 38% of these patients showed abnormal uterine bleeding. 13 of them had had first trimester miscarriage, 1 had opted for second trimester voluntary termination of pregnancy, and 2 underwent caesarean section. Firstly, an office hysteroscopic diagnostic biopsy was realized to confirm RPOC clinical suspect. Two to three months after the diagnosis, patients underwent outpatient hysteroscopic morcellation of placental remnants. All procedures were performed on an outpatient setting and without any type of anaesthesia. Pre-procedural antibiotic was administered when an endometrial thickness greater than 3cm was found at ultrasound.

Results

The operators always performed hysteroscopic electromechanical morcellation of RPOC in less than 5 minutes with a 100% success rate achieved in a single operative session. No intense pain was reported by patients during procedure. There were no intra-procedural or post-procedural complications, so all patients were discharged after treatment. The pathologists, besides confirming the initial RPOC diagnosis, considered histopathologic samples adequate not being present electro-coagulation artifacts on the tissues.

Conclusions

Office hysteroscopic morcellation is an efficient method for the removal of RPOC as an alternative to the inpatient electro-cauterization technique. The use of mechanical energy prevents potential thermal damage on the healthy endometrium and limits the risk of uterine perforation because of the blunted tip and lateral operating opening of the instrument.

Prevalence, risk factor, management, and reproductive outcome for Asherman's syndrome in low socio-economic settings for reproductive age group

Shrikant Ohri¹, Namrata Ray²

¹*Newlife Hospital, gynaecological laparoscopic surgeon, Varanasi, India*

²*Newlife Hospital and Healthcare pvt ltd, obstetrics and gynaecology, Varanasi, India*

Background

This study was done to evaluate prevalence, assess risk factors and surgical management by hysteroscopy and reproductive outcome obtained in infertile patients diagnosed with Asherman's syndrome in a low socio-economic setting.

Methods

It is a prospective study performed on patients age 21 to 40 years who visited with infertility and were diagnosed with Asherman's syndrome for a period of 4 years at NewLife Hospital, Varanasi, UP, India.

3D USG was the investigation of choice, hysteroscopic adhesiolysis with scissors was done in all till bilateral ostia were seen in a line or reddish myometrium was visualized

Results

A total of 194 out of 1240 patients with infertility had Asherman syndrome with a prevalence of 15%. The most common complaints were pain (10%) and menstrual abnormalities 108(56%), hypomenorrhea was 117(55%), repeated pregnancy loss (10%) and pregnancy complications (8%) and no symptom (10%) where the other common presenting complaints.

Patients of primary infertility were 80 (41%) rest were of secondary infertility

History of miscarriage without curettage was in 15(7%) and miscarriage with curettage in 55(28%) cases, 13(6%) females had history of operative hysteroscopy for a different cause and 3 had history of laparoscopic myomectomy. 71(37%) patients had no previous significant history. Other causes were abnormal placentation, genital tuberculosis and compression sutures for obstetrics haemorrhage.

All underwent hysteroscopic adhesiolysis with scissors or bipolar current under normal saline.

Adhesions were classified into mild, moderate, or severe according to the MEC classification.

35(18%) had severe Asherman, 118(61%) had moderate and 41(21%) were mild Asherman.

Re-adhesion preventive measures (Paediatric foleys, hormone, hyaluronic acid gel) were taken in all even after 2nd or 3rd relook surgery.

relook surgery was performed in 60 (30%) patients and 3rd surgery was done in 19 patients, total surgery performed was 273. Mean operative time was 17 mins.

post-surgery spontaneous pregnancy was obtained in 59(30%), by ART in 31(16%), failed ART 19(10%) with a total pregnancy of 90(46%) and term delivery in 58 patients.

Hypomenorrhea was cured in 80(71%) and amenorrhea in 22(49%) cured.

operative complication rate was less in mild to moderate conditions.

Conclusions

Choosing patients of Asherman from the infertility group by 3D USG the prevalence of the disease in infertility was established as 15%. We tried to create a comprehensive summary of problems related to the condition and its treatment modality and outcome of it

The management of moderate to severe disease is still a challenge, and the prognosis of severe disease remains poor. Close antenatal surveillance and monitoring are necessary for women who conceive after treatment.

A case report of a patient with recurrent miscarriages associated with the uterine septum

Irina Ramzan¹, Anita Nargund¹

¹Aneurin Bevan University Health Board, Gynaecology, Newport, United Kingdom

Background

Studies demonstrated higher rate of first-trimester miscarriage in women with a septate uterus compared with those with a normal uterine cavity. There have been few meta- analyses demonstrating reduced pregnancy loss with uterine septum resection. American society of reproductive medicine recommends metroplasty as a treatment choice for patients with septate uteri and history of recurrent miscarriages.

However, small RCT by Rikken et al. in 2021 showed that intervention did not improve chance of conception, did not prevent pregnancy loss or preterm birth.

Methods

Review of literature on the diagnosis and management of uterine septum.

Results

We are presenting a case of 32-year-old nulliparous patient who presented in the gynaecology outpatient department with the history of four first trimester miscarriages. Baseline investigations were negative. Previous 2D pelvic ultrasound images were reviewed, which reported bicornuate uterus. MRI pelvis was requested and revealed uterine septum, extending to the level of the internal os, 3.3cm in length. Transcervical resection of uterine septum was offered to the patient, risks and available evidence were discussed. Uncomplicated transcervical resection of uterine septum was performed with bipolar resectoscope. Patient had a spontaneous conception three months later. Pregnancy was uneventful with the caesarean section delivery at term for a failed induction of labour.

Conclusions

In our case, MRI assisted us in the correct classification of uterine malformation. When there is no access to 3D ultrasound imaging or there is a complex case, ESHRE recommends MRI pelvis as it has same diagnostic value as 3D ultrasound.

There is an ongoing debate whether to offer resection to patients with septate uterus. In the United Kingdom, patients are offered investigations and referred to the recurrent miscarriage clinic if they have had three or more miscarriages. RCOG green top guideline 2011 on the investigation and treatment of couples with recurrent miscarriages states that there is insufficient evidence to prevent miscarriage by resecting uterine septum, while NICE 2015 guideline suggests metroplasty for patients with primary infertility and uterine septum. A draft version of updated RCOG guideline is moving towards individualised care in the management of recurrent miscarriages.

Our case demonstrates successful outcome of uterine septum resection. Early and accurate diagnosis of congenital uterine malformations, adequate training in gynaecological imaging allows delivery of appropriate care to patients with septate uterus.

We feel that individualised approach with patient`s counselling on the risks and benefits; MDT involvement could be reasonable in the management of women with recurrent miscarriages and uterine septum. Certainly, large RCT evidence will support optimal management.

We would like to thank the patient for kindly giving us permission to write this case report.

Transcervical fibroid ablation for treatment of symptomatic uterine fibroids with sonata: our experience in the United Kingdom

Rahul Savant¹, Samendranath Roy², Dolon Basu³

¹University Hospital of North Tees, Obstetrics and Gynaecology, Stockton-on-Tees, United Kingdom

²North Tees and Hartlepool Hospital, Obs and Gynae, Stockton on Tees, United Kingdom

³North Tees and Hartlepool Hospital, Obs & Gynae, Stockton on Tees, United Kingdom

Background

The Sonata System combines real-time intrauterine ultrasound guidance with targeted radiofrequency ablation in an incisionless procedure to treat symptomatic uterine fibroids.

- Delivers a breakthrough alternative to hysterectomy and myomectomy
- Transcervical delivery avoids the peritoneal cavity and does not require general anaesthesia
- Treats most fibroid types including submucous, intramural, transmural, and subserous

Methods

27 Cases with symptomatic fibroids who underwent Transcervical Fibroid Ablation for Treatment of Symptomatic Uterine Fibroids with Sonata were included. They underwent Sonata procedure from August 21 to February 23 in a District General Hospital in the United Kingdom. They were followed up at 3 months and 12 months after the procedure

Results

18 cases had fibroid size between 3 to 5 cms, 4 were between 5 to 7 cms ,1 had a fibroid larger than 7 cms and 4 had fibroid size less than 3 cms. At 3 months of follow up 55% had improvement of symptoms, 26% had no change and 15% had worsening of their symptoms of heavy periods.

At 12 months of follow up 63% showed improvement, 22 % experienced no improvement and 4% had worsening of their symptoms.

There was no direct correlation between the size of the fibroids and the treatment outcome.

78% of the subjects were happy to recommend the Sonata procedure to their friends and family.

Conclusions

Transcervical Fibroid Ablation for Treatment of Symptomatic Uterine Fibroids with Sonata is a novel alternative in managing symptomatic fibroids. It is an incisionless technique which can be performed as a day case procedure and also had cost saving compared to hysterectomy.

Endometrial osseous metaplasia following surgical termination of pregnancy - a case report

Leena Nagpal¹, Lina Antoun², Justin Clark³

¹Birmingham women's hospital, Clinical Fellow in Obstetrics and Gynaecology, Birmingham, United Kingdom

²Birmingham women's hospital, ST7 Obstetrics & Gynaecology, Birmingham, United Kingdom

³Birmingham Women's hospital, professor in obstetrics & Gynaecology, Birmingham, United Kingdom

Background

Osseous metaplasia of the endometrium seems related to transformation of mesenchymal tissue to bone in response to inflammation & the reparative process induced by abortion and results in secondary infertility, menstrual irregularities, pain or dysmenorrhea. History of abortion, either spontaneous or therapeutic is a hallmark & time lag varies between 8 weeks & 14 years.

Methods

30 yrs. old lady with previous three hysteroscopies for heavy menstrual bleeding & continuous vaginal discharge following surgical termination in Nigeria 5 yrs. back for foetal anomaly with previous hysteroscopy showing fragments of bone in the uterine cavity & histology confirming osseous metaplasia following post abortive endometritis was referred for further management .

On OPH endocervical canal & uterine cavity was full of bony fragments , appearing similar to coral , ostias were not visualized . She had two doses of Prostag with the view to thin the endometrium to attempt to force the fragments into the cavity & had hysteroscopy with fluid management system under fluoroscopic guidance in theatre with meticulous removal of all residual bone tissue using combination of conventional hysteroscopic grasping instruments & mechanical hysteroscopic tissue removal system (Truclear elie hysteroscope & dense tissue shaver).

During hysteroscopy there was limited view as bony fragments were covering the endocervical canal & uterine cavity, there were extensive adhesions, bleeding vessels while adhesiolysis obscured the view further while completely retrieving bony tissue & fluoroscopy to guide the extent of adhesiolysis & restoration of cavity as near to normal. 2.4 lt saline used with a fluid deficit of 900 ml.

Second hysteroscopy under fluoroscopy guidance five months later done as left side of cavity was obliterated completely due to scarring adhesiolysis with Coles scissors done & whole cavity was opened up & left tube visualized during fluoroscopic assessment at the end, there were no bone fragments. Denuded coil was inserted & estrogen prescribed for 6 weeks to prevent adhesions & help endometrium proliferate.

Results

Coil removed under hysteroscope after 6 weeks & no adhesions or bone fragments were found. She has started on IVF cycles with good quality embryo & ET of 6.3mm on day 14. Rest of fertility work up for both the partners has been normal.

Conclusions

Endometrial osseous metaplasia is a rare condition with various proposed theories & differential of malignant mixed Mullerian tumour (there was no evidence of malignancy on histology in this case) Hysteroscopic adhesiolysis under fluoroscopic guidance with extracting heterotopic tissue is a main stay of treatment & reestablishing fertility. Use of GnRH agonist helped us in retrieving all the bone fragments. Coil & estrogen helped to avoid intrauterine synechiae.

Conservative management of placenta increta in a nulliparous woman

Maria Papageorgiou¹, Sevasti Koulouraki¹, Makarios Eleftheriades¹, Leon Aravantinos¹, Panagiotis Christopoulos¹, Nikolaos Vlahos¹

¹2nd Department of Obstetrics and Gynecology- Aretaieio University Hospital, National and Kapodistrian University of Athens, Athens, Greece

Background

Placenta accreta spectrum (PAS) is a term used to describe a group of conditions characterized by abnormal invasion of trophoblastic tissue into the myometrium and sometimes to or beyond the uterine serosa. This condition is considered a spectrum because it encompasses a range of related conditions, including placenta accreta, placenta increta, and placenta percreta. PAS is typically diagnosed during pregnancy through ultrasound imaging, although it may remain undetected until delivery. Although its prevalence is only around 0,17 percent, it is important to highlight that a fiftyfold increase is described the last fifty years.

Methods

This case report concerns a 39-year-old nulliparous female patient with no prior medical history. She presented to our department at 26 weeks of gestation with intrauterine foetal demise. Foetal scans described no placental abnormalities. She underwent medical abortion using mifepristone and misoprostol. Following vaginal delivery attempts to remove the placenta by controlled cord traction were unsuccessful. Since placenta remained undelivered for two hours after delivery, a curettage was performed. An ultrasound was performed indicating retained increta placenta (image 1). The findings were confirmed by Magnetic resonance imaging (MRI) (image 2). The patient had no signs of infection or vaginal bleeding. Extensive counselling was offered concerning her options and the possible risks. Conservative management (intentional retention of the placenta) was chosen since she desired to preserve fertility. Methotrexate (MTX) was administered and the patient was discharged with recommendations for follow-up with regular visits. Ultrasound assessment, two months later, revealed placental tissue of 25x29x39mm (image 3). A hysteroscopy was performed. After visualization of the cavity, the retained products were identified and removed with resectoscope (image 4) followed by a temporary placement of a Foley's catheter balloon inflated with 10 ml normal saline into the uterine cavity to prevent adhesions. Retained placental tissue was histologically confirmed.

Results

Cesarean hysterectomy is currently the gold standard surgical management for PAS disorders. Data are still scarce regarding conservative management. The goal is to avoid the significant maternal morbidity and haemorrhage associated with hysterectomy and preserve fertility. On the other hand, opting for expectant management involves significant risks such as intrauterine infection, placental abscess, sepsis, and unpredictable massive haemorrhage. Furthermore, this approach necessitates prolonged monitoring until the placenta is fully absorbed.

Conclusions

Overall, conservative management in PAS is a complex and challenging treatment approach that requires close surveillance by obstetricians, maternal-foetal medicine specialists, and sonologists. Expectant management can be an option for a select group of patients and the decision should be based on a careful assessment of the risks and benefits for both the mother and the foetus.

Initial experience of robot-assisted endometriosis surgery with Hugo™ RAS system: a first case series in a tertiary care centre

Manuel Maria Ianieri^{1,2}, Matteo Pavone^{1,3,4}, Barbara Seeliger^{3,4,5,6}, Maria Vittoria Alesi¹, Marta Goglia^{3,4,7}, Giovanni Scambia¹

¹Fondazione Policlinico Universitario A. Gemelli- IRCCS- Roma- Italy,
UOC Ginecologia Oncologica- Dipartimento per la salute della Donna e del Bambino e della Salute Pubblica, Rome, Italy

²Mater Olbia Hospital, Gynecology and Breast Care Center, Olbia, Italy

³Institute of Image-Guided Surgery- IHU Strasbourg- Strasbourg, ihu, Strasbourg, France

⁴Research Institute Against Digestive Cancer, Ircad, Strasbourg, France

⁵University of Strasbourg, ICube- UMR 7357 CNRS, Strasbourg, France

⁶University Hospitals of Strasbourg, Department of Digestive and Endocrine Surgery, Strasbourg, France

⁷Sant'Andrea University Hospital- Sapienza University of Rome, Department of General Surgery, Rome, Italy

Background

Endometriosis is a benign, estrogen-dependent inflammatory disease. Medical treatment should be the first choice in treating the symptoms, but in case of failure surgical removal of the lesions may be required. Laparoscopy remains the gold standard for treating these patients, and in certain circumstances (obesity, complex surgical cases) robotically-assisted surgery can be beneficial. The Hugo™ RAS system was recently introduced for gynaecological procedures. No data have been reported on robot-assisted radical endometriosis excision using this device. The aim of this study is to describe the setting and feasibility of endometriosis surgery with this system and to report on the experience with a first series of patients in a centre of robotic surgery.

Methods

Data of endometriosis patients who consecutively underwent robot-assisted surgery with the Hugo™ RAS system were retrospectively collected (07/2022-01/2023, 15 patients), including medical history and demographic characteristics (age, body mass index, previous surgeries, hormone therapy, obstetric history). In particular, the system setup and docking configuration for surgery were recorded. Disease-specific symptoms before and after surgery, endometriosis stage, as well as intraoperative (operating time, estimated blood loss (EBL), complications) and peri-operative variables (length of hospital stay (LOS), catheterization) were collected. Early post-operative complications (within 30 days) were reported according to the Clavien-Dindo classification.

Results

Port placement followed the "bridge" configuration with a "compact" docking configuration. The median operative time was 186.5min (IQR174-220) the median EBL 50ml (IQR 0-100). One intraoperative complication occurred as bladder injury easily repaired. The median LOS was 3 days (IQR 3-4). The median duration of catheterization was 1day (IQR 1-1), the time to flatus and stool passage was 1day (IQR 1-2) and 3 days (IQR 3-3), respectively. One surgery related post-operative G2 complications was reported (fever treated by antibiotics). Surgery resulted in a statistically significant decrease in symptoms: mean dysmenorrhea (pre: 9.50±0.83 post: 1.7±2.26; p= 0.001), dyschezia (pre: 4.27±3.61 post: 2.40±2.92; p= 0.026), dysuria (pre: 2.73±3.39 post: 1.87±2.41; p=0.358), dyspareunia (pre: 6.53±3.15 post: 2.93±2.89; p=0.002) and chronic pelvic pain (pre: 8.8±1.20 post: 3.20±2.39; p=0.001).

Conclusions

In the first experience with a novel robotic system in endometriosis surgery, the integration of this platform in the described configuration was safe and feasible with regular perioperative outcomes and significant improvement in symptoms. Prospective comparative studies with a larger cohort and longer follow-up are needed to draw conclusions about the potential advantages over the current gold standard.

Clinical and obstetric outcomes after surgical treatment of isthmocele

Sara Catalán¹, Alina Hernández-Fleury¹, Sonia Monreal¹, Montserrat Cubo¹, Elena Suárez¹, Antonio Gil¹
¹Hospital Universitario Vall d'Hebron, Gynaecological endoscopy, Barcelona, Spain

Background

An isthmocele, also known as uterine niche, is a defect in the healing of hystero-graphy after caesarean section procedure observed by transvaginal ultrasound in the anterior uterine isthmus of the non-pregnant uterus.

The prevalence of isthmocele ranges from 19% to 84% depending on the series, but it may be underestimated due to the presence of asymptomatic cases and the lack of clinical awareness.

Approximately 30% to 40% of women with an isthmocele experience symptoms such as premenopausal abnormal uterine bleeding, pain, and infertility, including ectopic pregnancy implanted in the defect.

The primary objective of this study is to provide a description of the clinical and obstetric outcomes in patients diagnosed with isthmocele who received surgical treatment at our institution.

Methods

We performed a descriptive observational study to analyse clinical and obstetric outcomes after surgical treatment of isthmocele. The study included 8 patients diagnosed with isthmocele who underwent surgical intervention at Hospital Vall d'Hebron in Barcelona between 2016 and 2023. We analysed several key variables, including the number of previous caesarean sections, reasons for caesarean deliveries, patient symptoms prior to surgery, presence of retroverted uterus, surgical procedure performed, subsequent pregnancies, and resolution of symptoms after treatment.

Results

We included 8 patients between the ages of 35 and 43 diagnosed with isthmocele. Out of the nine patients, eight had one previous caesarean section, while one had two prior caesarean sections (the symptoms manifested after the last caesarean section). The caesarean sections indications were foetal distress (N=3/9, 33%), abnormal foetal presentation (N=2/9, 22%), prolonged labour (N=2/9, 22%), and unknown cause (N=2/9, 22%). A retroverted uterus was present in seven out of the eight patients (87.5%). Surgical procedures performed included robot-assisted laparoscopy with simultaneous hysteroscopy (N=2/8, 25%), laparoscopy with simultaneous hysteroscopy (N=2/8, 25%), laparoscopy alone (N=2/8, 25%), and hysteroscopy alone (N=2/8, 25%). The decision to perform an abdominal approach was determined by a myometrial thickness of 3mm or less.

Among the six patients with secondary infertility, three became pregnant (50%). Two of these pregnancies reached full term and resulted in caesarean section deliveries without obstetric complications. The third patient, who required assisted reproductive techniques, is currently pregnant. One patient experienced a fundus uterine perforation as a surgical complication during the laparoscopy procedure caused by the uterine manipulator. All patients with abnormal uterine bleeding showed improvement after surgery, including those who primarily presented with infertility issues.

Conclusions

The surgical treatment of isthmocele is an alternative for patients experiencing symptoms such as abnormal uterine bleeding or secondary infertility. Laparoscopy treatment, either with or without robot assistance, is an especially suitable approach when the residual myometrium thickness is less than 3mm and combined with simultaneous hysteroscopy provides a better identification of the isthmocele.

Uterine artery embolization: surpassing expectations? A captivating 10-year retrospective journey in a district general hospital in the United Kingdom

Rahul Gore¹, Mitalee Sawant¹, Saadia Saqib¹, Arun Sebastian¹, Kamran Safdar Rao¹
¹Colchester general hospital, Obstetrics and Gynaecology, Colchester, United Kingdom

Background

Aims and Objectives: To appraise the long-term efficacy of uterine artery embolization (UAE) in the management of symptoms attributed to fibroids, adenomyosis, or both, and to juxtapose our findings with established literature and guidelines.

Methods

Materials and Methods: We meticulously conducted a retrospective analysis of 174 patients who underwent UAE at our institution over a 10-year period (2013-2023). Patients were followed up at 6 months, 1 year, 2-3 years, 5 years, and 10 years. QOL (Quality of life questionnaire) was used for their symptoms, using a 1-10 scale. We carefully analysed patient demographics and post-procedure outcomes, including symptom relief, hysterectomy rate, and pregnancy rates.

Results

The mean age and BMI were 39 years and 29, respectively. Indications of the procedure were fibroids (84), adenomyosis (51), or both (39). At the 2-year mark, 77% of patients reported symptom relief, which further increased to 91% by 5 years. Optimal relief was observed in patients >45 years. Patients who experienced substantial symptom relief at 2-3 years maintained this alleviation over the subsequent 5 years, while those who did not achieve relief at 1 year witnessed exacerbating symptoms. Younger patients, especially with adenomyosis and concurrent endometriosis, needed adjuvant conservative modalities such as Progesterone or GnRh analogues and when the symptoms were persistent or worsened, they needed surgical treatment for endometriosis mainly for deep infiltrating endometriosis.

In adenomyosis cases, 71% accomplished enduring relief (average 3 years) from heavy periods, whereas 40-56% experienced partial relief of pain and pressure symptoms. In fibroid cases, 68-74% of patients reported significant alleviation in pressure and pain during periods, with 83-88% sustaining relief in the long term, as opposed to 58 – 83% in published RCTs. Overall, in our unit, UAE demonstrated an 88% success rate, with only 21 cases (12%) necessitating hysterectomy, as opposed to the Cochrane review (15-34%). The majority of hysterectomies (20) were planned, with one emergent case. Eight pregnancies were reported post-procedure with successful outcomes.

Conclusions

Conclusions:

1. Our study highlights the compelling efficacy of UAE as a therapeutic modality for symptomatic fibroids, adenomyosis, or both, demonstrating sustained symptom relief in a considerable majority of patients.
2. Our study's success rates and hysterectomy rates align with the published literature, underscoring the long-term symptom relief and low hysterectomy rates following UAE.
3. Our results accentuate the merit of UAE as a viable alternative to surgical interventions, particularly for patients endeavouring to preserve the uterus and fertility.
4. We recommend UAE procedures in multidisciplinary settings with meticulous patient selection along with evidence-based pre-procedure counselling for optimal outcomes and to improve patient safety and satisfaction.

Caesarean section scar endometriosis: a case series highlighting individualised patient care

Edward Harrison¹

¹University Hospital Wales, Gynaecology, Cardiff, United Kingdom

Background

Anterior abdominal wall endometriosis is uncommon presenting in just 0.3-1% extra pelvic endometriosis cases. It is thought to be due to seeding and is most commonly seen in patients who have undergone previous Caesarean Section or laparoscopic surgery but has also been reported in cases of amniocentesis.

Methods

We discuss four successfully managed cases, each with individualised care plans and differing management strategies. In case 1 we look at minimising surgical difficulty and incision size by marginally increasing the size of a <1cm lesion with selective oestrogen receptor modulators in a woman with a raised BMI. In case 2 we review how MRI can be used in preference to USS to identify anterior abdominal wall endometriosis in centres where access to experienced sonographers for endometriosis is limited. In case 3 we discuss how the endometrioma is isolated to the right rectus sheath angle and possible hypothesis to its seeding and preventative strategies. In case 4 we focus on the use of GnRH analogues to slow lesion growth, improve patient symptom control whilst awaiting surgery and mitigate rectus sheath involvement to reduce hernia risk.

Results

.

Conclusions

A patient's care should be individualised, tailored to their lesion's size and location. Ultrasound is useful in diagnosis in experienced hands. However, in many hospitals' ultrasounds are performed by sonographers who are not trained in endometriosis. In cases of multiple pain foci or where a lesion has not been seen on USS but the history is convincing, an MRI may be preferential. Surgery can be aided by the use of GnRH analogues to help down regulate, improve symptom relief and restrict lesion growth to minimise rectus sheath defects while awaiting surgery. The opposite can also be true, utilising, in moderation, selective oestrogen receptor modulators to increase endometrioma size to help locate lesions at time of surgery. In this case this mass increased in size by 50% from USS findings. In our experience, provided patients have no significant co-morbidities we feel rectus sheath mesh repair is commonly not needed in these cases with no reported cases of postoperative hernia. A caveat to this being in cases of a significant sized or irregular defect with excessive tension at wound margins. With rates of caesarean increasing worldwide we propose that we should be taking steps to mitigate risks of seeding at caesarean section including; appropriate burying of the first layer of the uterus, not reusing left over sutures on more superficial layers and not reusing swabs that have been used to clean the uterine cavity.

Perineural invasion in endometriosis, case presentation

Milena Petrovic¹, Konstantinos Lamprou¹, Imen Ben-Salha², Arvind Vashisht¹, Ertan Saridogan¹

¹University College London Hospital, Gynaecology Department, London, United Kingdom

²University College London Hospital, Department of Cellular Pathology, London, United Kingdom

Background

Endometriosis is a chronic inflammatory disease defined as the presence of endometrium-like tissue outside of the uterus. It affects 2-10% of the general female population, with endometriosis-associated pain (EAP) and infertility being the clinical hallmarks of the disease affecting not only these women's health, quality of life, everyday activities, physical functioning, education and work, intimacy, mental health and emotional wellbeing, but also their partners and families, and overall society. We're presenting the case of still rarely reported perineural involvement in endometriosis.

Methods

Methods/Clinical Details

Reproductive age woman with a long-standing history of dysmenorrhoea, chronic pelvic pain and deep dyspareunia resistant to hormonal treatment was referred to our Endometriosis Centre as no cause of the symptoms was identified over the years on imaging and diagnostic laparoscopy locally. Expert ultrasound in our unit identified <1 cm endometriosis deposits on uterosacral ligaments, right adnexa and right ovary, adherent ovaries to ipsilateral posterior aspect of the uterus, thickened recto-vaginal septum and obliterated pouch of Douglas. Surgery confirmed transvaginal ultrasound findings and histopathology revealed endometriosis with perineural spread in rectovaginal specimen.

Results

Results/Discussion

Perineural invasion is known although under-recognised route of metastatic spread in cancer. Perineural involvement in endometriosis and other benign conditions is rare but described. Reported literature reviews on perineural invasion in endometriosis showed sacral plexus and sacral nerve as the most commonly involved sites (57% and 31% respectively), and pain was the presenting symptom in 97% of the cases. Comparison of BSGE (The British Society for Gynaecological Endoscopy) Pelvic Pain questionnaire before the surgery and six months post-surgery showed a significant improvement in symptoms in our case, especially pre-menstrual pain (7/10 vs 0/10), dysmenorrhoea (9/10 vs 3/10), dyspareunia (8/10 vs 5/10), dyschesia during period (10/10 vs 0/10), lower back pain (7/10 vs 0/10 respectively).

Conclusions

Endometriosis-associated pain is the most debilitating of the disease, and unfortunately the mechanisms underlying the EAP are still poorly understood. Neuropelvelogy - a rapidly evolving field and a promising future in diagnosis and treatment of chronic pelvic pain, including EAP, combines neurology, advanced pelvic imaging and laparoscopic skills, nerve sparing surgery and most importantly - multidisciplinary high quality patient centred care approach.

First head-to-head comparison between Hugo RAS and Versius CMR in the pre-clinical setting: cross-sectional analysis on virtual-reality simulators.

Giorgia Gaia¹, Maria Chiara Sighinolfi², Margarita Afonina¹, Stefano Terzoni³, Alessandro Morandi¹, Anna Maria Marconi¹

¹San Paolo Hospital Medical School, Department of Obstetrics and Gynecology, Milan, Italy

²San Paolo Hospital Medical School, Department of Urology, Milan, Italy

³San Paolo Hospital Medical School, San Paolo Bachelor School of Nursing, Milan, Italy

Background

The new robotic systems HUGO™ Robotic Assisted Surgery System (RAS, Medtronic, CA), and Versius (CMR Surgical, Cambridge, UK) have recently entered the market after the Da Vinci®'s patent expiry. A direct comparison between these new platforms is still unavailable. In October 2022, the HUGO™ RAS and the Versius became simultaneously available at our tertiary referral centre in Milan, Italy (ASST Santi Paolo and Carlo, Milan, Italy). The aim of this study is to report the first head-to-head comparison of the HUGO™ RAS and Versius surgical system in the pre-clinical scenery; for this purpose, a cohort of subjects naive to robotic surgery was intentionally chosen to report on the face and content validity of new simulators.

Methods

This is a cross-sectional study involving medical students recruited voluntarily; participants were invited to join a hands-on practice simulation with the HUGO™ RAS and/or Versius Trainer Simulator. Afterward, participants fulfilled questionnaires addressing characteristics of the systems they practiced on, such as the easy-to-use fashion and other issues (questionnaire developed by Hertz et al, JSLS, 2018; Simulator Sickness Questionnaire).

Results

Twenty-eight undergraduates participated with 18 of them (64.3%) experiencing both systems. The HUGO™ RAS simulator was found easier to use ($p=0.036$) independently from experience with musical instruments or previous videogame use. The optic of the HUGO™ RAS simulator was judged as adequate for a higher number of raters compared to the Versius raters ($p=0.076$). The HUGO™ RAS has been considered a "useful training tool for residents" by a higher number of users compared to the Versius one ($p=0.019$). The overall sickness score did not show significant differences between platforms ($p=0.933$).

Conclusions

To our knowledge, this is the first article providing a direct comparison between new robotic systems; even if far from being a clinical comparison, it aims to provide an objective perception of HUGO™ RAS and Versius CMR from participants naive to robotic surgery. The implementation of such systems into clinical practice will transfer the comparison into the clinical setting, in the effort to find surgical indications and users mostly benefitting from each new technology.

VIDEO POSTER

ES32-0022 - VP003

Video in Poster

Inverted Y vault closure technique with prophylactic vault suspension

Ali Mohamed¹, John Pardey¹

¹Nepean Hospital- Sydney, Obstetrics and Gynaecology Dept, Penrith, Australia

Background

Vaginal vault dehiscence is an uncommon complication following hysterectomy. If not identified in a timely manner, it could lead to serious complications, such as sepsis and bowel perforation. The reported incidence ranges between 0.036% to 1.78%. There is no consensus, to date, or international guidelines to advice on measures to reduce incidence of vault dehiscence.

We present our technique for vaginal vault closure following total laparoscopic hysterectomy.

Methods

A stepwise video demonstration of our surgical technique

Results

N/A

Conclusions

Inverted Y closure is a feasible technique to close the vaginal vault following TLH, which might reduce the risk of future prolapse and dehiscence.

<https://player.vimeo.com/video/816116974?autoplay=1>

ES32-0049 - VP004

Video in Poster

Alternative approach for tissue extraction following myomectomy

Aya Mohr-Sasson¹, Sarah Beth Mehl¹, Randa Jalloul¹

¹McGovern Medical School at The University of Texas Health Science Center, Advanced Minimally Invasive Gynaecologic Surgery, Houston, USA

Background

Umbilical hernias are relatively common. Repair is recommended for large hernias or in the presence of symptoms. Recurrence can reach up to 27% and is associated to known risk factors including large defect and improper healing. The aim of this video is to demonstrate alternative to abdominal tissue extraction following myomectomy that is aimed to keep the abdominal wall integrity.

Methods

This video presents a 34-Year-old, G2P1011 with history of umbilical hernia repair without mesh at the age of 5. The patient was seen for menorrhagia and evaluation of infertility. Ultrasound examination demonstrated an intramural fibroid estimated 8 cm in maximal diameter bulging from the posterior wall. The patient was recommended to undergo robotic assisted myomectomy.

Results

Entry into the abdomen was achieved using Palmer's point. The umbilical area was observed with aberrant blood vessels. The patient underwent uncomplicated robotic myomectomy. A 1.5 cm incision was made at the posterior fornix above the level of the utero-sacral ligaments and an Endocatch bag was gently pushed through the incision into the pelvis. The fibroid was inserted into the bag and removed from the vagina. The incision was then closed using three figures of eight 0-Vicryl sutures.

Conclusions

Vaginal contained tissue extraction for fibroid removal can serve as an alternative approach to abdominal tissue extraction when there is interest to save the integrity of the abdomen.

<https://player.vimeo.com/video/838436667?autoplay=1>

ES32-0083 - VP005

Video in Poster

Temporary vascular clipping during laparoscopic management of niche ectopic

Sayed Elakhras¹, Bassem Sobhy², Mohamed Salama³

¹Omam Hospital, Dept. of Minimally Invasive Gynaecology, Cairo, Egypt

²Galaa Teaching Hospital, Obstetrics and Gynaecology, Cairo, Egypt

³Ain Shams University, Obstetrics and Gynaecology, Cairo, Egypt

Background

With the increase in the incidence of caesarean section, any subsequent risks of placenta previa, placenta accreta, and ectopic pregnancy have increased. Though rare, caesarean ectopic pregnancy has also increased in parallel with increase in caesarean rates.

Caesarean scar ectopic pregnancy is defined as implantation into the myometrial defect in the previous uterine incision. The prevalence of caesarean ectopic pregnancy is estimated to be one in 2,000 pregnancies, which could be potential viable pregnancies or miscarriages into the scar

There are two different kinds of caesarean scar ectopic pregnancies, one that grows inside into the uterine cavity as gestational sac develops and has the potential to reach viable gestation but with risk of placenta accreta and major obstetric haemorrhage-the endogenous type.

The other type is exogenous, which grows outward toward the bladder with potential for scar rupture and intra-abdominal bleeding. In such cases, early detection is of utmost importance to decrease the complications associated with it

Methods

We present a case of 34-year-old Para-3CS, presented with lower abdominal pain.

Ultrasound showed well defined cystic structure at anterior aspect of lower uterine segment suggesting of ectopic pregnancy at cs scar and the myometrium between bladder wall and gestational sac was absent; uterine cavity was empty; findings were consistent with caesarean scar ectopic pregnancy.

After confirmation of the diagnosis, plan of management was discussed with patient.

Results

Laparoscopic excision of CS scar pregnancy after dissection of urinary bladder was performed clipping of ovarian and uterine arteries were done to minimise potential blood loss

Closure of uterine incision was done using barbed sutures

The patient had an uneventful recovery. She was followed up after two weeks from surgery and was in good health.

Conclusions

We were successful in treating this rare form of ectopic pregnancy without any maternal morbidity with surgical management excision of ectopic pregnancy after temporary clipping of ovarian and uterine arteries

<https://player.vimeo.com/video/825090258?autoplay=1>

ES32-0163 - VP014
Video in Poster

Laparoscopic management of a purulent abdomen in a pregnant patient

Kunal Rathod¹, Amana Sharif¹, Chrysovalantis Agos¹, Harini Karunaratne¹, Michael Magro¹, Premilla Kollipara¹
¹Queens Hospital Romford, Gynaecology, London, United Kingdom

Background

A 30-year-old woman presented 20 weeks in to her second pregnancy with epigastric pain and diarrhoea. Initially she had no pelvic pain, vaginal bleeding, rupture of membranes, scar tenderness or fever. Her observations were normal, and she was afebrile. Foetal heartbeat was normal at 135bpm. Her abdomen was soft with mild tenderness over the epigastric region. She was treated with omeprazole, hyoscine butyl bromide (Buscopan) and analgesia for possible gastritis.

She returned 2 days later with lower abdominal pain and difficulty passing urine but no vaginal loss. Urinalysis showed ketones but no nitrites. Observations remained normal and afebrile. Abdominal examination revealed soft abdomen with generalised tenderness on deep palpation but no rigidity or guarding. Speculum examination was normal with long closed os. High vaginal swab and Urine was sent for culture. Additionally, an ultrasound (USS) of the renal tract and pelvis for cervical length was requested.

Before her scheduled scans she returned with increasing pelvic and generalised abdominal cramping with associated dysuria and flank pain. There was generalised abdominal tenderness, no guarding or rigidity. Cervix was closed and swab confirmed no evidence of ruptured membranes. Urinalysis showed ketones and protein. She was admitted for analgesia, antibiotics and inpatient USS renal tract mild showed right kidney pelvic dilatation 1.1cm. Pelvic USS showed normal cervical length and no

funnelling. However, revealed 79 x 42mm adnexal mass in the Pouch of Douglas suggestive of possible ruptured endometrioma or torsion.

She was consented for laparoscopic investigation and treatment and commenced on IV cefuroxime and metronidazole.

Methods

Laparoscopy was performed using a Palmer's point Veress entry. Immediate evidence of pustular peritonitis and filmy adhesions were noted throughout the abdomen. Systematic inspection revealed normal ovaries and tubes. Filmy adhesions were divided with blunt tip suction and four quadrant examination eventually revealed inflamed appendicular complex. Appendectomy was performed. Robinsons drained inserted. FHS was normal post operatively.

Results

Postoperative recovery showed improving inflammatory markers and pyrexia. The drain was removed on day 3 after diminishing pustular exudate draining. Unfortunately, she was diagnosed with Intrauterine death on day 4 post operation, and she was delivered vaginally.

Conclusions

Appendicitis can present atypically in pregnancy as in this case with symptoms of nausea predominating. Laparoscopic approach to investigating acute abdominal sepsis and treatment of appendicitis can safely be performed in pregnancy with modifications. Intrauterine death is a recognised risk factor of appendicitis in pregnancy and therefore surgical management is the ideal option to try to prevent this.

<https://player.vimeo.com/video/826642875?autoplay=1>

ES32-0191 - VP017

Video in Poster

Not just a simple cyst

Aya Mohr-Sasson¹, Sarah Beth Mehl Mehl¹, Randa Jallou¹

¹McGovern Medical School at The University of Texas Health Science Center, Advanced Minimally Invasive Gynaecologic Surgery, Houston, USA

Background

Large simple cysts are usually treated surgically especially in patients planned for fertility treatments, in order to avoid complications during ovarian stimulation and to improve access for ovum pick up. The aim of the video is to present the challenges of surgeons when intra-surgical findings differ from the expected ones, especially when fertility is desired.

Methods

This video presents a 33-Year-old woman, G4P0040, usually healthy, with obstetrical history of four spontaneous abortions. The patient attempted to conceive for 2.5 years. She was referred for surgical consultation due to large ovarian cyst diagnosed during infertility investigation. Transvaginal ultrasound examination demonstrated a 9.6 cm simple right ovarian cyst that was expanding compared to previous examination performed a year earlier, and an intramural 2 cm fibroid on the anterior uterine wall. On Hysterosalpingography both tubes were not observed and there was no peritoneal spillage. The patient was recommended to undergo robotic assisted myomectomy, hysteroscopy and chromopertubation.

Results

On diagnostic hysteroscopy using normal saline as distending medium a normal uterine cavity was seen with proliferative endometrium. Both ostia were noted to be in normal position. A diagnostic manipulator was then inserted to allow chromopertubation. Entry into the abdomen was achieved without complications. Pelvic screening demonstrated filmy adhesions of both fallopian tubes to the posterior uterine aspect. The left fimbria edge was occluded by small cysts and the right fimbria edge could not be seen due to adhesions to the posterior cul-de-sac. Large ovarian cyst was not observed on either side. Chromopertubation was performed demonstrating no spillage of diluted methylene blue dye from both tubes. Tubal adhesions were then removed using the cold scissors until complete separation of the tubes was achieved. A small incision was made at the cystic mesosalpinges area of the right distal fallopian tube exposing the fimbria. The tissue was further everted completing the tuboplasty and restoring normal anatomy. Similar steps were done on the left side. Once this was completed, second chromopertubation was performed demonstrating spillage of the tube on the right side. No dye was seen from the opening of the left tube. As the tube was in normal calibre and no hydrosalpinx was seen, a decision was made not to remove it.

Conclusions

Surgeons should be cautious and open minded to encounter different findings than the preliminary diagnosis. When the fimbria is not well demonstrated more effort should be done before taking any non-reversal surgical steps, especially when fertility is desired.

<https://player.vimeo.com/video/826711695?autoplay=1>

ES32-0197 - VP018

Video in Poster

Laparoscopic cerclage in pregnancy

Kunal Rathod¹, Michael Magro¹, Chineze Otigbah¹, Premilla Kollipara¹

¹Queens Hospital Romford, Gynaecology, London, United Kingdom

Background

Patient in her early 30's presented to our department with a history of previous eight second trimester miscarriages. Most of her pregnancies continued until nineteen weeks with an average pregnancy duration up to seventeen weeks. She had previous two emergencies and one elective cervical cerclage in pregnancies which unfortunately ended in a miscarriage. Cervical pessary was tried in the most antecedent pregnancy which too was unsuccessful. All her previous pregnancies were registered in a different hospital.

She presented in this pregnancy for an antenatal registration at eight weeks and was referred to foetal medicine consultant immediately. Ultrasound scan showed viable foetus along with a fundal intramural fibroid measuring 5 cm. Both parents were informed about laparoscopic cerclage to prevent risk of second trimester miscarriage and preterm delivery. Appropriate consent was taken and the risk of laparoscopic surgeries including risk of repeat miscarriage was informed.

Methods

Veress needle was used for CO2 insufflation at Palmer's point. Initial insufflation pressures were kept at 20 mm/hg. Blunt tip 5 mm trocar was used along with a 5 mm 30-degree scope. 10 mm supraumbilical port was inserted under vision and 2 additional 5 mm secondary ports were placed in supra pubic and right lateral abdomen. Intra-abdominal pressures were then maintained at 12 mm/hg all throughout the procedure. Merselene tape was used for laparoscopic cerclage which was performed in following four steps; step 1 opening anterior leaf of broad ligament and utero vesical fold, step 2 bladder dissection and exposure of cervix, step 3 circumferential passage of a merselene tape and step 4 of an anterior knot placement.

Results

Pregnancy continued until 28 weeks when she presented to our labour ward with threatened preterm labour. Antenatal steroids for foetal lung maturity were given and an emergency caesarean section was performed by a consultant without any complications and laparoscopic cerclage suture which was placed in pregnancy was preserved. Baby was transferred to the neonatal intensive care unit for 4 weeks followed by discharged to parents.

Conclusions

To recapitulate the usual treatment for women at risk for cervical insufficiency is a cerclage placed trans vaginally. When this approach has failed, or when this approach is not possible because of anatomic deformities, a laparoscopic cerclage is a viable option where expertise is available.

<https://player.vimeo.com/video/826724091?autoplay=1>

ES32-0356 - VP033

Video in Poster

Surgical technique for excision of caesarean scar endometriosis: approach and considerations

Mickey Buckingham¹, Suruchi Pandey¹

¹St George's Hospital, Gynaecology, London, United Kingdom

Background

Caesarean scar endometriosis (CSE) is a rare yet challenging condition characterised by the presence of endometrial tissue on the surgical scar following caesarean section. Surgical excision is the primary treatment modality. This video highlights the surgical technique for excision of CSE, emphasising key considerations to achieve optimal outcomes.

Methods

This video presentation displays the surgical approach to excision of CSE in a 28-year-old female who presented with a tender nodule at the site of the previous caesarean section scar, with symptoms increasing during menstruation.

Results

Pre-operative workup involves ultrasound and MRI scans to assess the size, location, and margins of the lesion.

Surgical steps displayed:

1. The margin of the palpable endometriosis nodule is marked.
2. The previous Caesarean scar is excised and subcutaneous dissection up to the encapsulated endometriosis lesion is performed.
3. Dissection of the lesion identified involvement with the anterior rectus fascia and rectus muscle and resection was performed with a 1cm margin around the lesion.
4. A washout with 0.9% sodium chloride and betadine is performed.
5. Plication of the rectus muscles is achieved using Vicryl 1 in an interrupted fashion.
6. To minimise hematoma formation, a size 10 Redivac drain is placed.
7. The anterior rectus fascia was closed with a non-absorbable looped Nylon 1-0 suture to reduce the risk of hernia formation.

The patient had an uneventful recovery and was discharged the next day. Histopathology confirmed the presence of endometriosis.

Conclusions

Surgical excision with an adequate margin remains the most effective treatment for CSE. Collaborative care with gynaecologists specialised in endometriosis and plastic surgeons is crucial. Further research is needed to explore preventive strategies during the index caesarean section to reduce the risk of CSE.

<https://player.vimeo.com/video/827037092?autoplay=1>

ES32-0370 - VP035

Video in Poster

Laparoscopic assisted vaginal radical trachelectomy with prophylactic cerclage: a safe fertility sparing treatment for early-stage cervical cancer

Matteo Pavone^{1,2,3}, *Marta Goglia*^{1,2,4}, *Giovanni Scambia*³, *Cherif Akladios*⁵, *Lise Lecointre*^{1,5,6}

¹*Institute of Image-Guided Surgery- IHU Strasbourg- Strasbourg, ihu, Strasbourg, France*

²*IRCAD- Research Institute Against Digestive Cancer IRCAD France, Ircad, Strasbourg, France*

³*Fondazione Policlinico Universitario A. Gemelli- IRCCS- Roma- Italy, UOC Ginecologia Oncologica- Dipartimento per la salute della Donna e del Bambino e della Salute Pubblica, Rome, Italy*

⁴*Sant'Andrea University Hospital- Sapienza University of Rome, Department of General Surgery, Rome, Italy*

⁵*University Hospitals of Strasbourg, Department of Gynaecologic Surgery, Strasbourg, France*

⁶*Université de Strasbourg, ICube UMR 7357-*

Laboratoire des Sciences de l'Ingénieur- de l'Informatique et de l'Imagerie de Gynecologic Surgery, Strasbourg, France

Background

In recent years fertility sparing treatments are increasingly developing in patients with early-stage cervical cancer. Among these, trachelectomy represents a milestone with a wide range of surgical approaches, evidence of oncological safety and positive obstetric outcomes. This video shows how it is possible to perform a laparoscopic assisted vaginal radical trachelectomy with a concomitant cerclage position in a patient who wants to preserve the possibility to conceive.

Methods

The case is of a 26-year-old patient who underwent conization for CIN3 with a subsequent diagnosis of squamous cervical cancer stage FIGO IB1. After a negative laparoscopic bilateral pelvic nodes sampling and the radiologic evidence (PET-CT and MRI) of a disease limited to the cervix the patient was candidate to trachelectomy according to her fertility sparing desire.

Results

Pneumoperitoneum is obtained with Veress needle. The optic trocar is placed above the umbilicus. Two lateral and one mid-line laparoscopic trocars are introduced under vision. The vesico-uterine space is dissected and the bladder moved down. A window is made on the broad ligaments and bilateral ureterolysis performed. The recto-vaginal space is then dissected till the medial para-rectal fossa.

Circular colpotomy is vaginally performed with a 1 cm tissue rim and the cervix is closed with Vicryl stitches in a vaginal cuff to avoid tumour spread. Careful dissection of the anterior and posterior septa is then carried out until reunification with laparoscopic dissection. Bilateral parametrectomy is performed 5 mm cranially the uterine artery arches and 1 cm far from the cervix. Radical trachelectomy is finalized with a negative deep margin at the frozen section. The uterine isthmus is then sutured to the vagina.

In the second laparoscopic time a 3 mm monofilament polypropylene sling cerclage is bilaterally positioned from posterior to anterior through the broad ligaments opening and fixed anteriorly on the uterine isthmus to prevent an eventual preterm delivery. Anterior and posterior peritoneization is performed with 3/0 V-Loc stitches to induce fibrosis retraction.

Conclusions

Laparoscopic assisted vaginal trachelectomy, is a feasible procedure combining the conservative advantages of the vaginal approach and the oncological safety of laparoscopic spaces dissection with good obstetric outcomes.

<https://player.vimeo.com/video/819562884?autoplay=1>

Myosure excision of retained products of conception

Kunal Rathod¹, Sarah Shehzad¹, Yatin Thakur²

¹Queens Hospital Romford, Gynaecology, London, United Kingdom

²Basildon Hospital, Gynaecology, Essex, United Kingdom

Background

Myosure intrauterine tissue removal device is used widely in an outpatient setting for selective removal of uterine tissue, endometrial or endocervical polyps and fibroids. Recently, use of myosure is extended to remove retained products of conception under vision as compared to blind suction curettage where the risk to formation of intrauterine adhesions is common. Myosure procedure requires excellent dexterity and hand eye coordination.

Methods

Patient presented to emergency gynaecology department 3 weeks after medical management of a miscarriage with misoprostol with a persistent positive pregnancy test and brownish vaginal discharge. Ultrasound scan was performed including 3D scan which showed presence of a 2 cm retained products in the uterus attached to the anterior wall. Myosure procedure was offered to the patient in a week's time.

Patient took 400 mg of ibuprofen and 1gm of paracetamol as pain relief medications 1 hour prior to the procedure. Informed consent was taken in the clinic. Patient was placed in a lithotomy position and 4 ampoules (8.8mls) of scandonest (local anaesthetic without adrenaline) was injected at 4 quadrants in the cervix.

Cervix was dilated to Hegar's dilator size 8 mm. Fluent system was used for distension of uterine cavity with normal saline. Myosure reach device along with omniscope was used. Vulva vagina and endocervix appeared normal. Endometrial cavity was polypoidal with thick endometrium. Retained products measuring 3 cm was present on the anterior left lateral uterine wall like a sessile polyp.

Results

Complete excision of the retained products of conception was performed in an outpatient setting. Total procedure time was 10 minutes with a fluid deficit of 240 mls and cutting time of 2 minutes and 50 seconds. Patient had minimal blood loss during the procedure. Recovery time was 15 minutes. Overall pain score during the entire procedure was 4/10. Histopathology confirmed retained products of conception. There were no intraoperative or postoperative complications.

Conclusions

Myosure procedure is a simple outpatient operative procedure which can be easily performed and reproducible although needs training. The use of Myosure device enables the direct visualisation of RPOC. Day case blind Evacuation of Retained Products of conception (ERPC), General anaesthetics and its associated risk, prolong waiting times can be avoided. Myosure procedure should be offered as the standard for management of all women needing repeat ERPC or removal of chronic RPOC

<https://player.vimeo.com/video/827056073?autoplay=1>

ES32-0595 - VP049

Video in Poster

Conservative caesarean scar pregnancy management: uterine artery embolization followed by tissue removal device hysteroscopic treatment

Eleonora La Fera¹, Maria Vittoria Alesi², Silvia D'Ippolito², Antonio Lanzone², Giovanni Scambia², Ursula Catena²

¹Fondazione Policlinico Universitario A. Gemelli- IRCCS,

Department of Woman and Child Health and Public Health, Rome, Italy

²Fondazione Policlinico Universitario Agostino Gemelli IRCCS,

Department of Woman and Child Health and Public Health, Rome, Italy

Background

Caesarean scar ectopic pregnancy (CSP) is a rare complication arising in patients with previous caesarean deliveries. A lot of treatments have been proposed, both medical and surgical, but until now there is not a consensus about the management.

Methods

We propose a stepwise demonstration with narrated video footage of the conservative treatment of CSP hysteroscopically managed with tissue removal device (TRD), after uterine artery embolization (UAE). 34 years old women with two previous caesarean sections was referred to our clinic with lower abdominal pain. Transvaginal ultrasound (TV-US) revealed a gestational sac with a viable embryo corresponding at 7 weeks of gestational age, implanted in the anterior isthmic region, at the level of the previous hysterotomic scar tissue. After a bioethic evaluation and appropriate counselling patient decided to terminate pregnancy.

Results

She underwent UAE and, four months later, she was scheduled for hysteroscopic treatment in our Digital Hysteroscopic Clinic (DHC) CLASS Hysteroscopy. A one-stop complete uterine evaluation through 2D-3D TV-US and hysteroscopy showed the trophoblastic remnants completely located in the uterine niche. A TRD was used to completely remove the trophoblastic lesion using a soft tissue blade. No complications were detected during and after the procedure.

Conclusions

UAE followed by TRD hysteroscopic treatment of the CSP represent a safe and valid method to treat these patients. Performing the procedure under direct vision using blunt tips allows to avoid potential complications, such as perforation and intra- or post-operative haemorrhagic events. Moreover, the TRD is a mechanical tool that permit to avoid the use of electrosurgery and the potential thermal injury. This reduces the risk of intrauterine adhesions formation, preserving the future fertility of our patients. Further studies are needed to confirm the safety of our technique and the reproductive outcomes.

<https://player.vimeo.com/video/834732193?autoplay=1>

ES32-0091 - VP006

Video in Poster

Vaginal approach for the surgically complex abdomen

Aya Mohr-Sasson¹, Mason Hui¹, Olivia Dziadek¹, Alvaro Mateo¹

¹McGovern Medical School at The University of Texas Health Science Center, Advanced Minimally Invasive Gynaecologic Surgery, Houston, USA

Background

Abdominal adhesions and distorted anatomy are major concerns during entry to the abdominal cavity in surgeries done by conventional laparoscopy. In addition to incorporating the benefits of endoscopic surgery, the Vaginal Natural Orifice Transluminal Endoscopic Surgery (vNOTES) approach avoids abdominal wall wounds and trocar-related complications. The aim of this video is to demonstrate the advantage of (vNOTES) approach in a woman with surgically complex abdomen.

Methods

This is a video case presentation of a 32-year-old woman G2P0020 with medical history of endometriosis, hypertension, Nutcracker syndrome, Myasthenia Gravis and Autoimmune dysautonomia. Her past surgical history included: jejunostomy, ileostomy and gastrostomy with PEG tube. The patient desired bilateral salpingectomy for sterilization.

Results

The video demonstrates the decision for choosing the vNOTES approach and the surgical steps.

Conclusions

vNOTES should be considered as the favourable surgical approach in women following previous abdominal surgeries.

<https://player.vimeo.com/video/825314938?autoplay=1>

Robotic intracorporeal Single Staple Anastomosis (RiSSA) in Rectosigmoid Endometriosis

Denis Tsepov¹, Youssef Youssef², Danilo Miskovic³, Gaby Moawad⁴

¹The Princess Grace Robotic Endometriosis Centre- HCA Healthcare, Department of Obstetrics and Gynaecology, London, United Kingdom

²Division of Minimally Invasive Gynecologic Surgery- Maimonides Medical Center, Department of Obstetrics and Gynaecology, Brooklyn- New York, USA

³St Mark's Hospital, Department of Surgery, London, United Kingdom

⁴George Washington University, Department of Obstetrics and Gynaecology-, Washington, USA

Background

The aim of this study is to provide a step-by-step video tutorial demonstrating two different surgical approaches for treating deep bowel endometriosis, which is the most common extragenital site (3-37%) and affects up to 12% of patients with deep endometriosis. Surgical management of bowel endometriosis includes bowel shaving, discoid resection, or segmental resection. Segmental bowel resection can be performed through conventional Mini laparotomy or a natural orifice approach. Re-anastomosis is done using a hand-sewn technique or surgical staplers, either with a single staple technique (SST) or a double staple technique (DST). Anastomotic leakage is a major complication that can occur in up to 2% of bowel resection cases for deep endometriosis. Higher leakage rates have been reported in colorectal cases when using DST compared to SST, which is associated with the number of linear stapler firings and the presence of lateral intersecting staple lines (dog-ears), which is a weak point in the anastomosis. Modified techniques have been described to reduce the risk of leakage in DST, including using a side-to-end anastomosis instead of an end-to-end approach to decrease the intersections of staple lines in the anastomosis. Another technique is performing an Omega stitch or invaginating technique to punch out the staple lines and the dog-ears with a circular stapler.

Methods

Two cases were referred to a tertiary referral endometriosis centre. The first case in the video showcases the double-stapling technique (DST) using both linear and circular staplers to perform an intracorporeal side-to-end anastomosis. The second case demonstrates a single-stapling technique (SST) with a double purse-string suture, where an end-to-end anastomosis is performed using a circular stapler.

Results

Both Patients had an uncomplicated postoperative recovery.

Conclusions

Staple lines intersections are weak points with decreased vascularity and increased possibility of leakage. The higher number of staple lines intersections is associated with anastomotic leakage. The use of SST for rectal anastomosis may reduce anastomotic complications and can be cost effective by using fewer surgical staples; however, larger studies are needed to confirm these findings in endometriosis cases.

<https://player.vimeo.com/video/826426048?autoplay=1>

ES32-0129 - VP010

Video in Poster

vNOTES hysterectomy in a woman presenting with a ventrofixed uterus following two previous caesarean sections: a video article

Solene Géry¹, Alexis Gromez¹, Jean-Baptiste Thoumas¹, Patrice Crochet¹, Sophia Braund¹

¹Rouen University hospital, Gynaecologic surgery, Rouen, France

Background

vNOTES uses the vagina as the surgical channel for endoscopy and achieves improved cosmesis compared to conventional laparoscopy as there are no abdominal incisions. Ventrofixation of the uterus to anterior abdominal wall scar following previous caesarean section (CS) further adds to the surgeon's concern of bladder injury. In such cases, a modification of the technique is proposed: introducing the vNOTES port first, before the opening of the vesico-uterine peritoneal folds, thus carried out under endoscopic view.

Methods

Stepwise demonstration of the technique with narrated video footage.

Results

vNOTES hysterectomy with the following key strategies was performed:

1. Circumcised colpotomy
2. Posterior peritoneal pouch opening
3. Insertion of the transvaginal port
4. Division of the uterine vessels bilaterally
5. Dissection of both parametria using the lateral window approach to better repair the dense medial scar-induced adhesences before sectioning
6. Transvaginal retrieval of the specimen after morcellation, and vaginal closure

Conclusions

This video demonstration illustrates the lateral window concept in case of a ventrofixed uterus, with dense anterior adhesions. Thus, the vNOTES technique can be undertaken with no abdominal scar, and with a limited risk of bladder injury. The anterior dissection performed under laparoscopic control overcomes the limitations of conventional vaginal surgery in such cases.

<https://player.vimeo.com/video/826451556?autoplay=1>

ES32-0200 - VP019
Video in Poster

Transvaginal Natural Orifice Specimen Extraction (NOSE): a 10-Step approach for laparoscopic excision of deep endometriosis of the rectosigmoid

Abhishek Mangeshikar¹, Youssef Youssef², Harsh Sheth³, Parshant Mangeshikar⁴, Gaby Moawad⁵

¹Saifee Hospital and The Indian Center for Endometriosis ICE, Department of Obstetrics and Gynaecology-, Mumbai, India

²Division of Minimally Invasive Gynecologic Surgery- Maimonides Medical Center, Department of Obstetrics and Gynaecology, Brooklyn- New York, USA

³Saifee Hospital, Department of Minimally invasive surgical Sciences, Mumbai, India

⁴Saifee Hospital and The Indian Center for Endometriosis ICE, Department of Obstetrics and Gynaecology, Mumbai, India

⁵George Washington University, Department of Obstetrics and Gynaecology-, Washington, USA

Background

Bowel endometriosis is the most common extragenital site and affects up to 12% of patients with deep infiltrating endometriosis. Depending on the location and depth of the lesion, surgical management of bowel endometriosis may include bowel shaving, discoid resection, or segmental resection. The resected segment can be extracted through a conventional mini-laparotomy technique, or through a natural orifice approach (NOSE) that can be either transvaginal in cases where hysterectomy is performed, or trans-anal in uterine-sparing cases. The complication rate associated with the NOSE approach is comparable to that of the conventional (mini-laparotomy) surgical approach.

Methods

A surgical video tutorial to provide a 10-step systematic approach for performing the transvaginal (NOSE) technique in cases of deep endometriosis that infiltrates the rectosigmoid.

Results

After an MRI revealed a rectosigmoid nodule measuring approximately 6 X 3.5 cm and located 12cm from the anal verge, the patient underwent conventional laparoscopy. During the procedure, the diseased bowel segment was dissected along its posterior, lateral, and anterior borders and then transected using linear staplers. Hysterectomy was also performed, followed by adequate bowel mobilization to enable the introduction of an anvil vaginally. The end-to-end anastomosis (EEA) circular stapler is used to perform a side-to-end anastomosis. Finally, a water leak test was performed to confirm the integrity of the anastomosis. The postoperative period was uneventful, and the patient was discharged on postoperative day five.

Conclusions

In patients requiring hysterectomy, segmental resection through a transvaginal (NOSE) approach is safe and feasible. In this tutorial we describe a reproducible 10-step approach that can be used by surgeons to perform this technique.

<https://player.vimeo.com/video/826758339?autoplay=1>

ES32-0225 - VP022

Video in Poster

Laparoscopy for a big uterus. Let's make it easier!

Nasuh Utku Doğan¹, Selen Dogan¹, Arif Can Ozsipahi¹, Sefa Metehan Ceylan¹
¹Akdeniz University, Gynaecology, Antalya, Turkey

Background

When certain surgical principles are strictly followed, surgery for a big uterus are operatively easier with laparoscopy than laparotomy. These steps are such as visualisation and identification of ureters, when possible, ligation of uterine arteries directly from hypogastric artery

Methods

In this video, we present a case of a 44-year nulliparous woman who was referred to our clinic with pelvic pain associated with a big myomatous uterus which extended beyond umbilicus.

Results

In pelvic MRI and ultrasonography, multiple myomas, the biggest measuring 120 mm was revealed. The patient had umbilical hernia possibly related to compression of a huge uterus. Laparoscopic hysterectomy and bilateral salpingectomy along with repair of umbilical hernia were performed. The uterus was taken out from umbilical hernia incision and the hernia site was repaired with surgical mesh. The weight of uterus was 1720 grams. Operation duration was 200 minutes and total blood loss was 10 cc. The patient was discharged on the postoperative second day.

Conclusions

Laparoscopy is a feasible method for the hysterectomy for a large uterus.

<https://player.vimeo.com/video/826778337?autoplay=1>

ES32-0244 - VP023

Video in Poster

Laparoscopic hysterectomy for deep infiltrating endometriosis: how can we make it simple?

Nasuh Utku Doğan¹, Selen Dogan¹, Can Dinc¹, Arif Can Ozsipahi¹
¹Akdeniz University, Gynaecology, Antalya, Turkey

Background

In symptomatic patients with deep infiltrating endometriosis, when fertility is of no concern, the ultimate goal is macroscopic clearance of all visible endometriotic tissue by using radical organ resections. When there is an involvement of Douglas along with rectosigmoid colon, hysterectomy should be started followed by anterior colpotomy and dissection of Douglas dissection by posterior colpotomy (retrograde hysterectomy). By this way, hysterectomy will be easier.

Methods

In this video, technique of laparoscopic retrograde hysterectomy was presented in a 42-year-old nulliparous woman with a previous four laparotomy for endometriosis. Along with hysterectomy, BSO, endometriotic nodule excision in sacrouterin ligament and rectal shaving were all performed.

Results

In this video, Douglas dissection after anterior colpotomy is presented. Total operation time was 210 minutes and blood loss were 50 cc. In postoperative fourth day, she was discharged.

Conclusions

Laparoscopic hysterectomy for deep infiltrating endometriosis becomes easier when certain surgical steps are followed and by this way complication rates decrease

<https://player.vimeo.com/video/826889479?autoplay=1>

ES32-0308 - VP027

Video in Poster

Total laparoscopic hysterectomy with pelvic lymph node staging with co-existent deep infiltrating endometriosis

Angelos Daniilidis¹, Georgios Grigoriadis², Dimitra Dalakoura²

¹Aristotle University of Thessaloniki,

1st Department of Obstetrics and Gynecology- Papageorgiou Genral Hospital, Thessaloniki, Greece

²Aristotle University of Thessaloniki,

2nd University Department of Obstetrics and Gynecology- Hippokration General Hospital, Thessaloniki, Greece

Background

Total laparoscopic hysterectomy (TLH) for endometrial cancer can be safely performed via the laparoscopic route. The addition of indocyanine green (ICG) cervical injections may reduce the need for systematic pelvic lymphadenectomy. Although the steps of this procedure have been standardized, co-existence of other pathologies, such as Deep Infiltrating Endometriosis (DIE), may make this procedure far more challenging.

Methods

Narrated surgical video of TLH with bilateral salpingo-oophorectomy (BSO) and pelvic lymph node staging using ICG cervical injections, with a focus on the complexities caused by anatomical distortion due to co-existent DIE.

Results

Following cervical injection of ICG, the sentinel lymph node was identified on the patient's left side and excised. On the patient's right side, it was not visualised and, hence, pelvic lymphadenectomy was performed. Due to the presence of a right ovarian endometrioma that obstructed the surgical view, a right salpingo-oophorectomy was performed. We identified an obliterated posterior cul-de-sac due to the extensive adhesions between the retro-cervical area and the rectum, due to DIE. Careful dissection allowed for mobilisation of the rectum off the retro-cervix. A rectal probe was used to help adjust the surgical plane. A TLH was completed with further removal of a DIE nodule, following closure of the vaginal vault laparoscopically.

Conclusions

Presence of DIE severely distorts the pelvic anatomy, often making procedures such as TLH particularly challenging. However, thorough knowledge of the anatomy and careful dissection will allow for such procedures to be completed safely through the minimal-access route.

<https://player.vimeo.com/video/826999769?autoplay=1>

ES32-0316 - VP028

Video in Poster

MRI-guided laparoscopic enucleation of 14 fibromas using temporary bilateral uterine artery clipping

Nikolaos Kathopoulos¹, Konstantinos Kypriotis¹, Michail Diakosavvas¹, Kyveli Angelou¹, Ioannis Chatzipapas¹, Athanasios Protopapas¹

¹National and Kapodistrian University of Athens,

1st Department of Obstetrics and Gynaecology- Alexandra Hospital, Athens, Greece

Background

Myomas constitute one of the most often benign uterine tumours. Over recent years due to the improvement of surgical techniques more cases of women suffering by multiple myomas undergo laparoscopic myomectomy.

Methods

In the present video we present a step-by-step technique to perform this type of surgery and the appropriate modifications to facilitate a safe and effective operation. The use of intraoperative MRI reading may help the surgeon to locate one-by-one the fibroma. Moreover, temporary bilateral artery clipping and intramyometrial vasopressin injection may contribute to minimize intraoperative blood loss. Vesicouterine fold dissection is an imperative step for safe extraction of myomas located in the frontal isthmic or cervical area of the uterus. Finally, suturing of the myoma bed in one or two layers is also presented in the video.

Results

In this present video 14 myomas were extracted using the techniques presented with minimal intra and post operative blood loss. The patient had an uneventful recovery and left the hospital on the second postoperative day.

Conclusions

Following key surgical steps, laparoscopic myomectomy is a safe and effective surgical technique even for multiple (>10) myomas.

<https://player.vimeo.com/video/839973561?autoplay=1>

ES32-0320 - VP029

Video in Poster

IVF and frozen pelvis - a sticky situation

Pavle Dimitrijevic¹, Benedetto Mondelli¹, Vasileios Minas¹

¹Ashford and St Peter's Hospitals, Centre for Endometriosis and Minimally Invasive Gynaecology, Chertsey, United Kingdom

Background

We present the case of a 40-year-old nulliparous woman with frozen pelvis and significantly distorted anatomy with a background of 3 miscarriages following recurrent failed IVF. Previous laparoscopy showed an obliterated POD, rectouterine DIE and right ovarian endometrioma that was drained.

Subsequent MRI showed tethering of rectosigmoid to uterus but no transmural bowel involvement and a 5cm posterior intramural fibroid. Following discussion at MDT the decision was made to restore anatomy in order to preserve the uterus and improve fertility.

Methods

In this video we use the SOSURE surgical technique, alongside uterine and ovarian suspension, to safely blunt and sharp dissect the paravaginal and pararectal spaces prior to excision of endometriosis.

Results

We discovered severe and dense adhesions between the uterus and recto-sigmoid, which we found difficult to explain by the presence of endometriosis only. The extent and complexity of these adhesions showed three significant anatomical distortions. Firstly, the left ureter was displaced medially. Secondly – a transverse artery lying at the level of the torus uterinus was noted, thirdly – a mass in the left pararectal space with an overlying lesion was seen. Following extensive adhesiolysis, these structures were identified as the uterine artery and the cervix respectively.

Conclusions

This video demonstrates our surgical technique when dealing with extensive pelvic adhesions and the challenge of correct identification of anatomy. We hypothesise that this lady's severe pelvic adhesions formed likely due to a combination of previous undiagnosed infection, possibly introduced by egg collection in the presence of rectovaginal endometriosis.

<https://player.vimeo.com/video/827011217?autoplay=1>

ES32-0325 - VP030

Video in Poster

Laparoscopic salpingectomy with extensive adhesiolysis in a patient with history of peritonitis

Angelos Daniilidis¹, Georgios Grigoriadis², Dimitra Dalakoura²

¹Aristotle University of Thessaloniki,

1st Department of Obstetrics and Gynecology- Papageorgiou General Hospital, Thessaloniki, Greece

²Aristotle University of Thessaloniki,

2nd University Department of Obstetrics and Gynecology- Hippokration General Hospital, Thessaloniki, Greece

Background

Laparoscopic salpingectomy may, in general, not be considered a particularly challenging procedure. However, presence of other pathology that causes anatomical distortion may make it technically demanding. We, hereby, present a case of laparoscopic right salpingectomy for hydrosalpinx in a patient with past history of peritonitis as a child, causing complete distortion of the anatomy due to extensive adhesions.

Methods

Narrated surgical video.

Results

Upon insertion of the optical trocar, we came across extensive adhesions, making access to the pathology difficult. Manipulation of the uterus, albeit not initially visible due to adhesions, helped our orientation. Carefully, we proceeded with adhesiolysis, using combination of blunt and sharp dissection. The pathology was revealed on the patient's right side and ruptured, filled with serous fluid. The right ovary was normal. We proceeded with right salpingectomy, operating far from the ureter, and respecting the right infundibulo-pelvic ligament. Our patient had minimal intra-operative blood loss and was discharged home on post-operative day 1.

Conclusions

Conditions causing distortion of normal anatomy can make any surgical intervention challenging. However, respecting the principles of careful dissection allows for the procedure to be performed safely and effectively.

<https://player.vimeo.com/video/827014454?autoplay=1>

ES32-0337 - VP031

Video in Poster

Laparoscopic management of bladder endometriosis after cystoscopic isosulfan blue injection

Taner Usta^{1,2}, Gul Sema Can Akyol³, Salih Yilmaz³, Aysel Ozkaynak³, Ahmet Kale⁴, Engin Oral⁵

¹Acibadem Altunizade Hospital- Mehmet Ali Aydinlar University, Obstetrics and Gynaecology, Istanbul, Turkey

²Acibadem Altunizade Hospital, Gynaecology and Obstetrics- Endometriosis and Pelvic Pain Center, Istanbul, Turkey

³Acibadem Altunizade Hospital, Gynaecology and Obstetrics- Endometriosis and Pelvic Pain Center, Istanbul, Turkey

⁴University of Health Sciences, Gynaecology and Obstetrics, Istanbul, Turkey

⁵Bezmialem Vakif University - School of Medicine, Gynaecology and Obstetrics, Istanbul, Turkey

Background

Bladder endometriosis (BE) is defined as endometrial tissue invading the detrusor muscle of the bladder and is the most common presentation of urinary tract endometriosis. Total excision is recommended for symptom resolution and prevention of persistence/recurrence. However, radical excisions to leave no residual disease might increase the rate of complications. To perform optimal resection, simultaneous use of the laparoscopy or robot-assisted laparoscopy with cystoscopy are described in studies. Still, it might be challenging to recognize endometriotic lesions, and this need for better visualization has increased the interest in tracers. ICG is the most commonly used tracer in gynaecologic practice. Blue dyes (methylene blue, isosulfan blue, patent blue) are the alternative tracers widely used in gastrointestinal surgeries. To our knowledge, this is the first time isosulfan blue has been used in an endometriosis surgery to delineate the borders of a lesion to provide an easier and more precise excision.

Herein we report a case of successful laparoscopic BE excision under the guidance of isosulfan blue.

Methods

Case: A 42-year-old female with a history of two c-sections and laparoscopic hysterectomy due to adenomyosis presented with pain recurrence 2 years after the surgery. Transvaginal ultrasound revealed a well-defined, slightly lobulated, hypoechoic mass on the bladder base, measuring 22x13 mm. Laparoscopic nodule excision was performed after isosulfan blue injection via cystoscopy to determine the borders of the lesion.

Results

The patient was discharged after 24 hours, and the urinary catheter was removed after a week. No perioperative complications occurred. The histopathological result confirmed the diagnosis. Her symptoms were entirely resolved in the postoperative 6th week.

Conclusions

Recognition and successful excision of the HE was achieved under the guidance of isosulfan blue. With this case, we shared our experience with an alternative dye in endometriosis surgery.

<https://player.vimeo.com/video/827023285?autoplay=1>

ES32-0490 - VP042

Video in Poster

A difficult case of post hysterectomy vault prolapse corrected by modified laparoscopic lateral suspension

Hossam El-Mansy¹, Mohamed Magdy²

¹Helwan University Hospitals, OBS/GYN department, Cairo, Egypt

²Ministry of Health, Gynaecology, Cairo, Egypt

Background

Post hysterectomy vault prolapse is one of the most difficult operations in Gynaecology. Laparoscopic lateral suspension (LLS) showed good results in these cases. Here we present a difficult case of post TLH vault prolapse using our modified technique of Laparoscopic Lateral suspension (published in ESGE 2022).

Methods

A 58 years old patient-para 3 vaginally with history of TLH 6 months ago. The vault prolapses started just two weeks after the operation.

The first step was to identify the anatomy. The colpotomizer was inserted in the vagina. No significant adhesions were present, but the extent of the urinary bladder was unidentifiable. The bladder was inflated with 150 cc saline so that the extent is identified. Cautious meticulous dissection of the bladder and posteriorly (colpotomizer guided) till complete dissection. The vault was opened using monopolar hook.

The stem of the mesh was fixed vaginally and the mesh was introduced inside. The vault was closed virginally. The procedure was continued Laparoscopically where the two arms were pulled. The final step was peritonization and insertion of intraperitoneal drain.

Results

The patient stayed in the hospital for one uneventful day. The drain was removed before discharge.

Conclusions

Laparoscopic lateral suspension is a very good option in post hysterectomy vault prolapse. This modification makes it easier.

<https://player.vimeo.com/video/831311336?autoplay=1>

Ultrasound-guided hysteroscopic resection of products of conception in an early pregnancy loss

Dianne Manzano¹

¹Ilocos Training and Regional Medical Center, Department of Obstetrics and Gynaecology, Dagupan City, Philippines

Background

The objective of this video presentation is to report a case of early pregnancy loss managed successfully with ultrasound-guided hysteroscopic removal of products of conception.

Methods

This was a case of a 33-year-old, G2P0 (0020), missed abortion at 13 weeks AOG. She had previous surgery of ultrasound-guided lysis of intrauterine adhesions for Asherman's Syndrome four months ago. A serum beta HCG revealed 153.6 mIU/mL. Transvaginal ultrasound confirmed the pregnancy with a gestational sac at 5 weeks AOG. She had vaginal spotting not associated with hypogastric pain. She was given Dydrogesterone 10 mg/tab 1 tablet thrice daily which afforded relief of her symptom. Four weeks after, a repeat ultrasound revealed the absence of a gestational sac and a retained product of conception. She was scheduled for a hysteroscopy under spinal anaesthesia blocked. On diagnostic hysteroscopy, the product of conception was seen attached on the posterior lower endometrial cavity, non-necrotic, with minimal vascularity seen surrounding the tissue. A normal endometrium was seen from the right lateral upper to mid-lower uterine cavity. The resectoscope was inserted and an angled cutting loop was applied in the cephalocaudal direction in between the cleavage plane of the endometrium and the products of conception until the tissue was completely detached. This was done under ultrasound guidance. The mild intrauterine adhesion in the fundal area was cut with a micro scissor.

Results

The hysteroscopic fluid deficit was 200 cc. Under ultrasound guidance, hysteroscopic removal of the products of conception was done completely with lysis of mild intrauterine adhesions using micro scissors. There were no intraoperative or postoperative complications. Eleven months after the procedure the patient got pregnant

Conclusions

Hysteroscopic removal of products of conception is a safe procedure and it minimizes the rate of intrauterine adhesions in the future which can result in fertility problems.

<https://player.vimeo.com/video/831654170?autoplay=1>

ES32-0641 - VP056

Video in Poster

Shaving off of a cervical endometriotic nodule with TLH + BS

Emre Kar¹, Yucel Kocyigit², Husnu Gorgen², Faruk Buyru², Ercan Bastu³

¹Çam and Sakura City Hospital, Obstetrics and Gynaecology, Istanbul, Turkey

²Fulya Acibadem Hospital, Obstetrics and Gynaecology, Istanbul, Turkey

³Nesta Clinic, Obstetrics & Gynaecology, Istanbul, Turkey

Background

Age: 47

History: 2 L/S Endometrioma Excision, 1 C/S

Chief Complaints: Menorrhagia and anemia resistant to Medication and Mirena. Pain located near pelvis and coccyx increasing in the last 3 months.

PE: A nodule with blunt borders located in the posterior fornix

TV-USG: Uterus AV, increased in size. Adenomyotic on the posterior wall. Nodularity reaching to the isthmic level. •MRI: a 19x12mm nodule in the Douglas pouch at cervical level

Methods

Shaving off of the nodule from rectum + TLH + BS

Results

Total excision

Conclusions

Endometriotic nodules with high adhesions to the rectum may be shaved off carefully without resection with total resolution of the symptoms

<https://player.vimeo.com/video/831675596?autoplay=1>

ES32-0645 - VP057

Video in Poster

An effective and low-cost ovarian suspension technique for improve pelvic exposure during endometriosis surgery

Milenko Pavlovic¹, Dusan Bader¹, Hugo Sovino²

¹*Clinica Davila, Obstetrics and Gynaecology, Santiago, Chile*

²*Clinica Indisa, Obstetrics and Gynaecology, Santiago, Chile*

Background

Ovarian suspension procedure is frequently performed during endometriosis surgery, to improve the exposure of the pelvis. Several techniques have been described in the literature for this purpose. One of the most frequently employed technique is the use of T´Lift device. This device may not be available in some gynaecologic units and other alternatives may be needed. One option is to use a straight needle through the abdominal wall, but the manipulation of this kind of needles may be challenging, especially when the pelvic space is narrow.

Methods

We present one technique of ovarian suspension employing a standard Vicryl 0 CT1 suture. This kind of suture is available in almost all gynaecological units worldwide, it is more affordable than a T´Lift device and the manipulation of the needle is simpler.

Results

A classic laparoscopic setup is established, with three 5mm trocars in the suprapubic region. One trocar is positioned at the midline and two trocars are placed in the iliac fossae. The accessory trocar placed in the iliac fossae is removed to pass through it, outside of the abdominal cavity, a needle holder. The suture is grasped with the needle holder at 2 cm of the needle and then is passed through the abdominal wall at the point of the accessory trocar insertion. After achieving the introduction of the needle in the abdominal cavity, the trocar is pushed through the abdominal wall, using the needle holder as a guide. Finally, a simple suture point is passed through the ovary, the needle is taken out of the abdominal cavity and the Vicryl suture is secured to the skin surface by a Kelly clamp.

Conclusions

This ovarian suspension technique using a Vicryl 0 CT1 suture, is a simple, fast, reproducible and low-cost procedure, making it an excellent alternative to other approaches.

<https://player.vimeo.com/video/831678081?autoplay=1>