

ANATOMICAL CADAVERIC SYNDESMOTIC ANKLE LIGAMENT LABORATORY TESTING



CHAPTER 4:

Anatomical cadaveric syndesmotic ankle ligament laboratory testing

Determining the Force required in arthroscopic evaluation to assess the stability of syndesmotic ankle injury – a cadaveric study.

Journal of ISAKOS (2019)

D'Hooghe P, Chambers M, Hogan M, Musahl V, Alkhelaifi K, Montassar T, Fu F, Kaux JF

D'Hooghe P, et al. JISAKOS 2019;4:100–104. doi:10.1136/jisakos-2017-000183

ABSTRACT

Background:

The diagnosis of isolated distal tibiofibular syndesmotic ankle instability proves to be a challenge. Although diagnostic imaging has added value, it is limited in the detection of distal syndesmotic ankle instability.

The gold standard remains intra-operative testing through arthroscopic probing while externally stressing the ankle in a sagittal direction. However, no validated arthroscopic guidelines have been established to distinguish a stable from an unstable syndesmotic ankle joint. This cadaveric study presents anatomical and biomechanical data that can help surgeons correctly identify isolated distal syndesmotic ankle instability.

Purpose:

The purpose of this study is to quantify the necessary forces applied during ankle arthroscopy to evaluate syndesmotic instability in freshly frozen cadaveric ankles.

Methods:

A total of 16 fresh frozen cadaveric (age 58–74 years) ankles were included in the study. A dynamometer was used to measure the force necessary for the shaver tip to be inserted into the distal tibiofibular joint with the ankle in a neutral position. Measurements were performed first with the syndesmosis intact, and again following progressive transection of the syndesmotic ligaments, along with distal fixation.

Results:

Significant differences were noted in the mean force required between the anterior inferior tibiofibular ligament (AITFL)+interosseous ligament (IOL) and no ligament cut methods ($p < 0.001$ between the AITFL+IOL and AITFL cut ($p < 0.001$; 95% CI 44.80 to 50.70), and between the AITFL+IOL and AITFL+IOL+PITFL cut ($p < 0.001$). There were also significant differences in the necessary mean forces applied between the one-SB and two-SB methods ($p < 0.001$), between the one-SB and one-screw methods ($p = 0.010$), between the one-SB and two-screw methods ($p = 0.01$), between the two-SB and two-screw methods ($p = 0.003$) and between the one-screw and two-screw methods ($p < 0.001$).

Significant differences were found between the AITFL+IOL cut and the one-SB ($p<0.001$), the two-SB ($p<0.001$), the one-screw ($p<0.001$) and the two-screw ($p<0.001$) methods.

Conclusion:

This cadaveric study provides biomechanical data that can assist the surgeon in the arthroscopic evaluation of syndesmotic injuries. The data from this study need to be clinically correlated to ultimately assist in improving the outcome of patients with syndesmotic ankle injuries. Our study offers to bridge the gap to the development of arthroscopic tools that can identify the need for surgical fixation to the syndesmosis based on the laxity of specific ankle ligaments that contribute to subtle instability.

What are the new findings?

- ▶ This cadaveric study provides biomechanical data that can assist surgeons in the arthroscopic evaluation of syndesmotic injuries.
- ▶ This cadaveric study aims at bridging the gap to the development of arthroscopic tools that can identify the need for surgical fixation to the syndesmosis based on the laxity of specific ankle ligaments that contribute to subtle instability.
- ▶ Since there are no validated arthroscopic measurements available yet, that the arthroscopic surgeon can use to identify subtle distal syndesmotic ankle instability, this cadaveric study offers new data in the process.

INTRODUCTION

The distal ankle syndesmosis is a fibrous articulation in which the opposing joint surfaces are joined by a complex of three ligaments. The anterior and posterior tibiofibular ligaments form the syndesmosis, along with the interosseous ligament. The inferior transverse tibiofibular ligament can be considered as a fourth syndesmotic ligament, but is rather an extension of the posterior tibiofibular ligament.^{1,2} In the absence of a fracture, an isolated syndesmotic injury can occur as a result of an external rotation force acting on the foot, leading to eversion of the talus within the ankle mortise and increased dorsiflexion or plantar flexion.^{3,4} It can also occur after traumatic supination in association with injury to the lateral ligaments.⁵ Such syndesmotic injuries have

been increasingly recognized in athletes since they can be associated with long-term ankle dysfunction and loss of time from play.⁶⁻⁸

According to the West Point Ankle Grading System, three grades of syndesmotic injuries can be distinguished.¹ A grade I injury involves a partial tear to the anterior inferior tibiofibular ligament (AITFL) with a normal ankle radiograph. Grade II indicates a complete rupture of the AITFL and a partial tear of the interosseous ligament (IOL) with a normal ankle radiograph, but a positive external rotation or squeeze test. There is no consensus regarding the stability of this injury pattern and they are often referred to as having latent instability.⁸

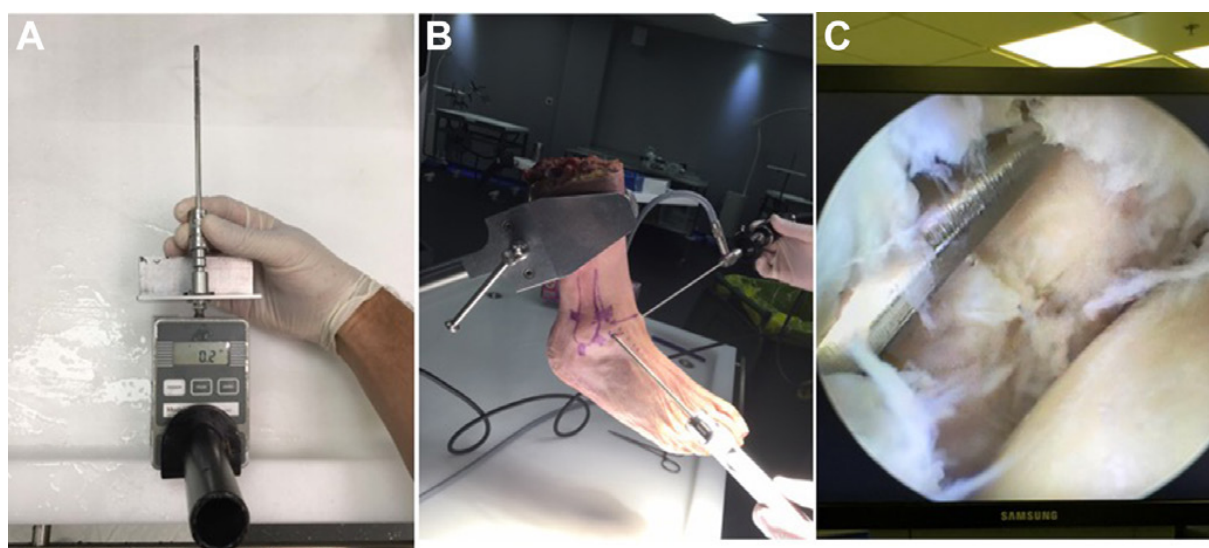


Figure 1. Arthroscopy set-up: (A) Presentation of the dynamometer and how the shaver is mounted onto it. The dynamometer shaver tip is inserted into the distal tibiofibular joint with the ankle in a neutral position during arthroscopy. (B) Overall set-up of the cadaveric specimen, portals, arthroscope and shaver during the testing procedures. (C) Intra-articular view of the anterolateral tibiotalar joint area with the shaver positioned during entry to the distal ankle syndesmosis.

Grade III injuries involve a complete disruption of the syndesmotic ligaments and a weight bearing ankle radiograph that is unstable with mortise widening.⁹ Stress radiographs and MRI can be helpful in the diagnosis of these injuries, but currently there is no best evidence-based test available that can identify syndesmotic instability, especially in Grade II lesions. This is particularly relevant in the athletic population, where appropriate management is crucial for the player to return to the team.⁸ There is a consensus to use arthroscopy in the evaluation of syndesmotic stability in doubtful cases, but there is no surgical

protocol available (except expert opinion) to identify syndesmotic stability under direct visualization with arthroscopy.⁹

The purpose of this study is to quantify the necessary forces applied during ankle arthroscopy to evaluate syndesmotic instability by using freshly frozen cadaveric ankles.

MATERIALS & METHODS

A total of 16 freshly frozen cadaveric (age range, 58–74 years) ankles were used for this study. Foot and ankle specimens were secured using a clamp and the standard arthroscopic portals were established (Figure 1). An intra-articular view was established to visualize the anterolateral tibiotalar joint as the shaver was inserted into the distal ankle syndesmosis (Figure 1). A dynamometer (Aspetar Model 12–0343, 2017) was adjusted to a 4 mm arthroscopic shaver to measure the force necessary to enter a 4 mm shaver tip 1 cm above the tibiocrural joint line in the distal syndesmosis with the ankle in a neutral position during arthroscopy (Figure 1).

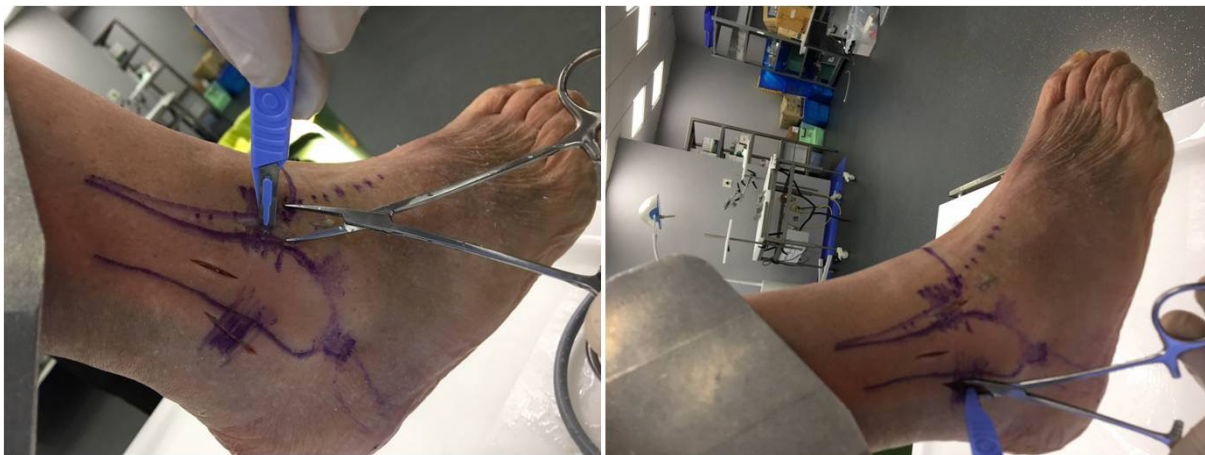

Figure 2. Ligament transections: Presentation on how the anterior inferior tibiobfibular ligament and posterior inferior tibiobfibular ligament are cut prior to testing.

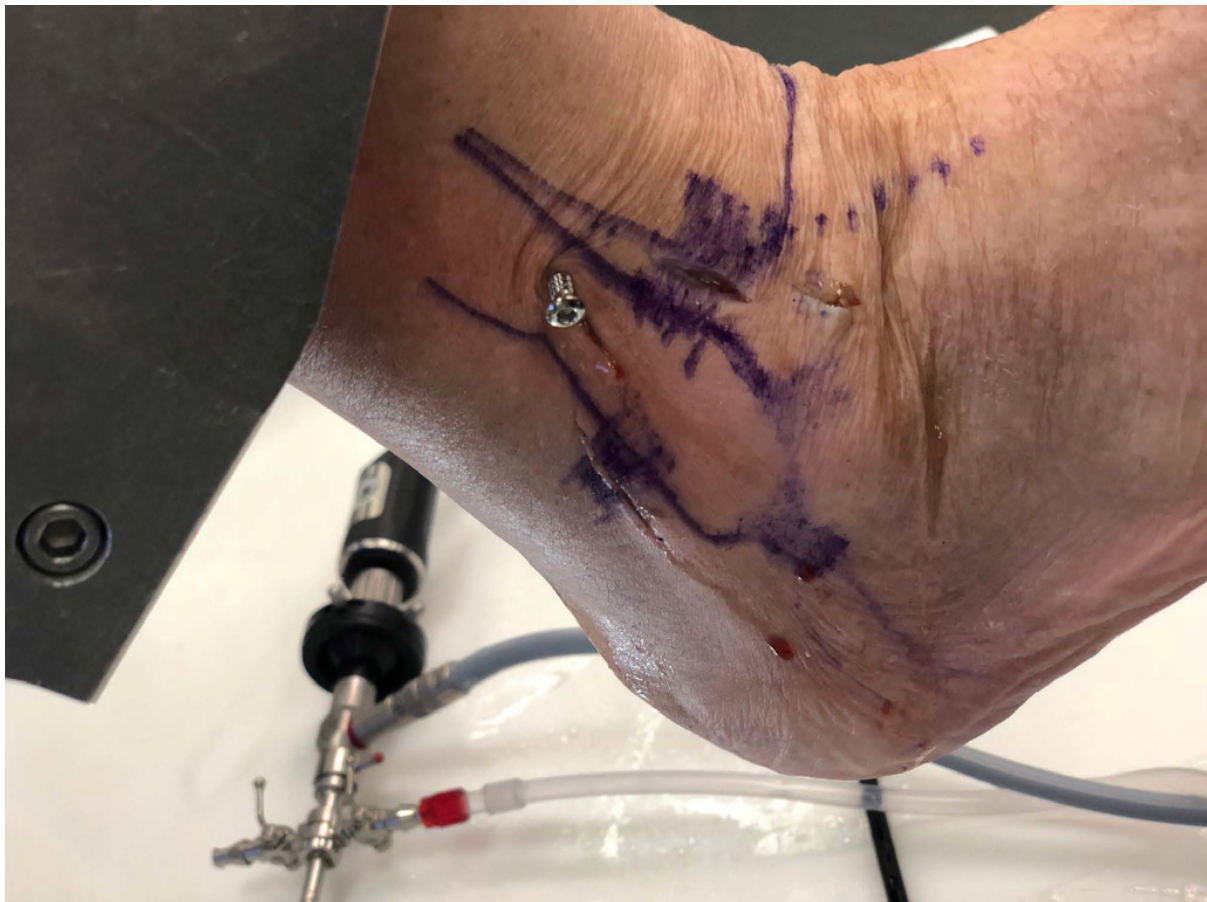

Figure 3. Screw fixation image showing how the screw was positioned (2-cortical, between 2 cm and 4 cm proximal from the tibiotalar joint and aimed at 30° of anterior angulation).

The dynamometer was trial tested to calibrate and assure measured accuracy based on 0.1 Newton.

The measurement was performed first with the syndesmosis intact, then with subsequent cutting of the AITFL, the IOL and the posterior inferior tibiofibular ligament (PITFL) (Figure 2). The force required to enter the 4 mm shaver tip, 1 cm proximal to the distal tibiotalarofibular joint was measured. After sectioning the AITFL and the IOL, two areas were prepared for syndesmotic suture button repair and two areas for syndesmotic screw fixation. A suture button was used to stabilize the syndesmosis and the shaver tip test was repeated. A second suture button was then introduced and the model was tested again. Next, the suture buttons were removed and one syndesmotic screw was introduced and the shaver test was repeated again. Finally, two screws were fixated for another shaver test check (Figure 3). The suture button/screw fixation was only

performed for the AITFL/IOL rupture combination, since the principal focus of this study is on the intra-operative decision making on Grade II syndesmotic injuries. All of the surgical procedures were completed by the same trained orthopaedic surgeon.

Statistical analysis

Descriptive data are presented as means \pm SD. Kolmogorov's test was applied to test the normal distribution of the data. Levene's test was applied to control for parametrical assumptions for homogeneity of variance. The sphericity was tested by the Mauchly test. When the assumption of sphericity was not met, the significance of F-ratios was adjusted according to the Greenhouse-Geisser procedure. The forces applied for the four surgical methods (no ligament cut, AITFL cut, AITFL+IOL cut and AITFL+IOL+ PITFL cut) were compared through a one-way analysis of variance (ANOVA) for repeated measures.

The same statistical analysis was used in order to compare the one-SB, the two-SB, the one-screw and the two-screw methods. Post hoc analysis included pairwise comparisons using Bonferroni interval adjustment to identify the significant differences. A paired-samples t-test was used to compare the AITFL+IOL cut method with the one-SB, the two-SB, the one-screw and the two-screw methods, respectively. The magnitude of the differences was assessed by effect sizes (η^2).¹⁰ This analysis considers η^2 values as: small ($\eta^2=0.02$), medium effect size ($\eta^2=0.13$) or large effect size ($\eta^2=0.26$).¹⁰ Statistical significance was set at $p<0.05$ and all analyses were carried out using SPSS V.20.0 programme for OS X (SPSS, Chicago, Illinois, USA).

RESULTS

Comparison of ligaments transected

The necessary mean forces, applied during the surgical procedure using the intact ligament, the AITFL cut, the AITFL+IOL cut and the AITFL+IOL+ PITFL cut methods are presented in table 1.

ANOVA revealed that there was a main effect on the necessary force applied based on the method used for ligamentous transection ($F_{2,09,31.30}=2458.13$, $p<0.001$, $\eta^2=0.994$). Significant differences were found between the AITFL+IOL and no ligament cut methods ($p<0.001$; 95% CI 66.71 to 73.16), between the AITFL+IOL and AITFL cut methods ($p<0.001$; 95% CI 44.80 to 50.70), and between the AITFL+IOL and AITFL+IOL+ PITFL cut methods ($p<0.001$; 95% CI

1.63 to 4.99). The force needed decreased by 25% when the AITFL was severed and by more half when the IOL was additionally severed. Additional section of the PITFL had a negligible effect.

Comparison of fixation methods

The necessary mean forces applied during the surgical procedure using the one-SB, the two-SB, the one-screw and the two-screw methods are detailed in table 2 and averages are presented in figure 4.

Original article

Table 1 Force required based on ligament deficiency

Specimen number	All intact	AITFL deficient	AITFL+IOL deficient	Complete transection
1	126 N	102 N	61 N	58 N
2	132 N	109 N	66 N	63 N
3	139 N	110 N	67 N	62 N
4	119 N	101 N	56 N	55 N
5	111 N	98 N	48 N	45 N
6	136 N	110 N	68 N	62 N
7	131 N	108 N	58 N	58 N
8	121 N	99 N	49 N	45 N
9	129 N	104 N	53 N	51 N
10	137 N	112 N	63 N	59 N
11	117 N	99 N	49 N	46 N
12	130 N	105 N	56 N	51 N
13	119 N	102 N	50 N	45 N
14	141 N	111 N	65 N	57 N
15	123 N	106 N	52 N	52 N
16	129 N	109 N	60 N	59 N

Individual force needed to enter the 4 mm shaver blade into the distal syndesmosis when: no ligament was cut, the AITFL was cut, the AITFL and IOL were cut, the AITFL, IOL and PITFL were cut (all three cut).
AITFL, anterior inferior tibiofibular ligament; IOL, interosseous ligament.

Table 2 Force required based on fixation type

Specimen number	1 SB	2 SB	1 screw	2 screws
1	111 N	114 N	115 N	117 N
2	119 N	119 N	124 N	128 N
3	121 N	125 N	122 N	125 N
4	109 N	113 N	112 N	117 N
5	102 N	108 N	107 N	119 N
6	122 N	126 N	125 N	131 N
7	117 N	119 N	124 N	128 N
8	110 N	117 N	109 N	114 N
9	116 N	121 N	115 N	119 N
10	117 N	123 N	119 N	126 N
11	107 N	118 N	115 N	121 N
12	115 N	124 N	117 N	128 N
13	111 N	115 N	111 N	124 N
14	130 N	132 N	128 N	140 N
15	122 N	128 N	127 N	132 N
16	120 N	130 N	129 N	134 N

Individual force needed to enter the 4 mm shaver blade into the distal syndesmosis with the following fixation: 1 SB, 2 SB, 1 screw, 2 screws.

ANOVA showed a main effect of fixation type ($F_{3,45}=40.21$, $p<0.001$, $\eta^2=0.728$) on the force applied throughout the surgical procedures using the SB and screw methods.

Considering pairwise comparisons, significant differences were found between the one-SB and two-SB methods ($p<0.001$; 95% CI 2.9 to 7.46), between the one-SB and one-screw methods ($p=0.010$; 95% CI 0.63 to 5.61), between the one-SB and two-screw methods ($p=0.010$; 95% CI 6.58 to 12.67), between the two-SB and two-screw methods ($p=0.003$; 95% CI 1.39 to 7.49), between the one-screw and two-screw methods ($p<0.001$; 95% CI 3.84 to 9.16). However, no significant difference was found between the two-SB and one-screw methods ($p=0.24$).

Comparison of the AITFL+IOL cut with the SB and screwMethods

For the one-SB method, $t(15)=43.84$; ($p<0.001$; 95% CI 55.18 to 60.81), the two-SB $t(15)=38.20$ ($p<0.001$; 95% CI 59.66 to 66.71), the one-screw revealed $t(15)=43.23$ ($p<0.001$; 95% CI 58.11 to 64.13) and the two-screw had a $t(15)=39.60$ ($p<0.001$; 95% CI 63.98 to 71.26), respectively (table 3).

DISCUSSION

The results of this study showed a significant decrease in the force required with any of the ligaments transected. The most notable difference was shown when the AITFL, PITFL and the IOL were all transected, as expected since this would reflect the greatest instability. Additionally, the type of fixation also impacted joint stability, evidenced by the force required. The greatest amount of force needed was seen with the two-screw fixation, suggesting that this method provides the greatest stability for the syndesmosis. These results were consistent in the average forces required, as well as intra-specimen measurements.

Stable isolated syndesmotic lesions can be treated conservatively, while unstable lesions require surgery.⁹ The indication for surgery includes a positive squeeze test with a positive external rotation test, tenderness over the anterior interosseous ligament, 5 cm proximal to the ankle joint and injury to the deltoid ligament or the posterior inferior tibiofibular ligament on MRI.^{2,11-13}

The radiographic measurements of an intact syndesmosis have great variability.¹⁴ The 'tibiofibular clear space' and the 'tibiofibular overlap' are the most frequently used radiographic measurements to determine instability.^{15,16} Although MRI can accurately identify individual ligamentous ruptures, studies that use the clear space and overlap measurements, unfortunately, do not correlate with syndesmotic instability. Also, since an MRI is not a dynamic test, it cannot diagnose abnormal joint movement.^{3,13}

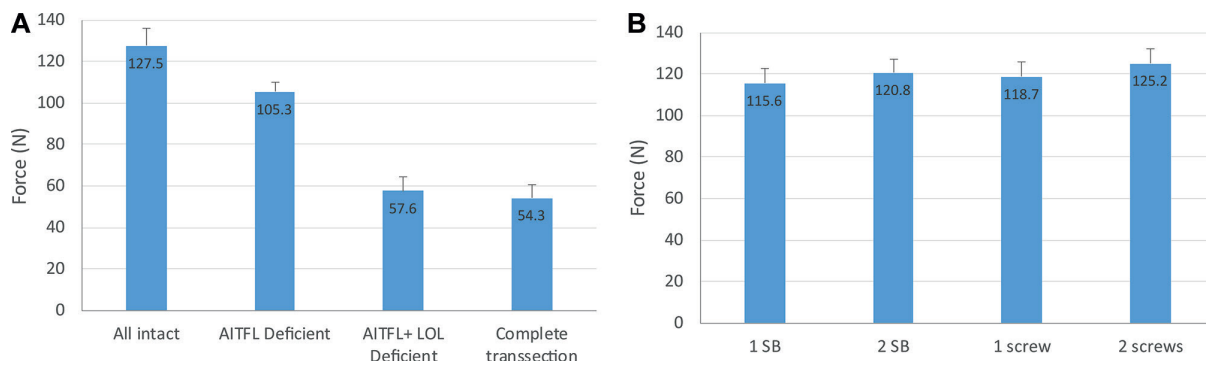


Figure 4. Mean Force: Measured Mean force needed based on the ligament cut methods and for the application of the SB and screw methods. AITFL, anterior inferior tibiofibular ligament; IOL, interosseous ligament.

In Grade II syndesmotic lesions, it is unclear which injuries should be treated conservatively or surgically. Currently, we are unable to quantify syndesmotic (in)stability arthroscopically, since there are no established arthroscopic criteria available.¹⁷

There is a consensus among experts that arthroscopy is the gold standard in the evaluation of syndesmotic instability.^{9,18} During arthroscopy, isolated syndesmotic instability can be assessed by inserting a 4 mm shaver tip into the anterior distal syndesmosis of the ankle to determine if there is syndesmotic disruption. This allows for the evaluation of distal syndesmotic joint space opening, while moving the ankle in external rotation. More than 4 mm of joint space opening has been accepted as being indicative of instability.⁹

Ankle arthroscopy is a more sensitive method in the detection of syndesmotic instability compared with stress radiography.^{1,12,17,19} Although there is still no consensus on how much diastasis the syndesmotic joint complex allows for to maintain physiological stability in the anterior compared with the posterior part of the syndesmosis, there is a known variation in distance between the tibia and fibula over the joint line.¹⁹ Especially the central part—that contains the tibiofibular syndesmotic recess—has variable differences in its dimensions.²⁰ Another topic of debate remains the location and the required force application to arthroscopically measure syndesmotic diastasis.⁹

Most authors agree to confirm arthroscopic stabilization of the distal tibiofibular joint in cases of doubt to avoid progression to chronic syndesmotic instability.¹⁷ In our cadaveric study, the force required to enter the distal syndesmosis was tested as recommended arthroscopically. A study by Takao et al demonstrated the value of arthroscopy as an accurate indicator for a

tibiofibular syndesmotoc tear.¹⁷ In cases of subtle syndesmotoc instability, however, every patient would require arthroscopic surgery as an invasive diagnostic tool. It can also be challenging to identify subtle syndesmotoc instability in less experienced arthroscopic surgeons. Furthermore, an arthroscopic finding of a ruptured anterior syndesmotoc ligament does not unequivocally mean there is syndesmotoc instability, because the interosseous complex (ligament and membrane) cannot reliably be assessed during ankle arthroscopy.

Table 3 Fixation w/AITFL+ IOL deficiency t-test

	t (15)	95% CI	P value
SB	43.84	55.18 to 60.81	<0.001
2 SB	38.2	59.66 to 66.71	<0.001
1 screw	43.23	58.11 to 64.13	<0.001
2 screws	39.6	63.98 to 71.26	<0.001

Significant differences found based on the fixation method with the AITFL+IOL cut. AITFL, anterior inferior tibiofibular ligament; IOL, interosseous ligament.

Indicators of instability, such as fibular subluxation, deltoid ligament injuries and posterior malleolar fractures should also be taken into account in the preoperative planning.²¹

Previous studies present a variety of methods and cut-off points to differentiate stable from unstable syndesmotoc injuries. Leeds indicated movement ≥ 2 mm between the tibia and fibula as a diagnosis of instability.²² Wagener et al. confirmed to instability if at least 3 mm of the test probe could swiftly be inserted and twisted in the syndesmosis.¹⁹ Another syndesmotoc evaluation method defines instability if the degree of fibular dislocation from the tibiofibular joint is more than 1 mm.¹²

Current literature does not provide us with clear and reproducible guidelines on the amount of displacement or degree of diastasis that are required to indicate syndesmotoc stabilization.^{1,9,18}

Also, most studies do not mention the testing location or necessary force used to detect syndesmotoc instability. Van de Bekerom et al showed that a lateral force of 100 N to the ankle mortise seems appropriate to diagnose instability and that forces of >100 N did not show a substantial increase in displacement.¹⁹ The main limitations of this study are that all measurements were taken on cadaveric specimens with a large age range without specific information on

previous ankle injury. The sample size was based on the known incidence of syndesmotic injuries, as well as the intra-reliability of the testing parameters. However, this study still has a relatively small sample size. Although the testing was performed by only one surgeon, the force to enter the distal syndesmosis can be operator-dependent. Additionally, having more than one observer would allow for us to assess the inter-reliability of observers and strengthen the reliability of this testing method. Also, several authors have concluded that the assessment of sagittal plane movement appears to be a more sensitive test of inferior tibiofibular instability than assessment in the coronal plane.

This study only looked at coronal plane syndesmotic instability. Furthermore, most of the aforementioned studies that assess distal syndesmotic instability are related to injuries with combined ankle fractures involved. Caution must be taken in interpreting the results of these studies related to ankle syndesmotic injuries without a fracture.

Clinical relevance

This cadaveric study presents the next step towards the validation of arthroscopic testing of syndesmotic injuries. Currently, there are cadaveric studies published that are not directly applicable to intra-operative utilization. Particularly, in the case of Grade II injuries, identifying the stable versus unstable ankle remains a challenge, since both radiographic imaging tools and clinical diagnostic tests are inconclusive. Even arthroscopic evaluation has relied heavily on surgeon experience and expert opinion without a standardized, validated measurement tool.

The data from this study need to be clinically correlated to ultimately assist in improving the outcome of patients with syndesmotic ankle injuries. Therefore, our study offers to bridge the gap to the development of arthroscopic tools that can identify the need for surgical fixation to the syndesmosis based on the laxity of specific ankle ligaments that contribute to subtle instability. Furthermore, the methods used in this study are reliable and accurate, allowing surgeons to examine the syndesmosis during arthroscopic surgery.

CONCLUSION

Together with stress radiographs and MRI, there are helpful clinical tests available to indicate syndesmotic ligament injury. Nonetheless, there is no best-evidence criteria to evaluate instability. This cadaveric study provides biomechanical data that can assist surgeons in the arthroscopic evaluation of syndesmotic injuries.

REFERENCES

1. van Dijk CN, Longo UG, Loppini M, et al. Classification and diagnosis of acute isolated syndesmotic injuries: ESSKA-AFAS consensus and guidelines. *Knee Surg Sports Traumatol Arthrosc* 2016;24:1200–16.
2. Ebraheim NA, Taser F, Shafiq Q, et al. Anatomical evaluation and clinical importance of the tibiofibular syndesmosis ligaments. *Surg Radiol Anat* 2006;28:142–9.
3. Beumer A, Valstar ER, Garling EH, et al. External rotation stress imaging in syndesmotic injuries of the ankle: comparison of lateral radiography and radiostereometry in a cadaveric model. *Acta Orthop Scand* 2003;74:201–5.
4. van den Bekerom MP, Haverkamp D, Kerkhoffs GM, et al. Syndesmotic stabilization in pronation external rotation ankle fractures. *Clin Orthop Relat Res* 2010;468:991–5.
5. van den Bekerom MP, Mutsaerts EL, van Dijk CN. Evaluation of the integrity of the deltoid ligament in supination external rotation ankle fractures: a systematic review of the literature. *Arch Orthop Trauma Surg* 2009;129:227–35.
6. Woods C, Hawkins R, Hulse M, et al. The football association medical research programme: an audit of injuries in professional football: an analysis of ankle sprains. *Br J Sports Med* 2003;37:233–8.
7. Kofotolis ND, Kellis E, Vlachopoulos SP. Ankle sprain injuries and risk factors in amateur soccer players during a 2-year period. *Am J Sports Med* 2007;35:458–66.
8. Roemer FW, Jomaah N, Niu J, et al. Ligamentous injuries and the risk of associated tissue damage in acute ankle sprains in athletes: a cross-sectional MRI study. *Am J Sports Med* 2014;42:1549–57.
9. van Dijk CN, Longo UG, Loppini M, et al. Conservative and surgical management of acute isolated syndesmotic injuries: ESSKA-AFAS consensus and guidelines. *Knee Surg Sports Traumatol Arthrosc* 2016;24:1217–27.
10. Cohen J. *Statistical power analysis for the behavioral sciences*. 2nd edn. Hillsdale, NJ: Lawrence Erlbaum Associates, 1988.
11. Sman AD, Hiller CE, Refshauge KM. Diagnostic accuracy of clinical tests for diagnosis of ankle syndesmosis injury: a systematic review. *Br J Sports Med* 2013;47:620–8.
12. Vopat ML, Vopat BG, Lubberts B, et al. Current trends in the diagnosis and management of syndesmotic injury. *Curr Rev Musculoskelet Med* 2017;10:94–103.
13. Oae K, Takao M, Naito K, et al. Injury of the tibiofibular syndesmosis: value of MR imaging for diagnosis. *Radiology* 2003;227:155–61.
14. Xenos JS, Hopkinson WJ, Mulligan ME, et al. The tibiofibular syndesmosis. Evaluation Of the ligamentous structures, methods of fixation, and radiographic assessment. *J Bone Joint Surg Am* 1995;77:847–56.
15. Harper MC. An anatomic and radiographic investigation of the tibiofibular clear space. *Foot Ankle* 1993;14:455–8.
16. Pneumaticos SG, Noble PC, Chatziioannou SN, et al. The effects of rotation on radiographic evaluation of the tibiofibular syndesmosis. *Foot Ankle Int* 2002;23:107–11.
17. Takao M, Ochi M, Oae K, et al. Diagnosis of a tear of the tibiofibular syndesmosis. The role of arthroscopy of the ankle. *J Bone Joint Surg Br* 2003;85:324–9.
18. Calder JD, Bamford R, Petrie A, et al. Stable versus unstable grade II high ankle sprains: a prospective study predicting the need for surgical stabilization and time to return to sports. *Arthroscopy* 2016;32:634–42.
19. van den Bekerom MP. Diagnosing syndesmotic instability in ankle fractures. *World J*

Orthop 2011;2:51–6.

20. Ebraheim NA, Lu J, Yang H, et al. Radiographic and CT evaluation of tibiofibular syndesmotoc diastasis: a cadaver study. *Foot Ankle Int* 1997;18:693–8.

21. Hunt KJ, Phisitkul P, Pirolo J, et al. High ankle sprains and syndesmotoc injuries in athletes. *J Am Acad Orthop Surg* 2015;23:661–73.

22. Leeds HC, Ehrlich MG. Instability of the distal tibiofibular syndesmosis after bimalleolar and trimalleolar ankle fractures. *J Bone Joint Surg Am* 1984;66:490–503.

CHAPTER

5

A NONINVASIVE APPROACH TO IDENTIFY UNSTABLE DISTAL SYNDESMOTIC ANKLE INJURIES THROUGH THE BIO-ENGINEERING OF A CLINICAL TESTING DEVICE



CHAPTER 5:

A noninvasive approach to identify unstable distal syndesmotic ankle injuries through the bio-engineering of a clinical testing device

Stable versus unstable grade 2 high ankle sprains in athletes: A noninvasive tool to predict the need for surgical fixation.

Clinical Research on Foot and Ankle Journal (2018)

D'Hooghe P, Bouhdida S, Whiteley R, Rosenbaum A, AlKhelaifi K, Kaux JF

D'Hooghe P et al., Clin Res Foot Ankle 2018, 6:1 DOI: 10.4172/2329-910X.100025

ABSTRACT

Background:

There are no standardized criteria for the diagnosis and management of syndesmotic injuries, creating great ambiguity regarding optimal treatment. Traditionally, individuals with clinical and/or radiological suspicion of syndesmotic instability warrant an examination under anaesthesia and/or diagnostic arthroscopy to confirm and treat.

Purpose:

Our aim was to identify clinical syndesmotic instability without the need of invasive arthroscopic procedures. However, the invasive process of this has inherent risks to the patient. We developed a device to dynamically evaluate the distal tibiofibular stability during external rotation of the ankle as an extension to the available clinical tests.

Methods:

We compared the results of this device with intra-operative arthroscopic findings in 15 athlete cases with isolated grade 2 syndesmotic instability and found very good correlation, especially when tested in dorsiflexion.

Conclusion:

We consider this syndhoo device very helpful as part of the available options in the clinical diagnosis of syndesmotic instability.

INTRODUCTION

Syndesmotic injuries, or high ankle sprains, comprise 10% of all ankle sprains¹. These injuries are frequently sustained during athletic competition, particularly soccer^{1,2}. However, as imaging studies suggest that up to 20% of acute ankle sprains involve the syndesmosis, the prevalence of syndesmotic injuries may be underestimated^{3,4}. Syndesmotic injuries often require twice as long to return to sport as compared to isolated lateral ligament sprains and can lead to prolonged pain and disability⁵⁻⁸. Further, the most common cause of chronic ankle dysfunction 6 months from an ankle trauma, is related to syndesmotic injuries⁷. Recurrent and undiagnosed ankle instability is known to ensue and eventually lead to premature ankle arthritis⁹.

Therefore, a timely diagnosis of unstable syndesmotic injuries is essential. A rapid pivoting and forced ankle dorsiflexion of the ankle with a forceful external rotation and pronation of the foot, is the most common mechanism of a high ankle sprain¹⁰. Planovalgus foot alignment, high competitive sports level and male gender are potential risk factors^{9,11,12}.

As the talus rotates in the mortise, the fibula rotates externally and moves posteriorly and laterally. This mechanism then separates the distal tibia and fibula and sequentially tears the AITFL, deep deltoid ligament (or causes a malleolar fracture), the Inferior Oblique Ligament (IOL), and finally the Posterior Inferior Talo-fibular Ligament ^{10,13}(PITFL).

When there is a combined syndesmotic injury with a deltoid ligament disruption, talar instability occurs¹⁴.

Less commonly, the injury may occur in forced dorsiflexion without rotation since the anterior part of the talus is wider than the posterior part. The magnitude and duration of force application appear to be predictive factors of lesion severity⁹. Syndesmotic injuries are classified in 3 Grades, ranging from a partially torn AITFL to a complete disruption of all ligaments with mortise widening¹⁵.

PURPOSE

There are no standardized criteria for the diagnosis and management of syndesmotic injuries, creating great ambiguity regarding optimal treatment. Our purpose is to identify clinical syndesmotic instability without the need of invasive arthroscopic procedures.

METHODS

The described device is developed in close collaboration between our Center's surgery and physiotherapy departments to identify syndesmotic instability necessitating (mini) open reduction and internal fixation. In our study, a Grade 2 isolated syndesmotic injury is defined as a lesion to the antero-inferior tibiofibular ligament and the interosseous ligament of the ankle with involvement of the deltoid ligament on Magnetic Resonance scanning (MRI).

We tested 15 registered athletes between the age of 18-36 years old, who presented with a Grade 2 isolated syndesmotic injury (confirmed on MRI) between 1 January 2015 and 1 May 2017. All 15 athletes were

independently tested by an experienced physiotherapist with the syndhoo device that we developed. They all had a grade 2 isolated syndesmotic injury with clinical and radiological signs of potential instability and therefore all were indicated for arthroscopy¹⁵.

For every syndhoo-tested athlete, an arthroscopy was performed by 1 experienced ankle surgeon at our Center between January 2017 and September 2017. During arthroscopy, the syndesmosis was considered positive (unstable) if a 4.5 mm arthroscopic shaver could be pushed through the distal syndesmosis, 1 cm proximal from the tibiotalar joint. The physiotherapist and surgeon were blinded to the other one's results. All patients were tested and treated between 1 and 4 weeks from the initial injury.

The principle of this syndhoo device is to dynamically evaluate the distal tibiofibular stability during external rotation of the ankle as an extension to the available clinical tests. Cadaveric testing has shown that the distal syndesmosis is unstable when a force of 87-100 N is applied. The foot is positioned and fixed on the syndhoo board that rotates over the heel (Figure 1A, Figure 1B).

The board can be put in neutral position, 20 degrees of plantar flexion and 20 degrees of dorsiflexion (Figure 1C, Figure 1D). The knee is stabilized through a patellar strap and the patient is tested in sitting position (Figure 1B).

With a dynamometer, the foot is passively externally rotated with the hinge positioned over the heel (Figure 1E, Figure 1F). When the patient experiences clinical apprehension at a force <87 N, the syndhoo test is considered positive. If the apprehension occurs during a force 87-100N, the syndhoo test is considered equivocal. When no apprehension occurs or the apprehension occurs with a force >100N, the syndhoo test is considered negative.



Figure 1A: Image of the syndhoo device (front side).

Figure 1B: Image of the syndhoo device from the side with the foot placed on the rotating board in neutral position.

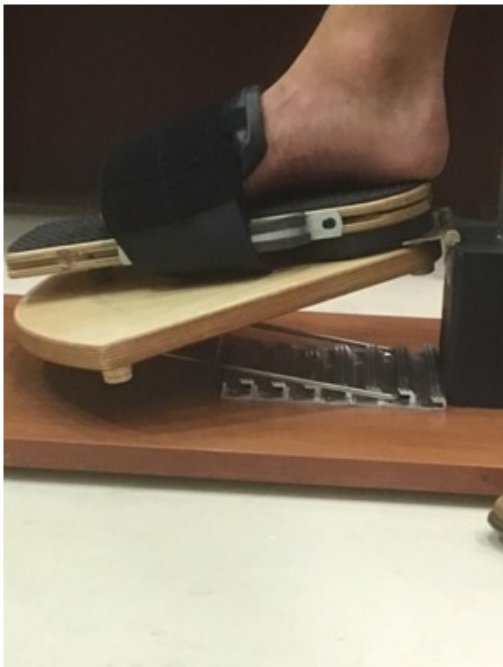

Figure 1C: Image of the syndhoo device from the side with the foot placed on the rotating board in 20 degrees of plantar flexion.

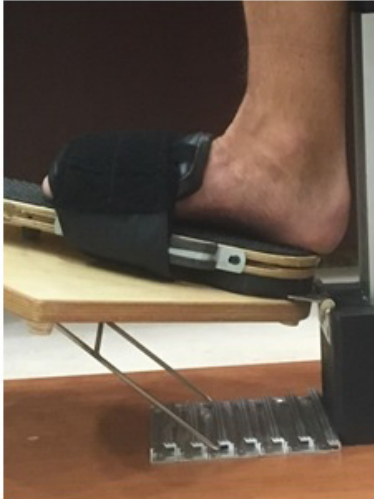

Figure 1D: Image of the syndhoo device from the side with the foot placed on the rotating board in 20 degrees of dorsiflexion.



Figure 1E: Image close up of the dynamometer, placed at the medial foot side of the rotating board.



Figure 1F: Overview image of the dynamometer, linked to the rotating board.

Statistically, Cohen's kappa (κ) has been used to determine the inter-rater agreement between the arthroscopy method (as a reference) and the three syndhoo methods (dorsiflexion, neutral, plantar flexion).

Based on the guidelines from Altman, and adapted from Landis & Koch, Cohen's kappa (κ) is interpreted as poor agreement if less than 0.20, fair agreement if between 0.20 to 0.40, moderate agreement if between 0.40 to 0.60, good agreement if between 0.60 to 0.80, and very good agreement if between 0.80 to 1.00).

RESULTS

Syndhoo dorsiflexion: when pushing manually the dynamometer in external rotation (with the board in 20 degrees of dorsiflexion), the test is considered positive if the athlete feels apprehension at a force <87 Newton (N).

Syndhoo neutral: when pushing manually the dynamometer in external rotation (with the board in neutral position), the test is considered positive if the athlete feels apprehension at a force <87 Newton (N).

Syndhoo plantar flexion: when pushing manually the dynamometer in external rotation (with the board in 20 degrees of plantar flexion), the test is considered positive if the athlete feels apprehension at a force <87 Newton (N).

The descriptive results of the four types of diagnosis are presented in Table 1.

Subject ID	Left Ankle	Right Ankle	Syndhoo Dorsiflexion	Syndhoo Neutral	Syndhoo Plantar Flexion	Arthroscopy
1	2		Positive	Positive	Positive	Positive
2	11.2		Negative	Negative	Negative	Negative
3	13		Negative	Negative	Negative	Negative
4		3.2	Positive	Positive	Positive	Positive
5	6]		Positive	Negative	Negative	Positive
6	5.8		Positive	Negative	Negative	Positive
7	1.6		Positive	Positive	Positive	Positive
8	7		Positive	Negative	Negative	Positive
9		5.4	Positive	Positive	Negative	Positive
10	8,6		Negative	Negative	Negative	Negative
11	8		Negative	Negative	Negative	Negative
12	8,4		Negative	Negative	Negative	Negative
13	3,6		Positive	Positive	Positive	Positive
14	5,6		Positive	Negative	Negative	Positive
15	6,2		Positive	Negative	Negative	Positive

Table 1: Diagnosis results.

There was very good agreement between arthroscopy and syndhoos dorsiflexion diagnosis ($\kappa=1$, $p<0.001$). However, no significant agreement was found between arthroscopy, and syndhoos neutral and syndhoos plantar flexion ($p=0.053$ and $p=0.99$, respectively).

DISCUSSION

Syndesmotic injuries are divided into three Grades. Grade I represents an AITFL sprain without instability. Grade II represents an AITFL tear and a partial IOL tear with mild instability. Grade III represents a complete rupture of all 3 syndesmotic ligaments with evident instability^{7,15}.

The severity of the syndesmotic instability guides the choice of treatment. Grade I injuries are treated non-surgically¹⁶ while the treatment of Grade II injuries depends on the presented syndesmotic (in)stability testing¹⁷. Stable syndesmotic injuries (type I and IIa) should be treated conservatively, whereas unstable injuries (type IIb and III) warrant surgical fixation. A recent study found that a positive squeeze test and combined injury to the ATFL and deep deltoid ligament, are key factors in differentiating stable (type IIa) from unstable Grade II injuries (type IIb).

Nowadays, there is a consensus to perform an examination under anaesthesia and arthroscopic evaluation of the syndesmosis in case of a Grade II injury with clinical and/or radiological suspicion of dynamic instability (type IIb) (Figure 2)^{18,19}. In case of 2 mm or more dynamic distal tibiofibular diastasis, arthroscopic-assisted surgical fixation is warranted¹⁶.

Grade III injuries often present with associated injuries and are inherently unstable. Surgical fixation by means of screws or suture buttons can be used to reduce the mortise and stabilize the syndesmosis^{20,21}. The Hook and/or Cotton test are regarded as reliable intra-operative stress tests to evaluate syndesmotic (in)- stability⁵. Cadaveric studies have shown that the syndesmosis becomes unstable (opens more than 5 mm in tibiofibular clear space) when a force above 87-100 N is applied⁵. Arthroscopy is considered 'the golden standard' in the diagnostic assessment of syndesmotic (in)stability²² and in case of doubt, fixation is advised because of the problems caused by chronic syndesmotic instability⁵.

Athletes frequently present with an inability to bear weight, anterolateral pain between the distal tibia and fibula, medial ankle pain, ankle effusion and pain during gait push off²³. However, anterolateral pain is not specific, as up to 40% of

patients with an ATFL tear describe pain over the AITFL. Clinically it's been suggested that the more proximal the patient's pain, the more significant the injury²².

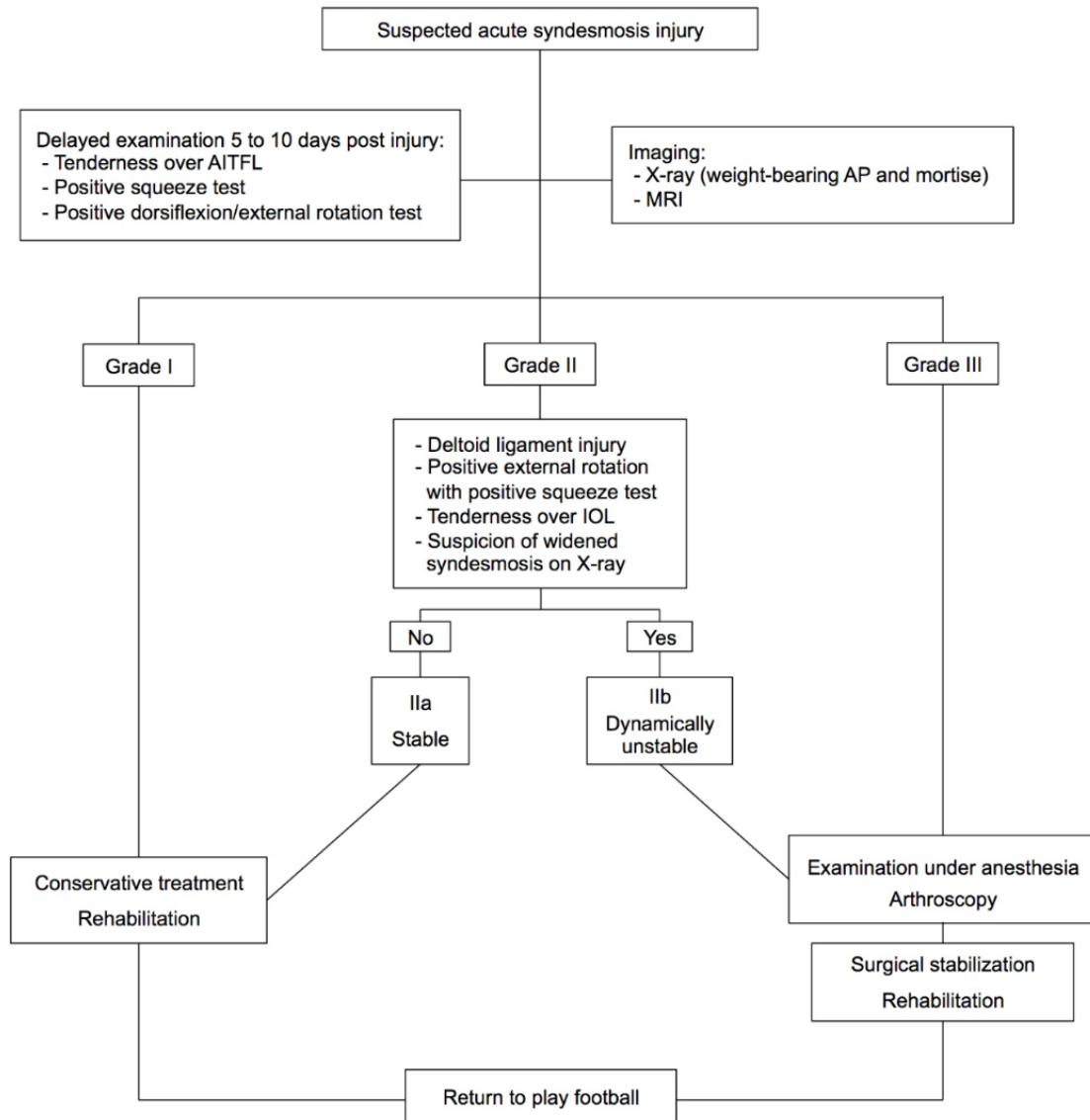


Figure 2: Treatment algorithm for suspected syndesmotic injuries. (Adapted from Ballal MS et al. Bone Joint Journal 2016 – permission to publish confirmed)

Several clinical tests can be used in the evaluation of a syndesmotic injury. The external rotation test and the squeeze test are the most commonly described tests, but the Cotton test, the fibular-translation test and the cross-legged test can also be used¹⁵. The combination of tenderness on palpation over the ATFL, a positive fibular translation test, and positive Cotton test is considered highly clinically suspicious¹⁷. Although the squeeze test has been shown to be highly

sensitive, there is no one “gold-standard” for the clinical diagnosis of syndesmotic instability²⁴. In case of clinical suspicion, advanced imaging, such as MRI, is warranted.

Plain radiographs should always be obtained when there is concern for syndesmotic injury. The tibiofibular clear space, defined as the distance between the medial border of the fibula and the lateral border of the posterior tibia, is one of the most reliable indicators of syndesmotic disruption²⁵. This distance is measured at 1 cm proximal to the tibial plafond and should not exceed 6 mm in both the AP and mortise views²⁵. Stress radiographs are no longer recommended in the routine evaluation of syndesmotic instability since biomechanical studies have not shown significant advantage over plain radiographs^{17,26}.

Computed tomography (CT) scanning can be helpful in identifying minor diastasis and small avulsion fractures²⁷. Although its value still needs further evaluation, promising new diagnostic types of bilateral standing CT scan stress view are useful²⁸.

Magnetic Resonance Imaging (MRI) can identify most ligamentous syndesmotic injuries and combined injuries¹⁷. MRI shows a sensitivity of 100% and a specificity of 93% for AITFL injuries (positive likelihood ratio of 14) and a sensitivity and specificity of 100% for PITFL injuries (infinite positive likelihood ratio)²⁹ and has high Degree of inter-observer reliability³⁰. Ultrasonography is a fast and inexpensive tool to evaluate distal tibiofibular stability and does not expose the athlete to radiation. Further, it enables a dynamic assessment of the ligamentous injury, which is useful in cases of subtle instability. Patients with an acute AITFL rupture (confirmed on MRI) show a 100% sensitivity and specificity on dynamic ultrasound evaluation¹. The disadvantages are that ultrasonography cannot detect associated injuries and is proven to be investigator dependent¹⁷.

CONCLUSION

Traditionally, individuals with clinical and/or radiological suspicion of syndesmotic instability warrant an examination under anaesthesia and/or diagnostic arthroscopy to confirm and treat. However, the invasive process of this has inherent risks to the patient. The described non-invasive syndhoo device in this article can be a valuable tool in the evaluation of isolated syndesmotic ankle instability.

Further studies on the correlation of this non-invasive test with clinical examination, imaging and arthroscopic findings are needed. Ongoing work at our institution is seeking to establish the agreement between the examination described here and MR quantification of syndesmotic injury which we hope will better depict the cut-point for a positive test.

We have found this syndhoo device very helpful as part of the available options in the clinical diagnosis of syndesmotic instability.

REFERENCES

1. Mei Dan O, Kots E, Barchilon V, Massarwe S, Nyska M, et al. (2009) A dynamic ultrasound examination for the diagnosis of ankle syndesmotic injury in professional athletes: A preliminary study. *Am J Sports Med* 37: 1009-1016
2. Kofotolis ND, Kellis E, Vlachopoulos SP (2007) Ankle sprain injuries and risk factors in amateur soccer players during a 2-year period. *Am J Sports Med* 35: 458-466.
3. Roemer FW, Jomaah N, Niu J, Almusa E, Roger B, et al. (2014) Ligamentous Injuries and the risk of associated tissue damage in acute ankle sprains in athletes: A cross-sectional MRI study. *Am J Sports Med* 42: 1549-1557.
4. Woods C, Hawkins R, Hulse M, Hodson A (2003) The football association medical research programme: An audit of injuries in professional football: An analysis of ankle sprains. *Br J Sports Med* 37: 233-238.
5. Van den Bekerom MP (2011) Diagnosing syndesmotic instability in ankle fractures. *World J Orthop* 2: 51–56.
6. Wright RW, Barlie J, Suprent DA, Matave MJ (2004) Ankle syndesmosis in national hockey league players. *Am J Sports Med* 32: 1941– 1945.
7. Gerber JP, Williams GN, Scoville CR, Arciero RA, Taylor DC (1998) Persistent disability associated with ankle sprains: A prospective examination of an athletic population. *Foot Ankle* 19: 653–660.
8. Waldén M, Hagglund M, Ekstrand J (2013) Time-trends and circumstances surrounding ankle injuries in men's professional football: An 11-year follow-up of the UEFA champions league injury study. *Br J Sports Med* 47: 748-753.
9. Williams GN, Jones MH, Amendola A (2007) Syndesmotic ankle sprains in athletes. *Am J Sports Med* 35: 1197–1207.
10. Xenos JS, Hopkinson WJ, Mulligan ME, Olson EJ, Popovic NA (1995) The tibiofibular syndesmosis: Evaluation of the ligamentous structures, methods of fixation, and radiographic assessment. *J Bone Joint Surg Am* 77: 847-856.
11. Waterman BR, Belmont PJ, Cameron KL, Svoboda SJ, Alitz CJ, et al. (2011) Risk factors for syndesmotic and medial ankle sprain: Role of sex, sport, and level of competition. *Am J Sports Med* 39: 992-998
12. Williams GN, Allen EJ (2010) Rehabilitation of syndesmotic (high) ankle sprains. *Sports Health* 2: 460-470.
13. Beumer A, Valstar ER, Garling EH, Niesing R, Ginai AZ, et al. (2006) Effects of ligament sectioning on the kinematics of the distal tibiofibular syndesmosis. *Acta Orthop* 77: 531-540.

14. Zalavras C, Thordarson D (2007) Ankle syndesmosis injury. *J Am Acad Orthop Surg* 15: 330-339.
15. Calder JD, Bamford R, Petrie A, McCollum GA (2016) Stable versus unstable grade ii high ankle sprains: A prospective study predicting the need for surgical stabilization and time to return to sports. *Arthroscopy* 32: 634-642.
16. Mc Collum GA, van den Bekerom MP, Kerkhoffs GM, Calder JD, van Dijk CN (2013) Syndesmosis and deltoid ligament injuries in the athlete. *Knee Surg Sports Traumatol Arthrosc* 21: 1328-1337.
17. van Dijk CN, Longo UG, Loppini M, Florio P, Maltese L, et al. (2016) Classification and diagnosis of acute isolated syndesmotic injuries: ESSKA-AFAS consensus and guidelines. *Knee Surg Sports Traumatol Arthrosc* 24: 1200-1216.
18. Hunt KJ, Phisitkul P, Pirolo J, Amendola A (2015) High ankle sprains and syndesmotic injuries in athletes. *J Am Acad Orthop Surg* 23: 661-673.
19. Kerkhoffs GMMJ, de Leeuw PAJ, Tennant JN, Amendola A (2014) Ankle ligament lesions. In: *The ankle in football*. Springer Verlag, Paris, pp: 81-96.
20. Schepers T (2012) Acute distal tibiofibular syndesmosis injury: A systematic review of suture-button versus syndesmotic screw repair. *Int Orthop* 36: 1199–1206.
21. van Dijk CN, Longo UG, Loppini M, Florio P, Maltese L, et al. (2016) Conservative and surgical management of acute isolated syndesmotic injuries: ESSKA-AFAS consensus and guidelines. *Knee Surg Sports Traumatol Arthrosc* 24: 1217-1227.
22. Nussbaum ED, Hosea TM, Sieler SD, Incremona BR, Kessler DE (2001) Prospective evaluation of syndesmotic ankle sprains without diastasis. *Am J Sports Med* 29: 31-35.
23. Hopkinson WJ, St Pierre P, Ryan JB, Wheeler JH (1990) Syndesmosis sprains of the ankle. *Foot Ankle* 10: 325–330.
24. Sman AD, Hiller CE, Refshauge KM (2013) Diagnostic accuracy of clinical tests for diagnosis of ankle syndesmosis injury: A systematic review. *Br J Sports Med* 47: 620-628.
25. Harper MC (1993) An anatomic and radiographic investigation of the tibiofibular clear space. *Foot Ankle* 14: 455-458.
26. Beumer A, Valstar ER, Garling EH, van Leeuwen WJ, Sikma W, et al. (2003) External rotation stress imaging in syndesmotic injuries of the ankle: Comparison of lateral radiography and radiostereometry in a cadaveric model. *Acta Orthop Scand* 74: 201-205.
27. Ebraheim NA, Lu J, Yang H, Mekhail AO, Yeasting RA (1997) Radiographic and CT evaluation of tibiofibular syndesmotic diastasis: A cadaver study. *Foot Ankle Int* 18: 693-698.
28. Vopat ML, Vopat BG, Lubberts B, DiGiovanni CW (2017) Current trends in the diagnosis and management of syndesmotic injury. *Curr Rev Musculoskelet Med* 10: 94-103.
29. Takao M, Ochi M, Oae K, Naito K, Uchio Y (2003) Diagnosis of a tear of the distal tibiofibular syndesmosis. The role of arthroscopy of the ankle. *J Bone Joint Surg Br* 85: 324-329.
30. Oae K, Takao M, Naito K, Uchio Y, Kono T, et al. (2003) Injury of the tibiofibular syndesmosis: Value of MR imaging for diagnosis. *Radiology* 227: 155-161.

CHAPTER

6

THE MOST COMMON INJURY IN THE WORLD OF SPORTS BUT REMAINING DIAGNOSTIC AND THERAPEUTICAL CHALLENGES...



CHAPTER 6:

The most Common Injury in the World of Sports but remaining Diagnostic and Therapeutical Challenges...

Fixation Techniques in lower extremity Syndesmotic injuries- A Current Concepts Review.

Foot and Ankle International Journal (2017)

D'Hooghe P, York P, Kaux JF, Hunt K

Fixation Techniques in Lower Extremity Syndesmotic Injuries.
Pieter D'Hooghe, MD, Philip J. York, MD, Jean Francois Kaux, MD,
and Kenneth J. Hunt, MD
Foot & Ankle International® 2017, Vol. 38(11) 1278– 128

ABSTRACT

Introduction

In recent years, there has been increasing emphasis on the diagnosis and treatment of syndesmotic injuries. Injury recognition is crucial, especially in athletes where it has been shown to be associated with long-term ankle dysfunction, missed time from sports, and the need for operative stabilization.^{26,68} However, the physical and radiographic examinations can be deceiving, and accurate diagnosis can be difficult despite improved diagnostic modalities.

Additionally, there is controversy regarding criteria for operative intervention and, when indicated, which implants are optimal.

Purpose

Our objective is to present an evidence-based review of current techniques and implants for syndesmotic fixation.

ANATOMY & BIOMECHANICS

Stability of the ankle joint is largely due to bony articulations between the tibia, talus, and fibula. The distal tibiofibular joint is referred to as the tibiofibular syndesmosis.

The lateral surface of the distal tibia forms a triangular notch into which the convex medial distal fibula articulates. Strong ligaments form a fibrous joint between these bony surfaces. Holding these articulations in a relatively constant volumetric and spatial relationship are the anterior inferior tibiofibular ligament (AITFL), the interosseous tibiofibular ligament (IOL), and the superficial and deep fibers of the posterior inferior tibiofibular ligaments (PITFL). Distal to the PITFL lies the transverse tibiofibular ligament, or inferior transverse ligament. Together, the bony articulations and the ligaments holding them together resist constant axial, rotational, and translational forces.¹⁸

Additionally, the deltoid ligament confers secondary stability by resisting lateral shift of the talus.⁷²

The AITFL consists of 3 to 5 bands that are collectively trapezoidal in shape. It traverses from the anterior tubercle of the distal tibia (Tillaux-Chaput) approximately 5 mm superior to the articular surface and narrows as it attaches to the anterior surface of the distal fibula at the lateral malleolus.³³ It runs in an oblique direction from proximal anteromedial on the tibia to distal posterolateral on the anterior fibula. In certain positions, the lower margin of

the ligament comes in contact with the lateral ridge of the trochlea of the talus.^{18,69} The PITFL has interconnections with the inferior transverse ligament. It too is trapezoidal in shape and runs from the posterior malleolus of the distal tibia (Volkman tubercle) to the posterior aspect of the lateral malleolus. At its superior edge, it is almost continuous with the IOL, making it difficult to distinguish on cadaveric specimens.¹⁸

The inferior transverse ligament is denser than the PITFL but has a smaller, oval insertion just distal to the PITFL on the fibula and has variable insertions on the distal tibia. This ligament is fibrocartilaginous and acts to deepen the postero-inferior articulation similar to a labrum. The majority of the IOL runs laterodistal and anterior from the tibia to the fibula, resembling the orientation of the PITFL; however, anteriorly there are fibers that run in the opposite direction. The distal fibers on the tibia are at the level of the anterior tubercle (approximately 8 mm above the mortise) and attach at the fibula above the level of the talocrural joint. The fibular attachment is generally wider than the tibial attachment. The upper portion spanning from the tip of the incisura tibialis to the level of the talocrural joint is referred to as the interosseous membrane with the fibers distal to this referred to as the IOL.³³ Distally the ligament terminates at the level of the synovial recess approximately 9.3 mm above the tip of the lateral malleolus.⁶⁹

The distal aspect of the tibiofibular contact area contains a variable amount of very thin (0.5 mm) cartilaginous surface in which there is direct contact between the 2 bones. At this level, there are variable synovial plicae and synovial membrane.¹⁸

The bony and ligamentous relationships allow for controlled motion in the coronal, sagittal, and transverse planes. With ankle external rotation, the fibula externally rotates and translates posteriorly, although this displacement cannot be appreciated on radiographs.⁷ Clanton et al recently performed a biomechanical, cadaveric analysis of individual ligament contributions to ankle stability. They reported that in intact ankle specimens there was an average of 4.3 degrees of fibular rotation in the axial plane and 3.3 mm of fibular translation in the sagittal plane. Sectioning of the AITFL resulted in the greatest reduction in resistance to external rotation although there was a significant decrease in resistance with each sequential ligament sectioned. Sectioning of the superficial PITFL resulted in the greatest decrease in resistance to internal rotation.¹² Another study by Xenos et al⁷² revealed that with an external rotation force, the tibiofibular diastasis was 2.3 mm after sectioning of

the AITFL, which increased to 5.5 and 7.3 mm with subsequent sectioning of the IOL and PITFL, respectively.

The peroneal artery provides a perforating branch through the interosseous membrane an average of 3 cm above the joint line that is at risk for injury with significant syndesmotic disruption. This provides the majority of the anterior ligamentous vascular supply. Anterior tibial artery contribution is less common.⁴²

INCIDENCE & EPIDEMIOLOGY

Ankle sprains are the most common injury in athletes, comprising 10% to 30% of all sport-related injuries^{18,67} and up to 45% in sports such as basketball, volleyball, soccer and football.¹⁸ The incidence of injuries to the ankle syndesmosis is reported to be 7% to 25% of all ankle injuries^{26,32,67}. Although much less common than lateral ankle sprains, and overall less common than medial ankle sprains, syndesmotic sprains require longer time for recovery.²⁰

Male athletes have more than a 3-fold greater rate of syndesmotic injury than women.⁶⁷ Syndesmotic injuries have been found to be associated with certain positions in sports as well, with offensive lineman being statistically more likely to be affected compared to other positions in college football.³⁴ This may be related to the fact that increased body mass index has been shown to increase the risk of syndesmotic injury.⁶⁷

Purely ligamentous injuries are typically referred to as high ankle sprains. While complete ligamentous disruption can occur, these more commonly occur in association with an ankle fracture,³² specifically a distal fibular Weber B or C or a proximal fibular fracture (Maisonneuve injury).⁷¹

Conversely, syndesmotic injuries that require stabilization have been shown to accompany ankle fractures 10% to 20% of the time.^{16,52} Concomitant syndesmotic injuries have also been shown to occur in 17.8% of lateral ankle sprains.⁹

However, the injury mechanism will typically favor one injury over the other as high-grade syndesmotic injuries typically have lower grade lateral ankle sprains, while the converse has also been shown to be true.⁶⁵

MECHANISM OF INJURY

The most commonly reported mechanism of syndesmotic injury is when the foot is externally rotated while the ankle is dorsiflexed and the hindfoot everted.⁵² This puts the maximum diastasis stress on the syndesmosis with the wider portion of the talus engaged in the mortise and the rotation acting like a fulcrum on the fibula resulting in external rotation and posterior displacement.

This mechanism is supported by studies that have shown that up to 55% of syndesmotic sprains in a group of athletes occurred during a collision with the foot planted and externally rotated while the ankle dorsiflexes as the player subsequently falls forward.⁴⁸

The foot position at the time of external rotation plays a key role in the nature of the injury, with studies suggesting that if the foot is in neutral position a medial injury is more likely, whereas if the foot is in an everted position the AITFL is more likely to be the first ligament injured.²⁸

DIAGNOSIS

Diagnosing an athlete with a syndesmotic injury can be difficult. The pain is often diffuse and difficult to differentiate from a lateral ankle sprain. Additionally, as previously noted, there can be overlap in injury patterns. This can further cloud the diagnosis and potentially lead to missed syndesmotic injuries (Figure 1). However, a thorough history might uncover a mechanism that would increase the treating physician's suspicion. A thorough physical examination includes visual inspection for swelling, palpation for tenderness, and evaluation of the proximal extent of the tenderness.

The latter physical examination finding, known as "syndesmosis tenderness length" (the most proximal site of tenderness measured from the distal tip of the fibula), has been shown to correlate with the time to return to sports.⁵⁷

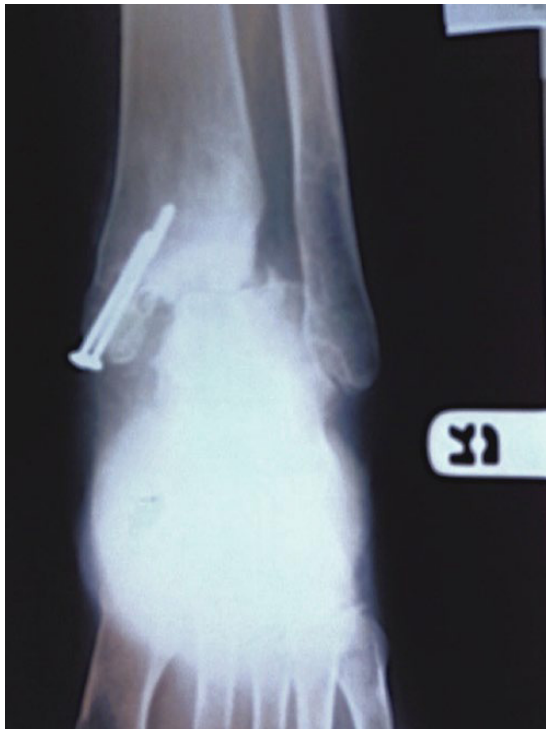

Figure 1. Anteroposterior radiograph of a patient who presented with persistent pain following fixation of a medial malleolar fracture revealing a missed syndesmotom injury.

The typical location of tenderness in a syndesmotom injury is at the anterolateral and/or posteromedial joint line. There are a number of special physical examination tests for syndesmotom injuries that have been described. These include the external rotation test, heel thump test, dorsiflexion compression test, fibular translation test, crossed-leg test, and squeeze test.

However, these tests have been shown to be difficult to interpret with a low predictive value in the presence of a painful or swollen ankle.³ The external rotation test has been shown to be most sensitive with the lowest false positive rate.⁵² This is performed with the ankle in neutral or slight dorsiflexion, the heel in neutral or varus position, with subsequent external rotation of the foot relative to the tibia to the point of resistance and pain.

Additionally, a stress radiograph can be obtained to evaluate for medial clear space (MCS) or tibiotalar widening.²¹

In the case of a suspected syndesmotom injury, radiographs must be carefully scrutinized. Signs of syndesmotom injury include avulsion fractures of the anterior tubercle of the tibia (Tillaux-Chaput fragment), anterior fibula (Wagstaffe le Fort fragment), and posterior malleolus (Volkman fragment).

Radiographs should be evaluated for the tibiofibular clear space (TFCS) (normal = mean 4.4 ± 0.8 mm on anteroposterior view and 3.9 ± 0.9 mm on mortise view, respectively), the tibiofibular overlap (normal = mean 8.8 ± 2.4 mm on anteroposterior view and 4.6 ± 2.1 mm on mortise view, respectively), and for any increased MCS (normal < 5 mm).¹⁵ However, it has been shown that tibiofibular overlap and TFCS do not correlate with syndesmotic injury seen on magnetic resonance imaging (MRI).³⁰ Additionally, MCS measurements have been shown to have poor accuracy and precision even among experienced providers.

In a recent cadaver study, 3 specimens were evaluated with a known amount of displacement (6, 4, and 1.7 mm). Measurement errors ranged from 16% at 5 degrees of internal rotation to 36% at 15 degrees of external rotation for the specimen with 6 mm of known MCS widening but was even greater ranging from -3% at neutral to 100% at 5 degrees external rotation for the intact specimen with 1.7 mm of MCS.⁴³

Although the sensitivity and specificity of detecting a syndesmotic injury on MRI has been shown to be up to 100%, determining the severity of that injury and the need for surgery is not straightforward and often only when frank diastasis is seen on radiography is the final determination for operative intervention made (Figure 2).⁶⁹

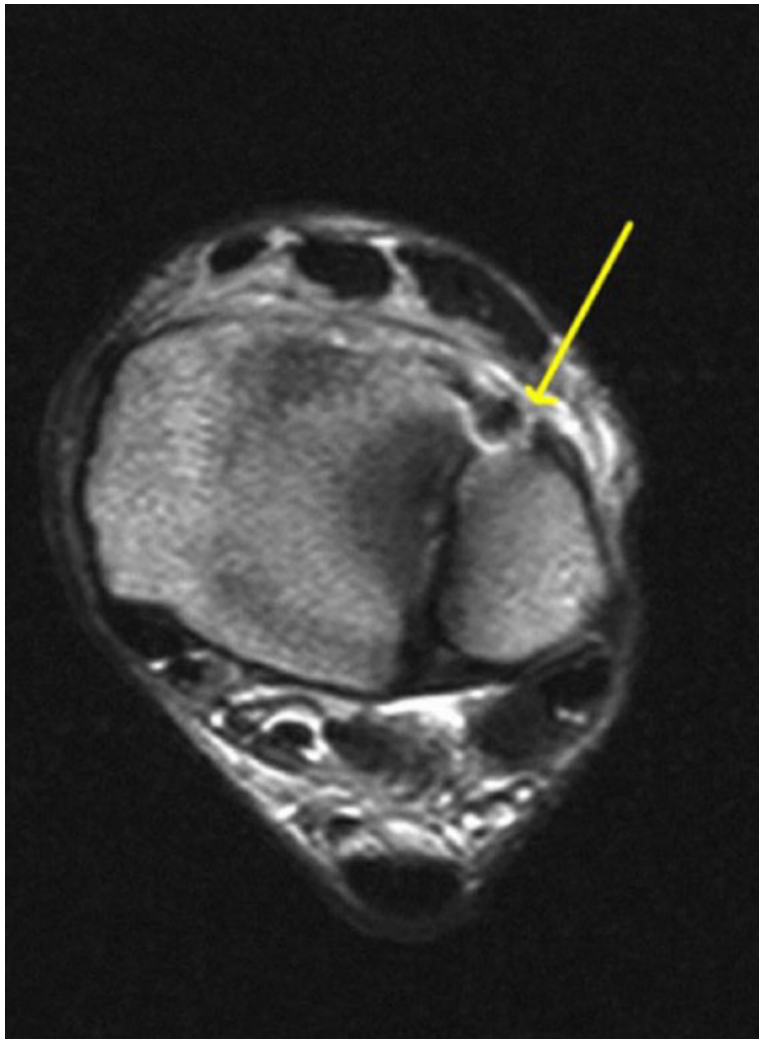


Figure 2. Magnetic resonance image of an elite-level athlete revealing anterior syndesmotomous disruption.

If an injury could potentially be managed nonoperatively, then stress radiographs can be helpful in assessing the integrity of the syndesmosis and of the deltoid ligament. However, there is no standardized technique or amount of force applied and the quality of the test can be significantly limited by the patient's pain.⁴

One recent study found that gravity stress radiographs (with the foot suspended via a bump under the calf allowing gravity to pull the foot in external rotation) resulted in equivalent MCS widening to manual stress radiographs.³⁷ Conversely, if there is an operative fracture, then stress radiographs can be postponed until surgery (Figure 3).

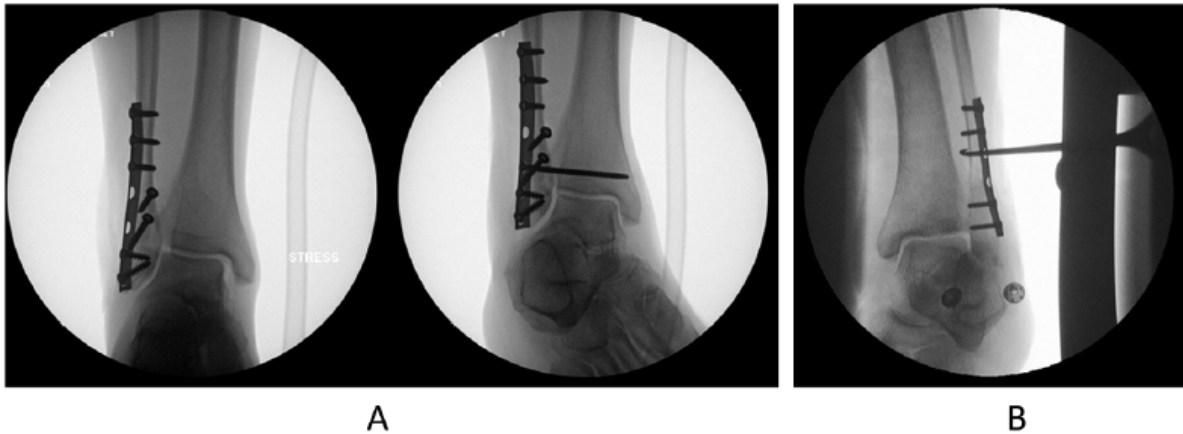

Figure 3. (A) Intraoperative fluoroscopy of ankle fixation. Left: Stress radiograph following fixation of a Weber B fibula fracture with medial clear space widening. Right: Radiograph following syndesmotic screw fixation. (B) Hook test performed in which the fibula is pulled lateral to assess for medial clear space widening.

CLASSIFICATION

Isolated syndesmotic injuries can be generally classified as stable or unstable. The stable variant is characterized by an intact deltoid ligament in the presence of an AITFL rupture with or without IOL rupture. Unstable injuries are syndesmotic disruption with latent or frank radiographic diastasis.

Latent diastasis consists of AITFL rupture with or without IOL and deltoid ligament rupture noted on stress radiographs, MRI, or on arthroscopic evaluation (Figure 4).

Frank diastasis can be seen on regular radiographs due to complete disruption of all syndesmotic ligaments.¹⁴ Unstable injuries require operative intervention, whereas there is controversy regarding the management of various Grades of stable injuries.

Another classification system attempts to grade the severity of the injury.⁷⁰ Grade I injuries are considered mild with normal radiographs and a clinically stable syndesmosis with mild lateral ankle injury. Grade II injuries are moderate in severity. These typically also have normal radiographs but with either a clinically diagnosed injury to the syndesmosis (positive external rotation and squeeze test) or MRI findings of a syndesmotic injury. However, in Grade II injuries there is no consensus on joint stability, with some authors suggesting Grade II injuries are, by definition stable,⁵⁶ whereas others suggest such injuries can potentially be unstable.⁷⁰ Grade III injuries are characterized as complete syndesmotic disruption with diastasis or medial widening.³³

In the case of a Grade II injury, MRI,³⁰ stress radiographs or arthroscopy^{10,38} have all been advocated as diagnostic modalities to assist in determining severity of syndesmotic injury and appropriate treatment.

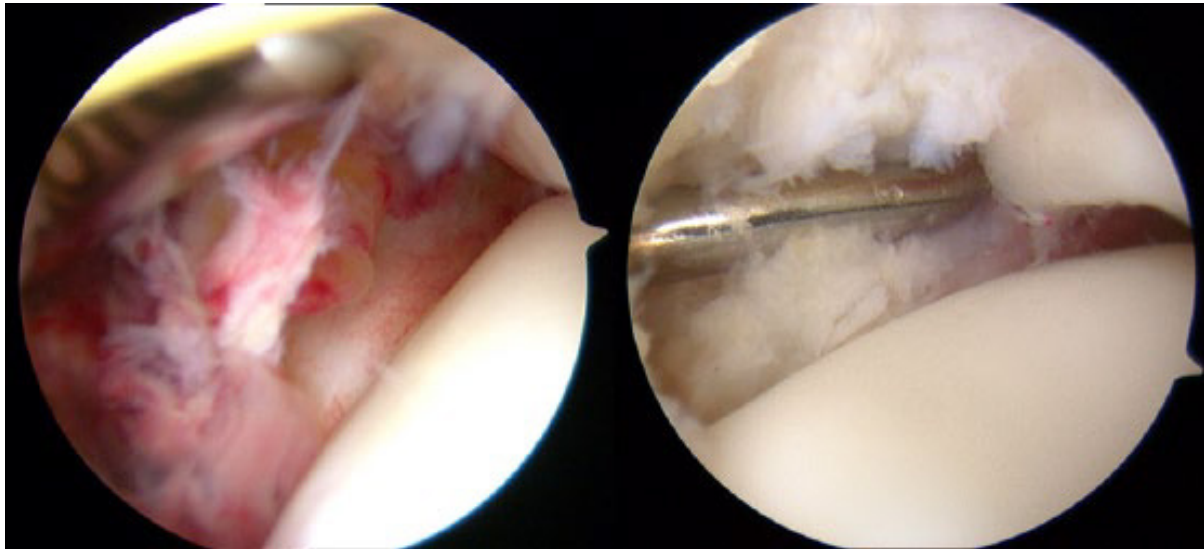


Figure 4. Arthroscopic images of 2 different patients with evidence of syndesmotic disruption.

MANAGEMENT OF SYNDESMOTIC INJURIES

Purely Ligamentous Injuries

In the case of sprains without diastasis, nonoperative management has been shown to result in good functional outcomes.⁴⁵ However, there is currently no consensus on the nonoperative regimen, with treatments ranging from taping to fracture boots to non-weight bearing cast immobilization. Other interventions such as injections, physical therapy, ultrasonography, nonsteroidal anti-inflammatory drugs, etc. are discussed throughout the literature without consensus. Reported lengths of immobilization vary from 1 to 6 weeks.^{14,52} Athletes should be informed that return to full sport takes longer compared to lateral ankle sprains. The syndesmosis tenderness length can be used to estimate the time loss from sports using the equation⁴⁸:

Days lost from competition = $5 \pm (0.93 \times [\text{tenderness length in centimeters}]) \pm 3.72$ days.

Rehabilitation is implemented in 3 phases:

Phase I is the acute phase. Goals include joint protection, minimization of inflammation and pain control.

Phase II is the subacute phase in which restoration of mobility, strength, and gait are emphasized. Finally, in *Phase III*, emphasis is placed on strengthening, neuromuscular control and sports-specific tasks.³³

A recent cohort-controlled study by Samra et al suggested that 10 rugby players with MRI-confirmed syndesmosis injury (involvement of the AITFL, IOL, and PITFL) treated without surgery who received a single autologous PRP injection into the AITFL had significantly shorter time to return to play than a historical cohort (20.7 days less for the intervention group vs historical control).

Following return, these patients had higher agility, increased vertical jump, and lower level of fear avoidance.⁵⁰ However, although they reported similar baseline characteristics between groups, the intervention was not blinded and there was no placebo control, both of which could have resulted in bias.

In contrast, all injuries with frank diastasis require syndesmotic fixation.¹ Taylor et al reported on 6 intercollegiate athlete patients with Grade III syndesmosis injuries treated with a 4.5-mm stainless steel cortical screw and reported good to excellent clinical outcomes in all patients with a mean return to sports at 40.7 days.⁶⁰ In their series, all hardware was removed at an average of 74 days (range 52-97).

Fractures With Syndesmotic Instability

Carr et al recently performed a large database analysis of ankle fracture and syndesmotic fixation between 2007 and 2011 and found no significant increase in procedures for all ankle fracture types (lateral malleolus, bimalleolar, and trimalleolar) during that time.⁸ However, the number of procedures to treat isolated syndesmotic injuries increased by 18% during that time period. In addition, the rate of syndesmotic fixation that accompanied fixation of ankle fractures significantly increased with a nearly 2-fold increase among bimalleolar fractures. The authors also reported that the rate of implant removal after

syndesmotic fixation significantly decreased. This suggests an overall increase in recognition and operative treatment of isolated syndesmotic injuries and those associated with ankle fractures. Although factors associated with higher energy ankle fractures (bimalleolar involvement or the need for initial external fixation) are associated with delayed union, the need for syndesmotic screw fixation has not been shown to be associated with delayed union of ankle fractures that undergo fixation.

Nevertheless, although bony union can be followed via routine radiographs, the healing of the syndesmosis is significantly slower, requiring prolonged periods of non-weight bearing up to 12 weeks.⁴⁰ Following fixation of medial and/or lateral malleolus fractures, an intraoperative stress radiograph can assess the integrity of the syndesmosis and guide the decision of whether or not syndesmotic fixation is of benefit.

Special consideration should be given to cases of bimalleolar ankle fractures in which there is an anterior colliculus avulsion of the medial malleolus. Tornetta reported on 27 patients with bimalleolar fractures who underwent external rotation stress radiographs intraoperatively after medial malleolar fixation and found that 7 (26%) had MCS widening even after medial fixation. He explained that this represents an injury to the deltoid ligament in which the stronger deep component has been ruptured and the weaker superficial component, which attaches to the anterior colliculus remains intact. If this occurs in conjunction with a syndesmotic injury it has the potential to present as late syndesmotic widening and significant instability.⁶³

SYNDESMOTIC FIXATION

Syndesmotic screws.

Syndesmotic screws have long been considered the gold standard for fixation of syndesmotic injuries. Most authors prefer 3.5 or 4.5 cortical screws which have equivalent biomechanical characteristics.⁶²

While some cadaveric studies have shown increased resistance to an applied load, specifically in shear stress, with a larger diameter screw,²⁷ this has not been reproduced in clinical studies.^{14,62} In Europe, most surgeons utilize a single

3.5 mm tricortical screw, 2.1 to 4 cm above the joint line for stabilization of Weber B or C fractures.⁵² However, a cadaveric study suggested that 2 screws provides a superior biomechanical construct compared to 1.⁶

Location of screw placement is often debated. McBryde et al reported less syndesmotic widening when the screw was placed at 2 cm above the joint compared to 3 cm.⁴¹ However, other studies have reported that screw placement at 2, 3, or 5 cm above the joint line show no difference in functional outcome.⁴¹

Tricortical screws (3.5 mm) were compared to quadricortical lag screws (both 3.5 and 4.5 mm) in terms of compression force in a 2012 cadaveric study. The lag screws maintained a significantly greater compression force after forceps removal compared to the tricortical screw. Additionally, after each 100-cycles of loading, the lag screws significantly exceeded the amount of compression force maintained by the tricortical screw. No differences were seen between the 3.5- and 4.5-mm lag screws.¹³

Ultimately, although cadaveric studies have suggested that 4 cortices provide more rigid fixation; screws with purchase in 3 cortices have been shown to more closely replicate tibiotalar biomechanics.¹⁴ Additionally, tricortical screws have decreased risk of screw breakage albeit at the cost of an increased rate of screw loosening.^{2,29,62} There is no current evidence to suggest a clinically appreciable difference between these 2 methods of screw fixation⁶ (Figure 5).

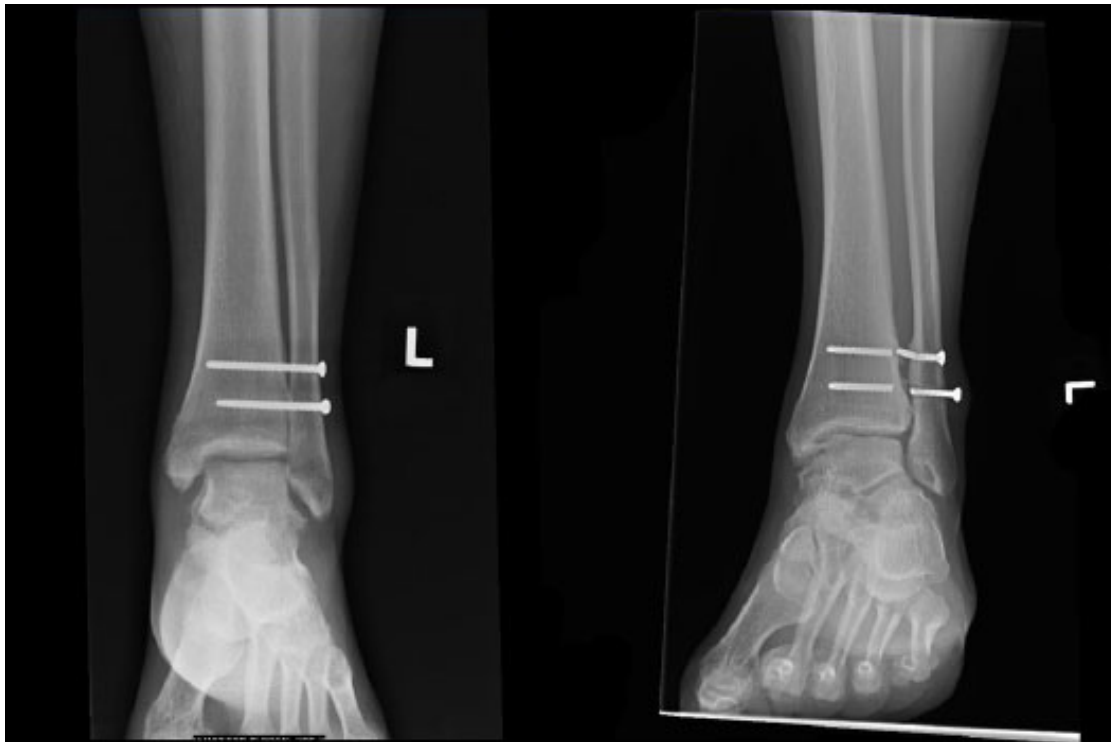


Figure 5. Left: Postoperative follow-up of a patient with a Maisonneuve injury treated with 2 tricortical syndesmotic screws. Right: Radiograph at 2 years postoperation with broken screws. The patient ultimately required screw removal of the lateral screw fragments because of prominence of the distal screw.

In terms of screw removal, there has been a longstanding debate in the literature. Although some recommend removal of quadricortical screws to prevent screw breakage,^{2,31} there is no consensus on when this should be performed, and there have been reports of diastasis at screw removal.⁵² Additionally, studies have suggested similar or better outcomes when the screw is retained,⁵¹ and, therefore, there is growing consensus that screw removal should be reserved for screws that are symptomatic (painful prominence).^{5,14,46,68} A recent systematic review by Dingemans et al concluded that although there is insufficient evidence overall to draw definitive conclusions regarding routine removal, the lack of evidence to justify removal along with the additional cost and increased risk to the patient would suggest that routine removal should be avoided.¹⁶

Suture button constructs

While screw fixation is still considered the gold standard, there are a number of theoretical advantages of suture button fixation (Figure 6). These have been

theorized to allow physiologic motion at the syndesmosis while maintaining reduction. Further, there is less risk of symptomatic hardware and need for implant removal. Finally, these constructs have been suggested to safely allow earlier ankle range of motion as the reduction can be held with progression of motion without the concern for implant failure (screw breakage) and recurrent diastasis.⁵² The argument that these constructs might be superior because they do not require routine removal is weakened by the growing evidence against routine screw removal. However, it has been suggested that these constructs might allow earlier weight bearing.

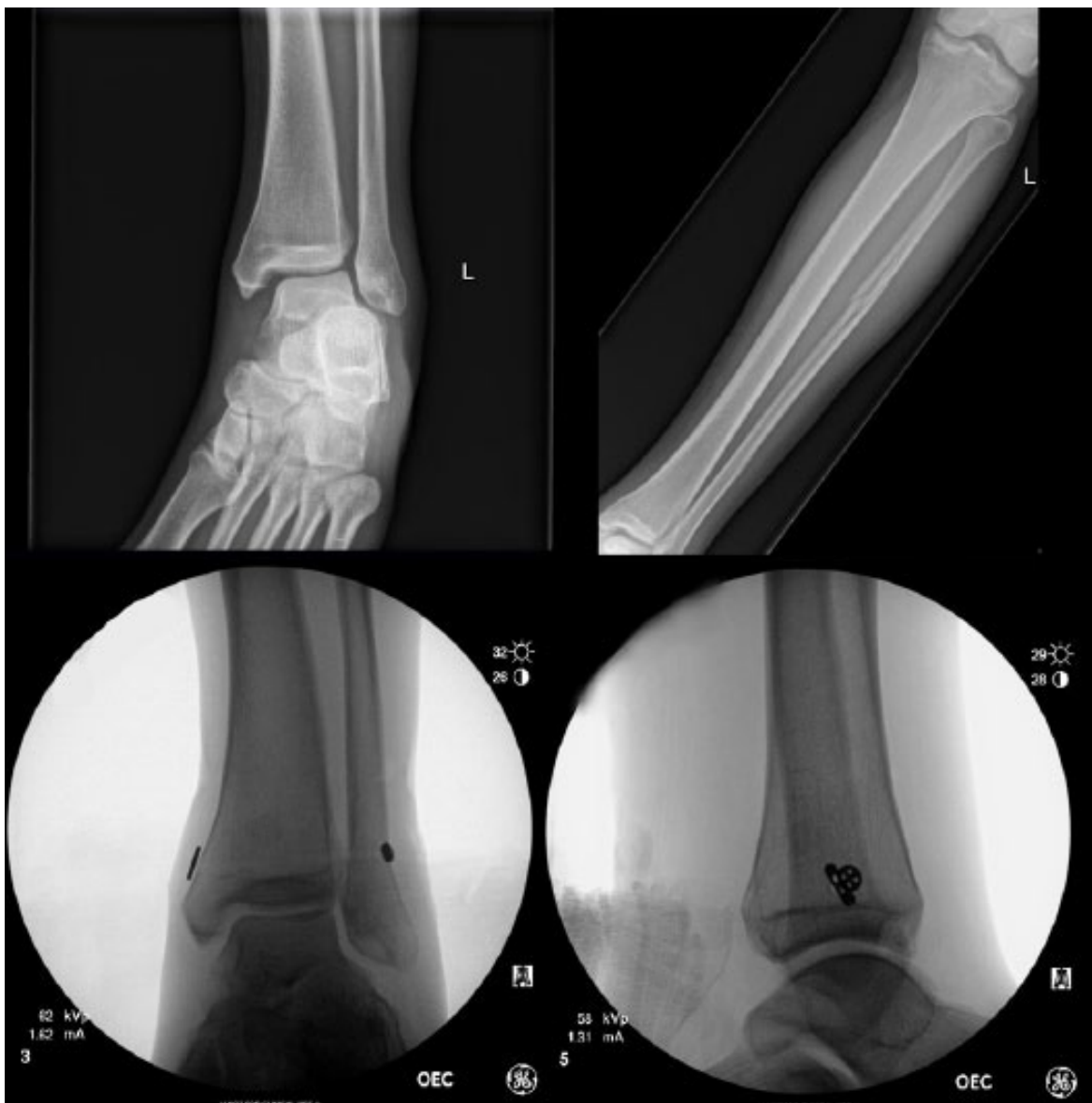

Figure 6. Top: Injury radiographs of a patient with a Maisonneuve injury. Bottom: Intraoperative fluoroscopic images of suture-button fixation of the syndesmosis.

This is due to concern that early stress on a syndesmotic screw might lead to breakage prior to ligamentous healing. Conversely, less rigid constructs such as the TightRope (Arthrex, Naples, FL) are purported to be sturdy enough to withstand physiologic loading that occurs with weight bearing and normal ankle motion.⁴⁷

Teramoto et al performed a cadaveric study on 6 ankles comparing single-suture button fixation, double-suture button fixation, anatomic suture button (from posterior fibula to anterolateral distal tibia), and screw fixation. The authors evaluated the amount of diastasis with various stresses on the ankle, including anterior traction, medial traction, and external rotation. With single-suture button fixation the diastasis increased significantly with all forces, whereas with double fixation the diastasis increased significantly with medially directed force and with external rotation but not with anterior traction. They found that with anatomic suture button placement, there were no significant differences compared to ankles tested prior to syndesmotic disruption. The screw fixation proved to be the most rigid fixation, with significantly decreased diastasis compared to suture button results.⁶¹

However, the clinical implications of that amount of motion are not currently known. Naqvi et al reported retrospectively on 49 patients with suture-button syndesmotic fixation. Patients with syndesmotic injuries associated with ankle fractures underwent single suture-button fixation and those with Maisonneuve injury underwent double suture-button fixation. The authors reported a mean time to weight bearing of 7.7 ± 1.1 weeks (range 5-10) and a mean return to normal activities at 11.2 ± 1.8 weeks. They reported that the original technique of tying the knot over the lateral aspect of the fibular button resulted in a significantly higher rate of wound complications compared to their reported modified technique of creating a subperiosteal recess in the posterior fibula in which they buried the knot. They reported satisfactory results at 2 years postoperatively.⁴⁷

A recent prospective randomized trial comparing screw fixation with a single 3.5-mm screw ($n = 22$) vs suture-button fixation ($n = 22$) of the syndesmosis revealed no difference in quality or maintenance of reduction between the two as seen on postoperative imaging. Additionally, there was no difference at 2-year follow-up in the incidence of ankle joint osteoarthritis.³⁶

In 2013, Ebrahimzadeh et al compared 2 suture-button devices (ZipTight [Biomet] and TightRope [Arthrex]) along with a 3.5-mm quadricortical screw fixation in a cadaveric, failure-to-load model. In 12 of 20 specimens, failure occurred via a

fibula fracture. The screw construct was found to provide a significantly higher torsional strength than the ZipTight (30.1 vs 22.2 Nm) but the difference seen between the screw and the TightRope was not significant.

The authors reported that there were no significant differences between the 2 suture button constructs. Ultimately, they suggested that the torsional fixation strengths of all 3 constructs were above the physiologic loads that would “likely” be experienced during the healing process, citing that level ground walking generally creates syndesmotic torsional stresses below 2 Nm and “various other activities” generally create stresses less than 20 Nm.¹⁹

One issue that arises with regard to the use of a suture button is how to determine the amount of force to put on the construct while securing the syndesmosis. Additionally, there has been debate regarding which position the foot should be in at the time of final tightening. A recent cadaveric study revealed that with the use of suture button syndesmotic fixation, there was consistent overcompression compared to the intact state, with significant volume reduction and medial displacement of the fibula.⁵³

Overcompression, however, is not unique to suture button constructs as it has been reported to occur with forceps reduction and screw fixation as well.⁴⁹

However, the clinical impact of overcompression of the syndesmosis is not known and it has been shown that this compression does not appear to affect ankle dorsiflexion/ plantarflexion. Further, it has been shown that the position of the foot (ie, plantarflexion, neutral, or dorsiflexion) during the time of compression and fixation has no significant effect on postoperative ankle motion.^{49,53,64}

Another recent cadaveric study compared a single screw to either a single suture-button construct or a divergent double– suture button construct.⁹ The authors found that while all fixation techniques provided significant torsional stability, no technique provided the rotational stability and native anatomic relationships provided by the intact ligaments.

Further, the screw provided the most rigid restraint to anterior- posterior translation of the fibula with the highest amount of translation seen in the single–suture button group.¹¹ Although multiple studies have addressed biomechanical stability, Laflamme et al reported on functional scores in addition to radiographic outcomes of patients randomized to either static fixation with a single 3.5-mm quadricortical screw (n = 36) or dynamic fixation with a single

TightRope (n = 34). Dynamic fixation resulted in improved Olerud- Molander functional scores at 3, 6, and 12 months (significant at 12 months). AOFAS scores were significantly better in the TightRope group at 3 months only. There were 4 cases of lost reduction in the screw group compared to zero in the TightRope group.

Anatomic repair of syndesmotic ligaments. There has been recent support for anatomic repair of the syndesmosis. Schottel et al in 2016 reported from a cadaveric model that anatomic repair using suture anchors for the deltoid ligament and PITFL was not significantly inferior to screw fixation in terms of external rotational stability.⁵⁴ Zhan et al reported that patients who had augmented anatomic repair of the AITFL with a 5.0-mm anchor placed into tibia and tied to the fibular plate had better functional outcomes and earlier return to work than patients with screw fixation.

Additionally, there were significantly fewer cases of malreduction in the repair group (19.2% vs 7.4%). The repair group had significantly higher overall range of motion, although they had significantly decreased plantarflexion compared to the screw group.⁷³

A recent topic of debate is in relation to fixation of the posterior malleolus and the role that it plays in syndesmotic reconstruction and stabilization. Even small posterior fragments in trimalleolar fractures can represent complete avulsion of the PITFL. Therefore, the previous teaching that posterior malleolar fractures that constitute less than 20% of the joint surface do not require fixation has been called into question. Posterior malleolar fixation has been found to further stabilize the syndesmosis and decrease the risk of post-traumatic arthritis.¹⁷ A cadaveric study by Gardner et al found that in specimens with unstable syndesmoses, fixation of a posterior malleolus fracture restored 70% of preinjury stiffness compared to only 40% with screw fixation.²³

A prospective clinical study of 31 patients (9 who underwent posterior malleolus fixation and 14 who underwent screw fixation of their syndesmotic injury) revealed that fixation of a posterior malleolus fracture with the PITFL attached resulted in at least equivalent stability and clinical outcomes as trans-syndesmotic screw fixation.⁴⁴ This is typically performed through a posterolateral approach with the patient in a prone position.⁶⁶

COMPLICATIONS & TECHNICAL CONSIDERATIONS

The overall rate of complications for nonoperative management of purely ligamentous injuries has been reported to be 68%.¹⁴ These complications include stiffness, pain and/or limp with activity, mild swelling, reinjury, heterotopic ossification (HO), and residual painful instability (Figure 7).

HO is a late marker of a more severe injury and has been reported in up to 50% of cases of isolated ligamentous injuries and is associated with a higher rate of reinjury and recurrent ankle sprains. However, Taylor et al suggested that early functional and proprioceptive exercises after a 4-day period of immobilization decreased the zone of secondary injury due to inflammation with a decreased rate of HO formation.⁵⁹

In terms of operative complications, syndesmotic malreduction has been shown to occur in up to 50% of cases.^{24,39} Intra-operative measurements such as MCS, tibiofibular overlap, and TFCS can be challenging. An intra-operative lateral radiograph of the contralateral ankle with the medial and lateral talar domes overlapping can assess the distance between the posterior tibial and fibular cortices. This can be compared to the injured ankle after reduction prior to placing the final fixation.⁵⁵ This technique has been suggested to result in better assessment of reduction compared to anteroposterior or mortise radiographs and can help guide reduction to within 2.5 mm. Without the direct comparison, it has been shown that experienced surgeons have difficulty identifying posteriorly displaced malreduction compared to an anteriorly malreduced fibula.³⁵

A 2012 study found that forceps can aid in maintaining reduction during screw placement but that the best position for clamp placement was on the lateral malleolar ridge of the fibula and at the midpoint of the anterior-posterior width of the tibia. However, they found that forceps reduction in their cadaveric study resulted in overcompression of the syndesmosis in all tong positions.⁴⁹

Some authors suggest the use of postoperative CT scan to evaluate the quality of the reduction as this has been shown to correlate with the development of posttraumatic arthritis and overall clinical outcome.⁶⁸

Franke et al reported that in 251 patients, intra-operative CT scans were obtained after the surgeon felt that the joint was anatomically reduced based on 3-view fluoroscopy. They found that even with fluoroscopic imaging, 32.7% of patients had malreduced syndesmoses that required correction.²²

A 2014 study including 25 patients requiring syndesmotic fixation using postoperative CT scans reported 36% (9 patients) were malreduced.

Interestingly, however, with syndesmotic screws removed at an average of 107 days, 8/9 malreduced syndesmoses spontaneously reduced after screw removal as seen on repeat CT scan.⁵⁸ Another study by Gennis et al reported that even with slight change in MCS, TFCS, and overlap after weight bearing, there was no significant difference seen between patients who underwent elective screw removal at 3 months, versus patients who had broken or intact screws at final follow-up.²⁵

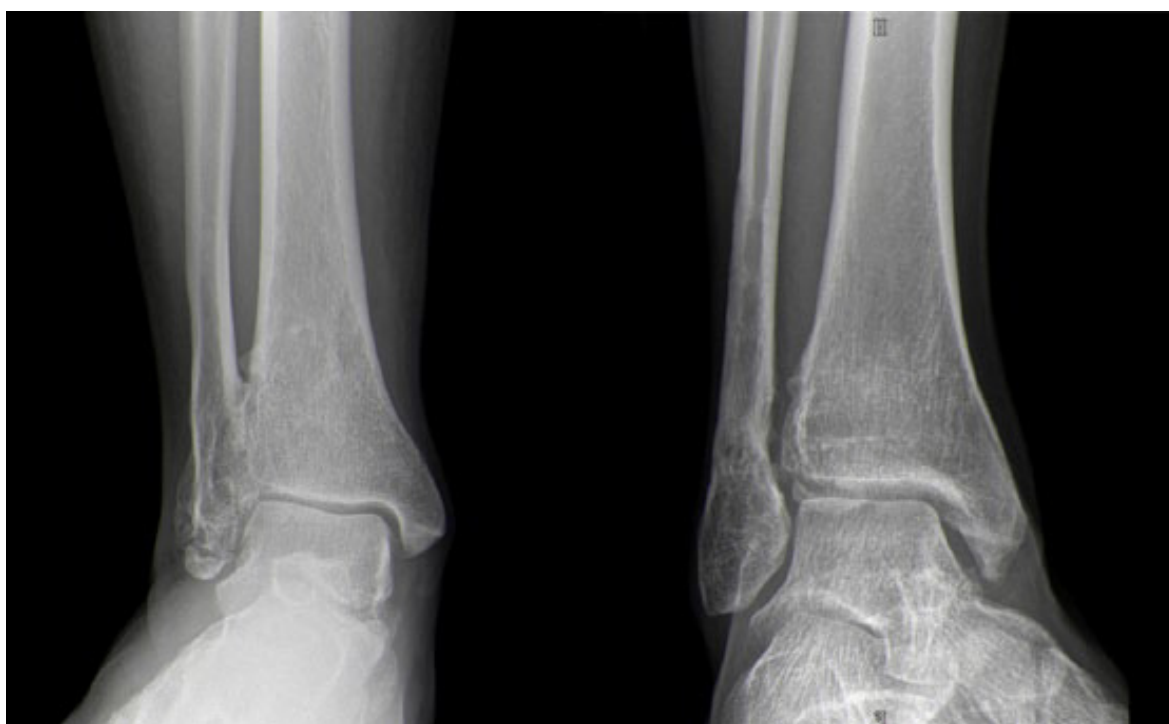


Figure 7. Anteroposterior radiographs of 2 patients with chronic ligamentous syndesmotic injuries. Left: Autofusion of the syndesmosis is seen. Right: Mild heterotopic ossification and early degenerative changes are seen.

SUMMARY

Syndesmotic injuries are increasingly common in both competitive and recreational athletes. Although screw fixation has been shown to provide greater stability than newer suture-button constructs, the benefit of the earlier motion allowed by these constructs is not completely understood. Although both of these techniques have the ability to overcompress the syndesmosis, it is unclear what effect this has on healing and ankle motion. Additionally, direct anatomic repair of syndesmotic ligaments with or without augmentation

has shown promising results in terms of anatomic restoration of the joint with acceptable strength. At present, more work is needed to understand the long-term impact of newer treatments and the utility of more aggressive rehabilitation techniques.

REFERENCES

1. Amendola A, Williams G, Foster D. Evidence-based approach to treatment of acute traumatic syndesmosis (high ankle) sprains. *Sports Med Arthrosc.* 2006;14(4):232-236.
2. van den Bekerom MPJ, Hogervorst M, Bolhuis HW, van Dijk CN. Operative aspects of the syndesmotom screw: review of current concepts. *Injury.* 2008;39(4):491-498.
3. van den Bekerom MPJ, Lamme B, Hogervorst M, Bolhuis HW. Which ankle fractures require syndesmotom stabilization? *J Foot Ankle Surg.* 2007;46(6):456-463.
4. van den Bekerom MPJ, Mutsaerts ELAR, Dijk CN. Evaluation of the integrity of the deltoid ligament in supination external rotation ankle fractures: a systematic review of the literature. *Arch Orthop Trauma Surg.* 2009;129(2):227-235.
5. Bell DP, Wong MK. Syndesmotom screw fixation in Weber C ankle injuries—should the screw be removed before weight bearing? *Injury.* 2006;37(9):891-898.
6. Beumer A, Campo MM, Niesing R, Day J, Kleinrensink GJ, Swierstra BA. Screw fixation of the syndesmosis: a cadaver model comparing stainless steel and titanium screws and three and four cortical fixation. *Injury.* 2005;36(1):60-64.
7. Beumer A, Valstar E, Garling E, et al. Effects of ligament sectioning on the kinematics of the distal tibiofibular syndesmosis: a radiostereometric study of 10 cadaveric specimens based on presumed trauma mechanisms with suggestions for treatment. *Acta Orthop.* 2006;77(3):531-540.
8. Carr JBI, Werner BC, Yarboro SR. An update on management of syndesmosis injury: a National US Database Study. 2016, December.
9. de César PC, Avila EM, de Abreu MR. Comparison of magnetic resonance imaging to physical examination for syndesmotom injury after lateral ankle sprain. *Foot Ankle Int.* 2011;32(12):1110-1114.
10. Chan K, Lui T. Role of ankle arthroscopy in management of acute ankle fracture. *Arthroscopy.* 2016;32(11):2373-2380.
11. Clanton TO, Whitlow SR, Williams BT, et al. Biomechanical comparison of 3 current ankle syndesmosis repair techniques. *Foot Ankle Int.* 2017;38(2):200-207.
12. Clanton TO, Williams BT, Backus JD, et al. Biomechanical analysis of the individual ligament contributions to syndesmotom stability. *Foot Ankle Int.* 2017;38(1):66-75.
13. Darwish HH, Glisson RR, DeOrio JK. Compression screw fixation of the syndesmosis. *Foot Ankle Int.* 2012;33(10):893- 899.
14. van Dijk CN, Longo UG, Loppini M, et al. Conservative and surgical management of acute isolated syndesmotom injuries: ESSKA-AFAS consensus and guidelines. *Knee Surg Sport Traumatol Arthrosc.* 2016;24(4):1217-1227.
15. Dikos GD, Heisler J, Choplin RH, Weber TG. Normal tibiofibular relationships at the syndesmosis on axial CT imaging. *J Orthop Trauma.* 2012;26(7):433-438.
16. Dingemans SA, Rammelt S, White TO, Goslings JC, Schepers T. Should syndesmotom screws be removed after surgical fixation of unstable ankle fractures? a systematic review. *Bone Joint J.* 2016;98(11):1497-1504.
17. Drijfhout van Hooff CC, Verhage SM, Hoogendoorn JM. Influence of fragment size and postoperative joint congruency on long-term outcome of posterior malleolar fractures. *Foot Ankle Int.* 2015;36(6):673-678.
18. Ebraheim NA, Taser F, Shafiq Q, Yeasting RA. Anatomical evaluation and clinical importance of the tibiofibular syndesmosis ligaments. *Surg Radiol Anat.* 2006;28(2): 142-149.
19. Ebramzadeh E, Knutsen AR, Sangiorgio SN, Brambila M, Harris TG. Biomechanical comparison of syndesmotom injury fixation methods using a cadaveric model. *Foot Ankle Int.* 2013;34(12):1710-1717.
20. Fallat L, Grimm DJ, Saracco JA. Sprained ankle syndrome: prevalence and analysis of 639 acute injuries. *J Foot Ankle Surg.* 1998;37(4):280-285.

21. Femino JE, Vaseenon T, Phistkul P, et al. Varus external rotation stress test for radiographic detection of deep deltoid ligament disruption with and without syndesmotic disruption. *Foot Ankle Int.* 2013;34(2):251-260.
22. Franke J, Von Recum J, Suda AJ, Grützner PA, Wendl K. Intraoperative three-dimensional imaging in the treatment of acute unstable syndesmotic injuries. *J Bone Joint Surg.* 2012;94(15):1386-1390.
23. Gardner MJ, Brodsky A, Briggs SM, Nielson JH, Lorich DG. Fixation of posterior malleolar fractures provides greater syndesmotic stability. *Clin Orthop Relat Res.* 2006; 447:165-171.
24. Gardner MJ, Demetrakopoulos D, Briggs SM, Helfet DL, Lorich DG. Malreduction of the tibiofibular syndesmosis in ankle fractures. *Foot Ankle Int.* 2006;27(10):788-792.
25. Gennis E, Koenig S, Rodericks D, Otlans P, Tornetta P. The fate of the fixed syndesmosis over time. *Foot Ankle Int.* 2015;36(10):1202-1208.
26. Gerber J, Williams G, Scoville C, Arciero R, Taylor D. Persistent disability associated with ankle sprains: a prospective examination of an athletic population. *Foot Ankle Int.* 1998;19(10):653-660.
27. Hansen M, Le L, Wertheimer S, Meyer E, Haut R. Syndesmosis fixation: analysis of shear stress via axial load on 3.5-mm and 4.5-mm quadricortical syndesmotic screws. *J Foot Ankle Surg.* 2006;45(2):65-69.
28. Haraguchi N, Armiger RS. A new interpretation of the mechanism of ankle fracture. *J Bone Joint Surg Am.* 2009;91(4):821- 829.
29. Heim D, Schmidlin V, Ziviello O. Do type B malleolar fractures need a positioning screw? *Injury.* 2002;33(8): 729-734.
30. Hermans J, Wentink N, Beumer A, et al. Correlation between radiological assessment of acute ankle fractures and syndesmotic injury on MRI. *Skelet Radiol.* 2012;41:787-801.
31. Høiness P, Strømsøe K. Tricortical versus quadricortical syndesmosis fixation in ankle fractures: a prospective, randomized study comparing two methods of syndesmosis fixation. *J Orthop Trauma.* 2004;18(6):331-337.
32. Hunt KJ, George E, Harris AHS, Dragoo JL. Epidemiology of syndesmosis injuries in intercollegiate football: incidence and risk factors from National Collegiate Athletic Association Injury Surveillance System Data from 2004-2005 to 2008-2009. *Clin J Sport Med.* 2013;23(4): 278-282.
33. Hunt KJ, Phisitkul P, Pirollo J, Amendola A. High ankle sprains and syndesmotic injuries in athletes. *J Am Acad Orthop Surg.* 2015;23(11):661-673.
34. Kaplan LD, Jost PW, Honkamp N, Norwig J, West R, Bradley JP. Incidence and variance of foot and ankle injuries in elite college football players. *Am J Orthop (Belle Mead NJ).* 2011;40(1):40-44.
35. Koenig SJ, Tornetta P, Merlin G, et al. Can we tell if the syndesmosis is reduced using fluoroscopy? *J Orthop Trauma.* 2015;29(9):e326-e330.
36. Kortekangas T, Savola O, Flinkkilä T, et al. A prospective randomised study comparing TightRope and syndesmotic screw fixation for accuracy and maintenance of syndesmotic reduction assessed with bilateral computed tomography. *Injury.* 2015;46(6):1119-1126.
37. LeBa T-B, Gugala Z, Morris RP, Panchbhavi VK. Gravity versus manual external rotation stress view in evaluating ankle stability. *Foot Ankle Spec.* 2015;8(3):175-179.
38. Lui T, Ip K, Chow H. Comparison of radiologic and arthroscopic diagnoses of distal tibiofibular syndesmosis disruption in acute ankle fracture. *Arthroscopy.* 2005;21(11):1370.
39. Marmor M, Hansen E, Han H, Buckley J, Matiyahu A. Limitations of standard fluoroscopy in detecting rotational malreduction of the syndesmosis in an ankle fracture model. *Foot Ankle Int.* 2011;32(6):616-622.
40. Matson AP, Hamid KS, Adams SB. Predictors of time to union after operative fixation of closed ankle fractures. *Foot Ankle Spec.* 2017;10(4):308-314.
41. McBryde A, Chiasson B, Wilhelm A, Donovan F, Ray T, Bacilla P. Syndesmotic screw placement: a biomechanical analysis. *Foot Ankle Int.* 1997;18(5):262-266.
42. McKeon KE, Wright RW, Johnson JE, McCormick JJ, Klein SE. Vascular anatomy of the tibiofibular syndesmosis. *J Bone Joint Surg Am.* 2012;94(10):931-938.
43. Metitiri O, Ghorbanhoseini M, Zurakowski D, Hochman M, Nazarian A, Kwon J. Accuracy and measurement error of the medial clear space of the ankle. *Foot Ankle Int.* 2017;38(4):443-451.
44. Miller AN, Carroll EA, Parker RJ, Helfet DL, Lorich DG. Posterior malleolar stabilization of syndesmotic injuries is equivalent to screw fixation. *Clin Orthop Relat Res.* 2010;468(4):1129-1135.
45. Miller TL, Skalak T. Evaluation and treatment recommendations for acute injuries to the ankle syndesmosis without associated fracture. *Sports Med.* 2014;44(2):179-188.

46. Moore JA Jr, Shank JR, Morgan SJ, Smith WR. Syndesmosis fixation: a comparison of three and four cortices of screw fixation without hardware removal. *Foot Ankle Int.* 2006;27(8):567-572.
47. Naqvi GA, Shafqat A, Awan N. Tightrope fixation of ankle syndesmosis injuries: clinical outcome, complications and technique modification. *Injury.* 2012;43(6):838-842.
48. Nussbaum ED, Hosea TM, Sieler SD, Incremona BR, Kessler DE. Prospective evaluation of syndesmotic ankle sprains without diastasis. *Am J Sports Med.* 2001;29(1): 31-35.
49. Phisitkul P, Ebinger T, Goetz J, Vaseenon T, Marsh JL. Forceps reduction of the syndesmosis in rotational ankle fractures. *J Bone Joint Surg Am.* 2012;94:2256-2261.
50. Samra DJ, Sman AD, Rae K, Linklater J, Refshauge KM, Hiller CE. Effectiveness of a single platelet-rich plasma injection to promote recovery in rugby players with ankle syndesmosis injury. *BMJ Open Sport Exerc Med.* 2015;1(1):e000033.
51. Schepers T. To retain or remove the syndesmotic screw: a review of literature. *Arch Orthop Trauma Surg.* 2011;131(7): 879-883.
52. Schnetzke M, Vetter SY, Beisemann N, Swartman B, Grützner PA, Franke J. Management of syndesmotic injuries: what is the evidence? *World J Orthop.* 2016; 7(11):718.
53. Schon J, Mikula J, Backus J, et al. 3D model analysis of ankle flexion on anatomic reduction of a syndesmotic injury. *Foot Ankle Int.* 2017;38(4):436-442.
54. Schottel PC, Baxter J, Gilbert S, Garner MR, Lorich DG. Anatomic ligament repair restores ankle and syndesmotic rotational stability as much as syndesmotic screw fixation. *J Orthop Trauma.* 2016;30(2):e36-e40.
55. Schreiber JJ, McLawhorn AS, Dy CJ, Goldwyn EM. Intraoperative contralateral view for assessing accurate syndesmosis reduction. *Orthopedics.* 2013;36(5): 360-361.
56. Scranton PJ. Sprains and soft tissue injuries. In: Pfefer G, ed. *Chronic Ankle Pain in the Athlete.* Rosemont, IL: Academy of Orthopaedic Surgeons; 2000:3-20.
57. Sikka RS, Fetzer GB, Sugarman E, et al. Correlating MRI findings with disability in syndesmotic sprains of NFL players. *Foot Ankle Int.* 2012;33(5):371-378.
58. Song DJ, Lanzi JT, Groth AT, et al. The effect of syndesmosis screw removal on the reduction of the distal tibiofibular joint. *Foot Ankle Int.* 2014;35(6):543-548.
59. Taylor DC, Englehardt DL, Bassett FH 3rd. Syndesmosis sprains of the ankle. The influence of heterotopic ossification. *Am J Sports Med.* 1992;20(2):146-150.
60. Taylor DC, Tenuta JJ, Uhorchak JM, Arciero RA. Aggressive surgical treatment and early return to sports in athletes with grade III syndesmosis sprains. *Am J Sports Med.* 2007;35(11): 1833-1838.
61. Teramoto A, Suzuki D, Kamiya T, Chikenji T, Watanabe K, Yamashita T. Comparison of different fixation methods of the suture-button implant for tibiofibular syndesmosis injuries. *Am J Sports Med.* 2011;39(10):2226-2232.
62. Thompson M, Gesink D. Biomechanical comparison of syndesmosis fixation with 3.5- and 4.5-millimeter stainless steel screws. *Foot Ankle Int.* 2000;21(9):736-741.
63. Tornetta P. Competence of the deltoid ligament in bimalleolar ankle fractures after medial malleolar fixation. *J Bone Joint Surg Am.* 2000;82(6):843-848.
64. Tornetta P, Spoo JE, Reynolds FA, Lee C. Overtightening of the ankle syndesmosis: is it really possible? *J Bone Joint Surg Am.* 2001;83(4):489-492.
65. Uys HD, Rijke AM. Clinical association of acute lateral ankle sprain with syndesmotic involvement: a stress radiography and magnetic resonance imaging study. *Am J Sports Med.* 2002;30(6):816-822.
66. Verhage SM, Boot F, Schipper IB, Hoogendoorn JM. Open reduction and internal fixation of posterior malleolar fractures using the posterolateral approach. *Bone Joint J.* 2016;98(6):812-817.
67. Waterman BR, Belmont PJ, Cameron KL, Svoboda SJ, Alitz CJ, Owens BD. Risk factors for syndesmotic and medial ankle sprain: role of sex, sport, and level of competition. *Am J Sports Med.* 2011;39(5):992-998.
68. Weening B, Bhandari M. Predictors of functional outcome following transsyndesmotic screw fixation of ankle fractures. *J Orthop Trauma.* 2005;19(2):102-108.
69. Williams BT, Ahrberg a. B, Goldsmith MT, et al. Ankle syndesmosis: a qualitative and quantitative anatomic analysis. *Am J Sports Med.* 2015;43(1):88-97.
70. Wolf BR, Amendola A. Syndesmosis injuries in the athlete: when and how to operate. *Curr Opin Orthop.* 2002;13(2):151-154.
71. Wuest TK. Injuries to the distal lower extremity syndesmosis. *J Am Acad Orthop Surg.* 1997;5(3):172-181.
72. Xenos JS, Hopkinson WJ, Mulligan ME, Olson EJ, Popovic NA. The tibiofibular syndesmosis. Evaluation of

- the ligamentous structures, methods of fixation, and radiographic assessment. *J Bone Joint Surg Am.* 1995;77(6): 847-856.
73. Zhan Y, Yan X, Xia R, Cheng T, Luo C. Anterior-inferior tibiofibular ligament anatomical repair and augmentation versus trans-syndesmosis screw fixation for the syndesmotic instability in external-rotation type ankle fracture with posterior malleolus involvement: a prospective and comparative study. *Injury.* 2016;47(7):1574-1580.

French Translation and validation of the Cumberland Ankle Instability Tool, an instrument for measuring functional ankle instability.

Foot and Ankle Surgery Journal (2019)

Geerinck A, Beudart C, Salvan Q, Van Bever J, D'Hooghe P, Bruyère O, Kaux JF

French translation and validation of the Cumberland Ankle Instability Tool, an instrument for measuring functional ankle instability

Geerinck A, Beudart C, Salvan Q, Van Beveren J, D'Hooghe P, Bruyère O, Kaux JF.

Foot Ankle Surg. 2019 May 9. pii: S1268-7731(19)30065-7. doi: 10.1016/j.fas.2019.05.002. [Epub ahead of print]

ABSTRACT

Background:

Ankle sprains are one of the most common musculoskeletal injuries, and can lead to chronic ankle instability (CAI). The Cumberland Ankle Instability Tool (CAIT) measures a subset of CAI, functional ankle instability (FAI). Because no French version existed, we set out to translate and validate the CAIT in French.

Methods:

The CAIT-F was translated using a forward-backward methodology. We examined its psychometric properties and calculated a cut-off score for FAI in a sample of 102 subjects (median age 22 years).

Results:

The CAIT was translated without significant problems. The CAIT-F can discriminate between those with and without FAI ($p < 0.001$), with a cut-off score of ≤ 23 points. The test-retest reliability is excellent ($ICC = 0.960$), as is the internal consistency ($\alpha = 0.885$). Construct validity was confirmed. No floor or ceiling effects were detected among subjects with FAI.

Conclusions:

The CAIT is now available in French, and is a valid and reliable instrument.

INTRODUCTION

Ankle sprains are one of the most common musculoskeletal injuries, with an incidence rate of between 5 and 7 per 1000 person-years in European populations¹. Additionally, it is estimated that roughly half of those sustaining ankle injuries do not seek professional treatment, so the true prevalence and incidence is probably higher than reported². Those engaged in regular sporting activities are particularly vulnerable, with 14.9% experiencing at least one ankle sprain³. While most patients experience a rapid improvement in pain within the first 2 weeks and further improvement after that, a non-negligible 5 to 33% still experience pain after 1 year.

Furthermore, after a first ankle sprain, the risk of re-sprain ranges from 3 to 34% and subjective instability was reported by up to 53% of subjects⁴. Hertel coined the term chronic ankle instability (CAI), which he defined as “the occurrence of repetitive bouts of lateral ankle instability, resulting in numerous

ankle sprains”, to describe a condition characterized by giving way of the ankle, mechanical instability, pain and swelling, loss of strength, recurrent sprains and functional instability⁵. The mechanics of chronic ankle instability are comprised of a spectrum of insufficiencies roughly divided into mechanical and functional. Mechanical ankle instability (MAI) is the result of physical changes such as pathologic laxity, impaired arthrokinematics, synovial changes and the development of degenerative joint disease. Functional ankle instability (FAI) is caused by changes to the neuromuscular system and affects the dynamic support of the ankle. FAI is associated with deficits in proprioception, neuromuscular control, strength and postural control⁵.

Functional instability has proven to be difficult to measure⁶. While mechanical instability can be measured by clinical tests, such as the anterior draw test, functional ankle stability is primarily diagnosed through patient-reported outcome measures (PROMS)⁷. The Cumberland Ankle Instability Tool (CAIT), designed by Hiller et al., is a PROM that can detect functional ankle instability and can also provide a measure of the severity of the instability⁶. It does so through nine questions evaluating ankle pain, subjective instability during activities such as running or hopping and the ability of the ankle to cope with episodes of giving way⁸. The questionnaire is completed separately for the left and right ankle. The answers for the nine questions are added up to a total score, which goes from 0 (indicating an extreme functional instability of the ankle) to 30 points (indicating a stable ankle).

Since its inception, the CAIT has been translated and validated in a number of languages, namely Spanish, Portuguese (Brazil), Persian, Korean, Japanese and Dutch⁹⁻¹⁴.

An overview of the results of these validations can be found in table 1. However, up until now, the questionnaire was not available in French.

The objective of this study is therefore to translate the CAIT into French and to examine its psychometric properties, so as to confirm its validity and reliability.

Table 1: Global view of the psychometric properties of the CAIT

CAIT version	Sample size (n)	Discriminative power	Internal consistency (α)	Test-retest reliability (ICC)	Construct validity (correlations with CAIT total score)	Floor and ceiling effects	Responsiveness	Cut-off score	SEM	SDC
English [9]	236			0.96	* VAS: $r = 0.76$ ($p < 0.01$) * LEFS: $r = 0.50$ ($p < 0.01$)			≤ 27		
Portuguese [13]	131		RA: 0.86 LA: 0.88	0.95 (0.93-0.97)		None observed	ES: 0.75 (95% CI: 0.49-1.00)			
Spanish [18]	108		0.766	0.979 (0.958-0.990)	* SF-36 PCS: $r = 0.241$ ($p = 0.012$) * SF-36 MCS: $r = -0.162$ ($p = 0.094$)		ES: 1.07			
English [27]	200							≤ 25		
Spanish [12]	171		RA: 0.84 LA: 0.80	* DA: 0.95 (0.93-0.96) * LA: 0.95 (0.93-0.96) * RA: 0.95 (0.94-0.97)		* Floor: $n = 0$ (0%) * Ceiling: $n = 7$ (9%)	0.69 (95% CI: 0.11-1.27)			
Korean [15]	168		0.89	0.94	* SF-36 PCS: $r = 0.70$ ($p = 0.001$) * SF-36 MCS: $r = -0.06$ ($p = 0.48$)				1.72	
Persian [14]	105		* RA: 0.81 * LA: 0.79	RA: 0.95 (0.91-0.97) LA: 0.91 (0.80-0.94)	* FAAM-ADL: $r = 0.41$ * FAAM-Sport: $r = 0.43$ * VAS: RA $r = 0.80$, LA $r = 0.64$	* Floor: RA=2.6%, LA=4.8% * Ceiling: RA=5.1%; LA=9.5%			RA: 2.03 LA: 2.4	RA: 5.6 LA: 6.5
	30		* RA: 0.77 * LA: 0.73			* Floor=0% * Ceiling >50%,				
Japanese [16]	111	AUC=0.932 ($p < 0.001$)	0.833	0.826 (0.732-0.888)	* Karlsson score: $r = 0.604$ ($p < 0.001$)			≤ 25		
English [28]	50									3.08
Dutch [17]	98		0.856	0.943	* self-reported instability: $r = -0.65$ ($p < 0.001$) * NRS pain scale: $r = -0.55$ ($p < 0.001$) * FAOS pain: $r = 0.42$ ($p < 0.001$) * FAOS symptoms: $r = 0.37$ ($p < 0.001$) * FAOS ADL: $r = 0.48$ ($p < 0.001$) * FAOS sport: $r = 0.36$ ($p < 0.001$) * FAOS QoL: $r = 0.43$ ($p < 0.001$)			≤ 11	0.82	2.28
French	102	$p < 0.001$	0.885	0.960 (0.942-0.973)	* SF-36 PCS: $r = 0.595$ ($p < 0.001$) * SF-36 MCS: $r = -0.198$ ($p = 0.091$) * FAAM- Sport: $r = 0.793$ ($p < 0.001$) * FAAM ADL: $r = 0.763$ ($p < 0.001$) * VAS: $r = 0.834$ ($p < 0.001$)	None observed in FAI group		≤ 23	1.52	4.21

VAS= visual analogue scale; LEFS= lower extremity functional scale; RA= right ankle; LA= left ankle; ES= effect size; SF-36 PCS= SF-36 physical component summary; SF-36 MCS= SF-36 mental component summary; AUC= area under the curve; NRS= numeric rating scale

MATERIALS & METHODS

Translation process

The translation methodology adopted in this study is based on the work of Beaton et al.¹⁵ and consisted of 6 phases. First, two bilingual translators, native French-speakers with English as their second language, independently translated the original tool into French. Secondly, a synthesis version was produced by the two translators. In the third phase, two different translators,

this time native English-speakers who spoke French as a second language, independently translated the synthesis version back into English. After this, an expert committee reviewed the different versions produced and modified where appropriate. The version of the tool agreed upon by the expert committee was subsequently presented to a linguist, who also proposed several modifications. Afterwards, a pre-test was organized with 10 subjects. The final version of the instrument was named the CAIT-F.

Study population

Participants were recruited from the student population of the University of Liège. This study recruited both subjects without a history of ankle trauma as well as subjects who reported to have experienced at least one sprained ankle and who experienced instability of the ankle and/or a feeling of the ankle giving way. Candidates were eligible for inclusion if they were at least 18 years old and spoke French on a daily basis. Candidates who had previously sprained their ankle were excluded if this had happened in the three months before recruitment, if another medical problem with the lower members was present or if they had had surgery on the lower members in the past. All participants provided informed consent. The study protocol was approved by the Medical Ethics committee of the University Teaching Hospital of Liège.

Instruments

Apart from the CAIT-F, participants completed the French versions of the Foot and Ankle Ability Measure (FAAM), the Short-Form 36-item Health Survey (SF-36), and a Visual Analogue Scale (VAS) rating the self-perceived stability of their ankle¹⁶⁻¹⁷.

The FAAM is a self-report outcome instrument designed to evaluate physical function for individuals with musculoskeletal disorders of the leg, foot and ankle. It is split into two subscales, one with 21 questions on activities of daily life (ADL) and the other with 8 questions on sports¹⁶.

A VAS is a simple and straightforward instrument, composed of a horizontal line of 10 cm in length, without markings. In this study, the VAS was used to let the participants auto-evaluate ankle instability, on a spectrum between extreme ankle instability on the far left of the scale, to no ankle instability on the far right.

The SF-36 is an auto-administered multi-item generic health survey which measures functional health and wellbeing from the subject's perspective. It has

36 items which are categorized into 8 domains, and also produces a physical and a mental summary score¹⁷.

Psychometric evaluation

The evaluation of the psychometric properties was carried out using the entire sample, with the exception of the evaluation of the presence of floor and ceiling effect, for which only subjects with a history of ankle instability were analyzed. For participants with a history of ankle instability, the affected or most-affected ankle was encoded. For participants without a history of ankle instability, we encoded either the left or right ankle.

Discriminative power

Given the fact that the CAIT-F evaluates the severity of functional ankle instability, its ability to distinguish between subjects with and without ankle instability was examined.

Following the example of previous validation studies of the CAIT, this study also calculated a cut-off score to distinguish between healthy and affected individuals. The choice of the optimal cut-off score was based on the highest Youden Index, which is calculated with the following formula¹⁸:

$$\text{sensitivity} + \text{specificity} - 1$$

Sensitivity and specificity was extracted from a receiver operating characteristic (ROC) curve.

Test-retest reliability

Test retest reliability shows the extent to which the questionnaire produces the same scores for repeated measurements in subjects whose health has not changed¹⁹. For this, participants completed the questionnaire twice, with an interval of 1 week in-between. Additionally, they were asked whether they had experienced any health problems concerning the lower members in the time between the first and the second administration. The test-retest reliability was evaluated with the intraclass correlation coefficient (ICC – two-way mixed, absolute agreement). An ICC higher than 0.70 is considered acceptable²⁰. We also calculated the standard error of measurement (SEM) and the smallest detectable change (SDC) of the questionnaire. The SEM provides a range around the observed value in which the theoretical “true” value can be found.

The SDC indicate the amount of change that needs to be measured to be sure that the change measured is real, and not potentially a product of measurement error. We calculated the SEM by dividing the standard deviation of the difference between test and retest scores by the square root of 2 ($SD_{diff} / \sqrt{2}$). The SDC was calculated by multiplying SD_{diff} by 1.96²¹.

Internal consistency

The internal consistency of a questionnaire is defined as “the degree of inter-relatedness among the items”¹⁹. This parameter is evaluated with the Cronbach’s alpha coefficient. A value between 0.7 and 0.9 indicates good internal consistency without significant risk of redundancy in the items²¹.

Construct validity

The evaluation of the construct validity of a questionnaire provides information on whether the questionnaire truly measures the concepts it claims to measure¹⁹. This is established through hypotheses on the correlations between the CAIT-F and questionnaires that measure similar concepts (convergent validity) or different concepts (divergent validity). A questionnaire has good construct validity when at least 75% of hypotheses are confirmed²⁰.

For the evaluation of the construct validity of the CAIT-F, the following hypotheses were formulated: we expect a moderate or strong correlation between the total score of the CAIT-F and the FAAM ADL score, as well as the FAAM Sport score. We also expect a moderate or strong correlation between the total score of the CAIT-F and the VAS. We hypothesize that a stronger correlation will exist between the total score of the CAIT-F and the SF-36 PCS than between the total score of the CAIT-F and the SF-36 MCS. Lastly, we postulate that we won’t find a significant correlation between the CAIT-F and the SF-36 MCS.

Spearman or Pearson correlation were used in function of the normality of distribution of the variables. A correlation <0.3 was considered weak, between or equal to 0.3 and 0.6 moderate and >0.6 strong.

Floor and ceiling effects

Floor and ceiling effects are considered to be present when at least 15% of the sample obtains the highest or lowest score possible.

Statistical analysis

All analyses were carried out with IBM SPSS for Windows, version 25 (Armonk, NY: IBM 178 Corp.).

Normality of distribution of the variables was established on the basis of the distance between mean and median, the histogram, the quantile-quantile plot and the Shapiro-Wilk test. Variables that displayed normal distribution were reported as mean \pm standard deviation, and non-normal variables as median (25th percentile – 75th percentile).

Differences in clinical characteristics and the discriminative power of the CAIT-F were examined with the Student T-test or the Mann-Whitney U-test, depending on their distribution.

Results were considered statistically significant at $p < 0.05$.

RESULTS

Translation

No major problems were encountered during the translation process. All differences between the translations were resolved by consensus except for 2 instances where advice from the linguistic expert (JVB) was requested before making a decision. The pre-final version of the questionnaire was then evaluated by the linguist, who proposed the following modifications:

In item 2, “j’ai l’impression que ma cheville est instable” was changed into “ma cheville me semble instable”.

Also in item 2, the linguist advised us to keep the translation of the first response option, “parfois quand je fais du sport (pas à chaque fois)”, but to change the second response option to “à chaque fois que je fais du sport” to make the distinction between the two clearer.

For the translation of the terms “typically” and “typical” in items 8 and 9, the linguist proposed the use of “habituellement” and “habituel”.

Lastly, for item 9, the linguist suggested using “après un incident habituel de torsion de cheville” instead of “après un incident où je me tords la cheville”.

The translated questionnaire was subsequently administered to 10 subjects, who reported that they did not have any issues with the comprehensibility of the questionnaire.

Population

A total of subjects agreed to participate and were included in the validation part of this study. The group with a history of ankle sprains and the group without ankle problems were evenly numbered, with 51 subjects per group. The gender distribution was also identical in both groups, with 16 (31.4%) men and 35 (68.6%) women per group.

The median age of the complete sample was 22 (20-25) years, with no significant difference for age between the healthy and pathological group ($p=0.657$). The median BMI was 23.21 (21.33-25.52) kg/m^2 , once again not significantly different between the two groups ($p=0.841$). The complete results for the clinical characteristics are detailed in table 2.

Discriminative power

As shown in table 2, the total score of the CAIT-F was significantly higher in the healthy group versus the FAI group [28 (27-30) versus 16 (11-20); $p<0.001$]. This confirms that the questionnaire can differentiate between individuals affected and non-affected by functional ankle instability.

To determine a cut-off score which distinguishes between the affected and non-affected individuals, we calculated the Youden Index for 26 potential cut-off scores, which are shown in table 3.

The maximum Youden index (0.922) indicates that the ideal cut-point lies at 23.5 points. This cut-point possesses a high sensitivity (0.922) and a high specificity (1.000). This means that a score of ≤ 23 points on the CAIT-F questionnaire is indicative of the presence of functional ankle instability.

Table 2: Characteristics of the study population

	All (n =102)	FAI (n=51)	No FAI (n=51)	p-value
Age (years)	22.00 (20.00-25.00)	22.00 (20.00-26.00)	22.00 (20.00-25.00)	0.657*
BMI (kg/m ²)	23.21 (21.37-25.42)	22.86 (21.33-25.52)	23.30 (21.40-25.00)	0.841*
Gender				
Male	32 (31.4%)	16 (31.4%)	16 (31.4%)	1**
Female	70 (68.6%)	35 (68.6%)	35 (68.6%)	
CAIT-F total score	25.00 (16.00-28.00)	16.00 (11.00-20.00)	28.00 (27.00-30.00)	<0.001*
SF-36 PCS	60.67 (54.98-63.97)	55.00 (47.69-59.40)	63.27 (61.67-66.71)	<0.001*
SF-36 MCS	45.27 (35.18-51.87)	48.82 (41.19-54.62)	40.83 (32.21-48.39)	0.004*
FAAM Sport score	92.19 (75.00-100.00)	75.00 (62.50-84.37)	100.00 (93.75-100.00)	<0.001*
FAAM ADL score	97.60 (91.67-100.00)	91.67 (85.71-95.23)	100.00 (98.34-100.00)	<0.001*

VAS	9.00	5.00	10.00	
	(5.00-10.00)	(3.00-7.00)	(10.00-10.00)	<0.001*

* Mann-Whitney U-test

** Chi-square test

Test-retest reliability

All participants completed the CAIT-F twice, with one week between the two administrations. None of the subjects reported a health problem in the interval between the administrations.

An ICC of 0.960 (95% CI: 0.942-0.973) was found for the total score of the CAIT-F, indicating excellent test-retest reliability. For the individual items, the ICC's ranged from 0.909 (95% CI: 0.866-0.938) for item 7 to 0.996 (95% CI: 0.995-0.998) for item 9. The ICC's for all items are reported in table 4. The SEM was calculated to be 1.52 points and the SDC was 4.21 points.

Internal consistency

The Cronbach's alpha for the entire questionnaire was 0.885, indicating good internal consistency.

We also evaluated the internal consistency when deleting a single item. The lowest alpha was found when deleting item 5 ($\alpha=0.866$) and the highest alpha when deleting item 7 ($\alpha=0.878$). Complete results are reported in table 4.

Lastly, we evaluated the strength of the correlations between the total score and the individual items of the CAIT-F, also shown in table 4. We obtained moderate to strong significant correlations for each item with the total score, going from $r = 0.554$ to $r = 0.834$.

Table 3 : Sensitivity, specificity and Youden index

CAIT score	Sensibility	Specificity	Youden index
0.00	0.000	1.000	0.000
1.50	0.020	1.000	0.020
4.50	0.039	1.000	0.039
7.50	0.059	1.000	0.059
8.50	0.098	1.000	0.098
9.50	0.157	1.000	0.157
10.50	0.235	1.000	0.235
11.50	0.353	1.000	0.353
12.50	0.373	1.000	0.373
13.50	0.451	1.000	0.451
15.00	0.471	1.000	0.471
16.50	0.510	1.000	0.510
17.50	0.549	1.000	0.549
18.50	0.667	1.000	0.667
19.50	0.745	1.000	0.745

20.50	0.765	1.000	0.765
21.50	0.804	1.000	0.804
22.50	0.902	1.000	0.902
23.50	0.922	1.000	0.922
24.50	0.941	0.980	0.921
25.50	0.980	0.902	0.882
26.50	0.980	0.765	0.745
27.50	0.980	0.569	0.549
28.50	1.000	0.412	0.412
29.50	1.000	0.373	0.373
31.00	1.000	0.000	0.000

Construct validity

We pre-specified 5 hypotheses on the strength of the correlations between the total score of the CAIT-F and MCS score of the SF-36, the Sport and ADL subscales of the FAAM and the VAS. As shown in table 5, all convergent hypotheses were confirmed when a strong correlation was found between the total score of the CAIT-F and the PCS score of the SF-36 ($r = 0.595$; $p < 0.001$), the Sport ($r = 0.793$; $p < 0.001$) and ADL ($r = 0.763$; $p < 0.001$) subscales of the FAAM and the VAS ($r = 0.834$; $p < 0.001$). The divergent validity was also confirmed since no significant correlation was found between the total score of the CAIT-F and the MCS score of the SF-36 ($r = -0.168$; $p = 0.091$).

Lastly, the hypothesis that the correlation between the CAIT-F and the PCS score would be greater than the correlation between the CAIT-F and the MCS score was also confirmed ($r = 0.595 > r = -0.168$).

Table 4: Test-retest reliability and internal consistency of the CAIT-F

	Test-retest reliability		Internal consistency		
	ICC	95% CI	Cronbach's alpha if item deleted	Correlation with total score	
				<i>r</i> ^a	p
Item 1	0.948	0.924 - 0.965	0.876	0.768	<0.001
Item 2	0.990	0.986 - 0.993	0.867	0.834	<0.001
Item 3	0.976	0.964 - 0.983	0.875	0.718	<0.001
Item 4	0.993	0.989 - 0.995	0.876	0.638	<0.001
Item 5	0.984	0.977 - 0.989	0.866	0.798	<0.001
Item 6	0.947	0.923 - 0.964	0.872	0.724	<0.001
Item 7	0.909	0.938		0.554	<0.001
Item 8	0.979	0.968 - 0.985	0.870	0.773	<0.001

Item 9	0.995 -	0.875		
	0.996	0.998	0.702	<0.001
Total	0.942 -			
score	0.960	0.973		

^a Spearman correlations

Floor and ceiling effects

None of the 51 participants with a history of ankle instability obtained the lowest (0 points) or the highest (30 points) score, indicating the absence of both floor and ceiling effects.

Table 5: Construct validity of the CAIT-F

	r^a	p		r^a	p
Convergent validity			Divergent validity		
SF-36 PCS	0.595	<0.001	SF-36 MCS	-0.198	0.091
FAAM Sport	0.793	<0.001			
FAAM ADL	0.763	<0.001			
VAS	0.834	<0.001			

^a Spearman correlations between CAIT-F total score and indicated scores

DISCUSSION

In the present study, the CAIT was translated into French and its psychometric properties were evaluated. The questionnaire was first translated using a forward-backward procedure. Subsequently, the questionnaire was completed twice by 102 subject and evaluated on its discriminative power, test-retest reliability, internal consistency, construct validity and the presence of floor and ceiling effects.

The subjects who reported ankle instability reported significantly lower total scores on the CAIT-F compared to those who did not, confirming the ability of the questionnaire to discriminate between the two.

This also allowed us to calculate a cut-off score for FAI, as has been previously done for the English, Dutch and Japanese versions^{6,13,14,22}.

We found that the ideal cut-off point in our population was ≤ 23 , which is slightly lower than the Japanese cut-off (≤ 25) and the recalculated English cut-off (≤ 25) but much higher than the Dutch cut-off (≤ 11). The sample recruited for this study is similar to the one recruited for the Japanese and the recalibration of the English cut-off. Both recruited young people, as did the

current study, and most subjects were physically active. It is thus a good sign that the cut-off scores in these three studies are relatively close to one another. The Dutch study recruited older participants (median age of 40 years) who presented at an orthopaedic outpatient clinic, a different population than the three aforementioned studies. It is therefore not surprising that their cut-off score is much lower than the others. It could be that specific cut-off values are needed for age-categories.

The results for the test-retest reliability are excellent, with an ICC of 0.960 (95% CI: 0.942-0.973) for the total score, and ICC's above 0.9 for the individual items. This is in line with previously obtained results, most of which were also close to 0.95 (see table 1).

The same is true for the internal consistency of the CAIT-F, where the Cronbach's alpha of 0.885 found in this study is completely in line with previously obtained results (see table 1), and in the range of 0.7 to 0.9 which indicates good internal consistency.

The construct validity of the CAIT-F was examined by correlations between convergent and divergent domains/scores from other questionnaires. The results obtained in this study are in agreement with earlier validations and confirm the construct validity of the CAIT-F.

Lastly, we did not find any floor or ceiling effect for the total score of the CAIT-F, as we expected from previous validations.

STRENGTHS

The main strengths of this study lie in the rigorous methodology used to produce the French translation of the CAIT, ensuring its equivalence to the original version. A second strength is the completeness of the validation, with discriminative power, internal consistency, test-retest reliability, construct validity and floor and ceiling effects examined. On top of that, this study also produced a cut-off score, a SEM-value and an SDC-value.

We were able to recruit a sufficient sample size for the evaluation of the psychometrics of the questionnaire, with 102 subjects in total and 51 subjects with FAI²⁰.

LIMITS

It is recommended that one of the two forward translators (English to French) should have a medical background and be familiar with the concepts in the questionnaire. Unfortunately, we were unable to find someone with this profile,

and instead the forward translations were carried out by a primary school teacher and a secondary school English teacher. However, both translators did not encounter any difficulties with technical terms and concepts, given that the questionnaire is meant to be completed by people who themselves do not have a medical background. Furthermore, the presence of an expert in physical medicine and rehabilitation at the expert review meeting should have provided a safeguard for any misunderstanding of a technical nature.

CONCLUSION

This study produced a French-language version of the CAIT, and confirmed that it is a valid, consistent and reliable instrument in a sample of 102 subjects. This study also provided a new cut-off score for the diagnosis of FAI (≤ 23 points) and calculated its SEM and SDC. The CAIT-F is ready to be used in clinical practice and research applications.

REFERENCES

1. Bridgman SA, Clement D, Downing A, et al. Population based epidemiology of ankle sprains attending accident and emergency units in the West Midlands of England, and a survey of UK practice for severe ankle sprains. *Emerg Med J* 2003;20:508–10.
2. McKay GD, Goldie PA, Payne WR, et al. Ankle injuries in basketball : injury rate and risk factors *Ankle injuries in basketball : injury rate and risk factors* 2001:103–8.
3. Hootman JM, Dick R, Agel J. Epidemiology of collegiate injuries for 15 sports: Summary and recommendations for injury prevention initiatives. *J Athl Train* 2007;42:311–9.
4. van Rijn RM, van Os AG, Bernsen RMD, et al. What Is the Clinical Course of Acute Ankle Sprains? A Systematic Literature Review. *Am J Med* 2008;121.
5. Hertel J. Functional anatomy, pathomechanics, and pathophysiology of lateral ankle instability. *J Athl Train* 2002;37:364–75.
6. Hiller CE, Refshauge KM, Bundy AC, et al. The Cumberland Ankle Instability Tool: A Report of Validity and Reliability Testing. *Arch Phys Med Rehabil* 2006;87:1235–41.
7. Parasher RK, Nagy DR, Em AL, et al. Clinical measurement of mechanical ankle instability. *Man Ther* 2012;17:470–3.
8. Cruz-Díaz D, Hita-Contreras F, Lomas-Vega R, et al. Cross-cultural adaptation and validation of the Spanish version of the Cumberland Ankle Instability Tool (CAIT): An instrument to assess unilateral chronic ankle instability. *Clin Rheumatol* 2013;32:91–8.
9. Rodríguez-Fernández ÁL, Rebollo-Roldán J, Jiménez-Rejano JJ, et al. Psychometric properties of the Spanish version of the Cumberland Ankle Instability Tool. *Disabil Rehabil* 2015;37:1888–94.
10. de Noronha M, Refshauge KM, Kilbreath SL, et al. Cross-cultural adaptation of the Brazilian-Portuguese version of the Cumberland Ankle Instability Tool (CAIT). *Disabil Rehabil* 2008;30:1959–65.
11. Hadadi M, Ebrahimi Takamjani I, Ebrahim Mosavi M, et al. Cross-cultural adaptation, reliability, and validity of the Persian version of the Cumberland Ankle Instability Tool. *Disabil Rehabil* 2017;39:1644–9.
12. Ko J, Rosen AB, Brown CN. Cross-Cultural Adaptation and Validation of the Korean Version of the Cumberland Ankle 2015;10:1007–14.
13. Kunugi S, Masunari A, Noh B, et al. Cross-cultural adaptation, reliability, and validity of the Japanese version of the Cumberland ankle instability tool. *Disabil Rehabil* 2017;39:50–8.

14. Vuurberg G, Kluit L, van Dijk CN. The Cumberland Ankle Instability Tool (CAIT) in the Dutch population with and without complaints of ankle instability. *Knee Surgery, Sport Traumatol Arthrosc* 2018;26:882–91.
15. Beaton DE, Bombardier C, Guillemin F, et al. Guidelines for the process of cross-cultural adaptation of self-report measures. *Spine (Phila Pa 1976)* 2000;25:3186–91.
16. Borloz S, Crevoisier X, Deriaz O, et al. Evidence for validity and reliability of a french version of the FAAM. *BMC Musculoskelet Disord* 2011;12:40.
17. Leplège A, Ecosse E, Verdier A, et al. The French SF-36 Health Survey: Translation, cultural adaptation and preliminary psychometric evaluation. *J Clin Epidemiol* 1998;51:1013–23.
18. Youden WJ. Index for rating diagnostic tests. *Cancer* 1950;3:32–5.
19. Mokkink LB, Terwee CB, Patrick DL, et al. The COSMIN study reached international consensus on taxonomy, terminology, and definitions of measurement properties for health-related patient-reported outcomes. *J Clin Epidemiol* 2010;63:737–45.
20. Terwee C, Bot S, De Boer M, et al. Quality criteria were proposed for measurement properties of health status questionnaires. *J Clin Epidemiol* 2007;60:34–42.
21. De Vet HCW, Terwee CB, Mokkink LB, et al. *Measurements in Medicine*. Cambridge University Press; 2011.
22. Wright CJ, Arnold BL, Ross SE, et al. Recalibration and validation of the Cumberland ankle instability tool cutoff score for individuals with chronic ankle instability. *Arch Phys Med Rehabil* 2014;95:1853–9.

Dynamic Stabilization of Syndesmosis Injuries Reduces Complications and Reoperations Compared to Screw Fixation: a Meta-Analysis of RCTs
Accepted in American Journal of Sports Medicine (June 2019)

Grassi A, Samuelsson K, D'Hooghe P, Romagnoli M, Mosca M, Zaffagnini S, Amendola A

ABSTRACT

Background:

Several devices to obtain a dynamic fixation of the syndesmosis have been introduced in the recent years, however their efficacy has been tested in few RCTs, without a clear benefit over the traditional static fixation with screws.

Purpose:

To perform a Level I meta-analysis of RCTs to investigate the complications, subjective outcomes and functional results after dynamic or static fixation of acute syndesmotic injuries.

Methods:

A systematic literature search of the MEDLINE/Pubmed, Cochrane Central Register of Controlled Trials (CENTRAL) and EBSCOhost electronic databases and clinicaltrials.gov for unpublished studies was performed. Eligible studies were randomized controlled trials (RCTs) comparing dynamic fixation and the static fixation of acute syndesmosis injuries. A meta-analysis was performed, while bias and quality of evidences were rated according to the Cochrane Database questionnaire and the Grading of Recommendations Assessment, Development and Evaluation (GRADE) guidelines.

Results:

Dynamic fixation has a significantly decreased RR (0.55, $p=0.003$) of complications, in particular the presence of inadequate reduction at the final follow-up (RR=0.36, $p=0.0008$) and the clinical diagnosis of recurrent diastasis or instability (RR=0.10, $p=0.03$). The effect was more evident compared to permanent screws (RR=0.10, $p=0.0001$). The reoperation rate was similar between the two groups (RR=0.64, $p=0.07$); however, the overall risk was reduced after dynamic fixation when compared to static fixation with permanent screws (RR=0.24, $p=0.007$). The AOFAS score was significantly higher in patients treated with dynamic fixation of 6.06 points ($p=0.005$) at 3 months, 5.21 points ($p=0.03$) at 12 months and 8.60 points ($p<0.00001$) at 24 months, while the Olerund-Morlander score was similar. VAS for pain was reduced at 6 months (-0.73 points, $p=0.003$) and at 12 months (-0.52 points, $p=0.005$) and ankle ROM was increased of 4.36° ($p=0.03$) with dynamic fixation. The overall

quality of evidence was from “moderate” to “very low” due to a substantial risk of bias, heterogeneity, indirectness of outcome reporting and evaluation of a limited number of patients.

Conclusion:

Dynamic fixation of syndesmotic injuries was able to reduce the number of complications and improve clinical outcomes compared to static screw fixation, especially malreduction and clinical instability or diastasis, at a follow-up of 2 years. A lower risk of reoperation with dynamic fixation was found compared to static fixation with permanent screw. However, lack of patients or personnel blinding, treatment heterogeneity, small samples and short follow-up, limits the overall quality of these evidences.

Level of Evidence: Meta-analysis of randomized controlled trials (Level I)

What is known about the subject?

Promising results have been reported with the use of dynamic fixation of syndesmotic injuries. However, only few RCTs are presents, with not consistent results in term of functional outcomes, reoperations and complications.

What this study adds to existing knowledge?

This meta-analysis of level I RCTs comparing dynamic with static fixation of tibio-peroneal distal syndesmosis summarizes the highest level of evidences on this topic and provides information to clinicians regarding the performance of static fixation over standard treatment. The improved subjective clinical outcomes and the reduced number of complications and reoperations makes the dynamic fixation a good option for syndesmosis injury treatment, at least at short-term follow-up.

INTRODUCTION

Injuries to the distal tibio-peroneal syndesmosis could be present in isolation, or in approximately 13-20% of ankle fractures, caused by an injury mechanism of pronation and external rotation⁷. Concomitant stabilization of the syndesmosis is mandatory in addition to fracture fixation since its misdiagnosis or inadequate treatment could be responsible of persistent pain, functional impairment and early osteoarthritis^{20, 27, 33, 35}. To obtain an accurate and stable syndesmosis

reduction, the actual gold-standard in treatment is represented by screw fixation³⁴. However, several complications are common with this treatment, such as screw loosening, breakage, local irritation and discomfort^{8, 14, 36}. Moreover, when screw removal is planned to avoid implant problems, loss of reduction could occur^{19, 37}.

For these reasons, several devices to obtain a dynamic fixation of the syndesmosis have been introduced^{6, 25, 30}, with the rationale to possibility obtaining a more physiological movement of the syndesmosis during joint load while maintaining the required reduction. The result would be to allow early weight-bearing reducing the risk of implant loosening and breakage, avoid a second reoperation for eventual screw removal and reduce the risk of loss of reduction after implant removal^{19, 28}. Several controlled studies comparing static screw fixation with various devices for dynamic fixation have been published and summarized in systematic reviews and meta-analyses^{3, 14, 17, 25, 28, 31, 42}. However, the most recent meta-analysis by Chen et al.³ which included 9 studies and 387 patients, was seriously biased by the overall limited quality due to the inclusion both prospective and retrospective studies, with only 3 RCTs^{4, 18, 19}. The great interest on the treatment of syndesmotic injuries is confirmed by the fact that several new RCTs have been performed both in Europe^{1, 5, 24}, Canada²³ or Asia⁴¹ in the last few years.

Due to the increased amount of high-level literature, there is the need to evaluate and summarize the Level I evidence regarding the static or dynamic fixation of syndesmotic injuries, in order to determine the most performant strategy in terms of patient's satisfaction, functional results and complications.

The aim of the present study was therefore to perform a Level I meta-analysis of RCTs to investigate the complications, subjective outcomes and functional results after dynamic or static fixation of acute syndesmotic injuries. The hypothesis was that dynamic and static syndesmosis fixation would present similar functional outcomes, complications and reoperations.

MATERIALS & METHODS

Literature search

This meta-analysis was conducted according to the Preferred Reporting Items for Systematic reviews and Meta-Analysis (PRISMA) guidelines²². A systematic electronic search of the following databases was performed in March 2018; Pubmed, EMBASE and Cochrane Central Register of Controlled Trials

(CENTRAL); the website clinicaltrials.gov for unpublished studies. The key words were “syndesmosis OR syndsmotic OR syndesmoses OR high ankle” combined with “suture-button OR button OR endo-button OR tightrope OR arthrex OR dynamic OR wires OR fixation device”. The electronic database search was supplemented by manual scanning of the reference lists of included articles and the ePublication lists of the leading orthopedic and sports medicine journals.

Article selection

Eligible studies were RCTs comparing screw fixation with dynamic fixation of syndesmotom injuries either with or without ankle fracture. Any device for dynamic stabilization was considered eligible for inclusion. Both published and unpublished studies in all languages were eligible. Biomechanical studies, in-vitro studies, review articles, surgical techniques, case reports, letters to the editor and editorials were excluded. There were no criteria for the technique used in the surgical procedure, study sample size or length of follow-up.

Two authors (X.X. and X.X) independently reviewed the title and abstract of each article from the literature search. The assessors were not blinded to the authors of the publications. The full text of an article was obtained and evaluated when eligibility could not be assessed from the first screening. Any disagreements were resolved via a consensus discussion between the reviewers and a third reviewer was consulted if the disagreement could not be resolved.

Data extraction

An electronic piloted form was created for data extraction. Data on patient demographics, including patient gender and age at surgery, were extracted, as well as details of study design, such as level of evidence, inclusion and exclusion criteria, method of randomization and length of follow-up. Treatment factors, such as injury classification, surgical technique for syndesmotom injury and concomitant injuries or fractures were also collected. The piloted form also included columns for the extraction of all outcome measurements, which were defined prior to study start and it was compulsory for a study to present data on at least one of the outcomes to be included.

Outcomes definition

The outcomes of interest were: functional outcome measurements defined as the American Orthopedic Foot and Ankle Score (AOFAS), The Olerud-Molander score, the Visual Analogic Scale (VAS) for pain, joint range of motion (ROM)

measured with dorsi-flexion and plantar-flexion, time to return to work and sport activity, and percentage of patients returning to the same pre-injury activity. Furthermore, complications and reoperations, as defined in each study, were collected. In particular, the inadequate reduction was considered intra or post-operatively when a correction of syndesmosis reduction was performed during surgery or the next day after CT scan; inadequate reduction was considered at final follow-up based on imaging criteria. Insufficient fixation was referred to inadequate reduction of fixation of concomitant fractures but not syndesmosis. Clinical recurrent diastasis or instability was based on clinical criteria defined in each study. Regarding reoperations, synthesis revision was considered when a reoperation was performed to correct a concomitant fracture synthesis, but not syndesmosis; wound revision was considered when a reoperation was performed to address wound problems without removing the syndesmotic implant, otherwise it was considered as implant removal. For both syndesmotic implant and fracture hardware, only the not planned removal were accounted.

Due to the extreme heterogeneity of the possible complications, these were evaluated as: “overall complications” defined as all the complications reported in each study; “device-related complications” defined as those possibly caused by the device used to stabilize the syndesmosis, such as malreduction, recurrent instability, infection, irritation and discomfort, implant break, implant loosening, and “clinically significant complications” defined as all the previous ones except for implant loosening and implant break. Also, reoperations were categorized as “overall” and “device-related”; the former were defined as syndesmosis re-fixation, wound revision and not planned implant removal.

Assessment of risk of bias and quality of evidence

The risk of bias was evaluated as “high risk”, “low risk” and “unclear risk” according to the standardized Cochrane Database questionnaire¹². Articles were not excluded on the basis of the assessment. The overall quality of evidence for each outcome was graded as “high”, “moderate”, “low” and “very low”, based on study design, risk of bias, inconsistency, indirectness, imprecision and publication bias, according to the Grading of Recommendations Assessment, Development and Evaluation (GRADE) guidelines². The risk of bias and GRADE evaluation was performed based on consensus by two authors (X.X. and X.X.). The intervention of a third reviewer was not needed because the authors reached consensus for all the items after discussion.

Statistical analysis

The meta-analysis was performed using RevMan V.5.0.18.33 (the Cochrane Collaboration, Copenhagen, Denmark). Continuous variables were extracted and analyzed as the mean \pm standard deviation (SD). The corresponding author was contacted and asked to provide the data if the SD was not reported. In the event of no response, the SD was calculated from the available data, according to a previously validated formula; $((\text{higher range value} - \text{lower range value})/4)$, or $\text{IQR}/1.35$ ^{10, 11}. If the SD could not be calculated using this approach, the highest SD was used. The mean difference (MD) and 95% confidence interval (CI) were calculated for continuous variables. The Relative Risk (RR) was calculated for dichotomous variables. The RR was defined as the ratio of the risk of an event in the two groups. It ranges from 0 to infinity, with values =1 indicating no differences of the risk between the groups, <1 indicating a lower risk in the “dynamic fixation” group (study group) and values >1 indicating an higher risk in the “dynamic fixation” group. We tested for heterogeneity using the χ^2 and Higgins’ I² tests⁹; according to Cochrane Guidelines, moderate heterogeneity was considered in the case of I² >30% or $p < 0.05$. We adopted a conservative statistical approach applying a Mantel-Haenszel random-effects model in presence of moderate heterogeneity, and a fixed-effects model only when both I² and p -value were <30% and >0.05, respectively⁹. When possible, the meta-analysis of clinical scores was performed at the 3, 6, 12 and 24 months follow-up. A sensitivity analysis was performed analyzing separately patients with suture-buttons or other devices, patients that underwent systematic screw removal or screw retain, and patients that had a follow-up ≤ 12 months or >12 months. A p -value of < 0.05 was considered statistically significant in all the analyses.

RESULTS

Article selection

The initial literature search yielded a total of 373 articles, and 18 were considered eligible for inclusion. Six of them were excluded because comparative studies without randomization, while 5 reports from clinicaltrials.gov were excluded because 1 RCT was still ongoing at the time of search, 1 was complete but with no report of the results, and 3 were referred to RCTs already completed and published. Therefore, after application of inclusion and exclusion criteria, 7 studies^{1, 4, 5, 18, 19, 21, 41} were included in the final analysis (Figure 1).

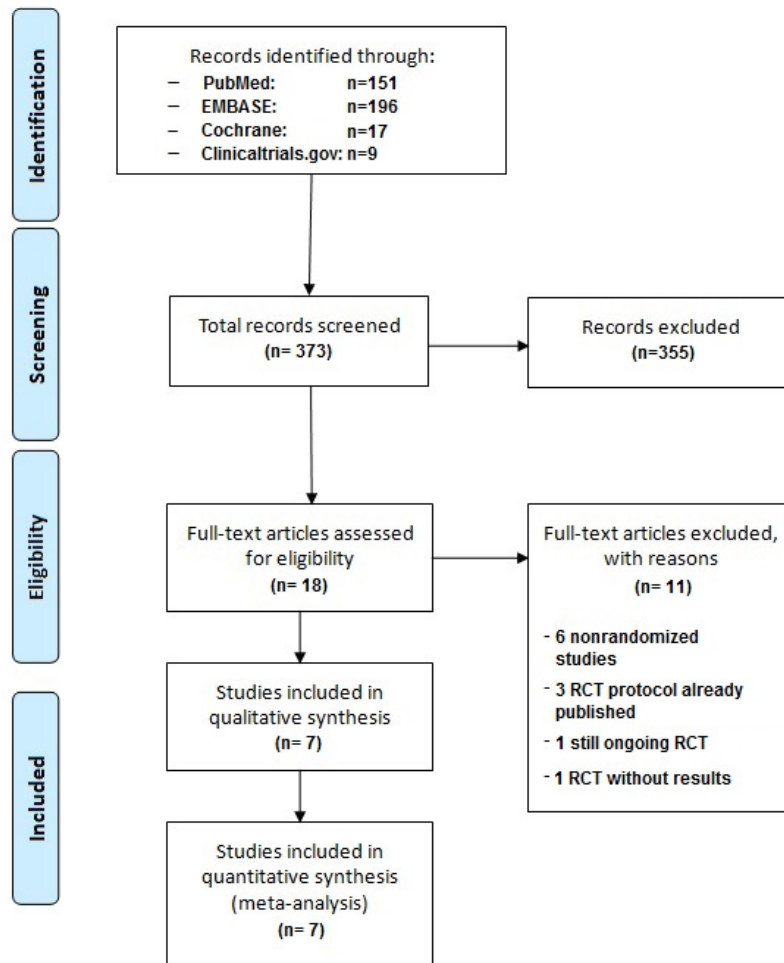


Figure 1: PRISMA flow-chart for study inclusion

Study characteristics

All of the included studies were level 1 RCTs. Well-defined exclusion criteria were specified by seven studies, which were mostly age >60 years, diabetes and open fractures. A total of 168 patients were treated with dynamic fixation and 167 patients with static fixation. The mean age ranged from 32 to 48.2 years in the dynamic group and from 35 to 46.7 years in the static group. The mean follow-up time in the included studies ranged from 12 to 24 months (Table 1).

The dynamic fixations were performed with several devices: suture buttons (5 RCTs), wire cerclages (1 RCT) or elastic hook plates (1 RCT). The static fixation was performed with one or two 3.5 to 6.5 mm screws. Four studies performed intra or post-operative imaging to detect syndesmosis malreduction and determine the need of syndesmosis refixation. Four studies had planned removal of the screws between 4 and 12 weeks. The postoperative

rehabilitation protocol consisted in a cast up to 6 weeks and full weight-bearing at the 6th week. All the studies evaluated reoperations and complications, while the most used subjective clinical scores were the VAS for pain (5 studies), the AOFAS (4 studies) and the Olerud-Molander (4 studies).

Authors	Year	Patients screened	Patients Randomized	Patients enrolled		Patients evaluated		Age		Sex		Fracture types		Fracture anatomy	
				Dynamic Fixation	Static Fixation	Dynamic Fixation	Static Fixation	Dynamic Fixation	Static Fixation	Dynamic Fixation	Static Fixation	Dynamic Fixation	Static Fixation		
Costello and Ebeling	2009	NA	NA	12	12	12	12	38 (18-55)	35 (18-53)	8M/4F	9M/3F	NA	NA	1 no fractures 4 Fibula	1 no fractures 6 Fibula
Massobrio et al.	2011	NA	NA	15	15	15	15	32 (16-62)	35 (15-73)	12M/3F	10M/5F	7 Weber B 5 Weber C 3 no fractures	9 Weber B 6 Weber C	3 no fractures 2 Fibula	8 Fibula 2 MM
Kortekangas et al.	2015	60	43	21	22	21	19	46.0 (14.8)	45.5 (15.7)	13M/8F	14M/8F	9 Maisonneuve 12 Weber C	9 Maisonneuve 12 Weber C	13 Fibula	9 Fibula
Lafamme et al.	2015	823	70	34	36	33	32	40.1 (14.8)	39.3 (12.4)	25M/9F	26M/10F	5 44B 29 44C	7 44B 29 44C	29 Fibula	30 Fibula
Andersen et al.	2018	196	97	48	49	48	49	46 (14.8)	43 (16.2)	34M/14F	30M/19F	15 Maisonneuve 33 Other	14 Maisonneuve 35 Other	NA	NA
Colovic et al.	2018	110	62	32	30	26	28	35 (18-60)	39 (18-60)	19M/7F	22M/6F	5 Weber B 3 Weber C 5 Maisonneuve 13 Isolated	6 Weber B 4 Weber C 7 Maisonneuve 11 Isolated	NA	NA
Xian et al.	2018	96	32	16	16	13	12	48.2 (11.1)	46.7 (12.1)	6M/7F	8M/4F	3 SER 3 7 SER 4 3 PER 4	2 SER 3 6 SER 4 4 PER 4	NA	NA

Table 1: Demographic characteristics and injury details of the patients included in the meta-analysis. SER, Supination External Rotation; PER, Pronation External Rotation; MM, Medial Malleolus; PM, Posterior Malleolus; M, Male; F, Female; NA, Not Assessed

Complications

Overall complications:

The random-effect meta-analysis for overall complications revealed a significantly decreased risk (RR=0.55, p=0.003) in the patients treated with dynamic fixation, in particular the presence of inadequate reduction at the final follow-up (RR=0.36, p=0.0008) (Figure 2b) and the clinical diagnosis of recurrent diastasis or instability (RR=0.10, p=0.03).

Also, the occurrence of implant break (RR=0.13, p=0.0002) or loosening (RR=0.06, p=0.006) was significantly reduced by the use of dynamic fixation devices.

Differently, the rates of inadequate post-operative reduction (figure 2a), insufficient fracture fixation, development of osteoarthritis or syndesmotic ossification, infection or irritation were similar between patient treated with dynamic and static fixation (Table 5). The risk of overall complications was reduced in patients treated with dynamic fixation independently from the device used, the screw removal or retain and the follow-up ≤12 or >12 months.

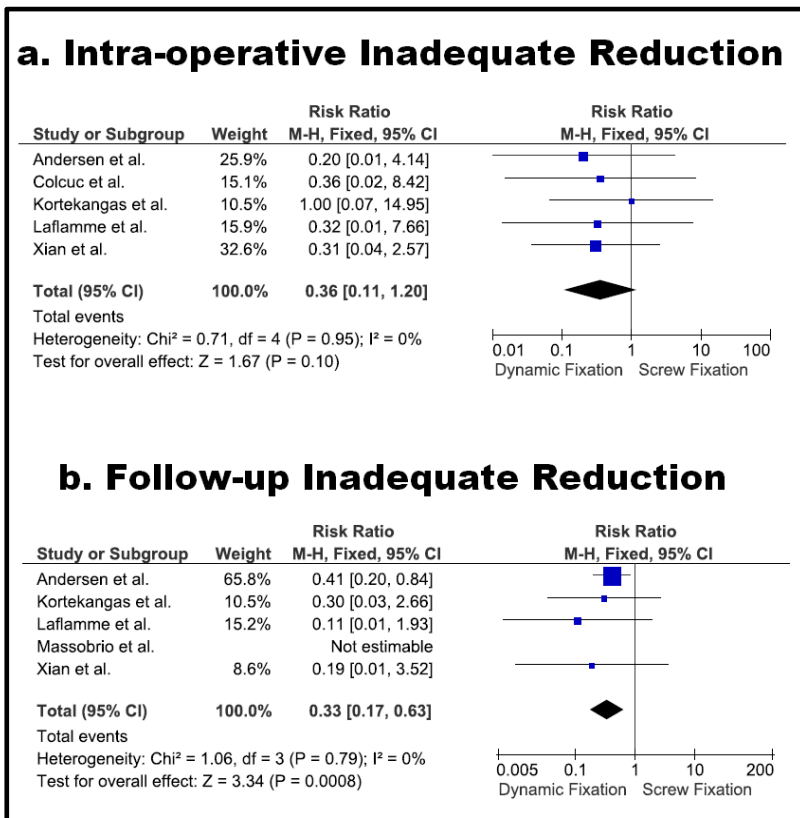


Figure 2. Forest-plots showing the incidence of inadequate intra-operative syndesmosis reduction (a) and inadequate reduction at final follow-up (b) in patients treated with Dynamic Fixation or Static Fixation.

Implant-related complications:

Considering only the complication strictly related to the device used for syndesmosis stabilization, a decreased risk ($\text{RR}=0.28$, $p=0.03$) was reported in the dynamic fixation group compared to the static fixation group (Table 5), especially with the use of a suture-button device for dynamic fixation ($\text{RR}=0.22$, $p=0.001$), or when static fixation was performed with permanent screws (0.10 , $p=0.0001$).

Differently, a similar risk between static and dynamic fixation was found when using other devices than suture-buttons ($\text{RR}=0.32$, $p=0.20$), or when syndesmotic screws were systematically removed ($\text{RR}=0.83$, $p=0.66$). The length of follow-up had no impact on this outcome.

Table V: Meta-analysis of Complications and Re-operations									
Outcome	Patients			Risk Ratio (RR)					
	Dynamic Fixation	Screw Fixation	Studies	Model	ES	95% CI	p-val	I2	p-val
Overall complications	168	167	7	RE	0.55	(0.37, 0.81)	0.003*	39%	0.13
Inadequate reduction (intra/post operative)	141	142	5	FE	0.36	(0.11, 1.20)	0.10	0%	0.95
Inadequate reduction (follow-up)	130	127	5	FE	0.36	(0.17, 0.63)	0.0008*	0%	0.79
Insufficient fixation	168	167	7	FE	0.60	(0.08, 4.40)	0.61	0%	0.59
Clinical recurrent diastasis/instability	74	77	2	FE	0.10	(0.01, 0.79)	0.03*	0%	0.58
Osteoarthritis	84	83	3	FE	0.78	(0.52, 1.17)	0.23	17%	0.30
Syndesmosis ossification	81	81	2	FE	1.18	(0.42, 3.32)	0.75	0%	0.88
Infection	168	167	7	FE	0.99	(0.36, 2.69)	0.98	0%	0.58
Irritation and discomfort	168	167	7	RE	0.75	(0.12, 4.66)	0.76	56%	0.05
Implant break	168	167	7	FE	0.13	(0.04, 0.38)	0.0002*	0%	0.92
Implant loosening	168	167	7	FE	0.06	(0.01, 0.44)	0.006*	22%	0.26
Overall reoperations	168	167	7	FE	0.64	(0.40, 1.03)	0.07	30%	0.21
Synthesis revision	168	167	7	FE	0.60	(0.08, 4.40)	0.61	0%	0.59
Syndesmosis re-fixation	168	167	7	FE	0.11	(0.01, 2.05)	0.22	NA	NA
Wound revision	168	167	7	FE	0.65	(0.11, 3.76)	0.63	0%	0.74
Hardware removal (not planned)	168	167	7	FE	1.02	(0.35, 2.94)	0.97	NA	NA
Implant removal (not planned)	168	167	7	RE	0.70	(0.21, 2.36)	0.56	48%	0.10
Arthrodesis	168	167	7	FE	3.06	(0.13, 73.34)	0.49	NA	NA
Implant-related complications (overall)	168	167	7	RE	0.28	(0.09, 0.88)	0.03*	65%	0.008
Implant-related complications (clinically relevant)	168	167	7	RE	0.66	(0.22, 1.98)	0.46	43%	0.12
Implant-related reoperations	168	167	7	FE	0.64	(0.38, 1.06)	0.08	20%	0.28

Table 5. Meta-analysis of the dichotomous outcomes complications and reoperations. P-val; p-value; ES, Effect Size; RE, Random-Effect; FE, Fixed-Effect, NA, Not Assessed.

Clinically relevant implant-related complications:

When further limiting the analysis to the complications with a clinical relevance, no differences were found between the two groups (Table 5). However, a lower risk was reported after dynamic fixation when compared only to static fixation with permanent screws (RR=0.26, p=0.01) (Figure 3), or considering only the studies with follow-up ≤12 months (RR=0.30, p=0.03).

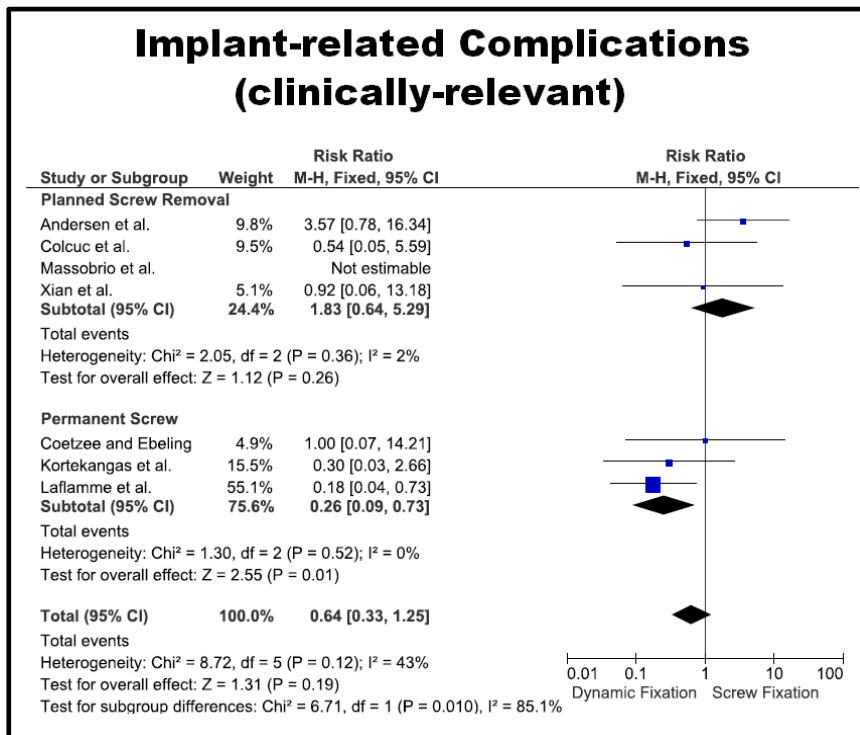


Figure 3. Forest-plots showing the incidence of clinically-relevant complications in patients treated with Dynamic Fixation or Static Fixation, stratified based on planned screw removal or permanent screw.

Reoperations

Overall reoperation:

The overall reoperation rate was similar between the two groups (RR=0.64, p=0.07) (Table 5). However, the overall risk was reduced after dynamic fixation when compared to static fixation only with permanent screws (RR=0.24, p=0.007) (Figure 4). The type of device and the follow-up length had no impact on this outcome.

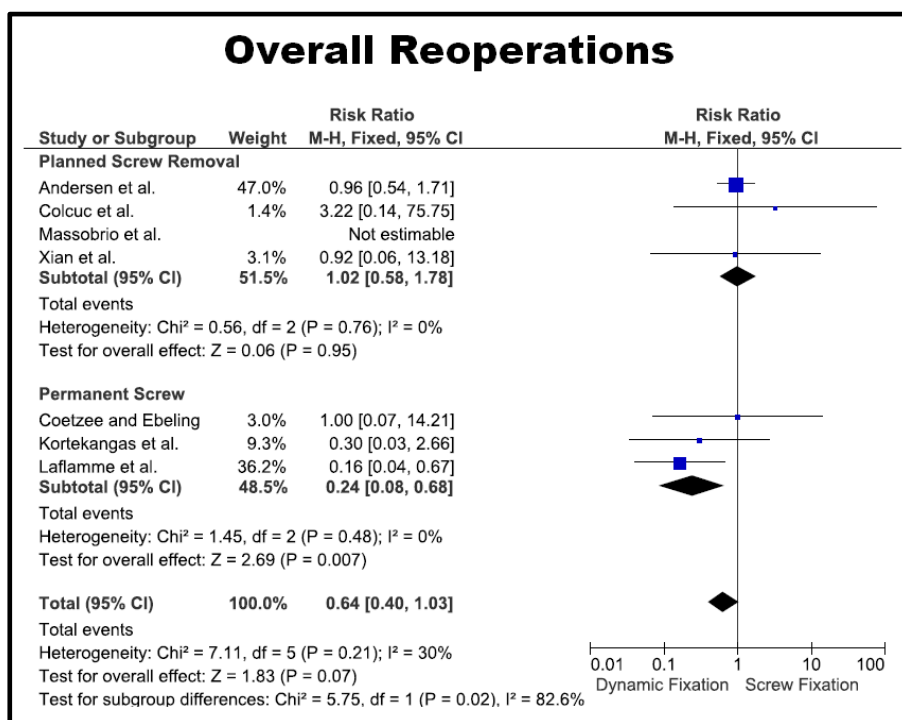


Figure 4. Forest-plots showing the incidence of overall reoperations in patients treated with Dynamic Fixation or Static Fixation, stratified based on planned screw removal or permanent screw.

Implant-related reoperations:

There were no differences also for the implant-related reoperations (RR=0.64, p=0.08) and for each of the considered type of reoperation (Table 5). However, the risk was lower in dynamic fixation when compared with static fixation with permanent screws (RR=0.26, p=0.01). Also, in this case, the type of device and the follow-up length had no impact.

Functional and subjective outcome measurements

Olerud-Morlander score:

The random-effect meta-analysis revealed no differences between the two groups for the Olerud-Molander score at the 3, 6, 12 and 24 months follow-up (Figure 5).

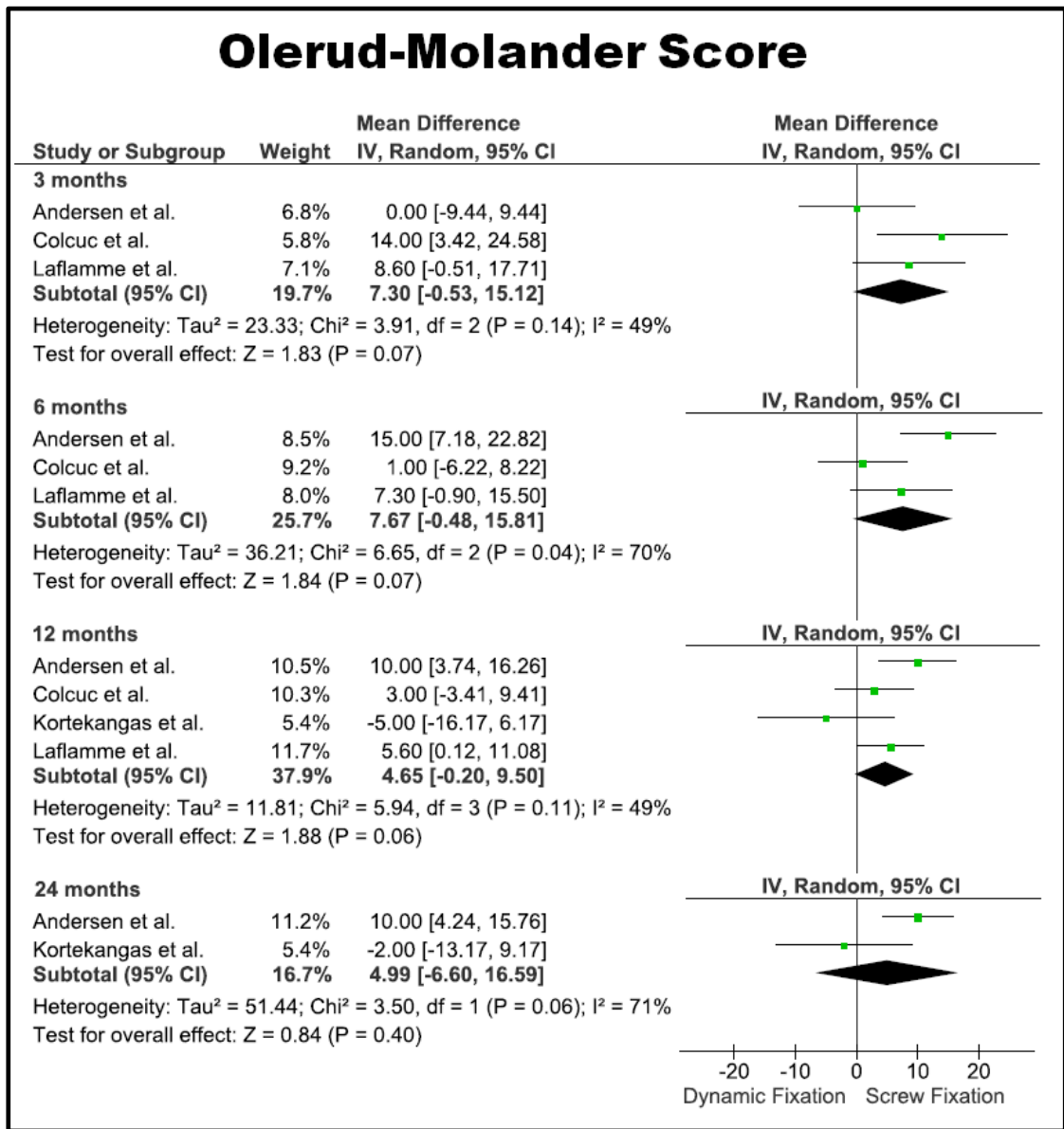


Figure 5. Forest-plots showing the mean difference of the Olerund-Molander score between patients treated with Dynamic Fixation or Static Fixation at 3 months, 6 months, 12 months and 24 months follow-up.

AOFAS score:

Differently, the AOFAS score was 6.06 points higher in patients treated with dynamic fixation respect to static fixation at 3 months (p=0.005), 5.21 points higher (p=0.03) at 12 months and 8.60 points higher (p<0.00001) at 24 months (Figure 6).

AOFAS Score

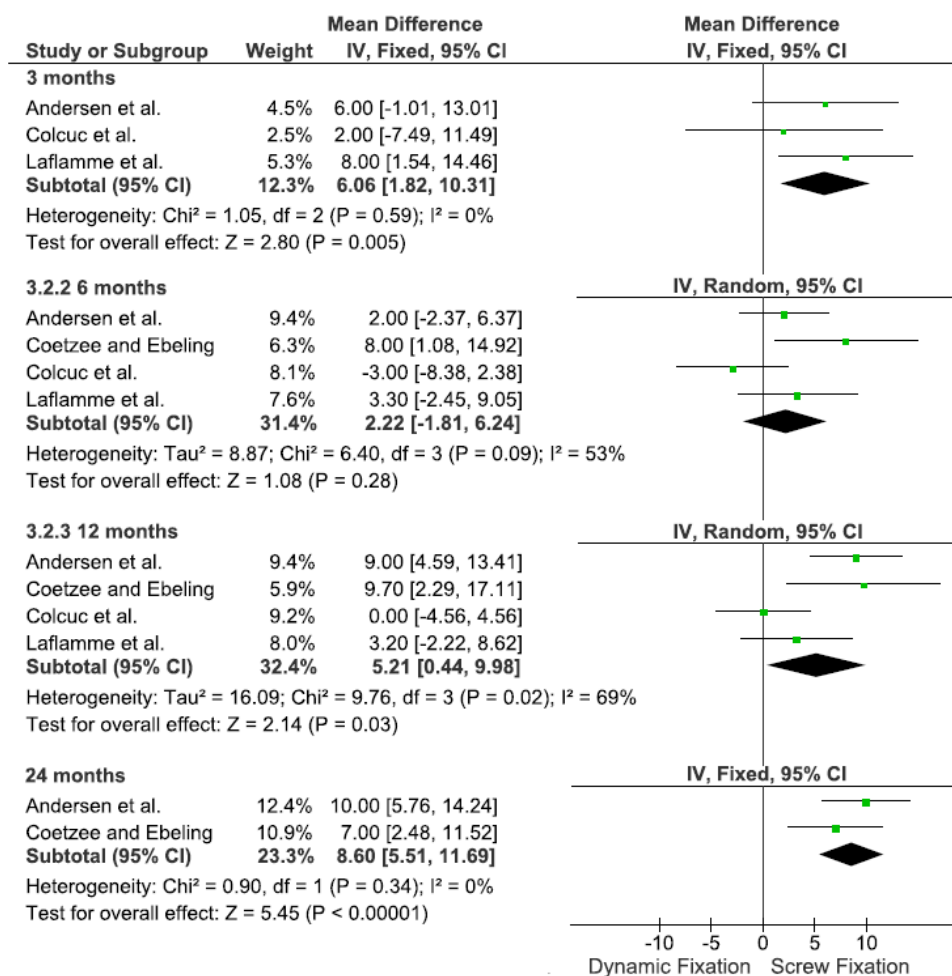


Figure 6. Forest-plots showing the mean difference of the AOFAS Score score between patients treated with Dynamic Fixation or Static Fixation at 3 months, 6 months, 12 months and 24 months follow-up.

VAS for pain score:

Also, the VAS for pain was lower in those undergoing syndesmosis repair with dynamic devices respect to static screws at 6 months (-0.73 points, p=0.003) and at 12 months (-0.52 points, p=0.005) (Figure 7).

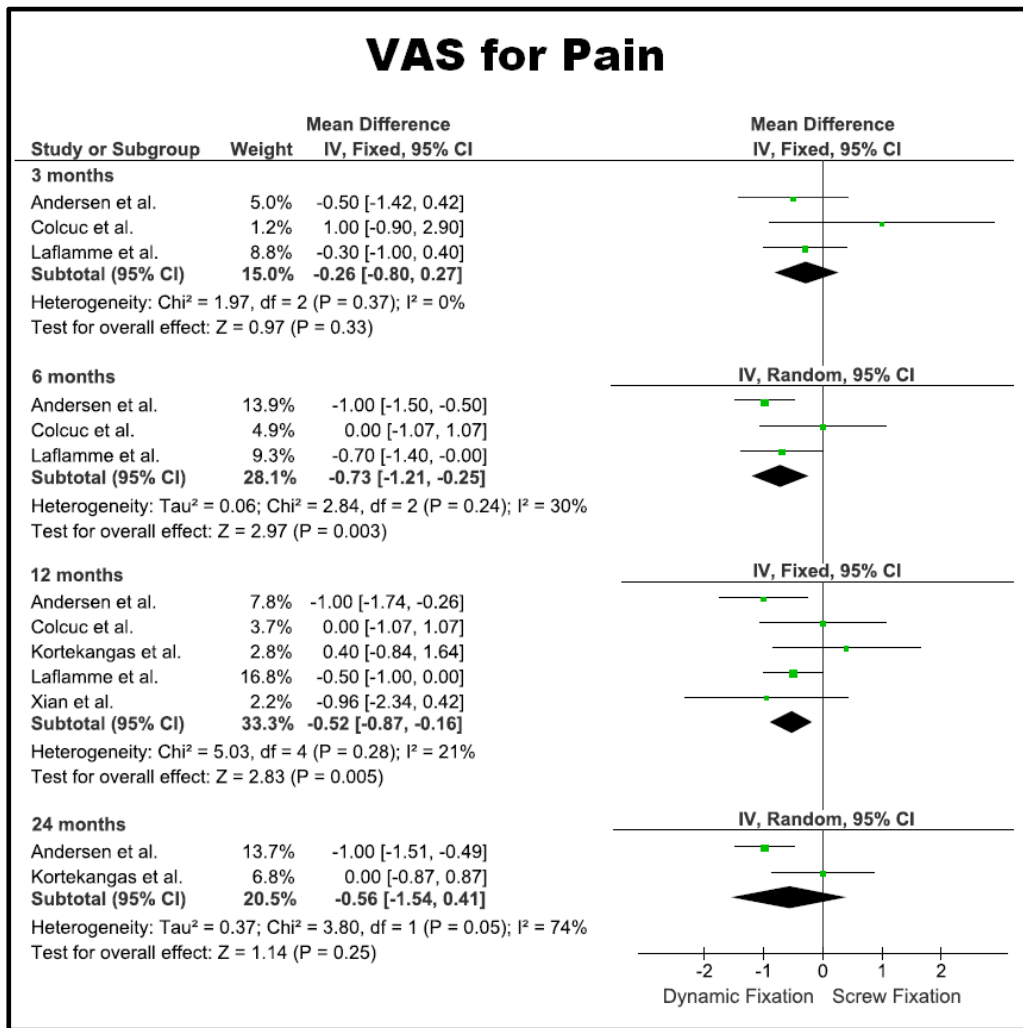


Figure 7. Forest-plots showing the mean difference of the VAS for pain score between patients treated with Dynamic Fixation or Static Fixation at 3 months, 6 months, 12 months and 24 months follow-up.

Ankle range of motion:

Regarding the range of motion, the dorsi-flexion was significantly increase of 4.36° (p=0.03) in the dynamic fixation group, while the plantar-flexion was similar between the two (Figure 8).

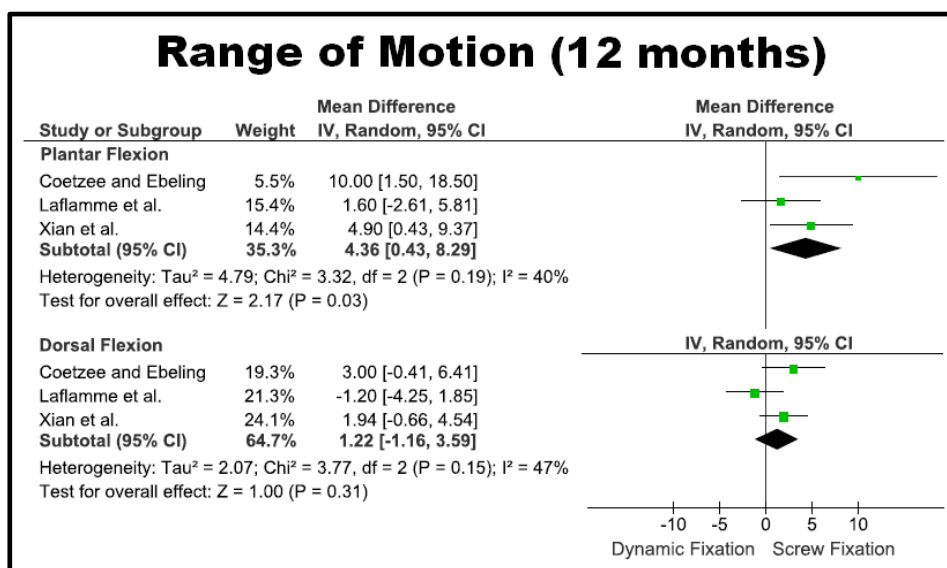


Figure 8. Forest-plots showing the mean difference of the plantar flexion (a) or dorsal flexion (b) range of motion between patients treated with Dynamic Fixation or Static Fixation.

Return to activity:

Finally, the time to return to work and sport were significantly shorter after dynamic fixation, despite only being evaluated in 2 studies and 1 study, respectively (Table 6). However, no data regarding the type of work, sport or level were provided within the included studies.

Summary of outcomes and sensitivity analysis

The risk of overall complications, inadequate reduction at follow-up, clinical recurrent diastasis or instability, implant break, implant loosening and the risk of implant-related complications were reduced with the use of dynamic fixation. When the dynamic fixation was not performed with a suture button, the risk of implant related complications was similar between the static and dynamic fixation. When static fixation was performed with permanent screws, the RR of implant related complications, clinically relevant complications, reoperations and implant-related reoperations were reduced in the dynamic fixation group. Follow-up length had a limited impact only on clinically relevant implant-related complication (Table 7). The AOFAS score, VAS for pain score, range of motion and return to activity were improved after dynamic fixation compared to static fixation.

Table VI: Meta-analysis of Functional Outcomes									
Outcome	Patients			Mean Difference (MD)					
	Dynamic Fixation	Screw Fixation	Studies	Model	ES	95% CI	p-val	I2	P-val
Olerud-Molander									
3 months	103	105	3	RE	7.30	(-0.53, 15.12)	0.07	45%	0.14
6 months	103	103	3	RE	7.67	(-0.48, 15.41)	0.07	70%	0.04
12 months	126	118	4	RE	4.65	(-0.20, 9.50)	0.06	49%	0.11
24 months	67	60	2	RE	4.99	(-6.60, 16.59)	0.40	71%	0.04
AOFAS									
3 months	105	105	3	FE	6.06	(1.82, 10.31)	0.005*	0%	0.59
6 months	115	115	4	RE	2.22	(-1.81, 6.24)	0.28	53%	0.09
12 months	117	111	4	RE	5.21	(0.44, 9.98)	0.03*	69%	0.02
24 months	53	50	2	FE	8.60	(5.51, 11.69)	0.00001*	0%	0.34
VAS for Pain									
3 months	104	103	3	FE	-0.26	(-0.80, 0.27)	0.33	0%	0.37
6 months	102	103	3	RE	-0.73	(-1.21, -0.25)	0.003*	30%	0.24
12 months	139	128	4	FE	-0.52	(-0.87, -0.16)	0.005*	21%	0.28
24 months	67	60	2	RE	-0.56	(-1.54, 0.41)	0.25	75%	0.05
Range of Motion (12 months)									
Dorsi-Flexion	58	56	3	RE	4.36	(0.43, 8.29)	0.03*	40%	0.19
Plantar-Flexion	58	56	3	RE	1.22	(-1.16, 3.59)	0.31	47%	0.15
Time to return to Activity									
Work	39	40	2	FE	-1.95	(-2.97, -0.94)	0.0002*	0%	0.96
Sport	26	28	1	FE	-5.00	(-8.74, -1.26)	0.009*	NA	NA

Table 6. Meta-analysis of the continuous subjective and functional outcomes. P-val; p-value; ES, Effect Size; RE, Random-Effect; FE, Fixed-Effect, NA, Not Assessed.

Dichotomous Outcomes	Overall complications			Overall re-operations			Implant-related complications (overall)			Implant-related complications (clinically relevant)			Implant-related re-operations		
	ES	95% CI	p-val	ES	95% CI	p-val	ES	95% CI	p-val	ES	95% CI	p-val	ES	95% CI	p-val
Tightrope (n=5)	0.56	(0.35, 0.90)	0.02*	0.58	(0.22, 1.55)	0.28	0.22	(0.13, 0.40)	0.001*	0.63	(0.18, 2.27)	0.48	0.63	(0.37, 1.05)	0.08
Other devices (n=2)	0.41	(0.17, 0.97)	0.04*	0.92	(0.06, 13.18)	0.95	0.32	(0.05, 1.83)	0.20	0.92	(0.06, 13.18)	0.95	0.92	(0.06, 13.18)	0.95
Permanent screw (n=3)	0.47	(0.33, 0.66)	0.0001*	0.24	(0.08, 0.68)	0.007*	0.10	(0.04, 0.24)	0.0001*	0.26	(0.09, 0.73)	0.01*	0.26	(0.09, 0.73)	0.01*
Blended screw removal (n=4)	0.64	(0.44, 0.94)	0.02*	1.02	(0.58, 1.78)	0.95	0.83	(0.36, 1.92)	0.66	1.83	(0.64, 5.29)	0.26	1.02	(0.55, 1.87)	0.96
Follow-up >12 weeks (n=3)	0.72	(0.56, 0.94)	0.02*	0.86	(0.50, 1.48)	0.58	0.36	(0.18, 0.71)	0.03*	1.22	(0.26, 5.80)	0.80	0.84	(0.46, 1.52)	0.56
Follow-up ≤12 weeks (n=4)	0.27	(0.14, 0.52)	0.001*	0.51	(0.09, 2.99)	0.45	0.13	(0.05, 0.33)	0.0001*	0.30	(0.10, 0.91)	0.03*	0.51	(0.09, 2.81)	0.44

Table 7. Results of sensitivity analysis for complications and reoperations, based on type of dynamic fixation, permanent or removed screw, and length of follow-up. P-val; p-value; ES, Effect Size.

Risk of bias assessment

All the studies presented at least one domain of the Cochrane Risk of Bias Tool at unclear or high risk of bias (Figure 9).

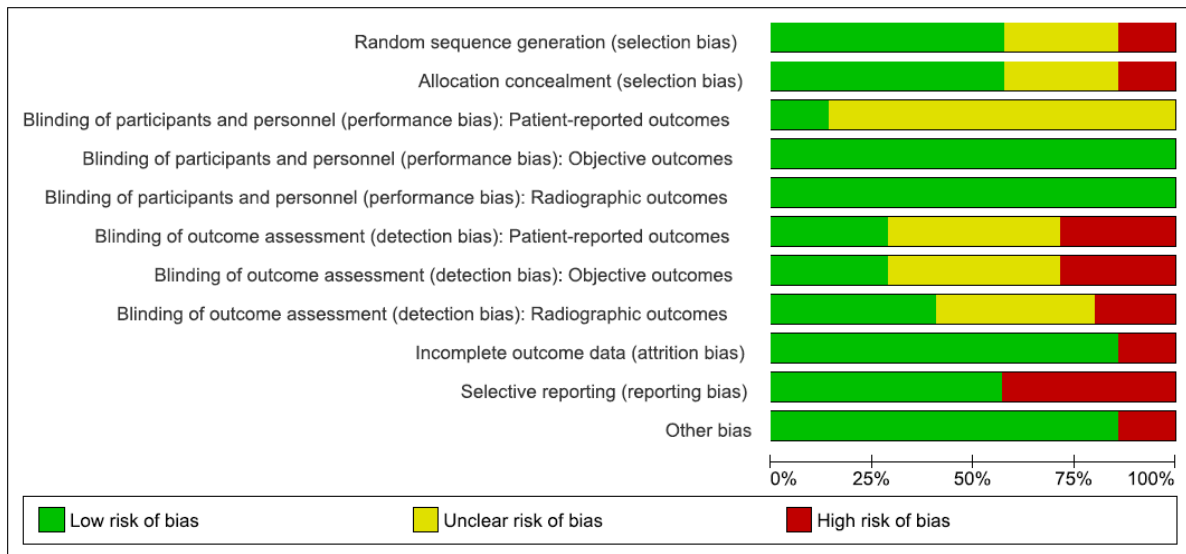


Figure 9. Risk of bias of each study: high-risk (red circle), low-risk (green circle) and unclear-risk (yellow circle)

Selection bias was high due to the inconsistent reporting of randomization and concealment methods in the included studies. Although the patients were not blinded to the allocated treatment, the risk of performance bias for objective outcomes such as complications and reoperations, and for radiographic outcomes was considered low, since those were not likely to be influenced by the patient's knowledge of a specific treatment. Differently, performance bias

was considered at high risk for subjective outcomes due to the lack of patients blinding. The detection bias was considered at high risk as well, since most of the outcomes were assessed by investigators with inadequate or unknown blinding to treatments. Attrition bias and reporting bias were considered to be low risk, since the drop-out rates were minimal and all the studies reported the result of all the outcomes described in the methods. One study was considered at high risk of bias because had different rehabilitation protocols between the two groups (Figure 10).

Quality assessment

The quality of evidence regarding the dynamic or static fixation of acute syndesmotic injury was generally “low” or “very low”, especially for reoperations and subjective or functional outcomes. The factors that lowered the quality according to the GRADE were the high risk of selection and performance bias, the high statistical heterogeneity and the limited number of included studies. Moreover, the indirectness of measurements, the imprecision due to small amount of changes, or the presence of discordant results based on sensitivity analysis further affected the quality. The highest level was “moderate”, and was reported for the compilation, both overall and implant-related”, especially considering a more evident effect of treatment when controlling for the confounding variables through the sensitivity analysis (Figure 11).

	Random sequence generation (selection bias)	Allocation concealment (selection bias)	Blinding of participants and personnel (performance bias): Patient-reported outcomes	Blinding of participants and personnel (performance bias): Objective outcomes	Blinding of participants and personnel (performance bias): Radiographic outcomes	Blinding of outcome assessment (detection bias): Patient-reported outcomes	Blinding of outcome assessment (detection bias): Objective outcomes	Blinding of outcome assessment (detection bias): Radiographic outcomes	Incomplete outcome data (attrition bias)	Selective reporting (reporting bias)	Other bias
Andersen et al.	+	+	?	+	+	-	-	+	+	+	+
Coetzee and Ebeling	?	?	?	+		?	?		+	-	+
Colcuc et al.	+	+	?	+		-	-		+	-	+
Kortekangas et al.	+	+	?	+	+	+	+	-	+	+	+
Laflamme et al.	+	+	+	+	+	+	+	+	+	+	+
Massobrio et al.	?	?	?	+	+	?	?	?	+	+	-
Xian et al.	-	-	?	+	+	?	?	?	-	-	+

Figure 10. Summary table for the risk of bias across the included studies.

Summary of findings:					
Dynamic Fixation compared to Static Fixation for Acute syndesmotic Injury					
Patient or population: Acute syndesmotic Injury Setting: Intervention: Dynamic Fixation Comparison: Static Fixation					
Outcome № of participants (studies)	Relative effect (95% CI)	Anticipated absolute effects (95% CI)		Certainty	What happens
			Difference		
Complications (overall) № of participants: 335 (7 RCTs)	RR 0.55 (0.37 to 0.81)	49.7%	27.3% (18.4 to 40.3)	22.4% fewer (31,3 fewer to 9,4 fewer)	⊕⊕⊕○ MODERATE a,b,c RR=0.36 for inadequate follow-up reduction; RR= 0.10 for recurrent clinical instability/diastasis. No impact of device, screws retain, follow-up
Complications (implant-related) № of participants: 335 (7 RCTs)	RR 0.28 (0.09 to 0.88)	34.7%	9.7% (3.1 to 30.6)	25.0% fewer (31,6 fewer to 4,2 fewer)	⊕⊕⊕○ MODERATE a,b,c Non significant RR using non suture button devices, or removing screw.
Complications (clinically relevant implant-related) № of participants: 335 (7 RCTs)	Non significant RR. Similar results with DF and SF			⊕○○○ VERY LOW a,b,d,e	RR=0.26 in favour of DF compared fo permanent screws; RR=0.30 in favour of DF when follow-up ≤12 months
Reoperations (overall) № of participants: 335 (7 RCTs)	Non significant RR. Similar results with DF and SF			⊕⊕○○ LOW a,e	RR=0.24 in favour of DF compared fo permanent screws
Reoperations (implant-related) № of participants: 335 (7 RCTs)	Non significant RR. Similar results with DF and SF ^a			⊕⊕○○ LOW ^{a,e}	RR=0.26 in favour of DF compared fo permanent screws
AOFAS score follow up: mean 12 months № of participants: 244 (4 RCTs)	-	-	-	MD 5.21 points higher (0.44 higher to 9.98 higher)	⊕⊕○○ LOW ^{b,f} SM=6.60 higher in DF at 3 months; SM=8.60 higher at 24 months; No significant SM at 6 months
VAS for pain score follow up: mean 12 months № of participants: 267 (4 RCTs)	-	-	-	MD 0.57 points lower (0.87 lower to 0.16 lower)	⊕⊕○○ LOW ^{f,g} SM=0.73 lower in DF at 6 months; no significant SM at 3 months and 24 months
Olerud-Morlander score follow up: mean 12 months № of participants: 244 (4 RCTs)	Non significant RR. Similar results with DF and SF			⊕⊕○○ LOW ^{b,f}	No significant SM also at 3, 6 and 24 months.
Ankle dorsal flexion № of participants: 114 (3 RCTs)	-	-	-	MD 4.36 ° higher (0.43 higher to 8.29 higher)	⊕○○○ VERY LOW b,h,i,j
Ankle plantar flexion № of participants: 114 (3 RCTs)	No significant MD. Similar results with DF and SF			⊕○○○ VERY LOW a,b,h,i,j	
Return to work № of participants: 79 (2 RCTs)	-	-	-	MD 1.95 weeks lower (2.97 lower to 0.94 lower)	⊕○○○ VERY LOW ^{j,k}
Return to sport № of participants: 54 (1 RCT)	-	-	-	mean 5 weeks lower (8.74 lower to 1.26 lower)	⊕○○○ VERY LOW ^{j,k}

***The risk in the intervention group** (and its 95% confidence interval) is based on the assumed risk in the comparison group and the **relative effect** of the intervention (and its 95% CI).

CI: Confidence interval; RR: Risk ratio; MD: Mean difference

GRADE Working Group grades of evidence
High certainty: We are very confident that the true effect lies close to that of the estimate of the effect
Moderate certainty: We are moderately confident in the effect estimate: The true effect is likely to be close to the estimate of the effect, but there is a possibility that it is substantially different
Low certainty: Our confidence in the effect estimate is limited: The true effect may be substantially different from the estimate of the effect
Very low certainty: We have very little confidence in the effect estimate: The true effect is likely to be substantially different from the estimate of effect

Explanations

- a. High risk of selection bias due to inappropriate or unclear randomization and concealment
- b. High heterogeneity of the meta-analysis
- c. Reduced RR according to sensitivity analysis
- d. Arbitrary definition of clinical significance
- e. Discordant results according to sensitivity analysis
- f. High risk of performance bias due to inadequate patients blinding
- g. Small amount of differences and discordant results based on follow-up
- h. High risk of detection bias due to inadequate clinicians blinding
- i. Limitations in manual measurements methods
- j. Limited number of studies

Figure 11. Summary table of the quality of evidence according to the GRADE for the outcomes after Dynamic Fixation or Static Fixation.

DISCUSSION

The most important finding of the present meta-analysis of RCTs was that the use of dynamic fixation for the treatment of syndesmotic injuries was able to reduce the number of complications and improve clinical outcomes compared to static screw fixation, thus rejecting the initial hypothesis. The inclusion of 7 Level 1 RCTs with 335 patients represents the meta-analysis on this topic with the highest level of evidence and the widest sample size.

Several considerations should be made regarding the management of syndesmotic injuries based on the present results and the available highest-level literature. First of all, most of the reported complications such as implant loosening or breakage could be considered clinically irrelevant, thus limiting the enthusiastic appeal of dynamic fixation. For this reason, we performed a further analysis excluding such events, reporting in fact similar results between static and dynamic fixation. However, when considering only the studies using permanent screws, a higher risk of clinically relevant complications in static fixation was found. Therefore, based on these results, dynamic fixation should be considered superior to screw fixation only when screws are retained. On the other hand, screw removal should not be considered totally harmless. Laflamme et al.¹⁹, which did not performed routine screw removal, reported 3 case of loss of reduction when the screw was removed due to unplanned reasons.

Similarly, Andersen et al.¹ reported the doubling of the patients with malreduced syndesmosis during the first year after surgery using serial CT, attributing this finding to loss of reduction occurred after routine screw removal. Therefore, late tibio-peroneal diastasis can be considered a common finding after screw removal, as already described by other authors²⁹ and, as a consequence, recurrent diastasis or instability could occur^{1, 5}.

Another relevant issue is the economic burden of syndesmotic injuries management. In fact, when screw removal is planned, the expense for the healthcare system is increased due to the need of a second operation, while in the case of screw retention the procedure remains cost-effective only if re-operation rate is maintained below 17.5% of cases²⁶. When evaluating reoperations in our meta-analysis, we found an almost 4-fold increase of implant-related reoperation when comparing dynamic fixation to permanent screw fixation.

Regarding clinical outcomes, dynamic fixation showed better results in terms of ankle pain from 6 to 12 months and ankle function from 12 to 24 months. The increased plantar flexion could have contributed to the more satisfactory outcomes as well, even if the difference of less than 5° could fall within the measurement error or could not be considered clinically significant. The clinical superiority of dynamic fixation compared to static fixation can be explained by the biomechanical characteristics of the construct. The restoration of a more physiological movements of the syndesmosis obtained with dynamic devices could have contributed to faster healing and clinical recovery¹⁶.

In fact, a shorter time to return to work and sport activity was reported in 2 studies^{5, 19}, even considering that a standardized rehabilitation protocol was used in the two groups (despite the possibility of early weight-bearing in the case of dynamic fixation). Another theoretical advantage of dynamic fixation, especially with suture-buttons, is that it may allow more motion and better self-centering of the syndesmosis, thus making anatomic reduction easier to accomplish³⁹. In fact, Westermann et al.³⁹ demonstrated in a cadaveric model the suture button's ability to allow for natural correction of deliberate malreduction, especially with posterior off-axis clamping. The authors postulated that suture-button syndesmotic fixation appeared to take advantage of ankle anatomy by seating the fibula within the tibial incisura fibularis as the construct was tensioned, resulting in superior reduction compared with rigid screw placement.

The detrimental effects of syndesmotic malreduction has been pointed out in clinical studies, since it has been identified as the most important predictor of functional outcome following surgery to treat an ankle fracture^{25, 38}. In this regard, an interesting consideration on the use of suture-buttons was highlighted by Kortekangas et al.¹⁸, which performed intra-operative bilateral CT scan to assess syndesmotic reduction. The authors noted a relevant number of patients with syndesmosis considered malreduced after suture button fixation. However, in all cases the syndesmoses were found to be well reduced after open exploration if the ankle was at 90° of dorsiflexion, thus not requiring re-fixation. The correct reduction was confirmed on postoperative CT, with the ankle at 90° of dorsiflexion in a below-knee cast. Therefore, they attributed the high rate of false positive findings in the intraoperative CT to the less rigid fixation of the suture button device, which could allow fibular rotation and posterior slide when the lower limb is in a free position.

Beside the results of statistical analysis, there are also important methodological considerations. The most important is the high risk of bias,

which impairs the overall quality of the evidences, despite derived only from RCTs. The main bias and limitations are those typical of surgical RCTs, such as inadequate blinding, small sample and heterogeneity in treatments.

Regarding the latter point, we performed a subgroup-analysis considering only patients treated with suture-button, without reporting higher risk of complications like stitch abscess or osteomyelitis, painful aseptic osteolysis and failed stabilization, as suggested is several series^{13, 32, 40}. Several technical tips has been in fact suggested to avoid complications and implant removal, such as cutting the FiberWire 1 cm beyond knot and burying end adjacent to fibula, performing a small medial incision to position the button abutting tibial cortex and always applying the button through the fibular plate³². In fact, applying these cautions, Storey et al.³² reported implant removal in only 8 out of 102 consecutive cases (7.8%).

Beside the high risk of performance and detection bias, the level of evidence for most of the outcomes was rated as “low” or “very low” according to the GRADE. The highest level (“moderate”) was reported for the lower risk of overall and implant-related complications. However, this could be questioned due to the inclusion of clinically irrelevant complications as well. Regarding the PROMs employed in the meta-analysis, a 5 to 8 points significant difference in the AOFAS score was found. Despite a minimal clinically important difference in AOFAS score has not been defined for the evaluation of ankle fractures, Andersen et al.¹ proposed a value of 6 points, thus suggesting a real clinical effect of the treatment. Another criticism to the AOFAS is represented by its limited precision, lack of responsiveness, and inclusion of measures obtained by the examiner, thus prone to detection bias^{1, 15}. Another limitation is due to the fact that, in order to be as much as conservative as possible in our analysis, we did not take into account the planned screw removal as reoperation. Moreover, the 2-years follow-up does not allow to confirm the results at long-term, thus caution should be used when interpreting the results and the safety of the dynamic fixation.

Finally, the strict inclusion criteria mostly to closed Weber B and C fracture in middle-aged patients limits the external validity of the treatment to this subset of patients. Therefore, further studies are required to confirm the encouraging results also in younger and athletic populations.

CONCLUSION

Dynamic fixation of syndesmotic injuries was able to reduce the number of complications and improve clinical outcomes compared to static screw fixation, especially malreduction and clinical instability or diastasis, at a follow-up of 2 years. A lower risk of reoperation with dynamic fixation was found compared to static fixation with permanent screw. However, lack of patients or personnel blinding, treatment heterogeneity, small samples and short follow-up, limits the overall quality of these evidences.

REFERENCES

1. Andersen MR, Frihagen F, Hellund JC, Madsen JE, Figved W. Randomized Trial Comparing Suture Button with Single Syndesmotic Screw for Syndesmosis Injury. *J Bone Joint Surg Am.* 2018 Jan 3;100(1):2-12. doi: 10.2106/JBJS.16.01011.
2. Balshem H, Helfand M, Schunemann HJ, et al. GRADE guidelines: 3. Rating the quality of evidence. *J Clin Epidemiol.* 2011;64(4):401-406.
- 3) Chen B, Chen C, Yang Z, Huang P, Dong H, Zeng Z. To compare the efficacy between fixation with tightrope and screw in the treatment of syndesmotic injuries: A meta-analysis. *Foot Ankle Surg.* 2017 Aug 18. pii: S1268-7731(17)31279-1. doi: 10.1016/j.fas.2017.08.001.
- 4) Coetzee JC, Ebeling P. Treatment of syndesmoses disruptions: a prospective, randomized study comparing conventional screw fixation vs TightRope® fiber wire fixation — medium term results. *SA Orthop J.* 2009;8:32–7
- 5) Colcuc C, Blank M, Stein T, Raimann F, Weber-Spickschen S, Fischer S, Hoffmann R. Lower complication rate and faster return to sports in patients with acute syndesmotic rupture treated with a new knotless suture button device. *Knee Surg Sports Traumatol Arthrosc.* 2018 Oct;26(10):3156-3164. doi: 10.1007/s00167-017-4820-3. Epub 2017 Dec 9.
- 6) Cottom JM, Hyer CF, Philbin TM, Berlet GC. Treatment of syndesmotic disruptions with the Arthrex Tightrope: a report of 25 cases. *Foot Ankle Int.* 2008 Aug;29(8):773-80. doi: 10.3113/FAI.2008.0773.
- 7) Dattani R1, Patnaik S, Kantak A, Srikanth B, Selvan TP. Injuries to the tibiofibular syndesmosis. *J Bone Joint Surg Br.* 2008 Apr;90(4):405-10. doi: 10.1302/0301-620X.90B4.19750.
- 8) Dingemans SA, Rammelt S, White TO, Goslings JC, Schepers T. Should syndesmotic screws be removed after surgical fixation of unstable ankle fractures? a systematic review. *Bone Joint J.* 2016 Nov;98-B(11):1497-1504. Review.
- 9) Deeks J, Higgins J, Altman DG. Chapter 9: Analysing data undertaking meta-analyses. In: Higgins J, Green S, eds. *Cochrane Handbook for Systematic Reviews of Interventions Version 5.1.0 (updated March 2011): The Cochrane Collaboration; 2011.*
- 10) Higgins J, Deeks J, Altman D. Chapter 16: Special topics in statistics. In: Higgins J, Green S, eds. *Cochrane Handbook for Systematic Reviews of Interventions Version 5.1.0 (updated March 2011): The Cochrane Collaboration; 2011.*

- 11) Higgins J, Deeks J. Chapter 7: Selecting studies and collecting data. In: Higgins J, Green S, eds. *Cochrane Handbook for Systematic Reviews of Interventions Version 5.1.0 (updated March 2011)*: The Cochrane Collaboration; 2011.
- 12) Higgins JPT, Green S. *Cochrane Handbook for Systematic Reviews of Intervention Version 5.1.0*: The Cochrane Collaboration; 2011.
- 13) Hong CC, Lee WT, Tan KJ. Osteomyelitis after TightRope® fixation of the ankle syndesmosis: a case report and review of the literature. *J Foot Ankle Surg.* 2015 Jan-Feb;54(1):130-4. Doi: 10.1053/j.jfas.2014.09.041. Epub 2014 Oct 31. Review.
- 14) Inge SY, Pull Ter Gunne AF, Aarts CAM, Bemelman M. A systematic review on dynamic versus static distal tibiofibular fixation. *Injury.* 2016 Dec;47(12):2627-2634. doi:10.1016/j.injury.2016.09.032.
- 15) Kitaoka HB, Alexander IJ, Adelaar RS, Nunley JA, Myerson MS, Sanders M. Clinical rating systems for the ankle-hindfoot, midfoot, hallux, and lesser toes. *Foot Ankle Int.* 1994;15(7):349-353.
- 16) Klitzman R1, Zhao H, Zhang LQ, Strohmeyer G, Vora A. Suture-button versus screw fixation of the syndesmosis: a biomechanical analysis. *Foot Ankle Int.* 2010 Jan;31(1):69-75. doi: 10.3113/FAI.2010.0069.
- 17) Kocadal O, Yucel M, Pepe M, Aksahin E, Aktekin CN. Evaluation of Reduction Accuracy of Suture-Button and Screw Fixation Techniques for Syndesmotic Injuries. *Foot Ankle Int.* 2016 Dec;37(12):1317-1325. Epub 2016 Aug 16.
- 18) Kortekangas T, Savola O, Flinkkilä T, Lepojärvi S, Nortunen S, Ohtonen P, Katisko J, Pakarinen H. A prospective randomised study comparing TightRope and syndesmotic screw fixation for accuracy and maintenance of syndesmotic reduction assessed with bilateral computed tomography. *Injury.* 2015;46(6):1119-26. doi: 10.1016/j.injury.2015.02.004. Epub 2015 Feb 21.
- 19) Laflamme M, Belzile EL, Bédard L, van den Bekerom MP, Glazebrook M, Pelet S. A prospective randomized multicenter trial comparing clinical outcomes of patients treated surgically with a static or dynamic implant for acute ankle syndesmosis rupture. *J Orthop Trauma.* 2015 May;29(5):216-23. doi: 10.1097/BOT.0000000000000245.
- 20) Marvan J, Dzupa V, Krbec M, Skala-Rosenbaum J, Bartoska R, Kachlik D, Baca V. Distal tibiofibular synostosis after surgically resolved ankle fractures: An epidemiological, clinical and morphological evaluation of a patient sample. *Injury.* 2016 Nov;47(11):2570-2574. doi: 10.1016/j.injury.2016.09.007. Epub 2016 Sep 7.
- 21) Massobrio M1, Antonietti G, Albanese P, Necci F. Operative treatment of tibiofibular diastasis: a comparative study between transfixation screw and reabsorbable cerclage. Preliminary result. *Clin Ter.* 2011;162(6):e161-7.
- 22) Moher D, Liberati A, Tetzlaff J, Altman DG. Preferred reporting items for systematic reviews and meta-analyses: the PRISMA statement. *Bmj.* 2009;339:b2535.
- 23) NCT02199249 <https://clinicaltrials.gov/ct2/show/NCT02199249>
- 24) NCT02930486 <https://clinicaltrials.gov/ct2/show/NCT02930486>
- 25) Naqvi GA, Shafqat A, Awan N. Tightrope fixation of ankle syndesmosis injuries: clinical outcome, complications and technique modification. *Injury.* 2012 Jun;43(6):838-42. doi: 10.1016/j.injury.2011.10.002. Epub 2011 Oct 27.

- 26) Ramsey DC1, Friess DM. Cost-Effectiveness Analysis of Syndesmotic Screw Versus Suture Button Fixation in Tibiofibular Syndesmotic Injuries. *J Orthop Trauma*. 2018 Jun;32(6):e198-e203. doi: 10.1097/BOT.0000000000001150.
- 27) Ray R, Koohnejad N, Clement ND, Keenan GF. Ankle fractures with syndesmotic stabilisation are associated with a high rate of secondary osteoarthritis. *Foot Ankle Surg*. 2017 Oct 28. pii: S1268-7731(17)31304-8. doi: 10.1016/j.fas.2017.10.005. [Epub ahead of print]
- 28) Schepers T. Acute distal tibiofibular syndesmosis injury: a systematic review of suture-button versus syndesmotic screw repair. *Int Orthop*. 2012 Jun;36(6):1199-206. doi: 10.1007/s00264-012-1500-2. Epub 2012 Feb 9. Review.
- 29) Schepers T, Van Lieshout EM, de Vries MR, Van der Elst M. Complications of syndesmotic screw removal. *Foot Ankle Int*. 2011 Nov;32(11):1040-4.
- 30) Seitz WH Jr, Bachner EJ, Abram LJ, Postak P, Polando G, Brooks DB, Greenwald AS. Repair of the tibiofibular syndesmosis with a flexible implant. *J Orthop Trauma*. 1991;5(1):78-82.
- 31) Seyhan M1, Donmez F2, Mahirogullari M3, Cakmak S4, Mutlu S5, Guler O6. Comparison of screw fixation with elastic fixation methods in the treatment of syndesmosis injuries in ankle fractures. *Injury*. 2015 Jul;46 Suppl 2:S19-23. doi: 10.1016/j.injury.2015.05.027. Epub 2015 Jun 24.
- 32) Storey P, Gadd RJ, Blundell C, Davies MB. Complications of suture button ankle syndesmosis stabilization with modifications of surgical technique. *Foot Ankle Int*. 2012 Sep;33(9):717-21.
- 33) Swords MP, Sands A, Shank JR. Late Treatment of Syndesmotic Injuries. *Foot Ankle Clin*. 2017 Mar;22(1):65-75. doi: 10.1016/j.fcl.2016.09.005. Epub 2016 Dec 21. Review.
- 34) Van Heest TJ, Lafferty PM. Injuries to the ankle syndesmosis. *J Bone Joint Surg Am*. 2014 Apr 2;96(7):603-13. doi: 10.2106/JBJS.M.00094. Review.
- 35) Vopat ML, Vopat BG, Lubberts B, DiGiovanni CW. Current trends in the diagnosis and management of syndesmotic injury. *Curr Rev Musculoskelet Med*. 2017;10:94-103.
- 36) Walker L1, Willis N2. Weber C ankle fractures: a retrospective audit of screw number, size, complications, and retrieval rates. *J Foot Ankle Surg*. 2015 May-Jun;54(3):454-7. doi: 10.1053/j.jfas.2014.11.015. Epub 2015 Jan 22.
- 37) Walley KC, Hofmann KJ, Velasco BT, Kwon JY. Removal of Hardware After Syndesmotic Screw Fixation: A Systematic Literature Review. *Foot Ankle Spec*. 2017 Jun;10(3):252-257. doi: 10.1177/1938640016685153. Epub 2016 Dec 27. Review.
- 38) Weening B, Bhandari M. Predictors of functional outcome following transsyndesmotic screw fixation of ankle fractures. *J Orthop Trauma*. 2005 Feb;19(2):102-8.
- 39) Westermann RW, Rungprai C, Goetz JE, Femino J, Amendola A, Phisitkul P. The effect of suture-button fixation on simulated syndesmotic malreduction: a cadaveric study. *J Bone Joint Surg Am*. 2014 Oct 15;96(20):1732-8.
- 40) Willmott, HJ; Singh, B; David, LA: Outcome and complications of treatment of ankle diastasis with TightRope[®] fixation. *Injury*.40:1204–1206, 2009. <http://dx.doi.org/10.1016/j.injury.2009.05.008>

41) Xian H1, Miao J1, Zhou Q1, Lian K2, Zhai W2, Liu Q3. Novel Elastic Syndesmosis Hook Plate Fixation Versus Routine Screw Fixation for Syndesmosis Injury. *J Foot Ankle Surg.* 2018 Jan - Feb;57(1):65-68. doi: 10.1053/j.jfas.2017.08.007.

42) Zhang P, Liang Y, He J, Fang Y, Chen P, Wang J. A systematic review of suture-button versus syndesmotic screw in the treatment of distal tibiofibular syndesmosis injury. *BMC Musculoskelet Disord.* 2017 Jul 4;18(1):286. doi: 10.1186/s12891-017-1645-7. Review.

Intra- and interrater reliability of acute ligamentous ankle injuries on 3T MRI
KSSTA, Journal of Knee Surgery, Sports Traumatology and Arthroscopy
(in preparation for review, expected submission: September 2019)

Baltes T, Arnáiz J, Al-Naimi M, Al Sayrafi O, Geertsema C, Geertsema L,
D'Hooghe P, Kerkhoffs G, Tol J

ABSTRACT

Objectives:

To determine the diagnostic reliability of the Schneck grading system for acute ligamentous ankle injuries and the Sikka classification for acute syndesmotic injuries.

Methods:

All acute ankle injuries in adult athletes (>18 yrs), presenting to the outpatient department of a specialized Orthopaedic and Sports Medicine Hospital, within 7 days post-injury were screened for inclusion. Ankle injuries were excluded if imaging demonstrated a frank ankle fracture or if the 3Tesla MRI study could not be acquired within 10 days post-injury. Two radiologists graded the three major ligamentous complexes and their comprising individual ligaments according the four-grade Schneck grading system. Syndesmotic injuries were classified according the four-grade Sikka classification. Agreement and kappa (K) statistics were calculated to determine intra and inter-rater reliability.

Results:

Between September 2016 and September 2018, a total of 92 MR scans were obtained (87 patients). For the ligamentous complexes diagnostic reliability of the Schneck grading system was slight to almost perfect (K=0.14-0.89). Inter and intra-rater reliability of the Sikka classification ranged from moderate to almost perfect. (K=0.51-0.92). For the individual ligaments, kappa values ranged from poor to almost perfect (K -0.02-0.94).

Conclusions:

Grading of the three major ligamentous complexes according the Schneck grading system and classification of syndesmosis injury according the Sikka classification resulted in reasonable to good diagnostic reliability. The reliability of the Schneck grading system for injury of the individual ligaments was limited.

INTRODUCTION

Acute ankle sprains are among the most common sport-related injuries.¹ The lateral ankle ligaments are most frequently injured (0.93 /1000 h), followed by the syndesmosis (0.38 /1000 h) and deltoid ligaments (0.06 /1000 h).² In athletes, Magnetic Resonance Imaging (MRI) is increasingly used for initial diagnosis and prognosis of ligamentous ankle injuries.³⁻⁵

Diagnostic reliability of standardized grading systems for acute ligamentous ankle injuries have been described in various studies.⁶⁻⁸ However, only one grading system included grading of injury in multiple ligamentous complexes.⁹ In this study, two radiologists determined intra and inter-rater reliability of a five-grade system for acute and chronic ligamentous ankle injury, based on 30 MR scans [1.5 Tesla (T)].⁹ The main limitation in this study was that it reported diagnostic reliability per ligamentous complex (e.g. lateral ligaments) and not per individual ligament (e.g. ATFL), leaving diagnostic reliability of scoring acute injury of individual ankle ligaments on 3Tesla MRI unknown.

Prognostic scoring of syndesmosis injury has been evaluated in two previous studies.^{8,10} In a retrospective cohort study by Howard et al. prognostic scoring of syndesmosis injury in 16 NFL players resulted in fair to almost perfect inter-observer reliability. However, except for syndesmotic joint width, no association between prognostic scoring and time to return to play was established. Sikka et al. evaluated a prognostic syndesmosis injury classification in a retrospective cohort study on 36 NFL players with MRI-confirmed [1.5 Tesla] syndesmosis injury. The main limitation in this study was that it lacked evaluation of the classifications' inter-rater reliability.

Given these two limitations, a diagnostic reliability study on grading of the individual ankle ligaments, the ligamentous complexes and classification of syndesmotic injury severity is warranted.^{7,10} Therefore, the aim of this study was to determine the diagnostic reliability of the commonly used four grade system for the (1) three ligamentous ankle complexes (2) individual ankle ligaments and the (3) Sikka classification for syndesmosis injury.

METHODS

Patient selection

Patients presenting to the outpatient department of a specialized Orthopaedic and Sports Medicine Hospital within seven days after an acute ankle injury were asked to participate in this study. Inclusion criteria were: acute ankle injuries in adult athletes (>18 yrs), participating in sports at a professional or recreational level and presenting within 7 days of injury. Ankle injuries were excluded if imaging studies demonstrated a frank ankle fracture or if the 3Tesla MRI study could not be acquired within 10 days post-injury. After clinical history and physical examination was performed by a Sports Medicine Physician or

Orthopaedic Surgeon, MRI images were obtained. Ethical approval was acquired from the Anti-Doping Lab Qatar review board (IRB No. F2016000153). Written informed consent was obtained from all patients at time of inclusion.

Magnetic Resonance Imaging

All MR scans were obtained using a wide-bore 3.0-Tesla MRI system (GE Discovery, GE Healthcare) with an 8-channel receive only Foot & Ankle array (Invivo, Philips Healthcare, Best, The Netherlands). In the sagittal plane T1-weighted (repetition time [TR] 460-500ms; echo time [TE] 42ms; 3.0-mm slice thickness; 0.5-mm interslice gap; 416x288 pixel matrix; 2 excitations [NEX] 16 cm² field of view [FOV]; Echo train length [ETL] 3) and Proton Density Fat Saturated [PD-FS] (TR 2500-3000ms, TE 30ms, 3.0-mm slice thickness, 0.5-mm interslice gap; 352x526 pixel matrix; 2 NEX; 20 cm² FOV; ETL 8) sequences were obtained. In the axial plane T2-weighted (TR 6600-7000ms; TE 70ms; 3.5-mm slice thickness, 0.5-mm interslice gap; 320x224 pixel matrix; 2 NEX; 13 cm² FOV; ETL 16) and PD-FS (TR 2900-3500; TE 35ms; 3.5-mm slice thickness, 0.5-mm interslice gap; 320x224 pixel matrix; 2 NEX; 13 cm² FOV; ETL 6) sequences were acquired. In the coronal plane a PD FS (TR 2700-3000; TE 35ms; 3.5-mm slice thickness; 0.5-mm interslice gap; 320x224 pixel matrix; 2 NEX; 16 cm² FOV; ETL 6) sequence was obtained.

Standardized MRI grading

The MR scans were scored by two radiologists specialized in musculoskeletal radiology (J.A. & M.A.) with 11 and 3 years of experience in MSK-imaging, respectively. The two radiologists, hereafter referred to as R1 and R2, scored the lesions using a standardized scoring form. Prior to assessing the MR scans both radiologists participated in an individual familiarization session, followed by a joint calibration session. During a two-hour familiarization session, the use of the standardized score form was practiced, assessing 10 ankle MR scans that were not included in this data-set. To assure accurate interpretation of the scoring form during the calibration session consensus was reached on the scoring of another 10 ankle MR scans, not included in this data-set. To assure blinding of the radiologist to the clinical findings, the MR scans were scored in presence of a post-graduate medical researcher. In order to determine intra-rater reliability, one radiologist (R1) repeated the scoring process. To minimize recall bias, the radiologist repeated scoring after a period of 28 days.

Grading system for ligamentous complexes and individual ligaments

The ligamentous complexes were graded as normal (Grade 0) or in accordance with the highest graded acute lesion (Grade 1-3) in one of its comprising individual ligaments. All individual ligaments were graded according to the commonly used Schneck grading system.⁷ (Table 1)

Classification of syndesmotic injury

In patients with an observed syndesmotic injury, the severity of the syndesmotic injury was classified in accordance to the classification proposed by Sikka RS et al.¹⁰ (Table 1)

Table 1 Schneck grading system and Sikka classification for grading of the ligamentous complexes and individual ligaments

Schneck classification	
- Grade 0	No abnormality of ligament
- Grade 1	Peri-ligamentous high signal/edema on proton density-weighted sequences
- Grade 2	Partial discontinuity but preserved remnant fibers
- Grade 3	Complete discontinuity
Sikka classification*	
- Grade I	Isolated injuries to the AITFL
- Grade II	Injury to the AITFL, interosseous ligaments, and interosseous membrane
- Grade III	Grade III: Injury to the AITFL, interosseous ligament, interosseous membrane and PITFL
- Grade IV	Injury to the AITFL, interosseous ligament, interosseous membrane, PITFL and deltoid ligament.

* Ligamentous injury was defined as partial or complete tear of the respective ligament

Grading of ligamentous complexes

The three major ligamentous complexes (lateral ankle complex, deltoid complex [subdivided in deep deltoid and superficial deltoid] and syndesmosis complex) were graded according the four Grade grading system.

Grading of individual ligaments

The following individual ankle ligaments were graded according to the four Grade grading system:

- Lateral ligaments; including the anterior talofibular ligament [ATFL], calcaneofibular ligament [CFL] and posterior talofibular ligament [PTFL]
- Medial ligaments; subdivided in the superficial deltoid ligaments (tibionavicular [TN], tibiospring [TS], tibiocalcaneal [TC] and posterior tibiotalar [PT], respectively) and the ligaments comprising the deep portion of the deltoid (anterior tibiotalar [ATT] and posterior tibiotalar [PTT]).

- Syndesmosis ligaments; including the anteroinferior tibiofibular ligament [AITFL], interosseous ligament [IOL], interosseous membrane [IOM], posteroinferior tibiofibular ligament [PITFL] and transverse tibiofibular ligament [TTFL]

Presence versus absence of acute ligamentous lesions

To assess the intra- and inter-rater reliability for the presence or absence of acute ligamentous lesions in the ligamentous complexes and individual ligaments, the MRI grading system was evaluated as dichotomous outcomes;

- Grade 0: was considered absence of an acute lesion
- Grade 1-3: was considered presence of an acute lesion.

Presence versus absence of complete discontinuity:

To assess the intra- and inter-rater reliability for the presence or absence of complete discontinuity in the ligamentous complexes and individual ligaments, the MRI grading system was evaluated as dichotomous outcomes;

- Grade 0-2: was considered absence of complete discontinuity
- Grade 3: was considered as presence of complete discontinuity.

Statistical analysis

Descriptive statistics was used to present patient demographics (age, time to MRI, sports) and the number and distribution of lesions graded by the individual observers. Continuous variables were presented as mean with standard deviation for data with a normal distribution and as median with interquartile range (IQR) in case of non-normal distribution. Categorical data were presented as frequencies and proportions.

Intra- and inter-rater reliability of the Schneck grading system⁷ (ligamentous lesions; grade 0-3) and Sikka classification system¹⁰ (syndesmosis injury; Grade I-IV) were determined using linear weighted kappa statistics on an ordinal scale (K). Intra and inter-rater reliability for dichotomized data were determined using unweighted kappa statistics.

Overall agreement was calculated for dichotomous observations and weighted agreement was calculated for ordinal variables. We calculated prevalence (P) and bias index (BI) from cross tabulations for the dichotomous variables. Prevalence was defined as percentage (%) of included ankle injuries with

positive findings. Bias index was defined as the extent to which the radiologist disagreed on the proportion of positive (or negative) findings.¹¹

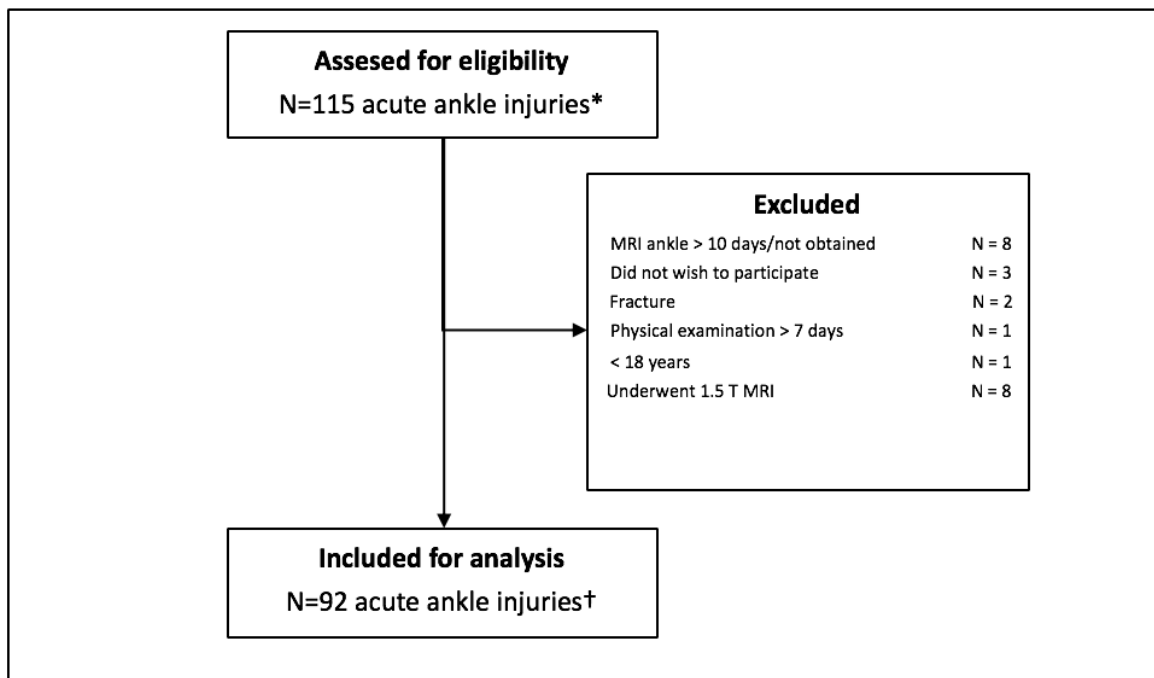
Reliability was considered poor if <0, slight 0–0.20, fair 0.21–0.40, moderate 0.41–0.60, substantial 0.61–0.80 and almost perfect if 0.81–1.00.¹² Statistical analysis was performed using Statistical Package for Social Sciences (SPSS version 21.0, Chicago, IL). Weighted agreement was calculated using Stata Statistical Software, Release 11 (College Station, TX; StataCorp LP).

RESULTS

Baseline characteristics

Between September 2016 and September 2018 a total of 115 acute ankle injuries (110 athletes) were assessed for eligibility. (Figure 1)

Figure 1 Flowchart



*In 110 athletes; † In 87 athletes

Ninety-two ankles were included. Of these 92 imaged acute ankle injuries, four were subsequent contra-lateral ankle injuries and one case of re-injury (>1 year). The median age at time of injury was 23 years (IQR 7), with a range from 18-42 years. The median time from injury to MRI was 3 days (IQR 4). Of the 87

included athletes, 47% played football, 14% volleyball, 14% basketball, 11% futsal, 5% athletics and 7% participated in other sports.

Grading of ligamentous complexes

The distribution of acute ligamentous complex lesions [Schneck grades 1-3] as graded by both radiologists, ranged from: lateral complex 72.8-87.0%; syndesmosis complex 18.5-68.5%; Deep deltoid complex 4.4-62.0%; Superficial deltoid complex 5.4-43.5%. (Table 2)

Table 2 Intra- and interrater reliability of grading ligamentous complexes and individual ligaments according to the four grade Schneck grading system and classification of syndesmosis injury according to the four grade Sikka classification system.

	Intra-rater					Inter-rater				
	N (lesions)		Kappa (95% CI)	Landis & Koch	Weighted Agreement	N (lesions)		Kappa (95% CI)	Landis & Koch	Weighted Agreement
	R1a	R1b				R1a	R2			
Schneck grading of ligamentous complexes										
Lateral complex	67	67	0.76 (0.65-0.86)	Substantial		67	80	0.47 (0.34-0.60)	Moderate	
Deltoid complex	10	8	0.51 (0.18-0.84)	Moderate		10	63	0.14 (0.04-0.24)	Slight	
- Superficial	5	6	0.65 (0.30-1.00)	Substantial		5	40	0.19 (0.03-0.35)	Slight	
- Deep	6	4	0.42 (-0.03-0.87)	Moderate		6	57	0.07 (-0.03-0.16)	Slight	
Syndesmosis complex	18	17	0.89 (0.80-0.99)	Almost perfect		18	63	0.37 (0.23-0.50)	Fair	
Sikka classification										
Syndesmosis	16	14	0.95 (0.90-1.01)	Almost perfect		16	42	0.51 (0.37-0.66)	Moderate	
Schneck grading of individual ligaments										
Lateral ankle ligaments										
- ATFL	66	67	0.73 (0.62-0.84)	Substantial		66	77	0.55 (0.43-0.68)	Moderate	
- CFL	46	46	0.62 (0.49-0.75)	Substantial		46	76	0.31 (0.20-0.41)	Fair	
- PTFL	2	0	N/A	N/A		2	25	0.14 (-0.05-0.33)	Slight	
Superficial deltoid ligaments										
- TN	4	5	0.56 (0.10-1.01)	Moderate		4	33	0.16 (0.02-0.30)	Slight	
- TS	5	5	0.69 (0.35-1.04)	Substantial		5	32	0.24 (0.06-0.42)	Fair	
- TC	3	2	0.32 (-0.19-0.83)	Fair		3	35	0.07 (-0.05-0.19)	Slight	
- PT	3	2	0.38 (-0.17-0.94)	Fair		3	25	0.01 (-0.08-0.10)	Slight	
Deep deltoid ligaments										
- ATT	6	3	0.48 (0.02-0.95)	Moderate		6	54	0.07 (-0.02-0.17)	Slight	
- PTT	2	3	0.27 (-0.20-0.74)	Fair		2	31	0.06 (-0.02-0.14)	Slight	
Syndesmosis ligaments										
- AITFL	18	17	0.89 (0.80-0.99)	Almost perfect		18	63	0.36 (0.22-0.49)	Fair	
- IOL	12	10	0.64 (0.43-0.86)	Substantial		12	26	0.56 (0.39-0.73)	Moderate	
- IOM	7	13	0.63 (0.40-0.87)	Substantial		7	17	0.53 (0.32-0.73)	Moderate	
- PITFL	10	9	0.94 (0.87-1.02)	Almost perfect		10	4	0.45 (0.16-0.75)	Moderate	
- TTFL	2	0	N/A	N/A		2	2	-0.02 (-0.04-0.00)	Poor	

Table 2. The total valid lesions for both radiologist (R1a, R1b R2) out of an overall total of 92 MR scans are presented (N). Reliability for grading (Schneck) and classification (Sikka) are presented as weighted-kappa (K) and weighted agreement. All values are presented with 95% confidence interval (95%CI); anterior talofibular ligament (ATFL); calcaneofibular ligament (CFL); posterior talofibular ligament (PTFL); tibionavicular (TN); tibiospring (TS); tibiocalcaneal (TC); posterior tibiotalar (PT); deep anterior tibiotalar (ATT); deep posterior tibiotalar (PTT); anteroinferior tibiofibular ligament (AITFL); interosseous ligament (IOL); interosseous membrane (IOM); posteroinferior tibiofibular ligament (PITFL); transverse tibiofibular ligament (TTFL); not applicable (N/A)

Intra and inter-rater reliability of the Schneck grading system for the three ligamentous complexes was respectively moderate to almost perfect (K= 0.51-0.89) and slight to moderate (K = 0.14-0.47).

Classification of syndesmotic injury

The distribution of the Sikka classification for both radiologists is reported in the supplementary appendix. (Table 2) Use of this classification system in patients with syndesmosis injury resulted in almost perfect intra-rater reliability ($k=0.95$) and moderate inter-rater reliability ($K=0.51$).

Grading of individual ligaments

The distribution of acute ligamentous lesions [Schneck Grades 1-3] per individual ligament, are graded by both radiologists. Grading of the individual lateral ankle ligaments resulted in substantial intra-rater reliability ($K=0.62-0.73$) and slight to moderate inter-rater reliability ($K=0.14-0.55$). For the individual syndesmosis ligaments intra-rater reliability ranged from substantial to almost perfect ($K=0.63-0.94$) and inter-rater reliability ranged from poor to moderate ($K=-0.02-0.56$). Intra-rater reliability for the deltoid ligaments ranged from fair to substantial ($K=0.27-0.69$) and inter-rater reliability ranged from slight to fair ($K=0.01-0.24$). Due to the low prevalence of PTFL and TTFL lesions, no intra-rater reliability could be established.

Presence versus absence of acute ligamentous lesions

Acute ligamentous lesions [Schneck Grades 1-3] were most frequently scored in the ATFL (71.7-83.7%), CFL (50.0-82.6%) and AITFL (18.5-68.5%). (Table 3)

Table 3 Dichotomization of Schneck grading system for (1) presence vs absence of acute lesions and (2) presence vs absence of complete discontinuity of the individual ankle ligaments.

	Intra-rater					Inter-rater				
	N (lesions)		Kappa (95% CI)	Landis. & Koch	Agreement	N (lesions)		Kappa (95% CI)	Landis. & Koch	Agreement
	R1a	R1b				R1a	R2			
Presence of acute ligamentous lesions^a										
<i>Lateral ankle complex</i>	67	67	0.73 (0.57-0.89)	Substantial	89.10%	67	80	0.31 (0.10-0.53)	Fair	77.20%
- ATFL	66	67	0.70 (0.54-0.87)	Substantial	88.00%	66	77	0.35 (0.14-0.57)	Fair	77.20%
- CFL	46	46	0.61 (0.45-0.77)	Substantial	80.40%	46	76	0.26 (0.11-0.41)	Fair	63.00%
- PTFL	2	0	N/A	N/A	97.80%	2	25	0.11 (-0.03-0.26)	Slight	75.00%
<i>Superficial deltoid complex</i>	5	6	0.52 (0.15-0.89)	Moderate	94.60%	5	40	0.14 (0.03-0.25)	Slight	62.00%
- TN	4	5	0.42 (0.00-0.83)	Moderate	94.60%	4	33	0.15 (0.02-0.29)	Slight	68.50%
- TS	5	5	0.58 (0.20-0.95)	Moderate	95.70%	5	32	0.20 (0.04-0.35)	Slight	70.70%
- TC	3	2	0.38 (-0.17-0.94)	Fair	96.70%	3	35	0.05 (-0.05-0.15)	Slight	63.00%
- PT	3	2	0.38 (-0.17-0.94)	Fair	96.70%	3	25	0.01 (-0.11-0.13)	Slight	71.70%
<i>Deep deltoid complex</i>	6	4	0.37 (-0.03-0.76)	Fair	93.50%	6	57	0.05 (-0.03-0.12)	Slight	42.40%
- ATT	6	3	0.42 (0.01-0.83)	Moderate	94.60%	6	54	0.06 (-0.02-0.14)	Slight	45.70%
- PTT	2	3	0.38 (-0.17-0.94)	Moderate	96.70%	2	31	0.08 (-0.03-0.19)	Slight	68.50%
<i>Syndesmosis complex</i>	18	17	0.82 (0.67-0.97)	Almost perfect	94.60%	18	63	0.17 (0.06-0.27)	Slight	48.90%
- AITFL	18	17	0.82 (0.67-0.97)	Almost perfect	94.60%	18	63	0.17 (0.06-0.27)	Slight	48.90%
- IOL	12	10	0.69 (0.46-0.92)	Substantial	93.50%	12	26	0.49 (0.29-0.69)	Moderate	82.60%
- IOM	7	13	0.67 (0.42-0.91)	Substantial	93.50%	7	17	0.53 (0.29-0.78)	Moderate	89.10%
- PITFL	10	9	0.94 (0.83-1.05)	Almost perfect	98.90%	10	4	0.54 (0.23-0.86)	Moderate	93.50%
- TTFL	2	0	N/A	N/A	97.80%	2	2	-0.02 (-0.04-0.00)	Poor	95.70%
Presence of complete discontinuity^b										
<i>Lateral ankle complex</i>	39	36	0.71 (0.56-0.85)	Substantial	85.90%	39	55	0.49 (0.33-0.66)	Moderate	73.90%
- ATFL	38	36	0.68 (0.53-0.84)	Substantial	84.80%	38	45	0.63 (0.47-0.79)	Substantial	81.50%
- CFL	17	9	0.56 (0.32-0.80)	Moderate	89.10%	17	49	0.29 (0.15-0.43)	Fair	63.00%
- PTFL	0	0	N/A	N/A	100.00%	0	0	N/A	N/A	100.00%
<i>Superficial deltoid complex</i>	1	1	1.00 (1.00-1.00)	Almost perfect	100.00%	1	5	0.32 (-0.16-0.80)	Fair	95.70%
- TN	1	1	1.00 (1.00-1.00)	Almost perfect	100.00%	1	3	-0.02 (-0.04-0.01)	Poor	95.70%
- TS	1	1	1.00 (1.00-1.00)	Almost perfect	100%	1	2	-0.02 (-0.04-0.01)	Poor	96.70%
- TC	0	0	N/A	N/A	100.00%	0	2	N/A	N/A	97.80%
- PT	0	0	N/A	N/A	100.00%	0	0	N/A	N/A	100.00%
<i>Deep deltoid complex</i>	2	1	0.66 (0.04-1.28)	Substantial	98.90%	2	5	-0.03 (-0.07-0.00)	Poor	92.40%
- ATT	2	1	0.66 (0.04-1.28)	Substantial	98.90%	2	5	-0.03 (-0.07-0.00)	Poor	92.40%
- PTT	0	0	N/A	N/A	100.00%	0	3	N/A	N/A	96.70%
<i>Syndesmosis complex</i>	13	12	0.95 (0.86-1.04)	Almost perfect	98.90%	13	14	0.87 (0.73-1.01)	Almost perfect	96.70%
- AITFL	13	12	0.95 (0.86-1.04)	Almost perfect	98.90%	13	13	0.91 (0.79-1.03)	Almost perfect	97.80%
- IOL	5	9	0.39 (0.05-0.72)	Fair	91.30%	5	12	0.43 (0.13-0.73)	Moderate	90.20%
- IOM	4	11	0.50 (0.19-0.81)	Moderate	92.40%	4	1	-0.02 (-0.05-0.01)	Poor	94.60%
- PITFL	0	1	N/A	N/A	98.90%	0	0	N/A	N/A	100.00%
- TTFL	1	0	N/A	N/A	98.90%	1	1	-0.01 (-0.03-0.00)	Poor	97.80%

Table 3. The total valid lesions for both radiologist (R1a, R1b R2) out of an overall total of 92 MR scans are presented (N). Reliability for grading (Schneck) dichotomized for the presence of acute lesions or complete discontinuity are presented as unweighted-kappa (K) and overall agreement. All values are presented with 95% confidence interval (CI); anterior talofibular ligament (ATFL); calcaneofibular ligament (CFL); posterior talofibular ligament (PTFL); tibionavicular (TN); tibiospring (TS); tibioalcaneal (TC); posterior tibiotalar (PT); deep anterior tibiotalar (ATT); deep posterior tibiotalar (PTT); anteroinferior tibiofibular ligament (AITFL); interosseous ligament (IOL); interosseous membrane (IOM); posteroinferior tibiofibular ligament (PITFL); transverse tibiofibular ligament (TTFL); not applicable (N/A)

Grading of the ATFL and CFL for acute lesions of the individual ligaments resulted in substantial intra-rater reliability (K=0.61-0.70) and fair inter-rater reliability (K=0.26-35), respectively. Almost perfect intra-rater reliability (K=0.82) and slight inter-rater reliability was observed for acute lesions of the AITFL (K=0.17). Intra and inter-rater reliability of the ligamentous complexes ranged from fair to almost perfect (K=0.37-0.82) and slight to fair (K=0.05-0.31).

Presence versus absence of complete discontinuity:

Complete ligamentous discontinuity [Schneck Grade 3] was scored most frequently in the ATFL (39.1-48.9%), CFL (9.8-53.3%) and AITFL (13.0-14.1%). (Table 3) Moderate to substantial intra-rater reliability was established for complete discontinuity of the ATFL and CFL (K=0.56-0.68) and inter-rater reliability ranged from fair to substantial (K=0.29-0.63). Almost perfect intra and

inter-rater reliability was observed for the AITFL ($K=0.91-0.95$). Due to the low prevalence of complete discontinuity, diagnostic reliability could not be established for some individual ligaments. ([Deltoid] TC, PT, PTT; [Syndesmosis] PITFL, TTFL; [Lateral] PTFL) Intra and inter-rater reliability of the ligamentous complexes ranged from substantial to almost perfect ($K=0.66-1.00$) and poor to moderate ($K=-0.03-0.87$).

DISCUSSION

In this study we reported the reliability of the commonly used Schneck grading system and the Sikka classification for acute ligamentous ankle injuries on 3Tesla MRI. Grading of the ligamentous complexes according the Schneck grading system and classification of syndesmosis injury according the Sikka classification resulted in reasonable to good reliability. Grading of the individual ankle ligaments according the Schneck grading system resulted in limited reliability. When dichotomized for the presence or absence of complete discontinuity, the inter-rater reliability of the ATFL and AITFL improved to substantial and almost perfect, respectively.

Grading of ligamentous complexes; comparison with previous literature

For grading of acute ligamentous complex injuries, only two previous studies have reported on the diagnostic reliability of a standardized grading approach.^{6,9} In a prospective study Gaebler et al. presented the diagnostic reliability of a grading approach to acute injury of the lateral ligamentous complex. Applied on 0.5 Tesla and 1.0 Tesla MRI, grading resulted in good intra-rater reliability ($\kappa = 0.65$) and fair inter-rater reliability ($\kappa = 0.40$).⁶ A more recent study by Roemer et al. reported perfect intra-rater reliability ($\kappa = 0.88$, $\kappa = 0.94$, $\kappa = 0.81$, respectively) and moderate to almost perfect inter-rater reliability ($\kappa = 0.85$, $\kappa = 0.90$, $\kappa = 0.41$, respectively) for grading of acute and chronic injury of the three ligamentous complexes, which is comparable to our findings.⁹

Grading of individual ligaments; comparison with previous literature

For grading of all the individual ankle ligaments, no comparable study on acute ankle injuries has been published. For the individual lateral ankle ligaments, one study investigated the reliability of 3Tesla MRI for acute injury of the ATFL.¹³ In this study the diagnostic accuracy and diagnostic reliability for addition of the 'bright-rim sign' to the standard diagnostic criteria of ATFL injury were

determined. Inter-rater reliability for acute injury of the ATFL varied widely, depending on the applied definition ($\kappa = 0.48\text{--}0.93$).

In chronic lateral ankle ligament injuries, two studies have investigated the reliability of scoring injury to the ATFL.^{14,15} Kim et al reported excellent inter-rater reliability (ICC=0.915) for detection of presence or absence of injury to the ATFL.¹⁴ In contrast to our study, no grading of injury severity was applied. In another study grading of chronic injury was reported in a cohort of patients with chronic lateral ankle instability.¹⁵ Grading on a four-grade scale for chronic injury resulted in substantial intra-rater reliability (K 0.68-0.75) and moderate to almost perfect inter-rater reliability (K 0.55-0.87).

For acute deltoid injury the inter-rater reliability on 3Tesla MRI has been reported in one study.¹⁶ In this study diagnostic reliability of MRI was investigated in a cohort of patients with lateral malleolar fractures secondary to a Supination-External Rotation trauma.

The inter-rater reliability for partial and complete discontinuity of the deep deltoid ligaments ranged from fair to moderate ($k = 0.46$; $k = 0.22$), which is better than observed in our cohort. In addition, the increased prevalence of deltoid injury in this cohort could potentially have decreased the reported kappa-values.¹¹

For syndesmotic injuries, three previous studies have reported on diagnostic reliability of MRI.^{8,17,18} The main difference with our population is that these studies only included patients with MRI-confirmed syndesmosis injury or with acute ankle fractures and thus an increased prevalence. As increased prevalence comes with high chance agreement, the reported kappa values for syndesmotic injury might be lower than the true kappa value in a non-selected population.¹¹

In the study by Hermans et al. patients with an acute ankle fracture underwent 1.5 Tesla MRI.¹⁷ Grading of acute syndesmosis injury demonstrated substantial and almost perfect inter-observer reliability for the AITFL (K=0.61) and PITFL (K=0.83). Addition of a 45° oblique MRI-plane improved the inter-rater reliability for the AITFL to almost perfect (K=0.92). As our multi-plane MRI-sequence lacked such a plane, the addition could hypothetically further improve the diagnostic reliability for low-grade injuries of the AITFL.

Presence versus absence of complete discontinuity:

In daily clinical practice the presence of peri-ligamentous oedema or partial discontinuity is less consequential, as the decision for surgical intervention is

based on the presence of complete ligamentous discontinuity.^{19,20} Simplified scoring for the presence of complete discontinuity or acute lesions might therefore be more clinically relevant in this setting. Therefore, the four grade Schneck grading was dichotomized for presence of acute lesions and presence of complete discontinuity. This resulted in improved inter-rater reliability for complete discontinuity of the ATFL (substantial) and AITFL (almost perfect). As complete discontinuity of these two ligaments has major ramifications in selected patients (e.g. athletes), the improved reliability of dichotomized grading might be preferential in the clinical setting.

Strength and Limitations

To our knowledge this study is the largest prospective cohort study on diagnostic reliability of grading acute injuries of all three ligamentous complexes. Its strength lies in its prospective design, broad inclusion criteria (all acute ankle injuries) and use of 3Tesla MRI. Despite these facts the study has some limitations. First, the reported reliability of the deltoid ligaments and posterior syndesmosis ligaments (PITFL and TTFL) should be interpreted with caution as the low prevalence of injury potentially influenced the k-values and corresponding confidence intervals.¹¹ An even larger cohort of athletes might improve the obtained k-values and narrow the confidence interval further. Secondly, although discrepancies in MRI grading are inherent, considerable bias was observed for the dichotomization strategy in which ligaments were graded either normal (Grade 0) or as having an acute lesion (Grade 1-3). The bias indices normalized for the dichotomization strategy in which ligaments were either not completely discontinuous (Grade 0-2) or completely discontinuous (Grade 3).

This suggests a bias of the second radiologist towards scoring low-grade injuries. Potentially, increased inter-rater reliability could have been achieved with a more elaborate calibration session. However, the limited calibration of both radiologists should be considered a strength of this study, as it represents daily clinical practice.

Future research should aim to correlate grading of injury severity with return to play prognosis after acute ligamentous ankle injuries. Application of the current available grading systems on 3Tesla MRI is insufficiently reliable for this purpose. Dichotomized scoring for complete discontinuity of ankle ligaments and additional (angulated) MR-planes could potentially improve inter-rater reliability, however additional research is required to substantiate these claims.

Implications for clinical practice

Scoring of acute ligamentous complex injury according the Schneck grading system and syndesmosis injury according the Sikka classification resulted in reasonable to good diagnostic reliability. Despite poor reliability for grading of the individual ligaments, complete discontinuity of the ATFL and AITFL could be determined with high reliability. Therefore, the use of MRI in the diagnosis of acute ligamentous ankle injuries can be advised in those patients with increased suspicion of syndesmosis injury.

CONCLUSION

In athletes, grading of the three major ligamentous complexes according the Schneck grading system and classification of syndesmosis injury according the Sikka classification resulted in reasonable to good diagnostic reliability. Using 3T MRI the diagnostic reliability of the Schneck grading system for injury of the individual ligaments was limited.

REFERENCES

1. Fong DT-P, Hong Y, Chan L-K, et al (2007) A systematic review on ankle injury and ankle sprain in sports. *Sports Med* 37:73–94
2. Doherty C, Delahunt E, Caulfield B, et al (2014) The Incidence and Prevalence of Ankle Sprain Injury: A Systematic Review and Meta-Analysis of Prospective Epidemiological Studies. *Sport Med* 44:123–40
3. Oae K, Takao M, Naito K, et al (2003) Injury of the tibiofibular syndesmosis: value of MR imaging for diagnosis. *Radiology* 227:155–61.
4. Takao M, Ochi M, Oae K, et al (2003) Diagnosis of a tear of the tibiofibular syndesmosis. The role of arthroscopy of the ankle. *J Bone Joint Surg Br* 85:324–9.
5. Oae K, Takao M, Uchio Y, et al (2010) Evaluation of anterior talofibular ligament injury with stress radiography, ultrasonography and MR imaging. *Skeletal Radiol* 39:41–7.
6. Gaebler C, Kukla C, Breitenseher MJ, et al (1997) Diagnosis of lateral ankle ligament injuries. Comparison between talar tilt, MRI and operative findings in 112 athletes. *Acta Orthop Scand* 68:286–90.
7. Schneck CD, Mesgarzadeh M, Bonakdarpour A (1992) MR imaging of the most commonly injured ankle ligaments. Part II. Ligament injuries. *Radiology* 184:507–12.
8. Howard DR, Rubin DA, Hillen TJ, et al (2012) Magnetic resonance imaging as a predictor of return to play following syndesmosis (high) ankle sprains in professional football players. *Sports Health* 4:535–43.
9. Roemer FW, Jomaah N, Niu J, et al (2014) Ligamentous Injuries and the Risk of Associated Tissue Damage in Acute Ankle Sprains in Athletes. *Am J Sports Med* 42:1549–57.
10. Sikka RS, Fetzer GB, Sugarman E, et al (2012) Correlating MRI findings with disability in syndesmotic sprains of NFL players. *Foot Ankle Int* 33:371–8.
11. Sim J, Wright CC (2005) The kappa statistic in reliability studies: use, interpretation, and sample size requirements. *Phys Ther* 85:257–68.
12. Landis JR, Koch GG (1977) The measurement of observer agreement for categorical data. *Biometrics* 33:159–74.

13. Lee MH, Cha JG, Lee YK, et al (2012) The bright rim sign on MRI for anterior talofibular ligament injury with arthroscopic correlation. *AJR Am J Roentgenol* 198:885–90.
14. Kim YS, Kim YB, Kim TG, et al (2015) Reliability and Validity of Magnetic Resonance Imaging for the Evaluation of the Anterior Talofibular Ligament in Patients Undergoing Ankle Arthroscopy. *Arthroscopy* 31:1540–7.
15. Morvan A, Klouche S, Thes A, et al (2018) Reliability and validity of preoperative MRI for surgical decision making in chronic lateral ankle instability. *Eur J Orthop Surg Traumatol* 28:713–9.
16. Nortunen S, Lepojärvi S, Savola O, et al (2014) Stability assessment of the ankle mortise in supination-external rotation-type ankle fractures: lack of additional diagnostic value of MRI. *J Bone Joint Surg Am* 96:1855–62.
17. Hermans JJ, Beumer A, Hop WCJ, et al (2012) Tibiofibular syndesmosis in acute ankle fractures: additional value of an oblique MR image plane. *Skeletal Radiol* 41:193–202.
18. Muratli HH, Biçimoğlu A, Celebi L, et al (2005) Magnetic resonance arthrographic evaluation of syndesmotic diastasis in ankle fractures. *Arch Orthop Trauma Surg* 125:222–7.
19. McCollum GA, van den Bekerom MPJ, Kerkhoffs GMMJ, et al (2013) Syndesmosis and deltoid ligament injuries in the athlete. *Knee Surg Sports Traumatol Arthrosc* 21:1328–37.
20. Vuurberg G, Hoorntje A, Wink LM, et al (2018) Diagnosis, treatment and prevention of ankle sprains: update of an evidence-based clinical guideline. *Br J Sports Med* 52:956.

MRI of Acute Ankle Sprain: The Association between Joint Effusion and Structural Injury Severity in a Large Cohort of Athletes

European Radiology Journal (2019)

Crema M, Krivokapic B, Gravidovic P, Popovic N, D'Hooghe P, Roemer F

MRI of ankle sprain:

the association between joint effusion and structural injury severity in a large cohort of athletes.

Crema MD, Krivokapic B, Guermazi A, Gravidovic P, Popovic N, D'Hooghe P, Roemer FW

Eur Radiol. 2019 Apr 1. doi: 10.1007/s00330-019-06156-1. [Epub ahead of print]

ABSTRACT

Objective:

To test the hypothesis if presence and amount of effusion in the tibiotalar and talocalcaneal joints are associated with an increased risk for severe structural injury in ankle sprains.

Methods:

A total of 261 athletes sustaining acute ankle sprains were assessed on MRI for the presence and the amount of joint effusion in the tibiotalar and talocalcaneal joints, as well as for ligamentous and osteochondral injury. Specific patterns of injury severity were defined based on lateral collateral ligament, syndesmotic, and talar osteochondral involvement. The presence and the amount effusion (Grades 1 and 2) were considered as risk factors for severe injury, while physiological amount of fluid (Grade 0) was considered as the referent. Conditional logistic regression was used to assess the risk for associated severe injuries (syndesmotic ligament rupture and talar osteochondral lesions) based on the presence and amount of tibiotalar and talocalcaneal effusions.

Results:

For ankles exhibiting large (Grade 2) effusion in the tibiotalar joint (without concomitant Grade 2 effusion in the talocalcaneal joint), the risk for partial or complete syndesmotic ligament rupture was increased more than eightfold (adjusted odds ratio 8.7 (95% confidence intervals 3.7–20.7); $p < 0.001$). The presence of any degree of effusion in any of the joints was associated with an increased risk for severe talar osteochondral involvement (several odds ratio values reported; $p < 0.001$), including large subchondral contusions and any acute osteochondral lesion.

Conclusion:

The presence of tibiotalar and talocalcaneal effusions is associated with an increased risk for severe concomitant structural injury in acute ankle sprains.

INTRODUCTION

Ankle sprain is one of the most frequent sports injuries among athletes. The inversion mechanism of sprain is by far the most common, frequently leading to lateral collateral ligament injury and potentially additional associated structural damage¹⁻⁶. The reference standard for the diagnosis of ankle sprain is physical

examination combined with radiographic assessment according to the Ottawa rules in order to exclude an associated fracture and to evaluate mortise alignment⁶⁻⁸.

Concomitant structural injuries associated with lateral collateral ligament sprain are not rare and may have impact on the prognosis, such as syndesmotic injuries, or osteochondral lesions. A timely diagnosis is crucial as untreated structural damage may lead to chronic instability of the ankle joint, especially in cases of high-grade collateral ligament and/or syndesmotic injury^{9,10}.

Ultrasound and magnetic resonance imaging (MRI) are able to assess ligamentous integrity after acute ankle sprains¹¹. Compared with MRI, ultrasound is widely available and cost-efficient, allowing for dynamic assessment of ligamentous structures of the ankle, including the syndesmosis. However, MRI performs better than ultrasound for the detection of deep soft-tissue and osteochondral involvement potentially associated with ankle sprain¹¹.

Joint effusion in the tibiotalar and talocalcaneal joints is frequently detected in association with acute ankle sprain^{12,13} and may be easily detected and quantified using both ultrasound and MRI¹³.

Assumingly, a larger amount of joint effusion would potentially reflect a more severe structural injury. However, there is no strong evidence that the presence and the amount of effusion detected after acute ankle sprain are associated with structural injury severity.

In a large retrospective cohort of athletes having sustained an acute ankle sprain assessed on MRI, we aimed to evaluate the cross-sectional associations of the presence and amount of effusion in the tibiotalar and talocalcaneal joints with the severity of injuries including collateral ligament complex, syndesmotic, and bony injuries, as well as osteochondral lesions.

We hypothesized that increasing amounts of joint effusion are associated with more severe structural injury in athletes with acute ankle sprain.

METHODS

Study population and design Ethical approval was obtained from the local Institutional Review Board (Anti-Doping Lab Qatar, IRB No. EX2013000001), which waived informed consent due to the retrospective nature of the study. Participants were professional athletes registered in the National Sports Medicine Program (NSMP) of the State of Qatar, a centralized organization responsible for medical diagnoses and treatment of professional athletes from several sports competing in the highest national leagues who are registered in

sports clubs in Qatar. Athletes in the NSMP may be clinically evaluated at the club level by a sports medicine physician or may be directly referred to a specialized secondary referral sports medicine center for injury assessment.

Included in this study were all NSMP athletes referred for an ankle MRI after sustaining an acute ankle sprain during training or competition between 1 and 30 days before the MRI examination. The large majority of athletes included were football (soccer) players. Reasons for referral were not uniform, with the most common reasons for MRI being suspected lateral collateral ligament injury, syndesmotic injury, or acute osteochondral lesions.

For the period of January 1, 2009, until December 31, 2012, we retrospectively searched for ankle MRI examinations of athletes in the hospital picture archiving and communication system. The search yielded 697 MRI scans of the ankle. Further, referral forms were searched for the terms acute ankle sprain, twisting injury, sprain, syndesmosis, lateral ligaments, and ligament tear. We then identified 297 MRI scans of 261 athletes based on these criteria. If an athlete had more than one MRI scan, only the baseline scan was included, which left 261 MRI scans of the ankle joint finally included in our study.

When the exact time interval from ankle sprain to MRI was not recorded, the occurrence of recent sprain was verified by the referral form, which had to include the terms acute or recent and trauma or sprain.

MRI acquisition

All MRI scans were obtained with a 1.5-Tesla large-bore MRI system (Espree, Siemens Healthineers), with a circumferential 8-channel extremity coil, using fat-suppressed, turbo spin echo, proton density-weighted sequences in the sagittal (repetition time [TR], 2330 ms; echo time [TE], 32 ms; 3-mm slice thickness; 0.6-mm interslice gap; 22 slices; 320 × 224-pixel matrix; 2 excitations [NEX]; 15.9-cm² field of view [FOV]; echo train length [ETL], coronal (TR, 2860 ms; TE, 32 ms; 3-mm slice thickness; 0.8-mm interslice gap; 27 slices; 320 × 224-pixel matrix; 2 NEX; 14.0-cm² FOV; ETL, and axial (TR, 2990 ms; TE, 35 ms; 4-mm slice thickness; 0.8-mm interslice gap; 26 slices; 320 × 224-pixel matrix; 2 NEX; 14.0-cm² FOV; ETL planes. In addition, sagittal (TR, 493 ms; TE, 14 ms; 3-mm slice thickness; 0.6-mm interslice gap; 22 slices; 3,203, 224-pixel matrix; 1 NEX; 15.9-cm² FOV; ETL, 1) and axial (TR, 583 ms; TE, 14 ms; 4-mm slice thickness; 0.8-mm interslice gap; 26 slices; 320 × 224-pixel matrix; 1 NEX; 14.0-cm² FOV; ETL, 1) T1-weighted sequences were acquired.

MRI interpretation

The MRI scans were read by a single musculoskeletal radiologist, with 15 years of experience in grading musculoskeletal MRI scans in a research context, on a high-resolution workstation using eFilm software (eFilm workstation v 3.4, Merge Healthcare).

The MRI scans were read blinded for referral and clinical reports. Inter-observer and intra-observer reliability was assessed using 30 randomly chosen MRI scans. Inter-observer reliability readings were performed by a second experienced musculoskeletal radiologist with 22 years of experience in standardized semiquantitative MRI assessment.

Intra-observer reliability was tested using the same 30 MRIs after an interval of 6 weeks to avoid recognition bias. Prior to the inter-observer reliability readings performed by the second radiologist, a 4-h calibration session between both readers was conducted using a different set of 20 MRI scans (not included in this cohort).

The following structures were assessed using consensus definitions that were developed based on the existing literature and during calibration between the two readers as described above¹²:

All ligamentous structures were graded as normal (Grade 0), as a low-Grade sprain (grade 1 = periligamentous high signal/edema on fat-suppressed proton density-weighted sequences and no discontinuity of fibers), as partial disruption (Grade 2 = partial discontinuity but preserved remnant fibers), as complete disruption (Grade 3 = complete discontinuity), and as scar tissue (Grade 4 = thinned or thickened ligament without discontinuity or periligamentous edema)^{14,15}.

Ligaments assessed included the lateral collateral ligament complex (anterior talofibular (ATFL), calcaneofibular (CFL), and posterior talofibular (PTFL) ligaments assessed separately), the syndesmotic ligaments (anterior-inferior tibiofibular ligament, posterior-inferior tibiofibular ligament, transverse tibiofibular ligament, and interosseous membrane assessed separately), the medial collateral (deltoid) ligament complex (scored separately for superficial and deep portions), the spring ligament complex (scored separately for inferopltar longitudinal, mediopltar oblique, and superomedial), and the sinus tarsi ligaments (scored separately for the interosseous talocalcaneal and cervical ligaments).

Bone structures excluding the talus, that is, the fibula, tibia, calcaneus, navicular, and other, were assessed for injury using both T1-weighted and fat-suppressed proton density-weighted sequences as 0 = normal, 1 = contusion (bone edema without a fracture line), and 2 = fracture.

Talar osteochondral involvement was assessed mainly using coronal and sagittal fat-suppressed proton density weighted sequences as 0 = normal, 1 = small subchondral edema only, 2 = large subchondral edema only, 3 = acute osteochondral lesion with intact cartilage, 4 = acute osteochondral lesion with cartilage injury, and 5 = chronic osteochondral lesion.

Small talar contusions were defined as being restricted to only one part of the talus, that is, the body, neck, or head. Large talar contusions were defined as involving at least two regions of the talus. Both definitions excluded contusions of the talar dome adjacent to the subchondral plate, which were scored as an osteochondral lesion without surface damage (as Grade 3 lesions and not as Grade 1 or 2 lesions).

Acute osteochondral talar lesions were defined as areas of diffuse hyperintensity of the lateral talar dome directly adjacent to the subchondral plate on proton density-weighted sequences with or without cartilage surface damage.

A chronic osteochondral lesion was defined as a well-demarcated or partially cystic lesion in the same location with or without surrounding edema¹⁶.

Finally, the presence and amount of effusion in the tibiotalar and talocalcaneal joints were scored separately using sagittal fat-suppressed proton density-weighted, from 0 to 2, according to the amount of capsular distension: Grade 0 = minimal physiological amounts of intra-articular fluid (normal); Grade 1 = effusion with less than 50% of maximum capsular distension; Grade 2 = effusion with $\geq 50\%$ of maximum capsular distension (Figs. 1, 2, and 3).

Statistical analysis

Conditional logistic regression analysis was performed to assess the risk for different patterns of ligament injury severity after ankle sprain in regard to the different Grades of pathological effusion (Grades 1 and 2) in the tibiotalar and talocalcaneal joints, using Grade 0 (minimal physiological effusion) as the reference.

Three different ligament injury severity patterns were defined taking into account the scoring of Grades as described in the Methods section: ankles with no acute injury (Grades 0, 1, or 4, assuming functional stability of scar tissue/Grade 4 lesions) or only low-Grade acute injury (Grade 2) involving lateral collateral ligaments and no syndesmotic injury; (C2) ankles with complete ATFL injuries (Grade 3) but no syndesmotic injury; and (C3) ankles with any syndesmotic injury. Any syndesmotic injury was defined as partial (Grade 2) or complete (Grade 3) disruption of one of the four structures assessed. Furthermore, the same analysis was applied to specifically assess the risk for severe ligamentous and osteochondral injuries in regard to the different grades of pathological effusion.

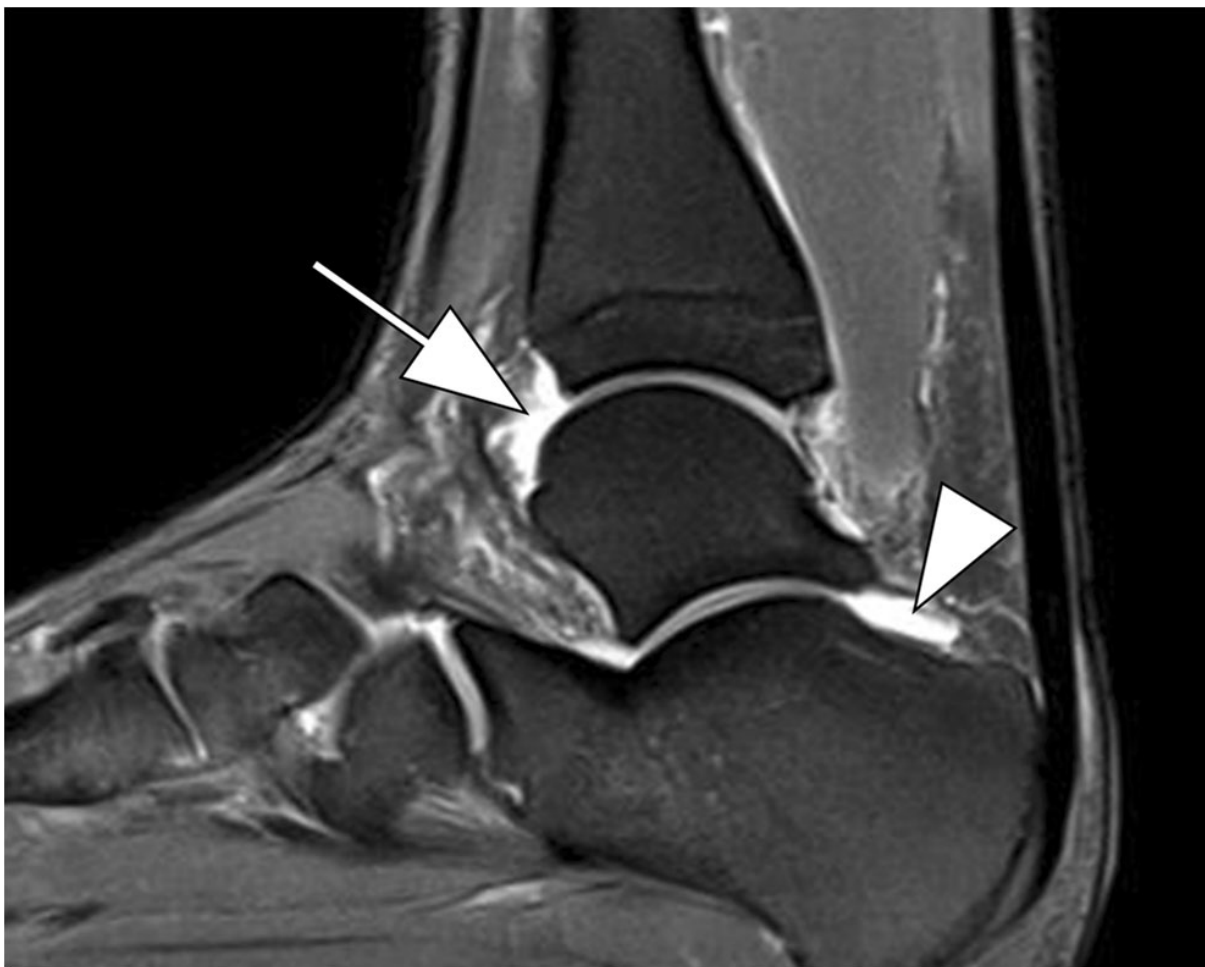

Figure 1. Sagittal fat-suppressed proton density-weighted MRI shows Grade 1 effusion in the tibiotalar (arrow) and the talocalcaneal (arrowhead) joints

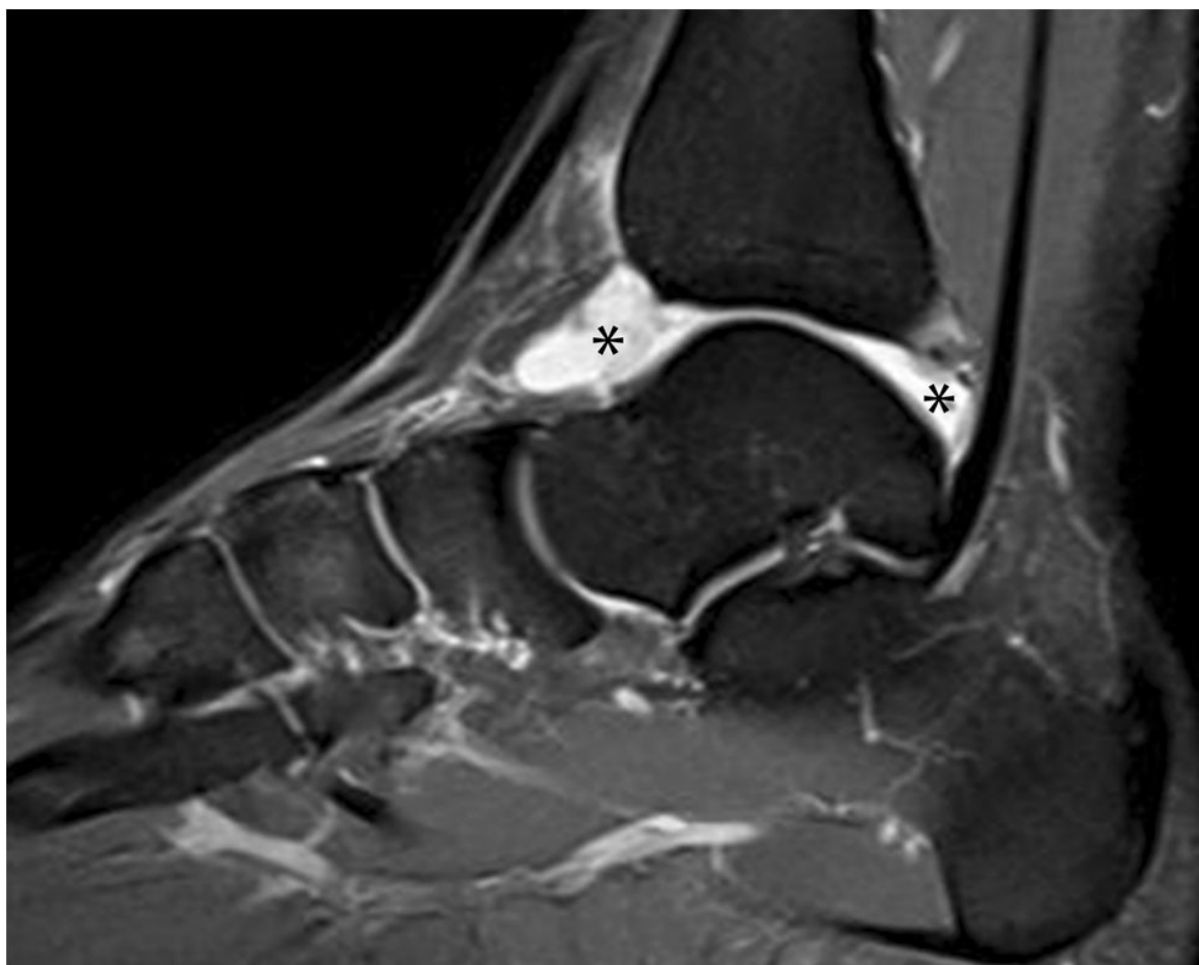


Figure 2. Sagittal proton density-weighted MRI shows Grade 2 effusion in the tibiotalar joint (*)

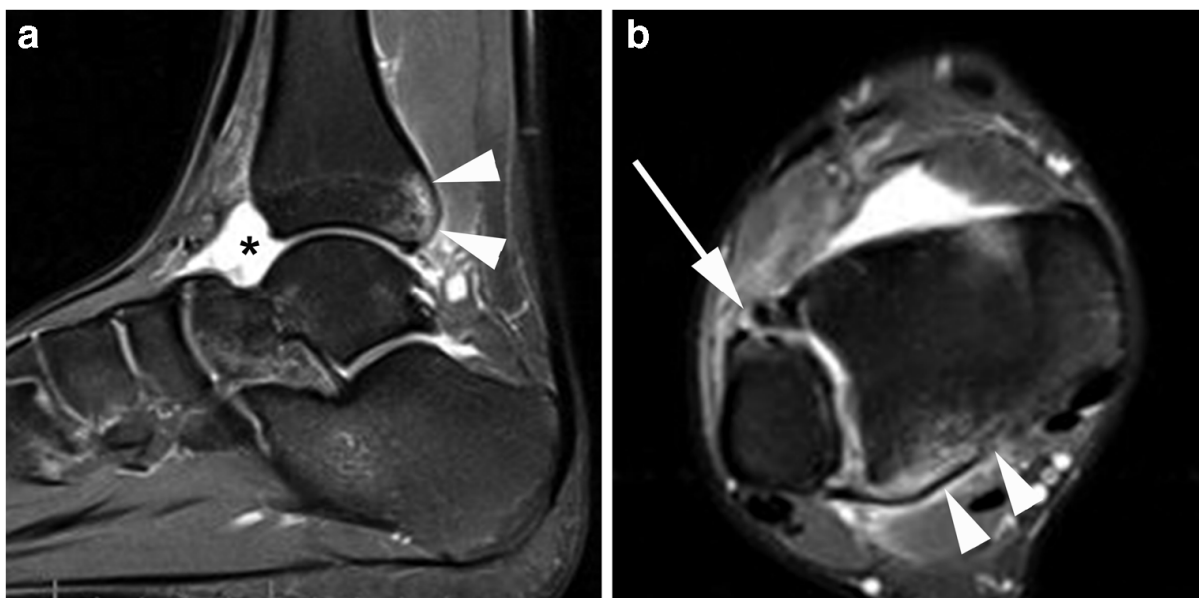


Figure 3. Acute syndesmotic injury after ankle sprain. a Sagittal fat-suppressed proton density-weighted image shows Grade 2 effusion in the talocalcaneal joint (*). Note the presence of traction bone marrow edema at the tibial insertion of the posterior-inferior tibiofibular ligament (arrowheads). b Axial fat-suppressed proton density-weighted image shows complete rupture of the anterior-inferior tibiofibular ligament (arrow) associated

with traction bone marrow edema at the tibial insertion of the posterior-inferior tibiofibular ligament (arrowheads)

(tibiotalar and talocalcaneal), four different patterns of effusion were evaluated as factors for injury severity: (P1) grade 0 or 1 effusion in both joints; (P2) grade 2 effusion in the tibiotalar joint only; (P3) grade 2 effusion in the talocalcaneal joint only; (P4) grade 2 effusion in both tibiotalar and talocalcaneal joints.

P1 was considered the reference standard when assessing the associations with ligament injury severity patterns. We additionally assessed the diagnostic performance of the presence of Grade 2 effusion in both joints (P4) for the detection of ankles exhibiting syndesmotic ligament injury (C3), the highest ligament injury severity considered in this study.

Finally, we considered two groups of talar osteochondral involvement for the analyses: T1-mild, including grades 1 and 2 (normal or small subchondral edema only) and T2- severe, including grades 3 to 5 (large subchondral edema only or any acute osteochondral lesion).

Reliability was assessed using weighted kappa statistics and overall percentage agreement. The Fisher exact test was applied to assess differences in the injury severity patterns based on age and sex. All analyses were performed using SAS software (version 9.3 for Windows, SAS Institute). We considered a two-tailed p value < 0.05 as statistically significant.

RESULTS

A total of 261 ankles of 261 patients were included. The athletes' characteristics were previously described in detail¹². Briefly, athletes included were on average 22.5 ± 4.9 years old (range 14–39 years), 88.1% were male athletes ($n = 230$) and 84.7% were registered with a football (soccer) club ($n = 221$). The average time from injury to MRI was 5.7 ± 4.8 days (range, 1– 26 days) for 214 athletes. For the remaining 47 athletes, the exact interval from ankle sprain to MRI was not recorded. The distribution of the different injury patterns in regard to age and sex is detailed in Table 1.

There were no significant differences in frequencies of the injury patterns for age or sex. When applying kappa statistics, intra-reader reliability ranged from 0.67 (sinus tarsi) to 1.00 (retinacula, bone, and tendons), whereas inter-reader

reliability ranged from 0.00 (retinacula) to 0.90 (syndesmosis). As some of the features were rare with regard to frequency, we also assessed overall percentage agreement, which ranged from 78.3% (effusion) to 100.0% (retinacula, bone, and tendons) for intra-reader reliability and from 68.3% (deltoid) to 98.9% (retinacula) for inter-reader reliability.

Some athletes had spring ligament injuries (3.8%) and sinus tarsi ligament involvement (16.1%). Retinaculum and tendon injuries were rare (1.1% and 1.5%, respectively). Ninety-two (35.2%) ankles had either partial or complete disruption (Grade 2 or 3) of the deep, superficial, or both parts of the deltoid ligament complex. Including low-Grade (Grade 1) injuries, (49.0%) ankles had suffered a deltoid ligament injury.

Patterns of joint effusion and ligament injury severity

The associations between the different patterns of joint effusion and injury severity are presented in Table 2.

The presence of severe (Grade 2) effusion in the tibiotalar joint only (without a concomitant Grade 2 effusion in the talocalcaneal joint) was associated with an increased risk for exhibiting partial or complete syndesmotic injury (adjusted odds ratio (aOR) = 8.7 (95% confidence intervals [CI] 3.7, 20.7); $p < 0.001$) regardless of the grade of concomitant lateral ligament injury.

A Grade 2 effusion in both joints was associated with an increased risk for exhibiting complete ATFL rupture without syndesmotic injury (aOR = 4.0; $p < 0.001$; Table 2). Furthermore, a Grade 2 effusion in the talocalcaneal joint only (without a concomitant Grade 2 effusion in the tibiotalar joint) was associated with an increased risk for exhibiting both complete ATFL rupture without syndesmotic injury (aOR = 4.1; $p < 0.001$) and partial or complete syndesmotic injury (aOR = 2.7; $p < 0.01$) (Table 2).

When considering each joint separately (tibiotalar and talocalcaneal), the associations of small (grade 1) and large (Grade 2) effusions with injury severity patterns are presented in Table 3. Compared with the reference (Grade 0 effusion), Grade 1 and 2 effusions in each joint separately were significantly associated with an increased risk for exhibiting a complete ATFL rupture without syndesmotic injury as well as partial or complete syndesmotic injury, except for the relationship between grade 2 effusion in the talocalcaneal joint and partial or complete syndesmotic injury ($p = 0.42$). The detection of grade 2 effusion in both tibiotalar and talocalcaneal joints exhibited 9.1% (95% CI 3.4,

20.7) sensitivity, 87.4% (95% CI 81.9, 91.4) specificity, 16.1% (95% CI 6.1, 34.5) positive predictive value (PPV), and 78.3% (95% CI 72.3, 83.3) negative predictive value (NPV) in the detection of syndesmotic ligament injuries.

Joint effusion and talar osteochondral involvement

The associations of Grades of effusion (1 and 2) with severity of talar osteochondral involvement are presented in Table 4.

The presence of Grade 1 or 2 effusions in the tibiotalar joint was associated with an increased risk for exhibiting large subchondral talar contusions or any acute talar osteochondral lesion (aORs of 3.7 and 2.5, respectively; $p < 0.001$). Also, the presence of Grade 1 or 2 effusions in the talocalcaneal joint was associated with an increased risk for exhibiting large subchondral talar contusions or any acute talar osteochondral lesion (aORs of 3.5 and 3.9, respectively; $p < 0.001$).

Table 1 Distribution of patterns of ligament injury according to age and gender

Injury pattern	No. of ankles	Gender		Age range					
		Male	Female	13–16	17–20	21–24	25–28	29–32	> 32
C1	105	90 (85.7%)	15 (14.3%)	11 (10.5%)	25 (23.7%)	26 (24.8%)	28 (26.7%)	11 (10.5%)	4 (3.8%)
C2	103	90 (87.4%)	13 (12.6%)	8 (7.8%)	36 (34.9%)	26 (25.3%)	24 (23.3%)	7 (6.8%)	2 (1.9%)
C3	53	50 (94.3%)	3 (5.7%)	6 (11.3%)	17 (32.1%)	15 (28.3%)	8 (15.1%)	5 (9.4%)	2 (3.8%)
Total	261	230 (88.1%)	31 (11.9)	25 (9.6%)	78 (29.9%)	67 (25.7%)	60 (23.0%)	23 (8.8%)	8 (3.1%)
<i>p</i> value from Fisher's exact test		0.809		0.760					

(C1) ankles with no or only low-grade lateral ligament injuries and no syndesmotic damage; (C2) ankles with complete ATFL injuries but no syndesmotic involvement; and (C3) ankles with partial or complete syndesmotic disruption

Table 2 Association of patterns of joint effusion in the tibiotalar and/or talocalcaneal joints with patterns of ligament injury

Joint effusion	No. of ankles N=261 (100%)	Ligament injury pattern		
		C1	C2	C3
P1	137 (52.5%)	67 (25.7%)	47 (18%)	23 (8.8%)
OR		1.0 (ref.)	1.0 (ref.)	1.0 (ref.)
P2	31 (11.9%)	10 (3.8%)	9 (3.5%)	12 (4.6%)
OR (95% CI)		1.4 (0.6, 3.2)	2.0 (0.9, 4.8)	8.7 (3.7, 20.7)
<i>p</i> value		0.45	0.10	0.00
P3	62 (23.8%)	18 (6.9%)	29 (11.1%)	15 (5.8%)
OR (95% CI)		1.2 (0.6, 2.2)	4.1 (2.2, 7.5)	2.7 (1.3, 5.4)
<i>p</i> value		0.67	0.00	0.01
P4	31 (11.9%)	9 (3.5%)	17 (6.5%)	5 (1.9%)
OR (95% CI)		1.1 (0.5, 2.5)	4.0 (1.9, 8.6)	1.3 (0.5, 3.6)
<i>p</i> value		0.87	0.00	0.62
Trend test	Z	2.94	-2.41	-0.65
	P	0.003	0.016	0.517

(C1) ankles with no or only low-grade lateral ligament injuries and no syndesmotic damage; (C2) ankles with complete ATFL injuries but no syndesmotic involvement; and (C3) ankles with partial or complete syndesmotic disruption. (P1) grade 0 or 1 effusion in both joints; (P2) grade 2 effusion in the tibiotalar joint only; (P3) grade 2 effusion in the talocalcaneal joint only; and (P4) grade 2 effusion in both tibiotalar and talocalcaneal joints. OR, odds ratio; CI, confidence intervals
Results in italics are statistically significant defined as $p < 0.05$

Table 3 Association of pathological grades of joint effusion in the tibiotalar and talocalcaneal joints separately with patterns of ligament injury

	No. of ankles N=261 (100%)	Ligament injury pattern		
		C1	C2	C3
Tibiotalar effusion				
Grade 0	53 (20.3%)	38 (14.6%)	6 (2.3%)	9 (3.5%)
OR		1.0 (ref.)	1.0 (ref.)	1.0 (ref.)
Grade 1	107 (41%)	35 (13.4%)	53 (20.3%)	19 (7.3%)
OR (95% CI)		0.5 (0.3, 1.1)	20.6 (8.1, 52.6)	2.8 (1.1, 6.6)
<i>p</i> value		0.10	0.00	0.02
Grade 2	101 (38.7%)	31 (11.9%)	43 (16.5%)	27 (10.3%)
OR (95% CI)		0.8 (0.5, 1.3)	1.7 (1.0, 2.9)	2.4 (1.3, 4.5)
<i>p</i> value		0.36	0.04	0.00
Trend test	Z	4.43	-3.10	-1.60
	P	<0.0001	0.002	0.109
Talocalcaneal effusion				
Grade 0	106 (40.6%)	56 (21.5%)	30 (11.5%)	20 (7.7%)
OR		1.0 (ref.)	1.0 (ref.)	1.0 (ref.)
Grade 1	101 (38.7%)	33 (12.6%)	43 (16.5%)	25 (9.6%)
OR (95% CI)		1.1 (0.6, 2.0)	5.2 (2.9, 9.3)	3.9 (1.9, 7.6)
<i>p</i> value		0.67	0.00	0.00
Grade 2	54 (20.7%)	15 (5.8%)	29 (11.1%)	10 (3.8%)
OR (95% CI)		0.8 (0.4, 1.6)	3.8 (2.1, 7.1)	1.4 (0.6, 2.9)
<i>p</i> value		0.61	0.00	0.42
Trend test	Z	3.39	-3.24	-0.192
	P	0.001	0.001	0.848

(C1) ankles with no or only low-grade lateral ligament injuries and no syndesmotic damage; (C2) ankles with complete ATFL injuries but no syndesmotic involvement; and (C3) ankles with partial or complete syndesmotic disruption. OR, odds ratio; CI, confidence intervals
Results in italics are statistically significant defined as $p < 0.05$

Table 4 Association of pathological grades of joint effusion in the tibiotalar and talocalcaneal joints separately with severity of talar osteochondral involvement

	No. of joints N= 261 (100%)	Talar osteochondral involvement	
		T1	T2
Tibiotalar effusion			
Grade 0	53 (20.3%)	44 (16.9%)	9 (3.5%)
OR		1.0 (ref.)	1.0 (ref.)
Grade 1	107 (41%)	83 (31.8%)	24 (9.2%)
OR (95% CI)		2.0 (0.9, 4.7)	3.7 (1.6, 8.7)
<i>p</i> value		0.11	0.00
Grade 2	101 (38.7%)	70 (26.8%)	31 (11.9%)
OR (95% CI)		0.8 (0.4, 1.4)	2.5 (1.4, 4.5)
<i>p</i> value		0.36	0.00
Trend test	<i>Z</i>	1.97	- 1.97
	<i>P</i>	0.048	0.048
Talocalcaneal effusion			
Grade 0	106 (40.6%)	86 (33%)	20 (7.7%)
OR		1.0 (ref.)	1.0 (ref.)
Grade 1	101 (38.7%)	77 (29.5%)	24 (9.2%)
OR (95% CI)		2.1 (1.1, 4.1)	3.5 (1.8, 6.9)
<i>p</i> value		0.03	0.00
Grade 2	54 (20.7%)	34 (13%)	20 (7.7%)
OR (95% CI)		0.7 (0.4, 1.3)	3.9 (2.0, 7.6)
<i>p</i> value		0.27	0.00
Trend test	<i>Z</i>	2.42	- 2.42
	<i>P</i>	0.015	0.015

(T1) includes grades 0 and 1 of talar osteochondral involvement (normal or small subchondral edema only); (T2) includes grades 3 to 5 (large subchondral edema only or any acute osteochondral lesion). OR, odds ratio; CI, confidence intervals

Results in italics are statistically significant defined as $p < 0.05$

DISCUSSION

In this large cohort of athletes sustaining an acute ankle sprain assessed on MRI, we demonstrated that the presence of effusion in both tibiotalar and talocalcaneal joints was associated with an increased risk for severe ligament injury such as complete ATFL rupture as well as partial or complete syndesmotc ligament rupture.

We also found that large (Grade 2) effusion in the tibiotalar joint only (without concomitant Grade 2 effusion in the talocalcaneal joint) increased more than eightfold the risk for partial or complete syndesmotc ligament rupture.

Furthermore, the presence of effusion in any of these joints was associated with

an increased risk for severe talar osteochondral involvement, including large subchondral contusions and any acute osteochondral lesion.

The assessment of injury severity in acute ankle sprain is crucial for treatment planning and rehabilitation of athletes and may help in determining recovery times after injury¹⁷⁻¹⁹. For instance, the occurrence of syndesmotic injury in association with ankle sprains may impact treatment decision and increases the recovery times of athletes, as previously demonstrated in comparison with isolated lateral ankle injury¹⁷⁻¹⁹.

Accurate assessment of structural injury severity after acute ankle sprains is limited using clinical examination only, especially when testing the syndesmosis, for which clinical tests demonstrate low sensitivity for the detection of injuries²⁰. Furthermore, it was demonstrated that clinical examination in the acute phase of a first-time lateral ankle sprain shows limited predictive value for the development of chronic ankle instability²¹. The occurrence of talar osteochondral involvement associated with ankle sprains may also impact treatment decision and prognosis²², the presence and severity of such involvement being extremely difficult to assess with clinical examination only. MRI is the imaging method capable to assess all different structures around the ankle joint including ligament, bone, and osteochondral involvement associated with sprain, with detailed assessment of injury severity¹¹. However, MRI is not routinely performed in all patients or athletes with acute ankle sprains as it is costly and thus not widely available.

This is why we took advantage of this large cohort of athletes assessed on MRI after sustaining acute ankle sprain, so we could test if the presence and amount of joint effusion are associated with injury severity. As a potential translation to the clinical routine, joint effusion can be easily assessed using ultrasound, which is much more available on a worldwide level than MRI.

If the presence of joint effusion were associated with structural injury severity in acute ankle sprain, an initial screening test using ultrasound could potentially be applied to patients and could be used to define which ones would benefit from further MRI assessment (those exhibiting joint effusion on ultrasound). We demonstrated that for ankles exhibiting severe (Grade 2) effusion in the tibiotalar joint (without concomitant grade 2 effusion in the talocalcaneal joint), the risk for partial or complete syndesmotic ligament rupture increased more than eightfold. Most radiologists and sports medicine physicians will agree that one could easily and quickly evaluate the presence and the amount of effusion

within the tibiotalar joint using ultrasound. Further, we demonstrated that the presence of effusion in the tibiotalar or talocalcaneal joints was associated with an increased risk for severe talar osteochondral involvement, reinforcing the potential usefulness of initial effusion assessment.

Finally, the absence of high-Grade effusion in both tibiotalar and talocalcaneal joints, which could be also verified on ultrasound, would likely indicate the absence of syndesmotic ligament injuries (considered in our study as the most severe ligament injury). We showed high specificity and relatively high NPV of Grade 2 effusion present in both joints in the detection of syndesmotic ligament injuries.

A number of limitations need mentioning. Although we propose an initial screening of athletes and patients on ultrasound to detect joint effusion and then select which ones should be further explored on MRI, we never compared ultrasound and MRI data. In a population of athletes, the threshold for prescribing an MRI examination certainly differs from that in the general population, and in our cohort, ultrasound was not performed prior to the MRI systematically. However, it is very likely that the assessment of joint effusion in both imaging techniques at the same moment would be equivalent¹³. Systematic longitudinal clinical follow-up was not available in this cohort, and for this reason, we do not know the relevance of the MRI findings in regard to prognosis, including recovery times.

Our cohort consisted largely of male athletes (the majority being football players) who had quick and easy access to MRI, and extrapolating our data to a non-athletic population or athletes in other sports should be performed with caution. Reasons for referral for MRI were not defined in a standardized fashion, but most MRI scans were obtained to rule out or confirm lateral ligament and syndesmotic injuries based on injury mechanism, symptom presentation, and clinical examination.


CONCLUSION

We demonstrated in a large cohort of athletes that ankles exhibiting MRI-detected effusion had a higher risk for exhibiting severe injuries such as complete ATFL rupture, partial or complete syndesmotic ligament rupture, and severe talar osteochondral involvement.

Based on these findings, athletes or patients sustaining acute ankle sprains could potentially be screened by ultrasound to evaluate the presence and the amount of effusion in the ankle, which is more widely available and less expensive than MRI. If an effusion is present, especially large amounts of effusion in the tibiotalar joint, these ankles could then be further evaluated by MRI given the increased risk for exhibiting severe injuries, including syndesmotic and talar osteochondral injuries.

REFERENCES

1. Beynon BD, Vacek PM, Murphy D, Alosa D, Paller D (2005) First-time inversion ankle ligament trauma: the effects of sex, level of competition, and sport on the incidence of injury. *Am J Sports Med* 33:1485–1491
2. Robinson P, White LM (2005) The biomechanics and imaging of soccer injuries. *Semin Musculoskelet Radiol* 9:397–420
3. Yard EE, Schroeder MJ, Fields SK, Collins CL, Comstock RD (2008) The epidemiology of United States high school soccer injuries, 2005–2007. *Am J Sports Med* 36:1930–1937
4. Maffulli N, Ferran NA (2008) Management of acute and chronic ankle instability. *J Am Acad Orthop Surg* 16:608–615
5. Swenson DM, Collins CL, Fields SK, Comstock RD (2013) Epidemiology of U.S. high school sports-related ligamentous ankle injuries, 2005/06–2010/11. *Clin J Sport Med* 23:190–196
6. van Dijk CN, Lim LS, Bossuyt PM, Marti RK (1996) Physical examination is sufficient for the diagnosis of sprained ankles. *J Bone Joint Surg Br* 78:958–962
7. Kerkhoffs GM, van den Bekerom M, Elders LA et al (2012) Diagnosis, treatment and prevention of ankle sprains: an evidence-based clinical guideline. *Br J Sports Med* 46:854–860
8. Stiell IG, Greenberg GH, McKnight RD, Nair RC, McDowell I, Worthington JR (1992) A study to develop clinical decision rules for the use of radiography in acute ankle injuries. *Ann Emerg Med* 21:384–390
9. Press CM, Gupta A, Hutchinson MR (2009) Management of ankle syndesmosis injuries in the athlete. *Curr Sports Med Rep* 8:228–233
10. Woods C, Hawkins R, Hulse M, Hodson A (2003) The Football Association Medical Research Programme: an audit of injuries in professional football: an analysis of ankle sprains. *Br J Sports Med* 37:233–238
11. Linklater JM, Hayter CL, Vu D (2017) Imaging of acute capsuloligamentous sports injuries in the ankle and foot: sports imaging series. *Radiology* 283:644–662
12. Roemer FW, Jomaah N, Niu J et al (2014) Ligamentous injuries and the risk of associated tissue damage in acute ankle sprains in athletes: a cross-sectional MRI study. *Am J Sports Med* 42:1549–1557
13. Guillodo Y, Riban P, Guennoc X, Dubrana F, Sarau A (2007) Usefulness of ultrasonographic detection of talocrural effusion in ankle sprains. *J Ultrasound Med* 26:831–836
14. Oae K, Takao M, Uchio Y, Ochi M (2010) Evaluation of anterior talofibular ligament injury with stress radiography, ultrasonography and MR imaging. *Skeletal Radiol* 39:41–47
15. Schneck CD, Mesgarzadeh M, Bonakdarpour A (1992) MR imaging of the most commonly injured ankle ligaments. Part II. Ligament injuries. *Radiology* 184:507–512
16. Griffith JF, Lau DT, Yeung DK, Wong MW (2012) High-resolution MR imaging of talar osteochondral lesions with new classification. *Skeletal Radiol* 41:387–399
17. Osbahr DC, Drakos MC, O’Loughlin PF et al (2013) Syndesmosis and lateral ankle sprains in the National Football League. *Orthopedics* 36:e1378–e1384
18. Miller BS, Downie BK, Johnson PD et al (2012) Time to return to play after high ankle sprains in collegiate football players: a prediction model. *Sports Health* 4:504–509
19. Sman AD, Hiller CE, Rae K, Linklater J, Black DA, Refshauge KM (2014) Prognosis of ankle syndesmosis injury. *Med Sci Sports Exerc* 46:671–677
20. de César PC, Avila EM, de Abreu MR (2011) Comparison of magnetic resonance imaging to physical examination for syndesmotic injury after lateral ankle sprain. *Foot Ankle Int* 32:1110–1114

- 
21. Doherty C, Bleakley C, Hertel J, Caulfield B, Ryan J, Delahunt E (2018) Clinical tests have limited predictive value for chronic ankle instability when conducted in the acute phase of a first-time lateral ankle sprain injury. *Arch Phys Med Rehabil* 99:720–725 e1
 22. van Eekeren IC, Reilingh ML, van Dijk CN (2012) Rehabilitation and return-to-sports activity after debridement and bone marrow stimulation of osteochondral talar defects. *Sports Med* 42:857–870

