



Laryngeal Dysfunction After Thyroid Surgery: Diagnosis, Evaluation and Treatment

C. Finck

To cite this article: C. Finck (2006) Laryngeal Dysfunction After Thyroid Surgery: Diagnosis, Evaluation and Treatment, Acta Chirurgica Belgica, 106:4, 378-387, DOI: 10.1080/00015458.2006.11679911

To link to this article: <https://doi.org/10.1080/00015458.2006.11679911>



Published online: 11 Mar 2016.



Submit your article to this journal [↗](#)



Article views: 40



View related articles [↗](#)



Citing articles: 3 View citing articles [↗](#)

Laryngeal Dysfunction After Thyroid Surgery : Diagnosis, Evaluation and Treatment

C. Finck

Service ORL et de Chirurgie Cervico-Faciale, CHU Sart Tilman, Liège

Key words. Laryngeal nerve paralysis ; recurrent laryngeal nerve ; thyroidectomy ; vocal fold ; dysphonia.

Abstract. Because of the close anatomical relationships between thyroid gland and laryngeal nerves, sensory-motor impairment of the laryngeal functions is a well known possible complication of thyroid surgery.

Laryngeal nerve paralysis can present with various and often associated symptoms like dysphagia, aspiration, voice alteration or dyspnea.

Several examination procedures are mandatory to perform a complete neuro-laryngeal evaluation : rigid and flexible video-stroboscopy will assess the abductor, adductor and tensor functions in breathing, sniffing, talking and eventually singing tasks. Laryngeal electromyography (LEMG), despite its technical difficulties, brings valuable objective and prognostic informations.

Aerodynamic assessment of voice production and objective acoustic voice evaluation are important for patients' follow-up, especially for voice professionals like teachers and singers.

Treatment of laryngeal sensory-motor nerve paralysis can be conservative, with the help of speech therapy.

Early surgical treatment is indicated in cases with severe functional problems like aspiration pneumonia, disabling breathy hypophonia, ineffective cough, disabling dyspnea. Surgical therapy at 6 to 9 months after injury is indicated in patients who demonstrate evidence of denervation or little activity on LEMG and have a poor response to a reasonable trial of speech therapy.

Many surgical procedures are available. Depending on the type of neuro-laryngeal deficit, the main and more widely used techniques are : injection laryngoplasty, medialization thyroplasty, arytenoid adduction, arytenoidopexy, crico-thyroid approximation, endoscopic laser cordotomy and re-innervation procedures.

Introduction

Because of the close anatomical relationships between thyroid gland and laryngeal nerves (Fig. 1), sensory-motor impairment of the laryngeal function is a well known possible complication of thyroid surgery. Laryngeal nerve trauma can lead to temporary drawbacks but also to long lasting or permanent sequelae.

The evolution of surgical techniques as well as the use of intra-operative laryngeal nerve monitoring lead to a decrease of the incidence of per-operative laryngeal nerve injury.

Completion thyroidectomy, volume of thyroid resection and surgeon's inexperience are important independent risk factors.

In 1963, an incidence of 17% of vocal fold paralysis was observed by Beahrs and Vandertoll (1) after completion thyroidectomy in a series of 548 patients.

In 1988, CALABRO *et al.* (2) report a much lower incidence : 1,5% of transient RLN paralysis after completion thyroidectomy.

Since the nineties, the incidence of laryngeal nerve paralysis dropped to 1 to 3%. Some series even report

only transient laryngeal paralysis and no permanent cases (3, 4).

Nevertheless, thyroidectomy still represents one of the most common etiologies of laryngeal nerve paralysis (5).

Laryngeal nerve paralysis can present with various and often associated symptoms like dysphagia, aspiration, voice alteration and dyspnea. Those symptoms depend on which nerve is injured, on the type of nerve lesion, on which motor units and how many are compromised, on the presence of laryngeal nerve connections, and with time, on the existence of re-innervation processes.

Normal anatomo-physiology of the larynx

Motor and sensory innervation of the larynx is carried by the left and right recurrent or inferior laryngeal nerves (RLN) and by the left and right superior laryngeal nerves (SLN).

RLN and SLN are both branches of the vagus nerve (X) (Fig. 2 and Fig. 3).

SLN arises from the vagus nerve just below the X's nodose ganglion. It branches into an external branch

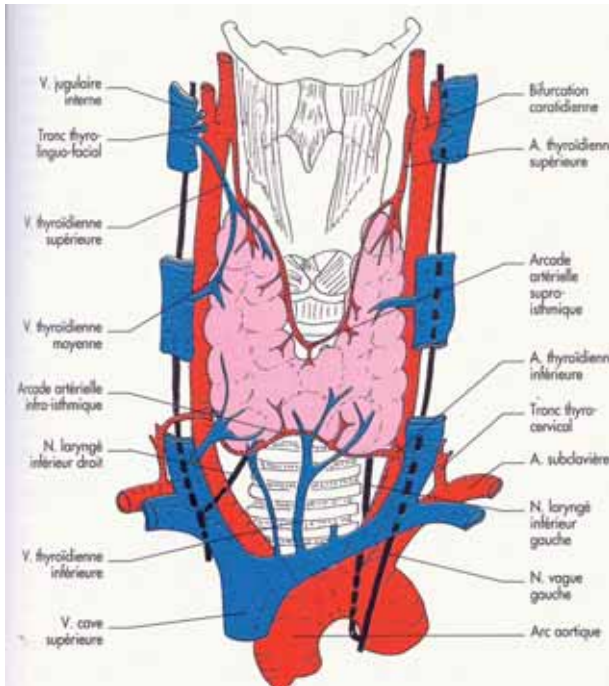


Fig. 1

Thyroid gland and vessels. In black : vagus nerve and inferior laryngeal nerves.

From BONFILS P., CHEVALLIER J.-M. "Anatomie ORL", Médecine –Sciences, Flammarion, Paris, 1998, p. 71.

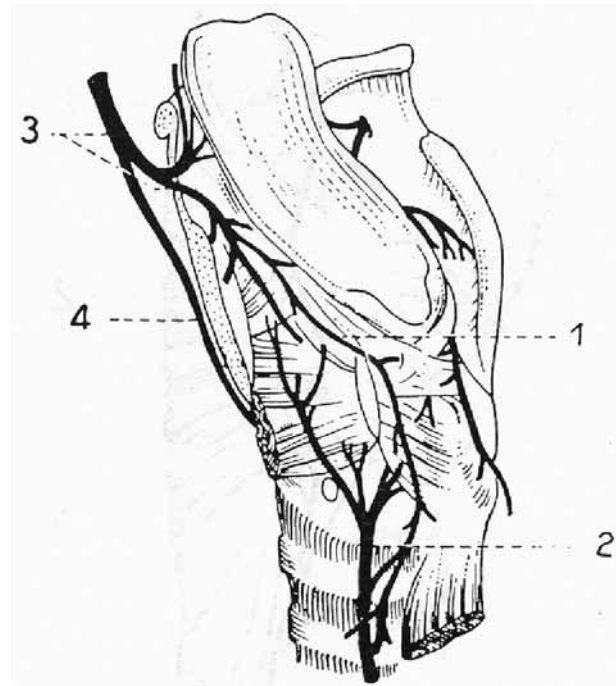


Fig. 2

Laryngeal nerves

1 : Galien's anastomosis

2 : inferior laryngeal nerve or recurrent nerve (RLN)

3 : superior laryngeal nerve (SLN)

4 : external branch of SLN, innervating the crico-thyroid muscle

From Ph. DEJONCKEERE "E.M.G. of the larynx" (11).

which provides motor innervation of the cricothyroid muscle, and an internal branch that carries sensory fibers from the supraglottis. The vagus nerve then continues its course in the neck along the carotid arteries. Inferior laryngeal nerves arise on the left at the level of the aorta and on the right just in front of the subclavian artery. Both inferior laryngeal nerves then adopt a recurrent course towards the larynx, in the tracheo-oesophageal groove.

All intrinsic muscles of the larynx, except the cricothyroid muscle (Fig. 4) which is innervated by the SLN, receive their motor fiber supply from the RLN. The RLN enters the larynx at the cricoid cartilage between the muscle fibers of the crico-pharyngeus muscle and the esophagus. The laryngeal muscles are innervated unilaterally except the interarytenoid muscle which is innervated by both RLN. Connections exist between SLN and RLN, like Galien's connection (Fig. 2).

The external branch of SLN can be damaged during the ligation of the superior thyroid artery. Damage to the inferior laryngeal nerves is possible due to their close relation to both the thyroid gland lobe and the inferior thyroid artery.

Intrinsic laryngeal muscles supplied by the RLN either adduct i.e. close the vocal folds: the thyro-arytenoid muscle [or vocal muscle (VM)], the lateral circoarytenoid muscle (LCA) and the interarytenoid muscle (IAM) or abduct i.e. open the vocal folds: the posterior circoarytenoid muscle (PCA) (Fig. 5, 6 and 7).

Abductor motor units contain more muscle fibers but there are four times as many adductor nerve fibers as abductor. As a result, the adductor motor units greatly outnumber the abductors (6).

The variability of the nervous supply of the intrinsic laryngeal muscles is still a subject of intense research. A recent anatomical study carried out on 75 human larynges obtained from necropsies shows the absence of abductor or adductor division of the RLN : in a majority of cases, adductor and abductor muscles are innervated by a common trunk. The authors also observed the existence of branches innervating adductor muscles from connections between SLN and RLN (7).

Vocal folds position and tension differ greatly depending on the functional goal: they are widely opened in maximal inspiration, delicately opposed in phonation, tightly closed in effort closure or coughing,

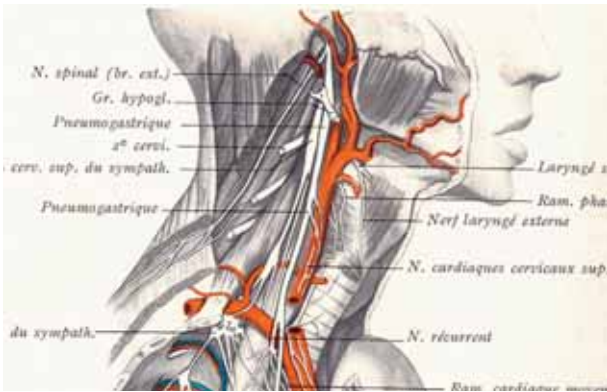


Fig. 3

Superior and inferior laryngeal nerves in the neck
From ROUVIÈRE "Anatomie humaine" Tome 1, Masson, 1981, p. 288.

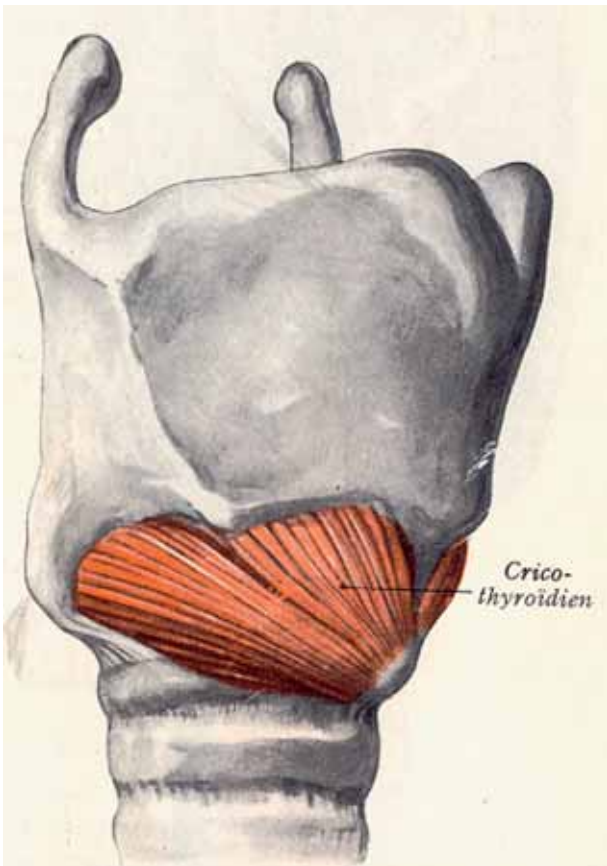


Fig. 4

Cricothyroid muscle (tensor of the VFs), innervated by SLN
From ROUVIÈRE "Anatomie humaine" Tome 1, Masson, 1981, p. 487.

sealed together under a sphincteric closure of the supra-glottis during swallowing.

The complex movements of the arytenoids on the cricoid cartilage are achieved thanks to a very special

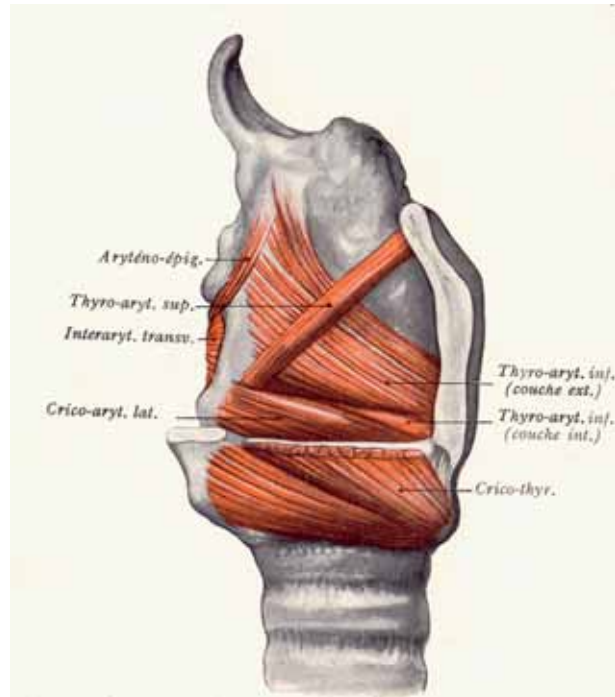


Fig. 5

Lateral cricoarytenoid muscle(LCA) and thyroarytenoid muscle.
From ROUVIÈRE "Anatomie humaine" Tome 1, Masson, 1981, p. 490.

shape of the crico-arytenoid joint and to a perfect balance between the laryngeal muscles. The crico-arytenoid joint has the shape of a saddle : the arytenoid is able to slide, rock, tilt and rotate like a rider on the cricoid cartilage (Fig. 8 and 9). Agonist-antagonist actions are fulfilled by the laryngeal muscles especially during phonation requiring precise and perfect control of muscular contraction : during emission of sounds, VF are closed but the PCA (the abductor muscle) is still active, holding posteriorly the arytenoid cartilage and counter balancing the action of the adductor muscles. Phonation of a wide range of sounds both in frequency and intensity necessitates constant control and adaptation of the contraction of the laryngeal muscles.

Laryngeal nerve trauma

Laryngeal nerve trauma during thyroid surgery leads to various symptoms affecting voice, respiration, swallowing and coughing. The following signs, if they persist in the postoperative period, justify an examination by an ENT specialist. Dysphonia can be light or severe : voice is usually breathy, weak, diplophonic, but the patient may be completely aphonic. This aphonia is associated with an inefficient (and silent !) cough.

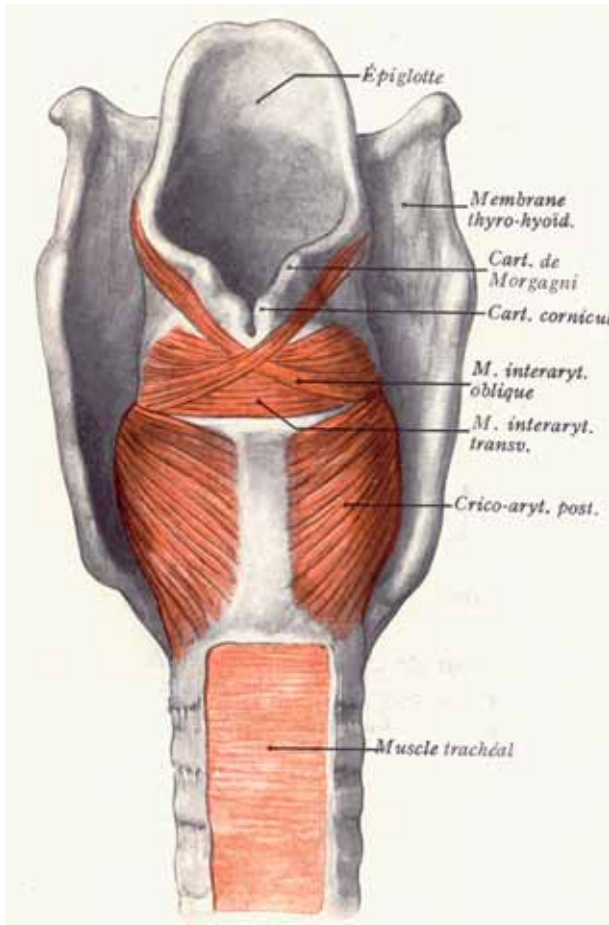


Fig. 6

Interarytenoid muscle (IAM) and posterior cricoarytenoid muscle (PCA).

From ROUVIÈRE "Anatomie humaine" Tome 1, Masson, 1981, p. 488.

Inspiratory dyspnea may be present. Usually light in unilateral lesions, dyspnea may be severe in bilateral nerve trauma.

Aspiration and dyspnea may be present in the first days after onset of the paralysis, and usually rapidly improve while voice remains altered.

Aspiration can be due to alteration of sensory feedbacks and input from the laryngeal mucosa as well as to insufficient motor laryngeal closure of the vocal folds during swallowing. Finally, paroxysmal laryngospasm is a frightening complication due to a sudden and forceful opposition of the glottic and supraglottic structure. It usually appears several weeks after surgery and is a possible consequence of a regenerative neurological process or of an altered laryngeal sensation (8).

The severity of symptoms and the prognosis depend on which nerve is damaged and on the type of nerve lesion, transient or permanent, partial or complete, uni- or bilateral. Moreover the clinical presentation depends

on which motor units and how many are compromised as well as on the patient's laryngeal nerve connections, knowing the variability of nerve supplies (7).

Spontaneous reinnervation process after nerve section is a well known phenomenon and especially the RLN has a marked propensity for regeneration (6).

Spontaneous reinnervation of the paralyzed larynx will in time, eventually modify the symptoms.

ENT examination

Several examination procedures are mandatory to perform a complete neurolaryngeal evaluation.

1. History

A thorough history of complaints has to be obtained. The voice in vocal cord paralysis is characterized by breathy and very unstable quality, loss of power and loss of voice range. These vocal characteristics will be worse when the patient tries to project the voice or shout: instead of being able of increasing the sound, breathiness and instability are increased. Patients also have a hard time to be heard in a crowded environment as a party or in a restaurant. The voice instability is named diplophonia, giving the impression that two sounds of different pitch are heard at the same time. High pitch phonation in falsetto register is also a common finding in patients with RLN paralysis. Patients very often complain of being out of breath when speaking and experience vocal strain. This is due to the inefficiency of the glottis closure during phonation. The air leakage will increase when the patient tries to raise the voice power: the paralyzed cord is not able to resist the increased subglottic pressure and will passively be drifted further away from the midline and above the glottic plane. Loss of range is noticeable in all patients but will be the major complaint of the patients who sing: high pitch notes are lost in mild cases and in severe cases, voice range is reduced to 3 or 4 tones while normal voice is characterized by a range of two octaves.

Loss of head register and reduction of voice range below one octave is observed in paralysis of SLN.

Occasionally, sore throat is noted because of increased vocal effort. Swallowing disorders are common in RLN paralysis. Aspiration is usually not overt, but the patients have to take extra care to prevent aspiration of liquids. These usually mild swallowing disorders improve, in general, rapidly while the voice symptoms remain very obvious.

Finally, dyspnea on exertion and phonation is present in unilateral RLN paralysis, but usually mild to moderate. In case of bilateral RLN injury and paralysis, dyspnea is the major symptom and eventually will require an emergency intubation.

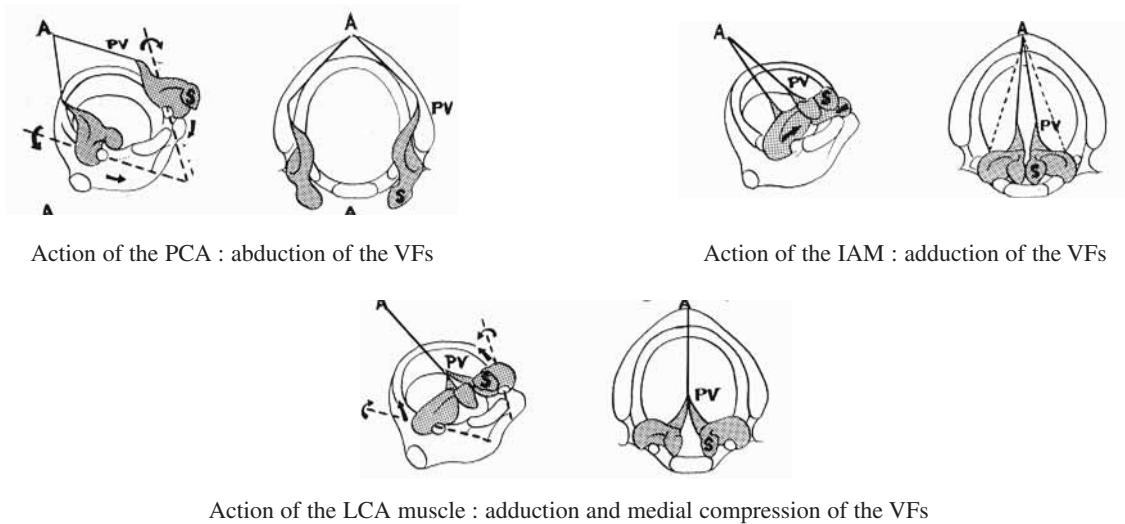


Fig. 7

Roles of the PCA, IAM and LCA muscles

From "La voix humaine et ses troubles", Librairie Arnette, Paris, 1984, p. 28

2. Physical examination

a) Observation of the larynx

This can be achieved with a mirror, a rigid telescope placed in the mouth or through a fibroscope passing through the nose. Rigid and flexible endoscopy can be videotaped or numerically recorded and coupled with stroboscopy. Stroboscopy is a method which artificially slows down the VF's vibration and hence permits the observation of the mucosal wave and lateral movement of vibration. Mirror examination is the oldest and simplest way to observe the VF but doesn't permit stroboscopy or documentation of the VF's movement on videotape or by numerical recording.

Fibroscopy or videofibroscopy is a key examination procedure. It permits the observation of the larynx in natural conditions and in different tasks : calm breathing, single vowel phonation, connected speech phonation, singing, coughing, sniffing (forced arytenoid abduction), swallowing. Fibroscopy allows to document compensatory gestures like supraglottic squeezing, ventricular phonation or pharyngeal constriction. During fibroscopy, the quality of glottis closure during phonation and signs of VF denervation will be assessed.

In case of RLN paralysis, the paralyzed VF is located more or less away from the midline. Three positions can be observed : median (close to the midline), paramedian and intermediate (far from the midline, in a position intermediate between normal adduction and abduction). The position of the paralyzed VF determines a phonatory gap. The importance of the gap during phonation is determined not only by the VF position but also by the amount of residual innervation : in case of complete denervation, the loss of muscle bulk increases the lack of

glottis closure. Signs of denervation of the paralyzed VF are : a more lateral position leading to a poor glottic closure, a reduced length of the paralyzed fold compared to the normal side, a lowered paralyzed fold, an exaggerated vertical movement during stroboscopy, an atrophic VF characterized by a loss of muscle bulk leading to a concavity of the free edge. On the denervated side, the arytenoid rolls forward, leaning over the glottis. With phonation the contra lateral normally innervated VF will shorten and adduct to match the reduced length of the denervated VF. Inversely, signs of partial denervation are the persistence of some muscle tone on the paralyzed side : an eventually closer position of the paralyzed VF to the midline, no VF atrophy, better glottic closure, some residual abduction during the sniffing task.

Videostroboscopy with the rigid telescope placed in the mouth can also permit to observe denervation and reinnervation patterns. In case of denervation, the glottal configuration shows mid cord gap, posterior gap and level differences between the VF, the paralyzed VF being lowered compared to the normal side. During VF vibration observed in stroboscopy, the denervated side shows a reduction in the amplitude both of lateral movement and of the mucosal wave. Asymmetry in phase and amplitude is obvious between the normal and denervated side. In case of complete denervation, the paralyzed VF behaves like a "flag in the breeze" with a loose and lax appearance. In case of early reinnervation there is a reversal of many of these findings before gross movement restoration.

b) Electromyography (EMG)

Assessment of the innervation status of intrinsic laryngeal muscles with EMG is important both for diagnosis

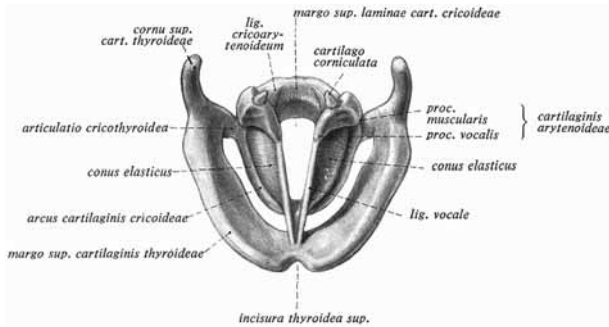


Fig. 8

Laryngeal cartilages and conus elasticus.
From SOBOTTA "Atlas d'Anatomie humaine", Ferner Staubesand, Maloine, 1977, p. 158.

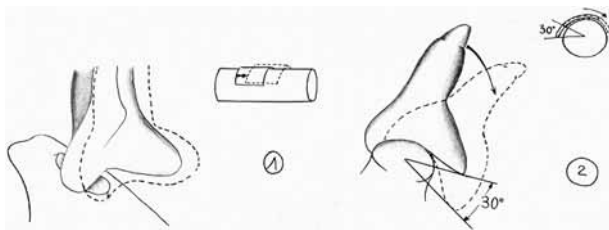


Fig. 9

Movements of the arytenoids on the cricoid cartilage .
From "La voix humaine et ses troubles", Librairie Arnette, Paris, 1984, p. 28.

and prognosis (9, 10). Two muscles are particularly interesting : the cricothyroid muscle depending on the SLN and the thyro-arytenoid muscle depending on the RLN. For these two muscles, a percutaneous route is taken for the insertion of the EMG needle.

During the percutaneous procedure, the patient is placed with the head in extension. No local anaesthesia is required. To evaluate the vocal muscle, the neck is punctured at the level of the cricothyroid membrane with a 37 mm disposable hypodermic electrode. After passing the cricothyroid membrane, the electrode is angled laterally and cranially until reaching the vocal muscle. Extra care is taken not to perforate the laryngeal mucosa.

To evaluate the cricothyroid muscle, the neck is punctured slightly laterally to the midline at the level of the cricoid cartilage. The electrode is angled slightly posterolaterally and upwards, aiming at the lower face of the thyroid cartilage.

For evaluation of the PCA muscle, which is more difficult to reach, needle insertion can be done through a trans-cutaneous or a peroral route. The trans-cutaneous route necessitates to rotate manually the thyroid cartilage towards the opposite side.

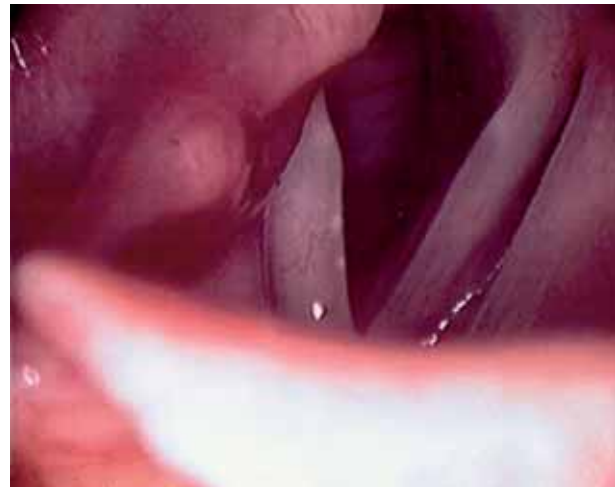

Fig. 10
Right RLN paralysis

During laryngeal electromyography (LEMG), electrical patterns are analyzed for spontaneous and evoked activity. All the following patterns can be observed in the case of paralyzed VF (11,12). Signs of denervation are : electrical silence during the first days after onset, fibrillation potential and positive sharp waves appear approximately 10 days after onset of paralysis. If no nerve regeneration occurs, these potentials may remain present for several years. In the eventuality of a reinnervation process after a complete denervation, nascent motor units may appear after several weeks which lead to the recording of low amplitude and relatively short duration polyphasic potentials. They can be observed at the earliest 2 months after onset and last for more than a year. In later stages of recovery (5-12 months after onset of nerve degeneration), spontaneous denervation potentials progressively disappear and the polyphasic potentials become larger sized and longer than initially, due to creation of giant motor units. This pattern is rarely observed (12). If the nerve lesion is partial, LEMG can record normal potentials or normal potentials reduced in number. These LEMG observations are not rare. If these normal potentials are observed in the early stages after onset of paralysis, this indicates that the laryngeal nerve was partly intact from the beginning or that it suffered from neurapraxia (nerve compression leading to a block of conduction) at the onset and partly recovered by the time of the LEMG examination. The presence of normal potentials in a later stage indicates incomplete paralysis from the onset or regeneration of nerve fibers (12).

The limitations of LEMG lie in the technical difficulties and in determining the prognosis of the paralysis. Verification of the accurate placement of the electrodes is difficult in patients with paralysis, and LEMG is not useful for prognostic purposes after six months after

onset of paralysis : any LEMG pattern can be observed in patients who won't recover laryngeal mobility (12).

c) Acoustic and aerodynamic measures

These measures permit to follow the laryngeal efficiency in terms of voice production and aerodynamic rentability. They are obtained at each consultation, permitting a longitudinal follow-up of each case.

In case of laryngeal paralysis, the following characteristics will be observed : reduction of maximum phonation time, reduction of dynamic range both in loudness and frequency, loss of high frequency harmonics and high frequency formants on the spectrogram, increased aperiodicity of the vibratory period (increased jitter), increased noise-to-harmonic ratio, increased mean airflow. Subglottic air pressure is usually diminished, the subject being unable to raise the pressure below the VFs because of the poor glottic closure.

Clinical entities

1. Unilateral RLN paralysis

VF motion impairment after thyroidectomy may present as the classical unilateral RLN paralysis which has been mainly described above (fig 10). Denervation signs are associated with the worse voices and the worse acoustic and aerodynamic measures. Denervation signs have also a poor prognostic value. In terms of a possible recovery, early signs can be observed with a good prognostic value : a more median position of the VF, absence of denervation signs at both the laryngeal observation and LEMG, presence of normal action potentials at LEMG or observation of some residual voluntary movement during laryngeal observation. Paramedian position of the paralyzed VF is the more frequently observed (70%), followed by the median position (20%) and the intermediate position (10%) (11, 12). In 110 cases with fixed VF, Hirano showed that the more medial the VF, the more often voluntary action potentials were obtained at the LEMG (12).

Nevertheless, all positions can be observed whether the paralysis is complete or not. One has also to remind that the position of the paralyzed VF depends not only on the balance between the intrinsic laryngeal muscles but also on the location and morphology of the cricoarytenoid joint.

Finally, 9% of the unilateral fixed VF have a combined lesion of RLN and SLN. In these cases, VF tend to be more lateral (12).

2. Superior laryngeal nerve paralysis

In case of lesion of the SLN, adduction and abduction of the VF is perfectly normal since both RLN are intact. The only motor deficit is the absence of contraction of

the crico-thyroid muscle. Even if the lesion is unilateral, it leads to a lack of longitudinal tension in the VFs. The voice is weak, often breathy. The patient is unable to shout or speak loudly but the major sign is the inability to reach the head register. For singers, it means a drastic reduction of their voice range which can be reduced to less than one octave (normally, voice range is at least two octaves).

As noted above, SLN paralysis can coexist with RLN paralysis. LEMG is the key procedure to demonstrate the nerve lesion, the crico-thyroid muscle being easily tested because of its external location in the larynx.

3. Bilateral laryngeal nerve paralysis

Most commonly, bilateral RLN paralysis will lead to combined dyspnea and dysphonia.

Like in unilateral RLN paralysis :

- the VF mobility impairment can be partial or complete and the nerve lesion can vary from neurapraxia to complete nerve section.
- the position of the paralyzed folds can vary from paramedian to lateral.

Depending on the more or less lateral position of the vocal folds and on an eventual paresis on one side instead of a complete paralysis, dyspnea will be more or less severe. In case of diplegia and tight position of the 2 VFs, an emergency tracheostomy sometimes has to be performed.

With time, if no recovery takes place, the management of those diplegia cases is always difficult and unsatisfactory because the procedures tending to improve breathing, degrade voice quality. The opposite is also true.

Natural evolution

In case of laryngeal denervation, spontaneous reinnervation process can be observed as soon as 2 months after denervation (12). There is a remarkable propensity for regeneration of the RLN (14). But when this regeneration process occurs, it is likely to be synkinetic. Synkinesis is a phenomenon that has been studied in other neuromotor systems : reinnervation process leads to the absence of net movement or to abnormal and counter productive movements. Neurophysiologic findings in such synkinetic cases include slow nerve-conduction time and loss of orderly recruitment at the EMG testing. The functional result of synkinesis is the loss of control of the strength of contraction and the loss of the fine motor control.

Synkinesis is considered to be the consequence of misguided peripheral motor axons which reinnervate inappropriate muscle fibers. In the larynx, there are four

times as many adductor nerve fibers as abductor nerve fibers. This difference in number of motor units favor reinnervation of adductor muscle fibers. Gradual reinnervation would account for the observed progressive shift of the paralyzed VF from a lateral to a more medial position (6). Nevertheless, even synkinetic, spontaneous laryngeal reinnervation improves voice thanks to restoration of muscle bulk inside the VF and restoration of the tonus of the laryngeal muscles holding the arytenoid cartilage.

Prognosis

To answer the anxious question of both the patient and the surgeon "what are the chances of recovery?" is very difficult for three main reasons.

First, because one has to differentiate the recovery of the laryngeal mobility and the functional recovery, essentially the voice restoration. Second, because even a complete paralysis can recover. Third, because even LEMG doesn't give a perfect answer.

To differentiate recovery of mobility and recovery of function is important knowing that in the case of spontaneous reinnervation, the patient can regain intralaryngeal muscle bulk and tonus leading to a voice close to normal, even without regaining normal laryngeal mobility: the reinnervated VF may remain immobile, unable to abduct, due to a synkinetic reinnervation pattern.

Even complete paralysis can functionally recover thanks to spontaneous reinnervation.

LEMG has its limits. Clinical experience has shown that the results of LEMG are often inconclusive. Fibrillation potentials (denervation pattern) are difficult to detect because of competing noise from neighboring muscles and because of the small size of the laryngeal muscles. A majority of patients with RLN paralysis do not have electrical silence in the early days after nerve trauma, because the nerve lesion is incomplete. Normal interference patterns can be recorded while laryngeal motion is absent for the same reason.

Patients with reduced interference pattern or with polyphasic potentials have certainly a nerve lesion but unfortunately, the likelihood of recovery cannot be predicted.

In the first six months after nerve lesion, the most important LEMG factor with a good prognostic value is the presence of action potentials induced by voluntary activity: in this case, 60% of the patients recovered laryngeal mobility (12). If no action potential is detected during that period of time, only 20% of the patients recovered laryngeal mobility (12).

LEMG isn't useful for prognostic purposes after 6 months following onset because all types of LEMG patterns can be recorded in the presence of a persistent immobile VF (12).

If recovery has to take place, it is usually observable in the first three months and rarely after one year following onset of paralysis.

Management of laryngeal paralysis

The management of laryngeal paralysis includes observation, speech therapy and surgery.

The choice of treatment is guided by the etiology, the importance and type of the functional deficit and the prognosis for recovery.

Recognition, by the surgeon, of a laryngeal mobility problem after thyroidectomy is the first important step. A rapid referral to an ENT specialist will permit a thoroughful neurolaryngeal evaluation.

In the first days after trauma, corticosteroids can be useful by reducing perineural inflammation. They should be used intravenously or per os. Inhaled corticosteroids, on the other hand, have no obvious efficiency.

1. Unilateral RLN paralysis

In these cases, restoration of voice is the main goal. Many patients improve spontaneously enough during the first 6 months of follow-up to avoid a surgical treatment.

During these 6 first months after onset of paralysis, speech therapy is important to help restoring a better voice. It will reduce the compensatory hyperkinetic gestures and help with breath control. But speech therapy alone cannot rehabilitate a completely aphonic patient or reduce significantly a very breathy voice nor help in reducing level differences between the normal and the paralyzed VF.

Usually, surgical treatment is postponed between 6 months and 1 year after onset of paralysis. At that time, denervation signs and poor response to speech therapy are obvious.

The needs for early surgical treatment (before 6 months) are aspiration, important breathy hypophonia and ineffective cough. Also have to be taken into account the needs of the professional voice user and the etiology of the paralysis (nerve cut or not).

Surgical procedures will try to improve the glottis closure and the glottis resistance during phonation. The procedures consist either in medialization techniques or in reinnervation procedures.

Medialization techniques consist in intra-cordal injections of several available implants (injection laryngoplasty) or in more or less complex framework laryngeal surgery (thyroplasty, arytenoidopexy, crico-thyroid subluxation).

Several substances can be injected into the VF. Teflon isn't used in our department because of the risks of migration and foreign body granulomas. Partially

resorbable substances available today are bovine collagen (Zyplast^o), micronized human dermis (Cymetra^o), autologous collagen, autologous fat, modified hyaluronic acid (Hylaform^o) (15, 16). More recently, non resorbable silicone (Bioplastic^o) is available.

Those substances have to be injected into the paralyzed VF muscle in order to augment the mass and resistance of the VF. After injection, the free edge of the paralyzed VF adopts a more medial position, improving glottis closure during phonation. Injection laryngoplasty can be performed under direct micro-laryngoscopy and general anaesthesia. Under local anaesthesia, laryngoplasty is performed transorally with a curved injection needle or transcutaneously by puncture through the neck.

The goal of frame work laryngeal surgery is also the medialization of the paralyzed VF.

Medialization of the VF can be achieved by a thyroplasty type I (17). Through an external neck dissection, a window is created in the thyroid lamina. An implant is then inserted and placed in the most effective position. The procedure is therefore done under local anaesthesia, permitting the patient to phonate while positioning the implant.

Several implants can be used: implants hydroxylapatite or Silastic prefabricated or a more versatile implant like Goretex vascular patches (18).

Because successful voice restoration using thyroplasty type I may be limited because of a large posterior glottic gap and because of the VF's level difference, surgical techniques have been developed to reposition the paralyzed arytenoid. Two techniques are available and can be used in combination with thyroplasty type I: the arytenoid adduction (19) and the more recent arytenopexy (20).

To obtain an improved longitudinal tension in the paralyzed VF, a cricothyroid subluxation can be added to the aforementioned procedures (21).

Reinnervation procedures may also be attempted. Reinnervation can be performed only if the laryngeal muscles are completely denervated. In case of partial denervation, neural sprouting is blocked by under expression of adhesion molecules by the innervated muscle fibers (22).

For unilateral paralysis, ansa-omohyoid neuromuscular pedicle onto the vocal muscle (23) and ansa cervicalis – RLN anastomosis have been performed (24) with some success. The goal of these reinnervation procedures is to restore some muscle bulk and muscle tone in the paralyzed VF but because of synkinesis, purposeful movement is rarely observed.

2. Bilateral RLN paralysis.

The main symptom is usually dyspnea but also dysphonia.

As in unilateral RLN paralysis, surgical treatment is postponed between 6 months and 1 year after onset of paralysis. The need for early surgical treatment is of course the intensity of dyspnea which sometimes requires emergency tracheostomy.

Some patients have the luck to recover at least partially some purposeful movement. In such cases, surgery is usually avoided and they are treated conservatively even if some degree of dyspnea and dysphonia is still present.

For the cases with no hope of recovery and with tight position of the VFs, several surgical procedures can be proposed to improve breathing: endoscopic VF lateralization, endoscopic laser cordotomy or CO2 laser arytenoidectomy.

Patients have to be aware that those procedures aim at improving breathing while voice quality will worsen.

In order not to degrade voice too much, all procedures are realized on one side only.

In our department, we prefer endoscopic laser cordotomy to endoscopic arytenoidectomy which can be followed by an intense scarring process. Scar contraction may lead to persistence of laryngeal stenosis, after arytenoidectomy.

Reinnervation procedures have been and are still attempted today. They consist in reinnervating specifically the PCA muscle (25) but clinical evaluation is still ongoing.

3. SLN paralysis.

The main problem of the patients suffering from SLN paralysis is the complete or partial lack of longitudinal tension of one or both VFs. The limited voice registration and lack of voice power can be improved by a surgical cricothyroid approximation procedure. It can consist in a cricothyroid subluxation, like proposed by ZEITELS (21) or in a cricothyroid approximation (26).

Conclusion

Although the incidence of laryngeal nerve paralysis after thyroidectomy is low, the condition has to be rapidly recognized by the surgeon to permit a rapid and thorough neurological examination by an ENT specialist.

Symptoms are dysphonia, dysphagia, dyspnea and aspiration. Their intensity and association are variable.

The assessment of the innervation status of intrinsic laryngeal muscles is important for diagnosis, prognosis and treatment. Many treatments are possible for the patients who do not recover spontaneously.

Speech therapy and corticosteroids are important in the early days after nerve trauma but most of the solutions for permanent sequelae are surgical procedures

consisting in medialization techniques, laryngeal framework surgery, reinnervation procedures or endoscopic procedures to relief the laryngeal breathing obstacle.

References

1. BEAHR O. H., VANDERTOLL D. J. Complications of secondary thyroidectomy. *Surg Gynecol Obstet*, 1963, **117** : 535-9.
2. CALABRO S., AUGUSTE L. J., ATTIE J. N. Morbidity of completion thyroidectomy for initially mis diagnosed thyroid carcinoma. *Head Neck Surg*, 1988, **10** : 235-8.
3. DE JONG S. A., DEMETER J. G., LAWRENCE A. M., PALOYAN E. Necessity and safety of completion thyroidectomy for differentiated thyroid carcinoma. *Surgery*, 1992, **112** : 734-739.
4. WAX M. K., BRIANT T. D. R. Completion thyroidectomy in the management of well-differentiated thyroid carcinoma. *Otolaryngol. Head Neck Surg*, 1992, **107** : 63-68.
5. BENNINGER M. S., CRUMLEY R. L., FORD C. N., GOULD W. J., HANSON D. G., OSSOFF R. H., SATALOFF R. T. Evaluation and treatment of the unilateral paralyzed vocal fold. *Otolaryngology Head Neck Surg*, 1994, **111** : 497-508.
6. WOODSON GAYLE E. Configuration of the glottis in laryngeal paralysis. II : animal experiments. *Laryngoscope*, 1993, **103** : 1235-1241.
7. MARANILLO E., LEON X., ORUS C., QUER M., SANUDO J. R. Variability innerve patterns of the adductor muscle group supplied by the recurrent laryngeal nerve. *Laryngoscope*, 2005, **115** : 358-362.
8. WANI M. K., WOODSON G. E. Paroxysmal laryngo-spasm after laryngeal nerve injury. *Laryngoscope*, 1999, **109** : 694-697.
9. Schaefer S. D. Laryngeal Electromyography. *Otolaryngol Clin of North Am*, 1991, **24** : 1053-1057
10. SIMPSON D. M., STERNMAN D., GRAVES W. S., SANDERS I. Vocal cord paralysis : clinical and electrophysiologic features. *Muscle and Nerve*, 1993, **16** : 952-957.
11. DEJONCKEERE Ph. E.M.G. of the larynx. Eds Marc Pietteur, 1987.
12. HIRANO M., NOZOE I., SHIN T., MAEYAMA T. Electromyography for Laryngeal Paralysis. In : *Neurology : Recent Advances*. HIRANO M., KIRCHNER J., BLESS D. (eds.). College Hill Press, Boston, pp. 232-243, 1987.
13. VEDA N. A clinical study of recurrent laryngeal nerve paralysis following surgical operations. Part II. *Hiroshima Med J*, 1968, **16** : 431-459.
14. WOODSON G. E. Configuration of the glottis in laryngeal paralysis. I : clinical study. *Laryngoscope*, 1993, **103** : 1227-1234.
15. REMACLE M., LAWSON G. Injectable substances for vocal fold augmentation. Current Opinion in *Otolaryngol Head Neck Surg*, 2001, **9** : 393-397.
16. FINCK C., LEFEBVRE P. Implantation of Esterified Hyaluronic Acid in microdissected Reinke's space after vocal fold microsurgery : first clinical experiences. *Laryngoscope*, 2005, **115** : 1841-1847.
17. ISSHIKI N., OKAMURA H., ISHIKAWA T. Thyroplasty type I (lateral compression) for dysphonia due to vocal cord paralysis or atrophy. *Acta Otolaryngol (Stockh)*, 1975, **80** : 465.
18. ZEITELS S. M., MAURI M., DAILY S. H. Medialization laryngoplasty with Gore-Tex for voice restoration secondary to glottal incompetence : indications and observations. *Ann Otol Rhinol Laryngol*, 2003, **112** : 180-184.
19. ISSHIKI N., TANABE M., SAWADA M. Arytenoid adduction for unilateral vocal cord paralysis. *Arch Otolaryngol Head Neck Surg*, 1978, **104** : 555.
20. ZEITELS M., HOCHMAN I., HILLMAN R. E. Adduction arytenopexy : a new procedure for paralytic dysphonia with implication, for implant medialization. *Ann Otol Rhinol Laryngol*, 1998, **107**, supplément 173, 1-24.
21. ZEITELS S. M., HILLMAN R. E., DESLOGE R. B., BUNTING G. A. Cricothyroid subluxation : a new innovation for enhancing the voice with laryngoplastic phonosurgery. *Ann Otol Rhinol Laryngol*, 1999, **108** : 1126-1131.
22. MARTINI R., SCHACHNER M. Immuno-electron microscopic localization of neural cell adhesion molecules (L1, N-CAM, and myelin-associated glycoprotein) in regenerating adult mouse sciatic nerve. *J Cell Biol*, 1988, **106** : 1735.
23. TUCKER H. M. Reinnervation of the unilaterally paralyzed larynx. *Ann Otol Rhinol Laryngol*, 1977, **86** : 789.
24. CRUMLEY R. L., IZDEBSKI K., MCKICKEN B. Nerve transfer versus Teflon injection for vocal cord paralysis : a comparison. *Laryngoscope*, 1998, **98** : 1200.
25. TUCKER H. M. Management of the patient with an incompetent larynx. *Am J Otol*, 1979, **1** : 47.
26. ISSHIKI N. and others. Thyroplasty as a new phonosurgical technique. *Acta Otolaryngol (Stockh)*, 1974, **78** : 451.

Dr. C. Finck, M.D.
 Chef de Clinique Adjoint
 Service ORL et de Chirurgie Cervico-Faciale
 CHU Sart Tilman
 B-4000 Liège
 Tel. : 4 366 7269
 Fax : 4 366 7525
 E-mail : camille.finck@ulg.chu.ac.be