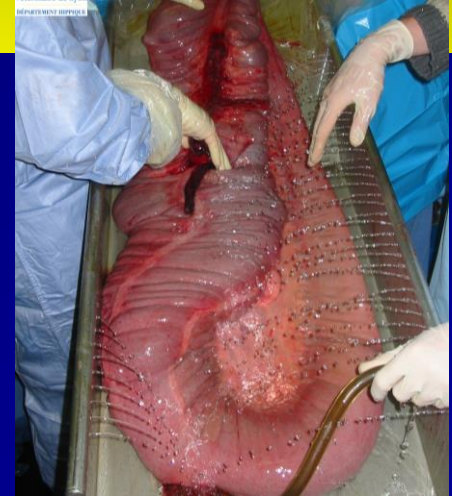

Herniation of the large colon through the gastrosplenic ligament: 4 cases

**M. Gangl, S. Grulke, J. Munoz,
A. Benamou-Smith, D. Serteyn**



**GREMERES, Lyon Equine Research Centre, Université de Lyon,
Lyon, France ;**

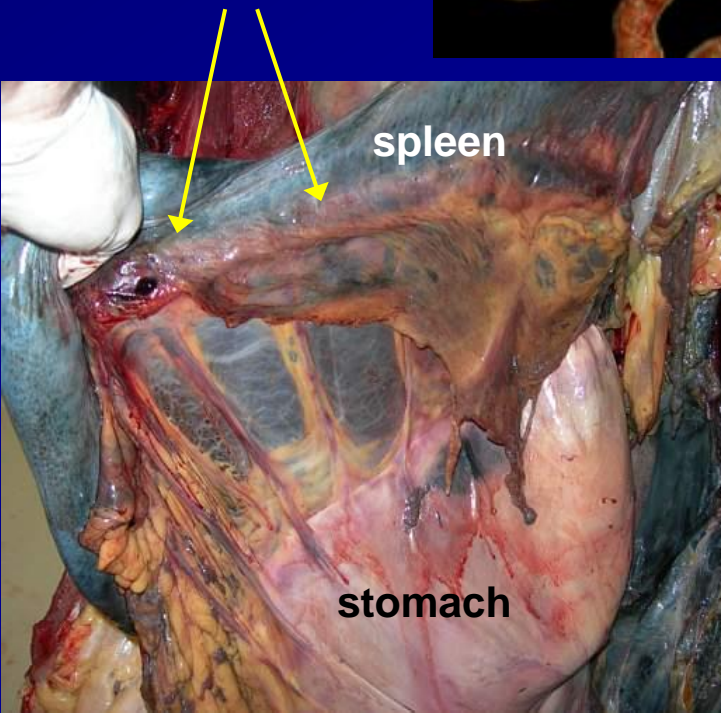
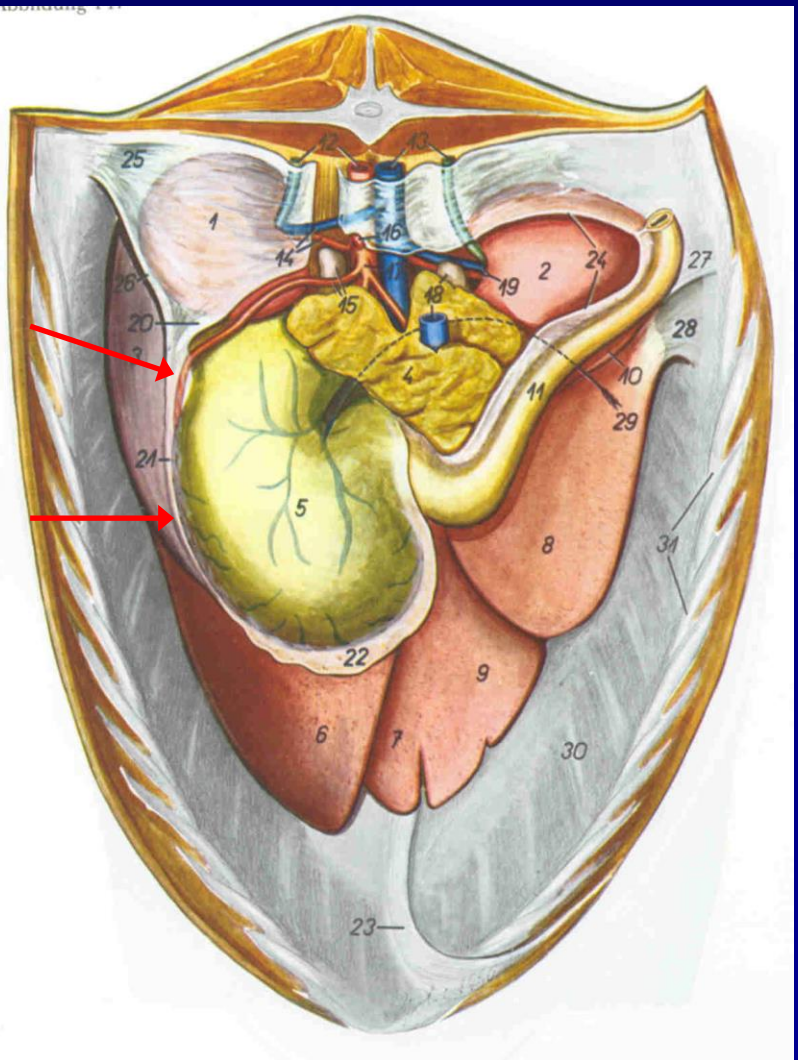
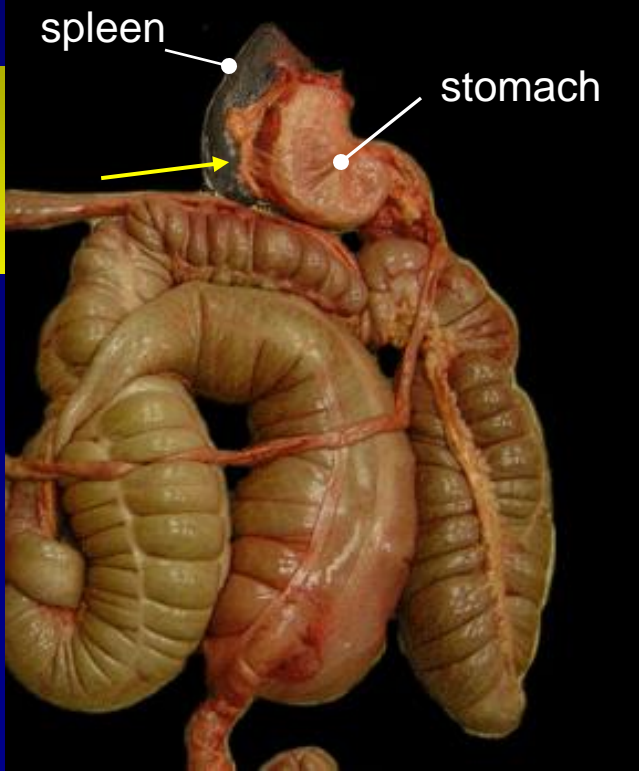
**Ecole Nationale Vétérinaire de Lyon, Département Hippique,
Marcy L'Etoile, France**

and



**Equine Clinic, Faculty of Veterinary Medicine, University of
Liège,
Sart Tilman, Belgium**

Introduction: Anatomy

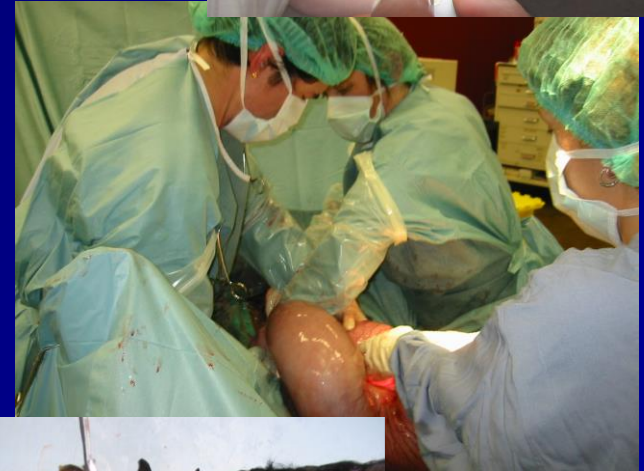

Introduction: case reports

- **Strangulation of small intestine through a rent in the gastrosplenic ligament: case series**
(Yovich et al, Vet Surg 1985)
- **Incarceration of small colon through a rent in the gastrosplenic ligament in a pony : 1 case**
(Rhoads and Parks, JAVMA 1999)
- **Incarceration of the large colon in the gastrosplenic ligament of a horse: 1 case**
(Trostle and Markel, JAVMA 1993)

Material and Method

- Review of medical records
- Complete physical examination, CBC and biochemistry, abdominocentesis and US if possible
- Ventral midline exploratory laparotomy
- Needle decompression or enterotomy, correction of displacement
- Post operative intensive care



Results: signalment

Horse 1	Horse 2	Horse 3	Horse 4
warmblood	warmblood	warmblood	selle Français
gelding	gelding	gelding	Gelding
563 kg	640 kg	560 kg	615 kg
6 years	8 years	18 years	6 years
Colic since 6 hours	Colic since 7 hours	Colic since at least 5 hours	Colic since at least 18 hrs

Results: clinical exam

Horse 1	Horse 2	Horse 3	Horse 4
Moderate pain	Severe pain	Moderate pain after flunixin	Severe pain
Pink CRT 2s	Injected CRT 3s	Injected CRT 3s	Pale CRT 3s
44 bpm	36 bpm	48 bpm	60 bpm
32 rpm	48 rpm	16 rpm	16 rpm
37,4°	36,4°	36,9°	37,8°

Results: clinical & ancillary exams

Horse 1	Horse 2	Horse 3	Horse 4
↓, tympanic	↓, tympanic	↓, tympanic	L: 0 R: ↓, tymp.
Food contents	0 L	Food contents	Food contents
LI distension NS hidden	LI distension NS and spleen hidden	LI distension NS and spleen hidden	LI distension and overload, spleen displaced, NS hidden
CBC&biochem. normal	CBC&biochem. normal	CBC&biochem. normal	CBC&biochem. normal
Not performed	Not performed	Not performed	Straw colored, clear, TP 22g/L US: spleen displaced, kidney visible



Results: surgery

Horse 1	Horse 2	Horse 3	Horse 4
Herniation of left colon LI gaseous distension	Herniation and nephrosplenic entrapment of left colon SI distension	Herniation of left colon LI gaseous distension	Herniation of whole colon severe alimentary overload SI distension
Needle aspiration and correction	Needle aspiration and correction	Needle aspiration and correction	Pelvic flexure enterotomy and correction
	Correction of displacement very difficult, haemorrhage	Correction of displacement difficult	

Results: post-operative complications

Horse 1	Horse 2	Horse 3	Horse 4
uncomplicated	48 hrs pain 5 days POI	Mild peritonitis	48 hrs pain 6 days POI
No complication (7 years)	No complication (3.5 years)	No complication (1.5 years)	Colic recurrence 6 weeks post op No diagnosis No post mortem

Discussion: occurrence

Ulg: 3 cases in 7 years
<1% of all exploratory
laparotomies

→ Rare type of large
colon displacement



Discussion: signalment

Horse 1	Horse 2	Horse 3	Horse 4
warmblood	warmblood	warmblood	Selle Français
gelding	gelding	gelding	gelding
6 years	8 years	18 years	6 years
563 kg	640 kg	560 kg	615 kg
Colic since 6 hours	Colic since 7 hours	Colic since at least 5 hours	Colic since at least 18 hrs

Discussion: clinical presentation

Horse 1	Horse 2	Horse 3	Horse 4
Moderate pain	Severe pain	Moderate pain after flunixin	Severe pain
Pink CRT 2s	Injected CRT 3s	Injected CRT 3s	Pale CRT 3s
44 bpm	36 bpm	48 bpm	60 bpm
32 rpm	48 rpm	16 rpm	16 rpm
37,4°	36,4°	36,9°	37,8°

Discussion: clinical presentation

Horse 1	Horse 2	Horse 3	Horse 4
↓, tympanic	↓, tympanic	↓, tympanic	L: 0 R: ↓, tymp.
Food contents	0 L	Food contents	Food contents
LI distension NS hidden	LI distension NS and spleen hidden	LI distension NS and spleen hidden	LI distension and overload, spleen displaced, NS hidden
CBC&biochem. normal	CBC&biochem. normal	CBC&biochem. normal	CBC&biochem. normal
Not performed	Not performed	Not performed	Straw colored, clear, TP 22g/L US: spleen displaced, kidney visible



Discussion: complications

Horse 1	Horse 2	Horse 3	Horse 4
uncomplicated	48 hrs pain 5 days POI	Mild peritonitis	48 hrs pain 6 days POI
No complication (7 years)	No complication (3.5 years)	No complication (1.5 years)	Colic recurrence 6 weeks post op No diagnosis No post mortem

Conclusions

Herniation of the large colon through the gastrosplenic ligament.... :

- Predisposition for large framed geldings ?
- Little alteration of physical exam or CBC
- Progressively worsening pain
- POI = possible post operative complication



Thank you for your attention



Belgian Horse Parade, August 2005, Liège