

High-risk metastatic post-molar neoplasia complicating twin pregnancy with complete mole and coexisting fetus. Case report and review of the literature

Marie Jacques¹, Frédéric Goffin², Anne-Céline Cheron³, Julie Vanalbada³, Jean-Louis Christophe⁴, Dominique Carly³, Brigitte Honhon⁵, Luc Dewolf⁶, Timour Willems⁷

¹ Obstetrics and Gynecology Department, Prenatal Diagnosis and Maternal Intensive Care, Grand Hôpital de Charleroi, Charleroi, Belgium; ² Belgian Gestational Trophoblastic Disease Reference Centre, University of Liège, Liège, Belgium; ³ Obstetrics and Gynecology Department, Prenatal Diagnosis and Maternal Intensive Care, Grand Hôpital de Charleroi, Charleroi, Belgium; ⁴ Nephrology Department, Grand Hôpital de Charleroi, Charleroi, Belgium; ⁵ Oncology Department, Grand Hôpital de Charleroi, Charleroi, Belgium; ⁶ Ophthalmology Department, Grand Hôpital de Charleroi, Charleroi, Belgium; ⁷ Gynecologic Oncology Department, Grand Hôpital de Charleroi, Charleroi, Belgium

ABSTRACT

Objective: To raise awareness of the recognition of twin pregnancy with complete hydatidiform mole and normal coexisting fetus (CHMCF). CHMCF are at high risk of developing preeclampsia, prematurity and up to 50% fetal loss. Additionally, about 35% develop gestational trophoblastic neoplasia, irrespectively of the duration of the pregnancy.

Case report: The patient was a primigravida with poorly controlled type 1 diabetes who became pregnant after ovulation stimulation and intrauterine insemination. She suffered from vaginal bleeding, hyperthyroidism and preeclampsia. CHMCF was suspected at 28 weeks of gestation. A caesarean section was performed at 30 weeks due to progressive high-risk diabetic retinopathy. The patient developed a high-risk metastatic post molar neoplasia with lung metastases and was treated with multidrug chemotherapy.

Conclusion: It is important to recognize early CHMCF to manage maternal and fetal complications, and inform patients about related risks and to allow them to decide about the continuation or termination of pregnancy.

KEYWORDS

Choriocarcinoma, diabetes mellitus, gestational trophoblastic neoplasia, hydatidiform mole, twin pregnancy.

Introduction

Twin pregnancy with complete hydatidiform mole and normal coexisting fetus (CHMCF) is a rare condition. It is usually suspected by the combination of ultrasound findings, clinical symptoms and high human chorionic gonadotropin (hCG) levels. The presence of a healthy fetus challenges the diagnosis^[1]. Nevertheless, diagnosing CHMCF is important to allow the patient to give free and informed consent about the continuation or termination of the pregnancy. Indeed, in addition to a higher risk of developing gestational trophoblastic neoplasia (GTN), these pregnancies are at risk of preeclampsia and fetal loss or preterm delivery^[2].

We present the case of a 21-year-old diabetic primigravida with a CHMCF arising after ovulation stimulation and intrauterine insemination. CHMCF was suspected during the second trimester. The patient suffered from vaginal bleeding, hyperthyroidism, preeclampsia and choriocarcinoma. The patient gave birth to a healthy baby at 30 gestational weeks.

Case presentation

The patient was a primigravida with a poorly controlled type 1 diabetes. Her glycosylated hemoglobin level was 7.3%

Article history

Received 1 Feb 2022 - Accepted 12 Jul 2022

Contact

Marie Jacques; dr@mjacques.be
Centre de gynécologie et obstétrique, Route de Luxembourg, 131
6700 Arlon; Belgium. Phone: +32 6 3245777

before the pregnancy. A twin pregnancy was achieved after ovulation stimulation with clomiphene citrate followed by intrauterine insemination. A spontaneous involution of one of the gestational sacs was observed between 6 and 8 weeks of gestation. At 8 weeks' gestation, the patient presented a subchorionic hematoma accompanied by vaginal bleeding. A non-invasive prenatal testing was performed which was normal (46, XX).

At 12 gestational weeks, the patient presented blurred vision. A diabetic retinopathy with right eye ischemia was documented and treated by laser photocoagulation. Furthermore, subclinical hyperthyroidism was treated with propylthiouracil. The patient was hospitalized at 26 weeks' gestation due to uncontrolled diabetes and left hospital against medical advice.

At 28 gestational weeks, patient presented mild hypertension, generalized edema and proteinuria (1.4 g/24 hours) without biological abnormalities, hence being diagnosed with preeclampsia. Her glycemic balance was still poor due to

preeclampsia, hence exogenous insulin needs were reduced. Thyroid function was normalized. Fetal surveillance was reassuring. However, a molar pregnancy was suspected due to the sonographic finding of a snowstorm appearance next to the placenta (Figure 1) associated to elevated hCG level (170,759 IU/L). Review of prior ultrasounds revealed that such images had already been seen but had been considered of unknown significance. Expectant management was proposed in a first time by the Belgian Trophoblastic Disease Reference Centre.

At 30 gestational weeks, a progressive bilateral fundal papillary edema with micro-aneurysm and micro-hemorrhage was highlighted. A caesarean section was performed to avoid further ophthalmological damage, after corticosteroid and magnesium sulfate treatment for fetal maturation and cerebral protection. The patient gave birth to a healthy newborn weighing 1,490 g, Apgar scores 6/9/10. A molar mass was easily removed with the hand (Figure 2). The uterine evacuation was considered complete. Placental analyses revealed a complete molar pregnancy with focus of trophoblastic atypia next to the normal placenta. The next day, hCG level decreased to 47,271 IU/L.

After one week of delivery hCG levels raised to 6,399 IU/L, 12,072 IU/L after two weeks and 23,403 IU/L after three weeks. An intrauterine mass of 30 x 38 mm was observed upon pelvic ultrasound. Upon magnetic resonance imaging (MRI), mass measured 48 x 40 x 49 mm that invaded more than 50% of the myometrium with intact serous. Chest-abdominal computed tomography scan revealed widespread multiple pulmonary metastases (Figure 3). Despite this, cerebral MRI was negative. Following the WHO-FIGO recommendations, a high-risk stage III gestational trophoblastic neoplasia (FIGO prognostic score 9) was allocated. Treatment with low-induction chemotherapy (etoposide and cisplatin) for 2 courses followed by EMA/CO chemotherapy (etoposide, methotrexate, dactinomycin/ cyclophosphamide, vincristine) was started due to the fact that the patient suddenly presented dyspnea (grade III according to the New York Heart Association) and fever.

Twelve weeks after delivery, there was a regression of the uterine mass and of the pulmonary metastases. Levels of hCG were null after four complete EMA/CO courses (17 weeks

Figure 1 Molar pregnancy upon abdominal ultrasound at 28 gestational weeks.

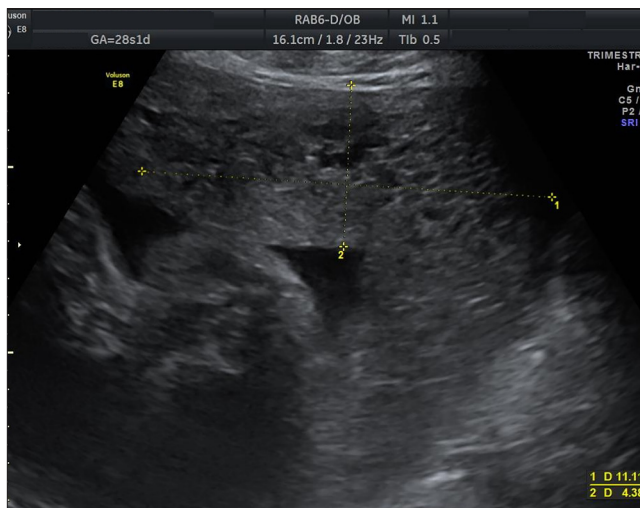


Figure 2 Macroscopic aspect of the normal placenta (left) and the complete hydatidiform mole (right) at delivery.

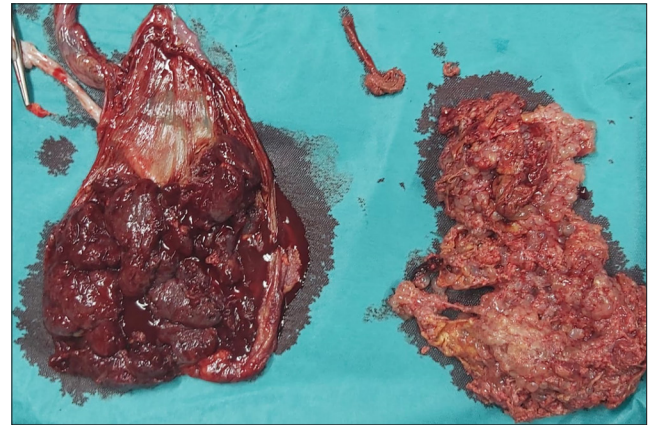
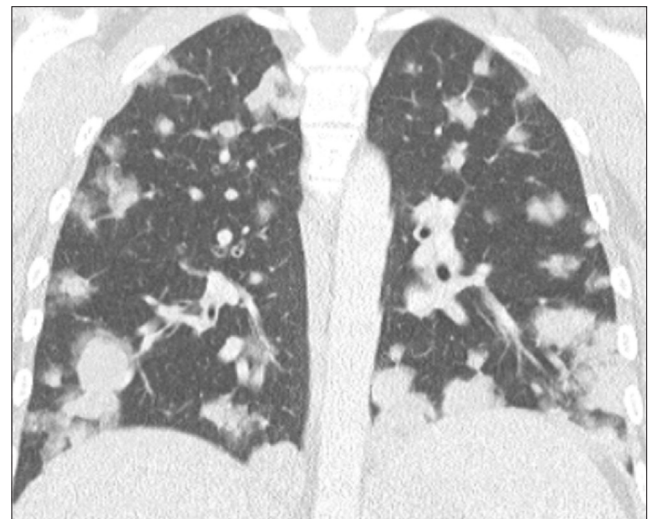


Figure 3 Chest computed tomography scan evidencing pulmonary metastases 3 weeks after delivery.



postpartum). The fifth EMA/CO course was interrupted due to severe medullar aplasia and febrile neutropenia with grade 3 necrotic mucositis, pancolitis, appendicitis and toxic lichenoid cutaneous rash. A new course of EMA/CO with reduced dose to 80% was started again at week 26 after delivery. hCG levels were regularly monitored and remained negative. A follow-up thoracic imaging revealed a favorable evolution with regression of the previous lesions.

At birth, the newborn was transferred to the neonatal intensive care unit due to respiratory distress syndrome and prematurity. Newborn's hCG level was first measured at 599 IU/L then rapidly decreased to be normalized after two weeks. The newborn had a normal thyroid function, presented a good evolution and was discharged at 36 gestational weeks.

Discussion

Gestational trophoblastic disease refers to a group of benign and malignant tumors arising from gestational tissue that can have locally invasive and metastatic potential [3]. Molar pregnancy, which is divided into complete and partial hydatidiform mole, is the most common form and is considered benign.

Complete hydatidiform moles (CHM) are mainly the consequence of the fertilization of an empty ovum with one or two spermatozoon and do not include fetal tissue [3,4]. CHMCF (a twin pregnancy combining a complete hydatidiform mole with an apparently normal fetus) is a rare condition estimated to occur in one in 20,000 to 100,000 pregnancies [1,2,5]. There is no evidence that CHMCF is facilitated by assisted reproductive technology [6]. A recent study suggests that maternal genetic susceptibility for meiosis defects may underlie the etiology of molar pregnancies [7].

The suspicion of molar pregnancy is usually based on the association of ultrasound findings, clinical symptoms and high hCG levels. Upon imaging, the CHM is located outside the placenta of a usually normal fetus and presents with the appearance of a “snowstorm” multivesicular pattern [4,8]. Three entities should be considered in case of an abnormal molar placenta observed next to a fetus, namely: a dizygotic gestation with a CHMCF, a single pregnancy consisting of a partial mole with a dysmorphic fetus and a mesenchymal dysplasia of the placenta with a viable fetus.

Patients with CHMCF may present vaginal bleeding, hyperemesis gravidarum, hyperthyroidism, preeclampsia and GTN [1,2,4,5,8]. About 35% of CHMCF cases will develop GTN [1]. Interruption of pregnancy does not seem to decrease the risk of GTN [1,2,4,6,9,10]. Nevertheless, as underlined by Sharon *et al.* [6] the pregnancy remains at high risk of maternal complications and only 40-60% live births are reported in ongoing pregnancies with high rates of preterm deliveries [9,10].

After delivery, close hCG monitoring is essential to diagnose a post-molar GTN which should be sought when hCG level stagnates for 4 consecutive values over ≥ 3 weeks, rises $\geq 10\%$ for 3 values over ≥ 2 weeks or persists 6 months after molar evacuation [3]. There is no evidence that hCG level before delivery predicts GTN [11]. The patient may present abnormal vaginal bleeding and pulmonary or neurologic symptoms in case of metastatic lesions.

Doppler pelvic ultrasound may locate the tumor in an enlarged irregular uterus and chest x-ray may reveal a pulmonary metastatic disease. Repeated uterine curettage may be considered in non-metastatic post-molar GTN. Workup for metastatic disease has to be completed with pelvic, abdominal and thoracic imaging. Brain MRI has to be performed in case of pulmonary metastases [3,12].

GTN have to be staged and scored with the FIGO staging and prognostic scoring system to ascertain the most appropriate therapy. Post-molar high-risk GTN (FIGO prognostic score ≥ 7) is relatively rare and estimated at only 6% [3]. It has to be managed with multiagent EMA/CO chemotherapy (etoposide, methotrexate and dactinomycin alternating weekly with cyclophosphamide and vincristine) repeated every two weeks until hCG levels normalize and continue normal for an additional 6-8 weeks for consolidation [3,12]. Long-term survival rates of 85% to 94% are reported with this treatment [3]. In widespread metastatic GTN, an induction chemotherapy with low dose regimen associating etoposide and cisplatin prior to initiating EMA/CO is recommended to avoid potential early death due to tumor collapse with hemorrhage, metabolic acidosis, septicemia and multiple organ failure [3,13].

Newborn prognosis is mainly based on prematurity complications. Positive newborn hCG is expected due to maternal to fetal hCG passive transfer during pregnancy [13]. However, newborn hCG levels have to be monitored because infant choriocarcinomas have been reported [14]. Furthermore, the newborn thyroid function has to be assessed in case of maternal hyperthyroidism and antithyroid drug intake.

Conclusion

Twin pregnancy with CHMCF is a rare condition that carries significant maternal and fetal complications. The most serious are fetal loss or preterm birth, preeclampsia and GTN. Even though continuation of pregnancy seems not unfavorable from the oncological point of view, these pregnancies remain at high risk of severe maternofetal complications. Therefore, it is of paramount importance to recognize CHMCF at an early gestational age to allow the patient to give free and informed consent about the continuation or termination of the pregnancy. In case of pregnancy continuation, the patient should be followed by a multidisciplinary team experienced in the management of high-risk pregnancies. Collaboration with trophoblastic diseases reference center is advised.

In the present case, CHMCF was suspected only one week before fetal extraction. Given this circumstance, the patient did not have the opportunity to give free and informed consent to continue her pregnancy. Regrettably, the patient developed almost all the most serious complications of CHMCF particularly preeclampsia, preterm delivery and subsequently high-risk metastatic post molar neoplasia.

References

1. Zilberman Sharon N, Maymon R, Melcer Y, Jauniaux E. Obstetric outcomes of twin pregnancies presenting with a complete hydatidiform mole and coexistent normal fetus: a systematic review and meta-analysis. *BJOG*. 2020;127:1450-7.
2. Lipi LB, Philp L, Goodman AK. A challenging case of twin pregnancy with complete hydatidiform mole and co-existing normal live fetus - A case report and review of the literature. *Gynecol Oncol Rep*. 2019;31:100519.
3. Abu-Rustum N, Birkeland M, Bradley K, et al. Gestational Trophoblastic Neoplasia, Version 2.2019, NCCN Clinical Practice Guidelines in Oncology. *J Natl Compr Canc Netw*. 2019;17:1374-91.
4. Ning F, Hou H, Morse AN, Lash GE. Understanding and management of gestational trophoblastic disease. *F1000Res*. 2019;8:F1000 Faculty Rev-428.
5. Nobuhara I, Harada N, Haruta N, et al. Multiple metastatic gestational trophoblastic disease after a twin pregnancy with complete hydatidiform mole and coexisting fetus, following assisted reproductive technology: Case report and literature review. *Taiwan J Obstet Gynecol*. 2018;57:588-93.
6. Zilberman Sharon N, Melcer Y, Maymon R. Is a complete hydatidiform mole and a co-existing normal fetus an iatrogenic effect? *Isr Med Assoc J*. 2019;21:653-7.
7. Khawajkie Y, Mechtouf N, Nguyen NMP, et al. Comprehensive analysis of 204 sporadic hydatidiform moles: revisiting risk factors and their correlations with the molar genotypes. *Mod Pathol*. 2020;33:880-92.
8. Kutuk MS, Ozgun MT, Dolanbay M, Batukan C, Uludag S, Basbug

- M. Sonographic findings and perinatal outcome of multiple pregnancies associating a complete hydatiform mole and a live fetus: a case series. *J Clin Ultrasound*. 2014;42:465-71.
9. Lin LH, Maestá I, Braga A, et al. Multiple pregnancies with complete mole and coexisting normal fetus in North and South America: a retrospective multicenter cohort and literature review. *Gynecol Oncol*. 2017;145:88-95.
 10. Massardier J, Golfier F, Journet D, et al. Twin pregnancy with complete hydatidiform mole and coexistent fetus: obstetrical and oncological outcomes in a series of 14 cases. *Eur J Obstet Gynecol Reprod Biol*. 2009;143:84-7.
 11. Kang WD, Choi HS, Kim SM. Prediction of persistent gestational trophoblastic neoplasia: the role of hCG level and ratio in 2 weeks after evacuation of complete mole. *Gynecol Oncol*. 2012;124:250-3.
 12. Sita-Lumsden A, Short D, Lindsay I, et al. Treatment outcomes for 618 women with gestational trophoblastic tumours following a molar pregnancy at the Charing Cross Hospital, 2000-2009. *Br J Cancer*. 2012;107:1810-4.
 13. Jorgensen K, Roychowdhury M, da Cunha G, Kim YB, Schorge JO. Stage IV gestational choriocarcinoma diagnosed in the third trimester. *Obstet Gynecol*. 2019;133:163-6.
 14. Getrajdman J, Kolev V, Brody E, Chuang L. Case of maternal and infantile choriocarcinoma following normal pregnancy. *Gynecol Oncol Case Rep*. 2012;2:102-4.

Conflict of Interest Statement: The authors declare no conflict of interest.