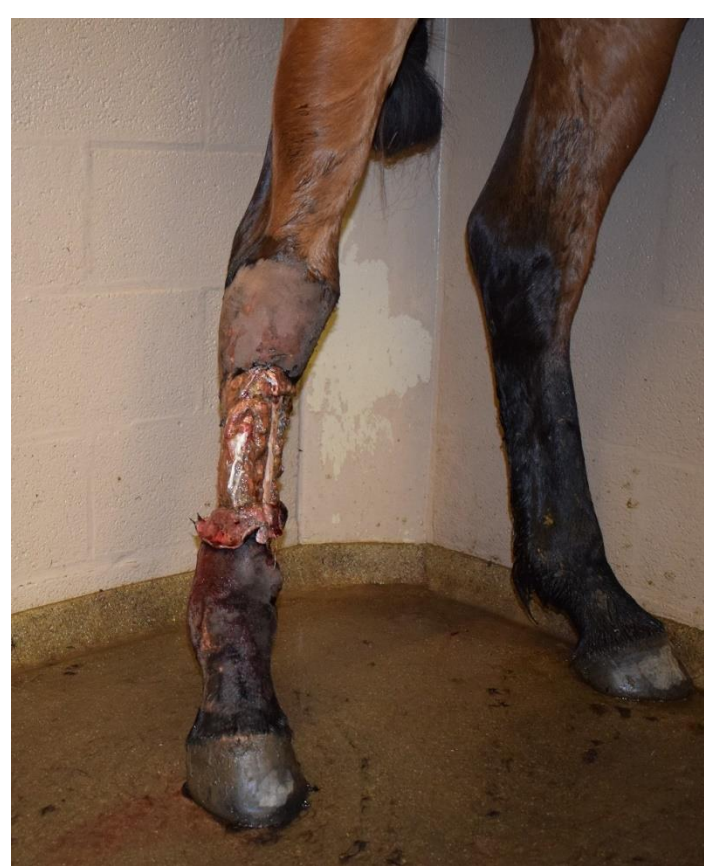

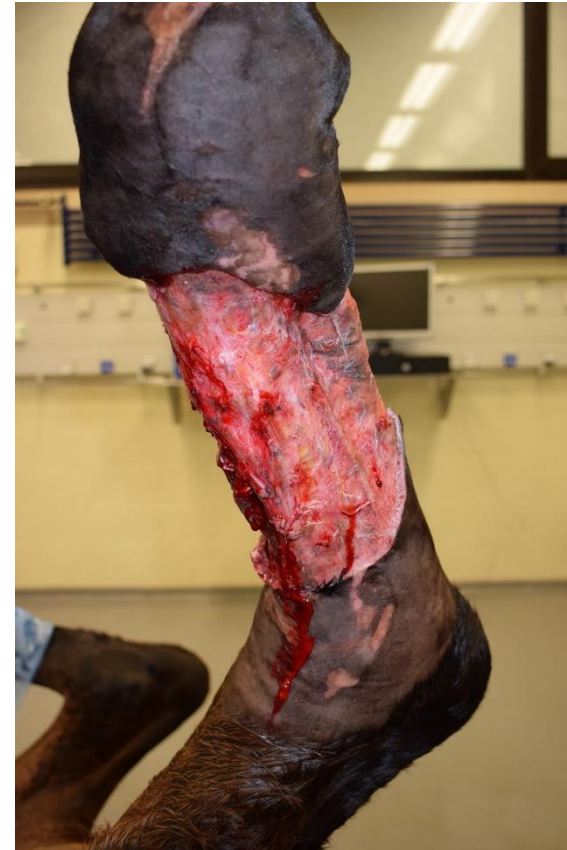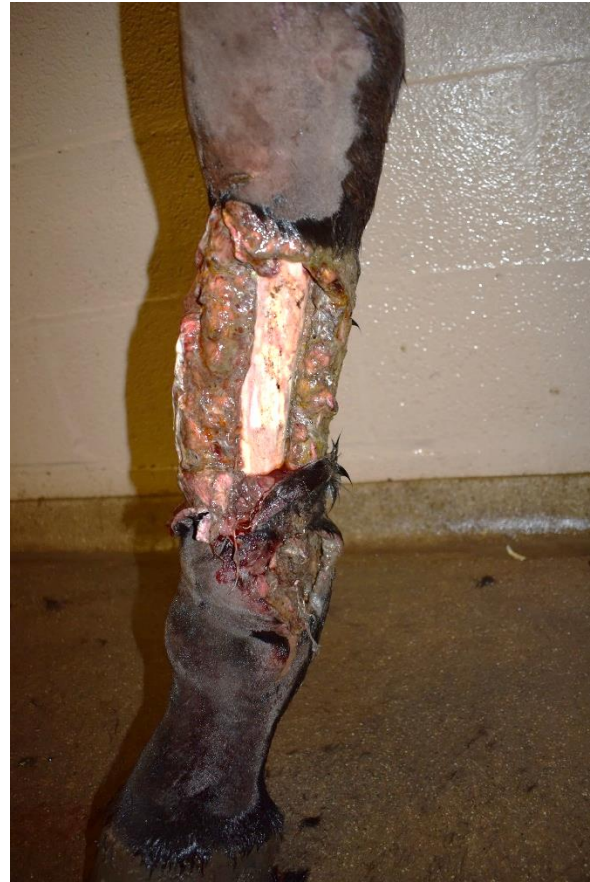# Wound center: MEEK graft case presentation

Sigrud Grulke and Alexandra Salciccia  
Equine Clinic, Liège University, Belgium

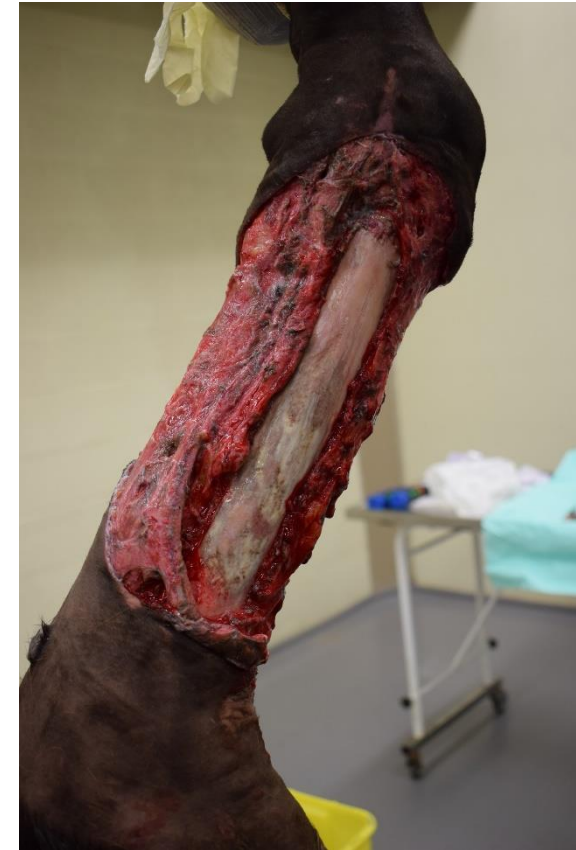# Extensive circular limb wound



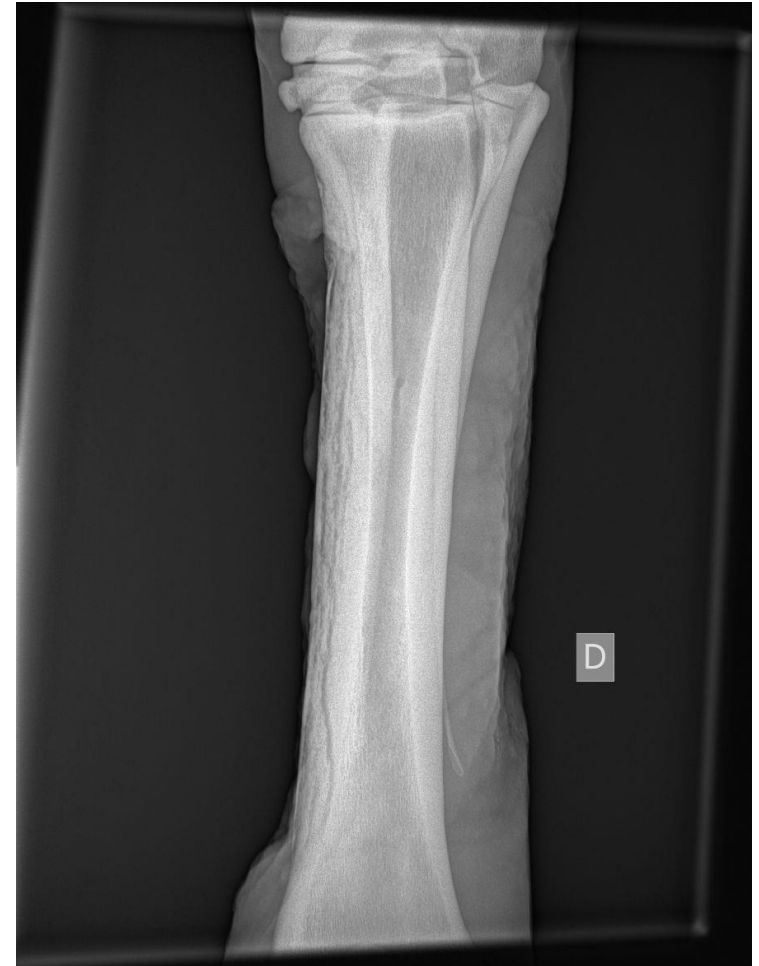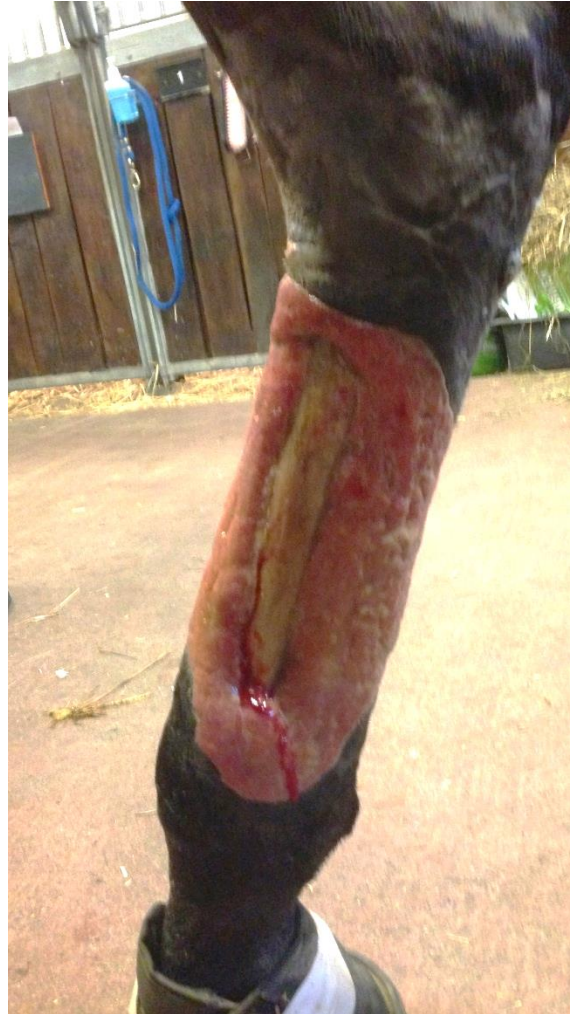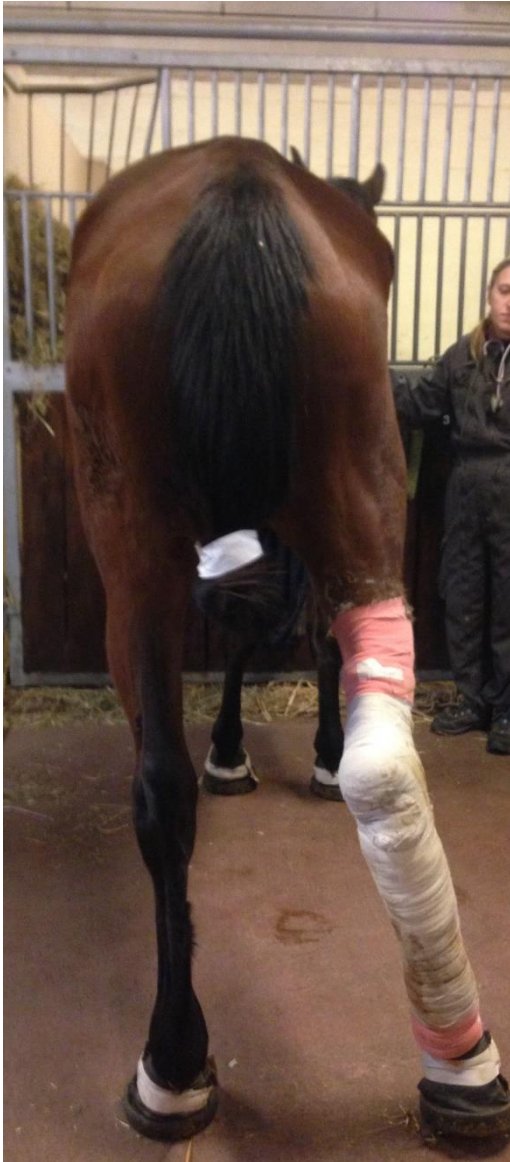On presentation



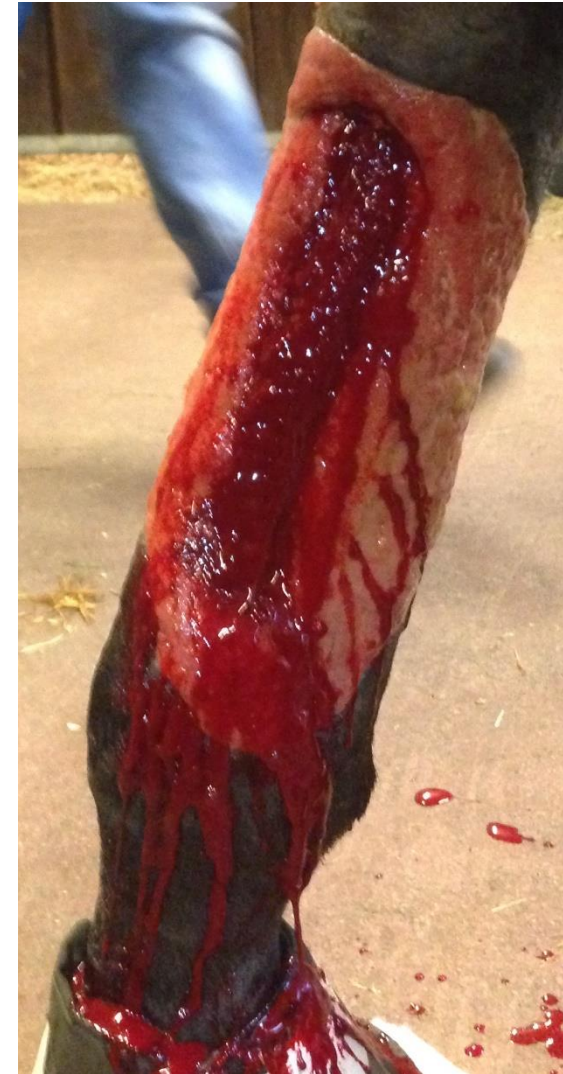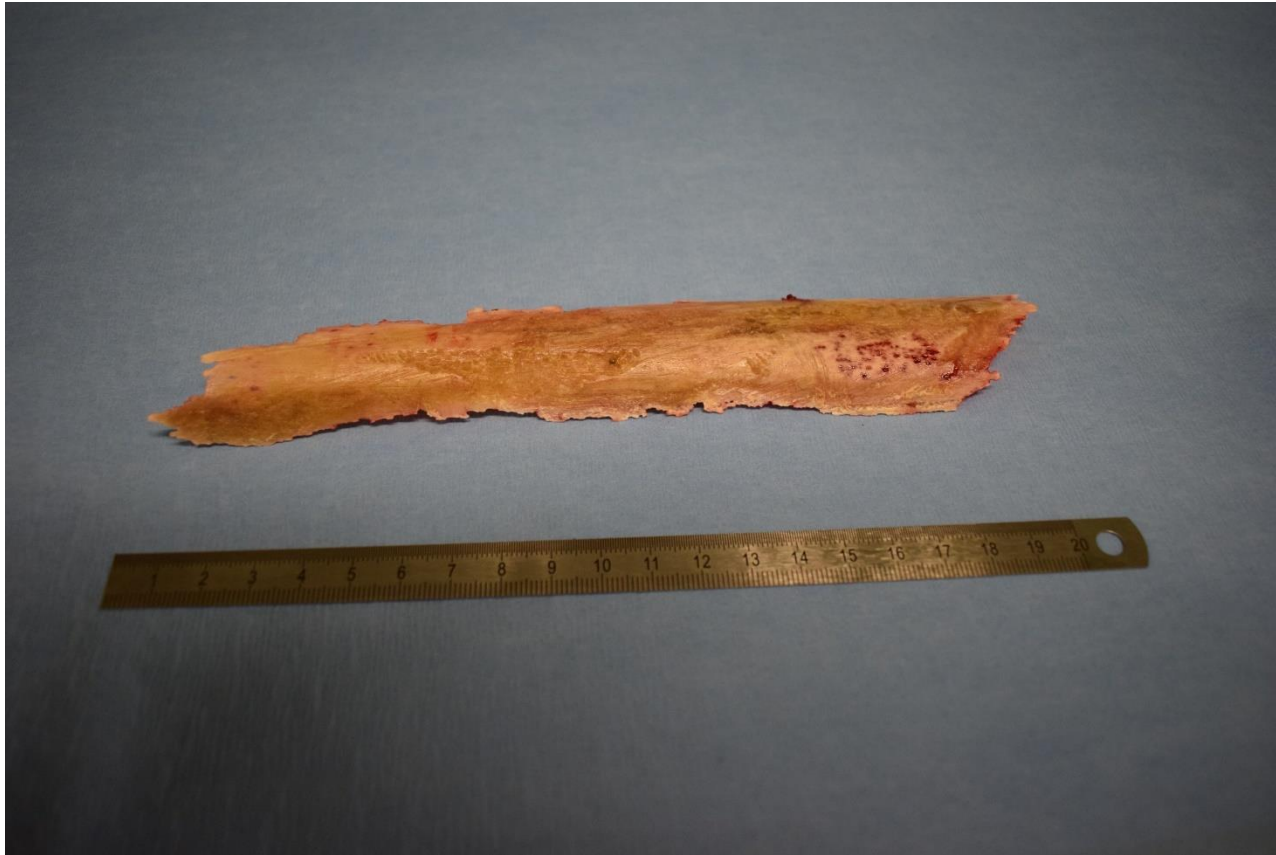After debridement



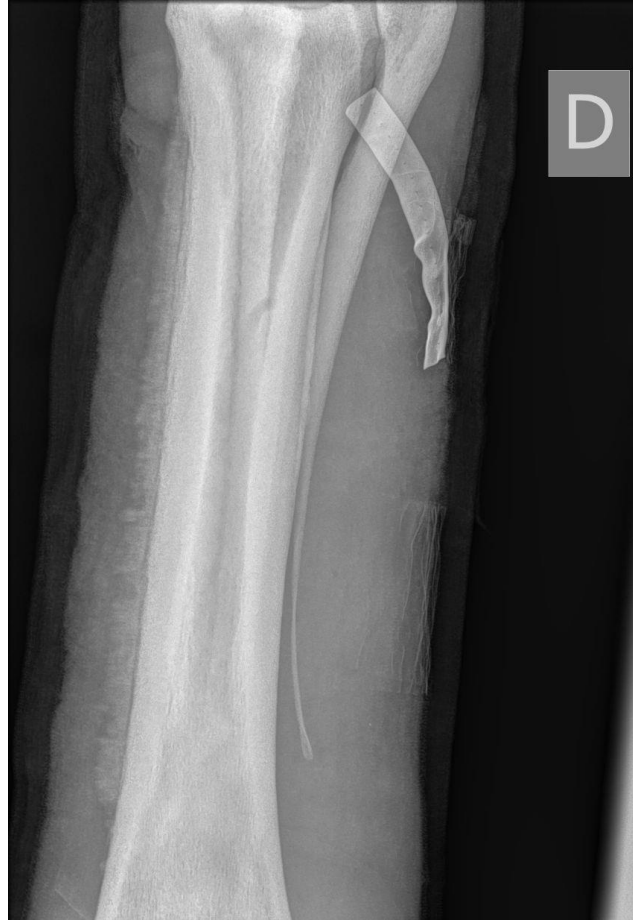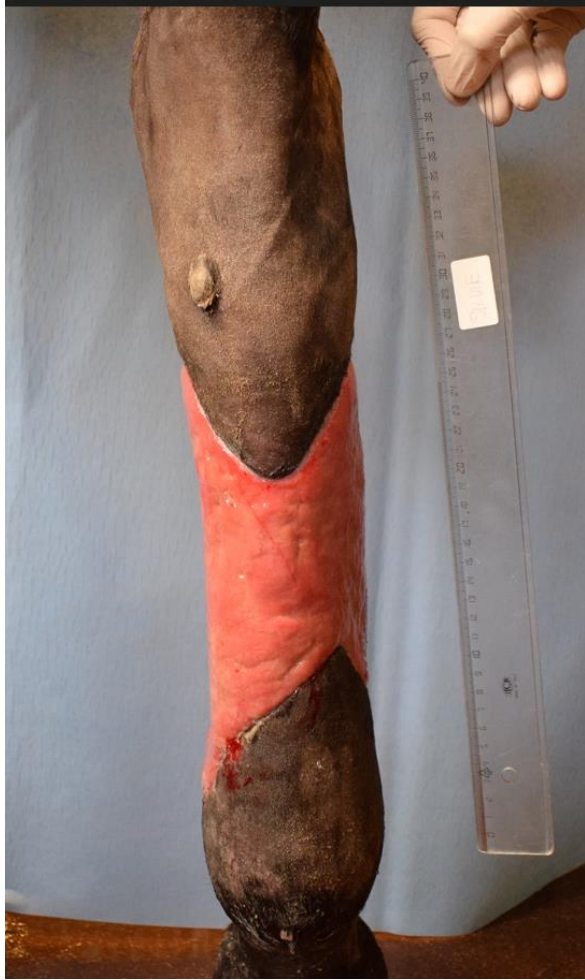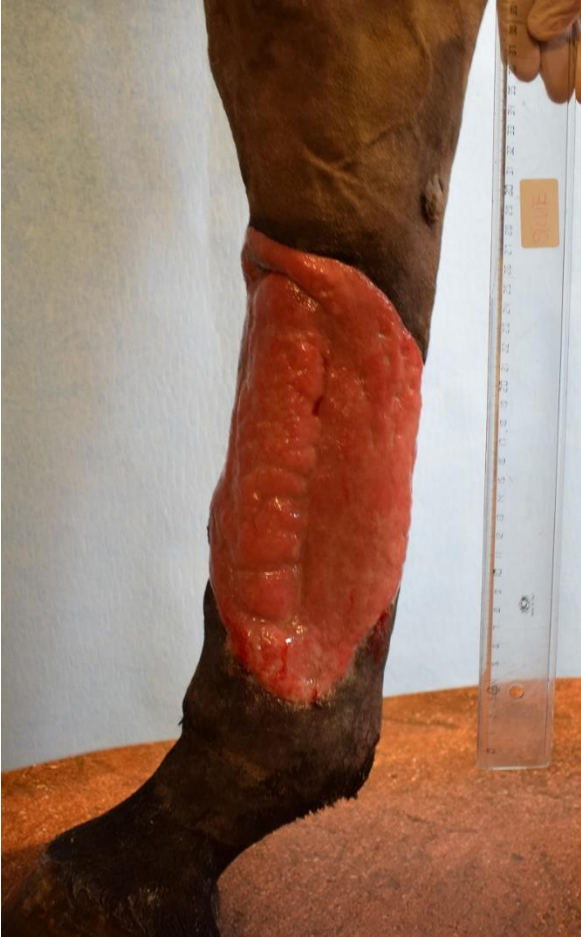# Sequester formation



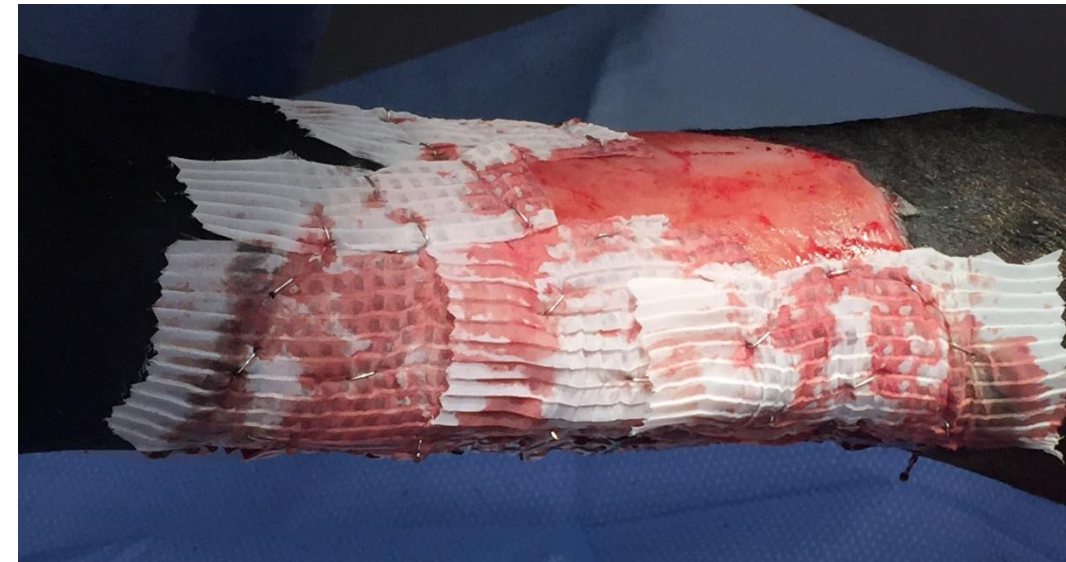
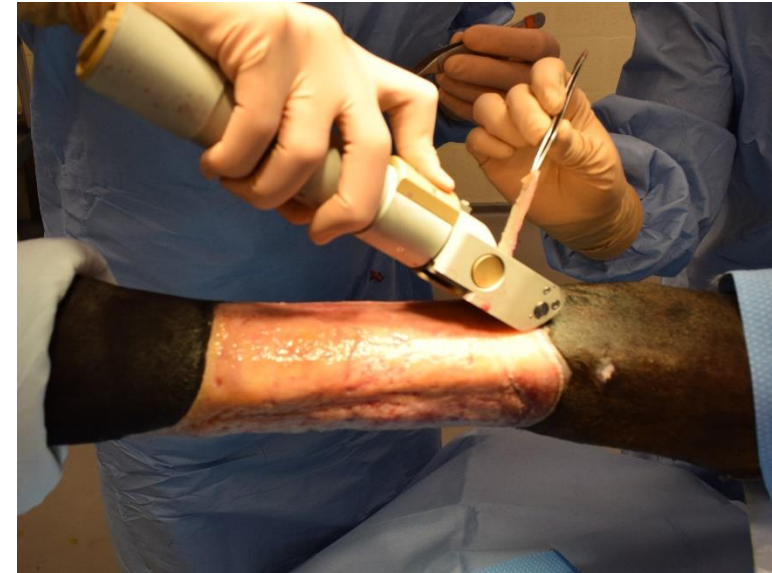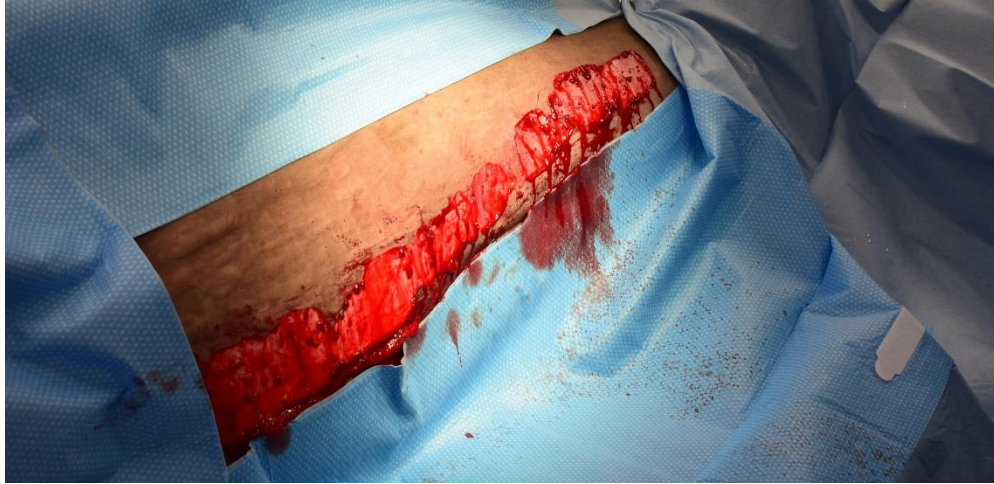# Sequester removal



# Preparation phase for graft

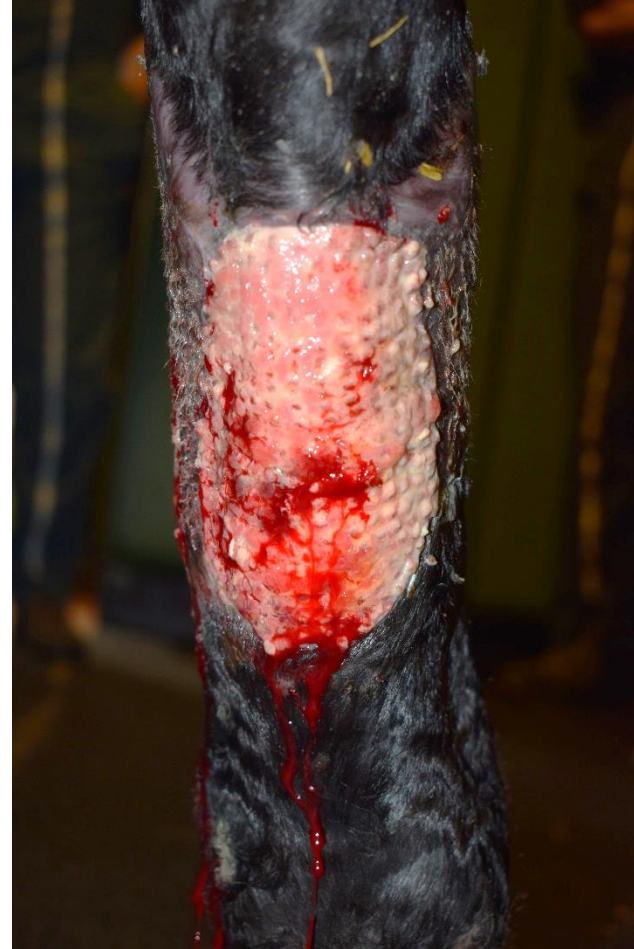
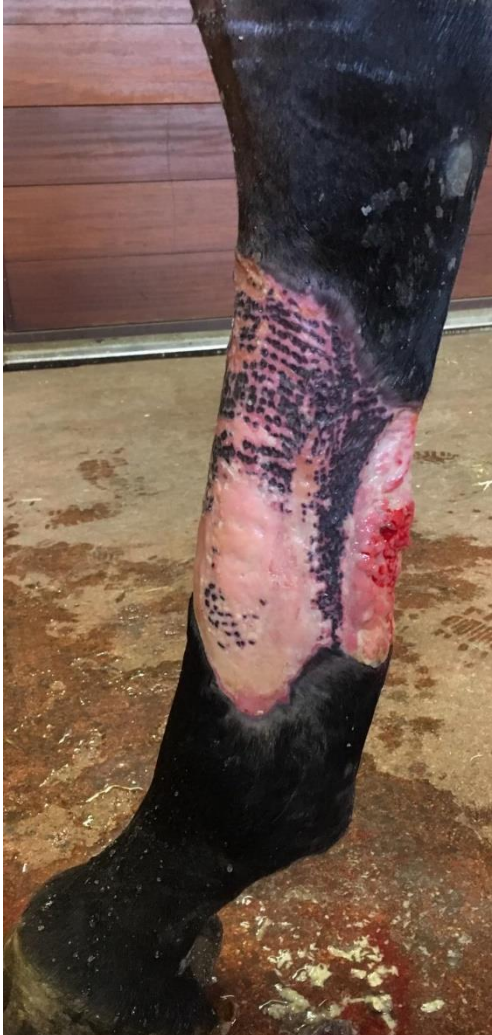
# MEEK micrograft under GA

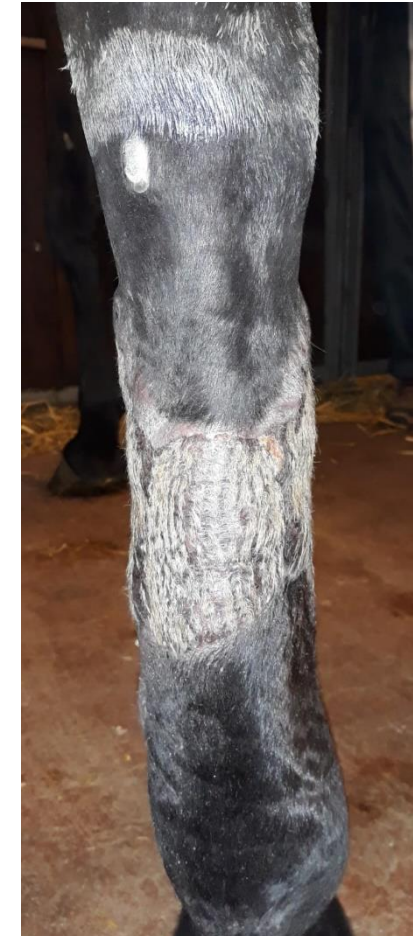

# Short-term complications

Loss of grafts on plantar and dorso-medial aspect of wound → 2<sup>nd</sup> graft



VWHA Milan 2023



# Long-term complication

Itching sensation (pruritus) →  
self trauma

Cause ? periosteal reaction +++  
(skin hydration, intermittent bandaging)

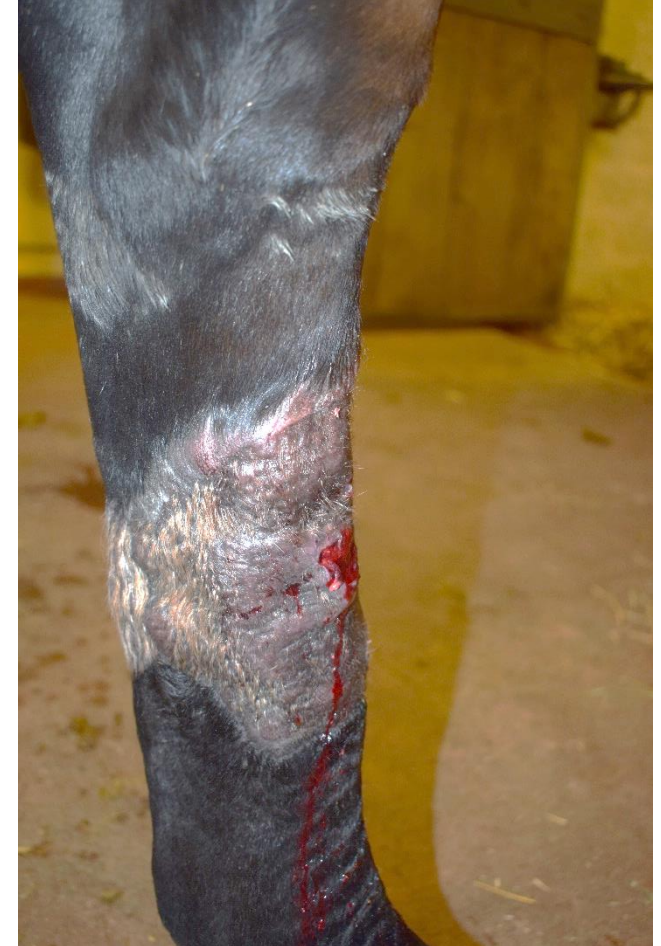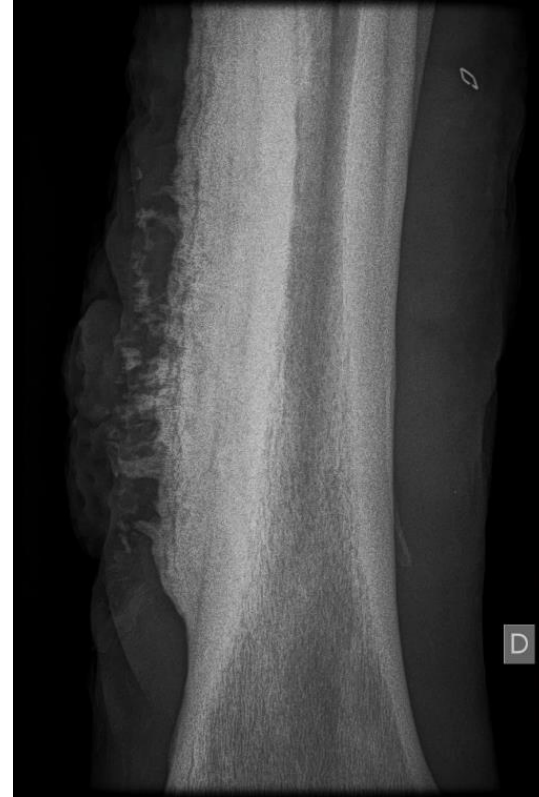resolution within 18 months

Acta Derm Venereol 2015; 95: 451–456

## CLINICAL REPORT

### Itch in Burn Areas After Skin Transplantation: Patient Characteristics, Influencing Factors and Therapy

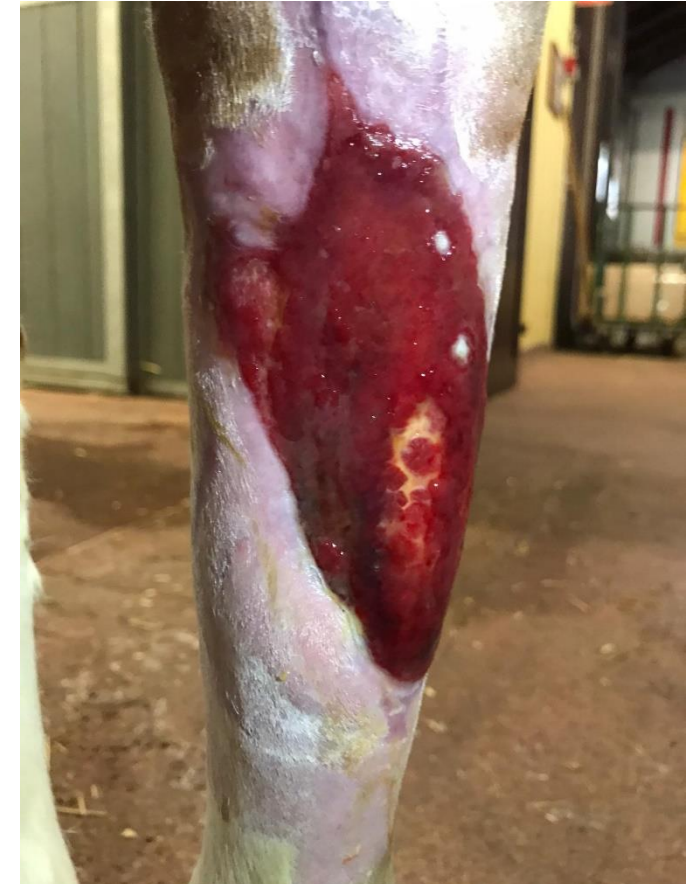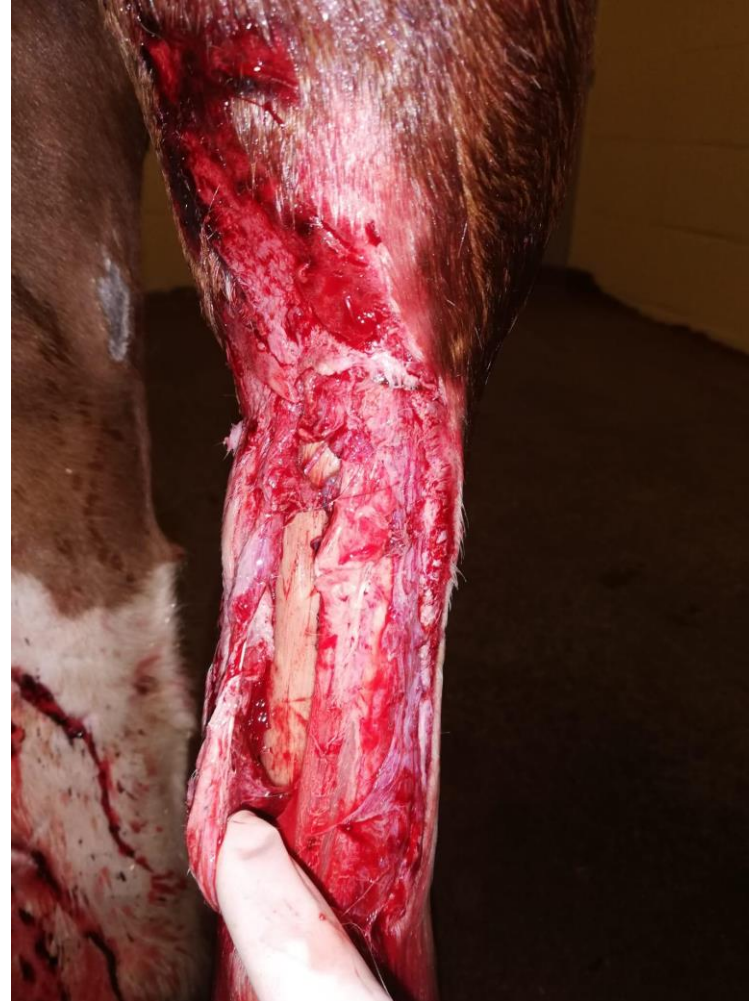Hester C. KUIPERS<sup>1,2</sup>, Marco BREMER<sup>3</sup>, Leen BRAEM<sup>4</sup>, Anne-Sofie GOEMANNE<sup>5</sup>, Esther MIDDELKOOP<sup>2,6</sup> and Nancy E. E. VAN LOEY<sup>6,7</sup>



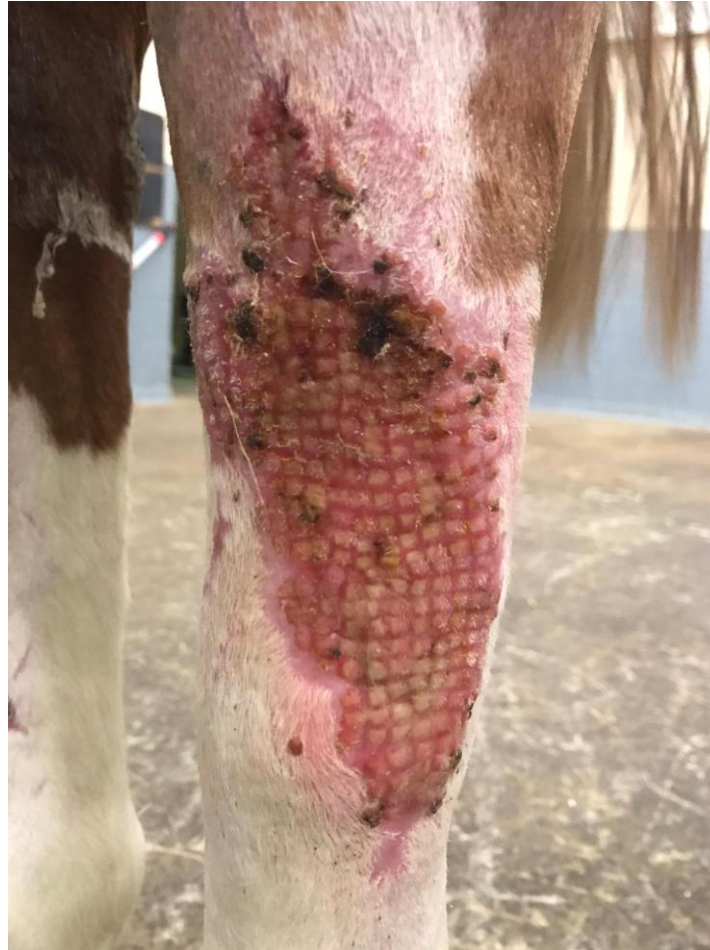
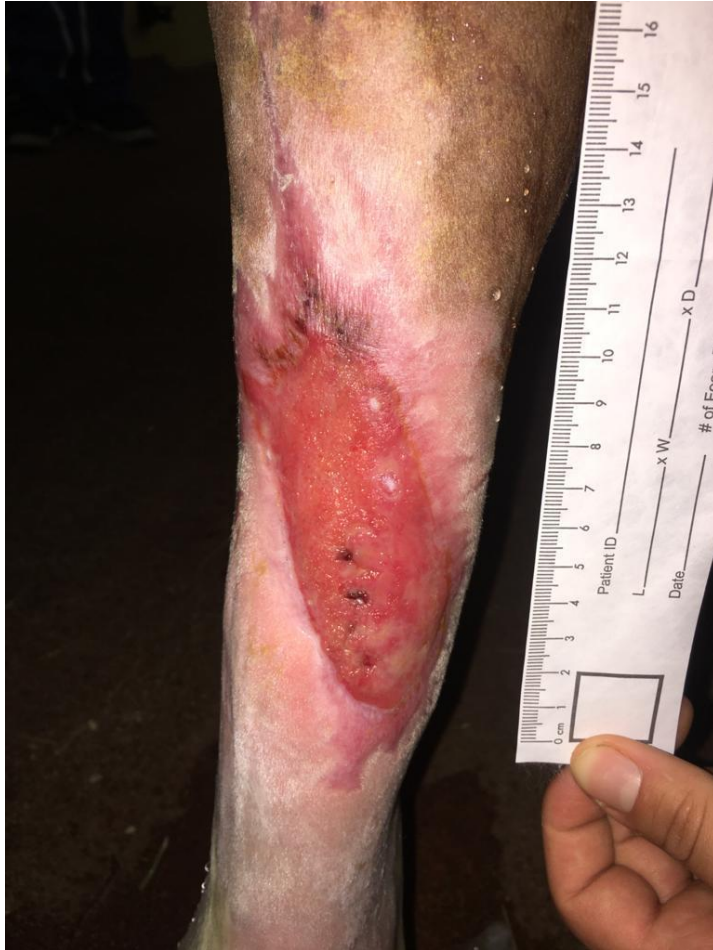
# Wound on dorsal MT/hock

- tibio-tarsal joint opened, bone exposed
- lavage tibio-tarsal joint
- debridement wound
- partial suture
- skin necrosis
- sequester formation
- resorption of sequester



# Wound on dorsal MT/hock



High acceptance rate of grafts

Complete epithelialization in 1 month

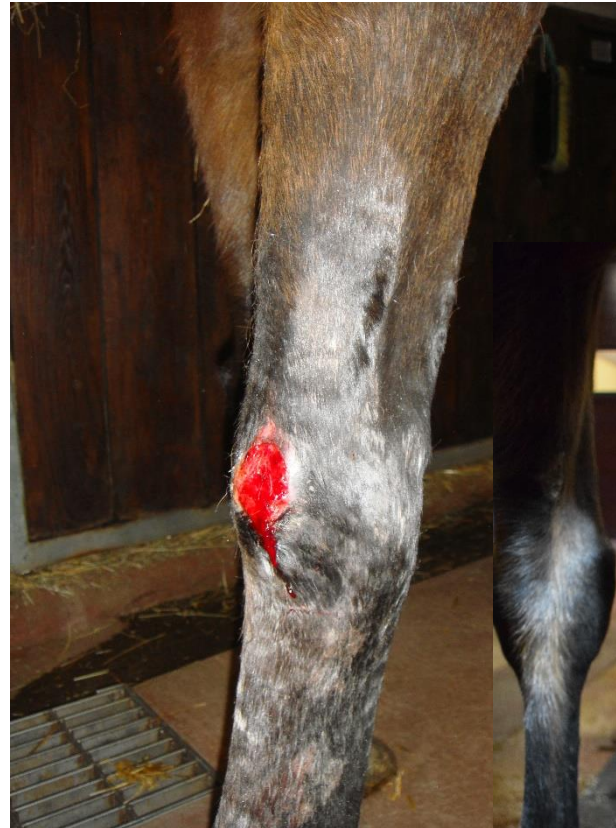Beginning growth of hair

Progressive removal of bandage

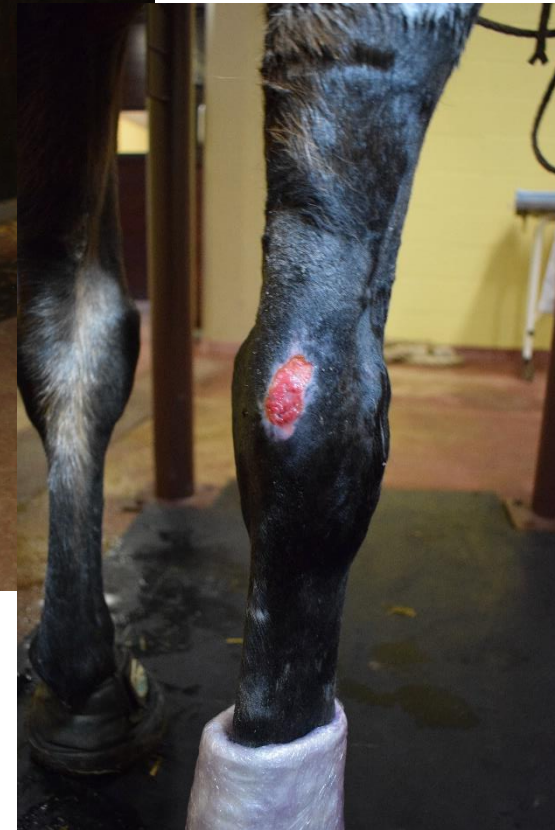Primary healing of donor site

# Chronic pressure sore palmar carpus

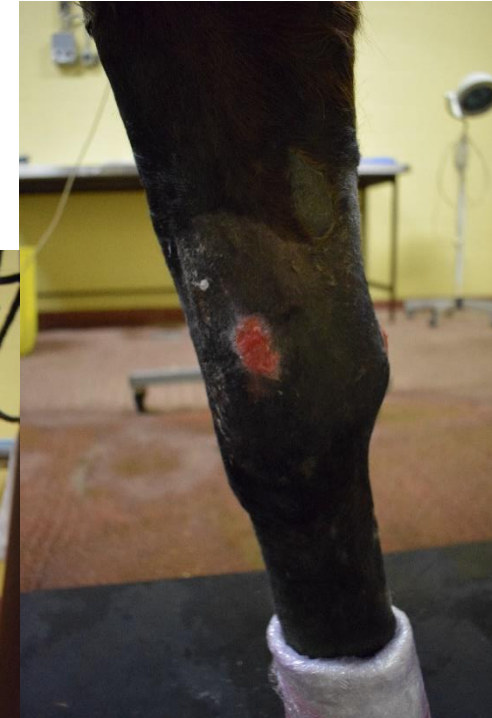- Treatment of wound on medial side of distal radius/carpal joint
- Pressure sore on palmar side on accessory bone
- Non healing for 9 months



On presentation



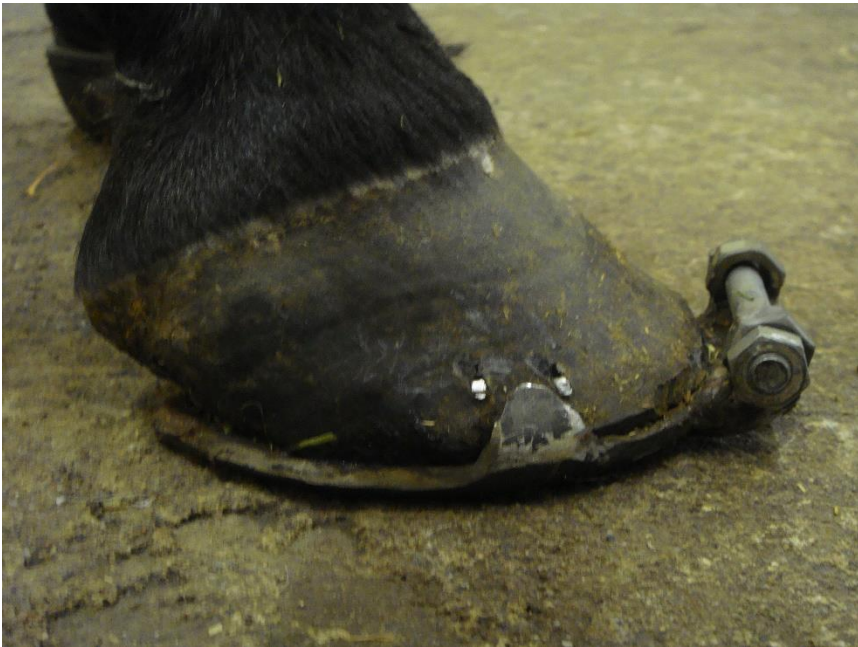After graft preparation



Initial wound

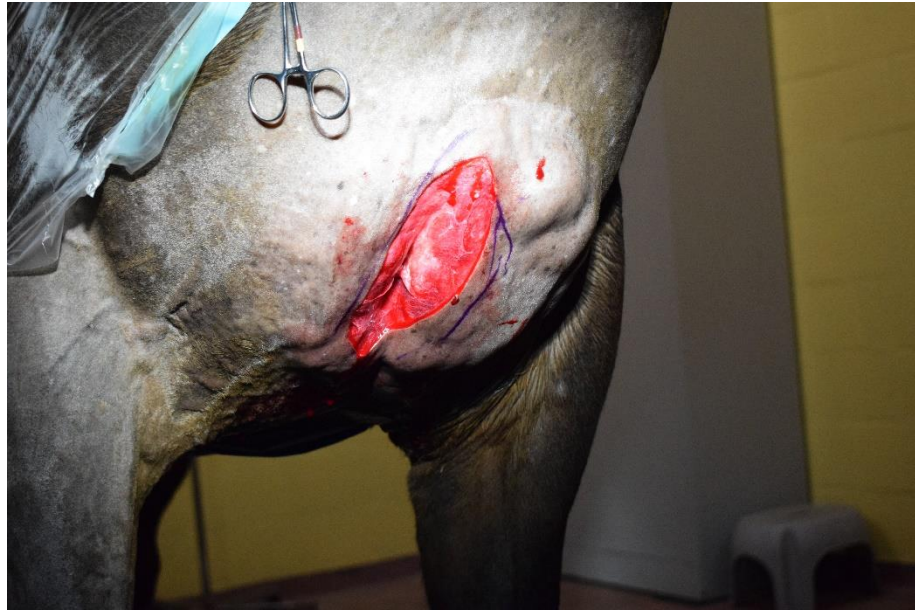# Chronic pressure sore

- Dorsal splint fixed on shoe
- Reduction of movement
- Less pressure on palmar side

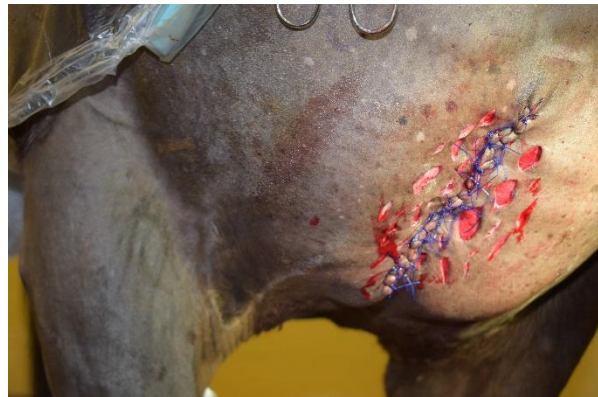

# Graft in standing sedated horse

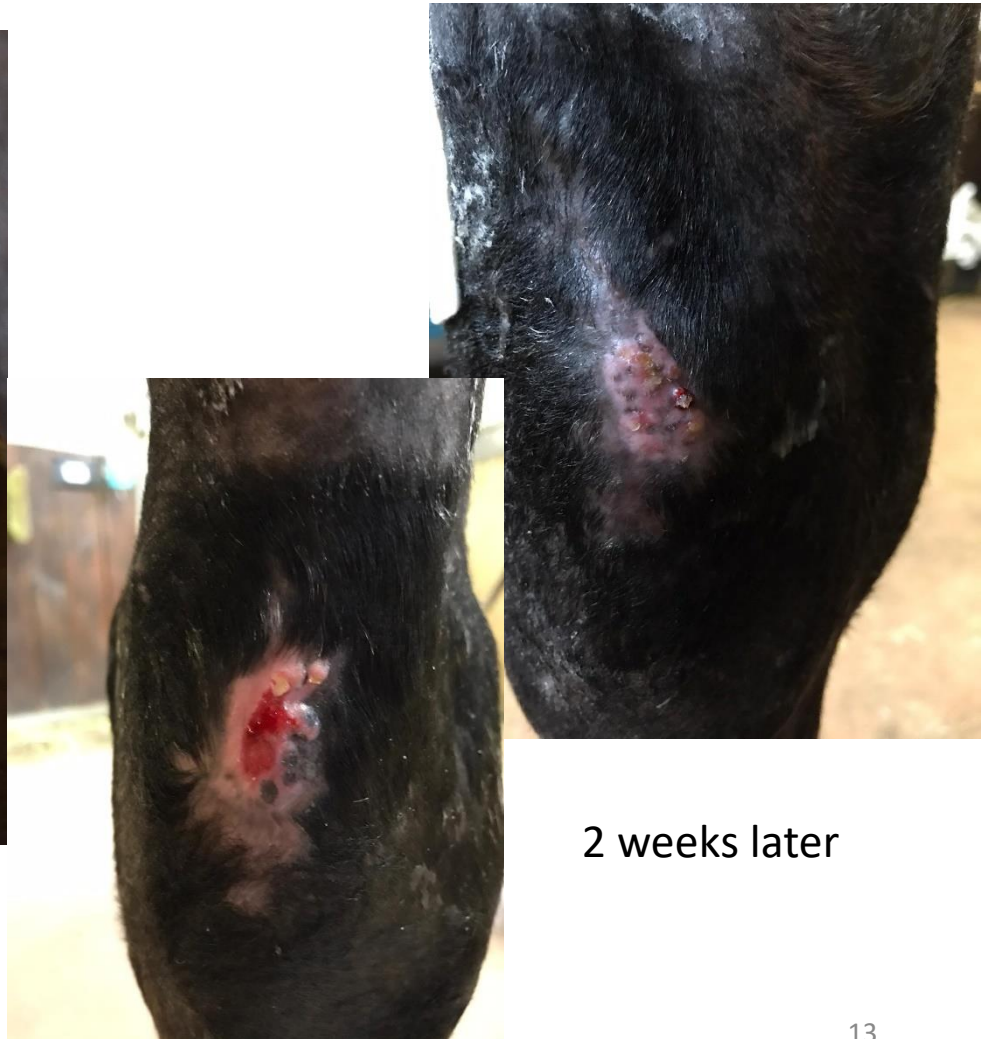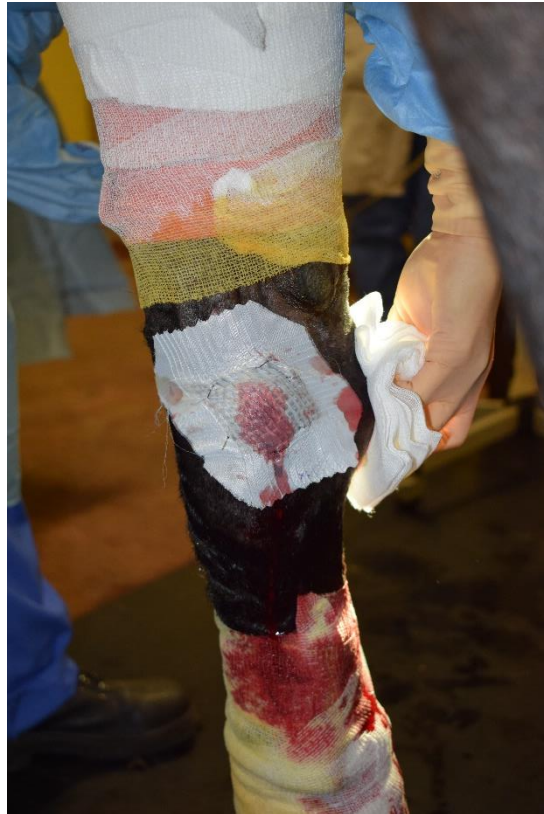Full thickness graft



Primary intention healing of donor site



MEEK graft on pressure sore and initial wound



2 weeks later

# Meek micrografting

Primary intention healing of donor site → no creation of a 2<sup>nd</sup> problematic wound

Healing of extensive limb wound

Quicker return to function

Good to excellent cosmetic result  
(brown coat on limb)

Excellent functional result

Itching ? Only in one case

