



E-ISSN: 2707-8353
P-ISSN: 2707-8345
IJCRO 2023; 5(1): 26-29
www.orthocasereports.com
Received: 06-11-2022
Accepted: 14-12-2022

Crahay Arnaud
Department of Trauma and
Orthopaedics, CHU SART-
TILMAN, Hippocrates
Avenue, Liege, Belgium

Boileau Pascal
ICR-Institut de Chirurgie
Réparatrice Locomoteur and
Sports (Institute For Sports
and Reconstructive Bone and
Joint Surgyré), Nice, France

Thirion Thierry
Department of Trauma and
Orthopaedics, CHU SART-
TILMAN, Hippocrate Avenue,
Liege, Belgium

Mahieu Xavier
Department of Trauma and
Orthopaedics, CHU SART-
TILMAN, Hippocrates
Avenue, Liege, Belgium

Corresponding Author:
Crahay Arnaud
Department of Trauma and
Orthopaedics, CHU SART-
TILMAN, Hippocrates
Avenue, Liege, Belgium

Anterior fracture-dislocation of the glenoid

Crahay Arnaud, Boileau Pascal, Thirion Thierry and Mahieu Xavier

DOI: <https://doi.org/10.22271/27078345.2023.v5.i1a.141>

Abstract

Fractures of the scapula represent less than 1% of all skeletal fractures. This case report describes an unusual case of fracture of the scapula with complete anterior dislocation of the glenoid and pillar of the scapula occurring in the right (dominant) shoulder of a 24-year-old male after a high-energy trauma (motorcycle accident). This fracture is very rare and did not fit in any known classifications (Ideberg, Euler and Rüedi, AO/OTA). The fracture was treated with open reduction and internal fixation through a double approach (deltopectoral and superior). A posterior cruciate ligament (PCL) guide was used to maintain the reduction and insert first a K-wire and then a cannulated screw. We discuss here the mechanism of injury, fracture pattern and the appropriate surgical approach and management in case of such an exceptional anterior fracture-dislocation of the glenoid.

Keywords: Glenoid fracture, scapula fracture, glenoid dislocation, shoulder dislocation, trauma

Introduction

Scapula fractures are uncommon and represent 0.5% to 1% of all skeletal fractures [1-4]. Scapula fractures account for 3%-5% of all shoulder girdle injuries [1-3]. Body fractures are account for about 50% of all scapula fractures [5]. These fractures have traditionally been the result of high-energy trauma and are associated with other multi-system injuries [4]. It's important to understand about their mechanisms, fracture patterns and optimal treatment strategies. A number of classification systems for glenoid and scapula fractures have been described.

In this article, we describe a rare case of anterior fracture-dislocation of the glenoid and pillar of the scapula. We will suggest the injury mechanism, the fracture pattern and our surgical approach to treat this fracture.

Case Report

A 24-year-old, right-handed man presented to the emergency department with right shoulder and scapula pain after a high-energy trauma (motorcycle accident). Physical examination showed deformity of the right shoulder without any neurovascular deficit. Anteroposterior and lateral standard radiographs and CT scan showed a fracture of the scapula with anterior displacement of the glenoid surface and vault with the lateral pillar of the scapula (Fig.1). The fracture line was running in the coronal plane, from the area above the superior edge of glenoid to the lateral border of scapula.

An open reduction and internal fixation were performed, using two surgical approaches: anterior and superior. First, a deltopectoral approach with lesser tuberosity osteotomy (LTO) was used to achieve the reduction of the fracture. The anterior displaced glenoid and pillar fracture was reduced using Homan retractors (Fig. 2A). Then, a superior approach was performed through the trapezius muscle behind the supraspinatus muscle with careful dissection of the suprascapular nerve. A PCL guide, introduced through the superior approach, was placed between the superior and inferior tubercles of the glenoid (Fig. 2B). With the guide in place, the reduction was maintained, and a K-wire was drilled from proximal to distal under fluoroscopic control (Fig. 2C). The reduced glenoid fracture was fixed with a 4.5 mm diameter cannulated screw. The subscapularis tendon was repaired with sutures and anchors. Postoperative radiographs and CT scan showed a perfect reduction of the fracture. The patient was immobilised for four weeks in a neutral rotation brace. After six weeks, active range of motion was authorized. Radiographs and CT-scan after 16 weeks showed complete fracture healing (Fig. 3). The patient achieved good shoulder function with complete range of motion and no pain.

Discussion

This case report presents a rare case of anterior fracture-dislocation of the glenoid and pillar of the scapula. The anterior fracture impaction of the humeral head (reverse Hill-Sachs fracture) suggests that a posterior dislocation of the shoulder occurred. This dislocation leads to anterior fracture and displacement of the glenoid vault with the pillar of the scapula. Posterior shoulder dislocation is infrequent and occurs after a high energy trauma in more than 50% of cases [6]. Associated injuries are very frequent. Humeral fractures were present in more than 30% after posterior shoulder dislocations [6]. As seen on 2D CT-scan with axial cut, the humeral head was perfectly aligned with the body of scapula (Fig. 1C). This is why we have called this fracture: anterior fracture-dislocation of the glenoid. This glenoid neck fracture still attached to the scapular lateral pillar is very unusual and rare. To achieve a precise diagnosis and possible associated injuries, radiographs and Ct scan should be performed. 3D reconstruction of CT imaging can be very

helpful to understand the fracture pattern [4]. An open reduction and internal fixation were performed, using two surgical approaches. Deltopectoral approach was necessary to reduce. The glenoid fossa and lateral pillar were displaced anteriorly, so it was impossible with a posterior approach (Judet) to obtain an anatomical reduction. The superior approach was necessary for the fixation with screw. We thought it necessary to perform an open superior approach to avoid the risk of suprascapular nerve damage. We use the AO/OTA classification scapula fracture classification system focus on glenoid and body involvement, but this fracture is not described [1, 2, 8]. Generally, every glenoid fracture is classifiable in the AO/OTA classification [1-3]. The Ideberg-Goss classification is still widely used with six general fracture types [8]. We also used the Euler and Rüedi classification which has five subdivisions and fracture patterns which can be combined [3, 5, 9, 10]. We have not been able to classify the patient's fracture with these widely used three classifications.

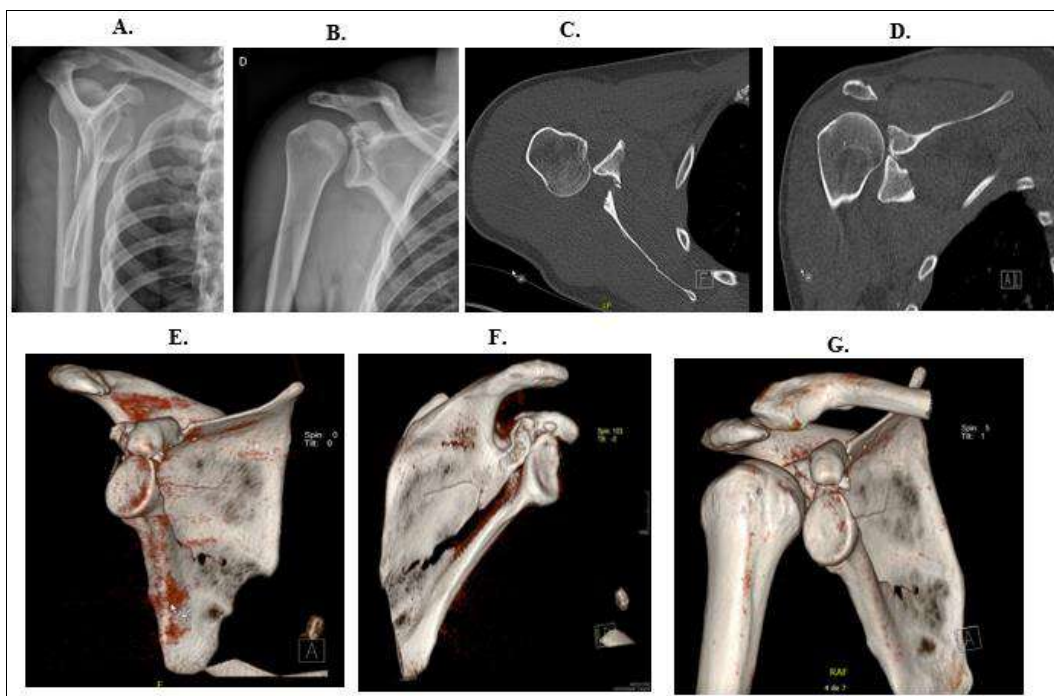


Fig 1: Radiographs and CT scan with 3D reconstructions are showing anterior displacement of the glenoid surface and vault together with the lateral pillar of the scapula.

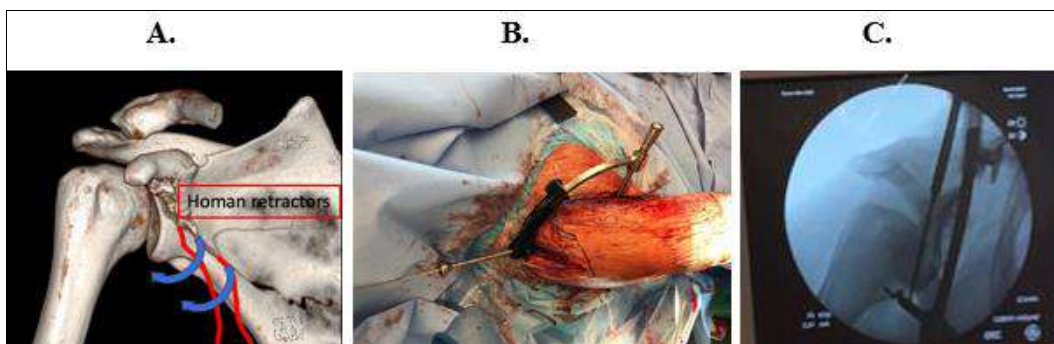


Fig 2: The fracture was reduced through a deltopectoral approach with LTO using Homan retractors (2A); a PCL guide was introduced through a superior approach and placed between the superior and inferior tubercles of the glenoid (2B); the reduction was maintained by the PCL guide, a K-wire was drilled from superior to inferior. This allowed to fix the fracture with a 4.5 mm cannulated screw (2C).

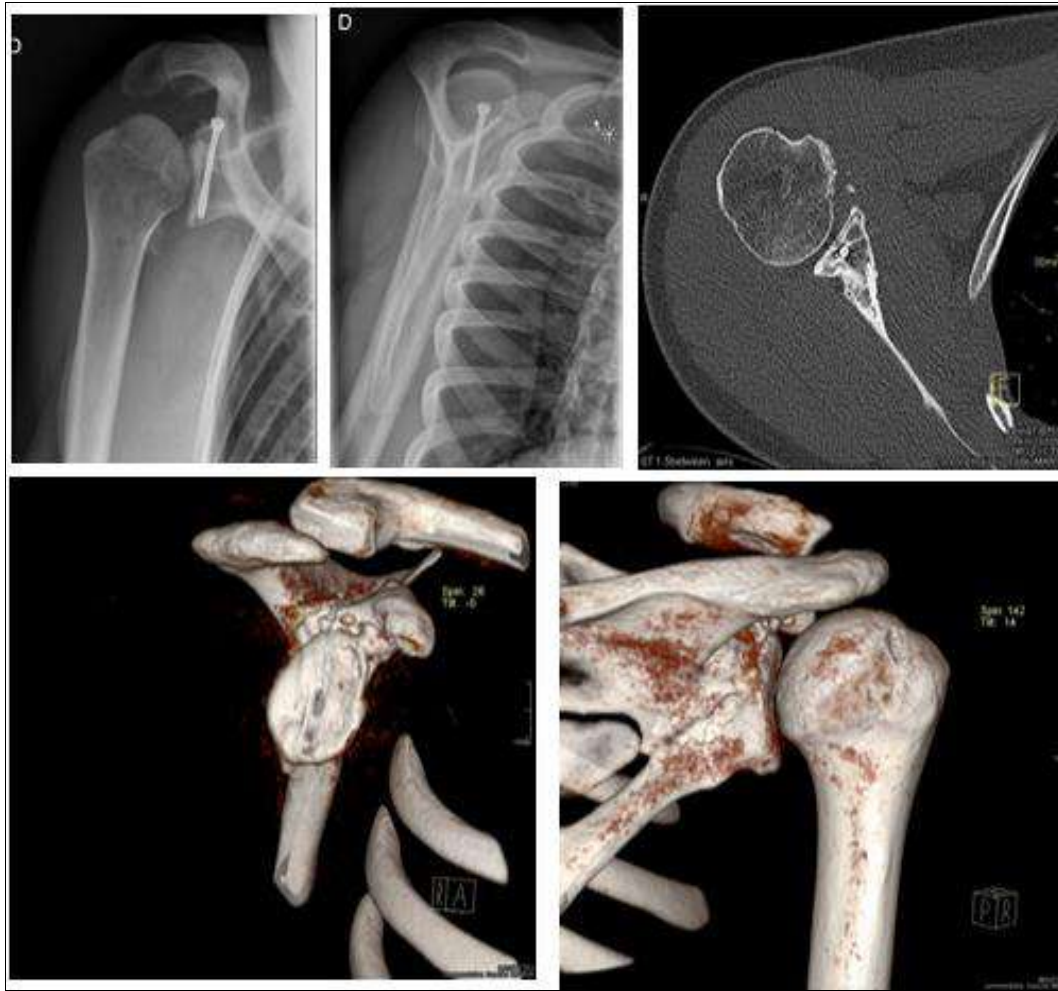


Fig 3: 16 weeks after surgery: AP and lateral radiographs and CT scan.

Conclusion

In summary, we report an unusual case of fracture of the scapula which, to the best of our knowledge, has never been described before and did not fit in any known classification of scapula fractures. This fracture involves anterior displacement of the glenoid surface and vault with the pillar of the scapula. We hypothesize that this fracture occurred after a posterior dislocation of the humeral head leading first to a posterior dislocation of the humeral head and thereafter to an anterior fracture pivot displacement of the glenoid and the lateral pillar of the scapula. The use of CT-scan with 3D reconstruction was useful to understand the mechanism of injury and plan the surgical management. We used an anterior and superior approaches and not a posterior approach. The patient obtained excellent radiological and clinical results.

Funding

The authors declare no funding.

Declaration of competing interest

The authors declare no conflict of interest.

References

1. Jaeger M, Lambert S, Südkamp NP, Kellam JF, Madsen JE, Babst R, *et al.* The AO Foundation and Orthopedic Trauma Association (AO/OTA) scapula fracture classification system: Focus on glenoid fossa involvement. *J Shoulder Elbow Surg.* 2013;22(4):512-20.
2. Audigé L, Kellam JF, Lambert S, Madsen JE, Babst R, Andermahr J, *et al.* The AO foundation and orthopedic trauma association (AO/OTA) scapula fracture classification system: Focus nobody involvement. *J Shoulder Elbow Surg.* 2014;23(2):189-96.
3. Gilbert F, Eden L, Meffert R, Konietzschke F, Lotz J, Bauer L, *et al.* Intra- and interobserver reliability of glenoid fracture classifications by Ideberg, Euler and AO. *BMC Musculoskeletal Discord.* 2018;19(1):27.
4. Rollo G, Huri G, Meccariello L, Familiari F, Çetik RM, Cataldi C, *et al.* Scapular body fractures: Short-term results of surgical management with extended indications. *Injury.* 2021;52(3):481-6.
5. Van Oostveen DPH, Temmerman OPP, Burger BJ, van Noort A, Robinson M. Glenoid Fractures: A review of pathology, classification, treatment and results. *Acta Orthoepy Belg.* 2014;80:88-98.
6. Parapodium's G, Iliopoulos E, Narvani AA, Levy O, Tsiridis E, Polyzois I. Posterior shoulder fracture-dislocation: A systematic review of the literature and current aspects of management. *Chinese Journal of Traumatology - English Edition.* 2021;24(1):18-24.
7. Gilbert F, Eden L, Meffert R, Konietzschke F, Lotz J, Bauer L, *et al.* Intra- and interobserver reliability of glenoid fracture classifications by Ideberg, Euler and AO. *BMC Musculoskeletal Discord.* 2018;19(1):27.

8. Ideberg R, Grevsten S, Larsson S. Epidemiology of scapular fractures Incidence and classification of 338 fractures. Vol. 66, Acta Ortho Scand; c1995.
9. Seidl AJ, Joyce CD. Acute Fractures of the Glenoid. The Journal of the American Academy of Orthopaedic Surgeons NLM (Medline). 2020;28:e978-87.
10. Wiedemann E. Frakturen der skapula. Unfallchirurg 2004;107(12):1124-33.

How to Cite This Article

Arnaud C, Pascal B, Thierry T, Xavier M. Anterior fracture-dislocation of the glenoid. International Journal of Case Reports in Orthopaedics. 2023;5(1):26-29.

Creative Commons (CC) License

This is an open access journal, and articles are distributed under the terms of the Creative Commons Attribution-Non Commercial-Share Alike 4.0 International (CC BY-NC-SA 4.0) License, which allows others to remix, tweak, and build upon the work non-commercially, as long as appropriate credit is given and the new creations are licensed under the identical terms.