

# Bilateral contracture of the carpal and digital flexor muscles resulting in carpal flexural deformity in a cat

*Journal of Feline Medicine and Surgery Open Reports*  
1–8

© The Author(s) 2023

Article reuse guidelines:

sagepub.com/journals-permissions

DOI: 10.1177/20551169231160226

journals.sagepub.com/home/jfmsopenreports

This paper was handled and processed by the European Editorial Office (ISFM) for publication in *JFMS Open Reports*



Emily Vrijsen<sup>1,2</sup>, Martin Hamon<sup>1</sup>, Pierre Picavet<sup>1</sup>, Bernard Bouvy<sup>1</sup> and Marc Balligand<sup>1</sup>

## Abstract

**Case summary** A 12-year-old neutered female domestic shorthair cat was presented with bilateral progressive forelimb lameness that was unresponsive to anti-inflammatory drugs. Bilateral carpal flexural deformity with hyperflexion of multiple toes of the right forelimb was observed. In the absence of abnormalities detected on radiographs and ultrasound, a bilateral contracture of the carpal and digital flexor muscles was diagnosed. Treatment consisted of single-session bilateral selective tenectomies (5 mm) of the flexor carpi ulnaris, flexor carpi radialis and superficial digital flexor muscle tendons on the left forelimb and tendons of the flexor carpi ulnaris muscle, and branches of the third and fourth digit of the deep digital flexor muscle on the right forelimb. Two months postoperatively, selective tenectomies (10 mm) were performed due to contracture recurrence on the left forelimb. The subjective outcome was rated as good 6 months postoperatively.

**Relevance and novel information** Digital and/or carpal contractures are rarely described in (feline) veterinary medicine and are limited to a few case reports. The exact aetiology remains unknown. A traumatic/iatrogenic origin seems to be the most likely cause. Surgery is indicated, consisting of selective tenectomy and/or tenotomy, and is associated with minor complications and an excellent outcome. This case report describes the presence, treatment and successful outcome of a cat with bilateral carpal and digital flexor muscle contractures resulting in carpal flexural deformity with valgus deviation treated with selective tenectomies.

**Keywords:** Bilateral contracture; flexor muscles; carpal flexural deformity; selective tenectomy; outcome

**Accepted:** 9 February 2023

## Case description

A 12-year-old female neutered domestic shorthair cat was referred to our institution with slowly progressive bilateral forelimb lameness and a decreased range of motion (ROM) in extension of both carpal joints. No history of trauma, nor surgical intervention was reported. Clinical signs started 10 months prior to referral, consisting of right forelimb lameness that evolved, into carpal hyperflexion with a lack of carpal extension. Medical treatments were instigated by the referring veterinarian, including the use of steroidal (methylprednisolone 0.5 mg/kg q24h PO [Moderin; Zoetis]) and non-steroidal anti-inflammatory drugs (meloxicam 0.05 mg/kg q24h PO [Metacam; Boehringer Ingelheim]), but both were unsuccessful. Six months after signs were noted on the right forelimb, similar clinical signs were noted on the left forelimb.

Physical examination was unremarkable, except for the presence of generalised moderate muscle atrophy of both forelimbs detected on palpation. Neurological examination was unremarkable. The cat was reluctant to move, and a carpal flexural deformity (CFD) with a certain degree of distal valgus deviation, which was more pronounced on the left side, was noted (Figure 1).

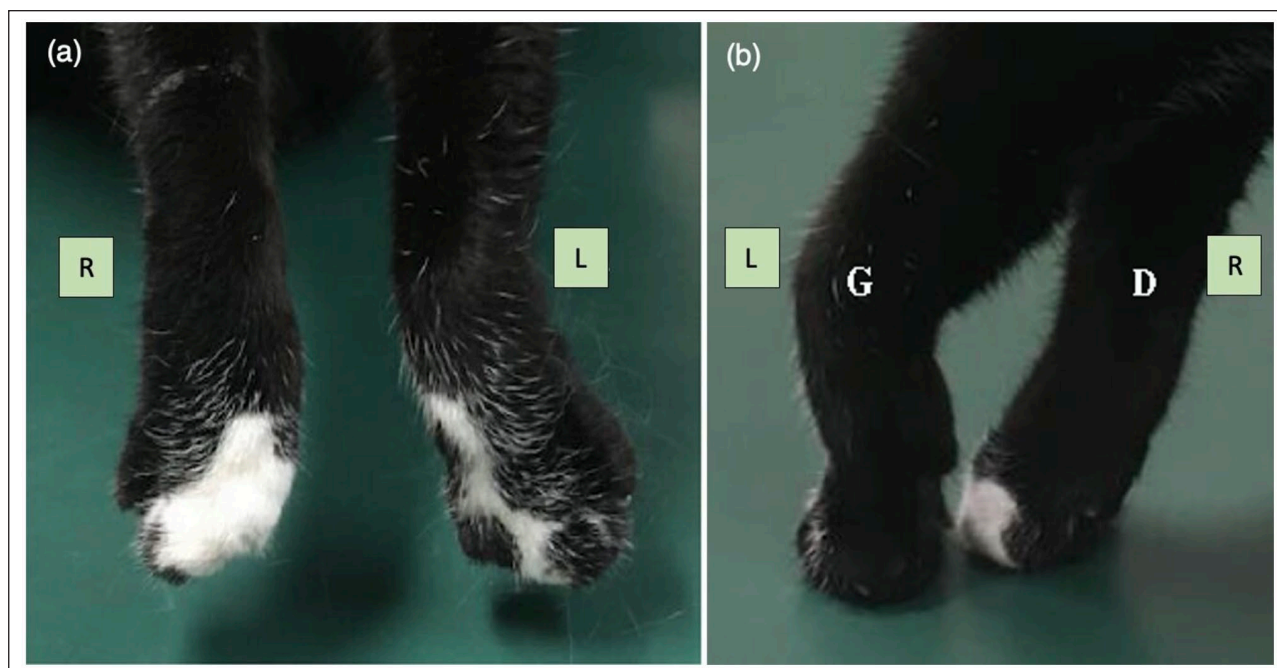
<sup>1</sup>Department of Clinical Sciences, FARAH, Faculty of Veterinary Medicine, University of Liège, Liège, Belgium

<sup>2</sup>Small Animal Department, Faculty of Veterinary Medicine, Ghent University, Merelbeke, Belgium

### Corresponding author:

Emily Vrijsen DVM, Small Animal Department, Faculty of Veterinary Medicine, Ghent University, Salisburylaan 133, Merelbeke 9820, Belgium  
Email: emily.vrijsen@ugent.be





**Figure 1** (a) Forelimbs without constraint demonstrating the presence of a carpal flexural deformity secondary to muscle contracture. A certain degree of valgus deviation is present due to hyperflexion of the carpus and digits, more pronounced in the left (L) forelimb and (b) forelimbs during stance, demonstrating an abnormal carpal flexion that is more pronounced in the left forelimb. R=right

A subtle permanent flexion of the digits II–V was observed, which was more pronounced on the right forelimb. A firm, non-painful induration of the flexor retinaculum was palpated, secondary to the tension of the tendons at this level, compromising carpal ROM in extension. The hyperflexion and valgus deviation were irreducible, and an increased tension of the flexor muscles, in particular the flexor carpi ulnaris muscle (FCUM) at its insertion onto the accessory bone, could be palpated. No other abnormalities were palpated at the level of the flexor muscles bellies.

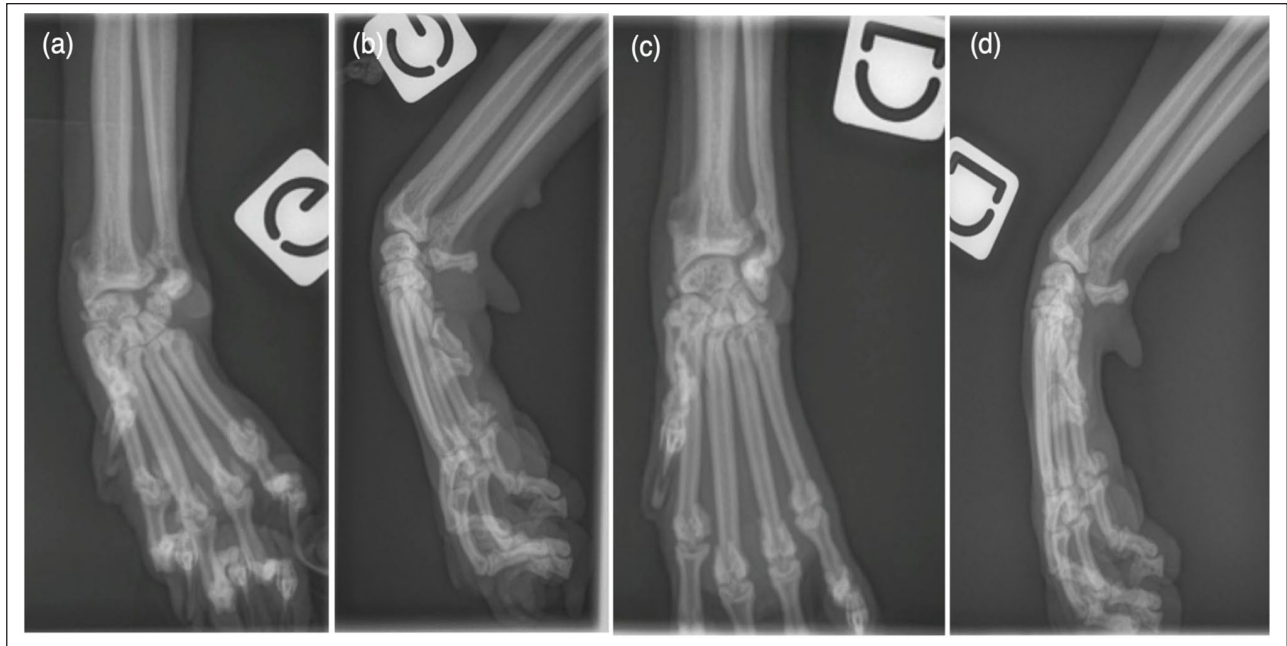Blood urea nitrogen, creatinine, creatine kinase and total thyroxine values were within the reference intervals. Orthogonal radiographs of both forelimbs demonstrated a valgus deviation of the distal extremities (Figure 2). Ultrasound of the musculature and corresponding tendons of both forelimbs was performed, but no abnormalities were identified.

Owing to the severity of the clinical signs and the cat's discomfort, surgery consisting of a selective tenectomy of the contracted flexor muscles was proposed. The cat was premedicated with methadone (0.2 mg/kg IV [Comfortan; Dechra]), and induced with midazolam (0.3 mg/kg IV [Dormazolam; Dechra]) and alfaxalone (Alfaxan; Jurox Animal Health) to effect. Anaesthesia was maintained with 1–2% isoflurane in 100% oxygen, alongside a continuous rate infusion of fentanyl (5–12 µg/kg/h IV [Fentadon; Dechra]). The patient

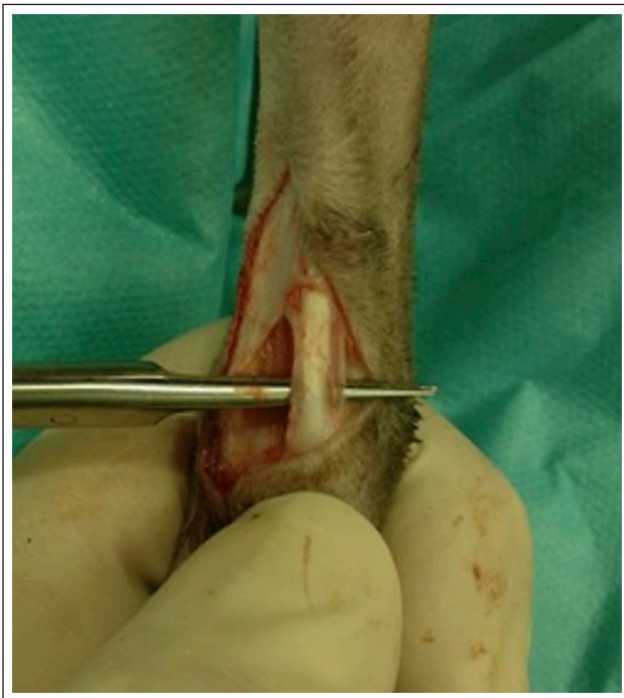received lactated Ringer's solution (10 ml/kg/h IV) intraoperatively. Cefazoline (20 mg/kg IV [Cefazoline; Sandoz]) was administered every 90 mins. The patient was positioned in dorsal recumbency with the palmar surface of both forelimbs toward the surgeon. On the left forelimb, a palmarolateral skin incision of 4 cm was made, proximal to the antebrachio-carpal joint, followed by blunt dissection to expose the flexor muscle tendons. The tendons of the FCUM, flexor carpi radialis muscle (FCRM) and superficial digital flexor muscles (SDFMs) were isolated, and resection of a 5 mm long segment of these tendons was performed using a #11 scalpel blade. The tenectomies were performed in following order: first the FCUM, then the FCRM and finally the SDFM. A progressive resolution of the carpal hyperflexion was noted during the tenectomies.

On the right forelimb, a tenectomy of the FCUM tendon was performed via a curvilinear skin incision starting palmaromedial to palmarolateral and proximal to the right antebrachio-carpal joint (Figure 3).

Small skin incisions were made at the palmar surface of the second phalanx of the third and fourth digits of the right forelimb, allowing for selective tenectomy of the tendon branches of the deep digital flexor muscle (DDFM) of these digits (Figure 4). The tendon branches of the remaining digits were left intact, as these are not the major weightbearing digits, and we did not want to be too invasive. Muscular and tendinous



**Figure 2** Orthogonal radiographs of both forelimbs demonstrating the presence of a carpal flexural limb deformity with a certain degree of valgus deviation of the distal extremities starting from the carpal joint and hyperflexion of the digits. (a) Dorsopalmar radiograph of the left forelimb; (b) lateral radiograph of the left forelimb; (c) dorsopalmar radiograph of the right forelimb; and (d) lateral radiograph of the right forelimb



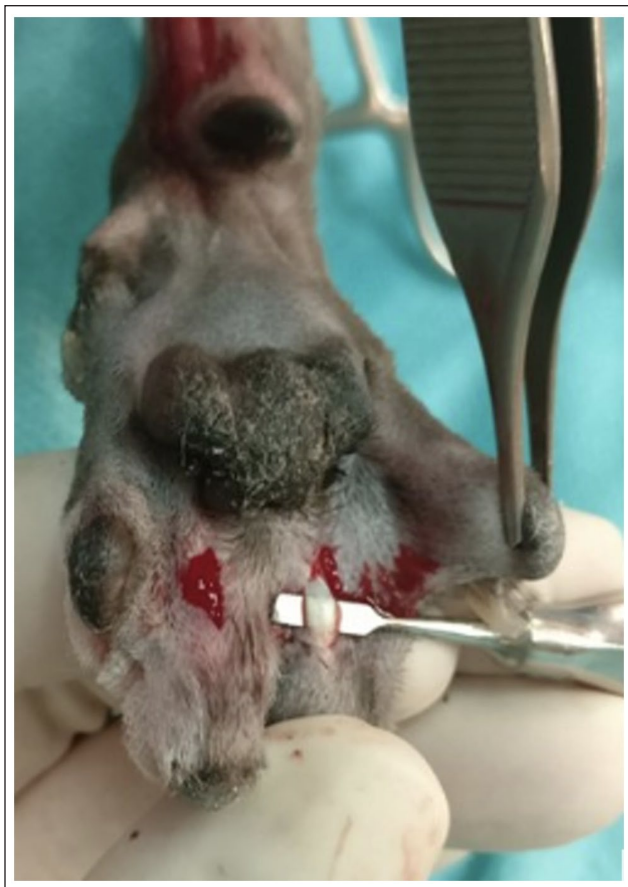**Figure 3** Intraoperative photograph before a tenectomy of the flexor carpi ulnaris muscle tendon of the right forelimb was performed. A palmaromedial to palmarolateral approach was used just proximal to the antebrachioacarpal joint. The tendon of the flexor carpi ulnaris muscle is highlighted with the surgical instrument

biopsies of all sectioned tendons and associated muscles were taken intraoperatively. The subcutaneous tissues were closed using a simple continuous pattern with a 4-0 poliglecaprone 25 suture (Monocryl; Ethicon). The skin was apposed with an interrupted suture pattern with 4-0 polyamide (Ethilon II; Ethicon).

A bandage with the carpal joints at the maximal angle of extension was placed during the first 12h postoperatively, and treatment with meloxicam (0.1 mg/kg q24h IV [Acticam; Eucuphar]) was initiated. Postoperative recovery was uneventful. Twelve hours postoperatively, a certain degree of hyperflexion of the carpal joints and a moderate bilateral forelimb lameness persisted (Figure 5). The cat was discharged 24h postoperatively with meloxicam (0.05 mg/kg q24h PO for 5 days [Metacam; Boehringer Ingelheim]). Histopathology of the sectioned tendons revealed minimal leukocytic infiltration, compatible with peripheral chronic inflammation; however, an ischaemic aetiology could not be excluded. Histopathology of the muscles showed minimal signs of atrophy.

One month postoperatively, the cat was still moderately lame on the left forelimb with a partial palmigrade stance and a slight retraction of the second and fifth digits. An improvement in locomotion quality was noted by the owner.

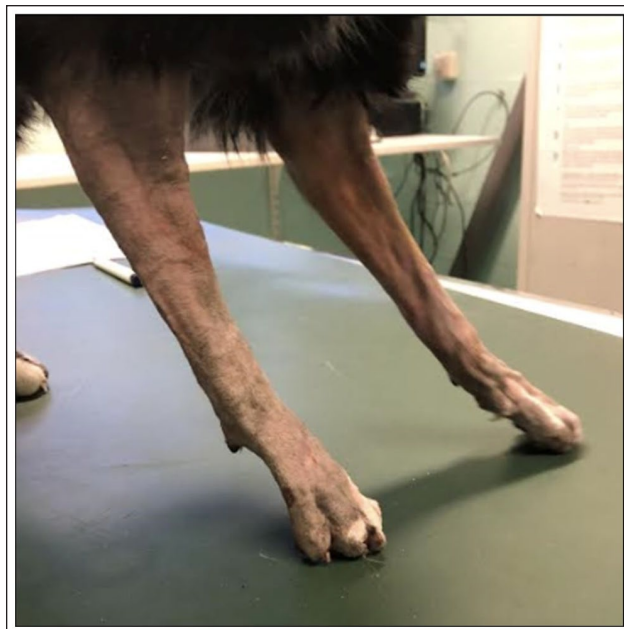Two months postoperatively, the cat presented with recurrence of clinical signs on the left forelimb, characterised by hyperflexion of the carpus and digits



**Figure 4** Intraoperative visualisation of the small skin incisions made at the palmar surface of the second phalanx of the third and fourth digit of the right forelimb, allowing for selective tenectomy of the tendon branches of the deep digital flexor muscle (elevated by a periosteal elevator)

two, three and four, and valgus deviation. The region of the flexor retinaculum was again indurated due to tendons in tension. No abnormalities were observed on the right forelimb. A selective tenectomy was repeated on the left forelimb. The same anaesthetic protocol and surgical approach, as mentioned above, were used. Fibrous tissue connecting both ends of the tendon was present at the previous tenectomy sites. More tenectomies were performed over a length of 10 mm of the tendons of the FCUM, FCRM and SDFM proximally to the antebrachio-carpal joint. Also, the tendon branches of the DDFM of the second, third and fourth digits were sectioned. Twenty-four hours postoperatively, the lameness had improved slightly. The cat was discharged with meloxicam (0.05 mg/kg q24h for 7 days [Metacam; Boehringer Ingelheim]).

Follow-up after the second intervention occurred by phone contact. One month after the second intervention, the cat was free of lameness and had no CFD of the forelimbs. The Last follow-up was performed 6 months



**Figure 5** Photograph of a lateral oblique view of both forelimbs of the cat 24 h postoperatively, demonstrating near-complete resolution of the carpal flexural deformity

postoperatively. The cat was doing well, although it was showing a slight lameness on the left forelimb. The owner declined any follow-up consultation.

## Discussion

This case report describes the presence of a bilateral contracture of the carpal and digital flexor muscles in a cat without a history of previous surgery or trauma, resulting in CFD with a certain degree of valgus deviation of the distal limb that was successfully treated with selective tenectomies. Musculotendinous contractures are more often reported in dogs than in cats. In dogs, contractures of the infraspinatus, quadriceps, semitendinosus, semi-membranosus and gracilis muscles are most commonly described, while in cats contractures of the brachial and digital flexor muscles are mostly reported.<sup>1-8</sup> Only eight cases of feline forelimb contractures have been reported in the veterinary literature and are summarised in Table 1.<sup>1-4</sup> The cat in this report had bilateral carpal hyperflexion with some degree of valgus deviation and digital flexion (II-V) that was more pronounced on the right forelimb, which is similar to two previously described cases by Thom et al.<sup>3</sup> The first case presented with digital flexural deformity and only the DDFM tendon underwent tenotomy and the contracture recurred with additional carpal abduction and flexion.<sup>3</sup> As the other forelimb became similarly affected, the cat was euthanased and post-mortem examination of all flexor muscles (FCRM, FCUM, SDFM and DDFM) revealed contractures of all

**Table 1** Summary of cats with forelimb contractures, including our case and previously described cases<sup>1–4</sup>

Case	Age (months)	Sex	Breed	Onychectomy	Clinical presentation	Diagnosis	Treatment	Histopathology	Outcome
Cat reported herein	144	FN	DSH	No	Bilateral CHF with a certain degree of valgus deviation and DF (II–V), >RFL; 2 months postoperatively, recurrence on the LFL: CHF, DF (II–IV)	Bilateral DFMC and CFMC	(1) LFL: tenotomy (5mm) of the FCUM, FCRM and SDFM; RFL: tenotomy (5mm) of the FCUM, DDFM (branches III, IV), (2) Recurrence in LFL: TC (10mm) of the FCUM, FCRM, SDFM and DDFM (branch II, III, IV)	Chronic inflammation at the tendon periphery	Normal RFL after first surgery; normal LFL at 6-month follow-up after second surgery
Cat 1, Cooper et al <sup>2</sup>	7	MN	DSH	Yes	Permanent flexion of all digits on both forelimbs	Bilateral DFMC	Bilateral tenotomy (5mm) of all branches of the DDFM	–	Normal 12 months postoperatively
Cat 2, Cooper et al <sup>2</sup>	14	MN	DR	Yes	Permanent flexion of all digits on both forelimbs	Bilateral DFMC	Bilateral tenotomy (5mm) of all branches of the DDFM	Normal tendons, surrounded by granulation tissue	Normal 2 weeks postoperatively
Cat, Taylor and Tangner <sup>4</sup>	156	MN	DSH	No	Permanent flexion of the right elbow	Brachialis muscle contracture of the RFL	Tenotomy of the brachialis muscle	Muscle degeneration fibrosis and granulation tissue	Good after second tenotomy for recurrence 8 months after first surgery
Cat 1, Cabon et al. <sup>1</sup>	48	MN	Siamese	Yes	Permanent flexion of proximal interphalangeal joint digit II of LFL	DFMC of LFL	Tenotomy (5 mm) of DDFM and SDFM digit II	–	Normal 2 weeks postoperatively
Cat 2, Cabon et al <sup>1</sup>	7	FN	Siamese	No	Permanent flexion of the proximal interphalangeal joint digit IV of the LFL	DFMC of the LFL	Tenotomy (5 mm) of the DDFM and SDFM digit IV	–	Normal 1 month postoperatively

(Continued)

Table 1 (Continued)

Case	Age (months)	Sex	Breed	Onychectomy	Clinical presentation	Diagnosis	Treatment	Histopathology	Outcome
Cat 3, Cabon et al <sup>1</sup>	84	MN	Siamese	Yes	Bilateral permanent flexion of proximal interphalangeal joint digits II–V	Bilateral DFMC	Bilateral tenectomy (5 mm) of the DDFM and SDFM digit III and IV and bilateral tenotomy of the DDFM and SDFM digits II and V	Reactive fibroplasia of the distal portion of the digital flexor tendons	Digital hyperextension in stance 2 weeks postoperatively
Cat 1, Thom et al <sup>3</sup>	156	FN	DR	No	Flexural deformity of all digits on the RFL 2 months postoperatively, presented with DF and CHF with abduction of the RFL 8 months later; same on the LFL	DFMC of the RFL; recurrence in DFMC with FCUM and ulnaris lateralis muscle RFL contracture; bilateral DFMC, FCUM and ulnaris lateralis muscle contracture	Tenotomy of all branches of the DDFM	Immune-mediated myositis	Euthanased 11 months after initial presentation
Cat 2, Thom et al <sup>3</sup>	120	FN	DR	Yes	Permanent DF (V) of LFL; 5 months later bilateral CHF and DF (I–V)	Bilateral DFMC	Bilateral flexor tenotomy	–	Bilateral carpal and metacarpophalangeal hyperextension 1 month postoperatively

FN = female neutered; DSH = domestic shorthair; CHF = carpal hyperflexion; DF = digital flexion; RFL = right forelimb; LFL = left forelimb; DFMC = digital flexor muscle contracture; FCUM = carpal flexor muscle contracture; FCUM = flexor carpi ulnaris muscle; FCRM = flexor carpi radialis muscle; SDFM = superficial digital flexor muscle; DDFM = deep digital flexor muscle; TC = tenectomy; MN = male neutered; DR = Devon Rex

flexors. The second case had a similar clinical presentation and a bilateral flexor tenotomy was performed, after which a carpal hyperextension occurred.<sup>3</sup> In the present case, tenectomies were performed not only limited to the digital flexor muscle tendons, but also included the FCUM and FCRM tendons, resulting in a good outcome. Despite the amount of tenectomies, no carpal or digital hyperextension was observed postoperatively. One case report described gastrocnemius and digital flexor muscle contractures in the hindlimb of a 3-month-old kitten with a congenital bilateral tarsal hyperextension deformity.<sup>9</sup> Another case report described the occurrence of fibrotic myopathy of the semitendinosus muscle in a cat, resulting in mechanical hindlimb lameness.<sup>10</sup>

The exact aetiology of contractures in cats remains unknown. Although onychectomy was performed in many cases described in the literature, this procedure often took place many years before the contracture developed. There are also reports in the literature, including our cat, where an onychectomy was not performed, so the direct relationship between this procedure and developing contractures has not been established.<sup>1-3</sup> Breed predispositions (Siamese and Devon Rex) are suspected;<sup>1,3</sup> however, owing to an insufficient number of cases, further studies are warranted. Contractures can be a result of (non)traumatic myositis, leading to reparative fibrosis.<sup>3</sup> For instance, *Toxoplasma gondii* is a commonly observed parasite in cats and can result in myositis.<sup>11,12</sup> Fibrotic myopathies have been reported as a possible cause in one cat.<sup>4</sup> Muscle biopsies of the affected flexor muscles were performed in the current case, demonstrating no abnormalities. In humans, a condition named as 'trigger finger' has been reported, which is characterised by a stenosis of the palmar retinacular sheath, resulting in flexor entrapment and a locked finger.<sup>13,14</sup> Unfortunately, no exact aetiology has been proposed.

In young cats, severe hindlimb contractures have been reported by Rohdin et al,<sup>15</sup> resulting in arthrogryposis. These contractures were a result of acquired motor neuron loss, with signs consistent with a chronic axonal damage on histopathological examination of peripheral nerve biopsies.<sup>15</sup> The prognosis of this feline motor neuron degeneration disease is poor; therefore, biopsies of the peripheral nerves should be taken in cats with musculotendinous contractures.<sup>13</sup> However, a definitive diagnosis of feline motor neuron degeneration is difficult and is based on post-mortem examination of the spinal cord.<sup>15</sup>

Despite the lack of a clear aetiology for contracture development in cats, surgical treatment consisting of tenectomies or tenotomies is suggested. Tenectomy seemed to have a better outcome, when comparing the different case reports.<sup>1-3</sup> In the case report by Thom et al,<sup>3</sup>

both cats were treated with a tenotomy: in one, the contracture recurred after tenotomy of the DDFM tendon; the other had permanent carpal hyperextension after bilateral flexor tenotomy. Our cat demonstrated an immediate resolution of the flexural deformity of the distal limbs with an improved quality of life 1 month after the selective tenectomies. However, 2 months postoperatively, recurrence of the CFD with a certain degree of valgus deviation was observed in the left forelimb, necessitating a second tenectomy owing to the presence of a fibrous tissue between the two tendon ends. After the second intervention, the flexural deformity disappeared. Considering that after a tenectomy of 5 mm, the contracture recurred and resolved completely after another tenectomy of 10 mm, further prospective studies are warranted to determine the size of an optimal defect in tendons. Despite performing selective tenectomies, mild carpal hyperflexion in our cat persisted immediately postoperatively. In our cat, there was no histopathological confirmation of muscle contracture of the muscles that had had their tendons sectioned. Therefore, if we had limited ourselves to the digital flexor muscle, it is possible that the cat would also have been able to recover carpal hyperextension through physiotherapy. Our case is very similar to the two cases described by Thom et al,<sup>3</sup> who stated that post-mortem examination of the flexor muscles (FCRM, FCUM, SDFM, DDFM) revealed contracture of all flexors. Although there was no histopathological confirmation in our case, we suggest that our cat was similarly affected based on the clinical signs and radiographic findings. In our cat, histopathology of the muscles revealed no abnormalities except minimal atrophy. Previous post-mortem histopathology of muscles affected by contracture demonstrated chronic inflammation with reparative fibrosis.<sup>3</sup> One hypothesis for our atypical finding is that we collected only a very small muscle fragment, which may not be representative of the whole muscle. Nevertheless, our guess is that at least one muscle contracture was required to cause the carpal flexural deformity observed.

## Conclusions

Carpal and digital flexor musculotendinous contractures in the forelimbs of feline patients are a rare condition, with little information available regarding aetiology. In our patient, selective tenectomy proved to be relatively simple, resulting in a good outcome and a marked improvement in the cat's quality of life. Further studies are indicated to identify the precise aetiology of this still unfamiliar condition.

**Acknowledgements** The authors wish to acknowledge Dr Tiphaine Durand for her implication in a TFE (travail de fin d'étude) on this clinical case.

**Conflict of interest** The authors declared no potential conflicts of interest with respect to the research, authorship, and/or publication of this article.

**Funding** The authors received no financial support for the research, authorship, and/or publication of this article.

**Ethical approval** The work described in this manuscript involved the use of non-experimental (owned or unowned) animals. Established internationally recognised high standards ('best practice') of veterinary clinical care for the individual patient were always followed and/or this work involved the use of cadavers. Ethical approval from a committee was therefore not specifically required for publication in *JFMS Open Reports*. Although not required, where ethical approval was still obtained, it is stated in the manuscript.

**Informed consent** Informed consent (verbal or written) was obtained from the owner or legal custodian of all animal(s) described in this work (experimental or non-experimental animals, including cadavers) for all procedure(s) undertaken (prospective or retrospective studies). No animals or people are identifiable within this publication, and therefore additional informed consent for publication was not required.

**ORCID iD** Emily Vrijzen  <https://orcid.org/0000-0003-3405-1562>

Pierre Picavet  <https://orcid.org/0000-0003-4265-1429>

## References

- 1 Cabon Q, Plante J and Gatineau M. **Digital flexor tendon contracture treated by tenectomy: different clinical presentations in three cats.** *JFMS Open Rep* 2015; 1. DOI: 10.1177/2055116915597237.
- 2 Cooper MA, Laverty PH and Soiderer EE. **Bilateral flexor tendon contracture following onychectomy in 2 cats.** *Can Vet J* 2005; 46: 244–246.
- 3 Thom LK, Pool RR and Mallik R. **Digital flexor musculotendinous contracture in two Devon Rex cats.** *J Feline Med Surg* 2017; 19: 304–310.
- 4 Taylor J and Tangner CH. **Acquired muscle contractures in the dog and cat. A review of the literature and case report.** *Vet Comp Orthop Traumatol* 2007; 20: 79–85.
- 5 Bennet RA. **Contracture of the infraspinatus muscle in dogs: a review of 12 cases.** *J Am Anim Hosp Assoc* 1986; 22: 481–487.
- 6 Lewis DD, Shelton GD, Piras A, et al. **Gracilis or semitendinosus myopathy in 18 dogs.** *J Am Anim Hosp Assoc* 1997; 33: 177–188.
- 7 Moore RW, Rouse GP, Piermattei DL, et al. **Fibrotic myopathy of the semitendinosus muscle in four dogs.** *Vet Surg* 1981; 10: 169–174.
- 8 Vidoni B, Hassan J, Bockstahler BA, et al. **Fibrotic gracilis myopathy – clinical signs, diagnostic imaging, therapy in a German Shepherd dog.** *Wien Tierarztl Monatsschr* 2008; 95: 8–14.
- 9 Yardimci C, Ozak A and Ozlem Nisbet H. **Surgical correction of bilateral congenital tarsal hyperextension deformity in a cat.** *Vet Comp Orthop Traumatol* 2015; 5: 364–368.
- 10 Lewis DD. **Fibrotic myopathy of the semitendinosus muscle in a cat.** *J Am Vet Med Assoc* 1988; 15: 240–241.
- 11 Podell M. **Inflammatory myopathies.** *Vet Clin North Am Small Anim Pract* 2002; 32: 147–167.
- 12 Butts DR and Langley-Hobbs SJ. **Lameness, generalised myopathy and myalgia in an adult cat with toxoplasmosis.** *JFMS Open Rep* 2020; 6. DOI: 10.1177/2055116920909668.
- 13 Moore JS. **Flexor tendon entrapment of the digits (trigger finger and trigger thumb).** *J Occup Environ Med* 2000; 42: 526–545.
- 14 Makkouk AH, Matthew AE, Oetgen E, et al. **Trigger finger: etiology, evaluation, and treatment.** *Curr Rev Musculoskelet Med* 2008; 1: 92–96.
- 15 Rohdin C, Karlstam E, Jäderlund KH, et al. **Acquired motor neuron loss causing severe pelvic limb contractures in a young cat.** *J Feline Med Surg* 2010; 12: 237–240.