

Alveolar echinococcosis is increasing in Southern Belgium: a report of the Belgian National Reference Laboratory for Echinococcosis (BNRLE) and clinical experience of ECHINO-Liege

Pr Olivier Detry

Service de Chirurgie Abdominale et Transplantation

CHU Liège, Université de Liège, Belgique

olivier.detry@chuliege.be

 EchinLiège Nationale Referentie Laboratorium
Echin.be
laboratoire National de Référence ECHINOCOCCOSE

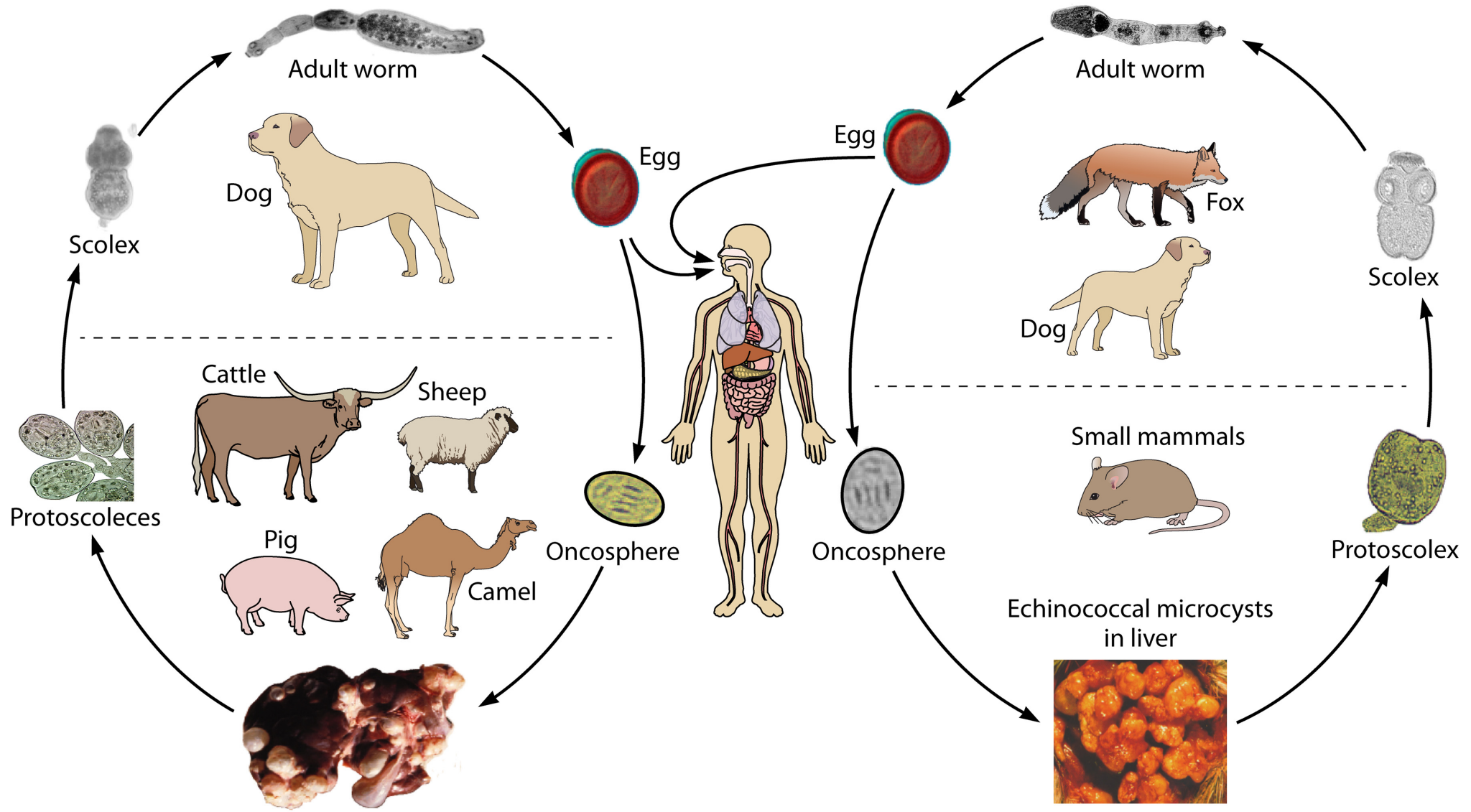
Alveolar echinococcosis is increasing in Southern Belgium: a report of the Belgian National Reference Laboratory for Echinococcosis (BNRLE) and clinical experience of ECHINO-Liege

O. DETRY (1), C. BIHAIN (2), R. SACHELI (3), S. EGREK (4), N. BLETARD (5), P. MEUNIER (6), P. LOVINFOSSE (7), J. DELWAIDE (8), N. BOTEMBE (9), E. LARRANAGA (10), C. TRUYENS (11), B. DELAERE (12), B. PIROTTE (13), J. GIOT (14), P. LEONARD (14), MP. HAYETTE (3)

[1] Centre Hospitalier Universitaire de Liège, Liège, Belgium, **ECHINO-Liege**, Dpt of Abdominal Surgery and Transplantation, [2] **CHU of Liège**, , Belgium, Dpt of Abdominal Surgery and Transplantation, [3] CHU of Liège, , Belgium, ECHINO- Liege, Dpt of Clinical Microbiology, Belgian National Reference Laboratory for Echinococcosis, (BNRLE), , [4] CHU of Liège, , Belgium, Dpt of Clinical Microbiology, Belgian National Reference Laboratory for Echinococcosis, (BNRLE), [5] CHU of Liège, , Belgium, ECHINO -Liege, Dpt of Pathology, [6] CHU of Liège, , Belgium, ECHINO-Liege, Dpt of Radiology, [7] CHU of Liège, , Belgium, ECHINO-Liege, Dpt of Nuclear Medicine, [8] CHU of Liège, , Belgium, ECHINO-Liege, Dpt of Hepatogastroenterology, [9] **Centre Hospitalier des Ardennes**, Libramont, Belgium, Dpt of Gastroenterology, [10] **Erasme Hospital**, Brussels, Belgium, Dpt of Infectiology, [11] Université Libre de Bruxelles Faculté de Médecine, Brussels, Belgium, of Parasitology, [12] **CHU Dinant Godinne**, Yvoir, Belgium, Dpt of Infectiology, [13] **CHR Citadelle**, Liège, Belgium, ECHINO-Liege, Dpt of Infectiology, [14] CHU of Liège, , Belgium, ECHINO-Liege, Dpt of Infectiology

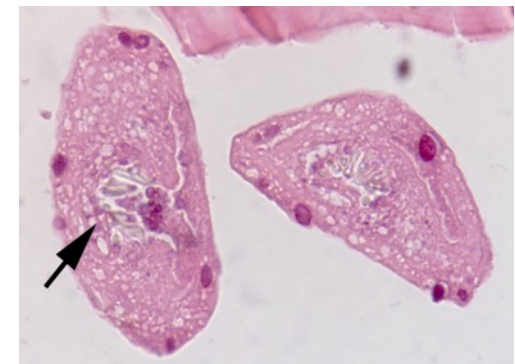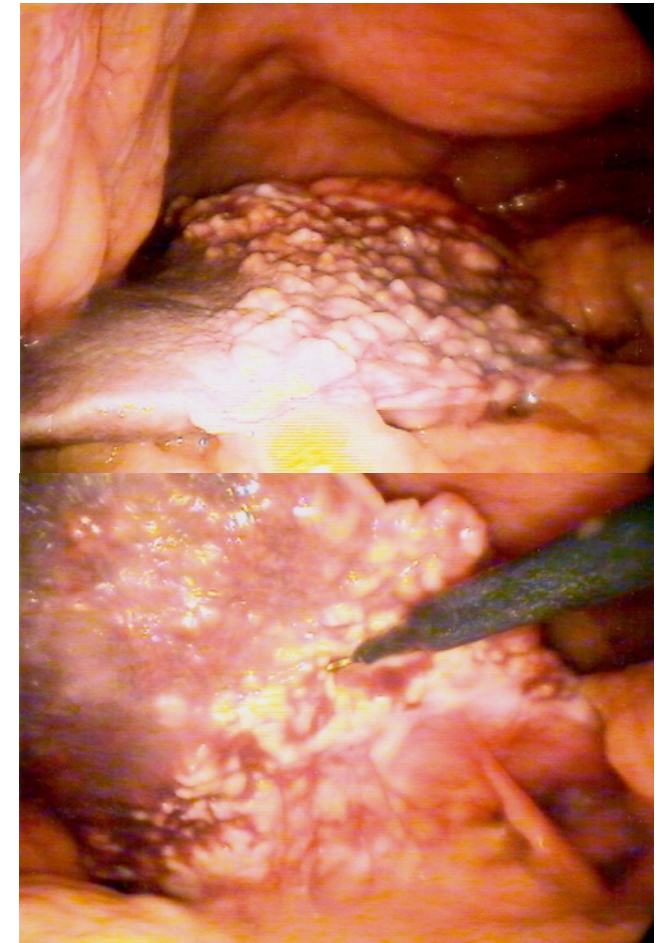
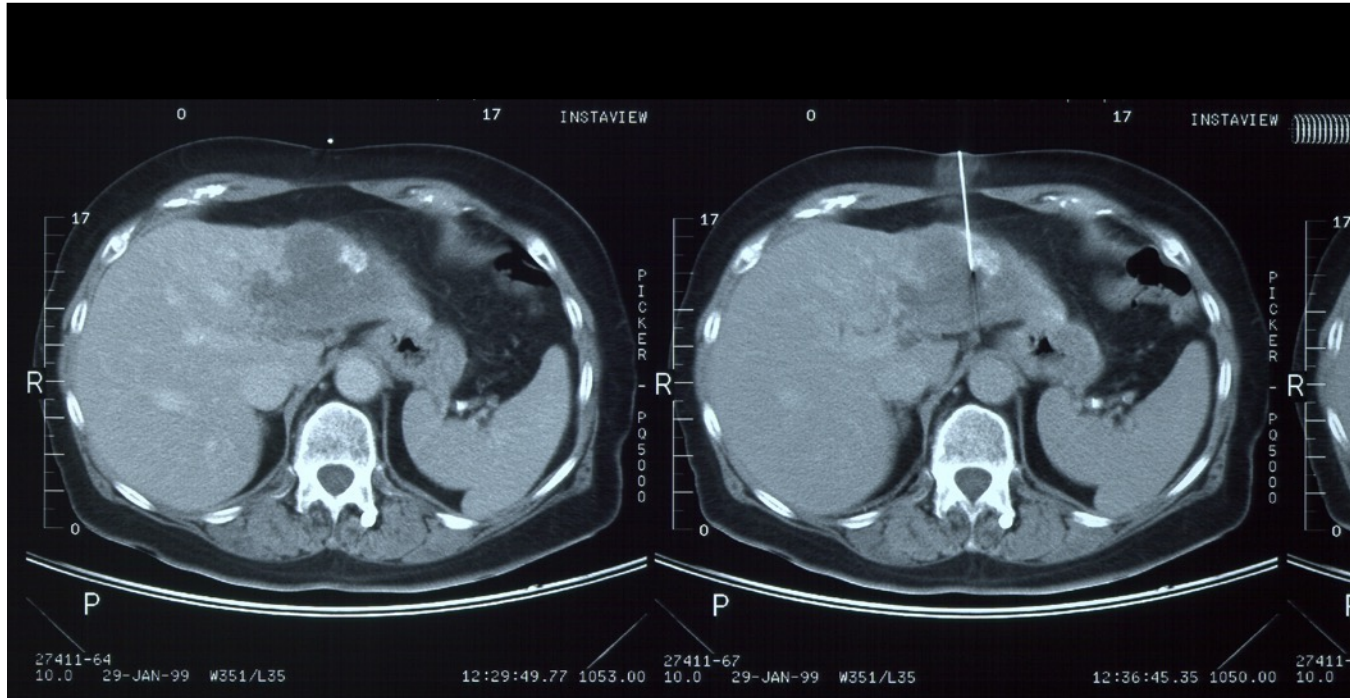
Echinococcus granulosus/ortleppi/canadensis

Echinococcus multilocularis



Alveolar Echinococcosis

- First local cases reported in early 2000s



Acta Gastroenterol Belg. 2002 Jan-Mar;65(1):55-60.

Acta Gastroenterol Belg. 2005 Jan-Mar;68(1):1-4.

ECHINO-Liege

- Clinicians (Surgeons, hepatologists, infectiologists)
- Radiologist, Nuclear medicine, Pathologists
- Microbiologists

- Veterinarians

Echinococcose – CHU Liège

- ECHINO – Liège
- Echinococcose.be
- Albendazole dosing
- Specific serologies (ELISA, Western Blot)
- PCR & genotyping
- National reference laboratory
- ECHINO-BANK
- Regional, national and international clinical contacts
- Publications in national and international journals
- ECHINO-DAY



Aims - Patients & Methods

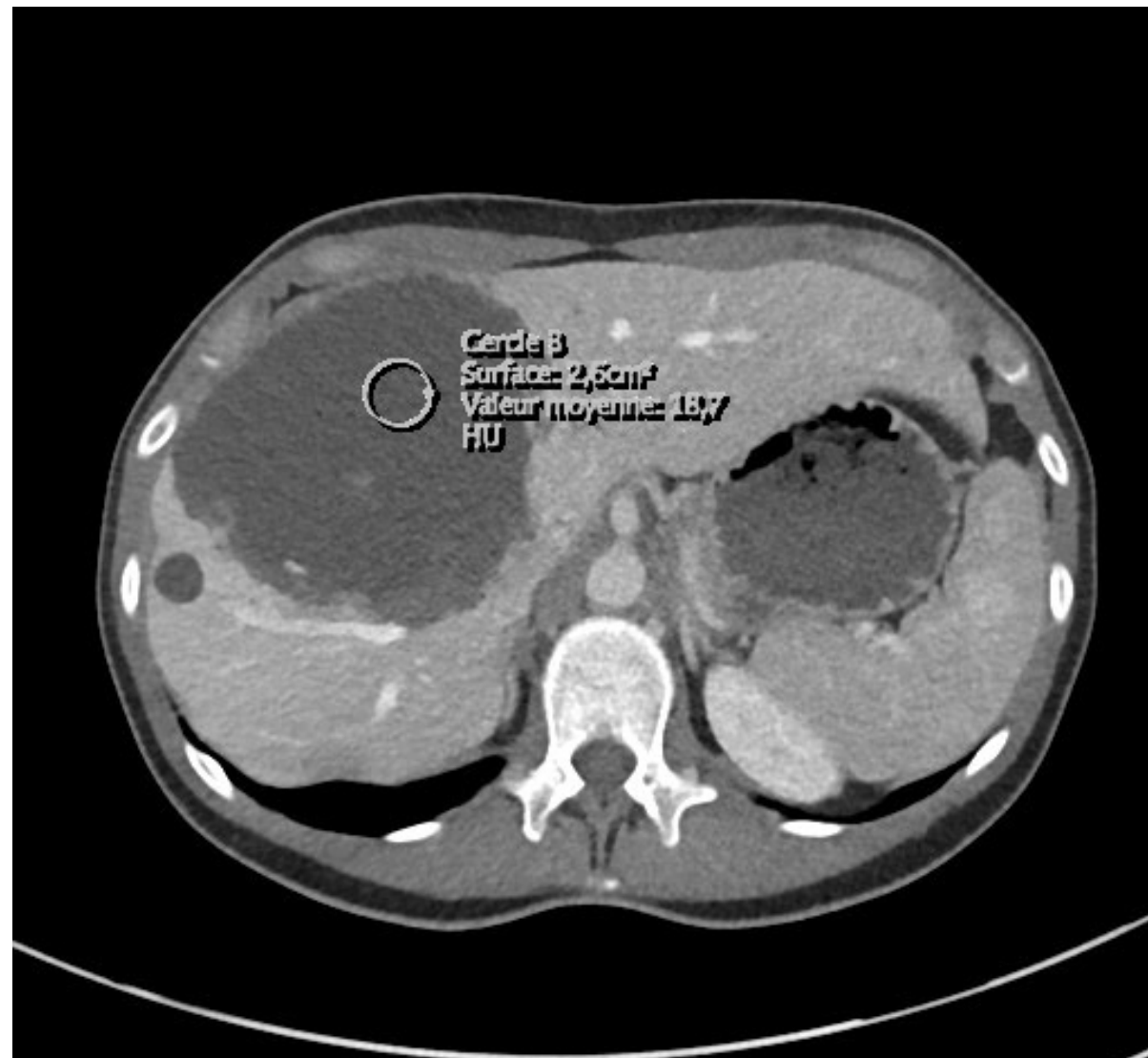
- Review of the cases already known and managed
- Incidence ? National study
- Awareness

Results

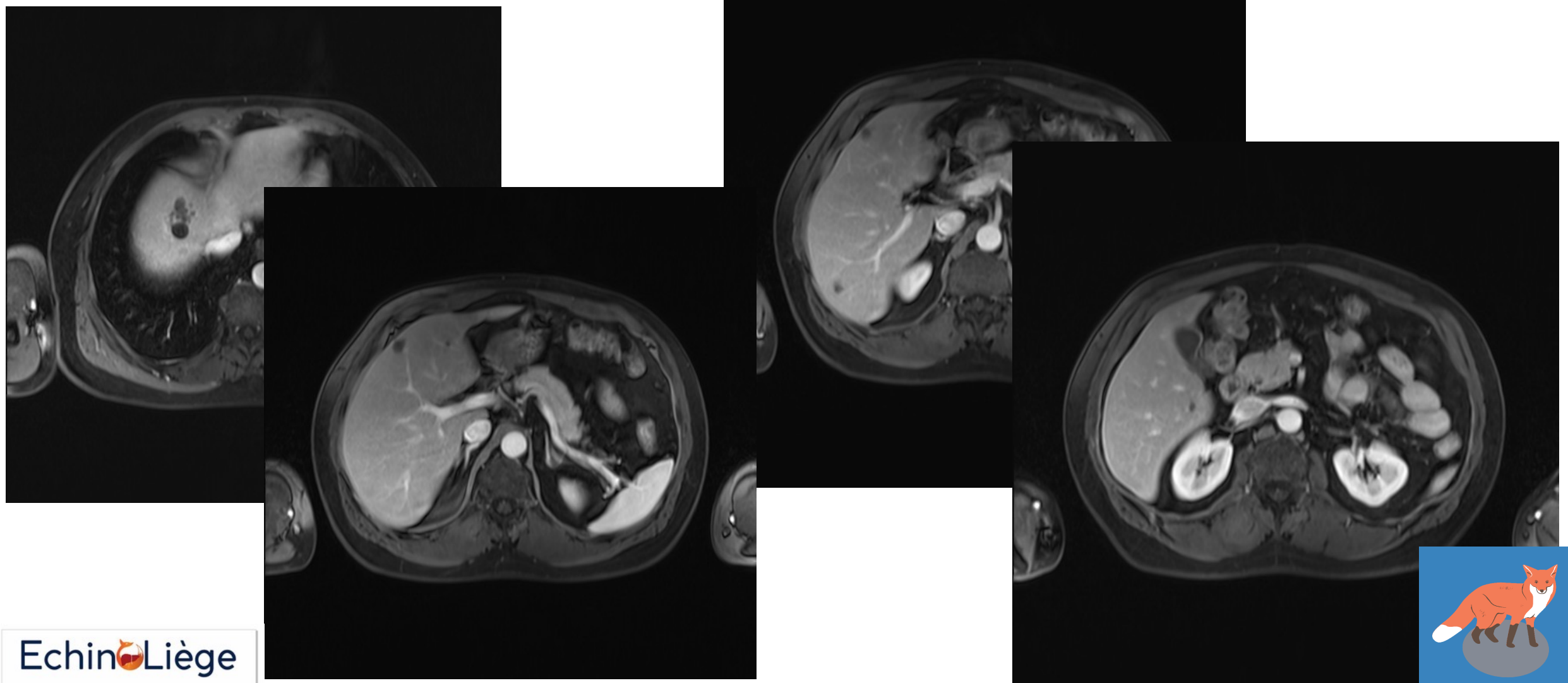
- 50 patients (28 males and 22 females, mean age: 60yrs, 19-89) living in Wallonia and Brussels regions (+ 1 France and 1 GDL)

- 31 liver resections and 1 liver transplantation

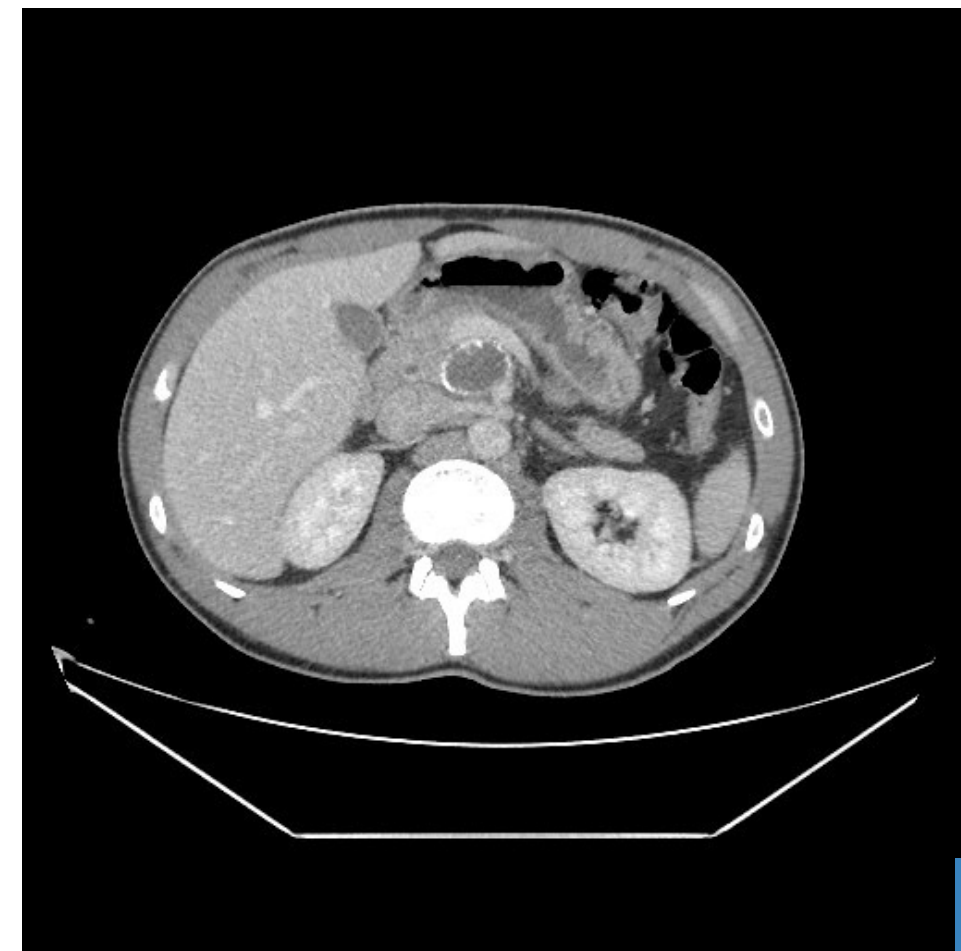
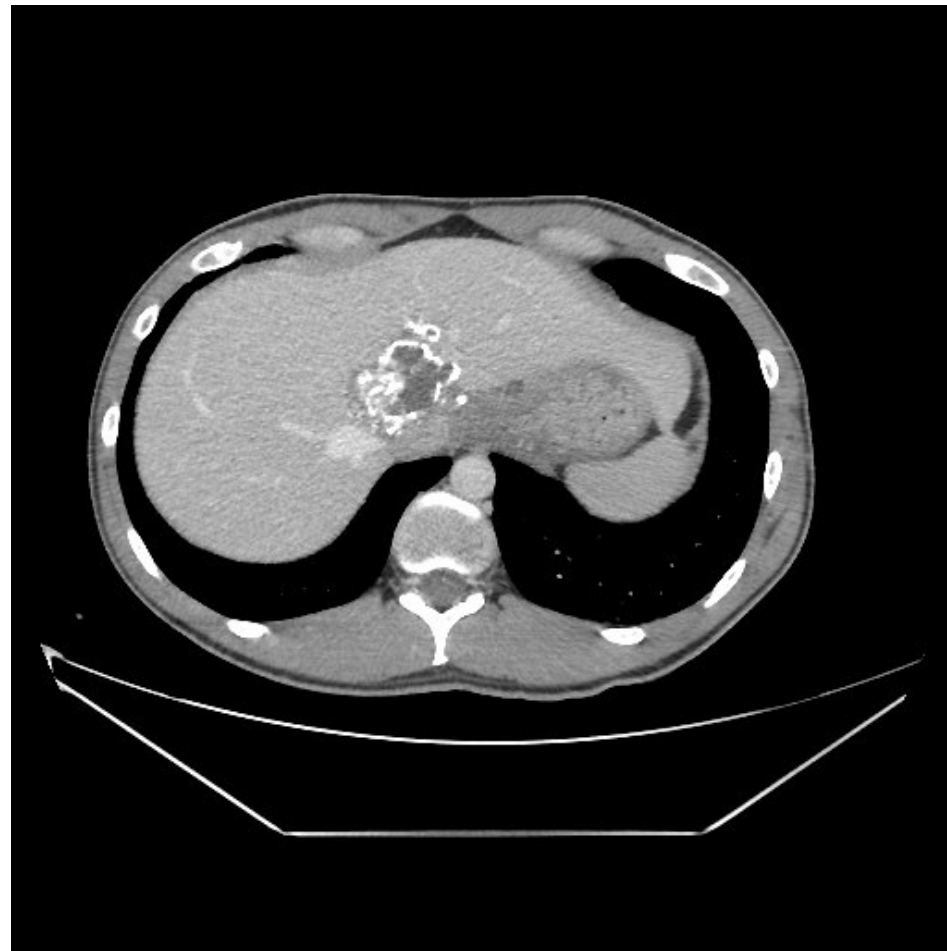Liver presentation 1



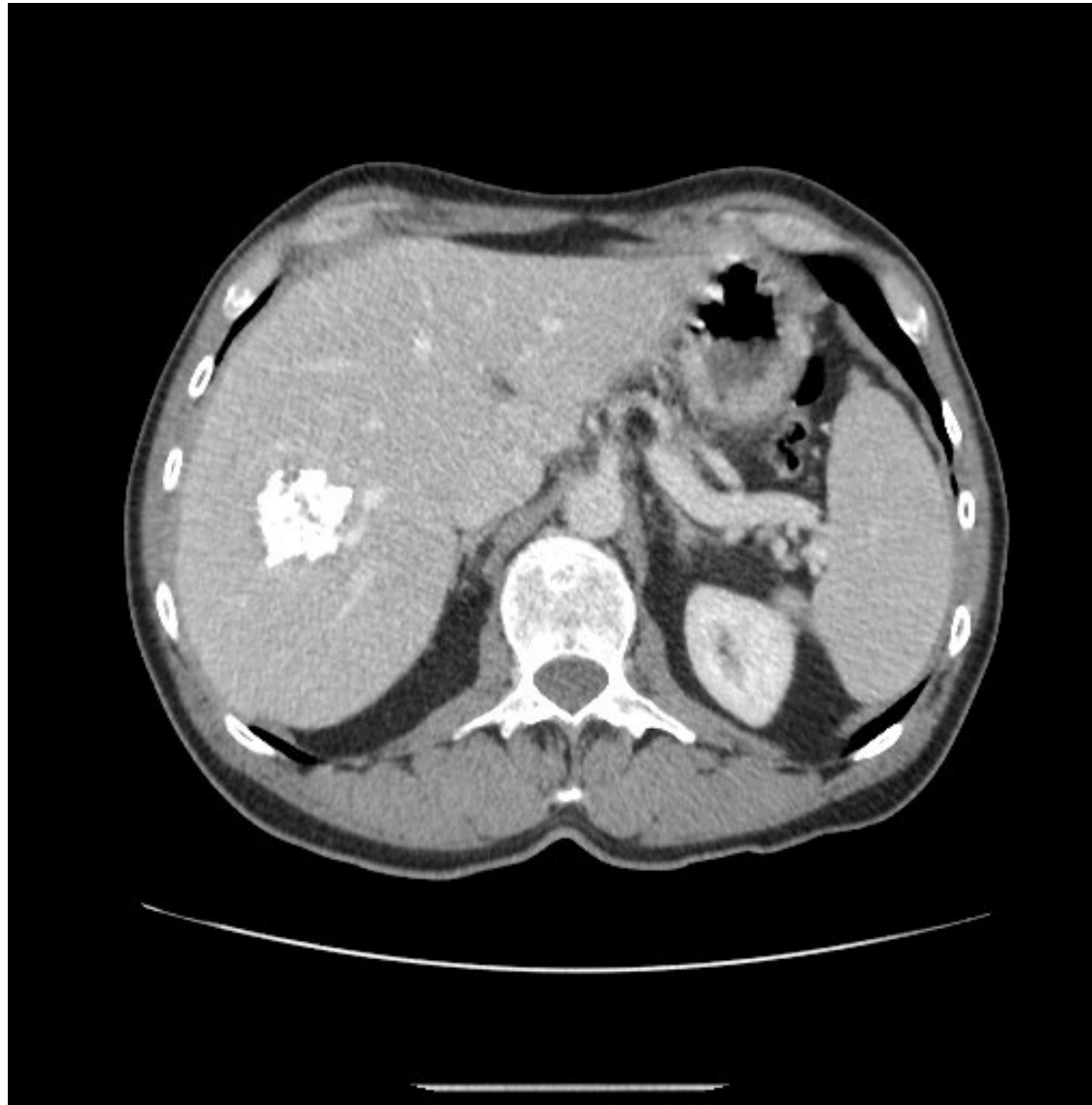
Liver presentation 2

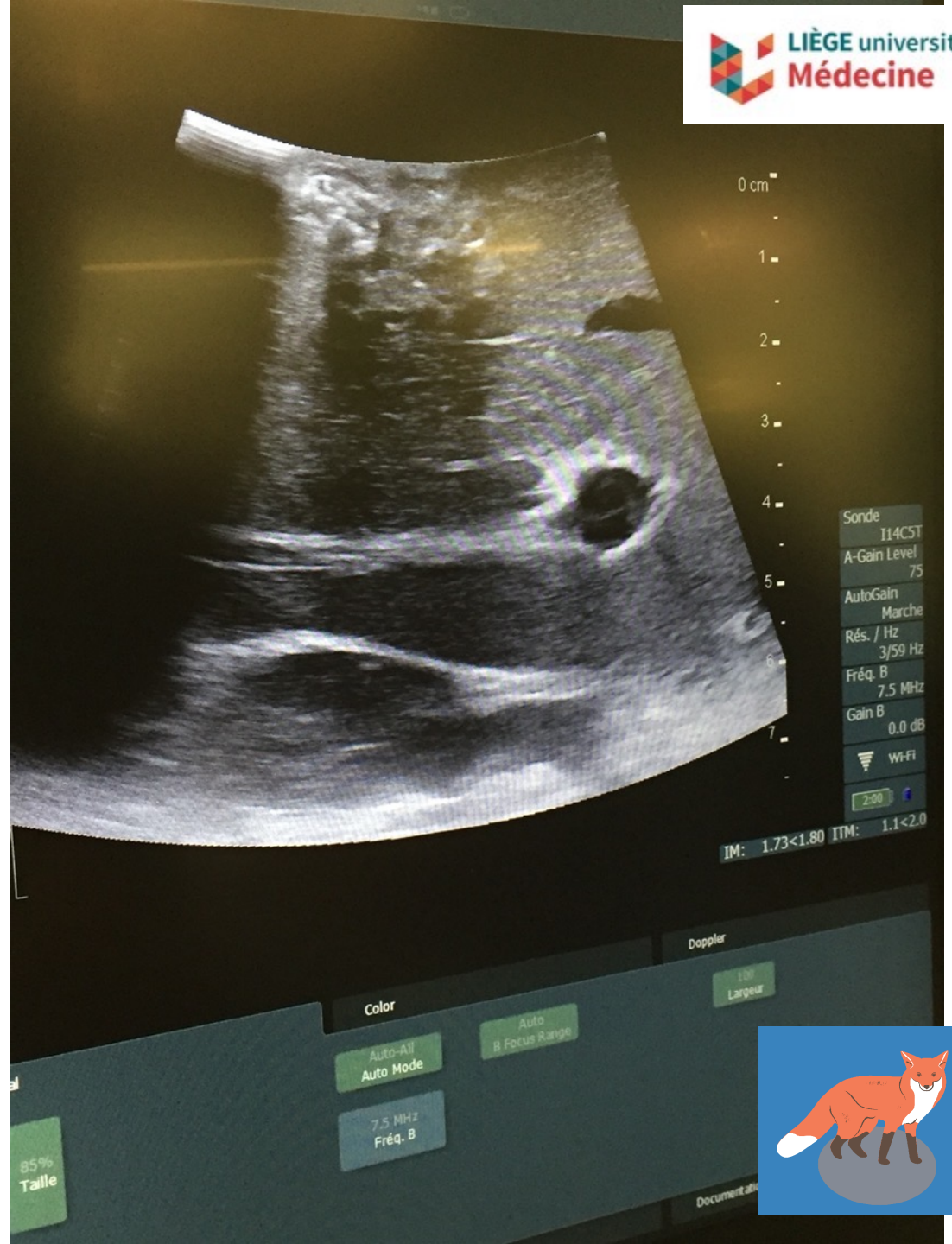
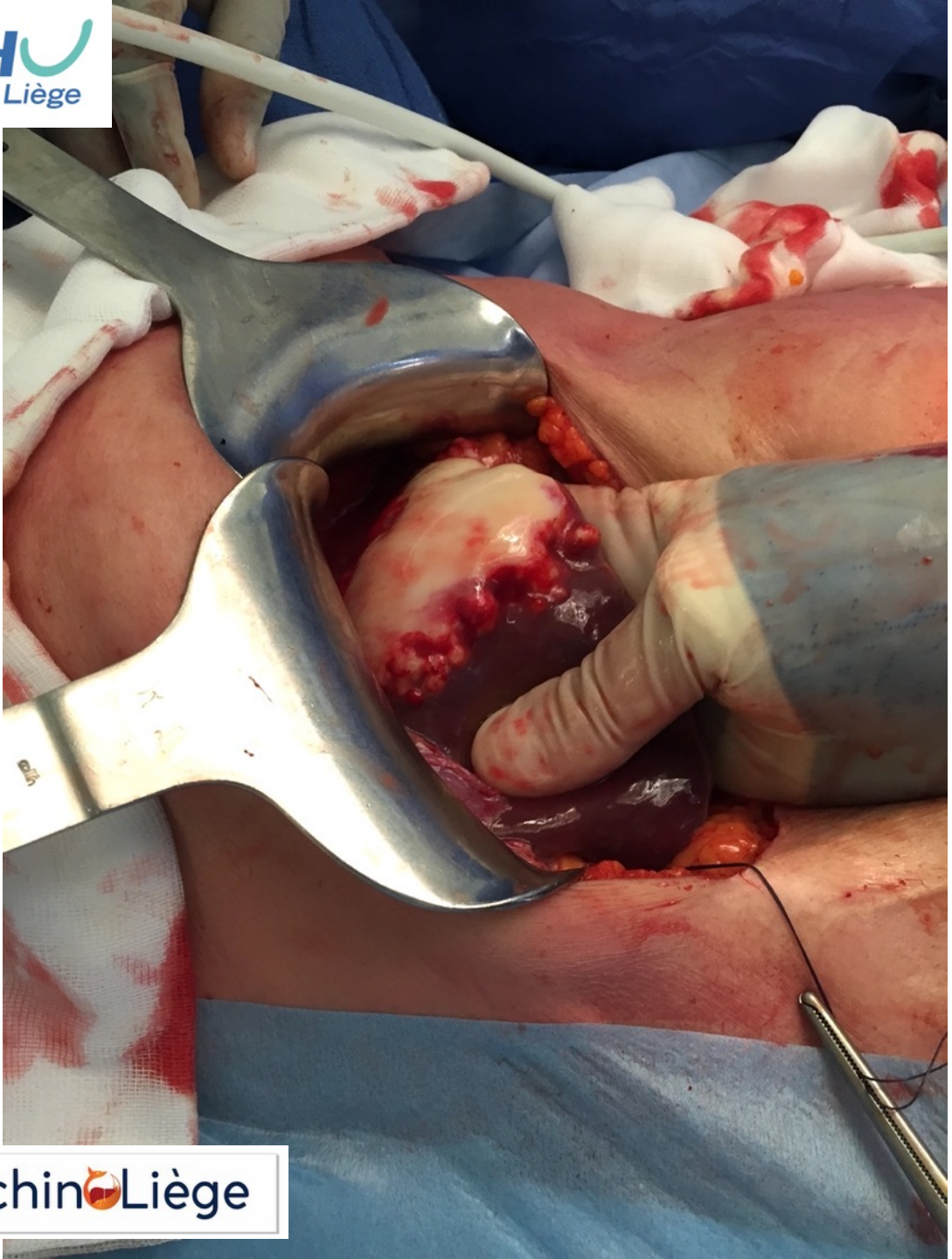



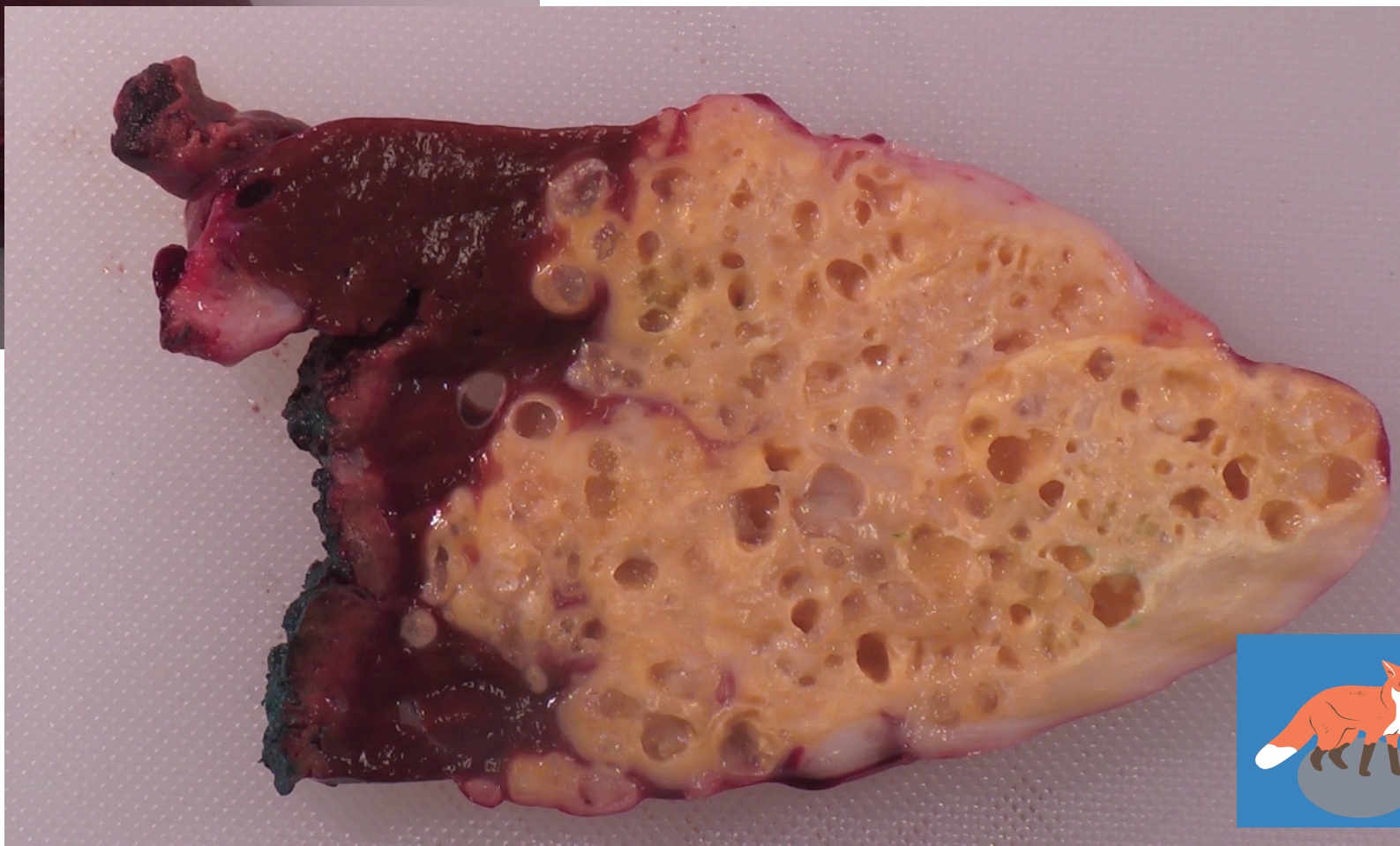
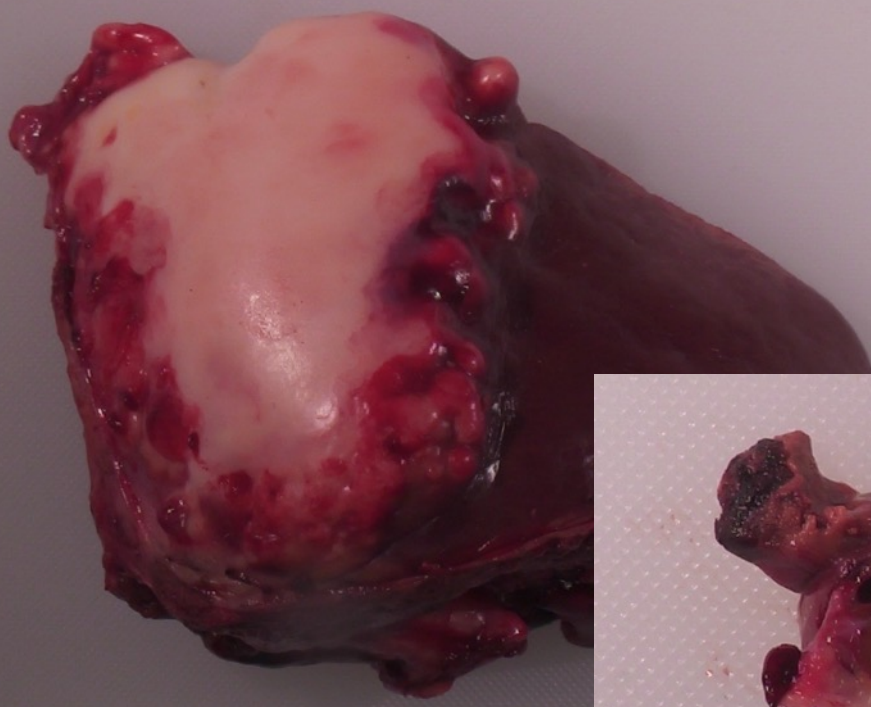
Liver presentation 3



Liver presentation 4







Annual report

National Reference Laboratory
Echinococe
laboratoire National de Référence ECHINOCOCCOSE

LABORATOIRE NATIONAL DE RÉFÉRENCE
DE L'ECHINOCOCCOSE

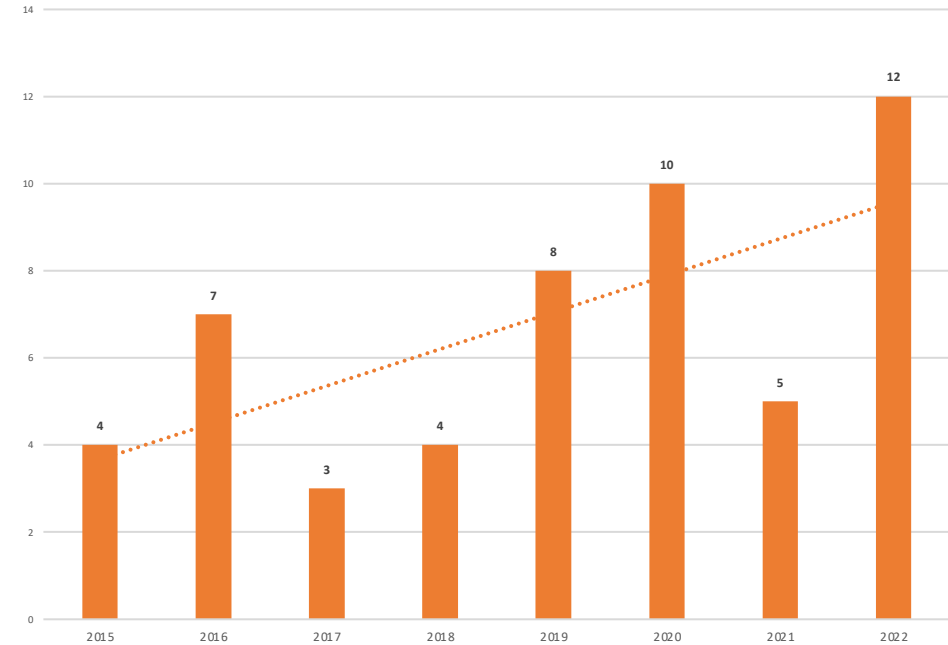
Rapport d'activité
Année 2021

Centre Hospitalier Universitaire de Liège
Service de Microbiologie Clinique

En collaboration avec EchinoLiège

CHU
de Liège

AOÛT 2022 | Liège | Belgique



Diagnosed Alveolar Echinococcosis cases
In Belgian residents 2015-2022*



Service de Santé et pathologies de la Faune Sauvage en RW



Accueil Le Service Résultats Tirs sanitaires Centres de collecte Contact

- › Collaborations
- › Publications

DÉPÔT D'UN ANIMAL SAUVAGE TROUVÉ MORT



Le programme de surveillance « WildTub »



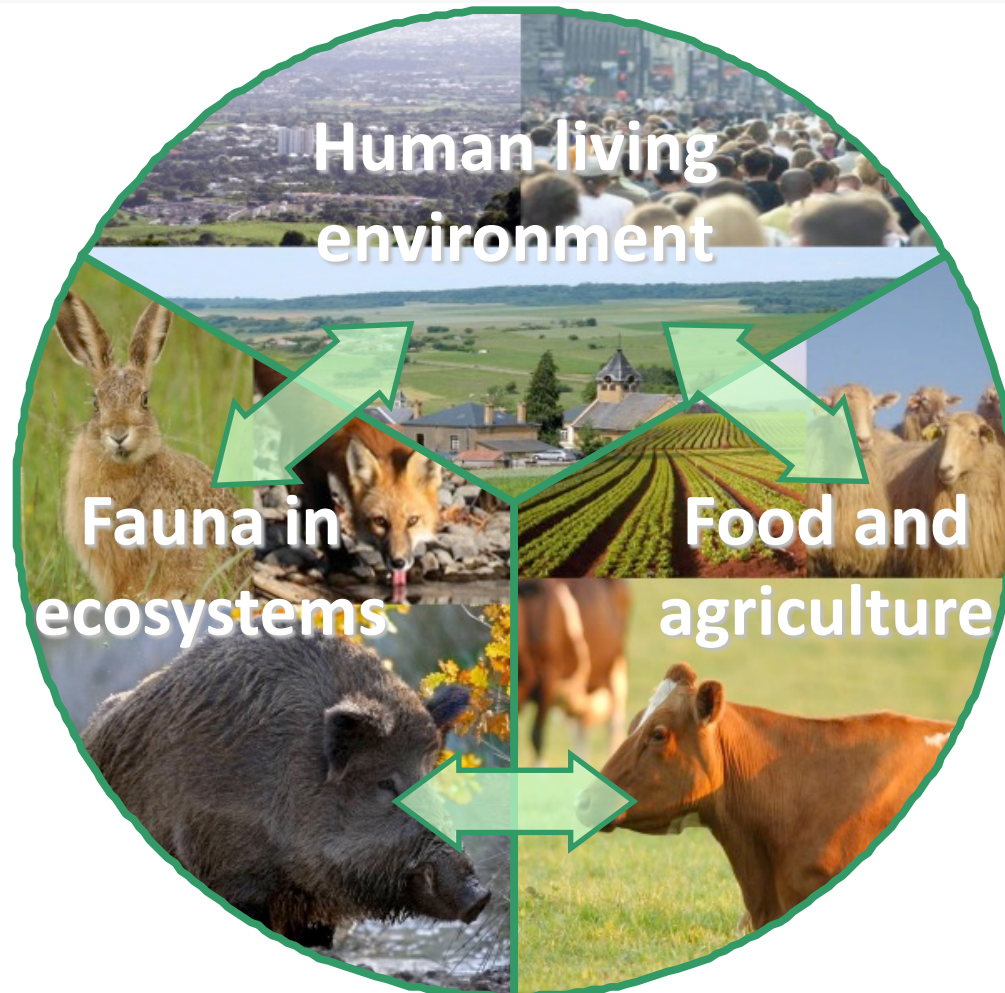
Le virus Usutu détecté en Province de Liège

Informations nécessaires à fournir

(en ligne) > [Formulaire de dépôt](#)

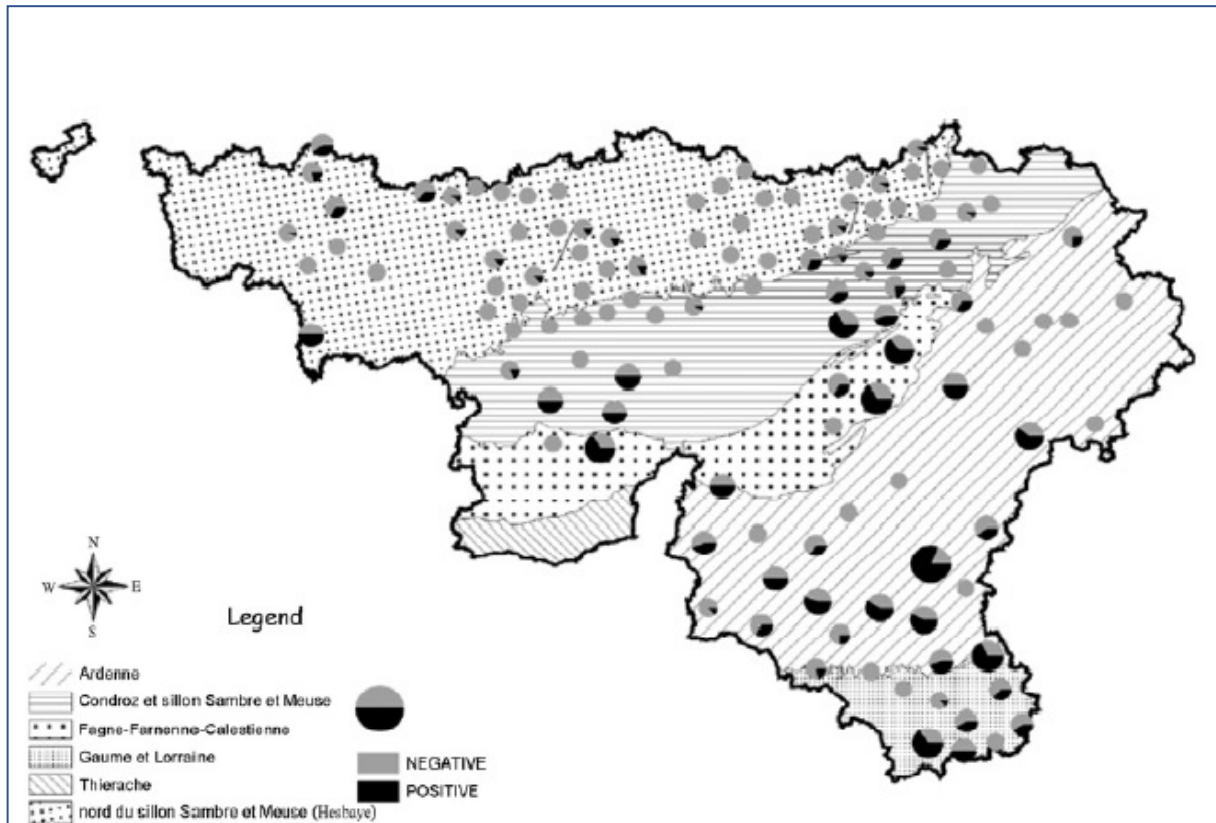
ou

(à imprimer) > [Fiche de renseignements](#)



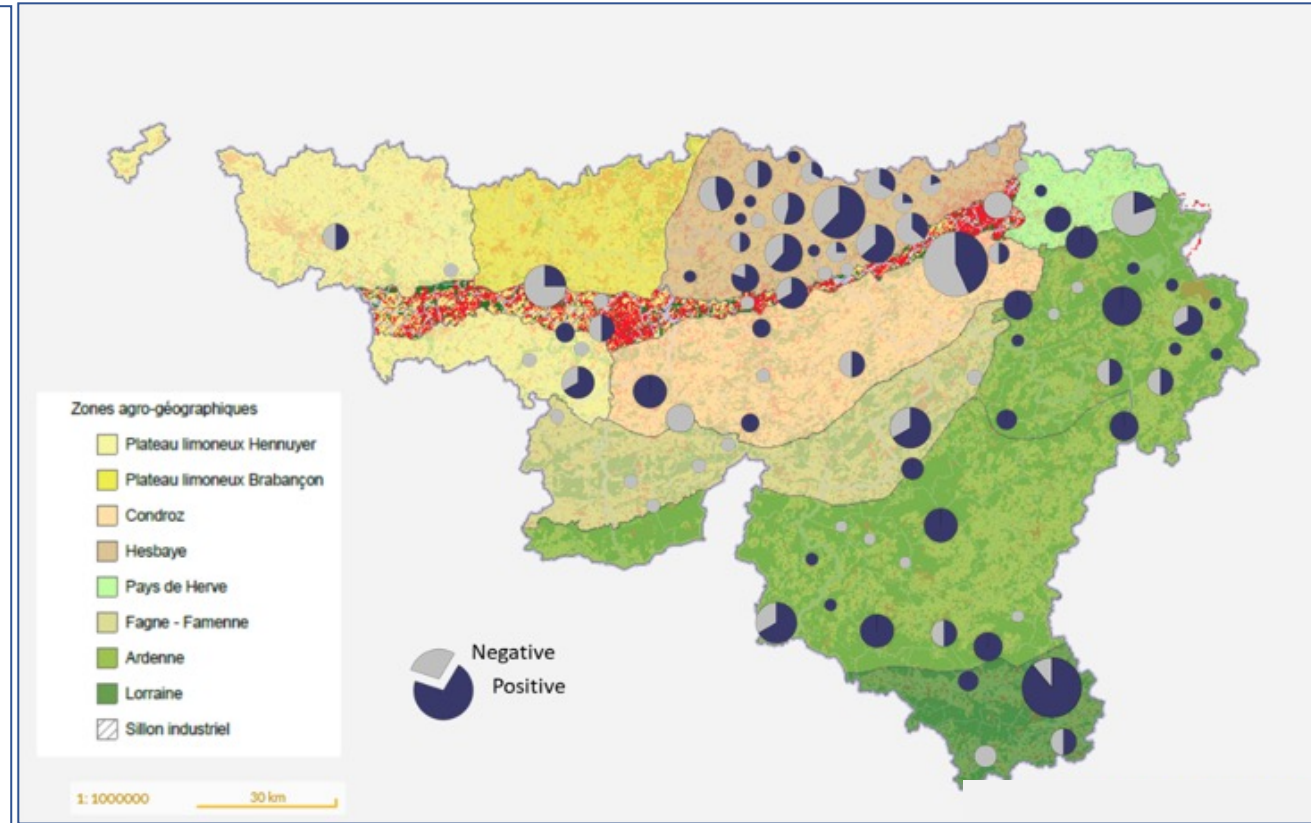
Prévalence *E. multilocularis* - Renard roux - Wallonie - Etudes antérieures

2003 – 2004 (n = 990)

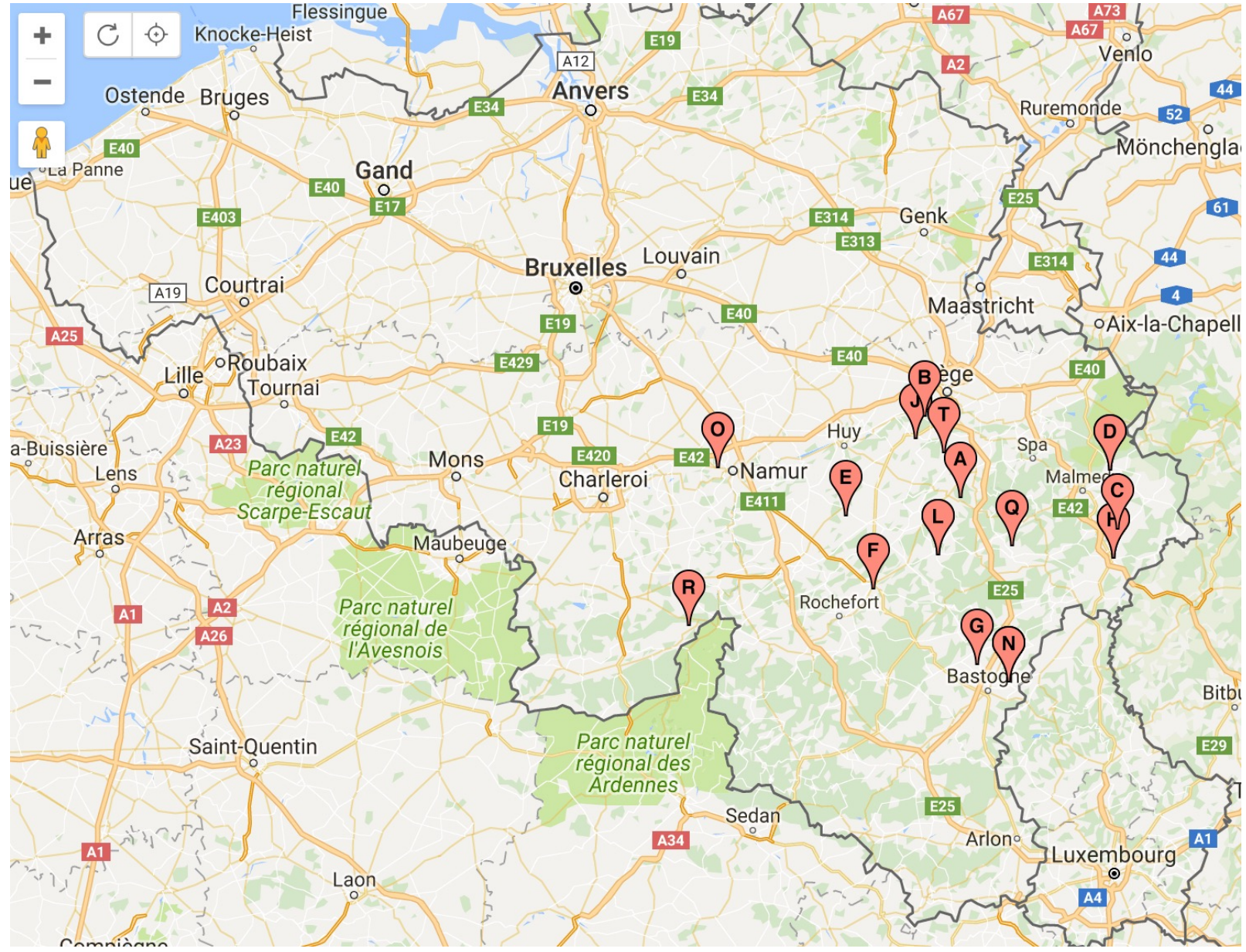

Hanosset et al., 2003

2018 – 2022 (n = 503)



Gautier et al., in preparation



Prévalence *E. multilocularis* - Renard roux - Flandre (2012 - 2015)

Echinococcus multilocularis in red foxes in North Belgium : Prevalence and trends in distribution
Jansen *et al.*, 2020, *Veterinary Parasitology: Regional Studies and Reports* 22

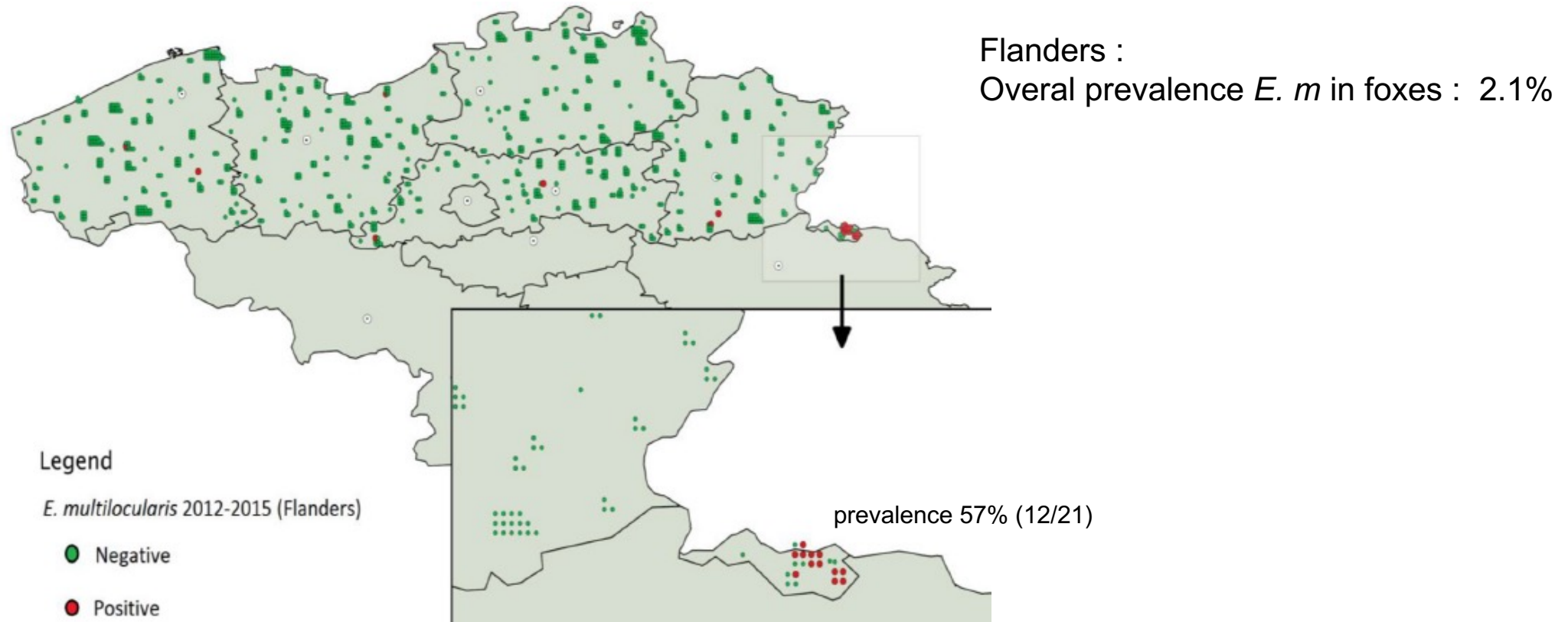
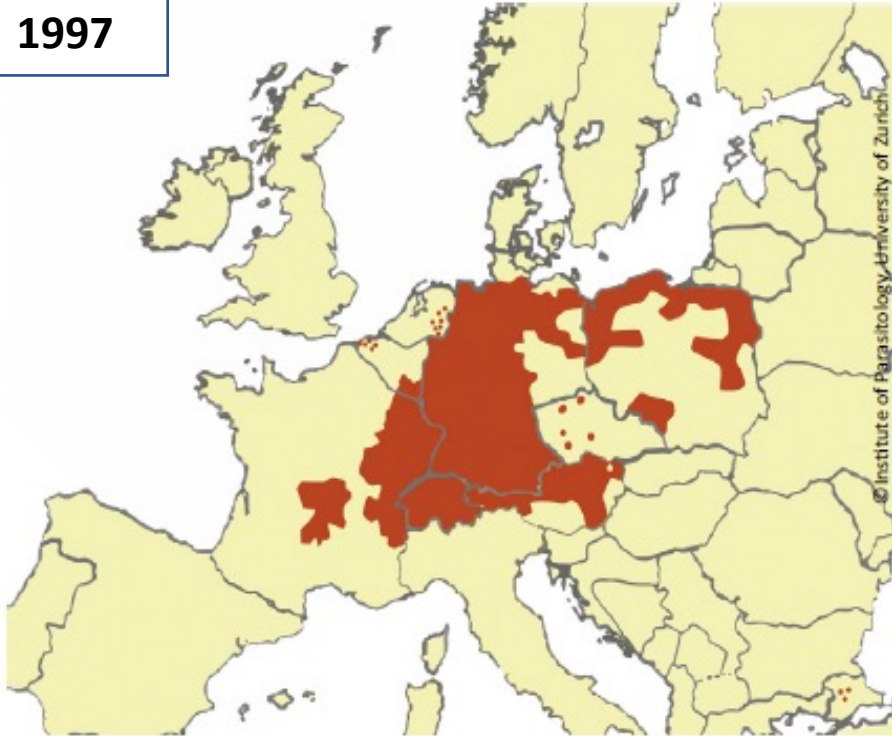

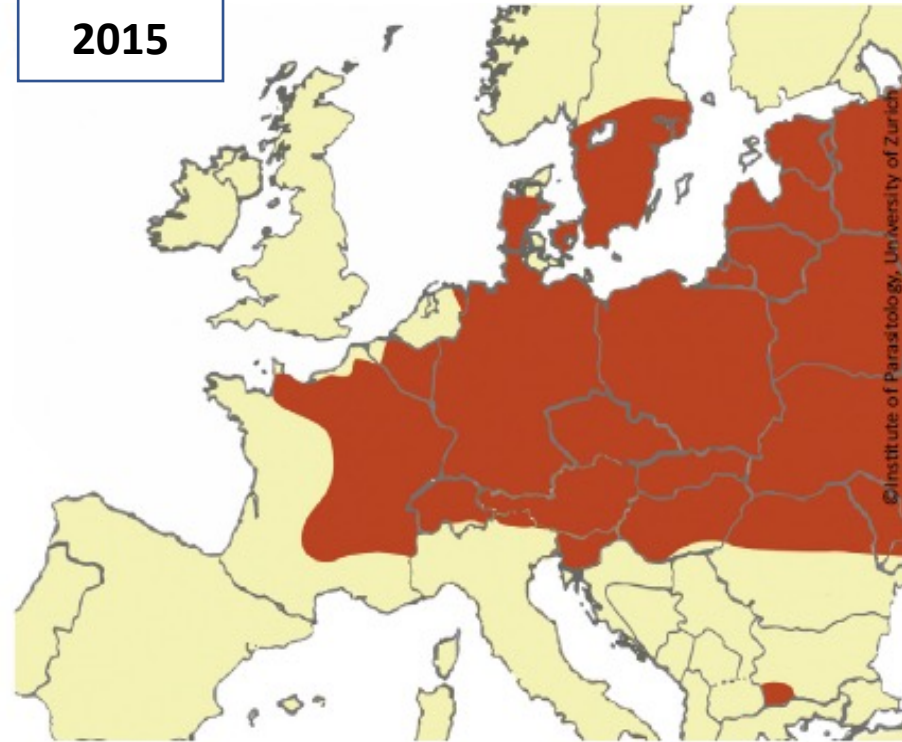
Fig. 2. Map showing red fox sample locations in the Flanders region: red and green dots present intestinal samples of foxes sampled in the period 2012–2015, with positive and negative findings for *Echinococcus multilocularis*, respectively. Jansen *et al.*, 2020

Prévalence *E. multilocularis* - Renard roux - Europe

1997



2015



Gottstein et al., 2015, Trends in Parasitology

Conclusions

- Alveolar echinococcosis is present in Wallonia
- Early diagnosis allows cure by surgery and 2 years of albendazole therapy
- ECHINO-Liege and the national laboraztory might be contacted to help in the diagnosis and management
- AE incidence might be underestimated



National retrospective survey

- Retrospective registry lead by the Dpt of Infectiology of Erasme hospital (central EC)
- All hospitals will be interrogated
- Dr Christian Mottet: christian.mottet@hubruxelles.be
- Pr Olivier Detry: olivier.detry@chuliege.be
- Pr Marie-Pierre Hayette: mphayette@chuliege.be
- www.echinococcose.be



THANK YOU !

