

Understanding the pathophysiology of reflex epilepsy using simultaneous EEG-fMRI

Manglore Sandhya^{1,2}, Rose Dawn Bharath^{1,2},
Rajanikant Panda^{1,2}, S.R. Chandra³, Naveen Kumar²,
Lija George^{1,2}, A. Thamodharan^{1,2}, Arun Kumar Gupta^{1,2},
P. Satishchandra³

¹ Cognitive Neuroscience Center, National Institute of Mental Health, Neuro Science (NIMHANS)

² Dept of Neuroimaging and Interventional Radiology, National Institute of Mental Health and Neuro Science (NIMHANS)

³ Dept of Neurology, National Institute of Mental Health and Neuro Science (NIMHANS), Bangalore, India

Received May 23, 2013; Accepted November 09, 2013

ABSTRACT – Measuring neuro-haemodynamic correlates in the brain of epilepsy patients using EEG-fMRI has opened new avenues in clinical neuroscience, as these are two complementary methods for understanding brain function. In this study, we investigated three patients with drug-resistant reflex epilepsy using EEG-fMRI. Different types of reflex epilepsy such as eating, startle myoclonus, and hot water epilepsy were included in the study. The analysis of EEG-fMRI data was based on the visual identification of interictal epileptiform discharges on scalp EEG. The convolution of onset time and duration of these epilepsy spikes was estimated, and using these condition-specific effects in a general linear model approach, we evaluated activation of fMRI. Patients with startle myoclonus epilepsy experienced epilepsy in response to sudden sound or touch, in association with increased delta and theta activity with a spike-and-slow-wave pattern of interictal epileptiform discharges on EEG and fronto-parietal network activation pattern on SPECT and EEG-fMRI. Eating epilepsy was triggered by sight or smell of food and fronto-temporal discharges were noted on video-EEG (VEEG). Similarly, fronto-temporo-parietal involvement was noted on SPECT and EEG-fMRI. Hot water epilepsy was triggered by contact with hot water either in the bath or by hand immersion, and VEEG showed fronto-parietal involvement. SPECT and EEG fMRI revealed a similar fronto-parietal-occipital involvement. From these results, we conclude that continuous EEG recording can improve the modelling of BOLD changes related to interictal epileptic activity and this can thus be used to understand the neuro-haemodynamic substrates involved in reflex epilepsy.

Key words: reflex epilepsy, EEG, fMRI, eating, hot water, startle myoclonus

Correspondence:

Rose Dawn Bharath
Cognitive Neuroscience Center and Dept
of Neuroimaging and Interventional
Radiology,
National Institute of Mental Health
and Neuro Science (NIMHANS),
Hosur Road,
Bangalore 560029, India
<cns.researchers@gmail.com>

Reflex epilepsy has always been an important “model of study” for understanding the mechanisms involved in triggering seizures (Chifari *et al.*, 2004). Advances in neuroimaging and EEG recording techniques have opened new horizons for the study of mechanisms that trigger seizures. Functional imaging provides high spatial resolution, but lacks the temporal resolution to model neuronal processing. EEG provides neuronal information with high temporal resolution, but lacks the spatial resolution of MRI. Multimodal imaging utilizes the information provided by these two complementary methods, and EEG monitoring together with functional MRI (EEG-fMRI) is used to map neurohaemodynamic changes with good spatio-temporal resolution (Mazziotta *et al.*, 2001; Rosa *et al.*, 2010). This technique, when extended to epilepsy, offers a new opportunity to localise the generators of interictal epileptiform discharges (IEDs) and capture the perfusion changes which occur using blood oxygen level-dependent (BOLD) contrast at time points of the seizure activity provided by EEG (Müri *et al.*, 1998; Goldman *et al.*, 2000; Diehl *et al.*, 2003; Mulert *et al.*, 2005).

In this study, we used simultaneous EEG-fMRI in patients with reflex epilepsy to localise generators of IEDs. Brain MRI in these cases did not reveal obvious structural lesions which could account for seizures. The onset and duration of each IED was noted from the entire EEG recorded signal and this information was fed to a general linear model (GLM) of resting fMRI in order to determine the neuro-haemodynamic correlates of these IEDs. Since EEG-fMRI is a relatively new technique, we validated the findings with video-EEG (VEEG) and interictal and ictal SPECT findings. The regional cerebral blood flow (rCBF) values obtained from interictal SPECT localise seizure focus with a sensitivity of 75% (Menzel *et al.*, 1995) and we correlated these findings with interictal BOLD changes obtained from EEG-fMRI.

Materials and methods

We studied three cases of reflex epilepsy.

All patients underwent EEG and brain fMRI after undergoing VEEG, brain MRI, and SPECT imaging two days prior to the study. A dedicated epilepsy protocol, which included T1MPRAGE and high-resolution imaging of hippocampus, was performed for brain MRI acquisition. VEEG and SPECT were recorded during ictal and interictal periods. The SPECT perfusion agent, ethylcysteinate dimer (ECD), was used to detect vascular changes associated with epilepsy. The SPECT data recorded was further processed using Lassens correction to obtain the rCBF maps (Matsuda *et al.*, 1993).

Sensory stimulus, specific to the type of reflex epilepsy, was given to all patients before being taken to the scanner for EEG-fMRI investigation, during the interictal period. An EEG was also obtained prior to entering the MRI scanner, before the actual recording of EEG-fMRI, in order to increase the yield of obtaining IEDs during simultaneous acquisition. EEG was visually analysed for spikes by a neurologist. Institutional ethics clearance and informed consent from the patient was obtained in all the cases.

Clinically, all the patients had refractory reflex epilepsy and were on medications, and seizures could be provoked by sensory stimulus. None of these cases were planned for surgery.

Patient details

Case 1 was a 17-year-old, right-handed boy with startle myoclonus. He developed seizures in response to sudden sensory stimuli. Age at onset was 2 years. Neurological examination revealed blindness. The epilepsy was triggered by sudden sound and touch. The seizure was not associated with preictal aura or loss of consciousness or postictal tiredness. There was no family history of epilepsy. EEG showed increased delta and theta activity with a spike-and-slow-wave pattern of IEDs. Brain MRI revealed changes of hypoxic ischaemic injury in bilateral occipital lobes. Interictal and ictal SPECT was performed 48 hours beforehand. The interictal scan revealed perfusion changes in the bilateral frontal (more on the left than right side) and left parietal lobes (*figure 1A*). This was more extensive in the ictal period (*figure 1B*) and involved the bilateral frontal and parietal temporal lobes as well as the thalamus. Hypoperfusion was noted in bilateral occipital lobes in both ictal and interictal recordings, in accordance with MRI findings of hypoxic ischaemic injury. The patient was taken for simultaneous EEG-fMRI investigation after interictal discharges were recorded on EEG, before entering the scanner following a sudden auditory stimulus.

Case 2 was an 11-year-old, right-handed male with a history of eating epilepsy. He had epilepsy since the age of eight years. The epilepsy was triggered by sight or smell of food. The seizure was not associated with preictal or postictal symptoms. His elder sibling had a history of complex partial seizures since the age of 2 years. Video-EEG suggested left fronto-temporal interictal discharges. Brain MRI did not reveal any focal lesion. SPECT images during the interictal period revealed perfusion changes involving left frontal, left parietal, left perirolandic, and occipital areas (*figure 2A*). These changes were more extensive during ictal SPECT and involved bilateral frontal, temporal occipital, and parietal lobes (*figure 2B*). The patient

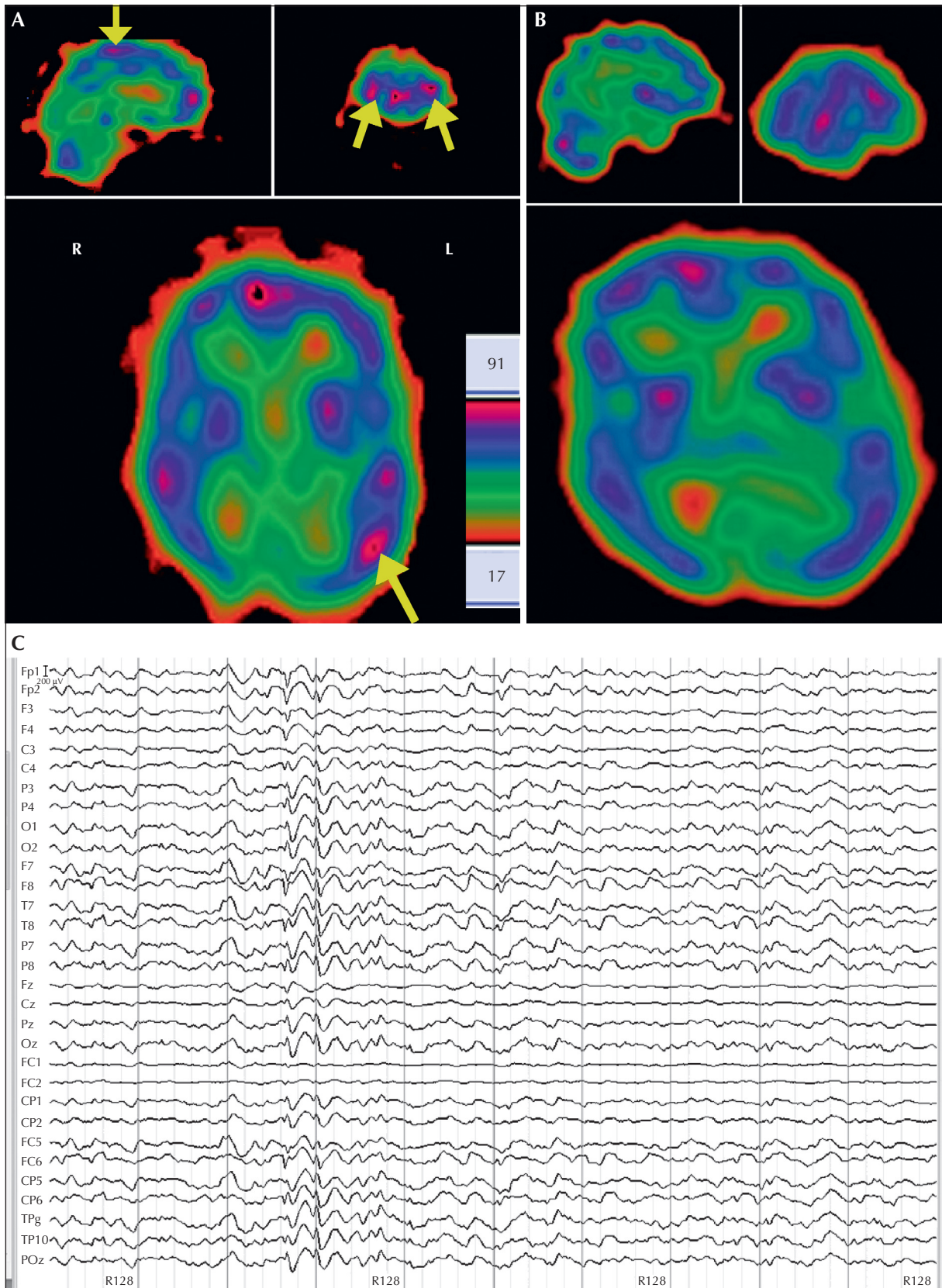


Figure 1. A case of startle myoclonus (case 1).

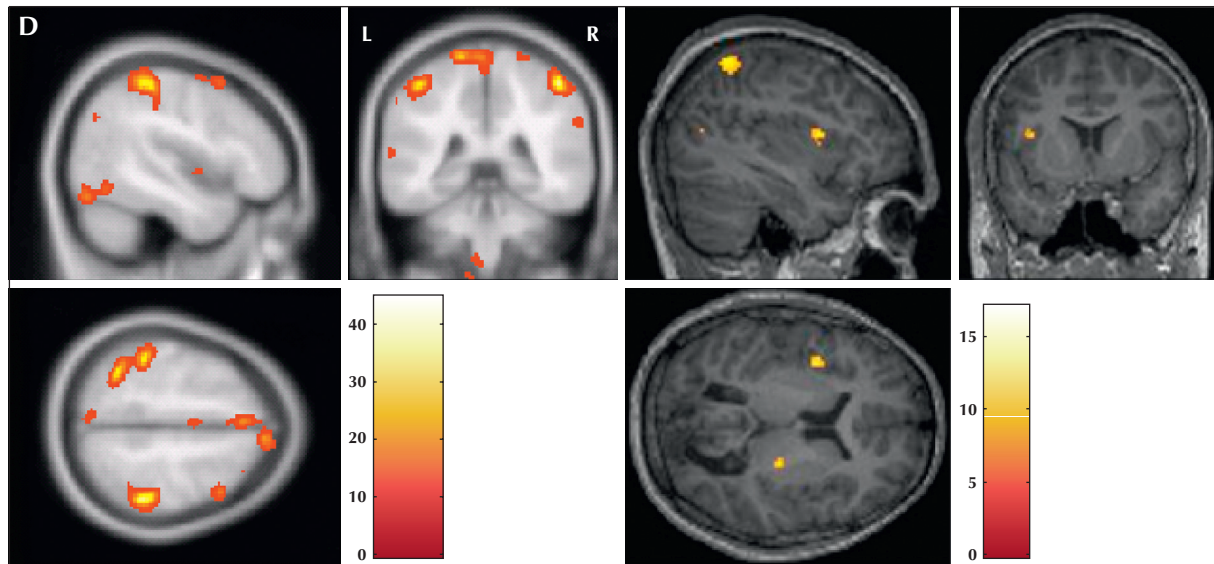


Figure 1. (case 1, continued) (A) Intercictal SPECT showing perfusion changes (rCBF) in the bilateral frontal region, more prominent on the left than the right side (yellow arrows; coronal image), and left parietal region (yellow arrows; axial plane and sagittal plane). (B) Ictal SPECT showing perfusion changes (rCBF) in the bilateral frontal (coronal image), temporo-parietal (sagittal image), and bilateral fronto parietal regions with thalamic involvement (axial image). (C) Intercictal EEG recording during simultaneous fMRI acquisition after cardio-ballistic and gradient artefact corrections. Increased delta and theta activity with spike-and-slow-wave pattern of IEDs is noted. (D) Location of peaks of regional activation using EEG-fMRI (MNI stereo tactic coordinates, $p < 0.001$ FDR uncorrected): the left perirolandic, left post central gyrus, and bilateral parietal lobes involving the superior and inferior parietal lobule, precuneus, and right thalamus.

The common network revealed by EEG-fMRI and SPECT (A) corresponded to the left frontal parietal network.

was taken for simultaneous EEG-fMRI recording after interictal discharges were recorded on EEG, before entering the scanner following an eating stimulus.

Case 3 was an 18-year-old, right-handed female with a history of hot water epilepsy since the age of 9 years. Generalised tonic-clonic epilepsy manifested after bathing in hot water or by touching things that were hot. The seizure was not associated with preictal or postictal symptoms. There was no family history of epilepsy. VEEG recorded left fronto-parietal IEDs. Brain MRI was normal. SPECT images during the interictal period revealed perfusion changes involving bilateral frontal, parietal temporal, and occipital regions (figure A). The changes were more extensive in the same areas during the ictal recording (figure B). The patient was taken for simultaneous EEG-fMRI investigation after interictal discharges were recorded on EEG before entering the scanner, following immersion of a hand in hot water.

Data acquisition

EEG

EEG data were recorded using a 32-channel MR compatible EEG system (Brain Products, Gilching, Germany).

The EEG cap consisted of 31 scalp electrodes placed according to the international 10-20 electrode placement system and one additional electrode dedicated to the electrocardiogram (ECG). Data were recorded relative to an FCz reference and a ground electrode was located at Iz (10-5 electrode system) (Oostenveld and Praamstra, 2001). Data were sampled at 5,000 Hz, with a bandpass of 0.016-250 Hz along with 50-Hz notch filtering. The impedance between electrode and scalp was kept below 5 k Ω .

fMRI

Resting fMRI was acquired using a 3T scanner (Skyra, Siemens, Erlangen, Germany). The subject's head was positioned within a 20-channel head coil with foam padding to provide comfort and to minimise head movements. T1-weighted, three dimensional high resolution imaging (MPRAGE) was performed to facilitate localisation of fMRI activation. Echo-planar images (EPI) using BOLD contrast were acquired and 185 volumes were obtained by applying the following EPI parameters: 34 slices, 6-mm slice thickness without any interslice gap, FOV of 192 \times 192 mm, matrix of 64 \times 64, repetition time of 3,000 ms, echo time of 35 ms, refocusing pulse of 90 $^\circ$, matrix of 256 \times 256 \times 114, and voxel size of 3 \times 3 \times 4 mm.

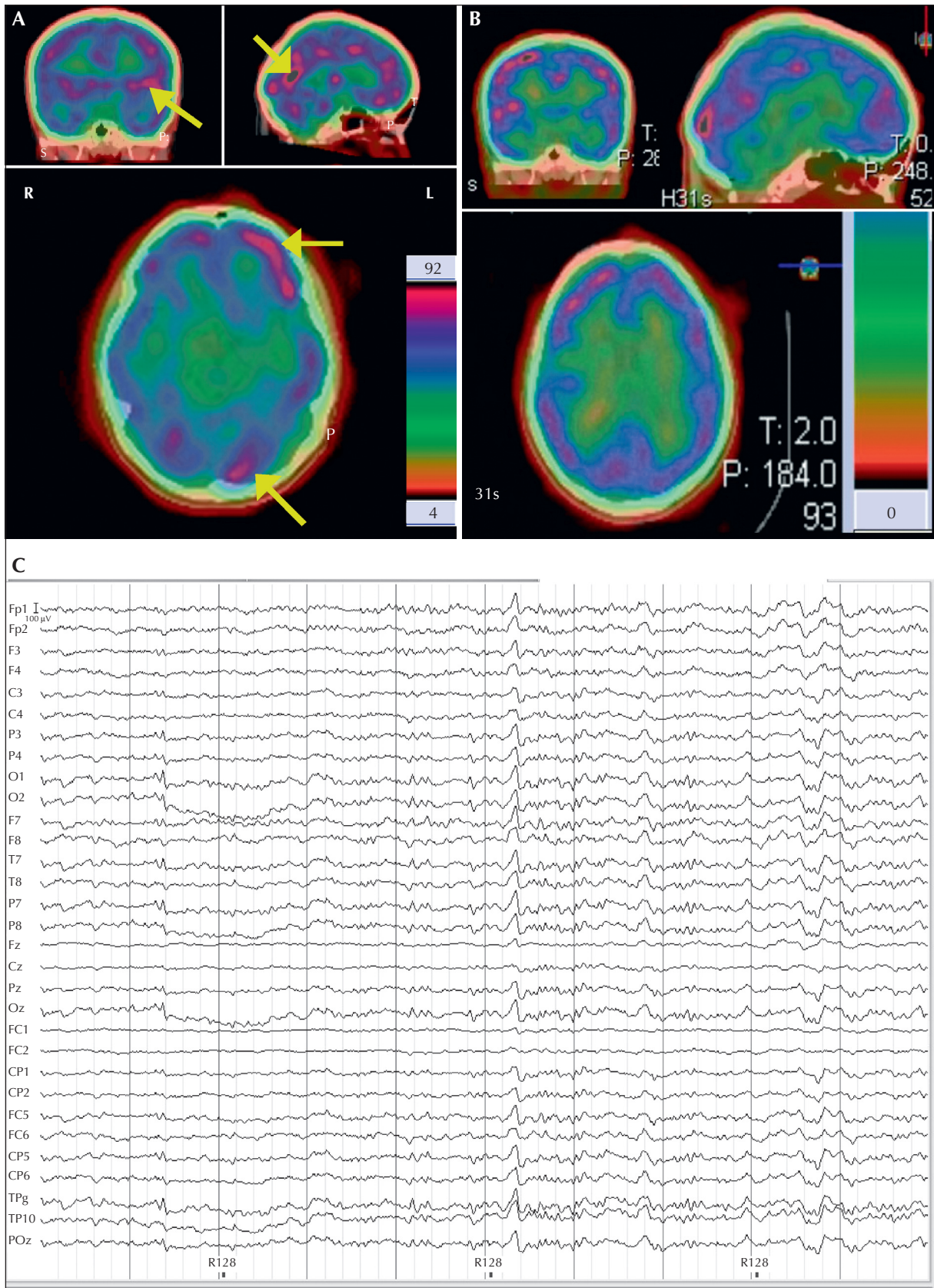


Figure 2. A case of eating epilepsy (case 2).

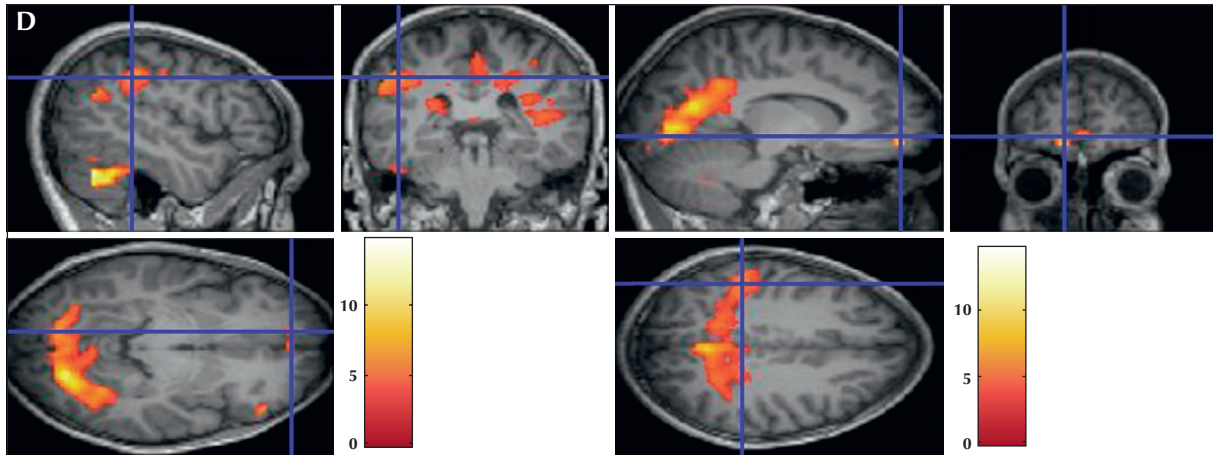


Figure 2. (case 2, continued) (A) Interictal SPECT showing perfusion changes (rCBF) in the left frontal, left perirolandic (yellow arrow; coronal plane), left parietal (yellow arrow; axial plane), and occipital areas (yellow arrow -sagittal plane). (B) Ictal SPECT showing perfusion changes (rCBF) in the bitemporal (coronal plane), occipital (sagittal plane), and bilateral fronto-parietal (axial plane) areas. (C) Interictal EEG recording during simultaneous fMRI acquisition after cardio-ballistic and gradient artefact corrections. Generalised sharp wave discharges are noted. (D) Location of peaks of regional activation using EEG-fMRI (MNI stereo tactic coordinates, $p < 0.001$ FDR uncorrected.): the left fronto-temporal (coronal plane), bilateral parietal areas (coronal plane), and mesial structures, such as the paracentral lobule, cingulate, medial frontal gyrus, and lingual and medial occipital gyrus (axial and sagittal plane). The common network revealed by EEG-fMRI and SPECT (A) corresponded to the left frontal parietal occipital network.

Data analysis

EEG data artefact removal and preprocessing

Raw EEG data were processed offline using Brain Vision Analyzer version 2 (Brain Products, Gilching, Germany). Gradient artefact correction was performed using modified versions of the algorithms proposed by Allen *et al.* (2000), whereby a gradient artefact template was subtracted from the EEG using a baseline-corrected sliding average of 20 MR volumes. Data were then down-sampled to 250 Hz. Following gradient artefact correction, the data were corrected for cardio-ballistic artefacts. For this, the average artefact subtraction method of Allen *et al.* (1998) was implemented using the Brain Vision Analyzer 2.

EEG-informed fMRI analysis

For the analysis of the resting functional data at the single subject level, we treated the IEDs of the EEG as single trial “event-related potentials (ERPs)” in an event-related design, considering the onset and duration as explanatory variables in the GLM analysis (Warbrick *et al.*, 2009).

fMRI analysis

Our study aimed to detect haemodynamic response during epileptogenic discharge in reflex epilepsy patients. The fMRI analysis was performed using statistical parametric mapping (SPM8; Wellcome Department of Cognitive Neurology, London). The data were realigned to the mean image, were then normalised to the Montreal Neurological Institute (MNI) template,

and were smoothed with a Gaussian kernel of 6 mm. Preprocessed data were modelled using the onset time and the duration of each IEDs as a regressor, convolved with a canonical haemodynamic response function (Friston *et al.*, 2007). An F-contrast was used to test for BOLD signal changes related to time of onset of the IEDs. Statistics were set at $p < 0.001$, uncorrected with a cluster size of 5 voxels since all the cases were assessed individually. The activated brain areas were labelled after transforming the coordinates of MNI template to Talairach coordinates. The areas showing greatest cluster size and mean intensity (T score) were considered significant for the purpose of lateralising the epilepsy network in a given case.

Results

Good quality EEG was obtained following pulse and gradient artefact subtraction, allowing identification of IEDs. Recordings of interictal discharges were observed and these were considered for further analysis. Head motion artefacts were absent since all the studies were performed during the interictal period.

Case 1: startle myoclonus

EEG changes included a spike-and-slow-wave pattern of IEDs, the onset and duration of which was convolved into the fMRI (figure 1C). Significant activations were noted in the left perirolandic, left post central gyrus, and bilateral parietal lobes involving the superior and inferior parietal lobule and precuneus on fMRI, with design based on the EEG data during simultaneous

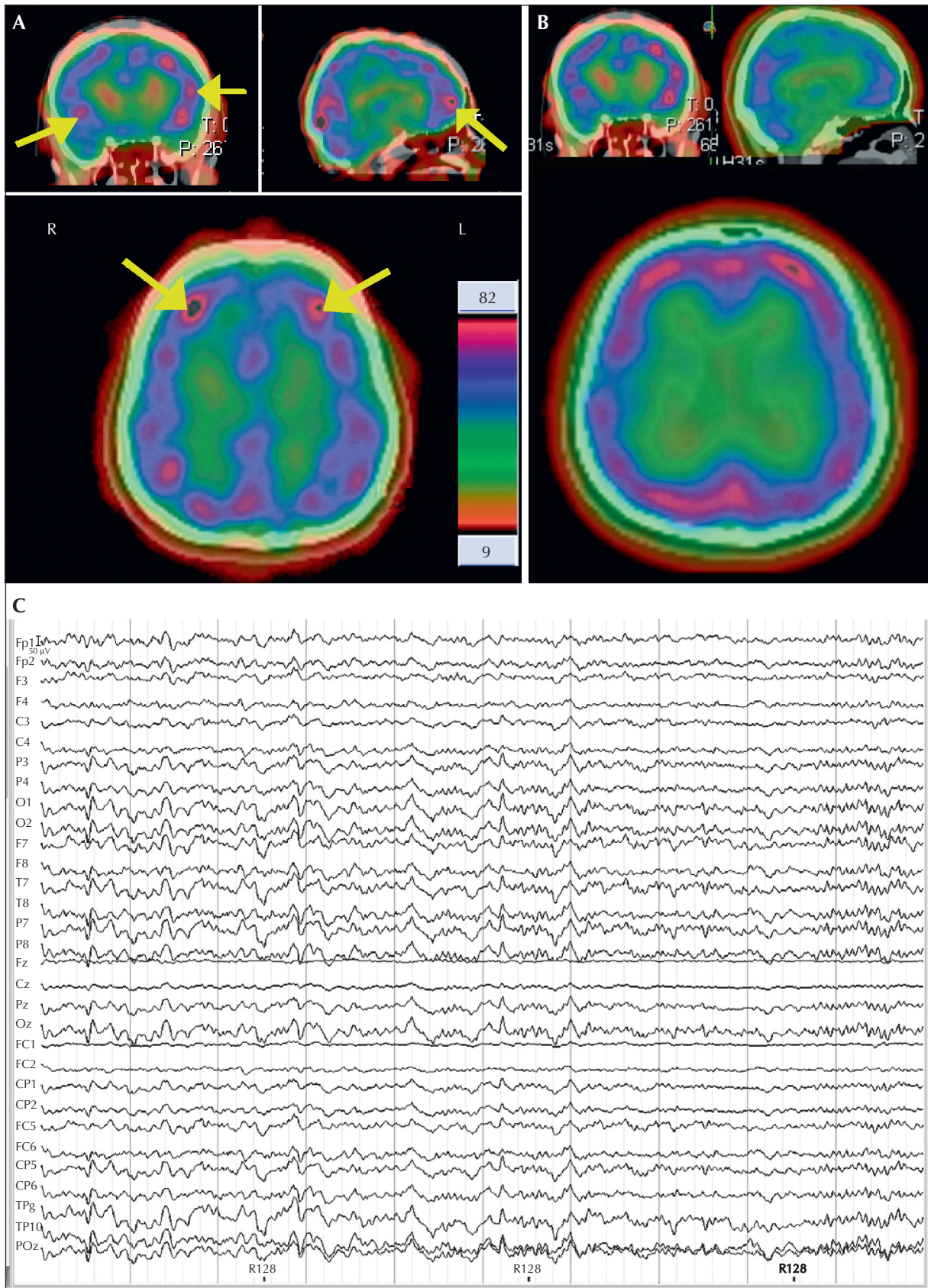


Figure 3. A case of hot water epilepsy (case 3).

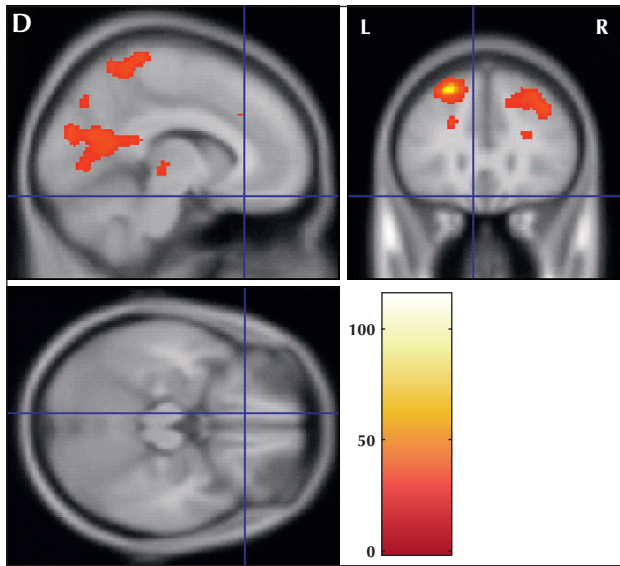


Figure 3. (case 3, continued) (A) Interictal SPECT showing perfusion changes (rCBF) in the bilateral frontal (yellow arrow; axial plane), biparietal (axial plane), temporal (yellow arrow; coronal plane), and occipital (sagittal plane) areas. (B) Ictal SPECT showing perfusion changes (rCBF) in the bilateral frontal, parietal, occipital (axial and sagittal plane), and bitemporal (coronal plane) regions. (C) Interictal EEG recording during simultaneous fMRI acquisition after cardio-ballistic and gradient artefact corrections. Spike-wave complex IEDs are noted. (D) Location of peaks of regional activation using EEG-fMRI (MNI stereo tactic coordinates, $p < 0.001$ FDR uncorrected.): the left superior and inferior frontal gyrus, mesial structures (such as the paracentral lobule), cingulate gyrus, medial frontal gyrus, and lingual and medial occipital gyrus.

The common network revealed by both EEG fMRI and SPECT (A) corresponded to the fronto-parietal occipital areas.

EEG-fMRI recording in the interictal period (figure 1D). The other neuronal substrate, for which significant clusters were obtained, corresponded to the right thalamus (figure 1D).

Case 2: eating epilepsy

EEG showed generalised sharp wave discharges (figure 2C). The onset and duration of each IED was convolved into the fMRI. Activation was noted in the left lateral fronto-temporal lobes involving the superior frontal gyrus, inferior frontal gyrus, superior temporal gyrus, bilateral parietal region, and the mesial structures, such as the paracentral lobule, cingulate gyrus, caudate, medial frontal gyrus, lingual, and medial occipital gyrus (figure 2D), with design based on the EEG data during simultaneous EEG-fMRI recording in the interictal period.

Case 3: hot water epilepsy

EEG changes noted included the spike-wave complex of the IEDs, the onset and duration of which was convolved into the fMRI (figure 3C). Activations were

noted in the left fronto-parietal structures involving superior frontal gyrus and right superior temporal gyrus. Medial structures involved were the parahippocampal gyrus, superior parietal lobule, inferior parietal lobule, posterior cingulate, and precuneus on fMRI, with design based on the EEG data during simultaneous EEG-fMRI recording in the interictal period (figure 3D).

Discussion

System epilepsies are a recently described entity. Unlike a classic seizure which spreads from a circumscribed region and propagates sequentially along one or more neural pathways to other brain areas, system epilepsy describes the susceptibility of a system as a whole, although it may be possible to identify some trigger areas within the system (Avanzini *et al.*, 2012). There may be symmetric or asymmetric involvement of cortical and subcortical structures with widespread multifocal or focal involvement. The network involved depends on the age and degree of maturity of the brain networks and can manifest as focal or generalised epilepsy (Capovilla *et al.*, 2009). Reflex epilepsy is one such entity in system epilepsy and can provide unique insight into the ictogenesis of human epilepsy and networks involved (Avanzini *et al.*, 2012). Reflex seizures can be either generalised or focal, with or without impairment of consciousness, and may be genetically inherited or acquired, idiopathic, cryptogenic or supported by a brain lesion (Striano *et al.*, 1989). Three types of reflex epilepsy are described; those induced by simple stimuli, complex stimuli, or higher cerebral functions. Functional imaging techniques such as PET, SPECT, and EEG-fMRI provide the potential to image epileptic activity. Abnormal EEG observed in patients with epilepsy is reflected by interictal epileptiform discharge, commonly called the “epileptic spike”. The SPECT imaging protocol includes both interictal and ictal imaging. EEG fMRI image acquisition is possible only during IED, due to gross patient motion, inherent during the ictal phase. Both EEG-fMRI and SPECT can be used to reflect the haemodynamic correlates of ictal and interictal discharges non-invasively.

EEG-fMRI exhibits good spatio-temporal resolution and can therefore be profitably used to study the structure and function of the distributed cortical and subcortical neural systems, putatively involved in reflex epilepsy, even in cryptogenic cases (Boucousis *et al.*, 2012).

ECD is a SPECT perfusion agent which is lipophilic and therefore diffuses into the normal brain and can be used to study perfusion changes during epilepsy. The rCBF values obtained after post-processing of SPECT

data during ictal and interictal phase reflect the blood flow changes associated with epilepsy.

In this study, the aim was to validate EEG-fMRI as a potential clinical tool for functional imaging with high spatio-temporal resolution to detect both cortical and subcortical networks involved in reflex epilepsy. The findings were correlated with interictal and ictal SPECT perfusion imaging and ictal VEEG for validation. Three types of reflex epilepsy were considered; startle myoclonus (somatosensory evoked epilepsy; simple stimuli) and eating and hot water epilepsy (complex stimuli evoked epilepsy). The foci were cryptogenic on MRI.

In startle epilepsy, seizures are mostly axial tonic and provoked by a sudden and unexpected stimulus. Structural imaging has shown perinatal hypoxic injury as the most common lesion associated with startle epilepsy (Alajouanine and Gastaut, 1955). Many theoretical and practical factors, including diagnostic, genetic, and pathophysiological issues still remain unresolved for both these entities. These issues can only be addressed by using robust imaging techniques in order to understand the pathophysiology, with good spatio-temporal resolution. Functional neuroimaging studies in startle epilepsy have implicated an interaction with the mesial fronto-parietal network, involving the supplementary motor area, perirolandic cortex, and precuneus (Fernández *et al.*, 2011). In our study,

a similar network was involved using EEG-fMRI and SPECT during the interictal period (*table 1*).

Epilepsy provoked by eating is a rare entity and the ictal semiology differs from patient to patient. The complex partial type of seizure is most commonly described. Diffuse cerebral damage is often noted on MRI and it may coexist with generalised or absence seizures (Loreto *et al.*, 2000). Reproduction of these seizures during EEG recording is often difficult as the stimulus is frequently complex, involving different components of eating, such as the sight of food, proprioceptive, olfactory or gustative stimulations, chewing, salivation, and gastric distension of eating (Cirignotta *et al.*, 1977). Two foci have been described in the amygdala or the perirolandic location, as demonstrated by EEG studies (Remillard *et al.*, 1998). A high incidence of familial clustering is known and bulky meals rich in carbohydrates have been postulated as possible triggering factors (Nagaraja and Chand, 1984). The case presented here was eating epilepsy triggered by olfactory and gustative stimulation, and the network implicated, based on EEG-fMRI, VEEG, and SPECT, was the left frontal parietal network and temporo-occipital areas (*table 1*).

Hot water epilepsy is most frequently reported in southern India due to the peculiar habit of pouring hot water over the head. This form of epilepsy is age related, more frequent in males, usually self-limited,

Table 1. Summary of the findings in reflex epilepsy using EEG-fMRI and correlation with VEEG and SPECT based on our study and other studies.

Type of reflex epilepsy	VEEG	SPECT	EEG-fMRI	Other studies
Startle myoclonus	Not available	Bilateral frontal (left more than right), left parietal lobe, and bilateral thalamii (ictal scan)	Left fronto-parietal lobes (post central gyrus, perirolandic, precuneus, superior, and inferior parietal lobule) and right thalamus.	Mesial fronto-parietal network (supplementary motor area, perirolandic cortex, and precuneus using fMRI) (Boucousis <i>et al.</i> , 2012).
Eating	Left fronto-parietal	Left frontal-parietal perirolandic area and occipital lobes	Left frontal temporal and bilateral parietal lobes, and mesial structures such as paracentral lobule, cingulate, caudate, medial frontal gyrus, and lingual and medial occipital gyri	Amygdala or in the perirolandic region using EEG (Loreto <i>et al.</i> , 2000).
Hot water	Left fronto-temporal	Bilateral fronto-parietal temporal occipital lobes	Left fronto-parietal temporal occipital lobes including mesial structures (parahippocampal gyrus, superior parietal lobule, posterior cingulate, and precuneus)	Left temporo-occipital area using EEG (Nagaraja and Chand, 1984).

and frequently familial (Satishchandra *et al.*, 1988). Patients are technically difficult to study in the laboratory. Lisvoski *et al.* (1992) reported a case of hot water epilepsy in which ictal EEG, recorded during a hot bath, showed focal epileptic discharges in the left temporo-occipital area and interictal SPECT showed hypometabolism in the same cerebral region. Our case is unique in that firstly, the patient developed significant IED even on immersion of the hand in hot water and this was replicated during the recording in the laboratory, and secondly, the left temporo-occipital network was involved, based on all three modalities, i.e. VEEG, EEG-fMRI, and SPECT (table 1).

This study is one of the first to describe the simultaneous role of EEG and fMRI in the study of pathophysiology of different types of reflex epilepsy. It is particularly useful in reflex epilepsy because, in addition to being a rare entity, in most of the cases the lesion is cryptogenic on MRI. Our study has not only demonstrated the network involved in each of these rare epilepsies in individual cases, but has also attempted to lateralise the onset zone by using perfusion imaging such as SPECT and VEEG findings for correlation.

Conclusion

The data discussed in this study supports the hypothesis that EEG-fMRI is a useful clinical tool to study the patho-physiological mechanisms and networks involved in epilepsy, particularly system epilepsy, such as reflex epilepsy, of which the pathophysiology is so far not understood. These developments can help open up new therapeutic possibilities. Further studies to validate and assess possible gains in sensitivity and specificity of the method are required and should be addressed in larger groups of patients. □

Acknowledgements and disclosures.

Our Cognitive Neuroscience Center is supported by the Department of Science and Technology (DST), India. We thank Dr Shobini L Rao (Dept. Clinical Psychology, NIMHANS, India) for inspiring us to carry out the research of simultaneous EEG-fMRI and multimodal neuroimaging. We thank our radiographers (Dept. Neuroimaging and Interventional Radiology, NIMHANS, India) for their support during data collection. The authors have no conflicts of interests to disclose.

References

Alajouanine T, Gastaut H. Synkinesis-startle and epilepsy startle triggered by unexpected sensory and sensitive factors. I. Anatomical and clinical data on 15 cases. *Rev Neurol (Paris)* 1955; 93: 29-41.

Allen PJ, Polizzi G, Krakow K, Fish DR, Lemieux L. Identification of EEG events in the MR scanner: the problem of pulse artifact and a method for its subtraction. *Neuroimage* 1998; 8: 229-39.

Allen PJ, Josephs O, Turner R. A method for removing imaging artifact from continuous EEG recorded during functional MRI. *Neuroimage* 2000; 12: 230-9.

Avanzini G, Manganotti P, Meletti S, *et al.* The system epilepsies: a pathophysiological hypothesis. *Epilepsia* 2012; 53: 771-8.

Boucousis SM, Beers CA, Cunningham CJB, *et al.* Feasibility of an intracranial EEG-fMRI protocol at 3T: risk assessment and image quality. *Neuroimage* 2012; 63: 1237-48.

Capovilla G, Berg AT, Cross JH, *et al.* Workshop Report: conceptual dichotomies in classifying epilepsies: partial versus generalized and idiopathic versus symptomatic (April 18-20, 2008, Monreale, Italy). *Epilepsia* 2009: 1645-9.

Chifari R, Piazzini A, Turner K, Canger R, Canevini MP, Wolf P. Reflex writing seizures in two siblings with juvenile myoclonic epilepsy. *Acta Neurol Scand* 2004; 109: 232-5.

Cirignotta F, Marcacci G, Lugaesi E. Epileptic seizures precipitated by eating. *Epilepsia* 1977; 18: 445-9.

Diehl B, Salek-haddadi A, Fish DR, Lemieux L. Mapping of spikes, slow waves, and motor tasks in a patient with malformation of cortical development using simultaneous EEG and fMRI. *Magn Reson Image* 2003; 21: 1167-73.

Fernández S, Donaire A, Maestro I, *et al.* Functional neuroimaging in startle epilepsy: involvement of a mesial frontoparietal network. *Epilepsia* 2011; 52: 1725-32.

Friston KJ, Ashburner JT, Kiebel SJ, Nichols TE, Penny WD. *Statistical parametric mapping: the analysis of functional brain images*. London: Academic Press, 2007.

Goldman RI, Stern JM, Engel J, Cohen MS. Acquiring simultaneous EEG and functional MRI. *Neurophysiol* 2000; 111: 1974-80.

Lisvoski F, Prier S, Koskas P, *et al.* Hot-water epilepsy in an adult: ictal EEG, MRI and SPECT features. *Seizure* 1992; 1: 203-6.

Loreto V, Nocerino C, Striano P, D'Aulos F, Boccella P, Striano S. Eating epilepsy. Heterogeneity of ictal semiology: the role of video-EEG monitoring. *Epileptic Disord* 2000; 2: 93-8.

Matsuda H, Tsuji S, Shuke N, Sumiya H, Tonami N, Hisada K. Noninvasive measurements of regional cerebral blood flow using technetium-99m hexamethylpropylene amine oxime. *Eur J Nucl Med* 1993; 20: 391-401.

Mazziotta J, Toga A, Evans A, *et al.* A probabilistic atlas and reference system for the human brain: International Consortium for Brain Mapping (ICBM). *Philos Trans R Soc Lond B Biol Sci* 2001; 356: 1293-322.

Menzel C, Hufnagel A, Grünwald F, *et al.* The relevance of interictal rCBF brain SPECT in temporal lobe epilepsy: diagnostic value and effects of spatial resolution. *Ann Nucl Med* 1995; 9: 215-23.

- Mulert C, Jäger L, Propp S, *et al.* Sound level dependence of the primary auditory cortex: simultaneous measurement with 61-channel EEG and fMRI. *Neuroimage* 2005; 28: 49-58.
- Müri RM, Felblinger J, Rösler KM, Jung B, Hess CW, Boesch C. Recording of electrical brain activity in a magnetic resonance environment: distorting effects of the static magnetic field. *Magn Reson Med* 1998; 39: 18-22.
- Nagaraja D, Chand RP. Eating epilepsy. *Clin Neurol Neurosurg* 1984; 86: 95-9.
- Oostenveld R, Praamstra P. The five percent electrode system for high-resolution EEG and ERP measurements. *Clin Neurophysiol* 2001; 112: 713-9.
- Remillard GM, Zifkin BG, Andermann F. Seizures induced by eating. *Adv Neurol* 1998; 75: 227-40.
- Rosa MJ, Kilner J, Blankenburg F, Josephs O, Penny W. Estimating the transfer function from neuronal activity to BOLD using simultaneous EEG-fMRI. *Neuroimage* 2010; 49: 1496-509.
- Satishchandra P, Shivaramakrishana A, Kaliaperumal VG, Schoenberg BS. Hot-water epilepsy: a variant of reflex epilepsy in southern India. *Epilepsia* 1988; 29: 52-6.
- Striano S, Meo R, Bilo L, Perrone M. An attempt to classify reflex seizures in accordance to recent proposals for classification of epilepsies. In: *Reflex seizures and reflex epilepsies. International colloquium on epileptic and reflex seizures.* Geneva (Switzerland): éditions Medecine and Hygiene, 1989: 489-93.
- Warbrick T, Mobascher A, Brinkmeyer J, *et al.* Single-trial P3 amplitude and latency informed event-related fMRI models yield different BOLD response patterns to a target detection task. *Neuroimage* 2009; 47: 1532-44.