

## CORRIGENDUM

# Corrigendum to “European Society for Vascular Surgery (ESVS) 2022 Clinical Practice Guidelines on the Management of Chronic Venous Disease of the Lower Limbs. [Eur J Vasc Endovasc Surg (2022) 63, 184-267]”

Marianne G. De Maeseneer <sup>a,\*</sup>, Stavros K. Kakkos <sup>a</sup>, Thomas Aherne <sup>a</sup>, Niels Baekgaard <sup>a</sup>, Stephen Black <sup>a</sup>, Lena Blomgren <sup>a</sup>, Athanasios Giannoukas <sup>a</sup>, Manjit Gohel <sup>a</sup>, Rick de Graaf <sup>a</sup>, Claudine Hamel-Desnos <sup>a</sup>, Arkadiusz Jawien <sup>a</sup>, Aleksandra Jaworucka-Kaczorowska <sup>a</sup>, Christopher R. Lattimer <sup>a</sup>, Giovanni Mosti <sup>a</sup>, Thomas Noppeney <sup>a</sup>, Marie Josee van Rijn <sup>a</sup>, Gerry Stansby <sup>a</sup>

ESVS Guidelines Committee <sup>b</sup>, Philippe Kolh, Frederico Bastos Goncalves, Nabil Chakfé, Raphael Coscas, Gert J. de Borst, Nuno V. Dias, Robert J. Hinchliffe, Igor B. Koncar, Jes S. Lindholt, Santi Trimarchi, Riikka Tulamo, Christopher P. Twine, Frank Vermassen, Anders Wanhainen

Document Reviewers <sup>c</sup>, Martin Björck, Nicos Labropoulos, Fedor Lurie, Armando Mansilha, Isaac K. Nyamekye, Marta Ramirez Ortega, Jorge H. Ulloa, Tomasz Urbanek, Andre M. van Rij, Marc E. Vuylsteke

The authors regret there was a mistake in Figure 6 and 13. In Figure 6, it should read ‘Compression’ for oedema, to include inelastic compression as well (green box); in Figure 13, the pressure at the ankle should read ‘ $\leq 40$  mm Hg’, for small and recent onset ulcer (yellow box):

DOI of original article: <https://doi.org/10.1016/j.ejvs.2021.12.024>

<sup>a</sup> **Writing Committee:** Marianne G. De Maeseneer (Chair)\* (Rotterdam, The Netherlands), Stavros K. Kakkos (Co-Chair) (Patras, Greece), Thomas Aherne (Galway, Ireland), Niels Baekgaard (Copenhagen, Denmark), Stephen Black (London, United Kingdom), Lena Blomgren (Örebro, Sweden), Athanasios Giannoukas (Larissa, Greece), Manjit Gohel (London, United Kingdom), Rick de Graaf (Friedrichshafen, Germany), Claudine Hamel-Desnos (Caen, France), Arkadiusz Jawien (Torun, Poland), Aleksandra Jaworucka-Kaczorowska (Gorzów, Poland), Christopher R. Lattimer (London, United Kingdom), Giovanni Mosti (Lucca, Italy), Thomas Noppeney (Regensburg, Germany), Marie Josee van Rijn (Rotterdam, The Netherlands), Gerry Stansby (Newcastle upon Tyne, United Kingdom)

<sup>b</sup> **ESVS Guidelines Committee:** Philippe Kolh (Chair, Review Coordinator) (Liège, Belgium), Frederico Bastos Goncalves (Lisboa, Portugal), Nabil Chakfé (Strasbourg, France), Raphael Coscas (Boulogne-Billancourt, France), Gert J. de Borst (Utrecht, The Netherlands), Nuno V. Dias (Malmö, Sweden), Robert J. Hinchliffe (Bristol, United Kingdom), Igor B. Koncar (Belgrade, Serbia), Jes S. Lindholt (Odense, Denmark), Santi Trimarchi (Milan, Italy), Riikka Tulamo (Helsinki, Finland), Christopher P. Twine (Bristol, United Kingdom), Frank Vermassen (Ghent, Belgium), Anders Wanhainen (Uppsala and Umeå, Sweden).

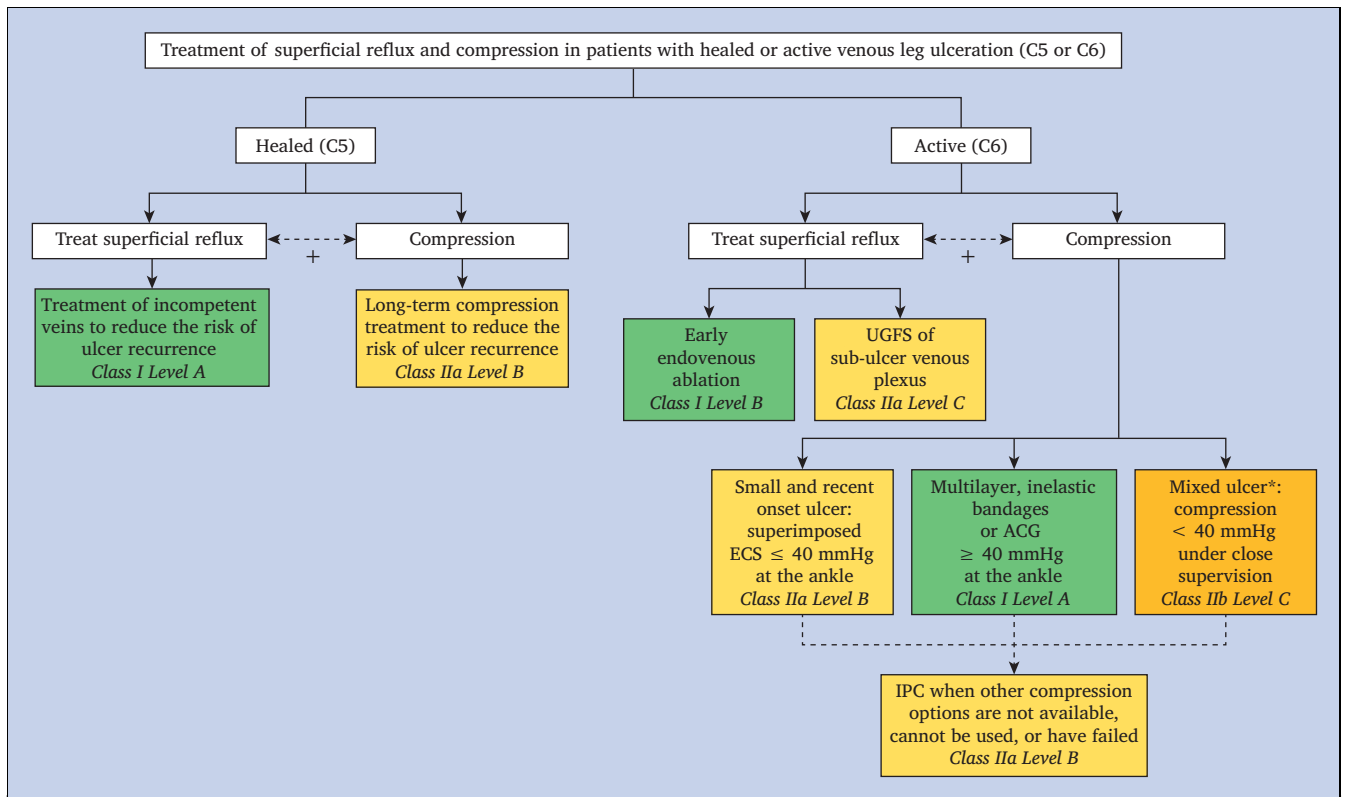
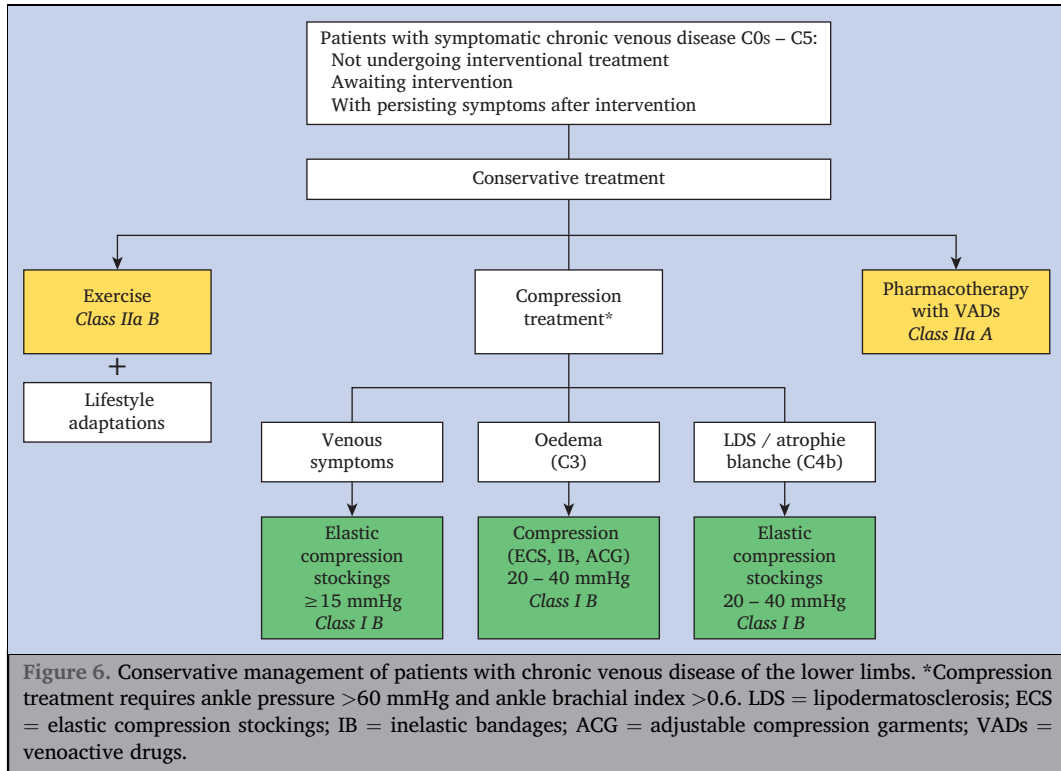
<sup>c</sup> **Document Reviewers:** Martin Björck (Uppsala, Sweden and Tartu, Estonia), Nicos Labropoulos (Stony Brook, NY, USA), Fedor Lurie (Toledo, OH, USA), Armando Mansilha (Porto, Portugal), Isaac K. Nyamekye (Worcester, United Kingdom), Marta Ramirez Ortega (Madrid, Spain), Jorge Ulloa (Bogota, Colombia), Tomasz Urbanek (Katowice, Poland), Andre van Rij (Dunedin, New Zealand), Marc Vuylsteke (Tiel, Belgium).

\* Corresponding author.

E-mail address: [mdmaesen@gmail.com](mailto:mdmaesen@gmail.com) (Marianne G. De Maeseneer).

1078-5884/© 2022 The Author(s). Published by Elsevier B.V. on behalf of European Society for Vascular Surgery. This is an open access article under the CC BY license (<http://creativecommons.org/licenses/by/4.0/>).

<https://doi.org/10.1016/j.ejvs.2022.05.044>



**Figure 13.** Superficial vein treatment modalities and compression therapy in patients with healed or active venous leg ulceration of CEAP (Clinical Etiological Anatomical Pathophysiological classification) clinical class C5 and C6 e details of general management strategy, outlined in Fig. 12. \*Compression for mixed arterial and venous ulcers only if systolic ankle pressure  $>60$  mmHg. UGFS = ultrasound-guided foam sclerotherapy; ECS = elastic compression stockings; ACG = adjustable compression garments.

The authors would like to apologise for any inconvenience caused.