

# Unusual complication of inferior mesenteric artery embolization for type 2 endoleak

Arnaud Kerzmann<sup>1</sup>, Denis Henroteaux<sup>2</sup>, Evelyne Boesmans<sup>1</sup>, Jean-Olivier Defraigne<sup>1</sup> <sup>1</sup>Dept of Cardiovascular and Thoracic Surgery, CHU Liège, Belgium | <sup>2</sup> Dept of Radiology, CHU Liège, Belgium

## Introduction

Type 2 endoleaks occur in almost 20 % of patients after endovascular aortic aneurysm repair (EVAR). Most of them disappear spontaneously. Some of them can lead to aneurysmal sac expansion and need secondary intervention. Treatment options are embolization, laparoscopic ligation or surgery. Embolization can be performed through transarterial or translumbar way.

We report one case of type 2 endoleak embolization with ethylene vinyl alcohol copolymer (Onyx Medtronic®). The last embolized into the branches of the inferior mesenteric artery and induced left colic necrosis.

## Case Report

- 74 years old man
- Past history of arterial hypertension, dyslipidemia and smoking habits
- EVAR for abdominal aortic aneurysm with greater diameter of 68 mm
- Primary type 2 endoleak coming from the inferior mesenteric artery and some lumbar arteries
- 16 months after EVAR, the endoleak stayed and the sac diameter raised from 68 mm to 77 mm
- Under local anesthesia, transarterial embolization with ethylene vinyl alcohol copolymer (Onyx Medtronic®) performed
- At the end of the procedure, the liquid embolic agent embolized into the branches of the inferior mesenteric artery. Sudden and severe abdominal pain, Hartmann's operation for acute left colic necrosis
- 3 months after the embolization, aneurysmal sac diameter stable despite residual type 2 endoleak coming from lumbar arteries and intestinal continuity restored
- Follow-up is going on

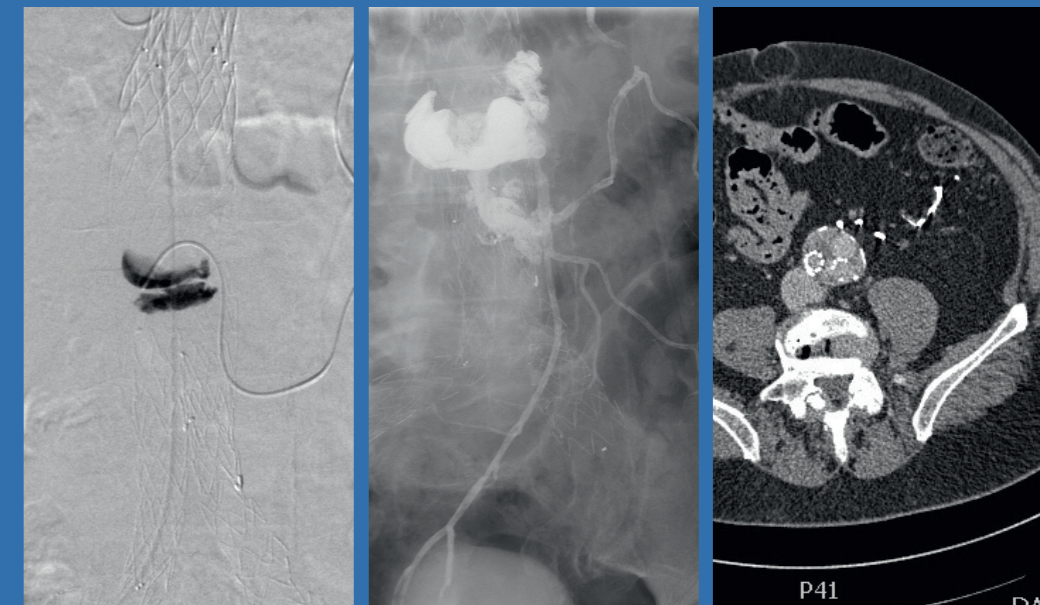
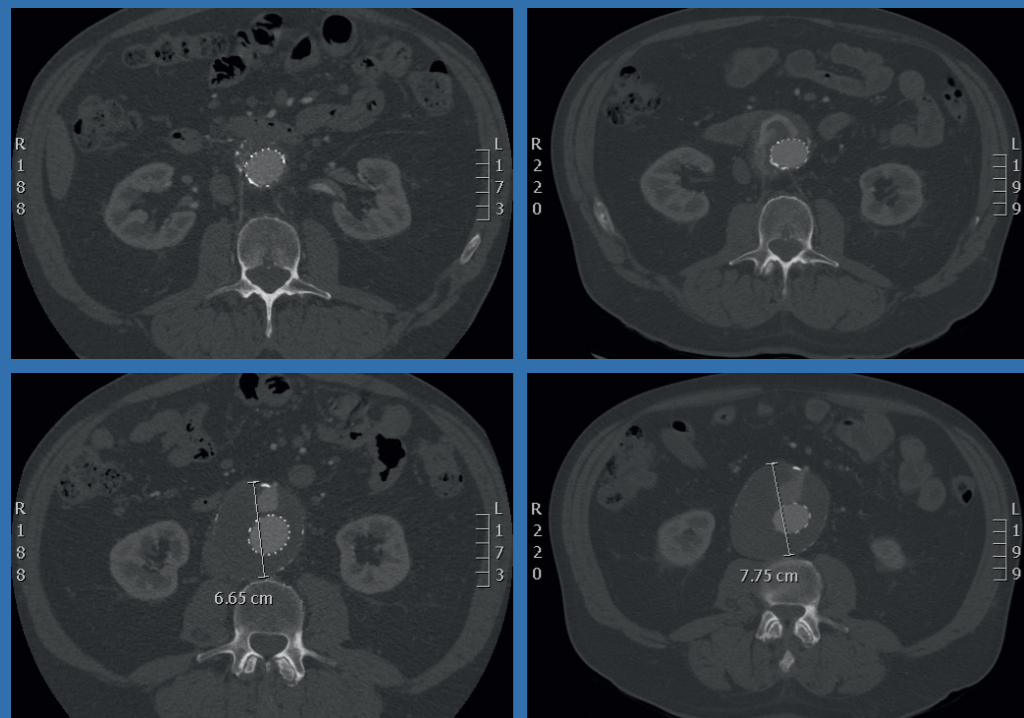
## Conclusion

Type 2 endoleaks with aneurysmal sac growth have to be treated. Embolization with ethylene vinyl alcohol copolymer is one option.

Take care of :

- to inject the copolymer very slowly
- to aspirate in the microcatheter by removing it

Microvascular plugs could be an option to avoid Onyx® embolization.



No conflict of interest

LINC, Leipzig, Germany,  
January 22-25, 2019

**CHU**  
de Liège

**LIÈGE**  
université