



**i-MEET**  
**NEXT GENERATION**  
Multidisciplinary European Endovascular Therapy

# Percutaneous angioplasty with drug eluting balloon for infra-inguinal venous bypass stenosis

*Ponte C., Kerzmann A., Boesmans E., Van Damme H., Defraigne J.-O.  
Dept. of Cardiovascular and Thoracic Surgery, CHU Liège, Belgium*



# Disclosure of Interest

Speaker name: Ponte Charlotte

✓ I do not have any potential conflict of interest

# Introduction (1)

Infra-inguinal bypasses have better results with saphenous vein graft<sup>1</sup>.

There are 3 types of venous bypass failure: thrombosis, intimal hyperplasia and atherosclerosis. Most of the time intimal hyperplasia occurs between the third and the eighteenth month after the bypass operation.

<sup>1</sup> Saphenous vein versus PTFE for above-knee femoropopliteal bypass. A review of the literature. Klinkert P & al. Eur J Vasc Endovasc Surg. 2004 Apr;27(4):357-362.

## Introduction (2)

Open surgical repair is still the best way to treat infra-inguinal venous bypass stenosis. Conventional percutaneous angioplasty doesn't show high primary patency rates at short-term<sup>2</sup>.

The recent studies about paclitaxel coated balloons in peripheral arterial disease (PAD) reveal the benefits of such balloons compared to not coated balloons<sup>3</sup>. We report our experience about use of drug eluting balloons to treat infra-inguinal venous bypass stenosis.

<sup>2</sup> Surgical and endovascular revision of infrainguinal vein bypass grafts: analysis of midterm outcomes from the PREVENT III trial. Berceli SA & al. J Vasc Surg. 2007 Dec;46(6):1173-1179.

<sup>3</sup> Trial of a paclitaxel-coated balloon for femoropopliteal artery disease. Rosenfield K & al. N Eng J Med. 2015 Jul 9;373(2):145-153.

# Methods and results (1)

From November 2012 to April 2018, 10 patients with 12 infra-inguinal venous bypass stenosis had 14 dilatations with paclitaxel coated balloons.

They were reviewed prospectively.

# Methods and results (2)

	Gender & age	Bypass	Previous PTA	Age of bypass (months)	Rutherford stage
1	F 51	popliteal above knee	yes	7	3
2	M 57	popliteal below knee	yes	13	3
3	M 62	posterior tibial	yes	3	3
4	M 72	popliteal above knee	yes	10	5
5	F 72	popliteal below knee	no	2	1
6	F 87	peroneal	no	20	5
7	F 70	popliteal above knee	no	4	3
8	F 56	popliteal above knee	no	9	6
9	M 57	popliteal below knee	no	52	2
10	F 57	popliteal above knee	no	21	3
11	F 71	popliteal above knee	no	9	3
12	M 64	posterior tibial	no	9	3

# Methods and results (3)

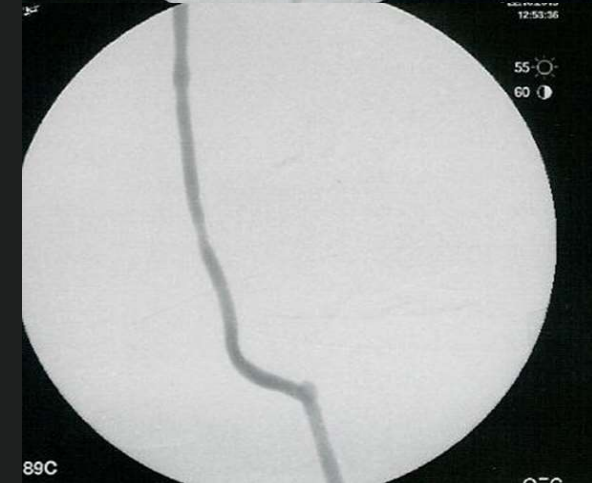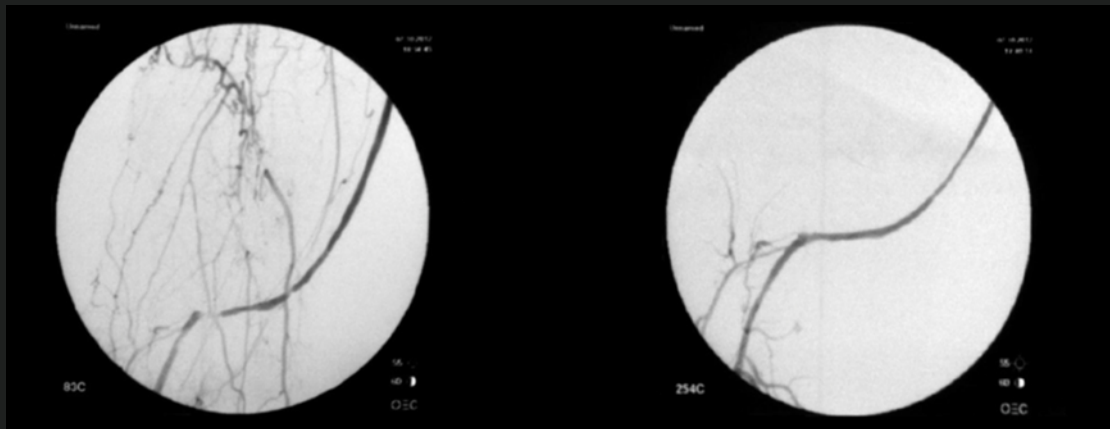
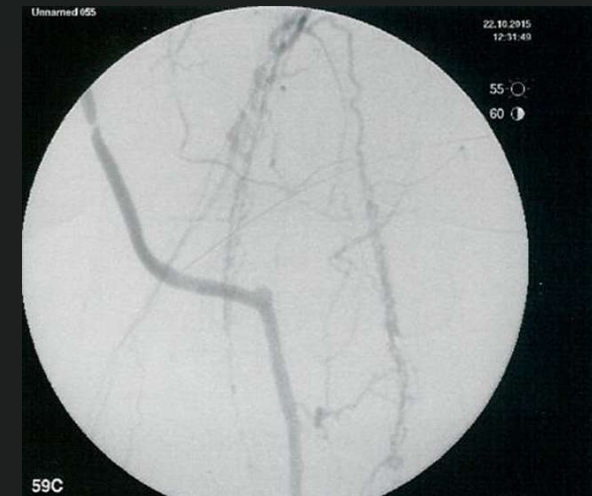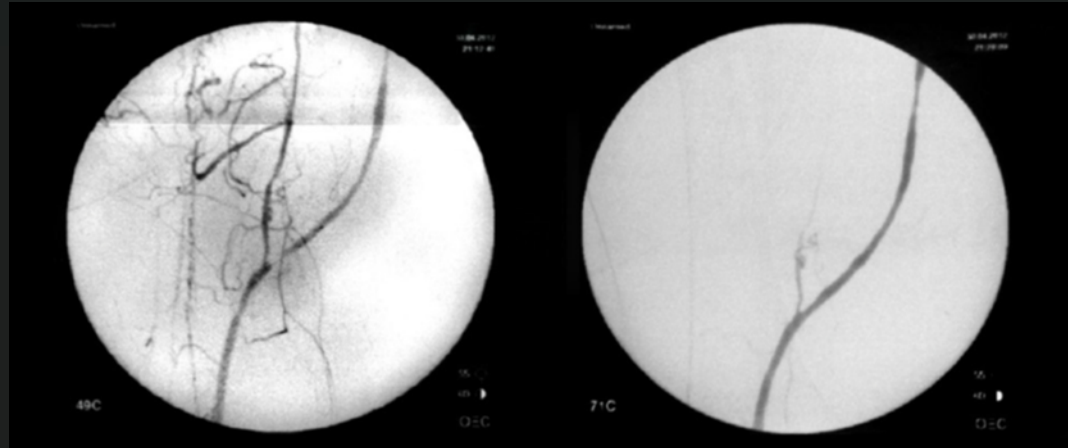
	Puncture side	Stenosis location	Predilatation	Dilatation with paclitaxel coated balloon
1	same as bypass	distal anastomosis	no	4 mm – 12 cm
2	controlateral	distal anastomosis	3 mm – 4 cm	4 mm – 8 cm
3	controlateral	middle third	3 mm – 4 cm	3,5 mm – 4 cm
4	same as bypass	distal anastomosis	4 mm – 4 cm	4 mm – 6 cm
5	same as bypass	distal anastomosis	no	5 mm – 6 cm
6	controlateral	distal anastomosis	2 mm – 4cm	2,5 mm – 8 cm
7	controlateral	proximal anastomosis	no	5 mm – 8 cm
8	same as bypass	distal third	4 mm – 4cm	5 mm – 15 cm
9	controlateral	distal third	2 mm – 4cm	4 mm – 8 cm
10	same as bypass	proximal third	4 mm – 2 cm	6 mm – 6 cm
11	same as bypass	distal anastomosis	3 mm – 10 cm	3,5 mm – 12 cm
12	controlateral	proximal anastomosis	3 mm – 4 cm	4 mm – 10 cm

# Methods and results (4)

	Follow-up (months)	Results
1	65	M 15: new dilatation M 24: thrombosis
2	65	M 33: thrombosis
3	56	good
4	30	M 30: death (brochopneumonia)
5	53	good
6	50	good
7	12	M 12: death (myocardial infarction)
8	34	good
9	30	good
10	29	M 29: new dilatation
11	0	D 1: death (myocardial infarction)
12	4	good



# Methods and results (5)



# Conclusions

The use of drug eluting balloon to treat infra-inguinal venous bypass stenosis is **minimal invasive** and **safe**.

**Randomized studies** are mandatory to compare paclitaxel coated balloon with conventional balloon angioplasty and with open surgical repair for the treatment of infra-inguinal venous bypass stenosis.