



Case Report

Allan-Herndon-Dudley syndrome in a female patient and related mechanisms

Caroline Olivati^{a,b,*}, Bianca Pereira Favilla^c, Erika Lopes Freitas^d, Bibiana Santos^d, Maria Isabel Melaragno^c, Vera Ayres Meloni^{a,c}, Flavia Piazzon^{a,e,f}

^a Rare Rosy Clinic, São Paulo, Brazil

^b Fleury Medicina e Saúde, São Paulo, Brazil

^c Genetics Division, Department of Morphology and Genetics, Universidade Federal de São Paulo, São Paulo, Brazil

^d Mendelics Análise Genômica, São Paulo, Brazil

^e Neuromuscular Reference Center, Department of Pediatrics, University Hospital Liège & University of Liège, Belgium

^f Neurometabolic Unit, University of São Paulo, São Paulo, Brazil



ARTICLE INFO

Keywords:

Allan-Herndon-Dudley syndrome

SLC16A2 gene

X-chromosome inactivation

ABSTRACT

Allan-Herndon-Dudley syndrome (AHDS) is characterized by neuropsychomotor developmental delay/intellectual disability, neurological impairment with a movement disorder, and an abnormal thyroid hormone profile. This disease is an X-linked disorder that mainly affects men. We described a female patient with a de novo variant in the *SLC16A2* gene, a milder AHDS phenotype, and a skewed X chromosome inactivation profile. We discuss the mechanisms associated with the expression of the phenotypic characteristics in female patients, including *SLC16A2* gene variants and cytogenomic alterations, as well as preferential inactivation of the normal X chromosome.

1. Introduction

Allan-Herndon-Dudley syndrome (AHDS, OMIM #300523) is a rare X-linked disorder, which basically affects males. It is characterized by global developmental delay and/or intellectual disability, feeding difficulties, hypotonia in infancy with poor head control, dystonia, choreoathetosis, paroxysmal movement disorder, pyramidal signs, and abnormal thyroid profile tests [1,2]. Most males have a severe intellectual disability with no speech acquisition and no development of motor milestones [1,2].

The *SLC16A2* gene, located at Xq13.2, is associated with the AHDS. It encodes the MCT8 protein, a cellular transmembrane transporter specific for thyroid hormones [3], which plays an important role in neurogenesis, neuronal migration, and myelination [4]. Affected individuals show high 3,3,5'-triiodothyronine (free t3), low triiodothyronine (free and total t4), normal levels of thyroid-stimulating hormone (TSH), and a free t3/t4 ratio > 0.75, leading to peripheral hyperthyroidism, with consequent muscle wasting, high heart rate, and hypertension due to high t3 in serum. In contrast, there is central hypothyroidism because MCT8 is essential for thyroid hormones to cross the hematoencephalic barrier [4].

Although large deletions have been associated with severe encephalopathy, no genotype-phenotype association has been established [5,6].

Heterozygous female carriers of mutations in *SLC16A2* are usually asymptomatic and show only abnormal laboratory thyroid tests [7–9], since they present a normal allele, besides the mutated one.

Regarding the symptomatic carriers, the literature shows two female patients with AHDS who presented markedly skewed X-chromosome inactivation towards the allele without the variant: one due to a balanced X-9 translocation [5], and the other due to a deletion involving the *SLC16A2* gene as well as the X-inactivation center [10]. Thus, investigating X-chromosome inactivation in symptomatic carriers of AHDS may also assist the genotype-phenotype correlation.

We report a female patient, who shows a moderate phenotype of AHDS and heterozygous de novo missense *SLC16A2* variant, and investigate her XCI pattern.

2. Case presentation

The 16-year-old female patient is the second child of a non-consanguineous couple with a healthy 17-year-old brother. She has

* Corresponding author at: Rare Rosy Clinic, Rua Borges Lagoa, 1080, CEP 04038-020 São Paulo, SP, Brazil.

E-mail address: geneticista.olivati@gmail.com (C. Olivati).

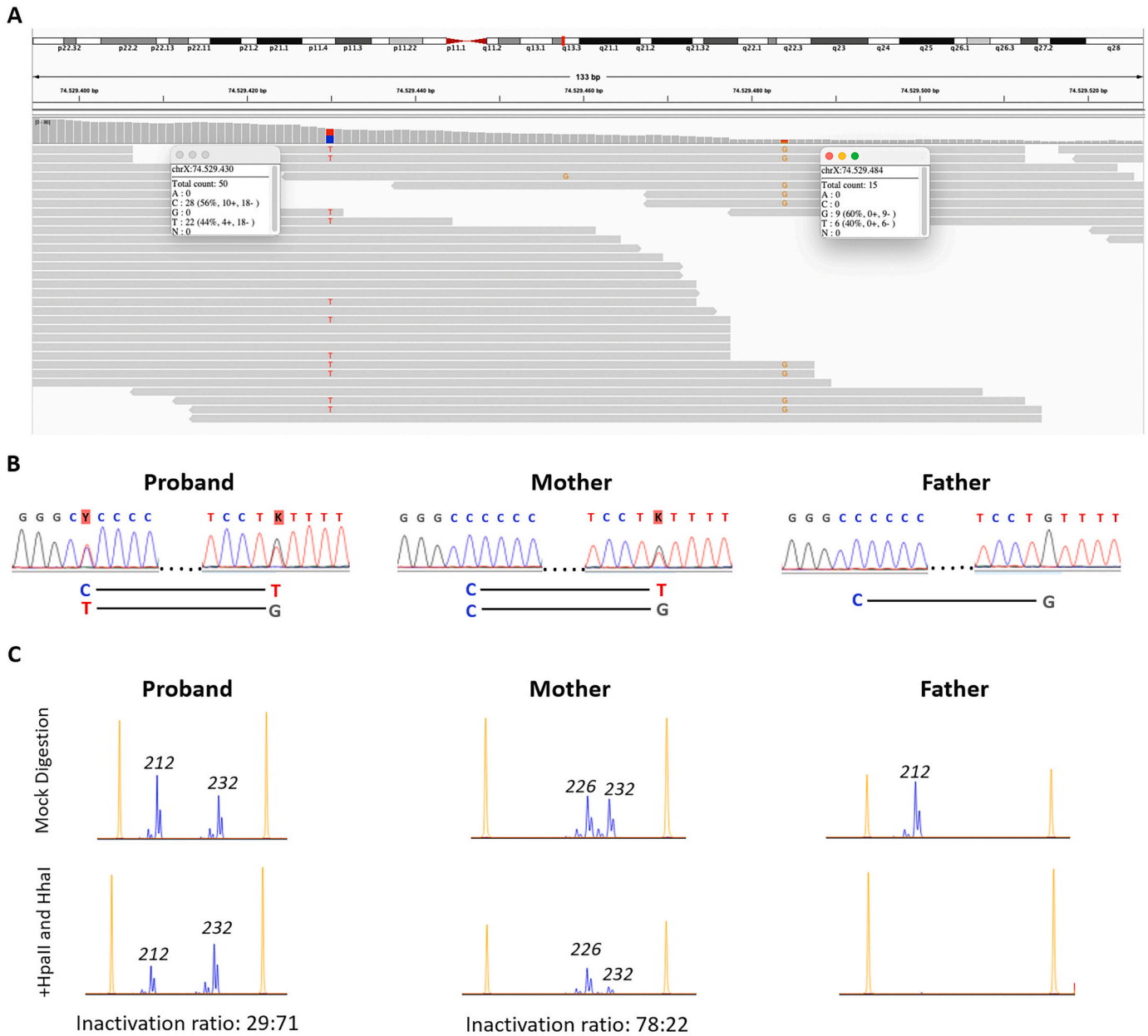


Fig. 1. Sequencing and X-inactivation results from the family. (A) At the top, ideogram of the X chromosome showing the site of the *SLC16A2* gene, at Xq13.2 (red rectangle); and at the bottom, partial result of whole-exome sequencing showing the missense variant in *SLC16A2*: c.1388C > T:p.Pro463Leu(ENST00000587091) on the left, and the heterozygous SNP (rs5937843), mapped at chrX:74529484 (GRCh38), 54 base pairs downstream from the *SLC16A2* variant, on the right. Note that the mutated *SLC16A2* allele is in cis with the G allele of the SNP. (B) Partial results of Sanger sequencing show the heterozygous *SLC16A2* variant (left) in the probanda and not in her parents, and the genotypes of the upstream SNP (right). At the bottom, a schematic representation of the *SLC16A2* variant plus downstream SNP haplotypes of the different members of the family reveals that the *SLC16A2* variant in the probanda is on the X-chromosome received from her father. (C) Electropherogram of the HUMARA results shows allele peaks from the microsatellite polymorphic marker in the first exon of the androgen receptor (AR) gene, located at Xq11.2. The allele peaks correspond to the PCR products of samples after mock digestion (top) and after digestion with the methylation-sensitive restriction enzymes *HpaII* and *HhaI* (bottom). The probanda presents a 212-bp allele of paternal origin and a 232-bp allele of maternal origin, which is preferentially inactive (inactivation ratio: 29 ± 1:71 ± 1). Her mother presented skewed inactivation towards the 226-bp allele, with the 232-bp allele being preferentially active (inactivation ratio: 78 ± 1:22 ± 1).

attention deficit hyperactivity and an intellectual quotient (IQ) of 71 with autistic features. Her height was 1.66 m (50-85th centile), weight of 60 kg with a body mass index (BMI) of 21.8 kg/m² (50-85th centile), span of 172 cm (6 cm above her height), and head circumference of 55 cm (+2 SD). The blood pressure was 110 × 72 mmHg, and the heart rate was 93 beats/min. She has mild dysmorphic facial features (short forehead, bitemporal narrowing, upslanted palpebral fissure, microtia I, narrow palate, and retrognathia), marfanoid habitus, joints hyperflexibility, lumbar hyperlordosis, mild thoracic scoliosis, genu

recurvatum, and dry skin in both arms. The thyroid workup showed high serum levels of total-t3 and free-t3 [total-t3 220ng/dL (RV 72-214 ng/dL); free t3 0,39 ng/dL (RV 0,24–0,37 ng/dL)], with low level of free-t4 [free-t4 0,9 ng/dL (RV 1,0–1,6 ng/dL)] and normal levels of TSH [TSH 2,8 m UI/L (RV 0,50–4,9mUI/L)]. The brain magnetic resonance imaging was unremarkable.

3. Cytogenetic and molecular analysis

The probanda and her parents presented normal karyotypes. Whole-exome sequencing (WES) revealed a de novo rare missense variant in *SLC16A2*: c.1388C > T:p.Pro463Leu (ENST00000587091), confirmed by Sanger sequencing, which is absent in gnomAD and ClinVar. No deletion or duplication of the *SLC16A2* gene was identified in the CNV analysis of the WES. In silico analyses support that this missense variant has a deleterious effect on protein structure or function, confirmed by a functional study [11]. The variant was classified as likely pathogenic according to the American College of Medical Genetics (ACMG – PS3, PM2, PM6, PP3). The haplotype analysis using a downstream single nucleotide polymorphism (SNP, rs5937843) revealed that the missense variant was present in the X chromosome that originated from the father (Fig. 1).

XCI studies by HUMARA, as described by Favilla et al. [2021] [13], revealed inactivation of the maternal and paternal alleles in the ratio of 71% and 29%, respectively, with the normal allele being preferentially inactive. Her mother presented a skewed XCI towards a different allele (78%:22%) (Fig. 1).

4. Discussion and conclusions

In our patient, WES revealed only one potential variant associated with developmental delay and autism. The variant is present in the coding region, leading to the Pro463Leu, which was previously associated with partial loss of thyroid hormone transport activity [11]. The same variant c.1388C > T in the *SLC16A2* gene was also described in an 11-month-old male with global developmental delay, decreased muscle strength, hypotonia with severe head lag, and abnormal thyroid profile test [14]. Nonetheless, our probanda presents similar phenotypic characteristics including intellectual disability and marfanoid habitus like a man with AHDS described by Chevarin et al. [2019] [15].

Our patient has a normal karyotype, which excludes possible balanced X-autosome translocation linked to skewed X inactivation.

The XCI ratio of 71%:29% in the probanda was considered undetermined [16] but leans towards a mildly skewed inactivation pattern of the maternal chromosome. The reduced percentage of active normal alleles, as the paternal chromosome, harboring the mutation, was active in approximately 71% of the cells, which also indicates altered X-inactivation as a possible mechanism for the expression of the phenotype in females.

Skewed X-chromosome inactivation can be seen in the general population [17], with levels of skewing increasing with age [18], as it may have been the case for the probanda's mother. However, it is also a common feature in symptomatic carriers of X-linked mutations, favoring the expression of the mutated allele [19,20], which is the case of the probanda.

The female patient with AHDS previously described by Frints et al. [2008] [5] presented a balanced translocation, 46,X,t(X;9)(q13.2;p24), with disruption of the *SLC16A2* gene at the breakpoint. Due to a preferential inactivation of the normal chromosome, as expected for these cases, there was no functional copy of the *SLC16A2* gene, resulting in the expression of the phenotype [5]. Another symptomatic female reported by Quesada-Espinosa et al. (2021) [10] presented a de novo 543 kb deletion of the X chromosome including exon 1 of the *SLC16A2* gene as well as the *JPX* and *FTX* genes. The deleted X chromosome was found to be the active one in 95% of the blood cells, which was attributed to the participation of the *JPX* and *FTX* genes in the X-chromosome inactivation.

In both patients, a markedly skewed inactivation associated with cytogenetic alterations was identified, unlike the probanda described here. This suggests that there are different mechanisms underlying skewness to express the phenotype in conditions with an X-linked pattern of inheritance, even though females may not present all the most frequent characteristics of the syndrome, like our patient.

The mechanisms underlying this skewed choice towards inactivating the chromosome harboring the normal allele have not been elucidated yet. It has recently been described that additional deleterious mutations on the other X-chromosome may favor the negative selection of cells in which it is expressed, generating skewed XCI and contributing to the expression of a given phenotype [19]. However, such a mechanism was not identified in the probanda. Even though we did not identify an extremely skewed XCI pattern towards the normal allele for the patient in peripheral blood, we may not rule out a more skewed XCI pattern in other tissues, which could impact the expression of her phenotype.

Thus, different mechanisms may be responsible for the expression of the AHDS phenotype in female patients, all of them associated with pathogenic variants in the *SLC16A2* gene as well as skewed X-chromosome inactivation, which can cause milder symptoms compared to male patients.

Statement of ethics

This study protocol was reviewed and approved by the Ethics Committee of the Universidade Federal de São Paulo, approval number CAAE 40846114.2.0000.5505. Written informed consent was obtained from the patient's parents for publication of this case report and any accompanying images in compliance with the Ethics Committee of the same Institution.

Funding sources

This work was supported by São Paulo Research Foundation (FAPESP), Brazil (grant to M.I.M. #2019/21644-0) and Coordenação de Aperfeiçoamento de Pessoal de Nível Superior (CAPES).

Declaration of Competing Interest

The authors declare no conflict of interest.

References

- [1] S. Groeneweg, et al., Disease characteristics of MCT8 deficiency: an international, retrospective, multicentre cohort study, *Lancet Diabetes Endocrinol.* vol. 8 (7) (2020) 594–605, 07, [https://doi.org/10.1016/S2213-8587\(20\)30153-4](https://doi.org/10.1016/S2213-8587(20)30153-4).
- [2] C.E. Schwartz, R.E. Stevenson, The MCT8 thyroid hormone transporter and Allan-Herndon-Dudley syndrome, *Best Pract. Res. Clin. Endocrinol. Metab.* 21 (2) (Jun 2007) 307–321, <https://doi.org/10.1016/j.beem.2007.03.009>.
- [3] M.A. Felmlee, R.S. Jones, V. Rodriguez-Cruz, K.E. Follman, M.E. Morris, Monocarboxylate transporters (SLC16): function, regulation, and role in health and disease, *Pharmacol. Rev.* vol. 72 (2) (2020) 466–485, 04, <https://doi.org/10.1124/pr.119.018762>.
- [4] A. Ceballos, et al., Importance of monocarboxylate transporter 8 for the blood-brain barrier-dependent availability of 3,5,3'-triiodo-L-thyronine, *Endocrinology* 150 (5) (May 2009) 2491–2496, <https://doi.org/10.1210/en.2008-1616>.
- [5] S.G. Frints, et al., MCT8 mutation analysis and identification of the first female with Allan-Herndon-Dudley syndrome due to loss of MCT8 expression, *Eur. J. Hum. Genet.* 16 (9) (Sep 2008) 1029–1037, <https://doi.org/10.1038/ejhg.2008.66>.
- [6] G. Remerand, et al., Expanding the phenotypic spectrum of Allan-Herndon-Dudley syndrome in patients with *SLC16A2* mutations, *Dev. Med. Child Neurol.* vol. 61 (12) (2019) 1439–1447, 12, <https://doi.org/10.1111/dmcn.14332>.
- [7] A.M. Dumitrescu, X.H. Liao, T.B. Best, K. Brockmann, S. Refetoff, A novel syndrome combining thyroid and neurological abnormalities is associated with mutations in a monocarboxylate transporter gene, *Am. J. Hum. Genet.* 74 (1) (Jan 2004) 168–175, <https://doi.org/10.1086/380999>.
- [8] V. Herzovich, et al., Unexpected peripheral markers of thyroid function in a patient with a novel mutation of the MCT8 thyroid hormone transporter gene, *Horm. Res.* 67 (1) (2007) 1–6, <https://doi.org/10.1159/000095805>.
- [9] C.E. Schwartz, et al., Allan-Herndon-Dudley syndrome and the monocarboxylate transporter 8 (MCT8) gene, *Am. J. Hum. Genet.* 77 (1) (Jul 2005) 41–53, <https://doi.org/10.1086/431313>.
- [10] J.F. Quesada-Espinosa, et al., First female with Allan-Herndon-Dudley syndrome and partial deletion of X-inactivation center, *Neurogenetics* vol. 22 (4) (2021) 343–346, 10, <https://doi.org/10.1007/s10048-021-00660-7>.
- [11] S. Kersseboom et al., "Mutations in MCT8 in patients with Allan-Herndon-Dudley syndrome affecting its cellular distribution," *Mol. Endocrinol.*, vol. 27, 5, pp. 801–813, doi: <https://doi.org/10.1210/me.2012-1356>.
- [13] B.P. Favilla, et al., Spread of X-chromosome inactivation into autosomal regions in patients with unbalanced X-autosome translocations and its phenotypic effects,

- Am. J. Med. Genet. A vol. 185 (8) (2021) 2295–2305, 08, <https://doi.org/10.1002/ajmg.a.62228>.
- [14] A. Papadimitriou, et al., A novel monocarboxylate transporter 8 gene mutation as a cause of severe neonatal hypotonia and developmental delay, *Pediatrics* 121 (1) (Jan 2008) e199–e202, <https://doi.org/10.1542/peds.2007-1247>.
- [15] M. Chevarin, et al., Excess of de novo variants in genes involved in chromatin remodelling in patients with marfanoid habitus and intellectual disability, *J. Med. Genet.* vol. 57 (7) (2020) 466–474, 07, <https://doi.org/10.1136/jmedgenet-2019-106425>.
- [16] V. Bolduc, et al., No evidence that skewing of X chromosome inactivation patterns is transmitted to offspring in humans, *J. Clin. Invest.* 118 (1) (Jan 2008) 333–341, <https://doi.org/10.1172/JCI33166>.
- [17] E. Shvetsova, et al., Skewed X-inactivation is common in the general female population, *Eur. J. Hum. Genet.* vol. 27 (3) (2019) 455–465, 03, <https://doi.org/10.1038/s41431-018-0291-3>.
- [18] J. Mengel-From, et al., Skewness of X-chromosome inactivation increases with age and varies across birth cohorts in elderly Danish women, *Sci. Rep.* vol. 11 (1) (2021) 4326, 02 22, <https://doi.org/10.1038/s41598-021-83702-2>.
- [19] R. Dardik, et al., Molecular Mechanisms of Skewed X-Chromosome Inactivation in Female Hemophilia Patients-Lessons from Wide Genome Analyses, *Int. J. Mol. Sci.* vol. 22 (16) (Aug 23 2021), <https://doi.org/10.3390/ijms22169074>.
- [20] E. Viggiano, E. Picillo, M. Ergoli, A. Cirillo, S. Del Gaudio, L. Politano, Skewed X-chromosome inactivation plays a crucial role in the onset of symptoms in carriers of Becker muscular dystrophy, *J. Gene Med.* vol. 19 (4) (Apr 2017), <https://doi.org/10.1002/jgm.2952>.