



Contents lists available at ScienceDirect

Hearing Research

journal homepage: www.elsevier.com/locate/heares

Methodological paper

Effects of systemic versus local gentamicin on the inner ear in the Atlantic cod, *Gadus morhua* (L.), relevance for fish hearing investigationsK. Faucher^{a,*}, Ø. Aas-Hansen^b, B. Damsgård^b, N.C. Stenklev^a^aENT Department, Institute of Clinical Medicine, University of Tromsø, Tromsø, Norway^bNorwegian Institute of Fisheries and Aquaculture Research, N-9291, Tromsø, Norway

ARTICLE INFO

Article history:

Received 20 December 2007

Received in revised form 28 March 2008

Accepted 31 March 2008

Available online xxx

Keywords:

Inner ear

Hair cells

Atlantic cod *Gadus morhua* (L.)

Gentamicin

Intrasaccular injection

Intravenous injection

ABSTRACT

Fish models are increasingly being used for hearing research investigations. Aminoglycoside antibiotics that are used for damaging the inner ear hair cells can have systemic side effects leading to death of study animals. This study aimed to compare two methods: (i) systemic (intravenous) and (ii) local (intrasaccular) gentamicin administration for induction of inner ear hair cell damage in the Atlantic cod, *Gadus morhua* (L.). Hair cell damage was assessed using scanning electron microscopy; hair cell density, prevalence of immature hair cells and kinocilia length were measured. Gentamicin-treated fish were compared with control and sham fish. Intravenous gentamicin led to dose-dependent mortality caused by nephrotoxicity. The only visible effect after treatment was more immature hair cells and shorter kinocilia, the effect on hair cell density was equivocal. Following intrasaccular gentamicin treatment, fish mortality was negligible, and hair cells were damaged regardless of dose. Here, we observed decreased hair cell density, high prevalence of immature hair cells, and significantly shortened kinocilia. Conclusion: intrasaccular injection is preferable to intravenous injection of gentamicin for the study of ototoxicity in the Atlantic cod.

© 2008 Elsevier B.V. All rights reserved.

1. Introduction

In contrast to mammals, many fish species have the ability to regenerate their inner ear and lateral line hair cells after damage (Kaus, 1987; Lombarte et al., 1993; Song et al., 1995; Scholik and Yan, 2001; Faucher et al., 2006; Smith et al., 2006). Given their capacity for regeneration, fish inner ear hair cells are nowadays a suitable model for investigations on hair cell regeneration and hearing function in animals. In this scope, it has been common to use aminoglycoside antibiotics to damage fish inner ear hair cells and then observe the regenerative process (Matsuura et al., 1971; Lombarte et al., 1993). These antibiotics are known to displace calcium ions from their receptors, thereby blocking the cation channels that are located at the apices of hair cell stereocilia (Hudspeth, 1983; Kroese et al., 1989). Among aminoglycoside antibiotics, gentamicin effects are reversible at low concentrations (Wersäll and Flock, 1964).

Whereas lateral line system hair cells are damaged by gentamicin and streptomycin immersion, no effects have been noted on inner ear hair cells after fish immersion in those aminoglycosides

(Matsuura et al., 1971; Schönleber and Anken, 2004). In contrast, intramuscular injections of gentamicin have led to damage of inner ear hair cells in freshwater fish (Yan et al., 1991; Lombarte et al., 1993). This aminoglycoside antibiotic, however, selectively damaged sensory hair cells in the inner ear lagena and utriculus of the teleost species, oscar (*Astronotus ocellatus*). No apparent damage to saccular hair cells was observed, even after high-dose gentamicin intramuscular injection (Yan et al., 1991). An alternative route of administration is the injection of aminoglycosides directly into the fish sacculus. Matsuura et al. (1971) showed that aminoglycoside antibiotics (kanamycin and streptomycin) suppress sacculus potentials when administered intraluminally to the goldfish (*Carassius auratus*) sacculus, but not when administered extraluminally. Following intrasaccular aminoglycoside injections, no adverse health effects were reported. After intramuscular injections of gentamicin, health disorders were common in the fish: loss of appetite, erratic swimming behaviour associated with weight gain, bloating of the abdomen and swelling around the eyes, indicative of osmoregulatory problems (Yan et al., 1991; Lombarte et al., 1993). Gentamicin causes renal injury after peritoneal injection in the goldfish, *C. auratus* (Liu et al., 2002). Nephrotoxicity and ototoxicity following aminoglycoside antibiotic treatment are well known in mammals (Dulon et al., 1988; Forge and Schacht, 2000). In guinea pigs, whilst nephrotoxicity can be reversible, inner ear lesions are permanent (Dulon et al., 1988; Hiel et al., 1993).

Abbreviations: NaCl, sodium chloride; CO₂, carbon dioxide; χ^2 , chi-square; SEM, scanning electron microscopy

* Corresponding author. Tel.: +32 4 758 92876.

E-mail address: kfaucher@hotmail.fr (K. Faucher).

0378-5955/\$ - see front matter © 2008 Elsevier B.V. All rights reserved.
doi:10.1016/j.heares.2008.03.007

Please cite this article in press as: Faucher, K. et al., Effects of systemic versus local gentamicin on the inner ear in the Atlantic cod, ..., *Hearing Res.* (2008), doi:10.1016/j.heares.2008.03.007

After exposure to aminoglycosides, inner ear hair cells regenerate within a period of between few days and about 20 days post-intervention in the oscar fish, *A. ocellatus* (Lombarte et al., 1993).

For the study of inner ear hair cell regeneration in fish using ototoxic drugs, it is important to develop a protocol that minimizes adverse effects and mortality, but produces acute hair cell damage. The present study examined two different methods for the delivery of an ototoxic drug to the Atlantic cod (*Gadus morhua*): (i) intravenous and (ii) intrasaccular gentamicin injection and compared these methods with regard to adverse effects and efficacy of inner ear hair cell damage. The Atlantic cod was chosen for its acute hearing and sensitivity to sound pressure (Hawkins, 1972; Chapman and Hawkins, 1973). In addition, a number of electrophysiological (Enger and Andersen, 1967; Sand and Enger, 1973) and behavioural hearing studies, based on conditioning and food rewards (Chapman and Hawkins, 1973; Schuijf, 1975; Schuijf and Buwalda, 1975; Schuijf and Hawkins, 1983), have already been performed on this species. This animal model will be thus a suitable model for further investigations on fish hearing.

2. Material and methods

2.1. Animal origin and fish tagging

235 reared Atlantic cod (*G. morhua*, L.) weighing around 0.5 kg, were obtained from the Aquaculture Research Station in Tromsø, Norway. They were housed in a 13.5 m³ tank supplied by aerated and filtered seawater, at natural temperature (about 6.5 °C) and photoperiod. All fish were anaesthetized by immersion in sea water containing metacaine (55 mg l⁻¹) for 5 min and fitted with coloured floy tags (FLOY TAG Inc., USA) for identification before gentamicin injection. Given the health problems and mortality reported in the literature for intramuscular gentamicin injection (Yan et al., 1991; Lombarte et al., 1993), more fish were used for gentamicin intravenous injection ($n = 160$) than for intrasaccular injection ($n = 75$) experiments.

2.2. Intravenous injections

Immediately after tagging, a single intravenous injection of gentamicin (Gensumycin injection solution, Aventis Pharma) or saline solution (10 g l⁻¹ NaCl) was performed in the caudal vein of the fish. They were divided into eight groups with 20 fish in each group: control (no injection), sham (intravenous injection of saline solution), and six groups given intravenous injection of gentamicin at 5, 10, 20, 40, 60 and 80 mg kg⁻¹, respectively. The injection volume was of 1 ml kg⁻¹ for all groups. After injection, fish swimming behaviour was normal.

2.3. Intrasaccular injections

Immediately after tagging, gentamicin (Gensumycin injection solution, Aventis Pharma) or saline solution (10 g l⁻¹ NaCl) was injected into both inner ear sacculi of the fish. Prior to this experiment, endolymph had been removed from the inner ear sacculi of specimens of Atlantic cods of the same weight (~0.5 kg) in order to ascertain the volume of gentamicin solution to be injected. The average volume of endolymph in one sacculus was found equal to ~0.05 ml. Intraluminal administration of gentamicin was performed on fish immobilized in a polystyrene gutter. The sacculi were entered from a lateral access route, using a metal trephination device through the pterotic bone, at the level of one half-length of the supraoccipital crest (Fig. 1A). A thin needle ($\varnothing = 0.40$ mm) was inserted through this device, on both sides successively. Correct positioning of the needle inside inner ear sacculi was ascertained in every fish using X-ray imaging (Fig. 1B).

Fish were divided into five groups with 15 fish in each: control (no injection), sham (intrasaccular injection of 0.05 ml saline solution: 10 g l⁻¹ NaCl), and three groups with intrasaccular injection of 0.05 ml gentamicin at 10, 20, 40 mg ml⁻¹, respectively. After injection, fish swimming behaviour was normal.

Fish were monitored for abnormal swimming behaviour and mortality for 1 month following the intravenous and intrasaccular gentamicin injection.

2.4. Inner ear SEM observations

At 3 days after treatment, the necessary lapse of time to observe hair bundle damage (Faucher, unpublished pilot data), two fish from each group were deeply anaesthetized with metacaine (75 mg l⁻¹), then decapitated. The cranium was opened and both inner ears were filled with 4% glutaraldehyde (Merck, Germany) in sodium cacodylate buffer (0.4 M, pH 7.2). Whole heads were then immediately stored in this fixative solution in the refrigerator (~6 °C) for about 24 h. The sensory maculae of their inner ear sacculi were then carefully removed from the skull and fixed again in 4% glutaraldehyde (in sodium cacodylate buffer, 0.4 M, pH 7.2) for 24 h. They were post-fixed with 2% osmium tetroxide (Carl Roth, Germany), and then dehydrated in graded acetone. Sensory maculae were critical point-dried using liquid CO₂ (BALTEC CPD 030), mounted on brass supports and sputter coated with gold (Cressington Sputter Coat) for observation using scanning electron microscopy (SEM, JEOL JSM-5410LV operating at 20 kV).

2.5. Histopathology

To clarify the issue of study-related animal mortality, two fish which had received 60 mg kg⁻¹ and two fish which had received 80 mg kg⁻¹ of intravenous gentamicin injection were collected immediately after death. Samples of internal organs (liver, intestine and kidney) were examined by light microscope by an experienced fish pathologist (commercial fish histopathology analysis service, The Norwegian Veterinary Institute, Harstad, Norway) after fixation in 4% glutaraldehyde (in sodium cacodylate buffer, 0.4 M, pH 7.2). Samples were compared between gentamicin-treated, control and sham fish.

2.6. Data processing and statistical analyses

Fish survival after treatment was examined for each group using the Kaplan–Meier estimate of survival function. In order to determine whether gentamicin led to changes in sensory hair cells, the ultrastructural status of the inner ear maculae sacculi were qualitatively compared between groups. Micrographs of local population samples were taken using SEM at three different places in the area close to the wide indentation in the ventral margin of the macula sacculi (Fig. 1C). Micrographs at 1500× magnification were taken at each location to assess an area of 5000 μm². Counts of visible hair cell bundles (damaged or normal), as well as abnormal-looking hair cells characterized by smaller hair bundles in which the kinocilium is lacking and the stereocilia are shorter, were performed at these three locations to assess the hair cell population. Counts of visible hair cell bundles were converted to density in the form of hair cell number/μm². Counts of abnormal hair cells were converted into prevalence (%) relative to total number of visible hair cell bundles. Micrographs at 4000× magnification were taken at each location to measure kinocilium length (in μm) of hair cell bundles. Averages of densities and kinocilium measures were calculated for each group. Average densities of visible hair cell bundles and average kinocilium lengths were then compared between groups using the non-parametric Kruskal–Wallis and Mann–Whitney tests. Prevalence of abnormal hair cells were compared between groups using the

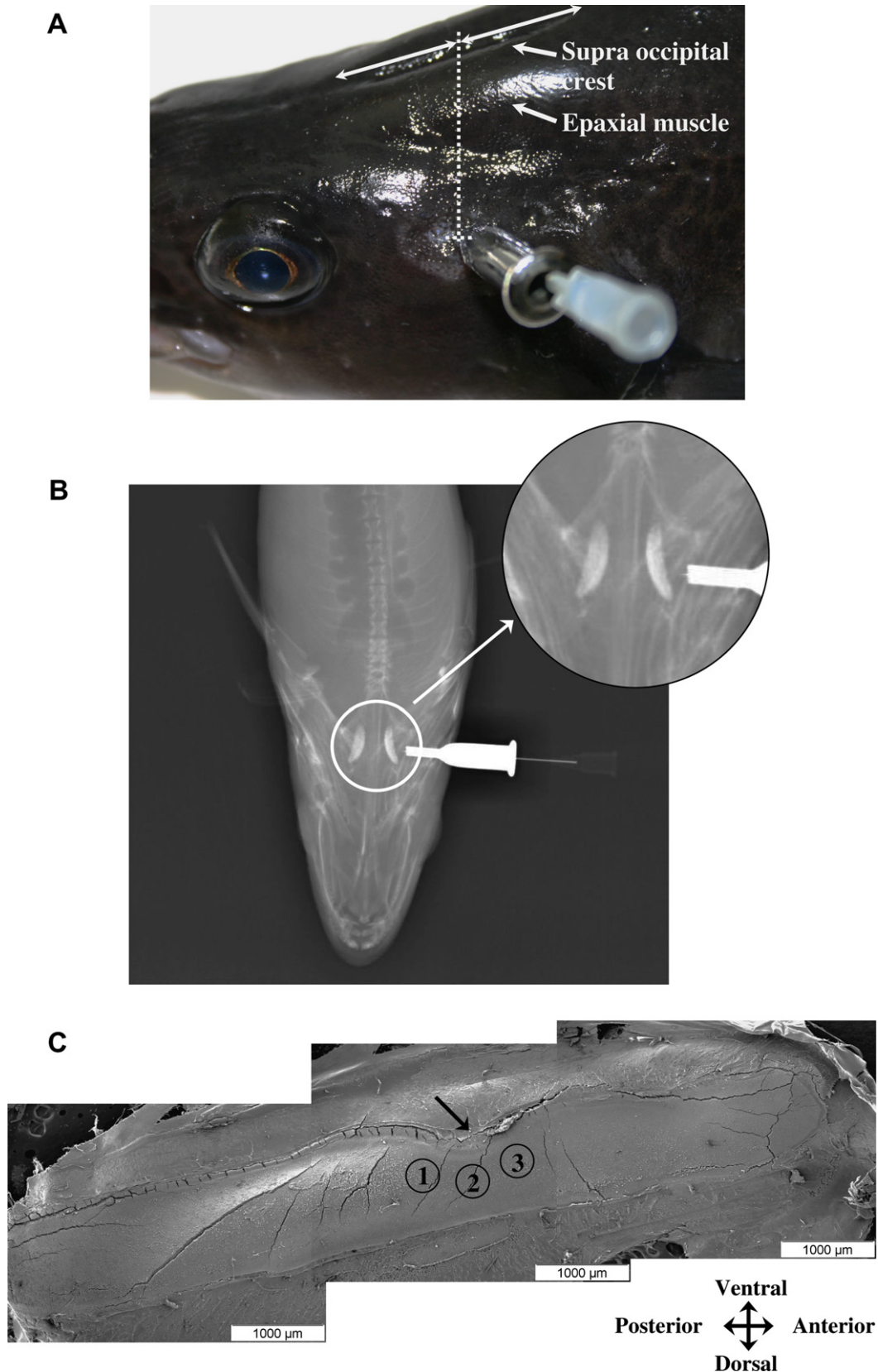


Fig. 1. (A) Illustration of Atlantic cod skull trephination for intrasaccular injection of gentamicin. Under anaesthesia, small holes were delicately made on both sides of the fish skull using a metal trephination device through the pterotic bone, at the level of one half-length of the supraoccipital crest. A volume of 0.05 ml of gentamicin was successively injected using a thin needle ($\varnothing = 0.40$ mm) inside both sacculi of Atlantic cod inner ear, (B) radiograph of Atlantic cod skull showing the location of the trephination for intrasaccular injection of gentamicin and (C) SEM micrographs of a whole sensory macula of the cod inner ear sacculus. Pictures at 1500 \times and 4000 \times magnifications were performed in three central areas (numbered) close to the wide indentation a little anterior to the middle of the ventral margin of the macula (black arrow).

chi-square (χ^2) test. All statistical tests were conducted with the XLstat-Pro 6.0 statistical analysis software (Addinsoft, France). The level of significance was set at $p < 0.05$.

This animal experiment has been approved by The Animal Care Committee of Norway (Aas-Hansen Ø., approval No. 07/29678-1).

3. Results

3.1. Fish survival

Fig. 2 shows the Kaplan–Meier estimate of the cumulative survival of fish after intravenous (Fig. 2A) and intrasaccular gentamicin injection (Fig. 2B). In the case of intravenous injection, no mortality was observed in control or sham fish. In contrast, around 1 week after intravenous gentamicin injection, fish presented erratic swimming behaviour and a bloated abdomen. From this moment, fish mortality was increased in this group. Dead or sick fish in many cases had haemorrhages from the anus. For the concern of fish welfare, fish with clear signs of such adverse effects were removed and killed with an overdose of anaesthetics (75 mg l^{-1} metacaine). The final cumulated survival probability was inversely proportional to the gentamicin dose that had been injected. Mortality was 100% after a time-lapse of between 19 and 23 days following injection with the highest doses (40, 60 and 80 mg kg^{-1}). At the end of the experimental period, only a few fish in the low-dose treatment groups (from 5 to 20 mg kg^{-1}) had survived the intravenous gentamicin injection (Fig. 2A).

After intrasaccular gentamicin injection, survival was high (Fig. 2B), with a mortality of four fish out of 60 at the end of the

experimental period (two from the sham group, one from the 20 mg ml^{-1} group, and one from the 40 mg ml^{-1} group). No abnormal swimming behaviour or other health problem was observed in any of these groups.

3.2. Histopathological analyses

Liver and intestine samples from intravenous-injected fish showed little evidence of tissue damage at light microscopic histological examination. The same applied to kidney samples from control fish. Glomeruli and other kidney tissues were intact in these fish (Fig. 3A). In kidney from gentamicin-treated fish, regardless of the dose, glomeruli were unaffected, while kidney tubuli presented a varying degree of degenerative or necrotic change when examined with light microscopy (Fig. 3B and C). Considerable amounts of cell debris in kidney tubule lumina, and circulatory disturbances in the kidney interstitial tissue were found, suggesting acute tubular necrosis.

3.3. Sensory hair cell damage

After intravenous (from 20 mg kg^{-1}) and intrasaccular gentamicin injection (all doses), damage to the sensory maculae of inner ear sacculi was observed (scanning electron microscope, SEM, Fig. 4). Damage in these groups was characterized by fusion of stereocilia, apical surfaces of hair cells without cilia or hair bundles with very short stereocilia and no kinocilium, and parts of the apical surfaces where hair bundles were lacking (see Fig. 4C and F).

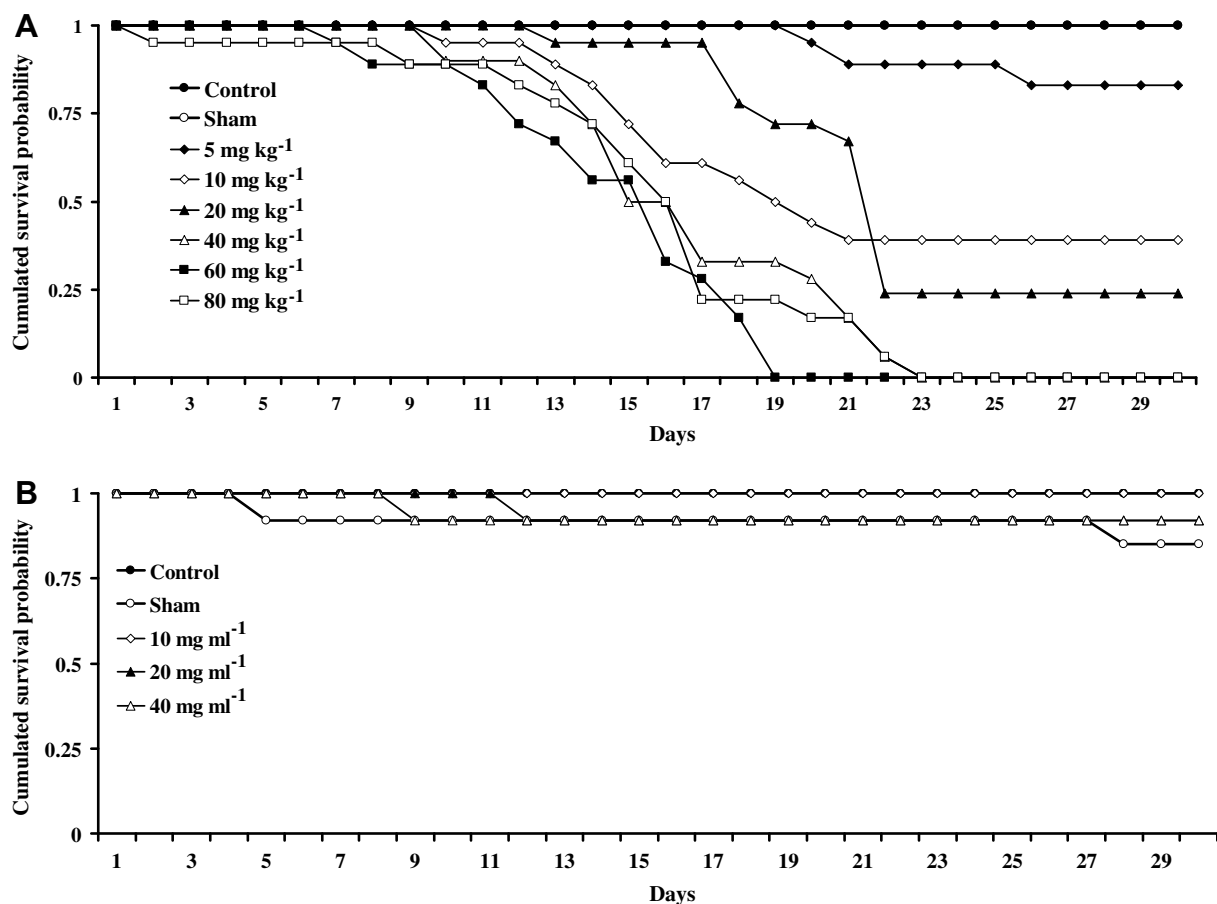


Fig. 2. Kaplan–Meier estimate of the survival of fish after intravenous (A) and intrasaccular injection (B) of gentamicin at different doses. (A) About 1 week after gentamicin intravenous injection, survival indices of fish started to decrease. Rate of survival was inversely proportional to the dose injected. Higher dose led to earlier death of fish. After around 20 days following injection with highest doses (from 40 to 80 mg kg^{-1}) all fish were dead. (B) After intrasaccular gentamicin injection, survival was excellent.

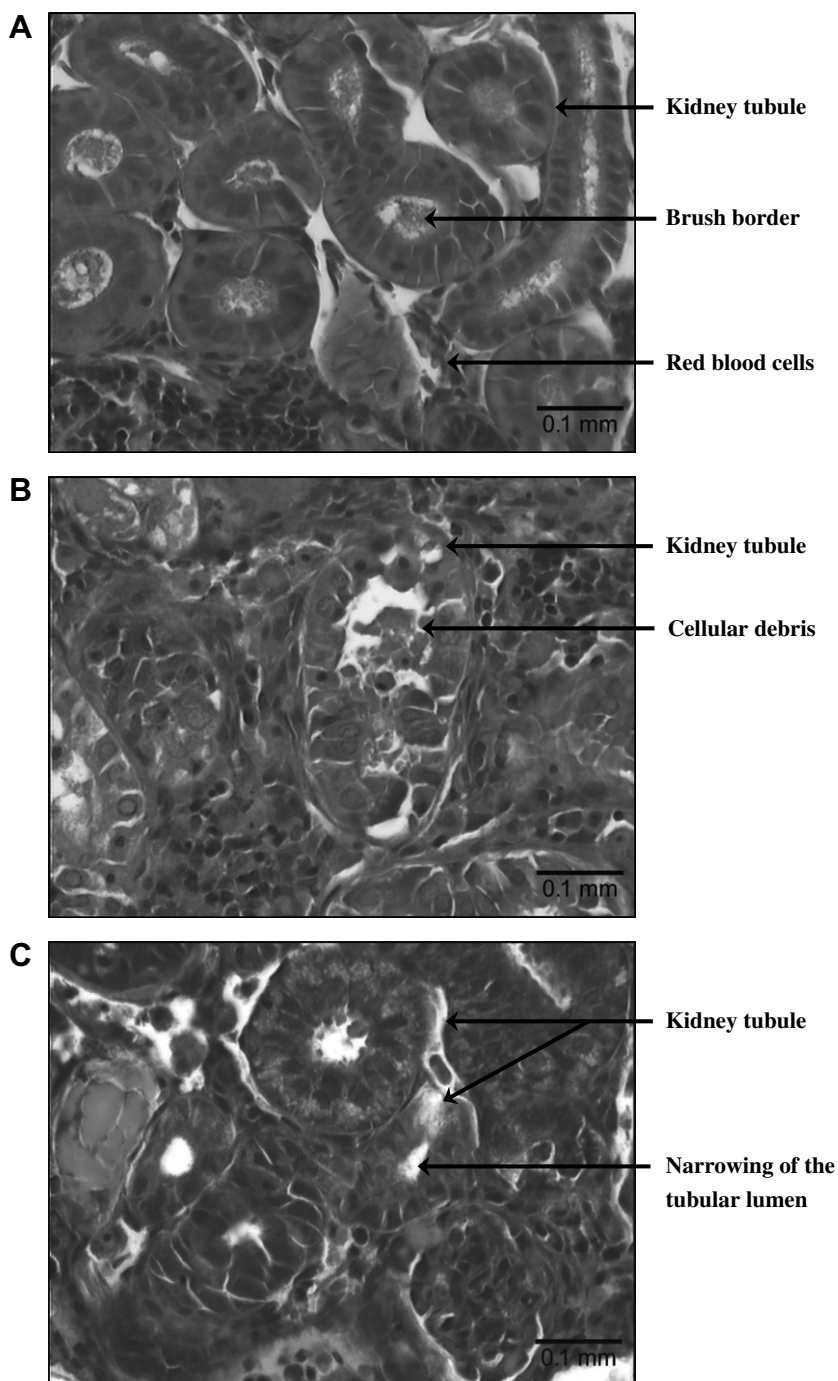


Fig. 3. Kidney ultrastructure observed in light microscope in a control Atlantic cod (A) and two Atlantic cods that had received 60 (B) and 80 mg kg⁻¹ (C) intravenous gentamicin injection. (A) In control fish, glomeruli and other kidney tissue were intact. (B) and (C) In treated fish, glomeruli seemed unaffected but kidney tubules presented a varying degree of degenerative or necrotic changes.

3.4. Intravenous gentamicin injection

In the group of intravenous gentamicin injection fish, control individuals presented an average hair cell density equal to 0.020 ± 0.003 hair cells μm^{-2} (Figs. 4A and 5A). A comparable average density was observed in sham fish (0.017 ± 0.003 hair cells μm^{-2} , $U = 103.0$, $p = 0.073$, $n = 24$ regions, $n = 4$ fish, Figs. 4B and 5A). No significant difference was evidenced between average hair cell density of control fish and fish which received 10 mg kg⁻¹ (0.020 ± 0.002 hair cells μm^{-2} , $n = 12$ regions, $n = 2$ fish), 40 mg kg⁻¹ (0.019 ± 0.002 hair cells μm^{-2} , $n = 12$ regions, $n = 2$ fish) and 60 mg kg⁻¹ gentamicin intravenously (0.018 ± 0.003 hair cells μm^{-2} ,

$n = 12$ regions, $n = 2$ fish, $H = 2.14$, $p = 0.543$, Fig. 5A). In contrast, compared to control fish, average hair cell densities were lower in fish which received 5 mg kg⁻¹ (0.007 ± 0.006 hair cells μm^{-2} , $U = 135.0$, $p = 0.000$, $n = 24$ regions, $n = 4$ fish), 20 mg kg⁻¹ (0.013 ± 0.006 hair cells μm^{-2} , $U = 118.0$, $p = 0.004$, $n = 24$ regions, $n = 4$ fish) and 80 mg kg⁻¹ (0.008 ± 0.006 hair cells μm^{-2} , $U = 133.0$, $p = 0.000$, $n = 24$ regions, $n = 4$ fish, Figs. 4C and 5A).

In all fish that were observed, abnormal hair cells showing no kinocilium and shorter stereocilia were seen (Fig. 4A and C). However, prevalence of abnormal hair cells were not significantly different between control (0.17%, $n = 12$ regions, $n = 2$ fish) and sham fish (0.61%, $n = 12$ regions, $n = 2$ fish, $\chi^2 = 2.84$, $p = 0.092$,




Fig. 4. Sensory maculae of inner ear sacculi from Atlantic cod observed using scanning electron microscopy after intravenous (A–C) and intrasaccular (D–F) injection. (A) control fish: intact inner ear, (B) sham fish: no damage observed, (C) Atlantic cod after the highest gentamicin dose that was injected (80 mg kg^{-1}): stereocilia seemed fused, some areas had very short hair cells and others were totally deprived of them, (D) control fish: intact sensory hair cells, (E) sham Atlantic cod: no apparent damage and (F) Atlantic cod after the highest gentamicin dose that was injected (40 mg ml^{-1}): stereocilia seemed fused and cilia were significantly shorter. Arrowheads show abnormal hair cells.

Fig. 5A). In contrast, the prevalence of abnormal hair cells was significantly higher than in control fish for all groups of gentamicin-

treated fish: 5 mg kg^{-1} (6.02% , $n = 12$ regions, $n = 2$ fish, $\chi^2 = 66.10$, $p < 0.0001$), 10 mg kg^{-1} (1.67% , $n = 12$ regions, $n = 2$ fish,

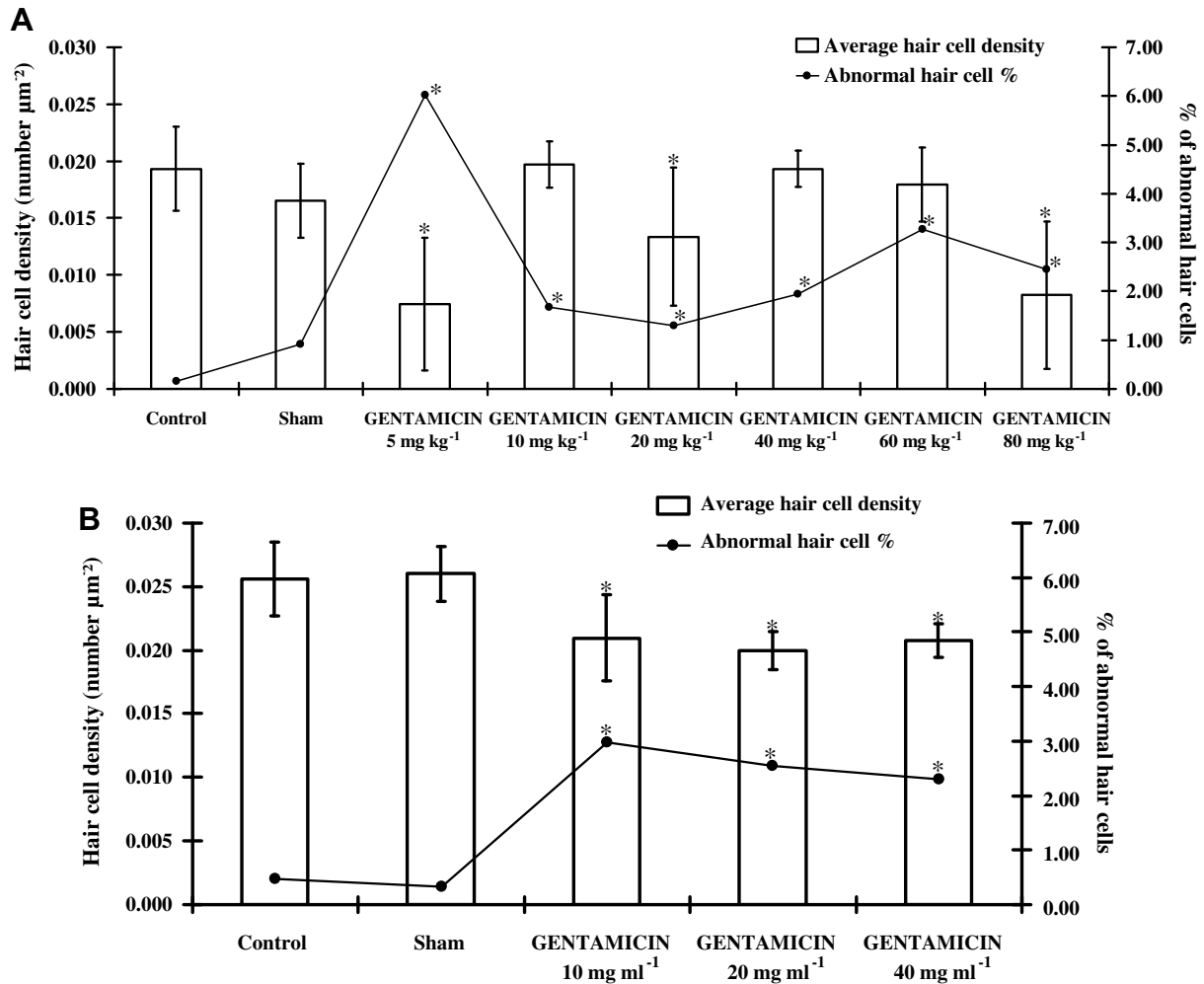


Fig. 5. Average hair cell density (number μm^{-2}) and prevalence of abnormal hair cells after intravenous (A) and intrasaccular (B) injection of gentamicin at different doses. (A) There was no significant relationship between the doses of gentamicin injected intravenously and the average hair cell density. Only the prevalence of abnormal hair cells tended to increase. (B) Intrasaccular gentamicin injection led to significant decrease of average hair cell density, associated with a greater prevalence of abnormal hair cells in comparison with control and sham fish. Vertical bars represent standard deviation of mean. Asterisks show data that were significantly different from control group.

$\chi^2 = 15.20$, $p < 0.0001$), 20 mg kg⁻¹ (1.29%, $n = 12$ regions, $n = 2$ fish, $\chi^2 = 10.19$, $p = 0.001$), 40 mg kg⁻¹ (1.94%, $n = 12$ regions, $n = 2$ fish, $\chi^2 = 18.40$, $p < 0.0001$), 60 mg kg⁻¹ (3.26%, $n = 12$ regions, $n = 2$ fish, $\chi^2 = 34.53$, $p < 0.0001$) and 80 mg kg⁻¹ (2.45%, $n = 12$ regions, $n = 2$ fish, $\chi^2 = 22.60$, $p < 0.0001$), than in control fish.

When possible, kinocilium length was measured (Fig. 6A). In control fish, the average length was equal to $5.15 \pm 1.25 \mu\text{m}$ ($n = 152$ kinocilia, $n = 2$ fish). Shorter kinocilia were observed in all other fish groups: sham ($4.58 \pm 2.52 \mu\text{m}$, $n = 118$ kinocilia, $n = 2$ fish, $U = 11501.5$, $p < 0.0001$), 5 mg kg⁻¹ ($2.12 \pm 0.95 \mu\text{m}$, $n = 96$ kinocilia, $n = 2$ fish, $U = 14231.5$, $p < 0.0001$), 10 mg kg⁻¹ ($3.32 \pm 1.09 \mu\text{m}$, $n = 193$ kinocilia, $n = 2$ fish, $U = 25380.5$, $p < 0.0001$), 20 mg kg⁻¹ ($3.52 \pm 1.48 \mu\text{m}$, $n = 149$ kinocilia, $n = 2$ fish, $U = 18009.5$, $p < 0.0001$), 40 mg kg⁻¹ ($2.40 \pm 1.08 \mu\text{m}$, $n = 173$ kinocilia, $U = 24950.5$, $p < 0.0001$), 60 mg kg⁻¹ ($2.77 \pm 1.05 \mu\text{m}$, $n = 153$ kinocilia, $n = 2$ fish, $U = 21671.0$, $p < 0.0001$) and 80 mg kg⁻¹ ($3.75 \pm 1.56 \mu\text{m}$, $n = 85$ kinocilia, $n = 2$ fish, $U = 9646.5$, $p < 0.0001$).

3.5. Intrasaccular gentamicin injection

After intrasaccular inner ear injection of saline solution, the average density of hair cells in sham fish (0.026 ± 0.002 hair cells μm^{-2} , $n = 12$ regions, $n = 2$ fish) was not significantly different

from the average density observed in control fish (0.026 ± 0.003 hair cells μm^{-2} , $n = 12$ regions, $n = 2$ fish, $U = 66.0$, $p = 0.729$, Figs. 4D, 4E and 5B). These values being similar, data from sham and control fish were compiled for comparison with treated fish. Whatever the dose, gentamicin-injected fish had a similar hair cell density ($H = 1.78$, $p = 0.410$, $n = 36$ regions, $n = 6$ fish, Fig. 5B). Indeed, the average hair cell density was equal to 0.021 ± 0.003 hair cells μm^{-2} ($n = 12$ regions, $n = 2$ fish) after 10 mg ml⁻¹ gentamicin injection, 0.020 ± 0.002 hair cells μm^{-2} ($n = 12$ regions, $n = 2$ fish) after 20 mg ml⁻¹ gentamicin injection and 0.021 ± 0.001 hair cells μm^{-2} ($n = 12$ regions, $n = 2$ fish) after 40 mg ml⁻¹ gentamicin injection. However, the average hair cell density in control and sham fish (0.026 ± 0.003 hair cells μm^{-2} , $n = 24$ regions, $n = 4$ fish), was found to be significantly higher than in treated fish when all gentamicin-treated groups were considered together (0.021 ± 0.002 hair cells μm^{-2} , $n = 36$ regions, $n = 6$ fish, $U = 824.0$, $p < 0.0001$, Figs. 4F and 5B).

The results were similar for prevalence of abnormal hair cells (Fig. 4D and F). In control fish, the prevalence of abnormal hair cells (0.474%, $n = 12$ regions, $n = 2$ fish) was not significantly different from the prevalence in sham fish (0.334%, $n = 12$ regions, $n = 2$ fish, $\chi^2 = 0.37$, $p = 0.545$). All treated fish had a similar prevalence of abnormal hair cells ($\chi^2 = 1.16$, $p = 0.560$, $n = 36$ regions, $n = 6$ fish), equal to 2.981% ($n = 12$ regions, $n = 2$ fish) after 10 mg ml⁻¹ genta-

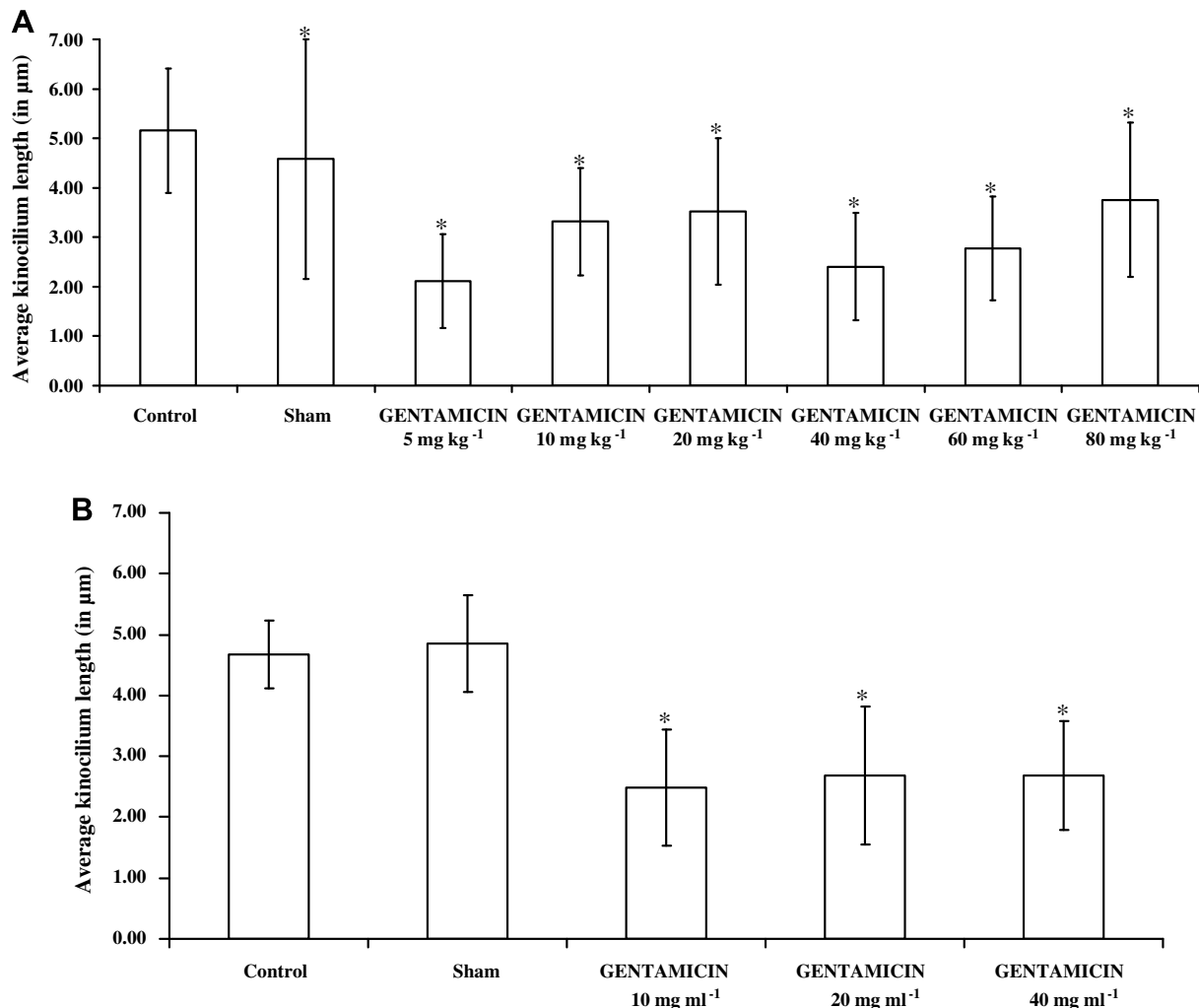


Fig. 6. Average kinocilia length in Atlantic cods after intravenous (A) and intrasaccular (B) injection of gentamicin at different doses. Both methods of gentamicin injection led to decrease of the average kinocilia length. Vertical bars represent standard deviation of mean. Asterisks show data that were significantly different from control group.

micin injection, 2.549% ($n = 12$ regions, $n = 2$ fish) after 20 mg ml⁻¹ gentamicin injection and 2.297% ($n = 12$ regions, $n = 2$ fish) after 40 mg ml⁻¹ gentamicin injection. The prevalence of abnormal hair cells was significantly higher in treated fish (2.612%, $n = 36$ regions, $n = 6$ fish), all doses considered together, compared to the pooled results for control and sham fish (0.403%, $n = 24$ regions, $n = 4$ fish, $\chi^2 = 50.14$, $p < 0.0001$).

When possible, length of kinocilia was measured (Fig. 6B). The average kinocilia length was similar between control ($4.68 \pm 0.56 \mu\text{m}$, $n = 130$ kinocilia, $n = 2$ fish) and sham fish ($4.85 \pm 0.80 \mu\text{m}$, $n = 90$ kinocilia, $n = 2$ fish, $U = 6687.5$, $p = 0.071$). In treated fish, the average kinocilia length was also similar between the three groups: $2.48 \pm 0.95 \mu\text{m}$ ($n = 142$ kinocilia, $n = 2$ fish) after 10 mg ml⁻¹ gentamicin intrasaccular injection, $2.68 \pm 1.14 \mu\text{m}$ ($n = 152$ kinocilia, $n = 2$ fish) after 20 mg ml⁻¹ gentamicin injection and $2.69 \pm 0.90 \mu\text{m}$ ($n = 137$ kinocilia, $n = 2$ fish) after 40 mg ml⁻¹ gentamicin injection ($H = 5.64$, $p = 0.06$). However, the average length of kinocilia was significantly lower in treated fish, all doses considered, than in control and sham fish when pooled together ($U = 89938.5$, $p < 0.0001$, Fig. 6B).

4. Discussion

We have established a model system to further investigate the ototoxic effects of gentamicin and hair cell regeneration. While this

study does not demonstrate directly if there is change at the level of the entire sensory hair cell, the damage we observed was restricted to the ciliary bundles alone. Nevertheless, this study shows that gentamicin led to hair cell bundle damage: fusion of stereocilia and areas without any hair bundles. This type of hair cell bundle alteration has previously been described in the fish and lizard inner ear (Presson and Popper, 1990; Yan et al., 1991; Lombarte et al., 1993; Avallone et al., 2008). The average hair cell density in the inner ear sacculi of the control fish (0.022 ± 0.005 hair cells μm^{-2}) was in concordance with the average of 0.025 hair cells μm^{-2} previously described by Dale (1976) in the same fish species. To evaluate hair bundle damage for each sample, kinocilia were assessed at three different areas, all of them located in the central part close to the wide indentation in the ventral margin of the macula sacculi. This was to avoid confounding with the well known difference in kinocilia length between the periphery and the centre of the inner ear macula sacculi in the Atlantic cod (Dale, 1976). This fact and the observation of greater inter-group than intra-group kinocilia length differences corroborated the data obtained here.

Although the fish that were treated with intravenous gentamicin were affected by acute renal tubular necrosis and subsequent mortality, the effect on inner ear hair cells was equivocal. Indeed, while hair cell density significantly decreased by 65%, 35% and 60% after intravenous gentamicin injection at 5, 20 and 80 mg ml⁻¹

respectively, no significant effect was observed using 10, 40 and 60 mg ml⁻¹. Hair bundle density measured following intravenous gentamicin injection was thus not dose-dependent. The only clearly visible alteration was the higher prevalence of abnormal hair cells (4.4 times higher), and the shorter cilia length (1.7 times shorter) in the treated fish compared to the sham and control individuals. In contrast, fish survival was high (93%) and significant hair cell damage was observed using the intrasaccular gentamicin administration method. Hair cell density decreased by 20%, the prevalence of abnormal hair bundles increased (6.5 times higher) and the length of kinocilia was nearly halved.

Toxic symptoms following intravenous gentamicin injection (bloating of the abdomen and erratic swimming behaviour) were abundant in our fish. Our observations correspond to the preliminary results evoked in the study of Lombarte et al. (1993) after intramuscular gentamicin injection in the oscar. In our study, histopathological analyses realized in fish which received high dose of intravenously-administrated gentamicin confirmed nephrotoxicity provoked by this aminoglycoside. Nephrotoxicity related to ototoxicity after aminoglycoside use is well-known in mammals (Dulon et al., 1988), including humans (Jackson and Ancieri; Gailunas et al., 1978). In the guinea pig, gentamicin treatment was associated with alterations to renal function in the first week of treatment, whereas ototoxicity was manifest in the third or the fourth week of treatment (Dulon et al., 1988). The time lag between nephrotoxic and ototoxic effects, and the absence of correlation between the degrees of damage between the two organs thus argued for dissociated phenomena. The fact that nephrotoxicity may occur before ototoxicity could explain why, in the present study, damage to hair cells was not really significant at the SEM level after intravenous gentamicin injections. Indeed, changes in hair cell density were not significant after 10, 40 and 60 mg kg⁻¹ gentamicin intravenous injections compared to control fish. However, a closer look at the sensory maculae of fish revealed a higher prevalence of abnormal hair cells in treated fish than in control ones. Those hair cells with smaller hair bundles in which the kinocilium is lacking and the stereocilia are shorter have been described in fish lateral system neuromasts (Rouse and Pickles, 1991). These hair cells could thus correspond to damaged hair bundles resulting from treatment, or to the emergence of immature hair cells, as suggested by Rouse and Pickles (1991). The general aspect of the hair bundles and the stereocilia seems effectively to point toward the second hypothesis. The high degree of hair cell turnover is well known both in fish lateral line neuromasts and in fish and lizard inner ear hair cells, in adults as well as in juveniles, and in healthy as well as in damaged tissue (Presson and Popper, 1990; Rouse and Pickles, 1991; Lombarte et al., 1993; Avallone et al., 2008). It would be reasonable to consider that hair cell turnover could be higher in damaged sensory maculae as part of a natural healing process.

Inconvenience of systemic administration: mortality caused by aminoglycoside-induced nephrotoxicity, associated with the high doses of antibiotics that are required to obtain sufficient hair cell damage, has already been observed in fish (Yan et al., 1991; Lombarte et al., 1993) as well as in the mouse (Nakagawa et al., 2003). In addition, previous studies demonstrated that in the oscar fish, intramuscular injection of gentamicin led to no apparent effect on saccular hair cells (Yan et al., 1991; Lombarte et al., 1993). In the present study, intrasaccular gentamicin administration effectively damaged saccular hair cells and had a low mortality rate. It is interesting to note that if hair cell density, prevalence of immature hair cells and kinocilia length showed alterations after intrasaccular treatment compared to control and sham fish, the damage observed was not dose-dependent. Thus, it would appear that maximal effect was already attained at the lowest dose of 10 mg ml⁻¹. However, this study does not demonstrate death of hair cells, just surface damage. It is conceivable that investigations

using transmission electronic microscopy might highlight deeper alterations at the cellular level. The apparent differences in hair cell density between control fish in the two different groups (Fig. 5A and B) probably represent biological variation throughout the experimental period.

In conclusion, intrasaccular administration of aminoglycosides should be the preferred delivery route for studies of ototoxic effects of drugs in fish. This method is more efficient in producing damage of inner ear hair cells and has a higher degree of organ specificity thus improving animal welfare through significant reduction in fish mortality.

Acknowledgements

We wish to thank Tor Evensen and Ronald Andersen, research technicians in the Norwegian Institute of Fisheries and Aquaculture Research and at the University of Tromsø, respectively, for their help during this experiment. We are grateful to Dr. Geir Bornø, veterinarian at the Norwegian Veterinary Institute (Veterinærinstituttet), Harstad, Norway for the histopathological analyses.

References

- Avallone, B., Fascio, U., Balsamo, G., Marmo, F., 2008. Gentamicin ototoxicity in the sacculus of the lizard *Podarcis Sicula* induces hair cell recovery and regeneration. *Hear. Res.* 235, 15–22.
- Chapman, C.J., Hawkins, A.D., 1973. A field study of hearing in the cod, *Gadus morhua* L. *J. Comp. Physiol. A* 85, 147–167.
- Dale, T., 1976. The labyrinthine mechanoreceptor organs of the cod *Gadus morhua* L. (Teleostei: Gadidae). A scanning electron microscopical study, with special reference to the morphological polarization of the macular sensory cells. *Norw. J. Zool.* 24, 85–128.
- Dulon, D., Arousseau, C., Erre, J.P., Aran, J.M., 1988. Relationship between the nephrotoxicity and ototoxicity induced by gentamicin in the guinea pig. *Acta Otolaryngol. (Stockh.)* 106, 219–225.
- Enger, P.S., Andersen, R., 1967. An electrophysiological field study of hearing in fish. *Comp. Biochem. Physiol.* 22, 517–525.
- Faucher, K., Fichet, D., Miramand, P., Lagardère, J.P., 2006. Impact of acute cadmium exposure on the trunk lateral line neuromasts and consequences on the “C-start” response behaviour of the sea bass (*Dicentrarchus labrax* L.; Teleostei, Moronidae). *Aquat. Toxicol.* 76, 278–294.
- Forge, A., Schacht, J., 2000. Aminoglycoside antibiotics. *Audiol. Neuro Otol.* 5, 3–22.
- Gailunas, P., Dominguez-Moreno, M., Lazrus, J.M., Lowrie, E.G., Gottlieb, M.N., Merrill, J.P., 1978. Vestibular toxicity of gentamicin: incidence in patients receiving long-term hemodialysis therapy. *Arch. Intern. Med.* 138, 1621–1624.
- Hawkins, A.D., 1972. The role played by the swimbladder in the hearing in fish. *J. Physiol.* 227, 47P.
- Hiel, H., Erre, J.P., Arousseau, C., Bouali, R., Dulon, D., Aran, J.M., 1993. Gentamicin uptake by cochlear hair cells precedes hearing impairment during chronic treatment. *Audiology* 32, 78–87.
- Hudspeth, A.J., 1983. Mechano-electrical transduction by hair cells in the acousticolateralis sensory system. *Ann. Rev. Neurosci.* 6, 187–215.
- Jackson, G.C., Ancieri, G., 1971. Ototoxicity of gentamicin in man: a survey and controlled analysis of clinical experience in the U.S. *J. Infect. Dis. Suppl.* 124, 130–137.
- Kaus, S., 1987. The effect of aminoglycoside antibiotics on the lateral line organ of *Aplocheilichthys lineatus* (Cyprinodontidae). *Acta Otolaryngol. (Stockh.)* 103, 291–298.
- Kroese, A.B.A., Das, A., Hudspeth, A.J., 1989. Blockage of the transduction channels of hair cells in the bullfrog's sacculus by aminoglycoside antibiotics. *Hear. Res.* 37, 203–217.
- Liu, M., Reimschuessel, R., Hassel, B.A., 2002. Molecular cloning of the fish interferon stimulated gene, 15 kDa (ISG15) orthologue: a ubiquitin-like gene induced by nephrotoxic damage. *Gene* 298, 129–139.
- Lombarte, A., Yan, H.Y., Popper, A.N., Chang, J.S., Platt, C., 1993. Damage and regeneration of hair cell ciliary bundles in a fish ear following treatment with gentamicin. *Hear. Res.* 64, 166–174.
- Matsuura, S., Ikeda, K., Furukawa, T., 1971. Effects of streptomycin, kanamycin, quinine, and other drugs on the microphonic potentials of goldfish sacculus. *Jap. J. Physiol.* 21, 579–590.
- Nakagawa, T., Kim, T.S., Murai, N., Endo, T., Iguchi, F., Tateya, I., Yamamoto, N., Naito, Y., Ito, J., 2003. A novel technique for inducing local inner ear damage. *Hear. Res.* 176, 122–127.
- Presson, J.C., Popper, A.N., 1990. Possible precursors to new hair cells, support cells, and Schwann cells in the ear of a post-embryonic fish. *Hear. Res.* 46, 9–21.
- Rouse, G.W., Pickles, J.O., 1991. Paired development of hair cells in neuromasts of the teleost lateral line. *Proc. R. Soc. Lond. B* 246, 123–128.

- Sand, O., Enger, P.S., 1973. Evidence for an auditory function of the swimbladder in the cod. *J. Exp. Biol.* 59, 405–414.
- Scholik, A.R., Yan, H.Y., 2001. Effects of underwater noise on auditory sensitivity of a cyprinid fish. *Hear. Res.* 152, 17–24.
- Schönleber, J., Anken, R.H., 2004. Efficacy of an ototoxic aminoglycoside (gentamicin) on the differentiation of the inner ear of cichlid fish. *Adv. Space Res.* 33, 1416–1420.
- Schuijf, A., 1975. Directional hearing of cod (*Gadus morhua*) under approximate free field conditions. *J. Comp. Physiol. A.* V98, 307–332.
- Schuijf, A., Buwalda, R.J.A., 1975. On the mechanism of directional hearing in cod (*Gadus morhua*L.). *J. Comp. Physiol. A.* V98, 333–343.
- Schuijf, A., Hawkins, A.D., 1983. Acoustic distance discrimination by the cod. *Nature* 302, 143–144.
- Smith, M.E., Coffin, A.B., Miller, D.L., Popper, A.N., 2006. Anatomical and functional recovery of the goldfish (*Carassius auratus*) ear following noise exposure. *J. Exp. Biol.* 209, 4193–4202.
- Song, J., Young Yan, H., Popper, A.N., 1995. Damage and recovery of hair cells in fish canal (but not superficial) neuromasts after gentamicin exposure. *Hear. Res.* 91, 63–71.
- Wersäll, J., Flock, Å., 1964. Suppression and restoration of the microphonic output from the lateral line organ after local application of streptomycin. *Life Sci.* 3, 1151–1155.
- Yan, H.Y., Saidel, W.M., Chang, J.S., Presson, J.C., Popper, A.N., 1991. Sensory hair cells of a fish ear: evidence of multiple types based on ototoxicity sensitivity. *Proc. R. Soc. Lond. B* 245, 133–138.