



## On the pathophysiology and treatment of akinetic mutism

Hisse Arnts<sup>a,\*</sup>, Willemijn S. van Erp<sup>b,c</sup>, Jan C.M. Lavrijsen<sup>b</sup>, Simon van Gaal<sup>d</sup>,  
Henk J. Groenewegen<sup>e</sup>, Pepijn van den Munckhof<sup>a</sup>

<sup>a</sup> Department of Neurosurgery, Amsterdam University Medical Centers, Location Academic Medical Center, Amsterdam, the Netherlands

<sup>b</sup> Department of Primary and Community Care, Center for Family Medicine, Geriatric Care and Public Health, Radboud University Medical Center, Nijmegen, the Netherlands

<sup>c</sup> Coma Science Group, GIGA Consciousness, Université de Liège, Liège, Belgium

<sup>d</sup> Department of Psychology, University of Amsterdam, Amsterdam, the Netherlands

<sup>e</sup> Department of Anatomy and Neurosciences, Neuroscience Campus Amsterdam, Amsterdam University Medical Centers, Location VU University Medical Center, Amsterdam, the Netherlands

### ARTICLE INFO

#### Keywords:

Akinetic mutism  
Frontal-subcortical neurocircuitry  
Behavior  
Disorders of diminished motivation

### ABSTRACT

Akinetic mutism (AM) is a rare neurological disorder characterized by the presence of an intact level of consciousness and sensorimotor capacity, but with a simultaneous decrease in goal-directed behavior and emotions. Patients are in a wakeful state of profound apathy, seemingly indifferent to pain, thirst, or hunger. It represents the far end within the spectrum of disorders of diminished motivation. In recent years, more has become known about the functional roles of neurocircuits and neurotransmitters associated with human motivational behavior. More specific, there is an increasing body of behavioral evidence that links specific damage of functional frontal-subcortical organization to the occurrence of distinct neurological deficits. In this review, we combine evidence from lesion studies and neurophysiological evidence in animals, imaging studies in humans, and clinical investigations in patients with AM to form an integrative theory of its pathophysiology. Moreover, the specific pharmacological interventions that have been used to treat AM and their rationales are reviewed, providing a comprehensive overview for use in clinical practice.

### 1. Introduction

Akinetic mutism (AM) is a rare neurological disorder of impaired initiation and motivation for behavior. Patients with AM maintain an intact level of consciousness, attention, language, and sensorimotor capacity, but present with a simultaneous decrease in goal-directed behavior, and emotion. (Miller and Cummings, 2018) Since its initial description in 1941, AM has been associated with structural damage to a considerable variety of functional brain areas. The disorder has been described in patients with cerebrovascular disease, with obstructive hydrocephalus, with tumors in the region of the third ventricle, and in patients suffering from other conditions affecting structural components of frontal-subcortical circuits. As a result of the wide variety of these lesions, AM has previously been described as a 'syndrome with little localizing value'. (Skultety, 1968) Moreover, the disease is

associated with a characteristic clinical heterogeneity that makes it difficult to diagnose. However, in recent years significant advances have been made in the understanding of the neuroanatomy, neurophysiology, and chemoarchitecture of neurocircuits that are involved in the initiation and motivation of behavior. In parallel with these developments, an increasingly broad spectrum of neurologic and neuropsychiatric phenomenology is being recognized as interpretable in the context of dysfunction of motivational circuitry. (Miller and Cummings, 2018) In addition, clear criteria for the assessment of patients with altered states of consciousness have been established, facilitating the distinction between conative disorders and, for example, the minimally conscious state. (Aspen Workgroup, 1995) These advances provide the opportunity to formulate an integrative theory of the development of AM in the context of dysfunction of specific frontal-subcortical neurocircuits. In this review, we combine evidence from

**Abbreviations:** ACC, anterior cingulate cortex; AM, akinetic mutism; CO, carbon monoxide; DA, dopamine; DS, dorsal striatum; GABA, gamma-aminobutyric acid; GPe, globus pallidus externus; GPi, globus pallidus internus; PFC, prefrontal cortex; SMA, supplementary motor cortex; SNc, substantia nigra pars compacta; VP, ventral pallidum; VS, ventral striatum; VTA, ventral tegmental area

\* Corresponding author at: Department of Neurosurgery, Amsterdam University Medical Centers, location Academic Medical Center, Meibergdreef 9, 1105 AZ, Amsterdam, the Netherlands.

E-mail address: [h.arnts@amc.uva.nl](mailto:h.arnts@amc.uva.nl) (H. Arnts).

<https://doi.org/10.1016/j.neubiorev.2020.02.006>

Received 28 February 2019; Received in revised form 3 January 2020; Accepted 5 February 2020

Available online 07 February 2020

0149-7634/ © 2020 The Authors. Published by Elsevier Ltd. This is an open access article under the CC BY license (<http://creativecommons.org/licenses/by/4.0/>).

recent animal and human studies in order to define the clinical consequences of frontal-subcortical disconnection and do an attempt to clarify the pathophysiology of AM. Subsequently, we review treatment strategies for patients with AM, and their rationale, with the aim to provide a comprehensive overview for use in clinical practice.

## 2. Definition of akinetic mutism

In search for the use of uniform nomenclature for disorders of altered consciousness, the American Congress of Rehabilitation Medicine (Aspen workgroup) has formulated specific neurobehavioral criteria for AM. In general, patients with AM show a lack of voluntary movement (akinesia) and absence of speech (mutism), though eye opening and spontaneous or environmentally induced visual tracking remain well maintained. Patients seem awake, but do not display affective reactions, do not initiate eating or drinking, and if speech occurs, it remains sparse. There is a great variety in associated neurological symptoms. (Giacino et al., 2014) While some patients show a minimal degree of command following and verbalization, others remain largely apathetic and akinetic. In the spectrum for disorders of diminished motivation, AM seems to represent an extreme form of abulia (absence of willpower). AM has been described in both children as adults of both sexes, and, in general, has no correlations with previous medical or psychiatric conditions. (Cairns et al., 1941) However, it may resemble other hyporesponsive conditions with a different underlying pathophysiology. The heterogeneity among patients with AM raises the possibility of misdiagnosing the condition with other diseases, such as psychiatric disorders, including catatonic schizophrenia, severe depression, conversion reaction, or other structural disorders, such as locked-in syndrome. (Fisher, 1989; Giacino, 1997; Nagaratnam et al., 2004; Shetty et al., 2009) As a result of this heterogeneity, the term AM has sometimes been used too extensively and improperly in the literature. (Kemper and Romanul, 1967; Nemeth et al., 1988) In general, patients with AM show variations of the same basic disorder: a state of diminished motor function, compromised speech, movement and facial expression, but with preservation of sensory functions and awareness. (Giacino et al., 2014)

While AM is associated with a failure to initiate spontaneous, voluntary responses, patients maintain the intrinsic capacity to move or speak. (Tibbetts, 2001) It might be a permanent condition after irreversible brain injury, though also be of temporary origin, if neurological recovery occurs, suggesting a considerable preservation of both speech and motor functions. The preservation of executive functions is also strikingly demonstrated in AM patients that experience a supposedly ‘telephone effect’, referring to unpredictable events, such as a ringing telephone or other verbal or environmental stimuli that cause a sudden restoration of speech and movement, possibly by a brain functioning on some sort of ‘automatic pilot’. (Fisher, 1983; Yarns and Quinn, 2013) These patients quickly lose these capacities when the stimulus ends. The severity of the akinesia and mutism usually impairs any relational exchange with others, and renders patients wheelchair-bound, and completely dependent of nursing care. Furthermore, the akinesia and mutism usually complicate daily care and prevent the deployment of any rehabilitation interventions. Although AM patients are conscious, they appear to lack the vector to express pain or any inner feelings, if present, to the outside world, which is often devastating for their families. Up until today, little is known about the emotional and psychological state of AM. Previously, one patient with AM responded to the question of why she did not talk during her illness with the answer ‘nothing ever came to mind’, suggesting a complete absence of thinking or reasoning. (Damasio, 1994) It goes without saying that it remains important that the diagnosis of AM should be made only after careful judgment of accompanying signs and in the whole context of the clinical presentation. (Tibbetts, 2001) For instance, it must be distinguished from anarthria and apraxia of speech, conditions wherein there is an inability to speak, but in which attempts to communicate by gesture or

facial expression are often successful. Accompanying cognitive impairments, that are often inherent to the underlying brain injury, are usually clinically assessed by a subset of cognitive screening tests, such as the Mini Mental State Examination (MMSE) and the Montreal Cognitive Assessment test (MOCA), though the value of these neurobehavioral assessment tools is often limited, because of the inability of patients to speak or move.

## 3. Pathophysiology of akinetic mutism

Distinct neurocircuits have been described that provide the neural basis of motivation. (Kalivas and Barnes, 2019) A wide variety of motivational deficits might develop after damage to frontal-subcortical structures that are involved in the translation of a motivational stimulus in a behavioral response. Along the way of the frontal-subcortical system, specific structures are found that are associated with the development of AM:

### 3.1. The role of the anterior cingulate cortex (ACC) and striatum

#### 3.1.1. The ACC

The frontal lobes act as integrator of information, processing both input from the external sensory world and internal limbic system. (Miller and Cummings, 2018) This function is reflected in the organization, physiology, and connections between areas of the frontal cortex and their afferent and efferent projections with the subcortical system. (Haber, 2016) The frontal cortex can be divided into several general functional regions: the orbital and medial prefrontal cortex (PFC), involved in emotions and motivation; the dorsolateral PFC, involved in higher cognitive processes or executive functions; the premotor areas, involved in different aspects of motor planning; and the motor cortex, involved in the execution of those plans. The development of symptoms of diminished motivation, lethargy, and a general loss of interest is closely related to lesions of different regions of the frontal cortex. However, there is converging evidence that the medial walls of the frontal lobes, particularly the anterior cingulate cortex (ACC), form a ‘usual suspect’ in the development of AM. (Darby et al., 2018; Devinsky et al., 1995; Tibbetts, 2001) The ACC has complex reciprocal connections with limbic structures and other parts of the frontal cortex and is thought to provide an interface between the decision-making process of the frontal lobe and the ‘emotional’ world of the limbic system. The ACC is responsible for learning and selecting high-level behavioral plans that provide the meaning behind and motivation for actions, and is thought to be essential in making a transition from early premotor processes to actual behavior. (Holroyd and Yeung, 2012) Moreover, it is thought to be crucial in the voluntary initiation of speech and vocalization through connections with brainstem periaqueductal grey that in turn connects with brainstem nuclei that innervate the muscles of articulation and phonation. (Jurgens, 2009; Medford and Critchley, 2010; Shenhav et al., 2013) Damage to the ACC is known to be a primary cause for akinesia and mutism and has frequently been described in case-reports of patients with bleeding, stroke, or other types of severe brain injury. (Choudhari, 2004; Nemeth et al., 1988) The most dramatic examples of akinesia and mutism follow bilateral lesions of the ACC, such as after bilateral damage to the vascular supply of the anterior cerebral artery territory. (Choudhari, 2004; Freemon, 1971; Nagaratnam et al., 2004; Nemeth et al., 1988) Unilateral ACC lesions have also been described as a cause of AM, though these usually only produce a transient phase of motivational dysfunction followed by gradual recovery. (Damasio and Anderson, 1993; Tibbetts, 2001) In a recent study, Darby et al., used a new lesion network mapping technique in MR-images of patients with AM and abulia and were able to show that patients with AM all experienced impairment of one specific network defined by connectivity to the ACC. (Darby et al., 2018) However, extensive damage to the ACC has also been reported without the occurrence of disorders of diminished motivation. For example,

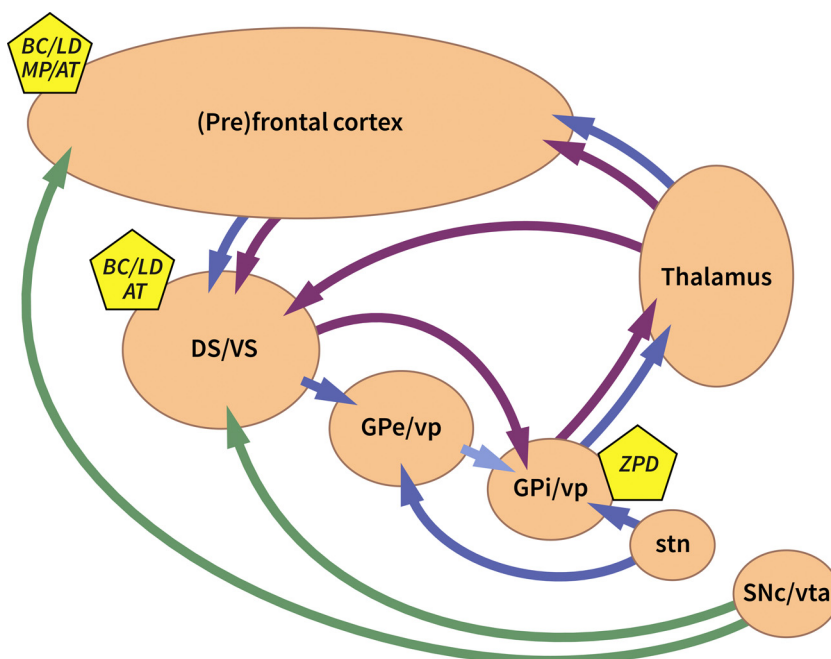
patients failed to develop AM after therapeutic bilateral anterior cingulotomies.(Ballantine et al., 1967; Livingston, 1953) Moreover, many patients with aneurysms of the anterior communication artery have undergone surgical ligation of both anterior cerebral arteries at the genu of the corpus callosum, which usually causes a stroke in the anterior cingulate gyrus, without suffering from AM.(Freemon, 1971; Meyers, 1951) Therefore, it remains uncertain whether ACC dysfunction alone is sufficient to result in a state of extreme sensory inattention and reduced behavioral output. It is known that the ACC is tightly linked with many other PFC areas, including most areas of the dorsal PFC, associated with cognitive control, and more posteriorly with motor control areas.(Haber, 2016) Most of the dramatic behavioral changes following ACC lesions are therefore thought to be associated with additional lesions, or impaired network functioning, in these adjacent areas of the frontal cortex.(Meador et al., 1986; Nemeth et al., 1988) Simultaneous impairment of both ACC and its connections with the supplementary motor area is known to produce more pronounced symptoms of akinesia and mutism, or even a qualitatively different state than those caused by ACC lesions alone.(Meador et al., 1986; Nemeth et al., 1988).

### 3.1.2. The striatum

Input from the frontal lobes terminates in the striatum (Fig. 1). The striatum comprises the caudate nucleus and putamen (dorsal striatum, DS) and nucleus accumbens (ventral striatum, VS). Connections from the frontal cortex are generally topographically organized in the striatum. Prefrontal areas project primarily to the VS, rostral caudate nucleus and putamen, while sensorimotor areas project more caudally, primarily to the putamen. While these distributions seem to form parallel and segregated cortico-basal ganglia circuits, there is extensive convergence of inputs from different functional regions in the brain.(Groenewegen et al., 2017; Haber, 2016) Overlap between the projections from the different (pre)frontal cortical areas with parietal, occipital, and temporal areas at the level of the striatum provides the anatomical substrate for interactions and integration of information between circuits that shape behavior. Of particular interest are the projections from the ACC to the ventromedial part of the striatum, including the shell region of the nucleus accumbens, which are particularly involved in ‘cognitive coloring’ of motivation.(Choi et al., 2017; Duffy, 2000; Heilbronner et al., 2016; Kalivas and Barnes, 2019) The

latter part can be considered as a transition zone between the striatum and limbic structures, like the bed nucleus of the stria terminalis.(Groenewegen et al., 2016; Haber and McFarland, 1999) Neurons in the nucleus accumbens shell not only project to ‘classical’ striatal targets like the pallidum and the substantia nigra, but also to preoptic and lateral hypothalamic areas and to mesencephalic areas beyond the substantia nigra.(Haber et al., 1990) In this way, the ACC not only has direct subcortical projections to the periaqueductal grey (see above), but may also indirectly, i.e., via the ventromedial striatum, influence subcortical structures like the lateral hypothalamus and the mesencephalic tegmentum.(Kalivas and Barnes, 2019)

Not surprisingly, the striatum has been implicated in several neurological disorders that are characterized by dysfunction of motivational processes, such as apathy, depression, and AM. For instance, symmetrical bilateral destruction of the striatum is known to produce a picture of cognitive deterioration with absence of voluntary movements.(Hawke and Donohue, 1951) Damage to the ventromedial striatum is known to produce anhedonia (loss of interest), as it is closely linked to reward valuation, decision-making, anticipation and motivation.(Der-Avakian and Markou, 2012; Kalivas and Barnes, 2019) However, disorders of diminished motivation are more frequently associated with damage to the DS, in particular the caudate nucleus, which is a key structure involved in planning of actions and executive functions.(Levy and Dubois, 2006; Monchi et al., 2006) In a review of patients with focal lesions of the basal ganglia, abulia occurred with 18 of 64 (28 %) small and large caudate lesions, 15 of which were unilateral.(Bhatia and Marsden, 1994) Moreover, unilateral or bilateral lesions of the dorsal portion of the head of the caudate nucleus are associated with a severe form of apathy: athymhormia.(Habib, 2004; Habib and Poncet, 1988) In both human and experimental animals, bilateral lesions, which include the head of the caudate nucleus, have also been associated with behavioral changes similar to AM.(Freemon, 1971; Mendez et al., 1989) In a more recent case-report, Jang et al. used diffusion tensor tractography in a patient with slowly progressive deterioration from abulia to AM after traumatic brain injury and showed remarkable damage to the prefrontal-caudate tract.(Jang et al., 2017) They hypothesized that degeneration of these circuits is responsible for the aggravation of abulia to AM with time. Paradoxically, other authors reported no evidence of disorders of diminished motivation after extensive bilateral damage to the caudate nucleus, so its role in the



**Fig. 1.** Schematic overview of frontal-subcortical circuitry associated with motivation and possible site(s) of action of pharmacological interventions in AM. Purple arrows represent the direct pathway, blue arrows represent the indirect pathway, and green arrows represent dopaminergic pathways. AT = Atomoxetine; BC = Bromocriptine; DS/VS = dorsal striatum/ventral striatum; GPe/vp = globus pallidus externus/ventral pallidum; GPi/vp = globus pallidus internus/ventral pallidum; LD = Levodopa; MP = Methylphenidate; SNc/vta = substantia nigra pars compacta/ventral tegmental area; stn = subthalamic nucleus; ZPD = Zolpidem.

development of AM remains uncertain.(Freeman, 1971; Meyers, 1942)

### 3.2. The role of mesolimbic and nigrostriatal dopaminergic pathways

The dopaminergic neurons, located in the ventral tegmental area (VTA) and substantia nigra pars compacta (SNc) in the midbrain play an important role in motivational neurocircuitry and modulate a broad range of behavioral and motor control processes.(Haber, 2014, 2016) Not surprisingly, damage to the dopaminergic neurons at their site of origin is a well-known cause of AM and the disease has frequently been reported after mesencephalic damage, such as in the case of stroke.(Alexander, 2001; Kim and You, 2017; Nemeth et al., 1986) From the midbrain, the VTA projects to the nucleus accumbens of the VS and prefrontal cortex via the mesocortical limbic system. The neurons of the SNc, in turn, project to the caudate and putamen of the DS through the nigrostriatal pathway.(Haber, 2014) Pharmacological and dopamine (DA) depletion studies demonstrate a critical role for mesolimbic DA in motivational behavior.(Salamone and Correa, 2012) While the role for nigrostriatal DA appears less dominant, both mesolimbic and nigrostriatal DA activity seems to be able to both gate input of sensory, motor, and incentive motivation-related signals to the striatum.(Horvitz, 2002) Therefore, both pathways are important ‘usual suspects’ in the development of AM. It is widely known that lesions of these pathways that convey DA from the midbrain to specific regions of the forebrain are associated with the occurrence of behavioral deficits.(Beaulieu and Gainetdinov, 2011) In the very first report of AM, Cairns et al., already associated the occurrence of AM to damage of fiber pathways alongside the third ventricle.(Cairns et al., 1941) In 1981, Ross and Stewart specified these pathways to be dopaminergic projections from midbrain to forebrain and described AM in a patient with disruption of these projections as result of a large hypothalamic tumor.(Ross and Stewart, 1981) Lesion studies in animals further confirm the critical role of mesolimbic and nigrostriatal DA pathways in behavior. For instance, bilateral or unilateral blocking injections in the substantia nigra, VTA, or nigro-striatal tract within the medial forebrain bundle have been shown to cause dramatic behavioral deficits.(Ungerstedt, 1970, 1971) Damage to any of these structures seem to result in a change in feeding, drinking, motor behavior, and in sensory and orienting functions in animals that seem equivalent to symptoms of AM in humans. These behavioral deficits could be reversed by administration of apomorphine, a direct dopamine agonist, and blocked by pre-treatment with spiroperidol, a dopamine receptor antagonist.(Ljungberg and Ungerstedt, 1976; Marshall and Gotthelf, 1979; Marshall and Ungerstedt, 1976) AM can also arise following indirect disruption of dopamine pathways, such as in hydrocephalus.(Messert et al., 1966; Rebai et al., 2012) Reduction of ventricular dilatation by ventricular drainage or lumbar puncture of cerebrospinal fluid is known to produce regression of symptoms, possibly by restoring the dopaminergic input from the midbrain projections.(Messert et al., 1966) This finding was further investigated in experimental hydrocephalus models in rabbits that showed reductions in DA release in different brain structures after ventricular dilatation, particularly in the striatum, SNc, and medial portion of the nigrostriatal pathway.(Kondziella et al., 2008; Tashiro et al., 1997)

### 3.3. The role of the basal-ganglia, thalamus, and their cortical projections

#### 3.3.1. The pallidal complex

The pallidal complex includes the internal (GPi) and external segments (GPe) of the globus pallidus and ventral pallidum (VP). The GPi and GPe receive inputs from both the caudate nucleus and putamen (DS). The VP is a mixture of GPi and GPe elements and receives its input from the VS.(Haber, 2016) The outputs from the GPi are to the thalamus, which then projects back to the cortex, forming part of the ‘direct’ cortico-basal ganglia circuit (Fig. 1). The GPe and parts of the VP project to the subthalamic nucleus (STN). The STN, in turn, provides

inputs to the GPi. This pathway is considered the ‘indirect’ pathway. The STN also receives direct projections from different parts of the frontal cortex, which are referred to as the hyperdirect pathway. As a result of the high convergence from the striatum to the GPi, one GPi neuron receives input from many striatal projection neurons. There is considerable, converging evidence to consider the (ventral) striato-pallidum as an interface between motivation and action, or as the site of conversion of motivational processes into behavioral output.(Habib, 2004) Not surprisingly, pallidal damage has been associated with the occurrence of a wide variety of motivational disorders, such as AM.(Habib, 2004) In 1989, Laplane et al., already described a lack of initiative, mental slowing, and obsessive-compulsive behavior in a number of cases that had sustained bilateral GP lesions and showed signs of frontal hypometabolism on PET-CT’s.(Laplane et al., 1989) Further imaging studies showed that bilateral lesions of the GP were associated with reduced blood flow in multiple frontal cortical regions, most prominently in the anterior parts of the frontal cortex, anterior cingulate and supplementary motor cortex.(Haaxma et al., 1993) A remarkable number of AM patients have been described after considerable, both unilateral and bilateral anatomical destruction of the GP.(Strub, 1989; Ure et al., 1998) Noticeably, a significant proportion of these reports have been related to GP damage after carbon monoxide (CO) poisoning.(Cravioto et al., 1960; Mackintosh, 1965; Tengvar et al., 2004; Ure et al., 1998) These patients usually develop the disease after a lucid interval from days to weeks, but typically within approximately one month. Neuroimaging findings in these patients have shown that CO intoxication is characterized by necrosis, particularly at the level of the GP, possibly by the hypotensive effects of CO intoxication in the watershed territory of the arterial supply of the GP, or as a result of CO binding to its intrinsic high iron concentration.(Lo et al., 2007) While the caudate nucleus, putamen, and thalamus are occasionally affected in CO poisoning, they are involved to a much lesser extent than the GP. Specific neuroimaging studies have repeatedly demonstrated significant hypoperfusion in frontal regions and anterior cingulate cortices in patients with CO poisoning and GPi lesions. However, while the GP seems to play a distinctive role in behavioral mechanisms, bilateral pallidotomies performed for the treatment of movement disorders did not produce AM.(De Bie et al., 2002) The complex role of the different (sub) portions of the GP in motivation for behavior remains subject of ongoing research in animals and humans.(Saga et al., 2017)

#### 3.3.2. The thalamus

The thalamus is a critical component of frontal-subcortical circuitry. Each functional region of the frontal cortex is innervated by specific areas of the thalamus. Due to its central position in the frontal-subcortical system, the thalamus has an important role in the synchronization of motivation and behavior, because it integrates information between different functional regions.(Haber and Calzavara, 2009) Afferent projections from the frontal regions project through the basal ganglia to distinctive regions of the ventral anterior (VA), midline/intralaminar and mediodorsal thalamus, which are known to be involved in goal-directed behavior.(Tekin and Cummings, 2002) Different parts of the thalamus then project back to different regions of the cortex and basal ganglia. For instance, the intralaminar nuclei, including the centromedian, parafascicular nuclei, central medial, paracentral, and central lateral nuclei project to the orbitofrontal and mediofrontal cortex, motor and premotor cortex, and GPi, while the mediodorsal nucleus projects to the prefrontal cortex and VP.(Van der Werf et al., 2002) In addition, the thalamus sends a massive, topographically organized projection directly back to the striatum. A variety of behavioral changes and deficits, such as apathy, disinhibition syndromes, and personality changes have been described after damage to specific regions of the thalamus. AM has particularly been described after paramedian territory infarction.(Castaigne et al., 1981; Segarra, 1970; van Domburg et al., 1996) Infarcts in the paramedian territory mainly involve the mediodorsal and intralaminar nuclei.(Carrera and Bogousslavsky,

2006) The classic features of acute paramedian infarcts include a decreased level of consciousness, vertical gaze paresis, and cognitive impairment. However, akinesia, mutism, and reduced spontaneous activity become apparent when the decreased level of consciousness resolves. Moreover, other behavioral deficits may develop after thalamic stroke, such as personality changes with disinhibited behavior, apathy, loss of self-activation, and amnesia, depending on slight anatomical variations in thalamic vascular supply and nuclei involved. (Bogousslavsky et al., 1991; Engelborghs et al., 2000; Habib, 2004) Though descriptions of disorders of diminished motivation after damage to the anterior territory of the thalamus seems to be rare, it is known that anterior involvement is also associated with a variety of behavioral changes. (Carrera and Bogousslavsky, 2006) In studies on cats and monkeys, bilateral lesions of the anterior nucleus of the thalamus have produced symptoms similar of an akinetic state. (Freemon, 1971; Meyer and Hunter, 1952) Moreover, Carota et al. described a patient with AM after bilateral thalamo-polar artery stroke and damage to the anterior nuclei of the thalamus. (Carota et al., 2014) While these observations suggests that different thalamic nuclei are fundamental relays associated with motivation and purposeful behavior, bilateral lesions in both dorsomedial and anterior thalamic nuclei inflicted for the treatment of psychiatric disorders have not produced AM, which questions the role of these structures in the development the disease. (Spiegel et al., 1953)

In essence, the feedforward parallel organization of the above-described frontal-subcortical circuits creates the anatomical framework for the integration and transformation of information from different functional regions of the cerebral cortex. (Haber, 2016) Goal-directed behavior is the end-result of complex information integration from limbic, cognitive, and motor domains within this frontal-subcortical system. All structures within this system (described in I, II, IIIa and IIIb) need to work in concert with each other to process the complex chain of events that produce goal-directed behavior. Removing a single element of this frontal-subcortical orchestra can severely affect the drive for actions, including emotions, motivation, and cognition. This explains why damage to different parts of (pre)frontal and subcortical structures has been demonstrated to lead to similar behavioral or cognitive deficits, such as severe combined akinesia and mutism.

#### 4. Treatment of akinetic mutism

The treatment of transient or chronic AM remains difficult and reports in the literature on possible treatment strategies, optimal doses, and duration of treatment are limited. It is obvious that the first step in the treatment of AM remains the resolution of its underlying cause. However, if AM represents a more permanent clinical state after severe brain injury, a variety of drugs can be administered to diminish or resolve dysfunction of motivational neurocircuitry. Several drugs have been reported in the literature to have an effect on patients with AM.

##### 4.1. Dopamine agonist therapy

The first report on the use of DA agonists in AM was described by Ross and Stewart. (Ross and Stewart, 1981) Increasing doses of Bromocriptine, a DA agonist, were administered to a patient with AM after revision surgery for a third ventricle tumor, resulting in a spectacular improvement in both motor function and behavior. Ross and Stewart hypothesized that bypassing the damaged ascending mesolimbic and nigrostriatal dopaminergic pathways with direct DA agonists, acting at the dopaminergic target areas, i.e., the striatum and or the (pre)frontal cortex must have resulted in the direct improvement of akinesia and mutism. Other authors have also extensively reported on the positive effects of Bromocriptine in both AM and other motivational deficits after brain injury since. (Anderson, 1992; Powell et al., 1996) Bromocriptine is a highly selective D2 DA receptor agonist. The highest levels of D2 dopamine receptors are found in the striatum, the nucleus

accumbens, and the olfactory tubercle. D2 receptors are also expressed at significant levels in the substantia nigra, VTA, and are present in both the prefrontal and cingulate cortex, providing rich anatomical substrates for drug-interactions in AM. It is thought that Bromocriptine changes the regulation of inhibitory signalling through these D2-expressing receptors, improving activity in frontal regions through alteration of top-down control of behavior and control of selective attention. However, it is most likely that Bromocriptine especially alters complex frontal-subcortical signalling in the striatum through its high D2 distribution there. (Beaulieu and Gainetdinov, 2011; Keeler et al., 2014) Recently, Yang et al. demonstrated a specific reduction in striatal dopaminergic uptake in a patient with acute AM and showed return to normal levels at the 6-month follow-up with complete resolution of clinical symptoms. (Yang et al., 2007) Since there is a characteristic dose-dependency for Bromocriptine, it seems that a certain ‘threshold’ of D2 receptor occupancy must be reached to restore the associated frontal lobe dysfunction and motivational deficits in AM. Some authors have hypothesized that this dose-dependency can be explained by the low ratio of D2 receptors in the prefrontal and anterior cingulate cortex compared with D1 receptors. (Crismon et al., 1988; Hall et al., 1994) L-dopa, a presynaptic DA agonist works on both D1 and D2 receptors of (pre)frontal regions and the striatum and is also known to result in neurological recovery in AM patients. (Combarros et al., 2000; Deborah et al., 2017) However, dopaminergic treatment remains experimental. At present, a clinically important use of dopaminergic agonists, such as L-dopa, is countering behavioral deficits thought to be associated with lowered levels of DA metabolites and concomitant frontal lobe dysfunction in patients with traumatic brain injury. (Chew and Zafonte, 2009; Diaz-Arrastia et al., 2014)

##### 4.2. Treatment with methylphenidate and atomoxetine

In addition to DA agonists, AM has been treated with drugs that alter both noradrenaline and DA levels in the brain, such as Methylphenidate and Atomoxetine. In 1958, Daly and Love successfully treated AM with Methylphenidate. (Daly and Love, 1958) Methylphenidate is thought to increase the synaptic concentration of both DA and noradrenaline by blocking the DA and noradrenaline transporter. (Leonard et al., 2004) Methylphenidate specifically increases both prefrontal and striatal levels of DA and noradrenaline, which may account for the re-activation of frontal (sub)cortical circuitry and restorative effects of the drug in patients with disorders of diminished motivation and initiation. (Berridge et al., 2006; Volkow et al., 2001) In 2010, Kim and You described a case of a patient with AM after bilateral frontal lobe injury that clinically responded to increasing doses of Atomoxetine. (Kim et al., 2010) In contrast to Methylphenidate, Atomoxetine is mainly associated with an increase in extracellular concentrations of noradrenaline and DA in the prefrontal cortex and likely does not alter DA levels in the striatum. (Bymaster et al., 2002) However, the re-activation of prefrontal cortical areas may have a strong widespread effect on connectivity and impact other parts of the frontal-subcortical system involved in the regulation of dopaminergic neurotransmission. (Easton et al., 2007; Taber et al., 1995) Furthermore, Atomoxetine has been associated with improvements of cognitive functions and attentional processes and has gained considerable attention from the clinical community for treating frontal lobe symptoms after traumatic brain injury. (Arnsten, 1998; Bymaster et al., 2002; Chew and Zafonte, 2009; Diaz-Arrastia et al., 2014; Gamo et al., 2010; Watanabe et al., 1995)

##### 4.3. ‘Awakenings’ after zolpidem

Zolpidem is a non-benzodiazepine short-acting allosteric agonist of the  $\alpha 1$  receptor subtype of the gamma aminobutyric acid receptor complex (GABA) with well-established sleep-promoting properties. (Gosseries et al., 2014) Zolpidem is known to produce a paradoxical ‘awakening’ effect in patients with AM, though its effects are short-

lasting and patients show a significant ‘wearing-off’ phenomenon. (Brefel-Courbon et al., 2007) Temporary neurological recovery after Zolpidem has also been reported in a small and specific subset of other patients with severe brain injury, especially in those with disorders of consciousness. (Bomalaski et al., 2017; Clauss et al., 2000) It has been suggested that the paradoxical effects of Zolpidem could be attributable to the modulation of subcortical connectivity, particularly at the level of the GP. (Schiff, 2010) According to Schiff et al., severe brain damage to cortical and/or subcortical structures might cause the striatum to fail to inhibit the inhibitory outflow of the GPI to the thalamocortical system. This general loss of active inhibition from the striatum causes a pathological ‘hyperactive’ GPI that, in turn, results in increased thalamic inhibition and thereby disturbs anterior forebrain signalling. These changes result in a reduction of spontaneous behavior or even loss of consciousness. This ‘downstate’ might also be responsible for the loss of initiation and motivation for behavior in AM. Zolpidem is thought to have a direct disinhibiting influence on these pathological GPI outflow signals, thereby re-activating the thalamocortical system and restoring anterior forebrain signalling. A part of this hypothesis is confirmed in several animal studies in which specific injections of Zolpidem in the GP has been shown to lead to a decrease in firing rate of GP neurons and changes in motor behavior of rats. (Chen et al., 2004; Crone et al., 2017) In contrast, local application of a GABA<sub>A</sub> receptor antagonist increased the firing rate of GP neurons. (Galvan et al., 2005) Interestingly, Xue et al. found that application of a GABA<sub>A</sub> antagonist induced stronger excitatory effects in the GP of rats with a previous chemically induced lesion. (Xue et al., 2010) They suggested that this phenomenon could be mediated by the expression of more postsynaptic GABA<sub>A</sub> receptors or by the increased release of GABA from striato-pallidal and/or pallido-pallidal terminals in an injured GP. This observation might be translated to patients with AM in which post-injury subcortical upregulation of GABA<sub>A</sub> receptors and change of GABA release might be responsible for the paradoxical reaction to Zolpidem administration. However, basal GABAergic control of (sub)cortical structures, including the GP, might be more heterogeneous than what was previously thought and Zolpidem’s actions in AM might be following a far more complex mechanism than proposed by Schiff et al. (Brown and McKenna, 2015; Crone et al., 2017) After all, the model seems insufficient to capture the whole pathophysiological spectrum of AM, since it seems to disregard the relationship with focal GPI lesions and AM (as described in IIIa), which would theoretically, and paradoxically, result in GPI inactivity.

Another, more conceptual, hypothesis on Zolpidem action in patients with severe brain injury is that of ‘neural dormancy’ or ‘diaschisis’. (Demirtas-Tatlidede et al., 2013) It is thought that a neuroprotective ‘dormancy’ mechanism originates after severe brain injury, resulting in a temporary rise in GABA levels to reduce and suppress brain activity and excitotoxicity to facilitate the recovery of brain tissue and prevent more neuronal loss. This neuroprotective GABA mechanism may still be present in the chronic phase after brain injury, preventing the functional activity of brain regions associated with initiation and motor behavior. In this view, the paradoxical effect of Zolpidem could be explained by a high specific GABA<sub>A</sub> action of vital, though dormant ‘down-regulated’ brain regions. A wide variety of structures maintain a high density of GABA<sub>A</sub> α1 subunits, such as the substantia nigra, basal forebrain, thalamic reticular nucleus, and lamina IV of sensorimotor cortical regions, making them rich input and output structures for the GABAergic effects of Zolpidem. (Dennis et al., 1988; Pinault, 2004) Finally, severe brain injury might also cause neural activity to lose its power of complex information integration, resulting from hypersynchronization among the neuronal population. It is thought that the brain enters a state of pathological hypersynchronization after severe brain injury, which is temporarily restored by GABA α1 sensitive desynchronization through Zolpidem. (Hall et al., 2010; Williams et al., 2013)

## 5. Discussion

The function of the frontal lobes as an integrator of information related both to the external sensory world and internal limbic system, and its role in motivation and processing of motor reactions, makes this region and its subcortical connections critically important in understanding the pathophysiology of AM. (Miller and Cummings, 2018) There are several structures in the brain that are ‘usual suspects’ in the development of AM, most prominently the ACC, but also the striatum, GPI, and medial thalamus. Injury to any of these single structures seems to be able to disrupt the processing and integration of information within the frontal-subcortical circuit, resulting in AM. Since different frontal-subcortical circuits integrate information from anatomically disparate, but functionally related brain regions, a broad range of structural lesions to different parts of the frontal-subcortical circuit results in the development of a similar state of extreme sensory inattention. This corroborates the fact that AM has been described following a wide variety of lesions throughout the brain with a special role for the ‘way stations’ in the above-described (pre)frontal basal-ganglia-thalamocortical circuits. However, within this computational network, it remains obscure what exact proportion each of these single structures contribute to the general, broad AM condition. A synthesis of lesion studies in animals, imaging studies in humans, and clinical investigations in patients with AM suggests that AM arises as a result of loss of an ‘energizing factor’ in the frontal-subcortical system. The (pre)frontal cortex, in particular the ACC, may be considered the ‘battery’ that contributes to motivational control, and facilitates neural processes underlying behavior. (Holroyd and Yeung, 2012; Kouneiher et al., 2009) Damage to the (pre)frontal cortex may result in the withdrawal of this energizing factor following disconnection of frontal regions from their associated striatal parts or following specific neurotransmitter deficiencies, eventually resulting in the development of AM. (Habib, 2004; Holroyd and Yeung, 2012, 2011) Loss of this ‘battery’ function might also be the result of more distal injury or dysfunction of any of the components of the nigrostriatal or mesolimbic pathways, impairing dopaminergic input to frontal regions and the striatum. Subsequently, the loss of neurotransmitter input to the striatum is thought to result in disinhibition of the GPI neurons, which become tonically active, exerting a powerful inhibiting influence on their thalamic targets. (Schiff, 2010) This negative influences frontal activity and forms a reinforcing negative loop that impairs both spontaneous motor behavior and speech, forming the basis of persisting AM. In addition to the well-known role of cortico-basal ganglia circuits in the initiation and execution of behavior, it is now thought that there are also specific circuits that are involved in proactive and reactive inhibition of behavior. (Jahanshahi et al., 2015) Motivational processes emerge from a competition process between these execution and inhibition systems that act in parallel within the frontal-subcortical circuit. (Leblois et al., 2006; Piron et al., 2016) Clinical manifestations of other basal ganglia-related disorders, such as Parkinson’s disease, Tourette syndrome, and obsessive-compulsive disorder are already thought to be related to imbalances between these dual systems. Theoretically, AM may also be the result of a severe imbalance between these systems, and may be caused by a damage-induced dominant over-inhibition of behavioral processes.

A variety of pharmacological interventions may be used in the treatment of AM. Developing a rational pharmacologic approach to akinetic mutism does not only depend upon knowledge of what brain structures are affected, but also which neurotransmitter systems are involved. (Ross and Stewart, 1981) Most reports have been written about the effects of DA agonists, such as Bromocriptine, and Levodopa. This treatment may be considered when there is specific damage to the (pre)frontal cortex, damage to the midbrain or specific dysfunction of the DA conveying pathways. However, the effects of DA agonists are usually dose-dependent, subacute and only become evident after a couple days of treatment. Therefore, it is justified to start with a short trial of 10 mg Zolpidem, since a positive effect can be registered almost

instantly, with the use of a single dose. If there is no effect, it is conceivable to start a trial of Bromocriptine, Levodopa or drugs that affect both dopaminergic and noradrenergic transmission, such as Methylphenidate, or Atomoxetine. However, it is important to remember that most studies in patients with AM were performed without formal behavioral assessments, blinding and medication free intervals, possibly causing bias of treatment. Currently, a wide variety of other pharmacological interventions are studied to treat a diverse set of symptoms of frontal lobe dysfunction associated with severe brain injury, such as amantadine and cholinesterase inhibitors. (Chew and Zafonte, 2009; Diaz-Arrastia et al., 2014) Most drugs are currently undergoing phase II or phase III clinical evaluation for which results are pending, and their specific effects in patients with AM remain unknown. Therefore, treatment remains experimental, and not without any consequences. Long-term treatment with DA agonist is fraught with significant potential adverse effects, including disabling dyskinesia. Moreover, dopaminergic and GABAergic drugs can induce significant side-effects in AM patients and have to be carefully considered and selected. (Jeon et al., 2017)

## 6. Conclusion

AM is a rare, but severe neurological disorder. Patients with AM lack the motivating vector for the expression of spontaneous motor behavior and speech. It results in near-complete dependence on others for the most basic activities of daily life, invariably leading to nursing home admission. AM seems to arise as a result of a severe imbalance in the integration of information within the frontal-subcortical loop. The disorder may arise after brain damage, through a lack of an 'energizing factor' for expressing spontaneous behavior, or through damage-associated over-inhibition of behavior. The numerous structures and the many neurotransmitters, receptors, and modulators involved in this frontal-subcortical system account for the observation that lesions in different brain regions may have similar behavioral effects and that a variety of medications may have similar effects on behavioral disturbances. A series of pharmacological interventions, depending on individual pathophysiology, may be administered to patients in order to restore the imbalance in motivational neurocircuitry. Future studies, with more patients, specific neuroimaging procedures, neuropsychological evaluations, and placebo-controlled administration of drugs seem necessary to clarify the frontal-subcortical dysfunction in this enigmatic disease.

## Funding

This research did not receive any specific grant from funding agencies in the public, commercial, or not-for-profit sectors.

## References

Alexander, M.P., 2001. Chronic akinetic mutism after mesencephalic-diencephalic infarction: remediated with dopaminergic medications. *Neurorehabil. Neural Repair* 15, 151–156.

Anderson, B., 1992. Relief of akinetic mutism from obstructive hydrocephalus using bromocriptine and ephedrine. *Case report. J. Neurosurg.* 76, 152–155.

Arnsten, A.F., 1998. Catecholamine modulation of prefrontal cortical cognitive function. *Trends Cogn. Sci. (Regul. Ed.)* 2, 436–447.

Aspen Workgroup, 1995. Recommendations for use of uniform nomenclature pertinent to patients with severe alterations in consciousness. *American Congress of Rehabilitation Medicine. Arch. Phys. Med. Rehabil.* 76, 205–209.

Ballantine Jr, H.T., Cassidy, W.L., Flanagan, N.B., Marino Jr, R., 1967. Stereotaxic anterior cingulotomy for neuropsychiatric illness and intractable pain. *J. Neurosurg.* 26, 488–495.

Beaulieu, J.M., Gainetdinov, R.R., 2011. The physiology, signaling, and pharmacology of dopamine receptors. *Pharmacol. Rev.* 63, 182–217.

Berridge, C.W., Devilbiss, D.M., Andrzejewski, M.E., Arnsten, A.F., Kelley, A.E., Schmeichel, B., Hamilton, C., Spencer, R.C., 2006. Methylphenidate preferentially increases catecholamine neurotransmission within the prefrontal cortex at low doses that enhance cognitive function. *Biol. Psychiatry* 60, 1111–1120.

Bhatia, K.P., Marsden, C.D., 1994. The behavioural and motor consequences of focal

lesions of the basal ganglia in man. *Brain* 117 (Pt 4), 859–876.

Bogousslavsky, J., Regli, F., Delaloye, B., Delaloye-Bischof, A., Assal, G., Uske, A., 1991. Loss of psychic self-activation with bithalamic infarction. *Neurobehavioural, CT, MRI and SPECT correlates. Acta Neurol. Scand.* 83, 309–316.

Bomalaski, M.N., Clafflin, E.S., Townsend, W., Peterson, M.D., 2017. Zolpidem for the treatment of neurologic disorders: a systematic review. *JAMA Neurol.* 74, 1130–1139.

Brefel-Courbon, C., Payoux, P., Ory, F., Sommet, A., Slaoui, T., Raboyeau, G., Lemesle, B., Puel, M., Montastruc, J.L., Demonet, J.F., Cardebat, D., 2007. Clinical and imaging evidence of zolpidem effect in hypoxic encephalopathy. *Ann. Neurol.* 62, 102–105.

Brown, R.E., McKenna, J.T., 2015. Turning a negative into a positive: ascending GABAergic control of cortical activation and arousal. *Front. Neurol.* 6, 135.

Bymaster, F.P., Katner, J.S., Nelson, D.L., Hemrick-Luecke, S.K., Threlkeld, P.G., Heiligenstein, J.H., Morin, S.M., Gehlert, D.R., Perry, K.W., 2002. Atomoxetine increases extracellular levels of norepinephrine and dopamine in prefrontal cortex of rat: a potential mechanism for efficacy in attention deficit/hyperactivity disorder. *Neuropsychopharmacology* 27, 699–711.

Cairns, H., Oldfield, R.C., Pennybacker, J.B., Whitteridge, D., 1941. Akinetic mutism with an epidural cyst of the 3rd ventricle. *Brain* 64, 273–290.

Carota, A., Pop, A.I., Dueron, N., Calabrese, P., 2014. Akinetic mutism and utilization behavior after bilateral thalamo-polar artery stroke. *Acta Neurol. Belg.* 114, 153–155.

Carrera, E., Bogousslavsky, J., 2006. The thalamus and behavior: effects of anatomically distinct strokes. *Neurology* 66, 1817–1823.

Castaigne, P., Lhermitte, F., Buge, A., Escourolle, R., Hauw, J.J., Lyon-Caen, O., 1981. Paramedian thalamic and midbrain infarct: clinical and neuropathological study. *Ann. Neurol.* 10, 127–148.

Chen, L., Savio Chan, C., Yung, W.H., 2004. Electrophysiological and behavioral effects of zolpidem in rat globus pallidus. *Exp. Neurol.* 186, 212–220.

Chew, E., Zafonte, R.D., 2009. Pharmacological management of neurobehavioral disorders following traumatic brain injury—a state-of-the-art review. *J. Rehabil. Res. Dev.* 46, 851–879.

Choi, E.Y., Ding, S.L., Haber, S.N., 2017. Combinatorial inputs to the ventral striatum from the temporal cortex, frontal cortex, and amygdala: implications for segmenting the striatum. *Eneuro* 4.

Choudhari, K.A., 2004. Subarachnoid haemorrhage and akinetic mutism. *Br. J. Neurosurg.* 18, 253–258.

Clauss, R.P., Guldenpfennig, W.M., Nel, H.W., Sathekge, M.M., Venkannagari, R.R., 2000. Extraordinary arousal from semi-comatose state on zolpidem. *A case report. S. Afr. Med. J.* 90, 68–72.

Combarros, O., Infante, J., Berciano, J., 2000. Akinetic mutism from frontal lobe damage responding to levodopa. *J. Neurol.* 247, 568–569.

Cravioto, H., Silberman, J., Feigin, I., 1960. A clinical and pathologic study of akinetic mutism. *Neurology* 10, 10–21.

Crismon, M.L., Childs, A., Wilcox, R.E., Barrow, N., 1988. The effect of bromocriptine on speech dysfunction in patients with diffuse brain injury (akinetic mutism). *Clin. Neuropharmacol.* 11, 462–466.

Crone, J.S., Lutkenhoff, E.S., Bio, B.J., Laureys, S., Monti, M.M., 2017. Testing proposed neuronal models of effective connectivity within the cortico-basal ganglia-thalamo-cortical loop during loss of consciousness. *Cereb. Cortex* 27, 2727–2738.

Daly, D.D., Love, J.G., 1958. Akinetic mutism. *Neurology* 8, 238–242.

Damasio, A.R., 1994. *Descartes' Error: Emotion, Reason, and the Human Brain*. Avon Books, New York, pp. 312.

Damasio, A.R., Anderson, S.W., 1993. The frontal lobes. In: Heilman, K.M., V.E (Eds.), *Clinical Neuropsychology*, 3rd ed. Oxford University Press, New York, pp. 409–460.

Darby, R.R., Joutsa, J., Burke, M.J., Fox, M.D., 2018. Lesion network localization of free will. *Proc Natl Acad Sci U S A* 115, 10792–10797.

De Bie, R.M., Schuurman, P.R., Esselink, R.A., Bosch, D.A., Speelman, J.D., 2002. Bilateral pallidotomy in Parkinson's disease: a retrospective study. *Mov. Disord.* 17, 533–538.

Deborah, G., Ong, E., Nighoghossian, N., 2017. Akinetic mutism reversibility after L-dopa therapy in unilateral left anterior cerebral artery infarction. *Neurocase* 23, 171–172.

Demirtas-Tatlidede, A., Bahar, S.Z., Gurvit, H., 2013. Akinetic mutism without a structural prefrontal lesion. *Cogn. Behav. Neurol.* 26, 59–62.

Dennis, T., Dubois, A., Benavides, J., Scatton, B., 1988. Distribution of central omega 1 (benzodiazepine1) and omega 2 (benzodiazepine2) receptor subtypes in the monkey and human brain. An autoradiographic study with [3H]flunitrazepam and the omega 1 selective ligand [3H]zolpidem. *J. Pharmacol. Exp. Ther.* 247, 309–322.

Der-Avakian, A., Markou, A., 2012. The neurobiology of anhedonia and other reward-related deficits. *Trends Neurosci.* 35, 68–77.

Devinsky, O., Morrell, M.J., Vogt, B.A., 1995. Contributions of anterior cingulate cortex to behaviour. *Brain* 118 (Pt 1), 279–306.

Diaz-Arrastia, R., Kochanek, P.M., Bergold, P., Kenney, K., Marx, C.E., Grimes, C.J., Loh, L.T., Adam, L.T., Oskvig, D., Curley, K.C., Salzer, W., 2014. Pharmacotherapy of traumatic brain injury: state of the science and the road forward: report of the Department of Defense Neurotrauma Pharmacology Workgroup. *J. Neurotrauma* 31, 135–158.

Duffy, J., 2000. Apathy in Neurologic Disorders. *Current Psychiatry Reports* 2. pp. 434–439.

Easton, N., Marshall, F., Fone, K., Marsden, C., 2007. Atomoxetine produces changes in cortico-basal thalamic loop circuits: assessed by pHMRI BOLD contrast. *Neuropharmacology* 52, 812–826.

Engelborghs, S., Marien, P., Pickut, B.A., Verstraeten, S., De Deyn, P.P., 2000. Loss of psychic self-activation after paramedian bithalamic infarction. *Stroke* 31, 1762–1765.

Fisher, C.M., 1983. Honored guest presentation: abulia minor vs. Agitated behavior. *Clin. Neurosurg.* 31, 9–31.

Fisher, C.M., 1989. 'Catatonia' due to disulfiram toxicity. *Arch. Neurol.* 46, 798–804.

- Freeman, F.R., 1971. Akinetic mutism and bilateral anterior cerebral artery occlusion. *J. Neurol Neurosurg Psychiatry* 34, 693–698.
- Galvan, A., Villalba, R.M., West, S.M., Maidment, N.T., Ackerson, L.C., Smith, Y., Wichmann, T., 2005. GABAergic modulation of the activity of globus pallidus neurons in primates: in vivo analysis of the functions of GABA receptors and GABA transporters. *J. Neurophysiol.* 94, 990–1000.
- Gamo, N.J., Wang, M., Arnsten, A.F., 2010. Methylphenidate and atomoxetine enhance prefrontal function through alpha2-adrenergic and dopamine D1 receptors. *J. Am. Acad. Child Adolesc. Psychiatry* 49, 1011–1023.
- Giardino, J.T., 1997. Disorders of consciousness: differential diagnosis and neuropathologic features. *Semin. Neurol.* 17, 105–111.
- Giardino, J.T., Fins, J.J., Laureys, S., Schiff, N.D., 2014. Disorders of consciousness after acquired brain injury: the state of the science. *Nat. Rev. Neurol.* 10, 99–114.
- Gosseries, O., Charland-Verville, V., Thonnard, M., Bodart, O., Laureys, S., Demertzi, A., 2014. Amantadine, apomorphine and zolpidem in the treatment of disorders of consciousness. *Curr. Pharm. Des.* 20, 4167–4184.
- Groenewegen, H.J., Voon, P., Scheel-Krüger, J., 2016. Limbic-basal ganglia circuits: parallel and integrative aspects. In: Soghomonian, J.J. (Ed.), *The Basal Ganglia. Novel Perspectives on Motor and Cognitive Functions*. Springer, pp. 11–45.
- Groenewegen, H.J., Wouterlood, F.G., Uylings, H.B.M., 2017. Organization of Prefrontal-Striatal Connections, *Handbook of Basal Ganglia Structure and Function*. Elsevier, pp. 433–449.
- Haaxma, R., Robbins, T.W., James, M., Brouwer, W.H., Colebatch, J.G., Marsden, C.D., 1993. Neurobehavioural changes in a patient with bilateral lesions of the globus pallidus. *Behav. Neurol.* 6, 229–237.
- Haber, S.N., 2014. The place of dopamine in the cortico-basal ganglia circuit. *Neuroscience* 282, 248–257.
- Haber, S.N., 2016. Corticostriatal circuitry. *Dialogues Clin. Neurosci.* 18, 7–21.
- Haber, S.N., Calzavara, R., 2009. The cortico-basal ganglia integrative network: the role of the thalamus. *Brain Res. Bull.* 78, 69–74.
- Haber, S.N., McFarland, N.R., 1999. The concept of the ventral striatum in nonhuman primates. *Ann. N.Y. Acad. Sci.* 877, 33–48.
- Haber, S.N., Lynd, E., Klein, C., Groenewegen, H.J., 1990. Topographic organization of the ventral striatal efferent projections in the rhesus-monkey - an anterograde tracing study. *J. Comp. Neurol.* 293, 282–298.
- Habib, M., 2004. Athymhormia and disorders of motivation in Basal Ganglia disease. *J. Neuropsychiatry Clin. Neurosci.* 16, 509–524.
- Habib, M., Poncet, M., 1988. [Loss of vitality, of interest and of the affect (athymhormia syndrome) in lacunar lesions of the corpus striatum]. *Rev. Neurol. (Paris)* 144, 571–577.
- Hall, H., Sedvall, G., Magnusson, O., Kopp, J., Halldin, C., Farde, L., 1994. Distribution of D1- and D2-dopamine receptors, and dopamine and its metabolites in the human brain. *Neuropsychopharmacology* 11, 245–256.
- Hall, S.D., Yamawaki, N., Fisher, A.E., Clauss, R.P., Woodhall, G.L., Stanford, I.M., 2010. GABA(A) alpha-1 subunit mediated desynchronization of elevated low frequency oscillations alleviates specific dysfunction in stroke—a case report. *Clin. Neurophysiol.* 121, 549–555.
- Hawke, W.A., Donohue, W.L., 1951. Bilateral symmetrical necrosis of the corpora striata; report of a fatal case and reference to a possible syndrome of the corpora striata. *J. Nerv. Ment. Dis.* 113, 20–39.
- Heilbronner, S.R., Rodriguez-Romaguera, J., Quirk, G.J., Groenewegen, H.J., Haber, S.N., 2016. Circuit-based corticostriatal homologies between rat and primate. *Biol. Psychiatry* 80, 509–521.
- Holroyd, C.B., Yeung, N., 2011. An integrative theory of anterior cingulate cortex function: option selection in hierarchical reinforcement learning. *Neural Basis of Motivational and Cognitive Control* 333–349.
- Holroyd, C.B., Yeung, N., 2012. Motivation of extended behaviors by anterior cingulate cortex. *Trends Cogn. Sci. (Regul. Ed.)* 16, 122–128.
- Horvitz, J.C., 2002. Dopamine gating of glutamatergic sensorimotor and incentive motivational input signals to the striatum. *Behav. Brain Res.* 137, 65–74.
- Jahanshahi, M., Obeso, I., Rothwell, J.C., Obeso, J.A., 2015. A fronto-striato-subthalamic-pallidal network for goal-directed and habitual inhibition. *Nat. Rev. Neurosci.* 16, 719–732.
- Jang, S.H., Chang, C.H., Jung, Y.J., Lee, H.D., 2017. Recovery of akinetic mutism and injured prefronto-caudate tract following shunt operation for hydrocephalus and rehabilitation: a case report. *Medicine (Baltimore)* 96, e9117.
- Jeon, D.G., Kim, Y.W., Kim, N.Y., Park, J.H., 2017. Serotonin syndrome following combined administration of dopaminergic and noradrenergic agents in a patient with akinetic mutism after frontal intracerebral hemorrhage: a case report. *Clin. Neuropharmacol.* 40, 180–182.
- Jurgens, U., 2009. The neural control of vocalization in mammals: a review. *J. Voice* 23, 1–10.
- Kalivas, P.W., Barnes, C.D., 2019. *Limbic Motor Circuits and Neuropsychiatry*. CRC Press, Boca Raton.
- Keeler, J.F., Pretsell, D.O., Robbins, T.W., 2014. Functional implications of dopamine D1 vs. D2 receptors: a 'prepare and select' model of the striatal direct vs. Indirect pathways. *Neuroscience* 282, 156–175.
- Kemper, T.L., Romanul, F.C., 1967. State resembling akinetic mutism in basilar artery occlusion. *Neurology* 17, 74–80.
- Kim, H.A., You, S., 2017. Akinetic mutism in a patient with acute infarcts in the bilateral substantia nigra. *J. Neurol. Sci.* 373, 46–47.
- Kim, Y.W., Shin, J.C., An, Y.S., 2010. Treatment of chronic akinetic mutism with atomoxetine: subtraction analysis of brain f-18 fluorodeoxyglucose positron emission tomographic images before and after medication: a case report. *Clin. Neuropharmacol.* 33, 209–211.
- Kondziella, D., Sonnewald, U., Tullberg, M., Wikkelso, C., 2008. Brain metabolism in adult chronic hydrocephalus. *J. Neurochem.* 106, 1515–1524.
- Kouneither, F., Charron, S., Koechlin, E., 2009. Motivation and cognitive control in the human prefrontal cortex. *Nat. Neurosci.* 12, 939–945.
- Laplane, D., Levesseur, M., Pillon, B., Dubois, B., Baulac, M., Mazoyer, B., Tran Dinh, S., Sette, G., Danze, F., Baron, J.C., 1989. Obsessive-compulsive and other behavioural changes with bilateral basal ganglia lesions. A neuropsychological, magnetic resonance imaging and positron tomography study. *Brain* 112 (Pt 3), 699–725.
- Leblois, A., Boraud, T., Meissner, W., Bergman, H., Hansel, D., 2006. Competition between feedback loops underlies normal and pathological dynamics in the basal ganglia. *J. Neurosci.* 26, 3567–3583.
- Levy, R., Dubois, B., 2006. Apathy and the functional anatomy of the prefrontal cortex-basal ganglia circuits. *Cereb. Cortex* 16, 916–928.
- Livingston, K.E., 1953. Cingulate cortex isolation for the treatment of psychoses and psychoneuroses. *Res. Publ. Assoc. Res. Nerv. Ment. Dis.* 31, 374–378 passim.
- Ljungberg, T., Ungerstedt, U., 1976. Reinstatement of eating by dopamine agonists in aphagic dopamine denervated rats. *Physiol. Behav.* 16, 277–283.
- Lo, C.P., Chen, S.Y., Lee, K.W., Chen, W.L., Chen, C.Y., Hsueh, C.J., Huang, G.S., 2007. Brain injury after acute carbon monoxide poisoning: early and late complications. *AJR Am. J. Roentgenol.* 189, W205–211.
- Mackintosh, T.F., 1965. Akinetic mutism following coal-gas poisoning with subsequent recovery. *Postgrad. Med. J.* 41, 567–573.
- Marshall, J.F., Gotthelf, T., 1979. Sensory inattention in rats with 6-hydroxydopamine-induced neuroses. *Exp. Neurol.* 65, 398–411.
- Marshall, J.F., Ungerstedt, U., 1976. Apomorphine-induced restoration of drinking to thirst challenges in 6-hydroxydopamine-treated rats. *Physiol. Behav.* 17, 817–822.
- Meador, K.J., Watson, R.T., Bowers, D., Heilman, K.M., 1986. Hypometria with hemispatial and limb motor neglect. *Brain* 109 (Pt 2), 293–305.
- Medford, N., Critchley, H.D., 2010. Conjoint activity of anterior insular and anterior cingulate cortex: awareness and response. *Brain Struct. Funct.* 214, 535–549.
- Mendez, M.F., Adams, N.L., Lewandowski, K.S., 1989. Neurobehavioral changes associated with caudate lesions. *Neurology* 39, 349–354.
- Messert, B., Henke, T.K., Langheim, W., 1966. Syndrome of akinetic mutism associated with obstructive hydrocephalus. *Neurology* 16, 635–649.
- Meyer, J.S., Hunter, J., 1952. Behaviour deficits following diencephalic lesions. *Neurology* 2, 112–130.
- Meyers, R., 1942. The modification of alternating tremors, rigidity and festination by surgery of the basal ganglia. *Res. Pub. Ass. Nerv. Ment. Dis.* 21, 602–665.
- Meyers, R., 1951. Dandy's striatal theory of "the center of consciousness"; surgical evidence and logical analysis indicating its improbability. *AMA Arch. Neurol. Psychiatry* 65, 659–671.
- Miller, B.L., Cummings, J.L., 2018. *The Human Frontal Lobes: Functions and Disorders*, 3rd ed. The Guilford Press, New York.
- Monchi, O., Petrides, M., Strafella, A.P., Worsley, K.J., Doyon, J., 2006. Functional role of the basal ganglia in the planning and execution of actions. *Ann. Neurol.* 59, 257–264.
- Nagaratnam, N., Nagaratnam, K., Ng, K., Dui, P., 2004. Akinetic mutism following stroke. *J. Clin. Neurosci.* 11, 25–30.
- Nemeth, G., Hegedus, K., Molnar, L., 1986. Akinetic mutism and locked-in syndrome: the functional-anatomical basis for their differentiation. *Funct. Neurol.* 1, 128–139.
- Nemeth, G., Hegedus, K., Molnar, L., 1988. Akinetic mutism associated with bicingular lesions: clinicopathological and functional anatomical correlates. *Eur. Arch. Psychiatry Neurol. Sci.* 237, 218–222.
- Pinault, D., 2004. The thalamic reticular nucleus: structure, function and concept. *Brain Res. Brain Res. Rev.* 46, 1–31.
- Piron, C., Kase, D., Topalidou, M., Goillandeau, M., Orignac, H., N'Guyen, T.H., Rougier, N., Boraud, T., 2016. The globus pallidus pars interna in goal-oriented and routine behaviors: resolving a long-standing paradox. *Mov. Disord.* 31, 1146–1154.
- Powell, J.H., al-Adawi, S., Morgan, J., Greenwood, R.J., 1996. Motivational deficits after brain injury: effects of bromocriptine in 11 patients. *J. Neurol Neurosurg Psychiatry* 60, 416–421.
- Rebai, R.M., Houissa, S., Mustapha, M.E., Azzouini, H., Assagaf, S., 2012. Akinetic mutism and parkinsonism after multiple shunt failure: case report and literature review. *J. Neurol. Surg. A. Cent. Eur. Neurosurg.* 73, 341–346.
- Ross, E.D., Stewart, R.M., 1981. Akinetic mutism from hypothalamic damage: successful treatment with dopamine agonists. *Neurology* 31, 1435–1439.
- Saga, Y., Hoshi, E., Tremblay, L., 2017. Roles of multiple globus pallidus territories of monkeys and humans in motivation, cognition and action: an anatomical, physiological and pathophysiological review. *Front. Neuroanat.* 11, 30.
- Salamone, J.D., Correa, M., 2012. The mysterious motivational functions of mesolimbic dopamine. *Neuron* 76, 470–485.
- Schiff, N.D., 2010. Recovery of consciousness after brain injury: a mesocircuit hypothesis. *Trends Neurosci.* 33, 1–9.
- Segarra, J.M., 1970. Cerebral vascular disease and behavior. I. The syndrome of the mesencephalic artery (basilar artery bifurcation). *Arch. Neurol.* 22, 408–418.
- Shenhav, A., Botvinick, M.M., Cohen, J.D., 2013. The expected value of control: an integrative theory of anterior cingulate cortex function. *Neuron* 79, 217–240.
- Shetty, A.C., Morris, J., O'Mahony, P., 2009. Akinetic mutism—not coma. *Age Ageing* 38, 350–351.
- Skultety, F.M., 1968. Clinical and experimental aspects of akinetic mutism. Report of a case. *Arch. Neurol.* 19, 1–14.
- Spiegel, E.A., Wycis, H.T., Freed, H., Orchinik, C., 1953. Thalamotomy and hypohalotomy for the treatment of psychoses. *Res. Publ. Assoc. Res. Nerv. Ment. Dis.* 31, 379–391 passim.
- Strub, R.L., 1989. Frontal lobe syndrome in a patient with bilateral globus pallidus lesions. *Arch. Neurol.* 46, 1024–1027.
- Taber, M.T., Das, S., Fibiger, H.C., 1995. Cortical regulation of subcortical dopamine



- release: mediation via the ventral tegmental area. *J. Neurochem.* 65, 1407–1410.
- Tashiro, Y., Drake, J.M., Chakraborty, S., Hattori, T., 1997. Functional injury of cholinergic, GABAergic and dopaminergic systems in the basal ganglia of adult rat with kaolin-induced hydrocephalus. *Brain Res.* 770, 45–52.
- Tekin, S., Cummings, J.L., 2002. Frontal-subcortical neuronal circuits and clinical neuropsychiatry: an update. *J. Psychosom. Res.* 53, 647–654.
- Tengvar, C., Johansson, B., Sorensen, J., 2004. Frontal lobe and cingulate cortical metabolic dysfunction in acquired akinetic mutism: a PET study of the interval form of carbon monoxide poisoning. *Brain Inj.* 18, 615–625.
- Tibbetts, P., 2001. The anterior cingulate cortex, akinetic mutism, and human volition. *Brain Mind* 2, 323–341.
- Ungerstedt, U., 1970. Is interruption of the nigro-striatal dopamine system producing the "lateral hypothalamus syndrome"? *Acta Physiol. Scand.* 80, 35A–36A.
- Ungerstedt, U., 1971. Adipsia and aphagia after 6-hydroxydopamine induced degeneration of the nigro-striatal dopamine system. *Acta Physiol. Scand. Suppl.* 367, 95–122.
- Ure, J., Faccio, E., Videla, H., Caccuri, R., Giudice, F., Ollari, J., Diez, M., 1998. Akinetic mutism: a report of three cases. *Acta Neurol. Scand.* 98, 439–444.
- Van der Werf, Y.D., Witter, M.P., Groenewegen, H.J., 2002. The intralaminar and midline nuclei of the thalamus. Anatomical and functional evidence for participation in processes of arousal and awareness. *Brain Res. Brain Res. Rev.* 39, 107–140.
- van Domburg, P.H., ten Donkelaar, H.J., Notermans, S.L., 1996. Akinetic mutism with bithalamic infarction. Neurophysiological correlates. *J. Neurol. Sci.* 139, 58–65.
- Volkow, N.D., Wang, G., Fowler, J.S., Logan, J., Gerasimov, M., Maynard, L., Ding, Y., Gatley, S.J., Gifford, A., Franceschi, D., 2001. Therapeutic doses of oral methylphenidate significantly increase extracellular dopamine in the human brain. *J. Neurosci.* 21, RC121.
- Watanabe, M.D., Martin, E.M., DeLeon, O.A., Gaviria, M., Pavel, D.G., Trepashko, D.W., 1995. Successful methylphenidate treatment of apathy after subcortical infarcts. *J. Neuropsychiatry Clin. Neurosci.* 7, 502–504.
- Williams, S.T., Conte, M.M., Goldfine, A.M., Noirhomme, Q., Gosseries, O., Thonnard, M., Beattie, B., Hersh, J., Katz, D.I., Victor, J.D., Laureys, S., Schiff, N.D., 2013. Common resting brain dynamics indicate a possible mechanism underlying zolpidem response in severe brain injury. *Elife* 2, e01157.
- Xue, Y., Han, X.H., Chen, L., 2010. Effects of pharmacological block of GABA(A) receptors on pallidal neurons in normal and parkinsonian state. *Front. Cell. Neurosci.* 4, 2.
- Yang, C.P., Huang, W.S., Shih, H.T., Lin, C.Y., Lu, M.K., Kao, C.H., Hsieh, T.C., Huang, K.J., Lee, Y.H., Tsai, C.H., 2007. Diminution of basal ganglia dopaminergic function may play an important role in the generation of akinetic mutism in a patient with anterior cerebral arterial infarct. *Clin. Neurol. Neurosurg.* 109, 602–606.
- Yarns, B.C., Quinn, D.K., 2013. Telephone effect in akinetic mutism from traumatic brain injury. *Psychosomatics* 54, 609–610.