

Necrobiosis Lipoidica following Breast Reduction

Gilles Absil, MD*

Patrick Collins, MD†

Lara El Hayderi, MD, PhD*

Arjen F. Nikkels MD, PhD*

Summary: Necrobiosis lipoidica (NL) is a rare granulomatous skin disorder of unknown physiopathology that is frequently associated with diabetes mellitus. The typical skin lesions of NL present as chronic, bilateral, well-defined red to yellow-brown plaques with telangiectasias, a violaceous border and a waxy atrophic center. The lower legs are the most often involved areas, but NL may exceptionally develop on scar tissue following surgery. The treatment is very challenging and notoriously difficult. We report a 60-year-old diabetic woman who developed NL all along the surgical scars following breast reduction, without presenting NL on the lower legs. NL should be considered among the rare but possible skin healing complications of surgery. (*Plast Reconstr Surg Glob Open* 2021;9:e3788; doi: 10.1097/GOX.0000000000003788; Published online 13 September 2021.)

A 60-year-old woman presented with indolent skin lesions developing on the scars and the direct surrounding areas after bilateral breast reduction, performed 8 months previously. Her medical history revealed high blood pressure, dyslipidemia, hypothyroidy, and a 3-year history of non-insulin-dependent diabetes mellitus (DM). The medication consisted of metformin, semaglutide, gliclazide, levothyroxine, bromazepam, simvastatin, furosemide, and omeprazole. There were no allergic antecedents. Previous surgical interventions revealed normal scarring without any signs of hypertrophic or keloid scarring.

Clinical examination revealed asymptomatic bilateral yellow-reddish atrophic plaques with numerous irregular telangiectasias around and under the nipples all along the surgical scars (Fig. 1). Nail examination showed diffuse thinning, longitudinal ridging and distal splitting, as well as nail pterygium of the left thumb compatible with nail lichen planus. Genital and oral examination as well as the complete body examination were normal, in particular the anterior aspects of the shins (Fig. 1).

A 4-mm punch biopsy was obtained under local anesthesia (Fig. 2). The histopathologic examination showed large areas of homogenization and hyalinization of collagen fibers compatible with necrobiosis, surrounded by a chronic inflammatory infiltrate comprising macrophages

and palisading giant multi-nucleated cells. Small nodules of lymphocytes and plasma cells were also present. Minimal changes with slight atrophy were observed in the epidermis. Colloidal iron and Alcian blue histochemical stains showed no significant mucin deposits.

The final conclusion was necrobiosis lipoidica (NL) developing on surgical scars. The patient was treated with topical tacrolimus ointment 0.1% twice daily for 2 months without achieving significant clinical improvements.

DISCUSSION

NL is a rare granulomatous dermatitis first described in 1929 by Oppenheim under the name “dermatitis atrophicans lipoidica diabetorum,” then renamed “necrobiosis lipoidica diabetorum” by Urbach in 1932. However, the association with DM is not systematic with only 11%–65%^{1,2} of patients with NL having clinically proven DM. Furthermore, only 0.3%–1.2%^{1,2} of diabetic patients will develop NL over their lifetime. Other risk factors for developing NL include obesity, hypertension, dyslipidemia, and thyroid disease, and there is an approximate 5:1 female-to-male ratio.³

The typical skin lesions of NL present as chronic, bilateral, well-defined red to yellow-brown plaques with telangiectasias, a violaceous border and a waxy atrophic center. The majority of lesions is asymptomatic but itch and/or pain are sometimes reported. Ulceration of the NL skin lesions is a frequent feature occurring in up to a third of patients, usually after a minor trauma.¹ Less common clinical presentations include papules and nodules, but they could simply represent an early disease stage.³

Regarding the localization of NL, the lower legs are involved in up to 97.8% of the patients. Exceptional and atypical localizations include the face and the scalp, the penis, the trunk, and the upper extremities.³

From the *Department of Dermatology, CHU du Sart Tilman, University of Liège, Liège, Belgium; and †Department of Dermatopathology, CHU du Sart Tilman, University of Liège, Liège, Belgium.

Received for publication June 18, 2021; accepted July 6, 2021.

Copyright © 2021 The Authors. Published by Wolters Kluwer Health, Inc. on behalf of The American Society of Plastic Surgeons. This is an open-access article distributed under the terms of the [Creative Commons Attribution-Non Commercial-No Derivatives License 4.0 \(CCBY-NC-ND\)](https://creativecommons.org/licenses/by-nc-nd/4.0/), where it is permissible to download and share the work provided it is properly cited. The work cannot be changed in any way or used commercially without permission from the journal.

DOI: 10.1097/GOX.0000000000003788

Disclosure: The authors have no financial interest to declare in relation to the content of this article.

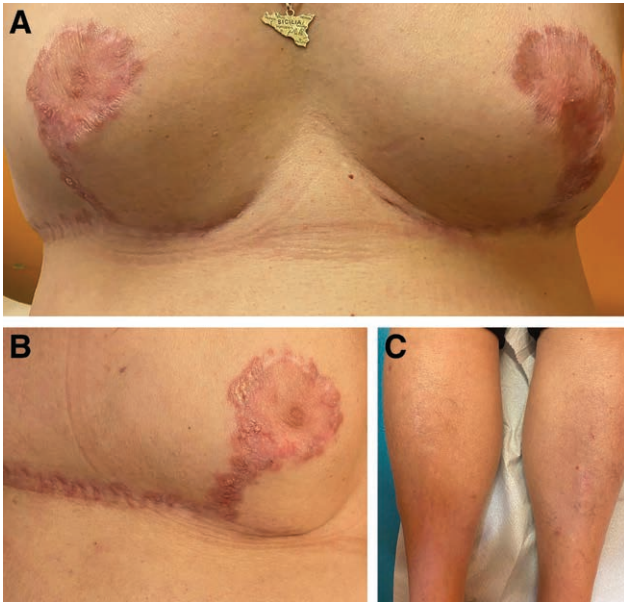


Fig. 1. A,B: Bilateral necrobiosis around and under the nipples along the surgical scars. C, Normal aspect of the pretibial areas.

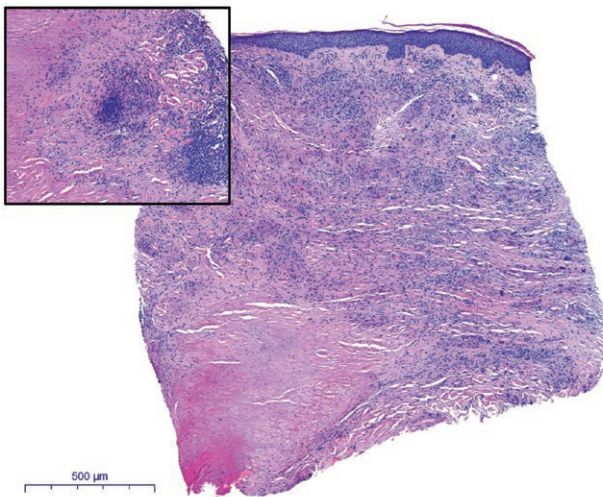


Fig. 2. Large areas of granulomatous homogenization and hyalinization of collagen fibers compatible with necrobiosis, surrounded by a chronic inflammatory infiltrate comprising macrophages and palisading giant multi-nucleated cells (×10, H/E) and high power magnification of the granulomatous reaction (×20, H/E).

The physiopathology of NL remains unknown, but suggested hypotheses include a microangiopathy, an antibody-mediated vascular disease, neutrophil defects, and collagen abnormalities.²

The Köbner’s phenomenon is defined as the development of an underlying skin disease on previously nonaffected skin following trauma. A link between NL and the Köbner effect on traumatized skin has been well established, with previous reports of NL developing on sites of insulin injections, burns, or surgical scars.^{4–9} However, it has been suggested that because NL sometimes develops on scar tissue without a previous history of NL elsewhere

on the skin, it might sometimes present as a Wolf’s isomorphic response. The latter is defined as a new skin disease occurring at the site of a previously healed dermatosis or as a manifestation of Ruocco’s “immunocompromised cutaneous district” in which a harmful event induces a local immune dysregulation that makes the skin susceptible to immune-mediated skin disorders.¹⁹ The time interval between trauma/surgery and the development of NL ranges from a few months to 10 years.^{4–9}

As far as we know, NL developing on surgical scars after breast reduction surgery is exceptional. Only two cases have been published in the English literature, following breast reconstruction surgery.^{8,9}

The treatment of NL is very challenging and notoriously difficult. An adequate control of glucose does not affect the evolution of NL but should always be aimed to prevent other complications of DM.¹⁰ The first-line treatments involve topical or intralesional corticosteroids of the borders of the lesions to reduce extension and progression or short courses of systemic corticosteroids in the event of extensive skin involvement. Second-line options including topical tacrolimus 0.1% ointment, topical tretinoin 0.5%, oral ciclosporin (3–5 mg/kg/d), and psoralen plus ultraviolet A have been used with some success.¹⁰ Other anecdotic treatments include intralesional infliximab and other TNF-alpha inhibitors such as etanercept, thalidomide, pioglitazone, fumaric acid esters, antimalarials, and hyperbaric oxygene.^{2,10} It is interesting to note that temptations of a surgical re-intervention should be avoided because surgery requires a deep excision involving the level of the periosteum or the deep facia as well as skin grafting, and that recurrence rates are high.

NL should be considered in the differential diagnosis of cutaneous inflammatory complications of surgical scars of the skin. Among them, sarcoidosis and pyoderma gangrenosum should be excluded.

Unfortunately, there is no predictive factor for developing NL postsurgery. It remains unknown whether the previous presence of NL of the anterior aspects and/or patients with DM should be monitored more closely as early treatment of NL presents better chances of esthetically acceptable healing.

In conclusion, NL is an exceptional cutaneous complication of breast reduction surgery. Rapid identification reduces the risk of extension of NL and unsightly very-difficult-to-treat scarring.

Gilles Absil, MD

CHU du Sart Tilman
University of Liège Avenue de l’Hôpital, 1
B-4000 Liège
Belgium
E-mail: gilles.absil@gmail.com

REFERENCES

- Muller SA, Winkelmann RK. Necrobiosis lipoidica diabetorum. A clinical and pathological investigation of 171 cases. *Arch Dermatol.* 1966;93:272–281.
- Sibbald C, Reid S, Alavi A. Necrobiosis lipoidica. *Dermatol Clin.* 2015;33:343–360.

3. Hashemi DA, Brown-Joel ZO, Tkachenko E, et al. Clinical features and comorbidities of patients with necrobiosis lipoidica with or without diabetes. *JAMA Dermatol.* 2019;155:455–459.
4. Miller RA. Koebner phenomenon in a diabetic with necrobiosis lipoidica diabetorum. *Int J Dermatol.* 1990;29:52–53.
5. Ghatge JV, Williford PM, Sane DC, et al. Necrobiosis lipoidica associated with Köbner's phenomenon in a patient with diabetes. *Cutis.* 2001;67:158–160.
6. Gebauer K, Armstrong M. Koebner phenomenon with necrobiosis lipoidica diabetorum. *Int J Dermatol.* 1993;32:895–896.
7. Prieto-Torres L, Bernárdez C, Hernández-Ostiz S, et al. Necrobiosis lipoidica developing within a surgical scar in a non-diabetic patient: type III Koebner phenomenon (isomorphic response), Wolf's isotopic response or Ruocco's immunocompromised cutaneous district? *Indian J Dermatol Venereol Leprol.* 2017;83:233–236.
8. Khurana M, Torbeck R, Kauh Y. An atrophic plaque on the breast six years after breast reconstruction surgery. *Dermatol Online J.* 2016;22:11.
9. Azoulay B, Bosque T, Burin des Rozières B, et al. Nécrobiose lipoïdique sur sein reconstruit par un implant en silicone: à propos d'un cas. *Ann Chir Plast Esth.* 2012;57:79–82.
10. Reid SD, Ladizinski B, Lee K, et al. Update on necrobiosis lipoidica: a review of etiology, diagnosis, and treatment options. *J Am Acad Dermatol.* 2013;69:783–791.