

Multimodality Imaging Strategies for the Assessment of Aortic Stenosis

Viewpoint of the Heart Valve Clinic International Database (HAVEC) Group

Raluca Dulgheru, MD; Philippe Pibarot, DVM, PhD; Partho P. Sengupta, MD, PhD; Luc A. Piérard, MD, PhD; Raphael Rosenhek, MD, PhD; Julien Magne, PhD; Erwan Donal, MD; PhD, Anne Bernard, MD, PhD; Khalil Fattouch, MD; Bernard Cosyns, MD, PhD; Mani Vannan, MBBS; Linda Gillam, MD; Patrizio Lancellotti, MD, PhD

Abstract—Aortic stenosis is the most frequent valvular heart disease. In aortic stenosis, therapeutic decision essentially depends on symptomatic status, stenosis severity, and status of left ventricular systolic function. Surgical aortic valve replacement or transcatheter aortic valve implantation is the sole effective therapy in symptomatic patients with severe aortic stenosis, whereas the management of asymptomatic patients remains controversial and is mainly based on individual risk stratification. Imaging is fundamental for the initial diagnostic work-up, follow-up, and selection of the optimal timing and type of intervention. The present review provides specific recommendations for utilization of multimodality imaging to optimize risk stratification and therapeutic decision-making processes in aortic stenosis. (*Circ Cardiovasc Imaging*. 2016;9:e004352. DOI: 10.1161/CIRCIMAGING.115.004352.)

Key Words: aortic valve stenosis ■ biomarkers ■ echocardiography, Doppler ■ guideline ■ prognosis ■ standards

Calcific aortic stenosis (AS) is the most frequent valvular heart disease in developed countries.¹ AS often has a long latency period before symptom onset; however, when symptoms develop and severe AS is present, the average survival is reduced to 2 to 3 years in the absence of treatment. Although surgical aortic valve replacement (AVR) or transcatheter aortic valve implantation (TAVI) is the sole effective treatment for symptomatic severe AS, the postoperative outcome varies notably from one patient to another. Risk stratification in asymptomatic patients and identification of markers of poor prognosis in symptomatic subjects have, thus, become key elements in the management of AS. Standard Doppler echocardiography is the cornerstone of the evaluation of AS, and in ≈65% to 70% of the patients, this imaging modality is sufficient to guide therapeutic management. However, in ≈25% to 30% of the patients, there are some uncertainties about AS severity at Doppler echocardiographic examination, and these patients may, thus, require multimodality imaging to confirm disease stage and guide

therapeutic decision making.²⁻⁷ The present review provides specific recommendations based on the current literature on the utilization of multimodality imaging in AS.

New Classification of AS and Concept of Disease Stages

The 2014 American College of Cardiology (ACC)/American Heart Association (AHA) guidelines have introduced the concept of disease staging for valvular heart disease, including AS (Figure 1),² which has introduced additional degrees of complexity in the classification of AS. The identification of disease stage is essentially based on the assessment of stenosis severity and left ventricular (LV) systolic function by Doppler echocardiography and the patient's symptomatic status. The symptomatic severe stage (D) includes patients who have developed symptoms as a result of severe AS. This stage is subdivided into 3 stages: D1, D2, and D3 according to the flow-gradient classification of AS.^{3,4} All these entities are characterized by a small aortic

Received November 14, 2015; accepted January 12, 2016.

From the University of Liège Hospital, GIGA Cardiovascular Sciences, Departments of Cardiology, Heart Valve Clinic, CHU Sart Tilman, Liège, Belgium (R.D., L.A.P., P.L.); Quebec Heart and Lung Institute, Department of Medicine, Quebec City, Quebec, Canada (P.P.); Zena and Michael A. Wiener Cardiovascular Institute, Icahn School of Medicine at Mount Sinai, Cardiology Department, New York, NY (P.P.S.); Department of Cardiology, Medical University of Vienna, Vienna, Austria (R.R.); CHU Limoges, Hôpital Dupuytren, Pôle Coeur-Poumon-Rein, Cardiology Department, Limoges, France (J.M.); CIC-IT U 804, CHU Rennes, Université Rennes 1, Cardiology Department, CHU RENNES, Rennes, France (E.D.); CHU Tours, France et Université de Tours, Cardiology Department, Tours, France (A.B.); Gruppo Villa Maria Care and Research, Anthea Hospital, Cardiology Department, Italy (K.F., P.L.); Cardiology, Centrum voor Hart en Vaatziekten, UZ Brussel, Belgium (B.C.); Piedmont Heart Institute, Cardiology Department, Atlanta, GA (M.V.); and Department of Cardiovascular Medicine, Morristown Medical Center, Morristown, NJ (L.G.).

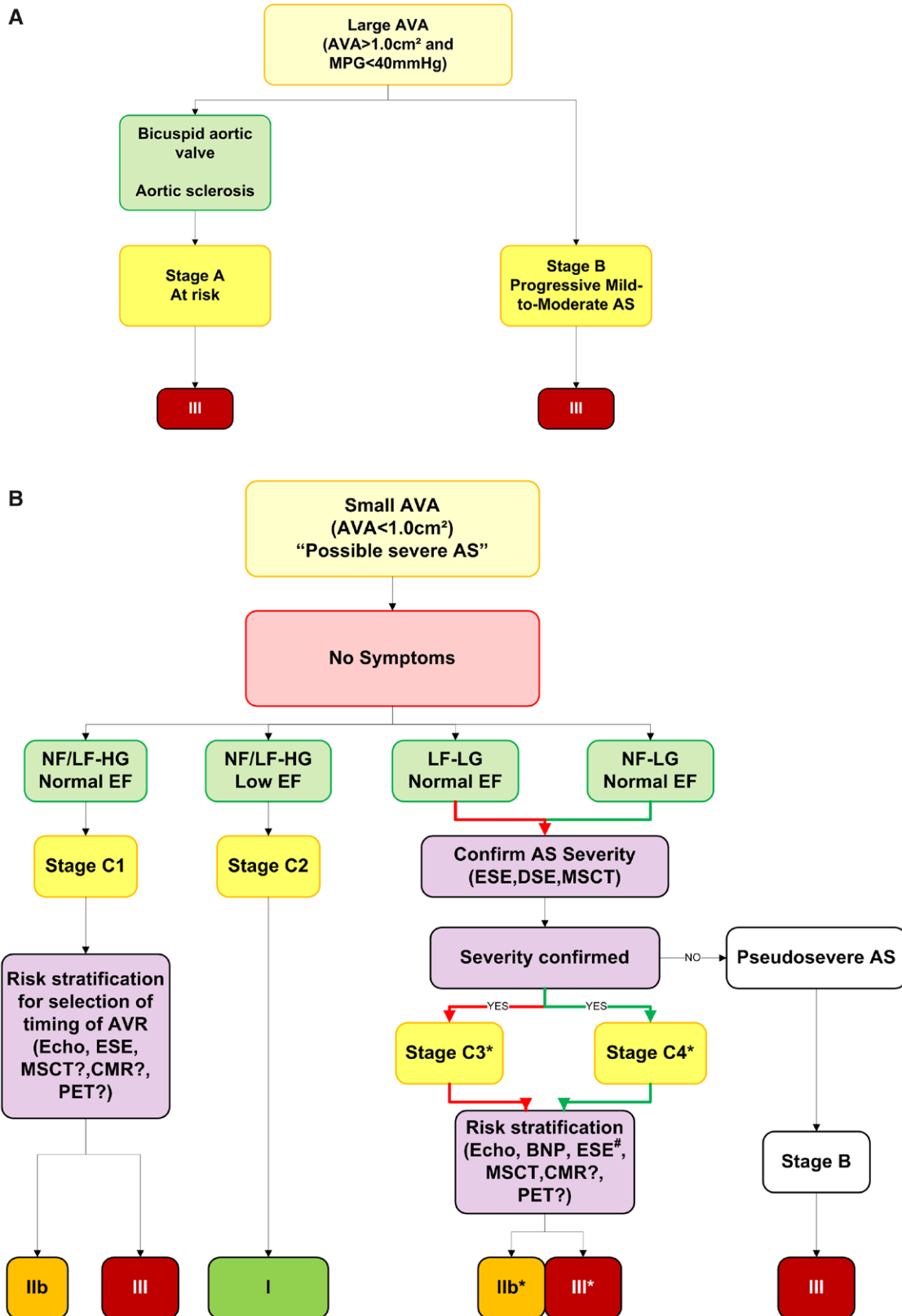
The Data Supplement is available at <http://circimaging.ahajournals.org/lookup/suppl/doi:10.1161/CIRCIMAGING.115.004352/-/DC1>.

Correspondence to Patrizio Lancellotti, MD, PhD, HAVEC Group, Avenue de l'hôpital, n1, Department of Cardiology, University Hospital, Université de Liège, CHU du Sart Tilman, 4000 Liège, Belgium. E-mail plancellotti@chu.ulg.ac.be

© 2016 American Heart Association, Inc.

Circ Cardiovasc Imaging is available at <http://circimaging.ahajournals.org>

DOI: 10.1161/CIRCIMAGING.115.004352



#For patients with a positive exercise stress test refer to Panel C
*Recommendation from the HAVEC group

Figure 1. (Continued).

Downloaded from <http://circimaging.ahajournals.org/> by guest on November 9, 2016

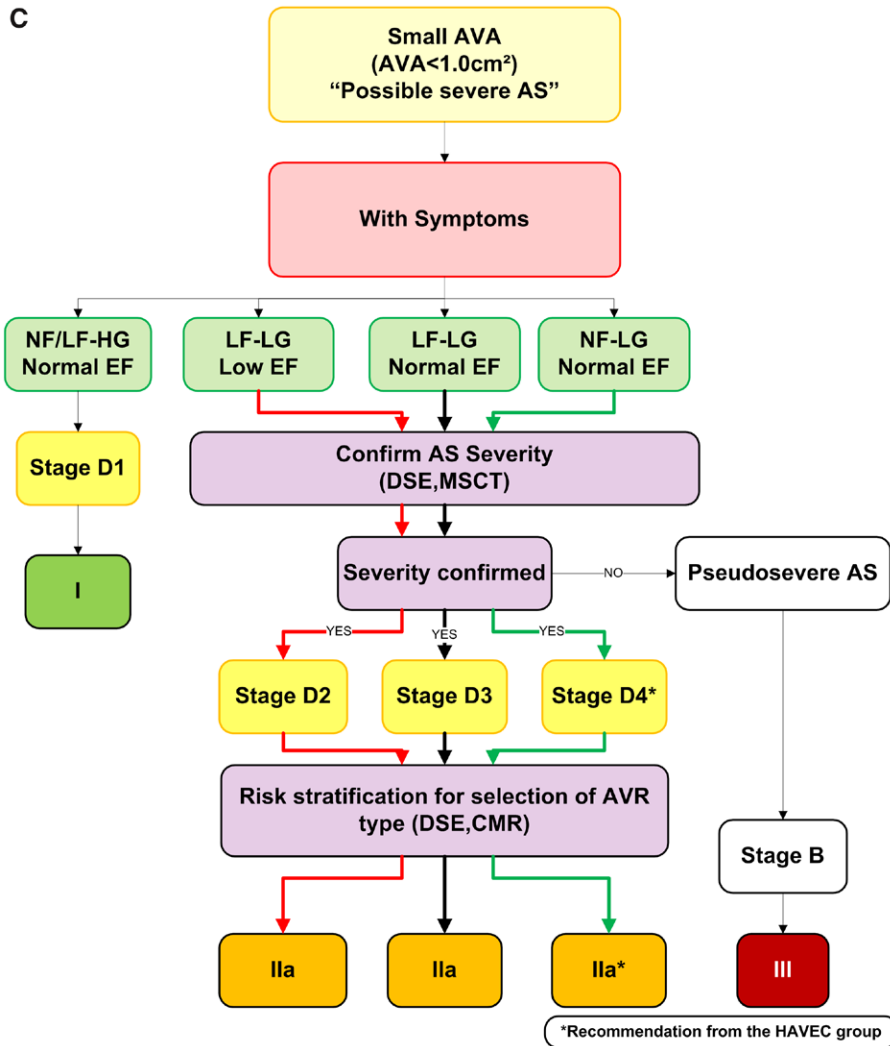


Figure 1 Continued. Algorithms proposed by the Heart Valve Clinic International Database (HAVEC) group for disease staging and management in patients with aortic valve stenosis. AS indicates aortic stenosis; AVA, aortic valve area; AVR, aortic valve replacement; CMR, cardiac magnetic resonance; DSE, dobutamine stress echocardiography; ESE, exercise stress echocardiography; EF, ejection fraction; HG, high gradient; LF, low flow; LG, low gradient; MPG, mean pressure gradient; MSCT, multislice computed tomography; NF, normal flow; and PET, positron emission tomography.

valve area (AVA; $<1.0 \text{ cm}^2$), thus suggesting severe AS, but they differ in terms of LV remodeling, systolic function, transvalvular flow, transvalvular pressure gradients, and outcomes. Patients with low LV ejection fraction (LVEF $<50\%$) and LG (LG $<40 \text{ mmHg}$) are referred as to classical low-flow (LF) LG AS and are classified as stage D2 in the ACC/AHA guidelines.² This entity is characterized by depressed LV systolic function, LV eccentric remodeling, and poor outcomes with medical therapy but high surgical risk with surgical AVR.^{5,6} Patients with a small AVA and a preserved LVEF are then separated into 4 groups according to (1) flow, that is, LF defined by an indexed LV stroke volume $<35 \text{ mL/m}^2$ versus normal flow (NF; $\geq 35 \text{ mL/m}^2$) and (2) mean gradient, that is, low (LG $<40 \text{ mmHg}$) versus high gradient (HG $\geq 40 \text{ mmHg}$). An LF state is indeed commonly defined as an indexed LV stroke volume of $<35 \text{ mL/m}^2$, a cutoff associated with worse outcomes in AS.^{7,8} The 4 flow-gradient groups are, thus, (1) NF-HG, (2) LF-HG, (3) NF-LG, and (4) LF-LG.

The current guidelines make no distinction between the NF-HG and LF-HG AS, and these 2 entities are grouped together

into the C1 or D1 stages depending on whether the patient is asymptomatic or symptomatic, respectively.² In these patients, the stenosis is likely severe, and there is no need for additional diagnostic tests to corroborate severity. However, among patients with HG and preserved LVEF, those with LF generally have a worse prognosis both before and after AVR, compared with those with NF.^{4,7,9} The patients with preserved LVEF and LF-LG are referred as to paradoxical LF-LG AS, which is classified as stage D3 in the ACC/AHA guidelines, if the patient is symptomatic.² In these patients, the decrease in stroke volume ($<35 \text{ mL/m}^2$) and transvalvular flow is generally related to pronounced LV concentric remodeling (relative wall thickness, >0.5) with small LV cavity (end-diastolic volume index, $<55 \text{ mL/m}^2$), restrictive LV diastolic pattern, and reduced global longitudinal strain (global strain, $<16\%$).^{3,8,10} However, the LF state may also occur because of concomitant mitral regurgitation, tricuspid regurgitation, atrial fibrillation, constrictive pericarditis, or severe pulmonary hypertension with right ventricular failure. Little is known about the natural history of paradoxical LF-LG AS.¹¹⁻¹³

Albeit there are some discrepancies, most of the previous studies report that among these 4 flow-gradient groups with small AVA and preserved LVEF, the one with paradoxical LF-LG AS has the worst prognosis and those with NF-LG AS has the best prognosis.^{4,7,14} Furthermore, AVR improves outcomes in both patients with HG AS and those with paradoxical LF-LG AS. In patients with NF-LG AS, previous studies have yielded conflicting results on the effect of AVR on outcomes. This entity may, at least in part, be related to the inherent discrepancy between the cut-point values of AVA (1.0 cm²) and mean gradient (40 mmHg) proposed in the guidelines to identify severe AS.¹⁵ Indeed, an AVA of 1.0 cm² corresponds to a mean gradient of 30 to 35 mmHg rather than 40 mmHg in a patient with NF rate, and as a consequence, several patients with moderate-to-severe AS might have discordant AVA-gradient measurements. Although the NF-LG entity is generally perceived as being a nonsevere form of AS, some recent studies using aortic valve calcium scoring by cardiac multislice computed tomography (MSCT) suggest that up to 50% of these patients would have severe AS.¹⁶ Consistent with this finding, several studies report a potential survival benefit of AVR in these patients.^{17,18} The guidelines provide no specific stage or recommendation of intervention for these patients with NF-LG. The Heart Valve Clinic International Database (HAVEC) group would suggest an integrated classification by creating new stages for these patients and those with LF-LG AS: patients with NF-LG, small AVA, and preserved LVEF would be classified as C4 stage if they are asymptomatic and D4 if they are symptomatic; and patients with LF-LG, small AVA, and preserved LVEF would be classified as C3 stage if they are asymptomatic (Figure 1).

Clinical Management of AS: New Challenges

In stages A and B, there is no indication of AVR (Figure 1A; Table 1). In stages C2 (severe AS with LV dysfunction) and D1 (symptomatic severe AS with HG), there is a class I indication for AVR.² For these stages, transthoracic Doppler echocardiography is generally sufficient, and there is no need for multimodality imaging. For patients in stage C1 (asymptomatic severe AS with HG), the challenge is to identify those who may need early prophylactic AVR (class IIa) versus those who can be safely managed with a wait-for-symptoms strategy. Multimodality imaging can play an important role to refine risk and optimize selection of the timing of AVR in these patients (Figure 2).¹⁹ The same approach should be applied to asymptomatic patients with paradoxical LF-LG AS (HAVEC C3 stage) although there is less evidence to support prophylactic AVR in these patients. When managed medically, a close follow-up is warranted. Aortic valve intervention might be considered (IIb) in high-risk patients identified by multimodality imaging (high calcium score, low global longitudinal strain, and extensive myocardial fibrosis by cardiac magnetic resonance [CMR]).

In symptomatic patients with LF-LG AS (stages D2 and D3), there is a class IIa recommendation of AVR.² However, in the presence of LF-LG, the stenosis severity remains uncertain and multimodality imaging is required to confirm stenosis severity and decide whether relief of valve obstruction is indicated. In patients with NF-LG AS (HAVEC C4 and D4 stages), there is no specific recommendation in the guidelines

Table 1. AHA/ACC and ESC Guidelines for Surgical AVR/TAVI in AS

	ESC 2012	ACC/AHA 2014
Severe high-gradient AS (stages C1 and D1): preserved LVEF, MPG \geq 40 mmHg, and AVA $<$ 1 cm ²		
Symptoms related to severe AS	I	I
Exercise-limiting symptoms during exercise testing	I	I
Asymptomatic with blood pressure drop during exercise testing or decreased exercise tolerance (AHA/ACC)	IIa	IIa
Asymptomatic severe AS undergoing other cardiac surgery	I	I
Asymptomatic patient with very severe AS (AHA/ACC, V_{max} $>$ 5 m/s and low surgical risk; ESC, V_{max} $>$ 5.5 m/s)	IIa	IIa
Asymptomatic with calcified aortic valve+rapid stenosis progression (\geq 0.3 m/s per year; ESC) or rapid disease progression and low surgical risk (AHA/ACC)	IIa	IIb
Markedly elevated BNP values without other explanation	IIb	...
Increase of MPG with exercise \geq 20 mmHg	IIb	...
Excessive LV hypertrophy in the absence of hypertension	IIb	...
Asymptomatic severe high-gradient AS with reduced LVEF (stage C2): AVA $<$ 1 cm ² (normal or low flow)		
Asymptomatic AS with MPG $>$ 40 mmHg or V_{max} $>$ 4 m/s and LVEF $<$ 50%	I	I
Classical low-flow, low-gradient symptomatic AS (stage D2): reduced LVEF, MPG $<$ 40 mmHg, and AVA $<$ 1 cm ²		
Symptomatic patients with severe LF/LG AS with reduced LVEF and evidence of flow reserve (AHA/ACC if true severe AS)	IIa	IIa
Symptomatic patients with severe LF/LG AS and LV dysfunction without flow reserve during DSE	IIb	...
Moderate symptomatic/asymptomatic AS (stage B): MPG $<$ 40 mmHg and AVA \geq 1 cm ²		
Moderate AS (AVA between 1.0 and 1.5 cm ² or indexed AVA between 0.6 cm ² /m ² and 0.9 cm ² /m ² or MPG between 25 and 40 mmHg according to ESC or V_{max} between 3 and 3.9 m/s according to AHA/ACC undergoing other cardiac surgery)	IIa	IIa
Symptomatic moderate AS with reduced LVEF
Normal-flow, low-gradient symptomatic AS (HAVEC stage D4): preserved LVEF, MPG $<$ 40 mmHg, AVA $<$ 1 cm ² , and SVi $<$ 35 mL/m ²		
Symptomatic normal-flow, low-gradient severe AS
Paradoxical low-flow, low-gradient symptomatic AS (stage D3): preserved LVEF, MPG $<$ 40 mmHg, AVA $<$ 1 cm ² , indexed AVA $<$ 0.6 cm ² /m ² , and SVi $<$ 35 mL/m ²		
Symptomatic patients with LF/LG severe AS and preserved LVEF only after careful confirmation of AS severity	IIa	IIa

AHA/ACC indicates American Heart Association/American College of Cardiology; AS, aortic stenosis; AVA, aortic valve area; AVR, aortic valve implantation; BNP, brain natriuretic peptide; DSE, dobutamine stress echocardiography; ESC, European Society of Cardiology; LF, low flow; LG, low gradient; LVEF, left ventricular ejection fraction; MPG, mean pressure gradient; SVi, stroke volume index; TAVI, transcatheter aortic valve implantation; and V_{max} , aortic jet velocity.

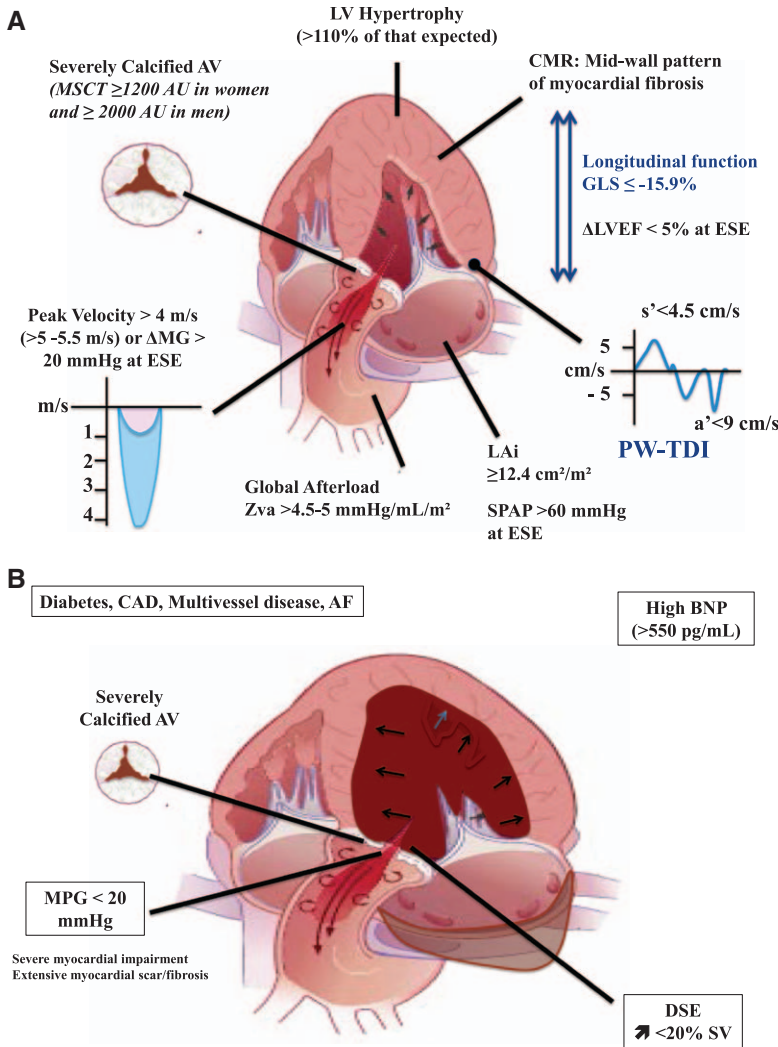


Figure 2. Risk factors predicting poor spontaneous outcome in patients with asymptomatic severe aortic stenosis (AS; stage C1; **A**) or with classical low-flow, low-gradient AS and reduced left ventricular ejection fraction (stage D3; **B**). AV indicates aortic valve; AF, atrial fibrillation; BNP, brain natriuretic peptide; CAD, coronary artery disease; CMR, cardiac magnetic resonance; Δ MG, change in mean pressure gradient; DSE, dobutamine stress echocardiography; GLS, global longitudinal strain; LAi, indexed left atrium area; LV, left ventricle; LVEF, LV ejection fraction; MPG, mean pressure gradient; MSCT, multislice computed tomography; PW-TDI, pulsed wave tissue Doppler at the mitral annulus; SPAP, systolic pulmonary artery pressure; and SV, stroke volume. Reprinted from Magne et al¹⁹ with permission of the publisher. Copyright ©2015, Elsevier.

and multimodality imaging may be helpful for individual risk stratification, adjust the frequency of the echo/clinical follow-up, and eventually recommend intervention. In patients with NF-LG AS, surgical AVR could be considered if multimodality imaging confirms that the stenosis is severe and if the patient is symptomatic (HAVEC D4 stage; Figure 1C). If the patient is asymptomatic (HAVEC C4 stage), a conservative approach should probably be recommended (Figure 1B).

Multimodality Imaging Assessment of AS Severity

Transthoracic Doppler Echocardiography

A comprehensive echocardiography report should contain information on aortic valve morphology (bicuspid versus tricuspid) and mobility, cause and severity of AS (AVA, mean gradient, and peak aortic jet velocity), and its consequences on LV function (stroke volume, LVEF, and diastolic function), left atrial pressure, and pulmonary arterial pressure (Data Supplement). The continuity equation is used to calculate the AVA. The LV outflow tract (LVOT) diameter should be systematically reported to allow accurate monitoring of stenosis progression during follow-up. The LVOT diameter should be

measured at the base of the aortic valve cusps or 1 to 5 mm below the aortic annulus using the zoomed view of the LVOT providing the largest diameter (distal LVOT diameter, relative to the direction of blood flow; Data Supplement). Recent studies suggest that the measurement of LVOT diameter >5 to 10 mm below the aortic annulus (proximal LVOT diameter, relative to the direction of flow) is less accurate and reproducible to estimate stroke volume and AVA.²⁰

Multiple echocardiographic windows and a good Doppler alignment to the flow direction are used to detect the highest aortic jet velocity. Accurate interpretation of the echocardiographic data requires reporting the level of systolic blood pressure (optimal level, <140 mmHg) and the diameter of the ascending aorta. Hypertension may contribute to increase LV afterload and decrease LV outflow, and it may, thus, interfere with the Doppler echocardiographic assessment of stenosis severity.²¹ The calculation of the valvuloarterial impedance (Z_{va}) can easily be performed as part of a routine echocardiographic examination and provides an estimate of the global (valvular+vascular) hemodynamic load.²²

Doppler echocardiography may overestimate the transvalvular pressure gradient compared with left heart catheterization in the presence of a small ascending aorta (diameter

of ascending aorta, <30 mm) because of significant pressure recovery downstream of the valve.^{22,23} Finally, the assessment of indexed LV mass and relative wall thickness is used to define the pattern of LV remodeling. Severe AS is expected to be associated with an abnormal LV remodeling pattern. If the LV mass and geometry are normal, it is unlikely that the patient has severe AS.

Transesophageal Echocardiography

Transesophageal echocardiography has the advantage of a higher spatial resolution and is useful to grade AS severity in patients with poor transthoracic acoustic windows in whom the measurement of the LVOT diameter and anatomic or geometric AVA by planimetry is not feasible or inaccurate. The measurement of effective AVA is also possible using the continuity equation provided that a good Doppler alignment to the flow direction is achieved from the transgastric view. It is important to underline that anatomic and effective AVAs are not equivalent from a physiological standpoint.²⁴ Indeed, the effective AVA is often smaller than the anatomic AVA because of the flow contraction that occurs between the anatomic stenosis and the vena contracta of the transvalvular flow jet. So, when the anatomic AVA is <1 cm² and the valve is severely calcified, the stenosis is often considered severe. In the case of uncertainties about AS severity using the planimetry or significant discordance with the effective AVA, other approaches should be used. Transesophageal echocardiography is also particularly useful before TAVI to evaluate the aortic annulus and the ascending aorta.

Three-Dimensional Echocardiography

Three-dimensional (3D) echocardiography can help in assessing AS severity. When compared with the transesophageal approach, 3D transthoracic echocardiography has lower spatial resolution and its quality depends on the acoustic windows. However, 3D transesophageal echocardiography has a satisfactory spatial resolution and may be useful to complement a nonconclusive 2D echo study. The AS severity can be estimated as follows: (1) guided 2D planimetry of the leaflet tips using a 3D data set that is cropped to obtain anatomic orifice area; (2) optimized computation of the effective orifice area using the continuity equation and the planimetry of the cross-sectional area of the LVOT without any geometric assumption from a 3D data set; (3) estimation of the 3D-derived stroke volume in the continuity equation using 3D LV end-diastolic and end-systolic volumes (providing that there is no significant mitral regurgitation, preferentially from a 3D transthoracic data set); and (4) 3D stroke volume measured by real-time volume color Doppler across the LVOT. Estimation of the LVOT area by 2D echocardiography is based on the measurement of the sagittal diameter in the parasternal long-axis view, and it assumes that the LVOT has a circular cross-section, which is often not the case (Data Supplement). When the shape of the LVOT is elliptical, the utilization of the sagittal diameter, which is generally smaller than the coronal diameter, may result in underestimation of LVOT area and, thus, of stroke volume and effective AVA. 3D transesophageal echocardiography proved also superior to 2D echocardiography to measure aortic annulus size (minimum and maximum

diameters and annulus perimeter) and shape before TAVI.²⁵ Results obtained by 3D transesophageal echocardiography are similar to MSCT or CMR-derived diameters and can be used for selection of transcatheter valve size to reduce the risk of paravalvular regurgitation.²⁵ 3D transesophageal echocardiography could be particularly useful to size the prosthesis dimension before TAVI in patients with severe chronic kidney disease to avoid the use of contrast agents.

Exercise Testing and Stress Echocardiography

Stress echocardiography is useful to confirm stenosis severity in patients with LF-LG AS and to identify patients at high risk of cardiovascular events in the case of asymptomatic severe AS (Table 2). Protocols, guide for referral, procedure, and reporting for valve stress echocardiography have been recently discussed.²⁶ In asymptomatic severe AS (C1 stage), exercise is the optimal stressor and is a class IIa indication in the ACC/AHA guidelines, whereas it is strongly advocated in the European Society of Cardiology recommendations.^{2,27} Exercise testing or exercise stress echocardiography using a modified Bruce protocol is useful to unmask symptoms in patients with severe AS who claim to be asymptomatic (Table 2). Indeed, about one third of patients with apparently no symptoms on medical questionnaire have exercise-limiting symptoms on exercise testing, and these patients have worse outcome.^{28–30} Beyond symptom development, a drop in systolic blood pressure by >20 mmHg is also predictive of outcome.²⁸ Although a negative exercise test is reassuring in younger patients, the predictive value of the test is improved when combined with echocardiographic assessment of LV function,³¹ transvalvular pressure gradients,^{28,32} and pulmonary arterial pressure.³³ An exercise increase in mean gradient ≥ 18 to 20 mmHg,^{28,32} the absence of contractile reserve (no or <5% exercise increase in LVEF),³⁴ or the presence of exercise pulmonary hypertension (>60 mmHg)³³ are all strong predictors of cardiac events.

Low-dose (≤ 20 $\mu\text{g}/\text{kg}$ per minute) dobutamine echocardiography is recommended (class IIa) in patients with suspected classical LF-LG AS and reduced LVEF² and could be useful in patients with paradoxical LF-LG AS in the absence of potential contraindications (Table 2).³⁵ According to ACC/AHA guidelines, a true severe AS is identified when the mean gradient is ≥ 40 mmHg and AVA is ≤ 1.0 cm² at any dobutamine stage.² This criterion is highly sensitive but lacks specificity, and it can only be achieved in patients who have significant LV flow reserve (ie, increase in stroke volume >20%). In patients with no flow reserve, the stenosis severity generally remains undermined with dobutamine stress echocardiography because the increase in flow is not sufficient to induce any change in AVA or gradient. Furthermore, in the frequent situation of patients with some degree of flow reserve but with peak stress flow rate remaining below normal at peak dose of dobutamine, the AVA (<1.0 cm²)–gradient (<40 mmHg) discordance that exists at rest often persists during the test. When the effective AVA increases (European Society of Cardiology definition: change, >0.3 cm²; effective AVA, >1.2 cm²; AHA/ACC definition AVA, >1 cm²) but the mean gradient remains <40 mmHg, pseudosevere AS (LV systolic dysfunction not related to AS) is considered to be present.^{2,27} When the stroke volume increase is <20% and no significant changes in mean

Table 2. Recommendations of the Heart Valve Clinic International Database (HAVEC) Group for the Indication of Multimodality Imaging in the Clinical Management of AS

Disease Stage	Definition of Disease Stage	Echo	DSE	ESE	CMR	MSCT	PET
A	At risk of developing AS	I	III	III	III	III	III
B	Progressive mild-to-moderate AS	I
C1	Asymptomatic NF/LF high-gradient severe AS	I	III	I (to assess symptoms and valve hemodynamics)	IIb (to assess myocardial fibrosis)	IIa (for its prognostic implications)	IIb (for its prognostic implications)
C2	Asymptomatic NF/LF high-gradient severe AS with LVEF<50%	I
C3*	Asymptomatic LF-LG AS with preserved LVEF	I	IIb (to distinguish between severe and pseudosevere AS)	IIa (to assess symptoms and valve hemodynamics and to distinguish between severe and pseudosevere AS)	IIb (to assess myocardial fibrosis)	IIa (for its prognostic implications and to distinguish severe from pseudosevere AS)	...
C4*	Asymptomatic NF/LG AS with preserved LVEF	I	IIb (to distinguish between severe and pseudosevere AS)	IIa (to assess symptoms and valve hemodynamics and to distinguish between severe and pseudosevere AS)	IIb (to assess myocardial fibrosis)	IIa (for its prognostic implications and to help distinguish severe AS from moderate AS)	...
D1	Symptomatic NF/LF high-gradient severe AS	I	...	III
D2	Symptomatic LF-LG AS with reduced LVEF	I	I (to distinguish between severe and pseudosevere AS and evaluate contractile reserve)	III	IIa (to assess myocardial fibrosis)	IIa (to help distinction between severe and pseudosevere AS in patients with no flow reserve)	...
D3	Symptomatic LF-LG AS with preserved LVEF	I	IIa (to help distinction between severe and pseudosevere AS)	III	IIa (to assess myocardial fibrosis)	I (to help distinction between severe and pseudosevere AS)	...
D4*	Symptomatic NF/LG severe AS with preserved LVEF	I	IIa (to help distinction between severe and pseudosevere AS)	III	IIb (to assess myocardial fibrosis)	I (to help distinction between severe and pseudosevere AS)	...

—: not relevant. AS indicates aortic stenosis; CMR, cardiac magnetic resonance; DSE, dobutamine stress echocardiography; echo, echocardiography; ESE, exercise stress echocardiography; I, indicated; IIa, should be considered; IIb, may be considered; III, not recommended; LF, low flow; LG, low gradient; LVEF, left ventricular ejection fraction; MSCT, multislice computed tomography; NF, normal flow; and PET, positron emission tomography.

*Additional HAVEC disease stages.

gradient and AVA are observed, AS severity remains indeterminate. In these patients, we recommend to calculate the projected AVA at NF rate (250 mL/s) to reconcile this discordance.³⁶ A projected AVA of ≤ 1.0 cm² or indexed projected AVA of ≤ 0.55 cm²/m² confirms the presence of true severe AS and predicts the risk of cardiac events.³⁶ However, it should be kept in mind that data on the cutoff values of stroke volume increase during the dobutamine test come from small studies on a limited number of patients and should be interpreted cautiously. In practice, a patient who does not have >20% increase in stroke volume but has a significant increase in gradient (mean pressure gradient >40 mmHg), nonparalleled by an increase in AVA (AVA <1.0 cm²), should be considered as having true severe AS (stage D2).

Cardiac MSCT

Cardiac MSCT allows visualization of the aortic valve and cardiac chambers throughout the cardiac cycle and provides information about the aortic valve morphology (ie, bicuspid

versus tricuspid valve), LV dimensions, coronary artery anatomy, coronary ostia localization, leaflet length, aortic annulus size, and aortic root morphology and dimensions. MSCT has a high spatial resolution and is particularly useful in patients with poor transthoracic acoustic windows or contraindication to transesophageal echocardiography. Using 3-multiplanar reformations, from left sagittal oblique and left coronal oblique views, a cross-sectional view of the aortic valve can be generated for accurate measurement of anatomic AVA.³⁷ MSCT allows accurate measurement of aortic annulus diameters (sagittal+coronal+mean values), area, and perimeter, which are key parameters for the selection of the prosthesis size before TAVI.³⁸ Protruding annular calcium (into the lumen) with >4 mm in size, severe aortic annular calcification (high calcium score), and undersizing of the transcatheter valve relative to the annulus size are the main predictors of postprocedural paravalvular regurgitation.³⁹

Typically, the annulus size is larger with MSCT, 3D echocardiography, or CMR than when measured with either 2D

Table 3. Recommendations of the Heart Valve Clinic International Database (HAVEC) Group for the Timing of Follow-Up of Multimodality Imaging in the Clinical Management of AS

Disease Stage	Echo	DSE	ESE	CMR	MSCT	PET
A	5 y
B	2–3 y
C1	6 mo	...	1 y	2 y
C2	3 mo
C3*	6 mo	...	1 y	2 y
C4*	6 mo	...	1 yr	2 yr
D1	3 mo
D2	3 mo
D3	3 mo
D4*	6 mo

ESE may be repeated each year in asymptomatic patients with severe AS to confirm the absence of symptoms and search for markers of poor prognosis, such as a significant increase in mean pressure gradient. CMR may be used each 2 years in asymptomatic patients to test for the development of myocardial fibrosis, an important prognostic factor in severe AS. AS indicates aortic stenosis; CMR, cardiac magnetic resonance; DSE, dobutamine stress echocardiography; ESE, exercise stress echocardiography; MSCT, multislice computed tomography; and PET, positron emission tomography.

transthoracic or transesophageal echocardiography (absolute difference, $\leq 1.52 \pm 1.1$ mm).^{37,38}

Aortic valve calcium scoring (Data Supplement) can also help discriminate severe from nonsevere AS in patients with discordant echocardiographic findings and particularly in patients with LF-LG AS and those with NF-LG AS who are characterized by a small AVA consistent with severe AS but a LG consistent with nonsevere AS.¹⁶ Different cutoff values of aortic valve calcium score should be used in men (≥ 2000 AU or ≥ 480 AU/cm²) versus women (≥ 1200 AU or ≥ 290 AU/cm²) to identify severe AS.^{16,40} A potential explanation for this intriguing finding is that women have relatively more valvular fibrosis than men. Fibrosis may also contribute to valvular stenosis, but as opposed to calcification, it is not detected by MSCT. Aortic valve calcium scoring by MSCT is particularly helpful when dobutamine stress echocardiography is not feasible or not conclusive, which is often the case in patients with classical LF-LG AS (D2 stage) and no flow reserve, in patients with paradoxical LF-LG (D3 stage), and in patients with NF-LG AS (HAVEC D4 stage; Figure 1). This imaging technique might also be useful to corroborate stenosis severity in asymptomatic patients with preserved LVEF, LG, and LF or NF (HAVEC C3 or C4 stages). It may be used in such cases depending on the local expertise and availability.

The aortic valve calcium load assessed by MSCT is also a powerful predictor of rapid stenosis progression and of cardiac events in patients with AS; it could be used to enhance individualized risk stratification in C1 stage AS.⁴¹

Cardiac Magnetic Resonance

CMR has emerged as an alternative noninvasive modality without ionizing radiation and is indicated as a complementary imaging when transthoracic or transesophageal

echocardiography is nondiagnostic (Table 2). CMR provides images of valve anatomy and motion and allows quantitative evaluation of AS and LV function. CMR planimetry for the assessment of anatomic AVA is possible but less than optimal in patients with calcific AS, especially when a nonplanar orifice exists.⁴² Other standard measures of stenosis severity can be obtained with CMR: peak anterograde velocity, pressure gradient, and effective AVA. Velocities and gradients are often underestimated with CMR when compared with Doppler echocardiography.⁴³ CMR also has the ability to characterize the pattern and volume of myocardial fibrosis (focal versus diffuse; subendocardial versus midwall)^{44,45} (Data Supplement). CMR late-gadolinium enhancement provides an estimation of the degree of focal fibrosis, which corresponds to replacement fibrosis most often related to ischemic heart disease or severe pressure-overload cardiomyopathies, such as in AS. In AS, myocardial fibrosis is one of the major processes driving the decompensation of the LV and the progression toward symptoms, heart failure, and adverse events. T1 mapping of extracellular volume provides an estimate of diffuse fibrosis, which consists, in large part, of reactive interstitial fibrosis and is more specific to pressure-overload cardiomyopathies. Some studies have shown that the presence of myocardial fibrosis in the midwall layer is more specific to AS rather than to ischemic heart disease and is a more powerful predictor of cardiac events.⁴⁴

Positron Emission Tomography/CT

Positron emission tomography (PET)/CT is a feasible and reproducible method that combines the anatomic information from CT with the functional information derived from PET. ¹⁸F-sodium fluoride (¹⁸F-NaF) is a PET tracer that exchanges with hydroxyl groups on hydroxyapatite crystals, a key structural component of both bone and vascular calcification. A recent study has shown that ¹⁸F-NaF, with high specificity and sensitivity, binds to calcium deposits in human atherosclerotic vascular tissue and is a useful tool to assess areas of vascular microcalcification noninvasively.⁴⁶ Increased ¹⁸F-NaF uptake has been also described in AS, where it is believed to identify areas of increased calcification activity.⁴⁷ The magnitude of increased ¹⁸F-NaF activity correlates well with disease severity.⁴⁸ In a recent study, PET/CT had the ability to predict disease progression (both as assessed by echocardiography and MSCT) and the development of adverse clinical events.⁴⁹ ¹⁸F-fluorodeoxyglucose is another PET tracer whose uptake has been linked to macrophage burden in the carotid arteries and which can be used to measure metabolic activity in the aortic valve as a surrogate for inflammation.⁴⁸ The uptake of ¹⁸F-fluorodeoxyglucose, which reflects valvular inflammation, is higher in patients with mild or moderate AS compared with controls but decreased in the severe AS stage. In contrast, the uptake in ¹⁸F-NaF increases progressively with each stage of AS severity and is maximal in severe AS (Data Supplement). Of note, the increase in ¹⁸F-NaF is also higher in AS than in aortic atheroma, whereas the opposite situation is seen for ¹⁸F-fluorodeoxyglucose, indicating that inflammation seems to have a lesser role in advanced AS and vice versa. Active mineralization may be predominant in the pathogenesis of

the disease. PET/CT, ¹⁸F-NaF, as a marker of calcification activity, is a good predictor of aortic valve calcium score progression by MSCT at 1 year.⁴⁷

Role of Multimodality Imaging for Patient Follow-Up

AS is characterized by a long asymptomatic phase, lasting several decades, during which outflow obstruction develops progressively. Generally, prognosis is considered fair in mild-to-moderate stages (stage A and B), and risks of symptoms and death are expected to correlate with the hemodynamic degree of AS severity.⁵⁰ However, because of wide variability in clinical (risk of sudden death varying from <1% to 5%)^{30,33,51} and hemodynamic progression (event-free survival at 5 years varying from 30% to 80% in severe AS),^{50,51} appropriate monitoring of disease status and individual risk stratification is warranted. Follow-up examinations are suggested to be obtained in a Heart Valve Center of Excellence,^{2,52} whenever possible (Table 3). Monitoring should look for any change in symptomatic status, in exercise tolerance ideally with an exercise test, in LV function, or in disease severity.

Specific Clinical Scenarios

Asymptomatic Severe AS—Stage C1

In this category of patients, a stepwise approach is advocated: (1) identification of patients with very severe stenosis (peak velocity, ≥ 5.0 m/s) and (2) determination of whether

the patient is truly asymptomatic and has a normal blood pressure response during exercise (Figure 3A). As a second step, further imaging-based risk assessment should be considered and include the assessment of (1) risk factors of rapid stenosis progression: severe aortic valve calcification on echo or MSCT, marked increase in mean pressure gradient (>18 – 20 mmHg) during exercise echo; and (2) markers of more advanced LV dysfunction: LF (indexed LV stroke volume <35 mL/m²),⁵³ high Z_{va} (>4.5 – 5 mmHg/mL/m²),⁵⁴ decreased longitudinal LV function (global strain $<16\%$),⁵⁴ enlarged left atrium (indexed left atrial area, ≥ 12.2 cm²/m²),⁵⁴ and high brain natriuretic peptide level (ratio-measured brain natriuretic peptide/normal reference brain natriuretic peptide for age and sex, >2).⁵⁵ CMR is not yet routinely indicated for risk stratification. However, this imaging modality may be useful to detect and quantitate myocardial fibrosis. When a watchful strategy is selected for a patient in C1 stage, the presence of any of the above-mentioned parameters underlines the need for closer follow-up (every 3 months).

Classical LF-LG AS—Stage D2

Because the resting echocardiographic examination in these patients is unable to ascertain the stenosis severity, a multimodality/imaging approach is mandatory (Figure 3B). Dobutamine stress echocardiography is the first-line recommended

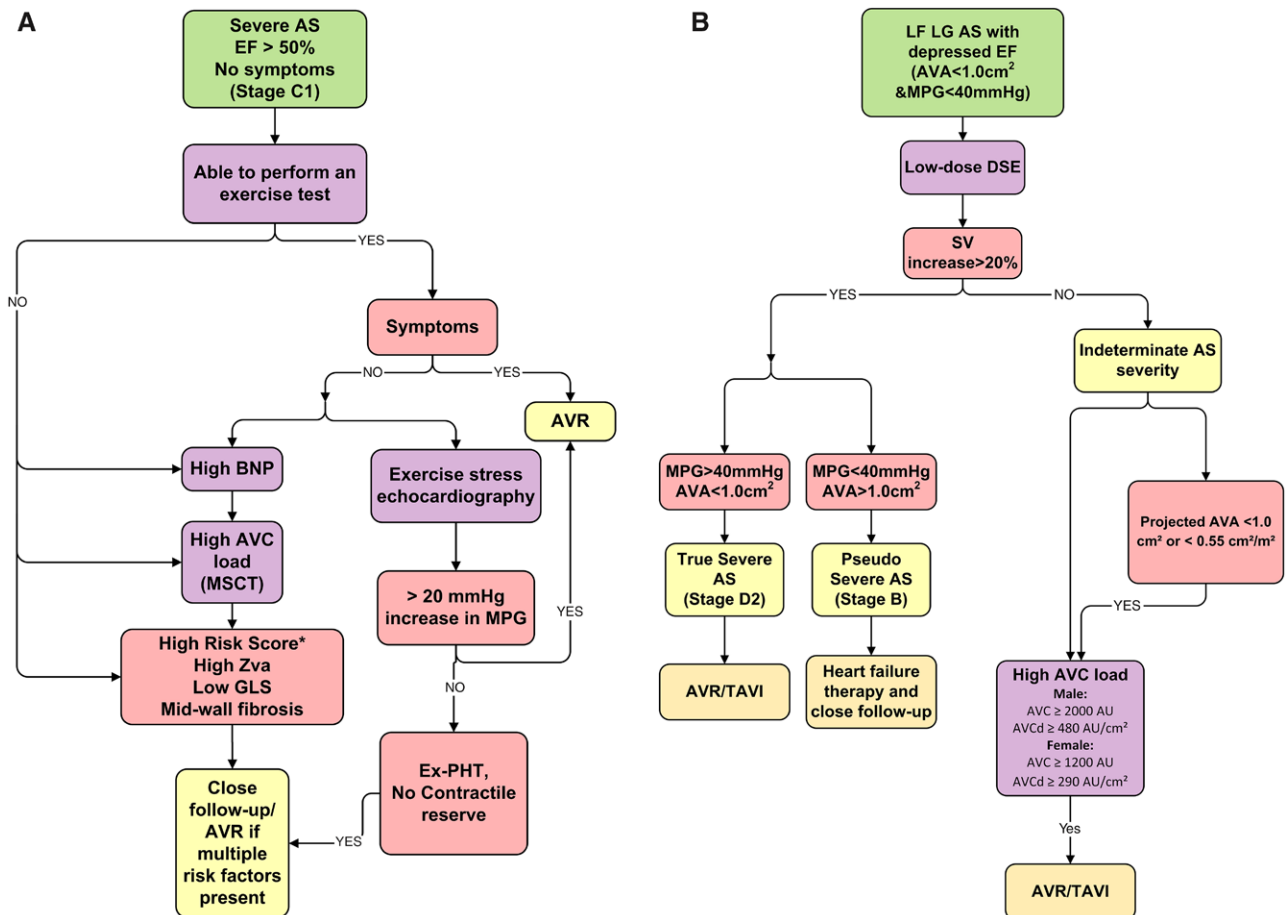


Figure 3. (Continued).

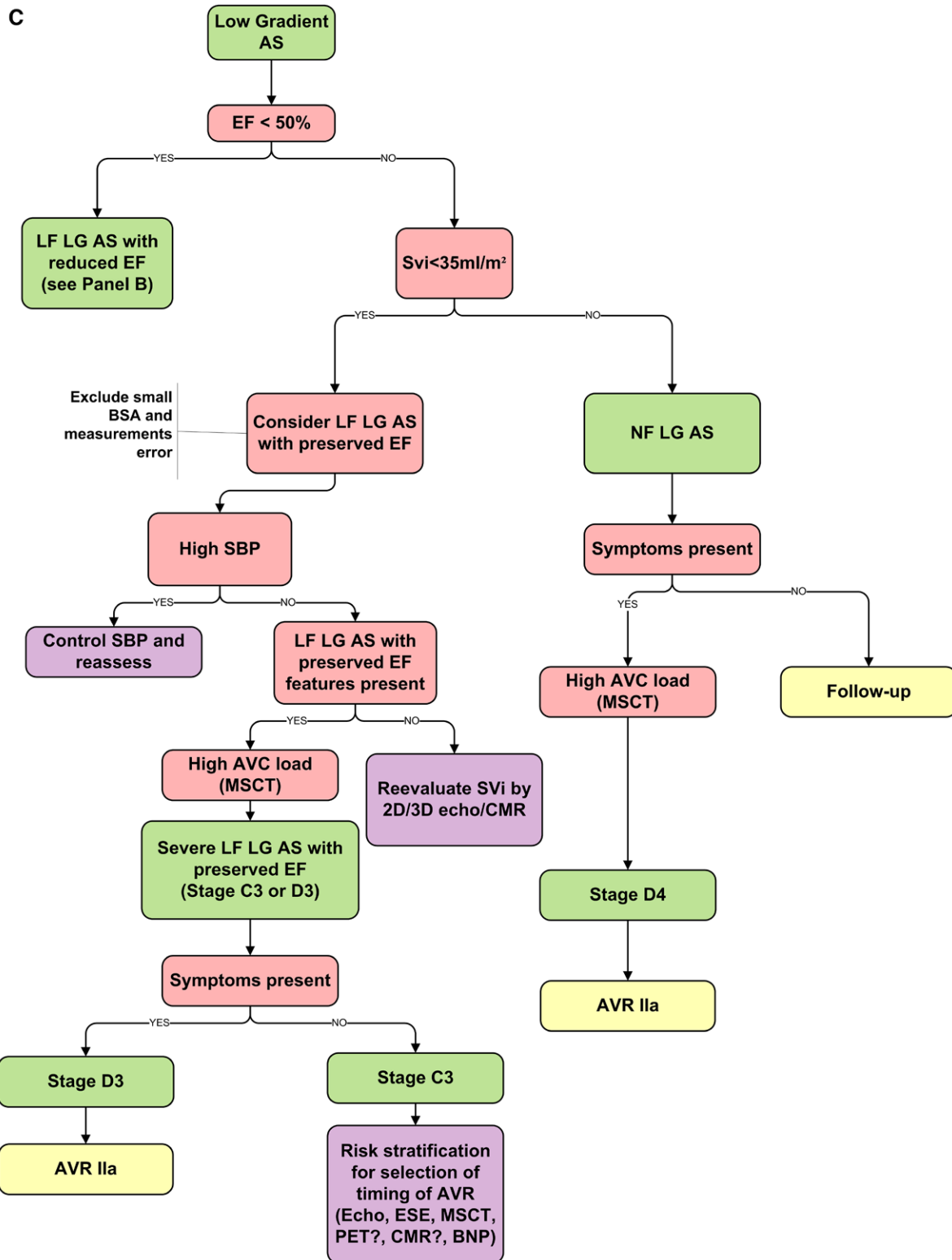


Figure 3 Continued. Algorithm proposed for individual risk stratification in severe asymptomatic aortic stenosis (AS; **A**), in low-flow (LF), low-gradient (LG) AS and reduced left ventricular ejection fraction (EF; **B**), and in LF, LG AS and preserved left ventricular EF (**C**). AVC indicates aortic valve calcification; AVR, aortic valve replacement; BNP, brain natriuretic peptide; BSA, body surface area; CMR, cardiac magnetic resonance; DSE, dobutamine stress echocardiography; ESE, exercise stress echocardiography; GLS, global longitudinal strain; LF, low flow; LG, low gradient; MPG, mean pressure gradient; MSCT, multislice computed tomography; NF, normal flow; PET, positron emission tomography; PHT, pulmonary hypertension; SBP, systolic blood pressure; SV, stroke volume; and TAVI, transcatheter aortic valve implantation.

test to confirm stenosis severity and assess the presence of flow reserve. The absence of flow reserve should not preclude surgical AVR although TAVI may be a valuable alternative in

such patients. In patients with indeterminate AS severity at dobutamine stress echocardiography (even after calculation of projected AVA), CT calcium scoring by MSCT can help

Table 4. Key Points From the Heart Valve Clinic International Database (HAVEC) Group on the Imaging Assessment of Patients With Severe AS

- (1) Transthoracic Doppler echocardiography is generally sufficient to make an accurate diagnosis of severe AS and guide decision making in most patients. However, a multimodality imaging approach is necessary in symptomatic patients with LF-LG AS (D2 and D3 stages) and potentially useful in patients with asymptomatic severe AS (C1 stage), asymptomatic LF/NF-LG AS, and preserved LVEF (HAVEC C3 and C4 stages), or symptomatic NF-LG AS (HAVEC D4 stage).
- (2) Transthoracic Doppler echocardiography is the first imaging approach to evaluate AS severity and is sufficient for an accurate diagnosis and treatment decision in stages A, B, and C2. In practice, we recommend to measure the LVOT diameter at the base of the aortic valve cusps or 1 to 5 mm below. The LVOT diameter and the highest aortic peak velocity using multiple windows should be reported. When both blood pressure and Z_{va} are elevated (>4.5–5 mm Hg/mL per m^2), antihypertensive therapy should be initiated/optimized and the echocardiographic examination should be repeated after normalization of blood pressures. The pattern of LV remodeling should be described.
- (3) TEE is recommended in the case of nondiagnostic TTE because of poor acoustic window or inconclusive TTE or to evaluate the aortic annulus/ascending aorta before TAVI.
- (4) 3D echocardiography should be considered in patients who have paradoxical LF-LG AS at 2D echocardiography (stages C3 HAVEC and D3) to corroborate the measurements of stroke volume and effective AVA. This imaging modality may also be used in place of or in complement of MSCT or CMR to measure the aortic annulus area/perimeter and select the most appropriate valve size in patients undergoing TAVI.
- (5) Exercise testing is the first test to identify truly asymptomatic patients. Exercise stress echocardiography provides incremental information for risk stratification in C1 stage patients and could be useful (1) to determine the relevance and optimal timing of early elective AVR and (2) to assess the potential need for AVR before high-risk noncardiac surgery. This imaging technique may also be useful in patients with C3 and C4 HAVEC stages to assess stenosis severity and enhance risk stratification. Dobutamine stress echocardiography should be considered in stages D2 and HAVEC C3 to differentiate true severe from pseudosevere AS and to evaluate the operative risk and inform the selection process between surgical AVR and TAVI in stage D2. When ambiguous dobutamine stress results are obtained (insufficient increase in stroke volume), we recommend computing the projected AVA at normal flow rate.
- (6) Aortic valve calcium scoring by MSCT should be considered in (1) patients with a small AVA and LG AS (D2, D3, D4, C3, and C4 stages) to corroborate stenosis severity when dobutamine stress echo is not feasible or not conclusive and (2) patients with asymptomatic severe AS to identify those at higher risk for rapid disease progression who may benefit from earlier intervention (C1 stage). MSCT with contrast injection should be performed in patients with planned TAVI procedure to measure aortic annulus/root anatomy/dimensions.
- (7) Measurement of AVA by CMR has little role in patients with LF-LG AS (D2, D3, and C3 stages) to corroborate stenosis severity unless it is associated with the dobutamine stress test, which increases the complexity and duration of the procedure. The localization and quantification of myocardial fibrosis by CMR may potentially be useful to optimize risk stratification and timing of AVR in asymptomatic patients with severe AS (C1 and HAVEC C3 and C4 stages). Indeed, patients with more advanced fibrosis might be considered for early intervention to prevent the development of potentially irreversible myocardial dysfunction and symptoms and to enhance risk stratification and guide the selection of the type of intervention in patients with LF-LG AS (D2 and D3 stages). Patients with extensive myocardial fibrosis are at higher risk of operative mortality and lack of functional improvement after surgical AVR.

(Continued)

Table 4. Continued

- (8) PET-CT with ^{18}F -NaF may be useful in asymptomatic patients with severe AS (C1 stage) to identify the patients who are at higher risk of rapid stenosis progression and who may, thus, benefit from an earlier intervention. However, further studies are needed to demonstrate the incremental value of PET-CT ^{18}F -NaF over the simple aortic valve calcium scoring by MSCT to predict stenosis progression rate and cardiac events.

AS indicates aortic stenosis; AVA, aortic valve area; AVR, aortic valve implantation; CMR, cardiac magnetic resonance; CT, computed tomography; LF, low flow; LG, low gradient; LVEF, left ventricular ejection fraction; LVOT, left ventricular outflow tract; MSCT, multislice computed tomography; NF, normal flow; PET, positron emission tomography; TAVI, transcatheter aortic valve implantation; and TEE, transesophageal echocardiography.

differentiate severe from moderate stenosis.¹⁶ CMR identification of extensive necrosis/fibrosis may also orientate toward TAVI because of its lower risk of cardiodepressive effects when compared with surgical AVR. Of note, European Society of Cardiology–European Association for Cardio-Thoracic Surgery guidelines consider an LVEF of <20% as a relative contraindication for TAVI.²⁷

Symptomatic Paradoxical LF-LG AS With Preserved LVEF—Stage D3

As for classical LF-LG AS—stage D2, confirmation of AS severity in symptomatic patients with paradoxical LF-LG AS requires multimodality/imaging approaches (Data Supplement). The recommended stepwise algorithm is depicted in Figure 3C: (1) rule out measurement errors; (2) calculate AVA indexed to body surface area to rule out the situation of small AVA in a small patient, which would correspond to a moderate AS; (3) identify the causal factors and features of LF-LG AS (pronounced concentric LV remodeling, small LV cavity, reduced longitudinal function, moderate-to-severe LV diastolic dysfunction, mitral stenosis, mitral regurgitation, tricuspid regurgitation, and atrial fibrillation); (4) redo the echo measurements after blood pressure control and confirm the LF state by 2D/3D echo volumetric methods or CMR; and (4) differentiate true versus pseudosevere stenosis with the use of stress echocardiography if feasible or MSCT (high AVC).^{16,35} Some recent studies suggest that TAVI may be preferable to surgical AVR in patients with paradoxical LF-LG AS because these patients are at higher risk of operative mortality and prosthesis–patient mismatch with surgical AVR.^{7,56} In these patients, it may also be useful to assess the extent of myocardial fibrosis by CMR to enhance risk stratification.^{10,44}

Symptomatic NF-LG AS With Preserved LVEF—Stage D4

Patients with NF-LG AS and preserved LVEF (HAVEC stage D4) are generally believed to be at less advanced stage of the disease than patients in LF-LG AS (stages D2 and D3). However, recent studies suggest that a substantial proportion may nonetheless have severe AS despite the LG and NF pattern. Hence, in symptomatic patients with NF-LG AS, it is important to corroborate stenosis severity preferably with the use of MSCT aortic valve calcium scoring. The same cut points as those used for LF-LG AS can be applied to these

patients. If MSCT supports the presence of severe stenosis in such patients, AVR may be considered (HAVEC group recommendation).

Future Research Directions

Although imaging plays a major role in the management of patients with AS, there is a need for large-scale registries and studies to strengthen its clinical value. This is one of the major goals of the HAVEC group. Imaging is still poorly implemented in the individual risk stratification of patients with AS. Although more recent scoring systems have included some imaging data, effort should be made to identify new imaging parameters that could be added to modern risk calculators. The choice between surgical AVR versus TAVI is currently mainly based on clinical risk assessment and evaluation of the heart team. The additional value of imaging in the decision-making process is clear but still limited to the sizing of the aortic annulus and root and the assessment of the peripheral arterial tree. Whether the CMR detection of myocardial fibrosis should be systematically added to the imaging evaluation work-up is unknown. Reversibility of myocardial fibrosis and associated dysfunction after surgical AVR or TAVI most likely depends on the type (interstitial versus replacement) and extent (mild versus severe) of fibrosis. Data on the role of CMR for monitoring the progression of fibrosis and the prognostic effect of diffuse fibrosis by T1 mapping are also lacking. Progression of AS is substantially unpredictable and cannot be mitigated by current medical treatments. However, new generations of drugs are under development, which may slow down or stop the fibrocalcific process. PET/CT, by evaluating local inflammatory processes taking place in the valve leaflets, might be used to evaluate the effects of these agents on progression of AS.

Conclusions

Grading AS severity and ensuing therapeutic decision remains challenging especially in the context of LF state. Multimodality/multiparametric imaging is important for disease staging, risk stratification, and therapeutic decision making (Table 4). Imaging parameters should be interpreted in conjunction with the clinical findings, the circulating biomarkers, and the symptomatic status. Repeated evaluation is warranted over time for adequate monitoring to assess the rate of progression of stenosis severity and any change in LV function. New imaging targeting inflammation, calcifications, or myocardial fibrosis may pave new ways for tailored medical strategy.

Acknowledgments

The HAVEC group is made of volunteers who have put together a collection of prospectively collected data on valvular heart disease.

Disclosures

None.

References

- Osnabrugge RL, Mylotte D, Head SJ, Van Mieghem NM, Nkomo VT, LeReun CM, Bogers AJ, Piazza N, Kappetein AP. Aortic stenosis in the elderly: disease prevalence and number of candidates for transcatheter aortic valve replacement: a meta-analysis and modeling study. *J Am Coll Cardiol*. 2013;62:1002–1012. doi: 10.1016/j.jacc.2013.05.015.
- Nishimura RA, Otto CM, Bonow RO, Carabello BA, Erwin JP 3rd, Guyton RA, O’Gara PT, Ruiz CE, Skubas NJ, Sorajja P, Sundt TM 3rd, Thomas JD; American College of Cardiology/American Heart Association Task Force on Practice Guidelines. 2014 AHA/ACC guideline for the management of patients with valvular heart disease: executive summary: a report of the American College of Cardiology/American Heart Association Task Force on Practice Guidelines. *J Am Coll Cardiol*. 2014;63:2438–2488. doi: 10.1016/j.jacc.2014.02.537.
- Dumesnil JG, Pibarot P, Carabello B. Paradoxical low flow and/or low gradient severe aortic stenosis despite preserved left ventricular ejection fraction: implications for diagnosis and treatment. *Eur Heart J*. 2010;31:281–289. doi: 10.1093/eurheartj/ehp361.
- Lancellotti P, Magne J, Donal E, Davin L, O’Connor K, Rosca M, Szymanski C, Cosyns B, Piérard LA. Clinical outcome in asymptomatic severe aortic stenosis: insights from the new proposed aortic stenosis grading classification. *J Am Coll Cardiol*. 2012;59:235–243. doi: 10.1016/j.jacc.2011.08.072.
- Monin JL, Quéré JP, Monchi M, Petit H, Baleynaud S, Chauvel C, Pop C, Ohlmann P, Lelguen C, Dehant P, Tribouilloy C, Guéret P. Low-gradient aortic stenosis: operative risk stratification and predictors for long-term outcome: a multicenter study using dobutamine stress hemodynamics. *Circulation*. 2003;108:319–324. doi: 10.1161/01.CIR.0000079171.43055.46.
- Tribouilloy C, Lévy F, Rusinaru D, Guéret P, Petit-Eisenmann H, Baleynaud S, Jobic Y, Adams C, Lelong B, Pasquet A, Chauvel C, Metz D, Quéré JP, Monin JL. Outcome after aortic valve replacement for low-flow/low-gradient aortic stenosis without contractile reserve on dobutamine stress echocardiography. *J Am Coll Cardiol*. 2009;53:1865–1873. doi: 10.1016/j.jacc.2009.02.026.
- Herrmann HC, Pibarot P, Hueter I, Gertz ZM, Stewart WJ, Kapadia S, Tuzcu EM, Babaliaros V, Thourani V, Szeto WY, Bavaria JE, Kodali S, Hahn RT, Williams M, Miller DC, Douglas PS, Leon MB. Predictors of mortality and outcomes of therapy in low-flow severe aortic stenosis: a Placement of Aortic Transcatheter Valves (PARTNER) trial analysis. *Circulation*. 2013;127:2316–2326. doi: 10.1161/CIRCULATIONAHA.112.001290.
- Hachicha Z, Dumesnil JG, Bogaty P, Pibarot P. Paradoxical low-flow, low-gradient severe aortic stenosis despite preserved ejection fraction is associated with higher afterload and reduced survival. *Circulation*. 2007;115:2856–2864. doi: 10.1161/CIRCULATIONAHA.106.668681.
- Le Ven F, Freeman M, Webb J, Clavel MA, Wheeler M, Dumont É, Thompson C, De Larocheillère R, Moss R, Doyle D, Ribeiro HB, Urena M, Nombela-Franco L, Rodés-Cabau J, Pibarot P. Impact of low flow on the outcome of high-risk patients undergoing transcatheter aortic valve replacement. *J Am Coll Cardiol*. 2013;62:782–788. doi: 10.1016/j.jacc.2013.05.044.
- Herrmann S, Störk S, Niemann M, Lange V, Strotmann JM, Frantz S, Beer M, Gattenlöhner S, Voelker W, Ertl G, Weidemann F. Low-gradient aortic valve stenosis myocardial fibrosis and its influence on function and outcome. *J Am Coll Cardiol*. 2011;58:402–412. doi: 10.1016/j.jacc.2011.02.059.
- Maes F, Boulif J, Piérard S, de Meester C, Melchior J, Gerber B, Vancraeynest D, Pouleur AC, Lazam S, Pasquet A, Vanoverschelde JL. Natural history of paradoxical low-gradient severe aortic stenosis. *Circ Cardiovasc Imaging*. 2014;7:714–722. doi: 10.1161/CIRCIMAGING.113.001695.
- Dahl JS, Eleid MF, Pislaru SV, Scott CG, Connolly HM, Pellikka PA. Development of paradoxical low-flow, low-gradient severe aortic stenosis. *Heart*. 2015;101:1015–1023. doi: 10.1136/heartjnl-2014-306838.
- Mehrotra P, Jansen K, Flynn AW, Tan TC, Elmariah S, Picard MH, Hung J. Differential left ventricular remodelling and longitudinal function distinguishes low flow from normal-flow preserved ejection fraction low-gradient severe aortic stenosis. *Eur Heart J*. 2013;34:1906–1914. doi: 10.1093/eurheartj/ehp094.
- Clavel MA, Dumesnil JG, Capoulade R, Mathieu P, Sénéchal M, Pibarot P. Outcome of patients with aortic stenosis, small valve area, and low-flow, low-gradient despite preserved left ventricular ejection fraction. *J Am Coll Cardiol*. 2012;60:1259–1267. doi: 10.1016/j.jacc.2011.12.054.
- Minnors J, Allgeier M, Gohlke-Baerwolf C, Kienzle RP, Neumann FJ, Jander N. Inconsistent grading of aortic valve stenosis by current guidelines: haemodynamic studies in patients with apparently normal left ventricular function. *Heart*. 2010;96:1463–1468. doi: 10.1136/hrt.2009.181982.
- Clavel MA, Messika-Zeitoun D, Pibarot P, Aggarwal SR, Malouf J, Araoz PA, Michelena HI, Cuff C, Larose E, Capoulade R, Vahanian A, Enriquez-Sarano M. The complex nature of discordant severe calcified

- aortic valve disease grading: new insights from combined Doppler echocardiographic and computed tomographic study. *J Am Coll Cardiol*. 2013;62:2329–2338. doi: 10.1016/j.jacc.2013.08.1621.
17. Ozkan A, Hachamovitch R, Kapadia SR, Tuzcu EM, Marwick TH. Impact of aortic valve replacement on outcome of symptomatic patients with severe aortic stenosis with low gradient and preserved left ventricular ejection fraction. *Circulation*. 2013;128:622–631. doi: 10.1161/CIRCULATIONAHA.112.001094.
 18. Tribouilloy C, Rusinaru D, Maréchaux S, Castel AL, Debry N, Maizel J, Mentaverri R, Kamel S, Slama M, Lévy F. Low-gradient, low-flow severe aortic stenosis with preserved left ventricular ejection fraction: characteristics, outcome, and implications for surgery. *J Am Coll Cardiol*. 2015;65:55–66. doi: 10.1016/j.jacc.2014.09.080.
 19. Magne J, Pibarot P, Sengupta PP, Donal E, Rosenhek R, Lancellotti P. Pulmonary hypertension in valvular disease: a comprehensive review on pathophysiology to therapy from the HAVEC Group. *JACC Cardiovasc Imaging*. 2015;8:83–99. doi: 10.1016/j.jcmg.2014.12.003.
 20. LaBounty TM, Miyasaka R, Chetcuti S, Grossman PM, Deeb GM, Patel HJ, Booher A, Patel S, Bach DS. Annulus instead of LVOT diameter improves agreement between echocardiography effective orifice area and invasive aortic valve area. *JACC Cardiovasc Imaging*. 2014;7:1065–1066. doi: 10.1016/j.jcmg.2014.03.021.
 21. Kadem L, Dumesnil JG, Rieu R, Durand LG, Garcia D, Pibarot P. Impact of systemic hypertension on the assessment of aortic stenosis. *Heart*. 2005;91:354–361. doi: 10.1136/hrt.2003.030601.
 22. Briand M, Dumesnil JG, Kadem L, Tongue AG, Rieu R, Garcia D, Pibarot P. Reduced systemic arterial compliance impacts significantly on left ventricular afterload and function in aortic stenosis: implications for diagnosis and treatment. *J Am Coll Cardiol*. 2005;46:291–298. doi: 10.1016/j.jacc.2004.10.081.
 23. Baumgartner H, Stefenelli T, Niederberger J, Schima H, Maurer G. “Overestimation” of catheter gradients by Doppler ultrasound in patients with aortic stenosis: a predictable manifestation of pressure recovery. *J Am Coll Cardiol*. 1999;33:1655–1661.
 24. Gilon D, Cape EG, Handschumacher MD, Song JK, Solheim J, VanAuer M, King ME, Levine RA. Effect of three-dimensional valve shape on the hemodynamics of aortic stenosis: three-dimensional echocardiographic stereolithography and patient studies. *J Am Coll Cardiol*. 2002;40:1479–1486.
 25. Altiok E, Koos R, Schröder J, Brehmer K, Hamada S, Becker M, Mahnken AH, Almalla M, Dohmen G, Autschbach R, Marx N, Hoffmann R. Comparison of two-dimensional and three-dimensional imaging techniques for measurement of aortic annulus diameters before transcatheter aortic valve implantation. *Heart*. 2011;97:1578–1584. doi: 10.1136/hrt.2011.223974.
 26. Garbi M, Chambers J, Vannan MA, Lancellotti P. Valve stress echocardiography: a practical guide for referral, procedure, reporting, and clinical implementation of results from the HAVEC group. *JACC Cardiovasc Imaging*. 2015;8:724–736. doi: 10.1016/j.jcmg.2015.02.010.
 27. Vahanian A, Alfieri O, Andreotti F, Antunes MJ, Barón-Esquivias G, Baumgartner H, Borger MA, Carrel TP, De Bonis M, Evangelista A, Falk V, Lung B, Lancellotti P, Pierard L, Price S, Schäfers HJ, Schuler G, Stepinska J, Swedberg K, Takkenberg J, Von Oppell UO, Windecker S, Zamorano JL, Zembala M; ESC Committee for Practice Guidelines (CPG); Joint Task Force on the Management of Valvular Heart Disease of the European Society of Cardiology (ESC); European Association for Cardio-Thoracic Surgery (EACTS). Guidelines on the management of valvular heart disease (version 2012): the Joint Task Force on the Management of Valvular Heart Disease of the European Society of Cardiology (ESC) and the European Association for Cardio-Thoracic Surgery (EACTS). *Eur J Cardiothorac Surg*. 2012;42:S1–S44. doi: 10.1093/ejcts/ezs455.
 28. Lancellotti P, Lebois F, Simon M, Tombeux C, Chauvel C, Pierard LA. Prognostic importance of quantitative exercise Doppler echocardiography in asymptomatic valvular aortic stenosis. *Circulation*. 2005;112(9 suppl):I377–I382. doi: 10.1161/CIRCULATIONAHA.104.523274.
 29. Das P, Rimington H, Chambers J. Exercise testing to stratify risk in aortic stenosis. *Eur Heart J*. 2005;26:1309–1313. doi: 10.1093/eurheartj/ehi250.
 30. Rafique AM, Biner S, Ray I, Forrester JS, Tolstrup K, Siegel RJ. Meta-analysis of prognostic value of stress testing in patients with asymptomatic severe aortic stenosis. *Am J Cardiol*. 2009;104:972–977. doi: 10.1016/j.amjcard.2009.05.044.
 31. Donal E, Thebault C, O’Connor K, Veillard D, Rosca M, Pierard L, Lancellotti P. Impact of aortic stenosis on longitudinal myocardial deformation during exercise. *Eur J Echocardiogr*. 2011;12:235–241. doi: 10.1093/ejehocardiography/ehq076.
 32. Maréchaux S, Hachicha Z, Bellouin A, Dumesnil JG, Meimoun P, Pasquet A, Bergeron S, Arsenault M, Le Tourneau T, Ennezat PV, Pibarot P. Usefulness of exercise-stress echocardiography for risk stratification of true asymptomatic patients with aortic valve stenosis. *Eur Heart J*. 2010;31:1390–1397. doi: 10.1093/eurheartj/ehq076.
 33. Lancellotti P, Magne J, Donal E, O’Connor K, Dulgheru R, Rosca M, Pierard LA. Determinants and prognostic significance of exercise pulmonary hypertension in asymptomatic severe aortic stenosis. *Circulation*. 2012;126:851–859. doi: 10.1161/CIRCULATIONAHA.111.088427.
 34. Maréchaux S, Ennezat PV, LeJemtel TH, Polge AS, de Groote P, Asseman P, Nevière R, Le Tourneau T, Deklunder G. Left ventricular response to exercise in aortic stenosis: an exercise echocardiographic study. *Echocardiography*. 2007;24:955–959. doi: 10.1111/j.1540-8175.2007.00501.x.
 35. Clavel MA, Ennezat PV, Maréchaux S, Dumesnil JG, Capoulade R, Hachicha Z, Mathieu P, Bellouin A, Bergeron S, Meimoun P, Arsenault M, Le Tourneau T, Pasquet A, Couture C, Pibarot P. Stress echocardiography to assess stenosis severity and predict outcome in patients with paradoxical low-flow, low-gradient aortic stenosis and preserved LVEF. *JACC Cardiovasc Imaging*. 2013;6:175–183. doi: 10.1016/j.jcmg.2012.10.015.
 36. Clavel MA, Burwash IG, Mundtler G, Dumesnil JG, Baumgartner H, Bergler-Klein J, Sénéchal M, Mathieu P, Couture C, Beanlands R, Pibarot P. Validation of conventional and simplified methods to calculate projected valve area at normal flow rate in patients with low flow, low gradient aortic stenosis: the multicenter TOPAS (True or Pseudo Severe Aortic Stenosis) study. *J Am Soc Echocardiogr*. 2010;23:380–386. doi: 10.1016/j.echo.2010.02.002.
 37. Messika-Zeitoun D, Serfaty JM, Brochet E, Ducrocq G, Lepage L, Detaint D, Hyafil F, Himbert D, Pasi N, Laissy JP, Iung B, Vahanian A. Multimodal assessment of the aortic annulus diameter: implications for transcatheter aortic valve implantation. *J Am Coll Cardiol*. 2010;55:186–194. doi: 10.1016/j.jacc.2009.06.063.
 38. Jilalawi H, Doctor N, Kashif M, Chakravarty T, Rafique A, Makar M, Furugan A, Nakamura M, Mirocha J, Gheorghiu M, Stegic J, Okuyama K, Sullivan DJ, Siegel R, Min JK, Gurudev SV, Fontana GP, Cheng W, Friede G, Shiota T, Makkar RR. Aortic annular sizing for transcatheter aortic valve replacement using cross-sectional 3-dimensional transesophageal echocardiography. *J Am Coll Cardiol*. 2013;61:908–916. doi: 10.1016/j.jacc.2012.11.055.
 39. Feuchtner G, Plank F, Bartel T, Mueller S, Leipsic J, Schachner T, Müller L, Friedrich G, Klauser A, Grimm M, Bonaros N. Prediction of paravalvular regurgitation after transcatheter aortic valve implantation by computed tomography: value of aortic valve and annular calcification. *Ann Thorac Surg*. 2013;96:1574–1580. doi: 10.1016/j.athoracsur.2013.06.049.
 40. Aggarwal SR, Clavel MA, Messika-Zeitoun D, Cuffe C, Malouf J, Araoz PA, Mankad R, Michelena H, Vahanian A, Enriquez-Sarano M. Sex differences in aortic valve calcification measured by multidetector computed tomography in aortic stenosis. *Circ Cardiovasc Imaging*. 2013;6:40–47. doi: 10.1161/CIRCIMAGING.112.980052.
 41. Clavel MA, Pibarot P, Messika-Zeitoun D, Capoulade R, Malouf J, Aggarwal S, Araoz PA, Michelena HI, Cuffe C, Larose E, Miller JD, Vahanian A, Enriquez-Sarano M. Impact of aortic valve calcification, as measured by MDCT, on survival in patients with aortic stenosis: results of an international registry study. *J Am Coll Cardiol*. 2014;64:1202–1213. doi: 10.1016/j.jacc.2014.05.066.
 42. Habis M, Daoud B, Roger VL, Ghostine S, Caussin C, Ramadan R, Nottin R, Lancelin B, Angel CY, Capderou A, Paul JF. Comparison of 64-slice computed tomography planimetry and Doppler echocardiography in the assessment of aortic valve stenosis. *J Heart Valve Dis*. 2007;16:216–224.
 43. Eichenberger AC, Jenni R, von Schulthess GK. Aortic valve pressure gradients in patients with aortic valve stenosis: quantification with velocity-encoded cine MR imaging. *AJR Am J Roentgenol*. 1993;160:971–977. doi: 10.2214/ajr.160.5.8470612.
 44. Dweck MR, Joshi S, Murigu T, Alpendurada F, Jabbour A, Melina G, Banya W, Gulati A, Roussin I, Raza S, Prasad NA, Wage R, Quarto C, Angeloni E, Refice S, Sheppard M, Cook SA, Kilner PJ, Pennell DJ, Newby DE, Mohiaddin RH, Pepper J, Prasad SK. Midwall fibrosis is an independent predictor of mortality in patients with aortic stenosis. *J Am Coll Cardiol*. 2011;58:1271–1279. doi: 10.1016/j.jacc.2011.03.064.
 45. Barone-Rochette G, Piérard S, De Meester de Ravenstein C, Seldrum S, Melchior J, Maes F, Pouleur AC, Vancraeynest D, Pasquet A, Vanoverschelde JL, Gerber BL. Prognostic significance of LGE by CMR in aortic stenosis patients undergoing valve replacement. *J Am Coll Cardiol*. 2014;64:144–154. doi: 10.1016/j.jacc.2014.02.612.

46. Irkle A, Vesey AT, Lewis DY, Skepper JN, Bird JL, Dweck MR, Joshi FR, Gallagher FA, Warburton EA, Bennett MR, Brindle KM, Newby DE, Rudd JH, Davenport AP. Identifying active vascular microcalcification by (18)F-sodium fluoride positron emission tomography. *Nat Commun*. 2015;6:7495. doi: 10.1038/ncomms8495.
47. Dweck MR, Jenkins WS, Vesey AT, Pringle MA, Chin CW, Malley TS, Cowie WJ, Tsampasian V, Richardson H, Fletcher A, Wallace WA, Pessotto R, van Beek EJ, Boon NA, Rudd JH, Newby DE. 18F-sodium fluoride uptake is a marker of active calcification and disease progression in patients with aortic stenosis. *Circ Cardiovasc Imaging*. 2014;7:371–378. doi: 10.1161/CIRCIMAGING.113.001508.
48. Dweck MR, Jones C, Joshi NV, Fletcher AM, Richardson H, White A, Marsden M, Pessotto R, Clark JC, Wallace WA, Salter DM, McKillop G, van Beek EJ, Boon NA, Rudd JH, Newby DE. Assessment of valvular calcification and inflammation by positron emission tomography in patients with aortic stenosis. *Circulation*. 2012;125:76–86. doi: 10.1161/CIRCULATIONAHA.111.051052.
49. Jenkins WS, Vesey AT, Shah AS, Pawade TA, Chin CW, White AC, Fletcher A, Carlidge TR, Mitchell AJ, Pringle MA, Brown OS, Pessotto R, McKillop G, Van Beek EJ, Boon NA, Rudd JH, Newby DE, Dweck MR. Valvular (18)F-fluoride and (18)F-fluorodeoxyglucose uptake predict disease progression and clinical outcome in patients with aortic stenosis. *J Am Coll Cardiol*. 2015;66:1200–1201. doi: 10.1016/j.jacc.2015.06.1325.
50. Otto CM, Burwash IG, Legget ME, Munt BI, Fujioka M, Healy NL, Kraft CD, Miyake-Hull CY, Schwaegler RG. Prospective study of asymptomatic valvular aortic stenosis. Clinical, echocardiographic, and exercise predictors of outcome. *Circulation*. 1997;95:2262–2270.
51. Pellikka PA, Sarano ME, Nishimura RA, Malouf JF, Bailey KR, Scott CG, Barnes ME, Tajik AJ. Outcome of 622 adults with asymptomatic, hemodynamically significant aortic stenosis during prolonged follow-up. *Circulation*. 2005;111:3290–3295. doi: 10.1161/CIRCULATIONAHA.104.495903.
52. Lancellotti P, Rosenhek R, Pibarot P, Jung B, Otto CM, Tornos P, Donal E, Prendergast B, Magne J, La Canna G, Piérard LA, Maurer G. ESC working group on valvular heart disease position paper—heart valve clinics: organization, structure, and experiences. *Eur Heart J*. 2013;34:1597–1606. doi: 10.1093/eurheartj/ehs443.
53. Eleid MF, Sorajja P, Michelena HI, Malouf JF, Scott CG, Pellikka PA. Flow-gradient patterns in severe aortic stenosis with preserved ejection fraction: clinical characteristics and predictors of survival. *Circulation*. 2013;128:1781–1789. doi: 10.1161/CIRCULATIONAHA.113.003695.
54. Lancellotti P, Donal E, Magne J, Moonen M, O'Connor K, Daubert JC, Pierard LA. Risk stratification in asymptomatic moderate to severe aortic stenosis: the importance of the valvular, arterial and ventricular interplay. *Heart*. 2010;96:1364–1371. doi: 10.1136/hrt.2009.190942.
55. Clavel MA, Malouf J, Michelena HI, Suri RM, Jaffe AS, Mahoney DW, Enriquez-Sarano M. B-type natriuretic peptide clinical activation in aortic stenosis: impact on long-term survival. *J Am Coll Cardiol*. 2014;63:2016–2025. doi: 10.1016/j.jacc.2014.02.581.
56. Mohty D, Boulogne C, Magne J, Pibarot P, Echahidi N, Cornu E, Dumesnil J, Laskar M, Virot P, Aboyans V. Prevalence and long-term outcome of aortic prosthesis-patient mismatch in patients with paradoxical low-flow severe aortic stenosis. *Circulation*. 2014;130(11 suppl 1):S25–S31. doi: 10.1161/CIRCULATIONAHA.113.007819.

Multimodality Imaging Strategies for the Assessment of Aortic Stenosis: Viewpoint of the Heart Valve Clinic International Database (HAVEC) Group

Raluca Dulgheru, Philippe Pibarot, Partho P. Sengupta, Luc A. Piérard, Raphael Rosenhek, Julien Magne, Erwan Donal, Anne Bernard, Khalil Fattouch, Bernard Cosyns, Mani Vannan, Linda Gillam and Patrizio Lancellotti

Circ Cardiovasc Imaging. 2016;9:e004352

doi: 10.1161/CIRCIMAGING.115.004352

Circulation: Cardiovascular Imaging is published by the American Heart Association, 7272 Greenville Avenue, Dallas, TX 75231

Copyright © 2016 American Heart Association, Inc. All rights reserved.

Print ISSN: 1941-9651. Online ISSN: 1942-0080

The online version of this article, along with updated information and services, is located on the World Wide Web at:

<http://circimaging.ahajournals.org/content/9/2/e004352>

Data Supplement (unedited) at:

<http://circimaging.ahajournals.org/content/suppl/2016/02/10/CIRCIMAGING.115.004352.DC1.html>

Permissions: Requests for permissions to reproduce figures, tables, or portions of articles originally published in *Circulation: Cardiovascular Imaging* can be obtained via RightsLink, a service of the Copyright Clearance Center, not the Editorial Office. Once the online version of the published article for which permission is being requested is located, click Request Permissions in the middle column of the Web page under Services. Further information about this process is available in the [Permissions and Rights Question and Answer](#) document.

Reprints: Information about reprints can be found online at:
<http://www.lww.com/reprints>

Subscriptions: Information about subscribing to *Circulation: Cardiovascular Imaging* is online at:
<http://circimaging.ahajournals.org/subscriptions/>

Supplemental Material

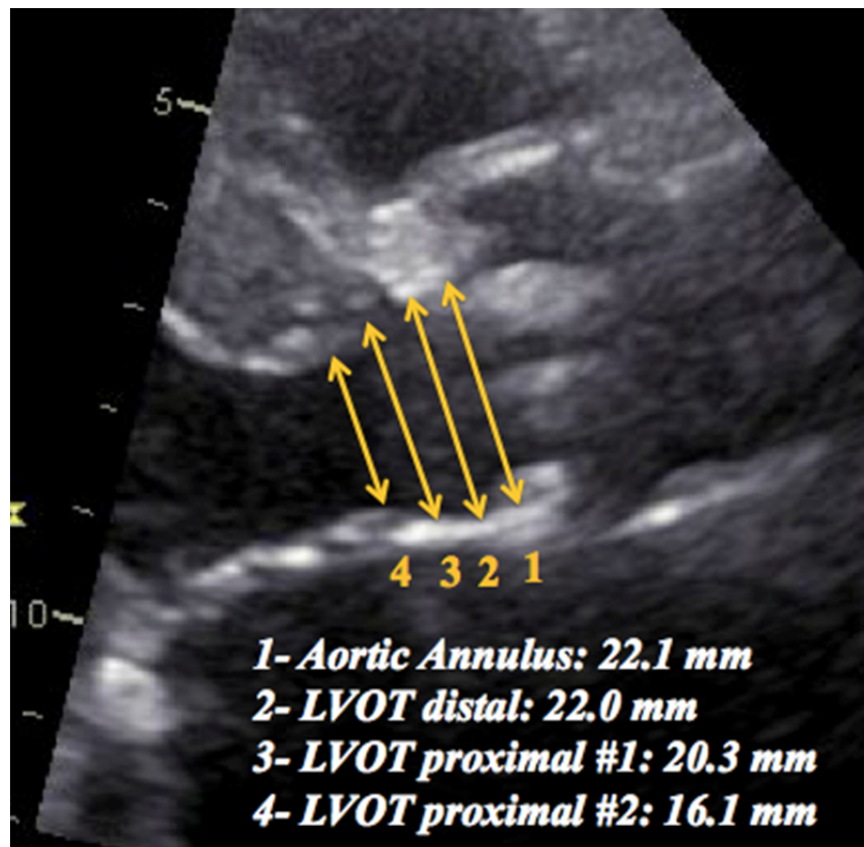
Suppl 1: Standardized echocardiography report of the HAVEC group

Parameters	Key points
Body surface area, m ²	Same formula to estimate body surface area has to be use with each echocardiographic study
Systolic Blood Pressure, mmHg	Systematically measured before each echocardiogram If high, rescanning is necessary after control of blood pressure values, since it may affect gradients and effective orifice area measurements
2D Echocardiography	
<i>Valve morphology</i>	
• Number of leaflets	Tricuspid/Bicuspid/Unknown
• Degree of calcification	Mildly/Moderately/Severely Calcified
<i>Etiology</i>	
Calcific/Rheumatic/Congenital/Post-radiotherapy/Others	
<i>Grading severity</i>	
• Effective AVA, cm ²	AVA as assessed by the continuity equation <i>LV outflow tract diameter and stroke volume index should always be reported to allow accurate progression monitoring and classify patients according to the flow-gradient relationship</i>
• Indexed AVA, cm ² /m ²	Indexed AVA should always be performed, especially in small stature or tall patients Indexed AVA should be interpreted with caution in obese patients
• Aortic peak velocity, m/s	All echocardiographic windows have to be used in order to allow reporting of maximal velocity The echocardiographic window that yields the highest value has to be reported for accurate progression monitoring
• Mean transaortic pressure gradient, mmHg	
<i>LV geometry and function</i>	
• LV mass index, g/m ²	Hemodynamically significant AS is virtually always associated with LV remodelling/hypertrophy
• Relative wall thickness	
• Pattern of LV remodelling	Normal LV/LV concentric remodelling/LV concentric hypertrophy/LV eccentric hypertrophy
• LV ejection fraction, %	As assessed by biplane Simpson method, stroke volume index obtained by this method may be recorded to allow recalculation of effective orifice area
• Global longitudinal function, %	Always report the vendor used for analysis to allow longitudinal comparison
• Mitral E/A	Diastolic function grade/pattern; increased LV filling pressure
• Mitral E/e'	
<i>Consequences on LA and pulmonary vasculature</i>	
• Left atrial volume index, mL/m ²	Use biplane Simpson's method
• Transtricuspid pressure gradient, mmHg	Conclude the possibility/probability of having or not pulmonary hypertension
• Inferior vena cava diameter and respiratory changes, mm and %	
• Systolic pulmonary arterial pressure, mmHg	
<i>LV hemodynamic load</i>	
• Systemic arterial compliance mL/m ² /mmHg	Assessment of arterial load is very important in the understanding of AS physiopathology, as it is not an isolated valvular disease, but a complex systemic process affecting both the valve and the arterial system
• Global afterload, mmHg/mL/m ²	

AS: aortic stenosis, AVA: aortic valve area, LV: left ventricle

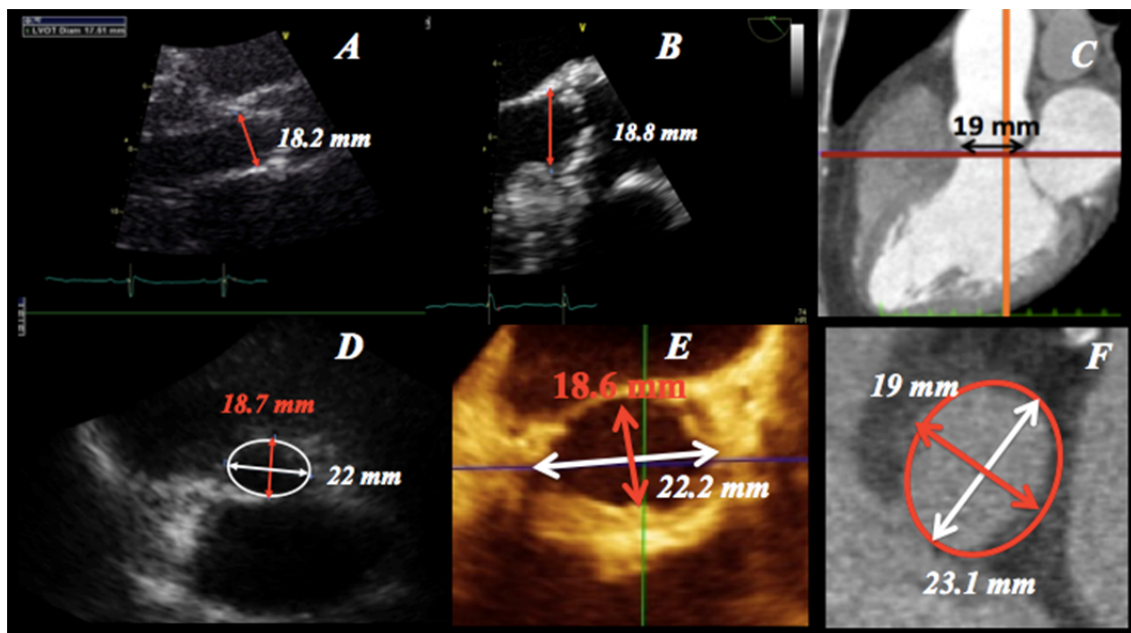
Suppl 2: Measurement of left ventricular outflow tract diameter by transthoracic echocardiography

Caption: Difference between proximal left ventricular outflow tract (LVOT) diameter (0.5-1cm below the aortic cusps (orange arrows # 3 and 4), distal LVOT diameter measured just (2-3 mm) below the aortic annulus at the level of the membranous section of the septum (orange #2), and the aortic annulus diameter measured at the base of the aortic valve cusps (orange arrow #1) in a patient with AS. Note that the presence of septal basal hypertrophy may lead to considerable underestimation of LVOT diameter if measured at the proximal level of the LVOT (orange arrow #4). It is recommended to use the distal LVOT diameter (arrow #2) or the aortic annulus diameter (arrow #1) to calculate the LVOT stroke volume and effective aortic valve area.



Suppl 3: Underestimation of left ventricle outflow tract diameter by transthoracic echocardiography in patients with non-circular outflow tract geometry revealed with 3D imaging techniques (3D echocardiography and CT).

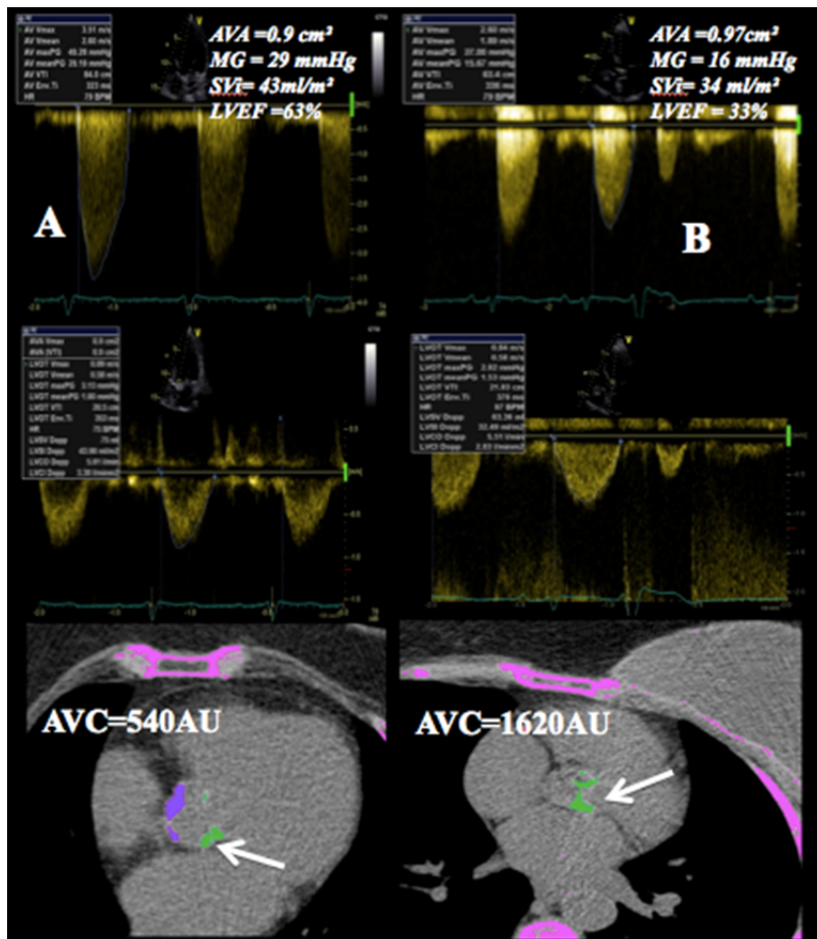
Caption: Patient with an AS and an elliptical left ventricular outflow tract (LVOT) in whom measurement of the LVOT diameter in the standard parasternal long-axis view led to an underestimation of the effective aortic valve area (AVA) by the continuity equation. 3D imaging (Panel D, E and F) reveals the elliptical shape of the LVOT. Note that 2D echocardiographic techniques can underestimate the size of the LVOT because only the smallest (sagittal) diameter can be measured (Panel A-transthoracic and B-transesophageal). A similar value for the antero-posterior diameter of the LVOT can be obtained by CT or CMR (Panel C). 3D transthoracic echocardiography (Panel D), 3D transesophageal (Panel E) and CT (Panel F) allow measurement of the antero-posterior diameter (red arrow) and of the coronal diameter (white arrow) as well as direct planimetry of the cross sectional area of the LVOT (red ellipse Panel F).



Suppl. 4: Aortic valve calcium score assessment by multi-slice computed tomography in patients with pseudo-severe aortic stenosis (AS) and preserved left ventricular ejection fraction (LVEF) (A) and low gradient true severe aortic stenosis and reduced LVEF (AS) (B).

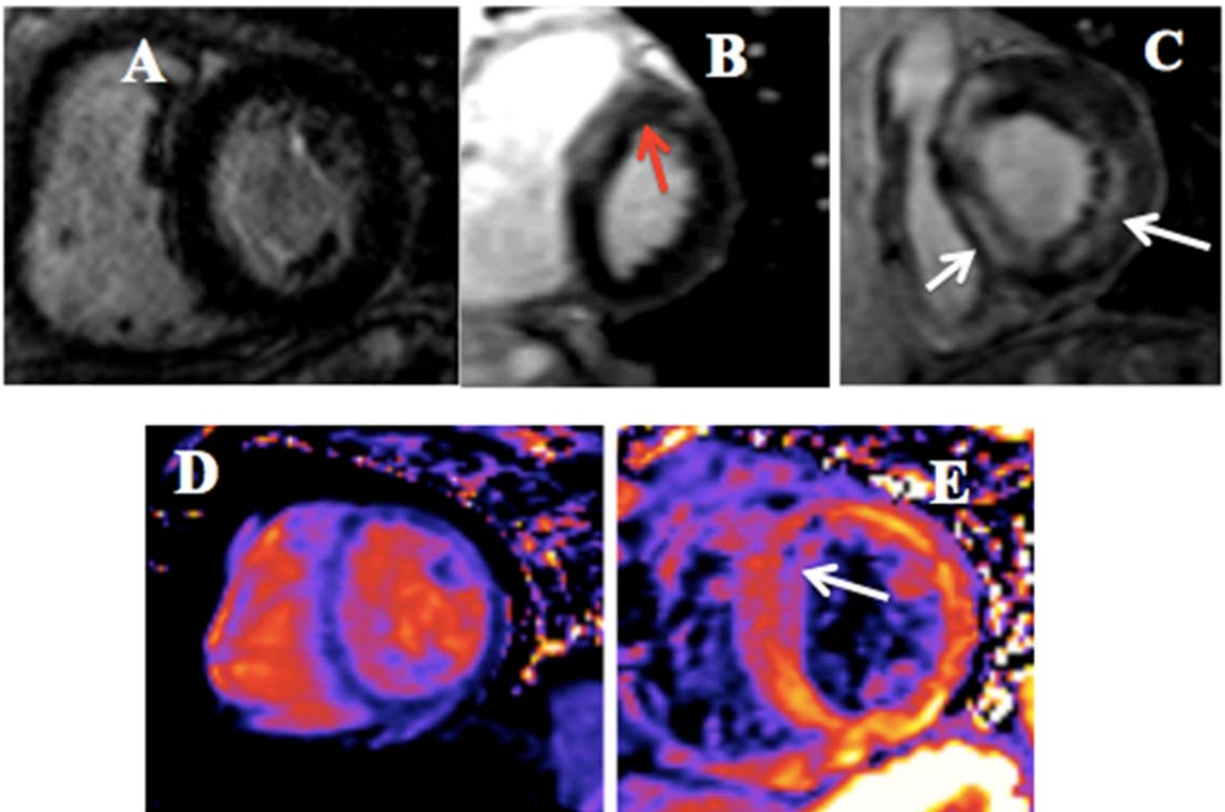
Caption: A) Female patient with low aortic valve calcium load by MSCT-multi-slice computed tomography (AVC) pleading for pseudo-severe AS. B) Female patient with high AVC confirming the presence of true severe AS. Green areas represent aortic valve calcifications (arrows).

Legend: AVA: aortic valve area; LVEF: left ventricular ejection fraction; MPG: mean pressure gradient; SVi: stroke volume index



Suppl. 5: Assessment of myocardial fibrosis by contrast enhanced cardiac magnetic resonance

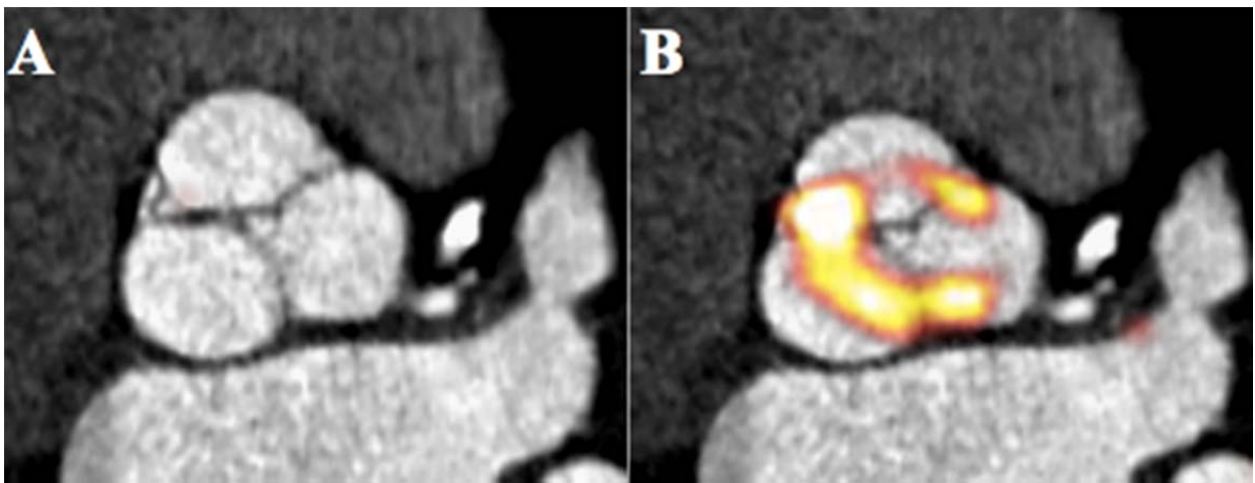
Caption: A) Patient with moderate aortic stenosis and no fibrosis (absence of late gadolinium enhancement); B) Patient with severe aortic stenosis and mild fibrosis (red arrow); C) Patient with severe aortic stenosis and extensive fibrosis (white arrows); DE) Short-axis midventricular unenhanced T1 mapping shows homogenous distribution of the T1 values (A). 15 minutes after gadolinium injection at the same location (B), the anteroseptal myocardial values of T1 are decreased as compared to the opposite area, with an intramyocardial and subendocardial predominance (arrow), figuring increased intramyocardial volume of distribution of the contrast agent (fibrosis)



Suppl. 6: 18F-Fluoride PET/CT imaging in aortic stenosis

Caption: A) Contrast enhanced CT image of the aortic valve demonstrates a try-leaflet aortic valve with little calcification visible; B) 18F-Fluoride PET image fused with the CT scans demonstrates several areas of increased uptake, indicating regions of calcification activity.

Courtesy of Drs. Tania Pawade and Marc Dweck



Suppl. 7: Figure 4: Multimodality imaging use for diagnosis and risk stratification in a patient with low flow low gradient AS with preserved left ventricular ejection fraction.

Caption: Low flow low gradient severe AS with preserved left ventricular ejection fraction (LVEF). Note the presence of significant LV hypertrophy with a small LV cavity size (Panel A). Careful measurement of LVOT diameter is performed in parasternal long-axis view in mid-systole, zoomed mode (Panel B). LVEF is preserved but longitudinal systolic dysfunction is present (reduced global longitudinal strain (GLS, Panel G). Stroke volume and indexed stroke volume are calculated by the Doppler method and confirm the presence of a low flow state (Panel C). AVA is calculated by the continuity equation and indicates a severe AS (AVA<1.0 cm², Panel D), in discordance with the mean gradient, which is below 40 mmHg (Panel D). Aortic valve calcium score confirms the presence of a high aortic valve calcium load (Panel E), while CMR provides direct planimetry of the anatomic valve area (Panel F) and helps in risk stratification by identifying mid-wall fibrosis (red arrows, Panel H). 3D transthoracic echocardiography helps to confirm the low-flow state. Note the low 3D stroke volume (Panel I).

