

ROHHAD(NET) Syndrome: Systematic review of the clinical timeline and recommendations for diagnosis and prognosis.

Julie Harvengt ¹, Caroline Gernay ², Meriem Mastouri ³, Nesrine Farhat ⁴, Marie-Christine Lebrethon ², Marie-Christine Seghaye ⁴, Vincent Bours ¹.

1. Department of Human Genetics, CHU Liège, Belgium.
2. Department of Paediatrics, Section Endocrinology, CHU Liège, Belgium.
3. Department of Paediatrics, Section Pneumology, CHU Liège, Belgium.
4. Department of Paediatrics, Section Cardiology, CHU Liège, Belgium.

Correspondence:

Dr Julie HARVENGT

Department of Human Genetics- CHU Liège

Avenue de l' Hôpital 1

4000 Sart-Tilman (Liège)

Belgium

Julie.Harvengt@chuliege.be

[Reprint request: Julie.Harvengt@chuliege.be](mailto:Julie.Harvengt@chuliege.be)

PATIENT CONSENT: obtained

DISCLOSURE SUMMARY: I certify that neither I nor my co-authors have a conflict of interest that is relevant to the subject matter or materials included in this work.

© Endocrine Society 2020. All rights reserved. For permissions, please e-mail: journals.permissions@oup.com jc.2019-40566 See endocrine.org/publications for Accepted Manuscript disclaimer and additional information.

Abstract

Context: Rapid onset Obesity with Hypothalamic dysfunction, Hypoventilation, Autonomic Dysregulation and Neural Tumor Syndrome (ROHHAD(NET)) is a rare and potentially fatal disease. No specific diagnostic biomarker is currently available, making prompt diagnosis challenging. Since its first definition in 2007, a complete clinical analysis leading to specific diagnosis and follow-up recommendations is still missing.

Objective: To describe the clinical timeline of symptoms of ROHHAD(NET) and propose recommendations for diagnosis and follow-up.

Design: We conducted a systematic review of all ROHHAD(NET) case studies and report a new ROHHAD patient with early diagnosis and multidisciplinary care.

Methods: All the articles that meet the definition of ROHHAD(NET) and provide chronological clinical data were reviewed according to the PRISMA individual patient data (IPD) guidelines. The data were grouped into 7 categories: hypothalamic dysfunction, autonomic dysregulation, hypoventilation, NET, psychiatric symptoms, other clinical manifestations, outcome.

Results: 43 IPD were analyzed. The timeline of the disease shows rapid onset obesity followed shortly afterwards by hypothalamic dysfunction. Dysautonomia was reported at a median age of 4.95 years and hypoventilation at 5.33 years, or 2,2 years after the initial

obesity. A NET was reported in 56% of the patients and 70% of these tumors were diagnosed within 2 years after initial weight gain.

Conclusion: Since early diagnosis improves the clinical management and the prognosis in ROHHAD(NET), this diagnosis should be considered for any child with a rapid and early obesity. We propose guidance for systematic follow-up and advise multidisciplinary management with the aim of improving prognosis and life expectancy.

KEY WORDS: ROHHAD; precocious obesity; central hypoventilation; dysautonomia; sinusual bradycardia; neural crest tumor.

Accepted Manuscript

Précis

A review was conducted to propose guidance for follow-up in case of ROHHAD(NET) and highlights the need to detect central hypoventilation and to screen for NET during the first 2 years of follow-up.

Accepted Manuscript

Introduction

Rapid-Onset Obesity with Hypoventilation, Hypothalamic dysfunction, and Autonomic Dysregulation Syndrome (ROHHAD) is a very rare autonomic and respiratory paediatric disorder associated with a high risk of mortality (1). Since the first case report in 1965 (1), in 2000 this specific clinical disorder was named, Late-Onset Central Hypoventilation with Hypothalamic Dysfunction (LO-CHS/HD) and described in a series of 11 patients (2). In 2007, an acronym was proposed to improve patient identification: ROHHAD (3). At that time, it was possible to distinguish it from Congenital Central Hypoventilation Syndrome (CCHS) with genetic testing : CCHS is associated with *PHOX2B* mutation while ROHHAD is not. The acronym of the disease was completed in 2008 for ROHHAD(NET) to include the risk of ganglioneuroma (GN) or ganglioneuroblastoma (GNB) observed in about 40% of ROHHAD patients (4). The aetiology of the disease remains unclear and there is still no significant genetic result. An autoimmune process or epigenetic disorders are currently considered as possible etiological hypotheses (5,6). Previous studies have not yet established whether ROHHAD and ROHHAD(NET) syndromes share the same aetiology. The definition of ROHHAD syndrome is currently based on clinical criteria, defined first by Ize Ludlow *et al* in 2007 (3). The major criterion is dramatic weight gain associated with central hypoventilation appearing between the age of 1.5 and 7 years in a previously healthy child.

This rapid-onset obesity is considered to be the first sign of hypothalamic dysfunction. At least one more evidence of hypothalamic dysfunction is necessary for the diagnosis, such as hyperprolactinemia, central hypothyroidism, disordered water balance, growth hormone abnormal response, adrenocortical insufficiency or puberty disorders.

symptoms, he was very hungry including nocturnal eating. After that time, the calorie intake was strictly controlled by the parents with a permanent rigorous diet.

The parents initially reported some sleep alteration with jerky breathing and grinding of teeth.

Over the first year of symptoms he developed behavioural disturbances including frustration tantrums and aggression. He has excellent cognitive skills, particularly high for memory activities.

At first examination, he was not dysmorphic. There were no stretch marks and no nigricans acanthosis. Somatic examination was normal except for generalized obesity.

The first investigations including cerebral MRI, abdominal ultrasound, cortisolemia (including an overnight dexamethasone test and three 24-hour urinary free cortisol) and thyroid hormone levels, were normal.

The polysomnography demonstrated a pattern of severe central hypoventilation with hypercapnia (mean PtcCO₂: 59 mmHg - Maximal PtcCO₂: 61 mmHg - Time spent with PtcCO₂>50 mmHg: 100%). Hypocretin concentration in cerebrospinal fluid (CSF) was normal (333 ng/l; normal value 224-653 ng/l) excluding narcolepsy. Treatment with nocturnal noninvasive ventilation (NIV) with facial mask was started at age four years. The diagnosis of ROHHAD syndrome was then confirmed and complementary investigations highlighted a central hypothyroidism, a normal IGF1 level, a moderate polyuria-polydipsia without diabetes insipidus and an arterial hypertension.

After 15 months of follow-up, the patient presented repeated syncope, occurring generally after intense laughing or severe anger and followed by general muscular hypotonia and post critical state. Parents had to resuscitate with non-invasive ventilation by mask. A 21-days Holter-electrocardiogram recording demonstrated an episode of sinus pause of 15 seconds

that was concomitant with a syncope. A cardiac pacemaker with a ventricular stimulation lead, ensuring a minimal heart rate of 60/minute, was therefore implanted at the age of 5 years and 4 months. Since this intervention, the patient has been syncope-free.

Today, at 7,5 years old, the patient continues to engage in a lot of physical activities, essentially based on endurance. He wears a connected device (digital watch) to track his physical activity. Management of his nocturnal respiratory assistance is demanding but well controlled with the NIV. Screening for NET is still negative.

Genetic investigations revealed no mutation in *PHOX2B*. A CGH array was normal. Prader-Willi syndrome was excluded. Whole Exome sequencing did not identify any pathogenic variant that could explain the phenotype.

Patient's and parents' consent was obtained for the present case report.

Methods

1. Search methods.

We conducted a systematic analysis of the medical literature to identify all published clinical cases of ROHHAD and/or ROHHAD(NET) using the online database PubMed, until September 30st, 2019. Language was restricted to English. The search query was limited with the terms ROHHAD and ROHHAD(NET). All the publications identified were included and analysed. These were supplemented with the incorporation of all the secondary references found in each article. The research was limited to articles published since 2007.

We reviewed each article adhering to the Preferred Reporting Items for Systematic Reviews and Meta-Analysis (PRISMA) individual patient data (IPD) guidelines (7) (Figure 2).

2. Eligibility criteria

We collected clinical case reports written in English. The clinical description had to include the timing of the onset of the different symptoms. The chronology had to be mentioned, with minimum two references to the different ages of the patient.

The clinical cases had to match with the definition of the ROHHAD syndrome, as published by Ize Ludlow *et al.* in 2007 (3): [1] onset of rapid and extreme weight gain after the age of 1.5 years in a previously healthy child, [2] evidence of hypothalamic dysfunction, [3] central hypoventilation and [4] features of autonomic dysregulation. Cases were eligible if they present criteria [1] + [3] + one clinical sign of hypothalamic dysfunction [2]. In the absence of criteria [2] or [3], if a neuroendocrine tumor is present, we collected the data, because of the possibility of further evolution in these patients with later onset of criteria [2] and [3] (in particular in case reports of young children).

To collect more individual data, abstracts presenting a complete overview of the clinical evolution of patients were also collected for the present review.

3. Exclusion criteria.

Original articles such as review article that do not contain individual data were not included. Letters to editors, commentary and more general publications about the ROHHAD(NET) syndrome were not included if they do not contain any individual data.

The clinical cases that did not match with the ROHHAD definition were excluded.

4. Data extraction.

Data were extracted from all the case reports included. The demographic information included age, gender and ethnicity. Clinical manifestations were divided into seven categories: (1) Hypothalamic dysfunction, (2) autonomic dysregulation, (3) hypoventilation, (4) neural crest tumors, (5) psychiatric symptoms, (6) other clinical manifestations, and (7) outcome. For each category, data were collected regarding clinical description, apparition of each symptom, laboratory findings and management strategy.

5. Data analysis.

Data were collected in order to calculate the mean age of apparition of each symptom. Mean age was calculated for each item for all patients for whom this data had been reported. Mean, median, standard deviation, minimum value, maximum value, percentile 25% and percentile 75% were automatically generated for each item with a conventional spread sheet. Data are expressed as medians (25th-75th percentiles) or percentages in the text. "R" software was used to generate Box-Plots graphs (R Core Team 2013).

Results

61 specific articles dedicated on the ROHHAD or ROHHAD(NET) Syndrome were considered and 33 articles were selected to extract IPD (4,5,8-38). A total of 43 patient descriptions were extracted from these case reports. Descriptions of around 70 supplementary ROHHAD patients were not included due to the possibility of duplicated patients and due to a lack of precise clinical description in these case series.

General description

Case reports of 43 patients were included, 29 females and 8 males (N=37; 6 missing data), with a female to male ratio of 3.6. All the cases were described at paediatric age except for two young adults (diagnosis made during infancy, and follow up until a maximum age of 27 years).

Figure 3 summarizes the results concerning the timing of onset of the different major clinical signs encountered in ROHHAD patients.

1. Hypothalamic Dysfunction

The main criterion of the disease is the onset of rapid weight gain that appeared at a median of 3.1 (2.8-4) years of age (N=43) with a description of hyperphagia that started at a median of 3 (2-3.6) years (N=23).

Figure 4a illustrates the timing of onset of different hypothalamic dysfunction encountered in ROHHAD syndrome and figure 4b shows the number of symptoms presented by each patient, with a median of 2 different symptoms reported per patient.

2. Hypoventilation

Hypoventilation was mentioned for 41 patients (Figure 4c). Two cases are not described in terms of hypoventilation, they are young patients (2.5 and 3.8 years) with NET and obesity.

Central hypoventilation occurred at a median of age of 5.3 (4-8.5) years (N=28) and was diagnosed for 83% of the patients in the five first years after the beginning of the obesity.

Obstructive apneas were also described for 15 children at a median of age of 4 (3.2-5.25) years. For 5 patients, an exclusive central hypoventilation was explicitly reported without

obstructive apnea. Cyanotic episodes were observed in 7 patients at a median of 4.7 (2.9-5) years of age.

Tracheostomy was needed for 12 patients at a median of age of 4.8 (4.1-5.1) years, secondary to the management of an acute respiratory distress (N=5/12) or secondary to the need to optimize ventilator chronic management (N=7/12).

NIV was started at a median age of 6.25 (4-7.9) years for the 10 cases which specified this timing. Two other cases described NIV treatment without reporting a specific timing.

11 patients presented with acute respiratory failure and required intubation, during the ROHHAD disease (N=3) or at the beginning of the diagnosis process (N=8) at a median age of 5 (3.3-9.5) years.

3. Autonomic Dysregulation

Autonomic disturbances were described for 35 patients. There was no available data for 8 patients. Table 1 shows a list of autonomic dysfunctions. They are encountered at various ages (Figure 4d) and stages of the disease. Concerning the thermal dysregulation, 4 patients were reported with hypothermia, 6 with hyperthermia and 5 with fluctuating hypo or hyperthermia (N=15).

4. Neural crest tumors (NET)

24 patients were reported with neural crest tumors, representing 56% of the cohort. The median age of occurrence was 4.75 years (4-8.45). The type of tumor was a ganglioneuroblastoma for 2 patients, a neuroblastoma for 2 patients and a ganglioneuroma for 18 patients. One child was described with an aggressive neuroblastoma presenting metastasis.

The different neural tumor locations reported were: adrenal N=9, thoracic N=5, paravertebral cervical N=1, paravertebral abdominal N=1, retro pancreatic N=1. One of the reported tumors was a benign hamartoma with proliferating neural elements.

In addition to these neural tumors, one other case presented a hepatocarcinoma at 26 years in the context of hepatic fibrosis due to an initial Non Alcoholic Fatty Liver Disease (NAFLD).

The period between the rapid weight gain and the diagnosis of the neural crest tumor was recorded for the 24 patients. According to this data, 50 % of the patients (28% of the total cohort) presented such a tumor at an interval of 0.75 years after weight gain and 70% of the patients (40% of the total cohort) were affected by a neural tumor within two years after the initial onset of obesity.

5. Psychiatric/Behavioural disorders

Psychiatric manifestations or behavioural problems are reported in ROHHAD(NET) patients.

Hallucinations were reported in 3 patients (median age of 10 (7.5-11) years). Major anxiety was reported in these three patients and in one additional case at a median of age of 4.5 (4.25-6.6) years.

Psychosis was also reported for 2 patients at 4.75 and 5 years, and flat affect for 4 other patients (median of age of 3 (2.9-4.25) years).

Behavioural problems were described for 13 patients at 3.8 (3-4.3) years: aggressiveness for 7 patients at 3.8 (3.25-4.2) years, hyperactivity for 2 of these 7 patients at 3 and 3.8 years and irritability for 3 others patients at 4 (3.6-4.75) years.

6. Others clinical manifestations

- Cerebral MRI results were reported for 23 patients and were normal except for two patients for which particularities were noted: one case presented an absence of the posterior bright spot and one presented a normal pituitary axis but with a general cerebral atrophy.
- A developmental disorder was encountered in nine cases with a developmental regression described for four patients at an age of 2.8 (2.6-3.2) years.
- Pneumonia can be a trigger of respiratory decompensation and was encountered in three cases.
- Seizures were described for three patients at a median age of 4 (3.5-7.5) years.
- Among the 43 patients described, there were two with narcolepsy confirmed with decreased hypocretin levels. Hyper-somnolence was reported in six other cases, without more clinical information about the eventual diagnosis of narcolepsy. Symptoms were often described as sleep attacks.
- Hypercholesterolemia was mentioned for two patients with major hypertriglyceridemia (1062 mg/dl) for one of them. Metabolic syndrome was reported for two patients and one of them developed severe insulin resistance evolving towards a clinical diabetes at 14 years.
- Rectal prolapses were reported for two patients, as a secondary sign of dysautonomia and dysregulation of digestive function.
- Celiac disease was reported for one patient, occurring five years after the initial rapid weight gain.
- Scoliosis was reported for one patient at nine years.

- Therapeutic management: three patients were reported to be treated with intravenous immunoglobulin, six patients with cyclophosphamide, five patients with rituximab and three with corticoids.

7. Outcome

The outcome was reported for 32 patients of the cohort. Six of the 32 patients died. The age of death was available for only three of these patients allowing the calculation of a median of age of 4.6 years (4.5-6.3). Among the reported causes of death, two were consecutive to a sudden cardiorespiratory arrest, one was secondary to a blocked tube during ventilation and another one was caused by a septic shock with multiple organ failure. An autopsy was only conducted for this last case, and revealed a hypothalamic encephalitis.

26 patients were clearly described to be still alive in their respective publications, with a median age of 8 (5.2-12.8) years (N=14) at the end of the described follow-up, among them 70% were younger than 12 years.

Discussion

Diagnosing ROHHAD Syndrome is challenging due to the lack of any specific marker. Clinical criteria offer clues to diagnosis but they do not all appear concurrently.

In our patient, the ROHHAD diagnosis was rapidly made thanks to the initial explorations. The prompt diagnosis was the first step in medical care and was essential to anticipate many of the symptoms such as the necessity for an early implantation of a cardiac pacemaker.

In addition to the vital management in ROHHAD Syndrome, a lot of co-morbidities and associated symptoms such as the risk of NET require a rigorous follow up. To better understand the clinical evolution and timeline of the disease, we analysed, for the first time, the detailed evolution of 43 patients described until now in the literature.

ROHHAD syndrome is characterized by a sequence of clinical features emerging with advancing age, commonly accepted as appearing in the order of the acronym: rapid-onset obesity with hypothalamic dysfunction, hypoventilation followed by autonomic dysregulation syndrome (3,39). There is however no evidence for a systematic sequence of symptoms. ROHHAD syndrome was also associated with a series of co-morbidities or associated symptoms such as NET (4,14). Currently, there is no specific recommendations for the management or the timing of the investigations. The last larger clinical description of a ROHHAD cohort of 15 patients was published in 2007 by Ize Ludlow *et al.* in the time where her group defined for the first time the term of ROHHAD disease (3).

The initial event is always rapid weight gain accompanied rapidly by a second hypothalamic dysfunction. The hypoventilation was found more or less rapidly after the onset of obesity (Figure 3). Our description shows that hypoventilation appears at a median of 2.2 (0-3.75) years after the first sign of rapid obesity. As patients were not systematically evaluated with a polysomnography at the beginning of the pathology, knowing precisely when hypoventilation starts is very difficult. We would recommend vigilance with such young patients with a weight curve showing a rapid weight gain without any other clear aetiology. If the child also presents an endocrinology disorder or a dysautonomic disturbance, a polysomnography seems to be a safe preventive exam in order to confirm the ROHHAD Syndrome. In case of high suspicion, the exam has to be repeated annually for a minimum of 5 years. In our review, the central hypoventilation was diagnosed for 83% of the patients in the 5 first years after the beginning of the obesity.

Hypothalamic dysfunctions were reported rapidly after the onset of obesity, with a median interval timing of less than one year (0.9 years). The principal hormonal dysregulation reported in the literature was the hyperprolactinemia with values ranging from slightly elevated (44.7 ng/ml) to significantly increased (380 ng/ml). Central hypothyroidism and growth hormone (GH) deficiency were frequently reported with GH levels almost undetectable after GH stimulation test (9,15,23,26-28).

Natremia disorders were a frequent observation with different types of water imbalance description. A series of patients were initially managed in Paediatric Intensive Care Unit (N=8). In this context, hypernatremia, hyponatremia and SIADH or diabetes insipidus were described (6,8,23,24,26,30,34,36). Some patients recovered but not all. Other patients presented initially with a polyuria-polydipsia syndrome (N=5) requiring for some of them a treatment with desmopressin (21,22,30,37).

Hypoventilation is a key symptom of the disease. In our cohort, central hypoventilation occurred at a median of 5.33 years of age, 2.2 years after the onset of obesity. Sleep apnea or a pattern of mixed apnea can be described initially. All the patients were treated initially with a nocturnal NIV. Tracheostomy was reported during acute decompensation (N=5/12), and for some patients it was necessary to optimize the chronic ventilation (maximum 24h/day) (N=7/12). One patient was mentioned to have a pacemaker diaphragm without a more precise specific description of his ventilation (22).

The management of the ventilation is an essential point to avoid respiratory failure, negative impact of hypercapnia and to help control BMI. Altered ventilation can be the cause of behavioural disorders or neurocognitive impairment (23). Our data suggest such a link: the occurrence of aggressiveness or mood disorders was mostly described at a median of 1.5 years before the diagnosis and the management of the hypoventilation. In our case,

the patient presented severe aggressive angers in the beginning of the disease. With perfect management of the NIV at home and strict regularity of sleeping hours, the patient improves very well with normal behaviour for their age.

Dysautonomia is a major clinical point in the syndrome. Impaired sweating and thermal dysregulation were principally reported. Hypo or hyperthermia can be objectivized, as mentioned in 15 cases of our cohort. Therefore, temperature instability reported in a young obese patient must lead to considering the possibility of ROHHAD syndrome. Cold hands and feet were visible signs observed in 6 patients of the series. Altered perception of pain is an essential point for which the clinician has to be attentive. All the reported dysautonomia signs were independent of each other. Strabismus and sweating alteration are the first two clinical signs encountered after the initial weight gain.

NET are classically diagnosed in around 50% of ROHHAD patients (4). Our review consolidates this statistic with 56% of patients encountered with NET. The majority of the tumors were ganglioneuroma mainly located at an adrenal place. All the patients were asymptomatic, except for one with a retro pancreatic mass and a metastatic process causing weight loss and jaundice. The clinical presentation and characterization of neuroblastoma seems to be specific in ROHHAD patients compared to the general population (Table 2) (40,41) with more indolent presentation and diagnosis at an older age. Nevertheless, only one ROHHAD patient was observed with MYCN amplification, a marker of pejorative prognostic factor and correlated with aggressive features at diagnosis.

No practical recommendations are currently available to define the NET screening. In some publications, ROHHAD clinical follow-up included: urinary catecholamine's dosages, NSE (Neuron Specific Enolase (biomarker of tumor proliferation in case of neuroblastoma))

screening, MIBG I¹²³ scintigraphy or chest and abdominal MRI. In our patient, the strategy is to screen with a MIBG I¹²³ scintigraphy every year because the use of MRI is strictly restricted due to the cardiac pacemaker. An annual tumor screening seems to be the most usual clinical practice, but our survey supports the need for more frequent screening during the 2 first years after the ROHHAD diagnosis. Our data show that 70% of the NET were detected in the 2 first years after the initial weight gain and 50 % at a maximum interval time of 0.75 years. A chest and abdominal MRI should be performed every year, alternating with annual MIBG I¹²³ scintigraphy, allowing surveillance every 6 months. In case of contra indications or unavailability for one of this exam, abdominal ultrasound is recommended as an alternative option. None of the ROHHAD patients was tested positive for catecholamines to establish follow-up recommendations on this basis. On the contrary, this measure is falsely reassuring for such patients. After the two first years of follow up, annual screening should be performed based on chest and abdominal MRI or MIBG I¹²³ scintigraphy, depending on the patient's medical conditions and the local hospital conditions (Figure 5). Because of some tardive occurrence of NET and the isolated case of an aggressive tumor 11 years after the initial rapid weight gain), the screening must be continued. Decreasing the frequency of imaging to every 2 years (3) could be discussed for the adult follow up. Data from young ROHHAD(NET) adult patients are needed to improve these clinical recommendations.

Currently, there are only two recent publications with adult data. The first (21) mentioned particularities for airway management and obstructive apnea concurrent with central hypoventilation, linked to the severe obesity. The second (25) focused on the natural history of one 27 years old ROHHAD patient who presented with fatty liver disease over time and a hepatocarcinoma at 26 years. In the total cohort of the 43 patients, no other case was

described with hepatic disturbances during childhood. Jalal-Eldin *et al.* patient was also the only one with a reported diabetes diagnosed at 14 years (25). Lipid metabolic disturbances were noted for two patients (hypertriglyceridemia for one and hypercholesterolemia for the other). With regards to improving the management of metabolic disturbances, further descriptions and young adult data would be useful. Close monitoring of metabolic parameters is nevertheless recommended during the whole follow-up.

Whole exome sequencing (WES) of the patient and his parents did not identify any genetic variant that could explain the phenotype, which confirms previous reports (6,30,42-44). Nevertheless, our guidance (Figure 5) recommend WES in order to rule out other differential diagnoses. For example, Thaker *et al.*, (45) revealed a patient with a clinically similar ROHHAD evolution with a *RAI1* mutation corresponding to a diagnosis of Smith-Magenis Syndrome.

Three main hypotheses for the cause of ROHHAD are currently being discussed though research remains inconclusive. First, genetic studies investigated candidate genes in the neuronal development (among which especially *BDNF* and *TRKB*) or in the hypothalamic and autonomic dysfunction pathway (among which *HTR1a*, *OTP*, *PACAP*, *HCRT*, *HCRTR1*, *HCRTR2*) but did not identify any significant genetic variant (6,30,39,40,42-44,46). A more recent genetic study (2018) investigated the eleven genes of the Prader Willi Syndrome (PWS) region including *MAGEL2* (39). No mutations were found, however, the expression levels of these genes have not been studied in ROHHAD patients and could be altered by epigenetic or (post -) transcriptional mechanisms. A study with a pair of monozygotic twins with different phenotypes (6,30) highlights this last notion and is consistent with the second etiological hypothesis, epigenetic disturbance. For the monozygotic twins the accumulation

of variants in their epigenome is indeed the main factor influencing their phenotype differences.

Finally, some literature suggests an autoimmune origin for the ROHHAD syndrome. Immunosuppressive treatment with high dose cyclophosphamide were reported to have positive effects, in particular on BMI stability and on neuropsychological function, but with limited follow-up data (maximum 18 months backward) (24,31). Two patients were found to have an intrathecal synthesis of oligoclonal bands at the time of diagnosis (33) but no other cases reported a measurement of oligoclonal bands in our cohort, in addition our patient tested negative. An immune process was also supported by the unique autopsy of a 5 year old girl with ROHHAD with evidence of hypothalamic encephalitis with a perivascular and mild parenchymal chronic inflammatory infiltrate of CD3 T cells without vascular necrosis (34). Giacomozzi *et al*, 2019, appear to go further with the identification for the first time of anti-pituitary and anti-hypothalamus autoantibodies on serum and CSF in a case of a ROHHAD girl who died at 3 years of age (5).

In our review, immunomodulating treatments were described for 6 patients, with the use of glucocorticoids, or intravenous gamma globulin or specific immunosuppressive treatments (cyclophosphamide, rituximab). These data were not specifically analysed because of the lack of precise information (time of administration, different dosages).

ROHHAD(NET) syndrome is considered as a life threatening condition with death occurring around the age of 10 years (8). In this review, the median age of death was estimated at 4,6 (4,5-6,3) of years (age of death only reported for 3 patients) but 26 patients were still alive at the end of the follow-up. Two of the six patients died as a result of sudden cardiac arrest. The young age at death could suggest that some cases may occur with more severe initial

clinical presentation. Early death can also be linked to a delayed diagnosis affecting the initial management which is essential for a better life support.

Conclusion

We report a ROHHAD case with early diagnosis and a multidisciplinary care program. This illustrates the need for clear diagnosis criteria and standardized monitoring. Based on a literature review, we propose several recommendations for the diagnosis and follow-up of these patients in the absence of reliable biomarkers and a clear aetiology. Early diagnosis and appropriate follow-up probably significantly improve prognosis and life expectancy.

Accepted Manuscript

Data availability

The datasets generated during and/or analysed during the current study are not publicly available but are available from the corresponding author on reasonable request.

Acknowledgments

The authors thank the proband and his parents for their assistance and participation in this study.

Accepted Manuscript

References

1. Fishman LS, Samson JH, Sperling DR. Primary alveolar hypoventilation syndrome (Ondine's curse). Association with manifestation of hypothalamic disease. *Am J Dis Child.* 1965;110:155-161.
2. Katz ES, McGrath S, Marcus CL. Late-onset central hypoventilation with hypothalamic dysfunction: a distinct clinical syndrome. *Pediatr Pulmonol.* 2000;29(1):62-68.
3. Ize-Ludlow D, Gray JA, Sperling MA, et al. Rapid-Onset Obesity With Hypothalamic Dysfunction, Hypoventilation, and Autonomic Dysregulation Presenting in Childhood. *Pediatrics.* 2007;120(1):e179-e188.
4. Bougnères P, Pantalone L, Linglart A, Rothenbühler A, Le Stunff C. Endocrine Manifestations of the Rapid-Onset Obesity with Hypoventilation, Hypothalamic, Autonomic Dysregulation, and Neural Tumor Syndrome in Childhood. *J Clin Endocrinol Metab.* 2008;93(10):3971-3980.
5. Giacomozzi C, Guaraldi F, Cambiaso P, et al. Anti-Hypothalamus and Anti-Pituitary Autoantibodies in ROHHAD Syndrome: Additional Evidence Supporting an Autoimmune Etiopathogenesis. *Horm Res Paediatr.* 2019:1–9.
6. Barclay SF, Rand CM, Borch LA, et al. Rapid-Onset Obesity with Hypothalamic Dysfunction, Hypoventilation, and Autonomic Dysregulation (ROHHAD): exome sequencing of trios, monozygotic twins and tumours. *Orphanet J Rare Dis.* 2015;10 (103) :1-13..
7. Stewart LA, Clarke M, Rovers M, et al. Preferred Reporting Items for Systematic Review and Meta-Analyses of individual participant data: the PRISMA-IPD Statement. *JAMA.* 2015;313(16):1657-1665.
8. Aljabban L, Kassab L, Bakoura NA, Alsalka MF, Maksoud I. Rapid-onset obesity, hypoventilation, hypothalamic dysfunction, autonomic dysregulation and neuroendocrine tumor syndrome with a homogenous enlargement of the pituitary gland: a case report. *J Med Case Reports.* 2016;10 (328) :1-9.
9. Abaci A, Catli G, Bayram E, et al. A case of rapid-onset obesity with hypothalamic dysfunction, hypoventilation, autonomic dysregulation, and neural crest tumor: ROHHADNET syndrome. *Endocr Pract.* 2012;19(1):e12–e16.
10. Al-Harbi AS, Al-Shamrani A, Al-Shawwa BA. Rapid-onset obesity, hypothalamic dysfunction, hypoventilation, and autonomic dysregulation in Saudi Arabia. *Saudi Med J.* 2016 Nov;37(11):1258–60.
11. Atapattu N, Dissanayaka L, Arulmoli S. A case of Rapid Onset Obesity, Hypoventilation, Hypothalamic Dysregulation and neuroendocrine Tumours-ROHHADNET Syndrome. *Horm Res Paediatr.* 2015;84 (suppl 1):438.(Abstract P3-898)
12. Bagheri B, Pourbakhtyaran E, Kiasari FT, Taherkhanchi B, Salarian S, Sadeghi A. Rapid-Onset Obesity with Hypothalamic Dysfunction, Hypoventilation, and Autonomic Dysregulation (ROHHAD) Syndrome: A Case Report. *Arch Pediatr Infect Dis.* 2017 Jan ;5(1) :e38351.
13. Baronio F, Marsigli A, Rinaldini D et al. Rapid Onset Obesity, endocrine hypertension and ganglioneuroblastoma intermixed: early manifestation of ROHHAD-NET syndrome?

- Presentation of two cases. 9th joint meeting of paediatric endocrinology. *Horm Res*. 2013;80 Suppl 1:427.(Abstract P3-d1-1406)
14. Calvo C, Storey C, Morcrette G, et al. Metastatic neuroblastoma in a patient with ROHHAD: A new alert regarding the risk of aggressive malignancies in this rare condition. *Pediatr Blood Cancer*. 2019;66(10):e27906.
 15. Cemeroglu AP, Eng DS, Most LA, Stalsonburg CM, Kleis L. Rapid-onset obesity with hypothalamic dysfunction, hypoventilation, and autonomic dysregulation syndrome and celiac disease in a 13-year-old girl: further evidence for autoimmunity? *J Pediatr Endocrinol Metab*. 2016;29(1):97–101.
 16. Chandrakantan A, Poulton TJ. Anesthetic considerations for rapid-onset obesity, hypoventilation, hypothalamic dysfunction, and autonomic dysfunction (ROHHAD) syndrome in children. *Pediatr Anesth*. 2013;23(1):28–32.
 17. Chew HB, Ngu LH, Keng WT. Rapid-onset obesity with hypothalamic dysfunction, hypoventilation and autonomic dysregulation (ROHHAD): a case with additional features and review of the literature. *BMJ Case Rep* [Internet]. 2011 Jan 25. Available from: <https://www.ncbi.nlm.nih.gov/pmc/articles/PMC3062047/>
 18. Dhondt K, Verloo P, Verhelst H, Van Coster R, Overeem S. Hypocretin-1 Deficiency in a Girl With ROHHAD Syndrome. *PEDIATRICS*. 2013 Sep 1;132(3):e788–92.
 19. Gallizia A, Napoli F, Ceccherini I, Ottonello G, Di Lorgi N et al. Rapid-onset obesity, hypoventilation, hypothalamic dysfunction, autonomic dysregulation, and neural crest tumour (ROHHADNET) syndrome in two Italian patients: clinical characterization and exome sequencing analysis. *Horm Res*. 2012;78(Suppl1):172.(Abstract P2-d2-557)
 20. Gordon SC, CM Rand, T Stewart et al. The Evolving Phenotype in a Patient with Rapid-Onset Obesity with Hypothalamic Dysfunction, Hypoventilation, and Autonomic Dysregulation (ROHHAD) and Response to Caffeine Treatment | D41. INTERESTING CASES IN PEDIATRIC PULMONOLOGY. *Am Thorac Soc Int Conf Meet, Colorado, 2015. (Abstract available from https://www.atsjournals.org/doi/pdf/10.1164/ajrccm-conference.2015.191.1_MeetingAbstracts.A5923)*
 21. Graziani A, Casalini P, Mirici-Cappa F, Pezzi G, Stefanini FG. Hypoventilation improvement in an adult non-invasively ventilated patient with Rapid-Onset Obesity with Hypothalamic Dysfunction Hypoventilation and Autonomic Dysregulation (ROHHAD). *Pneumologia*. 2016;4:222-224.
 22. Grudnikoff E, Foley C, Poole C, Theodosiadis E. Nocturnal Anxiety in a Youth with Rapid-onset Obesity, Hypothalamic Dysfunction, Hypoventilation, and Autonomic Dysregulation (ROHHAD). *J Can Acad Child Adolesc Psychiatry*. 2013;22(3):235-237.
 23. Ibáñez-Micó S, Marcos Oltra AM, de Murcia Lemauviel S, Ruiz Pruneda R, Martínez Ferrández C, Domingo Jiménez R. Síndrome ROHHAD (obesidad de rápida progresión, disfunción hipotalámica, hipoventilación y disregulación autonómica). Presentación de un caso y revisión de la literatura. *Neurología*. 2017;32(9):616-622.
 24. Jacobson LA, Rane S, McReynolds LJ, Steppan DA, Chen AR, Paz-Priel I. Improved Behavior and Neuropsychological Function in Children With ROHHAD After High-Dose Cyclophosphamide. *PEDIATRICS*. 2016;138(1):e20151080.

25. Jalal Eldin AW, Tombayoglu D, Butz L, et al. Natural history of ROHHAD syndrome: development of severe insulin resistance and fatty liver disease over time. *Clin Diabetes Endocrinol.* 2019;5 (9) :1-7..
26. Kocaay P, Şıklar Z, Çamtosun E, Kendirli T, Berberoğlu M. ROHHAD Syndrome: Reasons for Diagnostic Difficulties in Obesity. *J Clin Res Pediatr Endocrinol.* 2014;6(4):254-257.
27. Kot K, Moszczyńska E, Lecka-Ambroziak A, Migdał M, Szalecki M. ROHHAD in 9-year-old boy — clinical case. *Endokrynol Pol.* 2016;67(2):226-231.
28. Lucas-Herald AK, Davidson M, Davies P, et al. Two children with rapid onset obesity combined with respiratory and endocrine dysfunction. do they have ROHHAD? *Arch Dis Child.* 2012;97(Suppl 1):A119-A119.
29. Lim SH, Jeon SY, Jeon IS, Kang MH. Rapid-onset obesity with hypothalamic dysfunction, hypoventilation, and autonomic dysregulation associated with neuroblastoma. *Pediatr Blood Cancer.* 2018 Jun;65(6):e26983.
30. Patwari PP, Rand CM, Berry-Kravis EM, Ize-Ludlow D, Weese-Mayer DE. Monozygotic Twins Discordant for ROHHAD Phenotype. *PEDIATRICS.* 2011;128:e711-715.
31. Paz-Priel I, Cooke DW, Chen AR. Cyclophosphamide for Rapid-Onset Obesity, Hypothalamic Dysfunction, Hypoventilation, and Autonomic Dysregulation Syndrome. *J Pediatr.* 2011;158(2):337-339.
32. Sanklecha M, Sundaresan S, Udani V. ROHHAD Syndrome: The Girl who Forgets to Breathe. *Indian Pediatrics.* 2016;53:343-344.
33. Sartori S, Priante E, Pettenazzo A, et al. Intrathecal Synthesis of Oligoclonal Bands in Rapid-Onset Obesity With Hypothalamic Dysfunction, Hypoventilation, and Autonomic Dysregulation Syndrome: New Evidence Supporting Immunological Pathogenesis. *J Child Neurol.* 2014;29(3):421-425.
34. Sethi K, Lee Y-H, Daugherty LE, et al. ROHHADNET Syndrome Presenting as Major Behavioral Changes in a 5-Year-Old Obese Girl. *PEDIATRICS.* 2014;134(2):e586-e589.
35. Şiraz ÜG, Ökdemir D, Direk G, Akın L, Hatipoğlu N, Kendirci M, et al. ROHHAD Syndrome, a Rare Cause of Hypothalamic Obesity: Report of Two Cases. *J Clin Res Pediatr Endocrinol.* 2018 Dec;10(4):382-6.
36. Sumanasena SP, de Silva S, Perera I, Sudeen A, Wasala R. Rapid onset obesity, hypoventilation, hypothalamic, autonomic and thermal dysregulation, and neural tumour (ROHHADNET) syndrome presenting with Cushing syndrome. *Ceylon Med J.* 2012;57(1):47-48.
37. Ucar A, Bas F, Umur O, Yilmaz Y, Poyrazoglu S, Bundak R, Saka N, Darendeliler F. A case of rapid-onset obesity with hypothalamic dysfunction, hypoventilation, autonomic dysregulation : ROHHAD Syndrome. 9th joint meeting of pediatric endocrinology. *Horm Res.* 2013;80 (Suppl 1):241.(Abstract P2-d3-771)
38. Van Tellingen V, Van Trotsenburg P. Obesity in ROHHADNET Syndrome : Does cortisol play a role? *Horm Res Paediatr.* 2015;84 (suppl 1):230.(Abstract P2-384)
39. Barclay SF, Rand CM, Nguyen L, et al. ROHHAD and Prader-Willi syndrome (PWS): clinical and genetic comparison. *Orphanet J Rare Dis.* 2018;13 (124) :1-9..

40. Shohet J, Foster J. Neuroblastoma. *BMJ*. May 2017;j1863.
41. Swift CC, Eklund MJ, Kravaka JM, Alazraki AL. Updates in Diagnosis, Management, and Treatment of Neuroblastoma. *RadioGraphics*. 2018;38(2):566-580.
42. Patwari PP, Wolfe LF. Rapid-onset obesity with hypothalamic dysfunction, hypoventilation, and autonomic dysregulation: review and update. *Curr Opin Pediatr*. 2014;26(4):487–492.
43. Rand CM, Patwari PP, Rodikova EA, et al. Rapid-onset obesity with hypothalamic dysfunction, hypoventilation, and autonomic dysregulation: analysis of hypothalamic and autonomic candidate genes. *Pediatr Res*. 2011;70(4):375–378.
44. Barclay SF, Rand CM, Gray PA, et al. Absence of mutations in *HCRT*, *HCRTR1* and *HCRTR2* in patients with ROHHAD. *Respir Physiol Neurobiol*. 2016;221:59-63.
45. Thaker VV, Esteves KM, Towne MC, et al. Whole Exome Sequencing Identifies *RAI1* Mutation in a Morbidly Obese Child Diagnosed With ROHHAD Syndrome. *J Clin Endocrinol Metab*. 2015;100(5):1723-1730.
46. Lee JM, Shin J, Kim S, et al. Rapid-Onset Obesity with Hypoventilation, Hypothalamic, Autonomic Dysregulation, and Neuroendocrine Tumors (ROHHADNET) Syndrome: A Systematic Review. *BioMed Res Int*. 2018; 2018:1-17.

Accepted Manuscript

Legends

Figure 1: Weight, Height and BMI Curve of our patient (Growth Chart Flanders, 2004). Rapid weight gain since the age of three years, with progressive stabilisation of BMI, due to strict control of calorie intake and daily physical activities.

Arrow a: Time of ROHHAD diagnosis and start NIV during sleeping time.

Arrow b: Pacemaker implantation.

Figure 2: PRISMA IPD Flow Diagram (Based on Reference 7).

Figure 3: ROHHAD(NET) general timeline.

Age of outcome for each specific term of the ROHHAD(NET) Acronym.

Box plots show the median values and the first and third quartiles for each group. T-bars represent the rest of the data. Outlier data were not removed.

The grey cross shows the time of outcome of each symptoms for our patient. No NET was detected at that time, after three years and six months of follow-up.

Figure 4a: Hypothalamic dysfunction.

Age of outcome for the main hypothalamic disorders reported in ROHHAD(NET).

All the symptoms have appeared before 10 years of age, except rationally for the delayed puberty. Box plots show the median values and the first and third quartiles for each group. T-bars represent the rest of the data.

Figure 4b: Hypothalamic dysfunction.

Number of symptoms encountered by patients during the course of the disease.

Figure 4c: Hypoventilation.

Age of outcome of the different type of respiratory events reported in the cohort. Central and obstructive hypoventilation were reported, acute respiratory distress was mentioned for 11 patients and therapeutic management was reported with NIV or Tracheostomy.

Figure 4d: Autonomic dysregulation.

Age of outcome of the different types of autonomic dysregulation and therapeutic management. The grey cross shows the time of pacemaker implantation for our patient, at the younger age currently described.

Figure 5 : Guidance for management and follow-up in ROHHAD(NET) Syndrome.

Multidisciplinary approach is highlighted. All the caregivers should be supported by a Reference Centre for Rare Disease.

Table 1: Description of different types of autonomic dysregulations reported in ROHHAD(NET) and the median age of outcome.

N= number of patients reported with the symptom.

Table 2: Comparison between NET in the general population and in ROHHAD(NET) patients. NET refers to neural crest tumors. Neuroblastoma is commonly used to describe a spectrum of neuroblastic tumors including neuroblastomas (the most common type), ganglioneuroblastomas and ganglioneuromas (40).

MYCN gene is a cellular protooncogene : its amplification in the tumor is a pejorative factor.

Accepted Manuscript

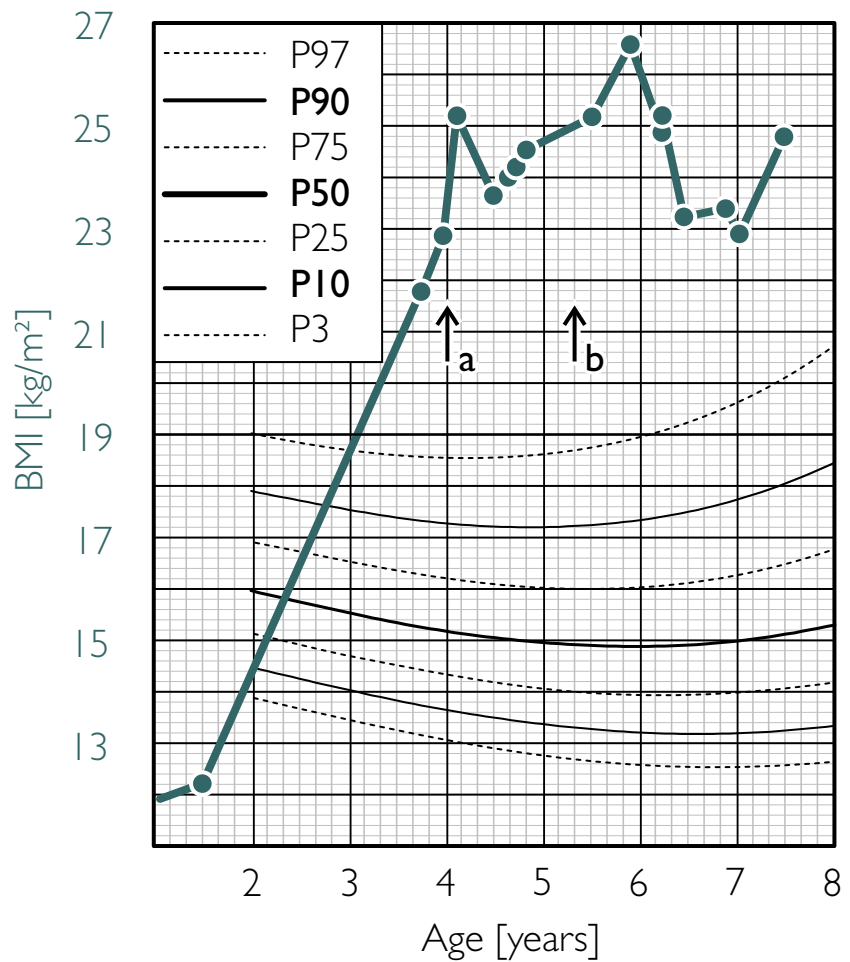
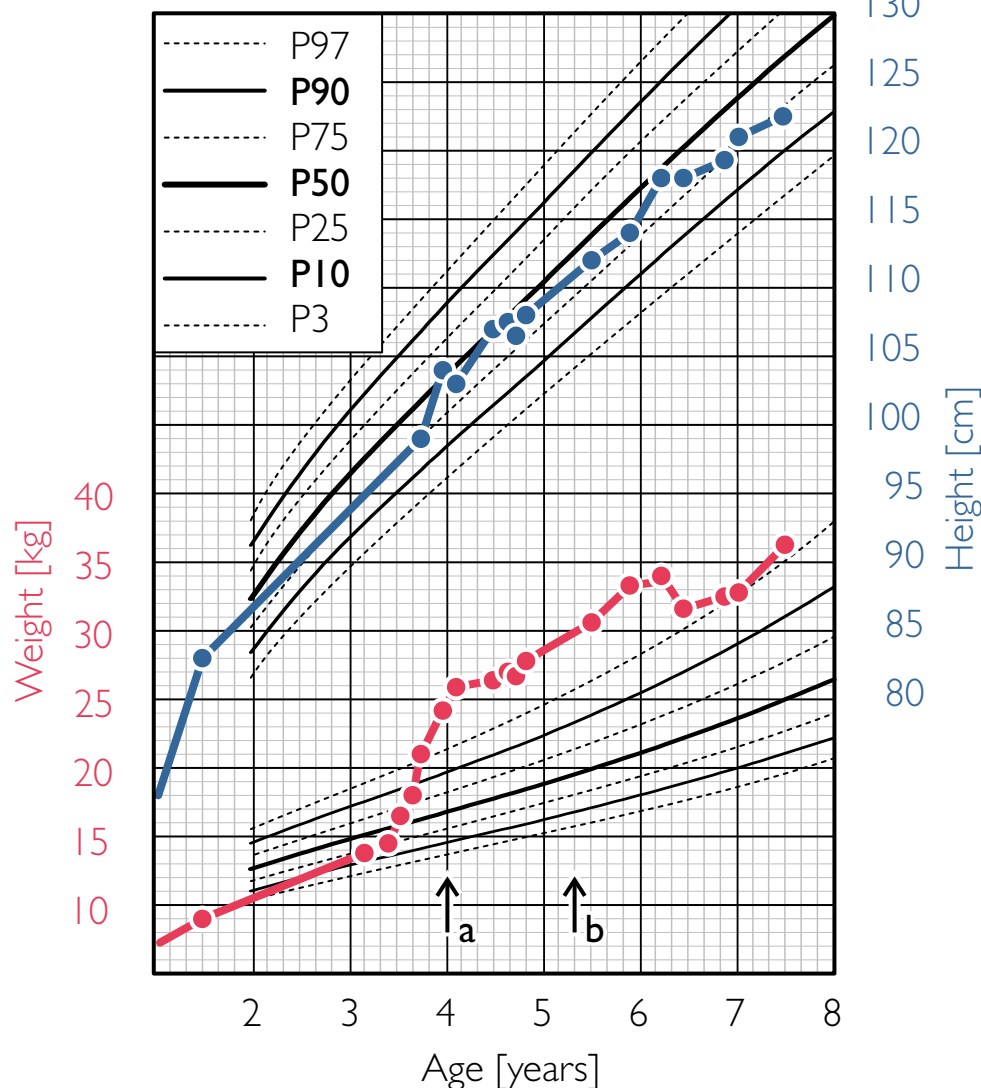
Table 1.

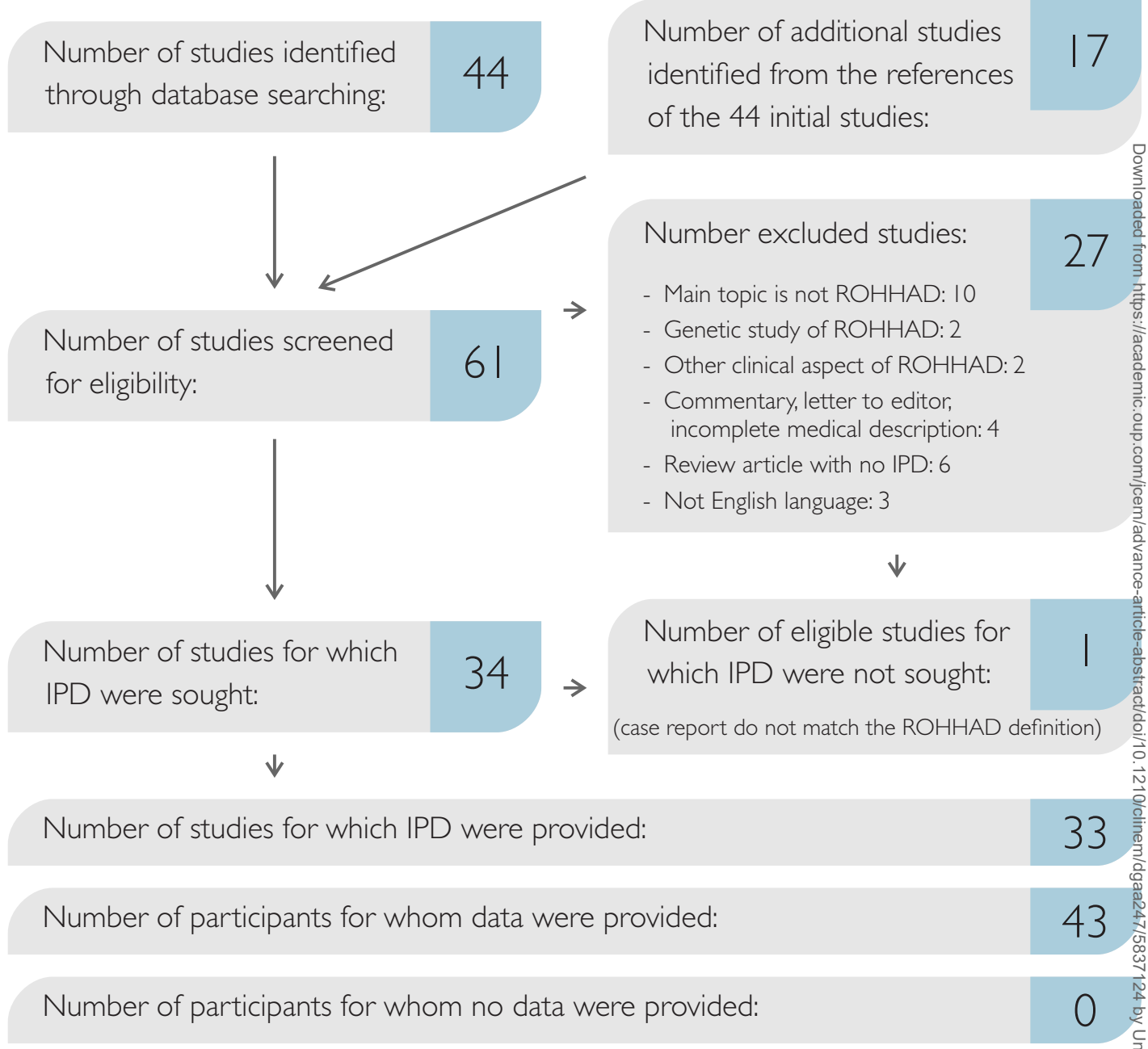
	N	MEAN AGE (Years)	MEDIAN	SD
Autonomic dysregulation				
Digestive				
Gastrointestinal dysmotility	4	4.9	4.1	2.1
Constipation	2	6.3	6.3	2.4
Ophthalmic				
Strabismus	6	4.7	3.0	4.6
Other ophthalmic manifestations	5	4.7	4.5	1.1
Bilateral ptosis	1	3.4	3.4	/
Thermic				
Cold hands and feet	6	4.8	4.2	2.7
Thermal dysregulation	23	7.8	7.3	3.9
Hypo/hyperthermia	15	/	/	/
Altered sweating	10	5.4	4.2	3.4
Cardiac				
Bradycardia	8	6.6	5.3	3.8
Syncope	1	3.0	3.0	
PCMK implantation	3	7.9	7.5	2.7
Painfulness				
Altered perception of pain	7	3.9	3.8	1.7
Others				
Dysarthria	2	11.0	11.0	5.7
Pulmonary hypertension	1	9.0	9.0	/

*Hypothermia N=4/Hyperthermia N=6/Both episodes of hypo- and hyperthermia N=5

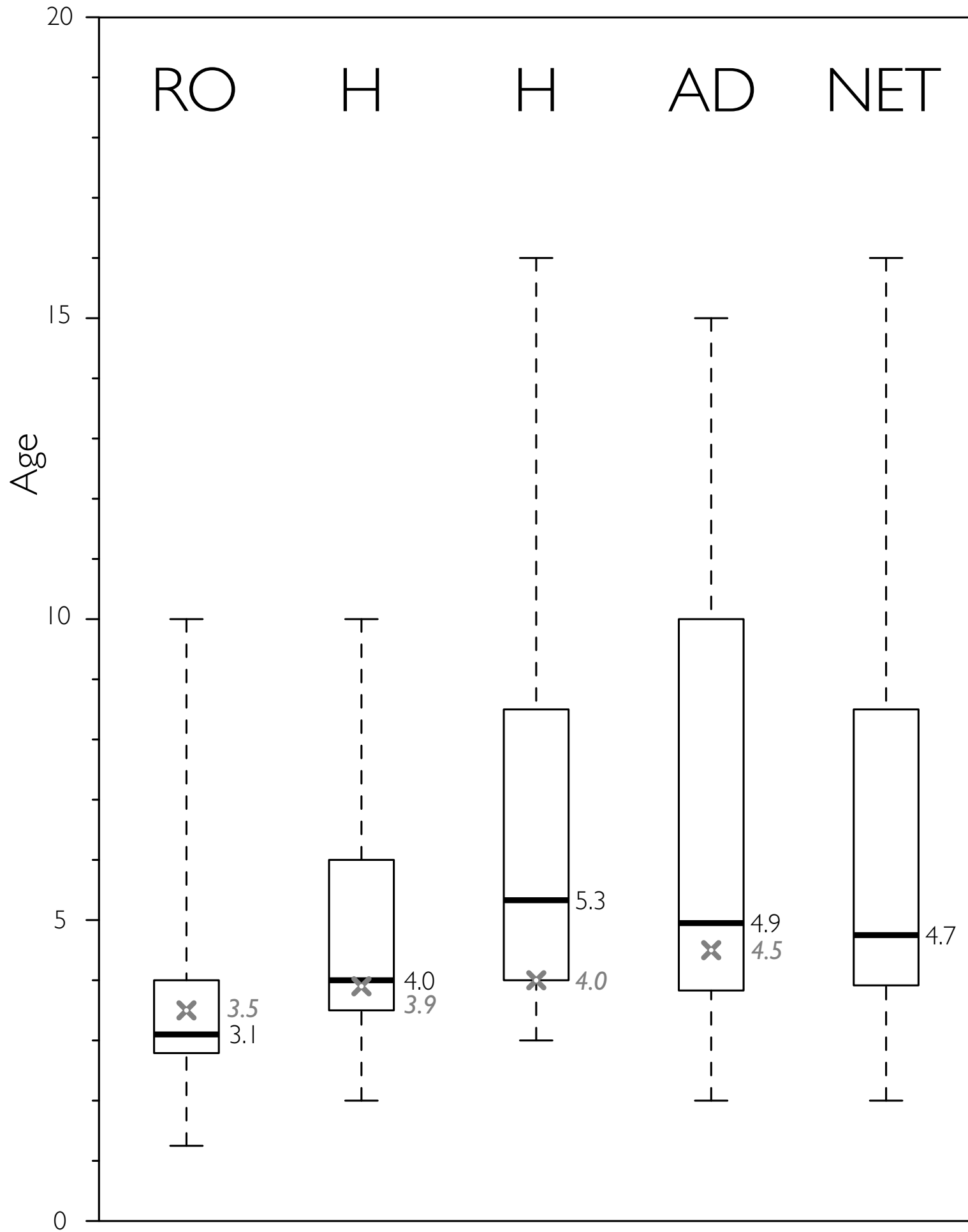
Table 2

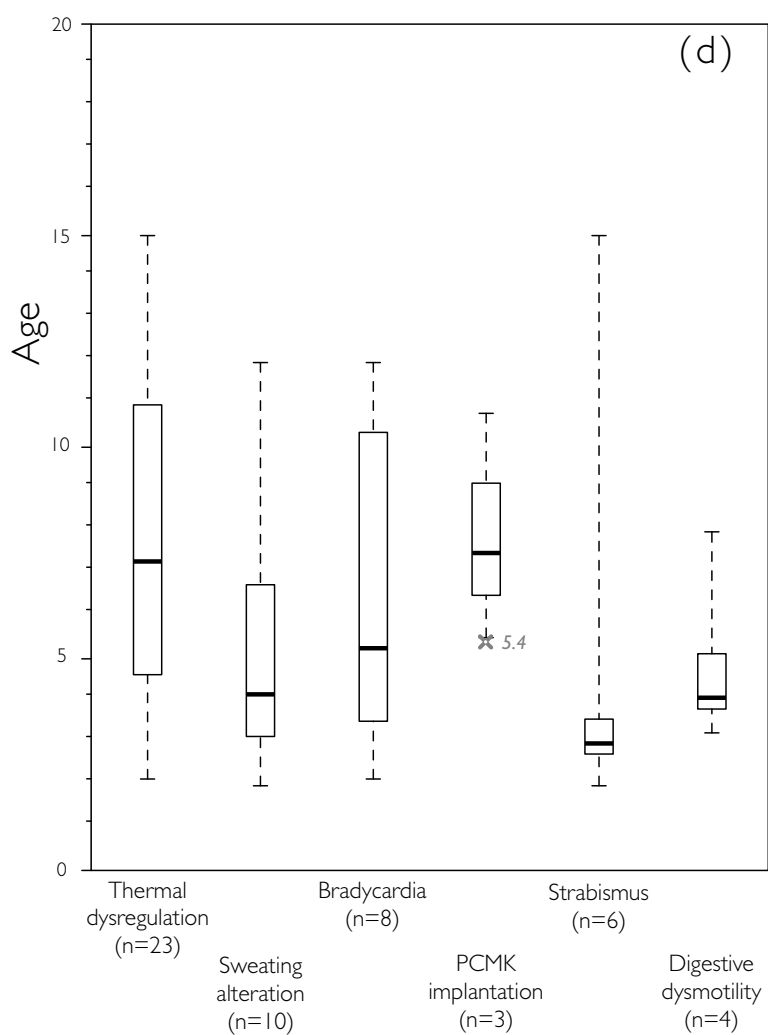
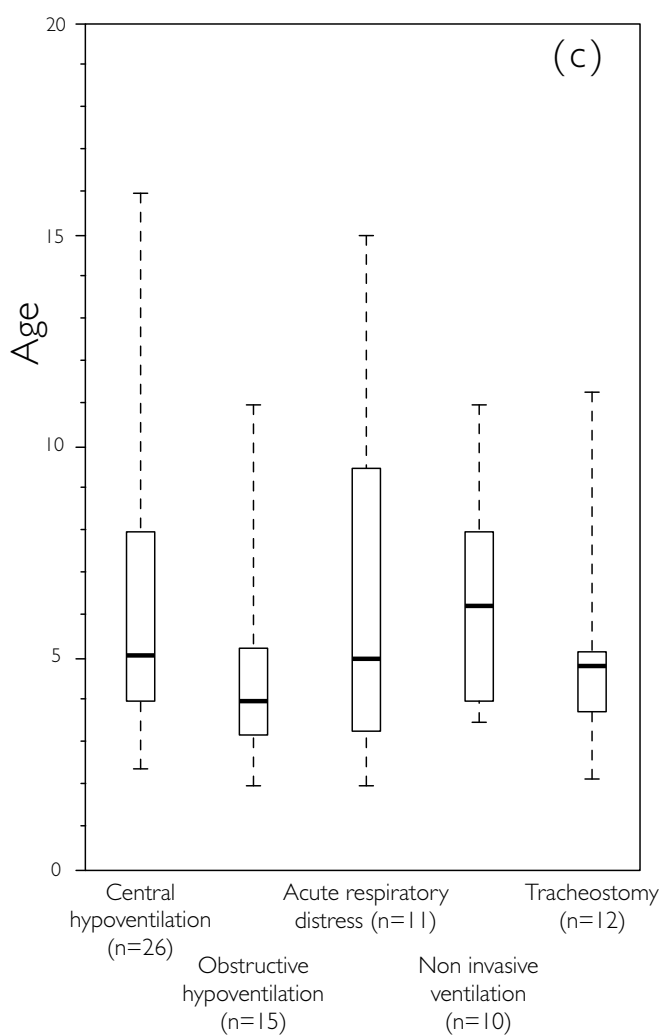
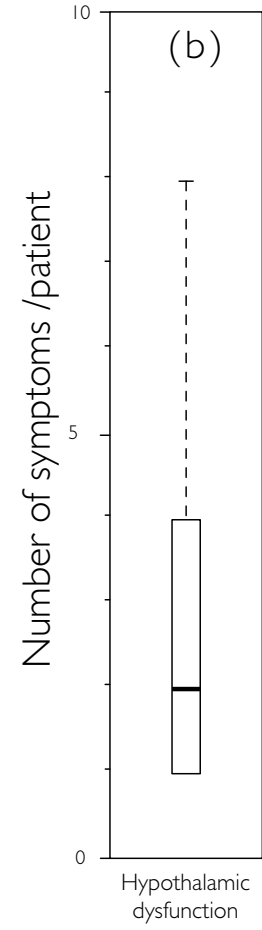
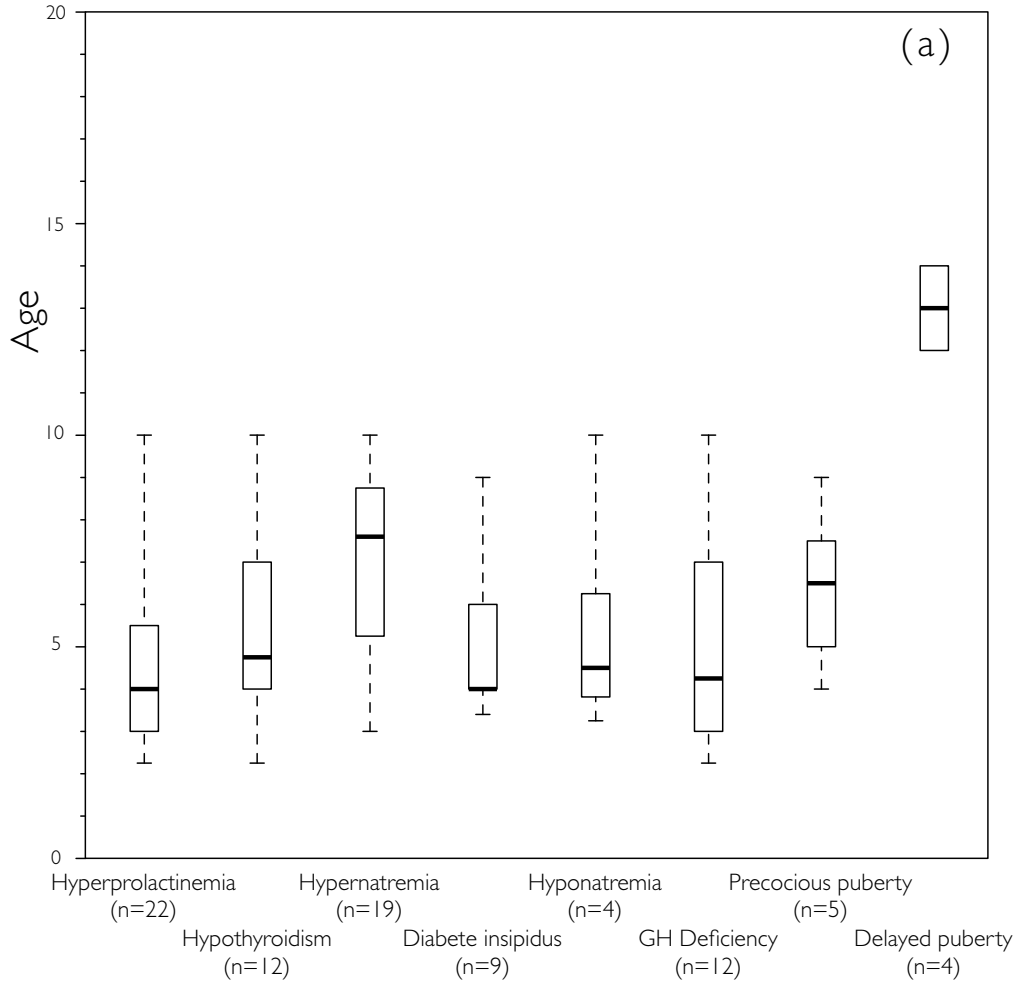
	General population (40,41)	ROHHAD(NET) patients (N=24)
Epidemiology	Incidence 1/10000 live-born	56 % in the cohort (n=24/43)
Median Age of diagnosis	19 months	4.75 years
Localisation	1/Adrenal (46%) 2/Extra adrenal abdominal location (18%) 3/Posterior mediastinum or thorax (14%)	1/Adrenal (N=9) 2/Thoracic (N=5) 3/Paravertebral cervical (N=1)
Catecholamine's metabolising	Positive in 75% of the patients (high levels of vanilylmandelic acid and homovanilic acid)	Never reported as pathologic
Symptomatology	Abdominal pain or distension Hypertension Scoliosis Neurologic signs (medullar compression)	No relevant symptoms Diagnosis made during screening
Metastasis at diagnosis	50% of cases	1 case (N=1/24)
Staging	Low risk Intermediate risk High risk 50%	1 metastatic case (N=1/24) 1 high risk reported (N=1/24)
MYCN amplification (pejorative factor)	20% of the primitive tumors	1 case reported





Number of studies included	Main outcomes	Number of participants included	Number of participants excluded
33	Gender	37	0
	Hypothalamic Dysfunction	43	
	Hypoventilation	41	
	Autonomic dysregulation	35	
	Tumor of neural crest origin	24	
	Psychiatric symptoms	23	
	Other manifestations	33	
	Outcomes	32	





Investigations/Screening	Therapeutic options
Ro/ Rapid obesity	
<ul style="list-style-type: none"> - Initial clinical and biological general evaluation - Cerebral MRI to exclude central tumor - Complete endocrine work up <ul style="list-style-type: none"> * to exclude other differential diagnosis of precocious obesity * evaluation of metabolic disturbances: dyslipidaemia, insulin resistance min 1x/year 	<ul style="list-style-type: none"> - BMI stabilisation <ul style="list-style-type: none"> * strict calorie intake control * regular physical activities (endurance training) - Oral Antidiabetic drugs (in case of confirmed diabetes) - Anti lipid treatment
H/ Hypothalamic dysfunction	
<ul style="list-style-type: none"> - Hormonal investigations : 1-2x/year: <ul style="list-style-type: none"> * Hypothyroidism? * Hyperprolactinemia? * GH deficiency? * Puberty delay? * Adrenal insufficiency? * ...? 	<ul style="list-style-type: none"> - Specific hormonal substitution (according to biological results)
H/ Hypoventilation	
<ul style="list-style-type: none"> - Polysomnography + nocturnal gaz exchange: Nocturnal hypoventilation? <ul style="list-style-type: none"> * If negative: control 1x/year during 5 years * After 5 years: control according to the symptoms - Prevention of respiratory infections 	<ul style="list-style-type: none"> - Artificial ventilation: <ul style="list-style-type: none"> * NIV (during sleeping time or 24h/day) * Tracheostomy * Diaphragmatic pacemaker - Influenza vaccination (winter) 1x/year (according to local recommendations) - Eviction from school at first respiratory symptoms - Consider antibiotics treatment - Airway support
Ad/ Autonomic dysregulation	
<ul style="list-style-type: none"> - ECG- Cardiac ultrasound: 1x/year - 72h Holter 1x/year + repeat in case of syncopes (risk of severe bradycardia) - Control blood pressure <ul style="list-style-type: none"> * 1x/3months, and at each medical visit * Monitoring blood pressure during VNI monitoring (at hospital) - Gastro-enterologic screening 1x/year <ul style="list-style-type: none"> * Celiac disease: transglutaminases autoantibodies analysis 1x/year * Screening for food intolerance according to symptoms * Transit dysregulation: constipation/diarrhea - Ophthalmologic evaluation: 1x/year <ul style="list-style-type: none"> * Strabismus? * Delayed pupil response to light? 	<ul style="list-style-type: none"> - Cardiac pacemaker - Anti-hypertensive drugs - Gluten free diet - Lactose free diet - Drugs for transit control
NET/ Neural tumor	
<ul style="list-style-type: none"> - Screening program to detect NET <ul style="list-style-type: none"> * Chest and Abdominal MRI 1x/year * MIBG I¹²³ scintigraphy 1x/year (Abdominal ultrasound in case of MIBG scintigraphy or MRI not available). > Resulting in an exam every 6 months during 2 years. - After 2 years of follow up : <ul style="list-style-type: none"> * Chest and abdominal MRI 1x/year (or MIBG I¹²³ scintigraphy depending of patient and hospital conditions) 	<ul style="list-style-type: none"> - In case of NET: Staging of the tumor and recommended treatment <ul style="list-style-type: none"> * low risk: surgical option * high risk: multimodal and aggressive treatment
Neurologic Impact	
<ul style="list-style-type: none"> - EEG in case of seizures - Behavioral disturbances: hallucinations, aggressiveness, flat affect ... 	<ul style="list-style-type: none"> - Anti-epileptic drugs - Anti psychotic drugs or specific treatment if symptoms are not controlled
Genetic considerations	
<ul style="list-style-type: none"> - Exclude a <i>PHOX2B</i> mutation - Exclude Genetic Obesity (consider Prader-Willi Syndrome) - Whole Exome Sequencing: to exclude other genetic diagnosis 	