

Absence of aromatase protein and mRNA expression in endometriosis

S. Colette¹, J.C. Lousse¹, S. Defrère¹, M. Curaba¹, J.F. Heilier²,
A. Van Langendonck¹, M. Mestdagt³, J.M. Foidart³, E. Loumaye⁴,
and J. Donnez^{1,5}

¹Université Catholique de Louvain, Faculty of Medicine, Gynecology Unit, 1200 Brussels, Belgium ²Université Catholique de Louvain, Faculty of Medicine, Industrial Toxicology and Occupational Medicine Unit, 1200 Brussels, Belgium ³Université de Liège, Laboratory of Tumor and Development Biology, 4000 Liège, Belgium

⁴PregLem S.A, 1228 Plan-les Ouates, Geneva, Switzerland

⁵Correspondence address. Tel: +32-2-764-95-01; Fax: +32-2-764-95-07; E-mail: jacques.donnez@uclouvain.be/anne.lepage@uclouvain.be

BACKGROUND: Aromatase has been reported to be involved in estrogen biosynthesis and expressed in eutopic and ectopic endometrium of endometriosis patients. The objective of the present study was to investigate its expression and localization in three distinct types of endometriosis.

METHODS: Human peritoneal, ovarian and rectovaginal endometriotic lesions and matched eutopic endometrium were collected from patients during laparoscopy. Aromatase protein localization (immunohistochemistry, $n = 63$) and mRNA expression [quantitative polymerase chain reaction (Q-PCR), $n = 64$] were assessed.

RESULTS: No aromatase protein was detected by immunohistochemistry in either the glandular or stromal compartment of endometriotic lesions or eutopic endometrium, while it was strong in placental syncytiotrophoblasts, granulosa and internal theca cells from pre-ovulatory follicles, and luteal cells from corpus luteum. By Q-PCR, low but discernible levels of aromatase expression were found in endometriomas, probably due to follicular expression. Transcripts for aromatase were barely detectable in only a few peritoneal and rectovaginal endometriotic lesions, and a few eutopic endometrium samples, probably due to contaminating surrounding tissues (adipose tissue, intact peritoneum).

CONCLUSIONS: Unlike previous studies, we observed no aromatase protein in any of the endometriosis types, and barely detectable aromatase mRNA expression, suggesting that locally produced aromatase (within endometriotic lesions) may be less implicated in endometriosis development than previously postulated. Potential factors responsible for these discrepancies are discussed.

Key words: aromatase / peritoneal endometriosis / ovarian endometriosis / rectovaginal endometriosis

Introduction

Endometriosis is one of the most commonly encountered benign gynecological disorders, characterized by the proliferation of endometrial glands and stroma outside the uterine cavity. The prevalence of endometriosis varies considerably from study to study. Approximately 10–15% of reproductive-age women are affected, but this figure rises to 40% of women presenting with infertility (Donnez *et al.*, 2002). We have identified three types of endometriosis, each with a different pathogenesis: peritoneal, ovarian and rectovaginal (Nisolle and Donnez, 1997).

The origin and establishment of peritoneal endometriosis can be explained by the ability of endometrial cells to survive, adhere, invade tissues and proliferate outside their eutopic location, according

to Sampson's implantation theory (Sampson, 1927; Nisolle and Donnez, 1997). In case of ovarian endometriosis, the presence of mesothelial invagination in continuum with endometriotic tissue suggests a metaplastic histogenesis of ovarian endometriotic lesions, but endometriotic cysts may also originate from invagination of superficial endometriotic implants. For rectovaginal nodules, immunocytochemical results show poor differentiation and hormonal independence of these lesions, and point to a close relationship with their mesodermal Müllerian origin (Nisolle and Donnez, 1997).

Endometriosis develops mostly in women of reproductive age and regresses after menopause or ovariectomy, clearly implicating estrogen in the establishment and maintenance of this disease. Most pharmacotherapeutic strategies against endometriosis are therefore designed to generate a low-estrogen milieu (Mihalyi *et al.*, 2006).

Aromatase is a key enzyme synthesizing estrogens from androgens, being involved in the conversion of androstenedione and testosterone to estrone and estradiol (E₂), respectively. Only one single gene (CYP19) encodes aromatase in mice and humans. In a number of species, including humans, aromatase expression shows broad tissue distribution and is found in the placenta, gonads, brain, adipose tissue and bone (Simpson et al., 1994). This enzyme is localized in the endoplasmic reticulum of estrogen-producing cells (Bulun et al., 2001; Simpson et al., 2001). Aromatase expression is essential for reproductive development and fertility, and aberrant aromatase expression in tissues is associated with a number of pathological conditions, including gynecomastia and sexual precocity, tumors of the breast, testes, liver, adrenal cortex and uterus, and endometriosis (Conley and Hinshelwood, 2001).

Aromatase expression in endometriosis has now been confirmed in numerous reports at the transcriptional level (Noble et al., 1996; Dheenadayalu et al., 2002; Ishihara et al., 2003; Heilier et al., 2006a, b; Matsuzaki et al., 2006; Bukulmez et al., 2007; Dassen et al., 2007; Kyama et al., 2007; Smuc et al., 2007; Attar et al., 2008; Smuc et al., 2008), activity level (Kitawaki et al., 1997; Noble et al., 1997; Murakami et al., 2006; Purohit et al., 2007) and protein level (Kitawaki et al., 1997, 1999a, b; Ishihara et al., 2003; Wölfler et al., 2005; Murakami et al., 2006; Velasco et al., 2006; Acien et al., 2007; Bukulmez et al., 2007; Hudelist et al., 2007). However, there is no consensus on its localization, since some authors found aromatase protein in stromal components (Fazleabas et al., 2003; Wölfler et al., 2005; Velasco et al., 2006; Acien et al., 2007), while others demonstrated glandular localization (Kitawaki et al., 1997, 1999a, b; Ishihara et al., 2003; Wölfler et al., 2005; Matsuzaki et al., 2006; Fechner et al., 2007; Hudelist et al., 2007). In addition, the extent of aromatase mRNA expression in endometriotic tissue is controversial, with published papers showing widely varying values (from barely detectable levels to a 530-fold increase!) (Heilier et al., 2006b; Bukulmez et al., 2007; Dassen et al., 2007; Kyama et al., 2007; Smuc et al., 2007; Aghajanova et al., 2009). Moreover, Delvoux et al. (2008) recently showed a complete absence of aromatase activity in endometriotic samples.

Aromatase inhibitors (AIs) have been successfully developed and one of their main therapeutic indications is hormone-dependent breast cancer (Fabian, 2007). Case reports and pilot studies have suggested that AIs combined with progestogens or oral contraceptives may effectively reduce pain symptoms related to the presence of endometriosis in both post-menopausal women and women of reproductive age (Patwardhan et al., 2008).

The objective of the present study was to investigate aromatase localization and mRNA expression in three distinct types of endometriosis by means of immunohistochemistry and quantitative polymerase chain reaction (Q-PCR). Immunohistochemistry was performed with anti-aromatase-specific antibodies to precisely localize the aromatase enzyme in endometriotic lesions, since there is no consensus in the literature on cell types expressing this enzyme. Q-PCR was carried out to quantify aromatase expression in endometriotic tissues (three protocols were compared), as existing studies show great variation in levels of aromatase expression.

Materials and Methods

The use of human tissue for this study was approved by the Institutional Review Board of the Université Catholique de Louvain.

Biopsy collection

Biopsies of endometriotic lesions and their matched eutopic endometrium were taken from 127 patients undergoing laparoscopy (mean age of patients: 31.8 ± 6.3 years). In 71 cases, patients were in ovulatory cycles and biopsies were dated as proliferative (n = 35) or secretory (n = 36). In 56 cases, patients were undergoing hormonal therapy (47 estrogen treatment and 9 GnRH analog therapy). Biopsies were classified as peritoneal (n = 64), ovarian (n = 66) or rectovaginal (n = 65) endometriotic lesions.

Eutopic endometrium was also collected from 10 patients without endometriosis (presenting for reanastomosis or tubal sterilization) using an endometrial biopsy curette (mean age of patients: 38.0 ± 6.1 years; proliferative phase: 3; secretory phase: 7; all in spontaneous cycles).

For 63 of the 127 patients, biopsies were fixed in 4% formaldehyde, embedded in paraffin and serially sectioned (5 μm) for immunohistochemical study. For the remaining 64 patients, fragments of biopsies were frozen in liquid nitrogen and kept at -80°C until mRNA analysis.

All the biopsies were dissected by an expert gynecologist. Histological examination of the excised tissue was systematically carried out after hematoxylin-eosin staining, and the nature of the lesions was histologically confirmed in all cases (presence of glands and stroma).

Immunohistochemical analysis

Preselection of anti-human aromatase antibody

The specificity of four anti-human aromatase antibodies, used in previous endometriosis studies (Fazleabas et al., 2003; Bukulmez et al., 2007; Fechner et al., 2007), was evaluated by western blot on placental protein extracts [1/250; horseradish peroxidase (HRP)-conjugated goat anti-mouse secondary antibodies, 1/10 000; 40 μg of protein charged in each lane].

Two rabbit polyclonal antibodies (BioVision Research Products, Mountain View, CA, USA; Abcam, Cambridge, UK) were excluded, as their specificity could not be confirmed. Indeed, a second band was observed in our protein extracts at 35 kDa. Sequencing (Eurogentec S.A., Seraing, Belgium) of this band showed that it was not due to degradation products, as hypothesized on the BioVision data sheet (data not shown).

Two mouse monoclonal anti-human aromatase antibodies [Acris Antibodies, Hiddenhausen, Germany (here denoted Abl); and AbD Serotec, Oxford, UK (here denoted AblI)] were shown to be specific, since only one band (around 55 kDa) was detected. This band was sequenced (Eurogentec S.A.) and was shown to correspond to aromatase (data not shown). They were developed in 2002 (Turner et al., 2002) and are directed against a conserved epitope of aromatase corresponding to amino acids 376–390 of the human aromatase sequence (KALEDDVID-GYPVKK, sequence compared with the aromatase sequence stored in the GenPept database: nP_000094). It was therefore decided to use only monoclonal antibodies in this study.

Aromatase immunohistochemistry

Tissue sections were deparaffinized in Histosafe (YVSOLAB S.A., Beerse, Belgium), hydrated in isopropanol (Merck, Darmstadt, Germany), washed briefly in water and incubated in hydrogen peroxide (Merck) 3% v/v in methanol (Merck) for 30 min to block endogenous peroxidase activity. Slides were rinsed in water and heat epitope retrieval was performed using Target Retrieval Solution, pH 9.0 (Dako, ViaReal Carpinteria CA, USA)+0.1% Tween 20 (Sigma-Aldrich, Steinheim, Germany) for 20 min at 96°C. Sections were rinsed in phosphate-buffered saline (PBS)/Tween 20 and non-specific reactions were blocked using bovine serum albumin (BSA) 5% (Sigma-Aldrich)+non-fat dry milk 2% (BioRad, Hercules, CA, USA) in hypersaline Tris buffer (pH 7.4) for 1 h at room temperature (RT). Endogenous biotin blocking was performed using the

Biotin Blocking System (Dako) as follows: avidin solution was incubated for 10 min at RT and sections were rinsed in PBS/Tween 20. Thereafter, biotin solution was incubated for 10 min at RT and sections were washed in PBS/Tween 20. Sections were incubated with anti-aromatase antibodies diluted 1:50 (Abl and AbII) in BSA 2.5%+non-fat dry milk 1% in hypersaline Tris buffer (pH 7.4) overnight at 4°C. Biotinylated rabbit anti-mouse secondary antibodies (Dako) were then diluted 1:100 in BSA 2.5%+non-fat dry milk 1% in hypersaline Tris buffer (pH 7.4) and incubated with the tissue sections for 30 min at RT. Bound antibodies were visualized by incubating the sections with avidin–biotin complex/HRP (ABC/HRP) reagent (Vector Laboratories, Inc., Burlingame, CA, USA) for 15 min at RT, followed by incubation with 3,3'-diaminobenzidine (Dako) for a further 15 min at RT. Sections were finally counterstained with Mayer's hemalum solution (Merck).

Human placental and ovarian tissues were utilized as positive controls for aromatase expression (Turner *et al.*, 2002). Negative control sections were processed using non-specific IgG, or omitting the specific primary antibodies.

Staining of iron deposits

Ferric iron deposits were evidenced in ovarian endometriotic lesions using Perls' Prussian blue staining (Perls, 1867). Briefly, dewaxed 5 µm-thick lesion sections were stained for 20 min in a solution of 1% kalium hexacyanoferrate and 2% (v/v) hydrochloric acid and nuclei were counterstained with nuclear fast red.

PCR and Q-PCR studies

Samples were homogenized in TRIzol reagent (Life Technologies, Gaithersburg, MD, USA) using an Ultra-Turrax T25 homogenizer (Janke and Kunkel, Brussels, Belgium). RNA quality was checked by spectrophotometry and analysis of the 28S:18S ratio after agarose gel electrophoresis. Total RNA was isolated using the classic chloroform extraction and isopropanol precipitation method. Total RNA (2.5 µg) was reverse transcribed with random hexamers (Eurogentec S.A.) and SuperScript RT RNase H2 reverse transcriptase (Life Technologies).

Three sets of primers (localized in a conserved aromatase sequence site) and three PCR protocols were applied.

A first aromatase sequence of interest was amplified by PCR (protocol I) using cDNA recovered from 15 patients undergoing laparoscopy. The following primers were used (Fechner *et al.*, 2007): TGG CTA CCC AGT GAA AAA GG (forward); CCA TGG CGA TGT ACT TTC CT (reverse) (amplicon length: 181 bp). The amplification program involved the following steps: 2 min at 94°C, 35 cycles of 15 s at 94°C, 30 s at 56°C and 15 s at 72°C, culminating in a final step of 2 min at 72°C. The generated PCR products were size-fractionated on 2% agarose gel and detected by ethidium bromide staining.

In a second set of experiments, other sequences of interest were amplified by Q-PCR (protocol II) using cDNA recovered from 30 patients. The following primers were used (Heilier *et al.*, 2006a, b): TGG ACA CCT CTA ACA CGC TCT TC (forward, aromatase) and GCC ATC AAT GAC CCC TTC ATT [forward, glyceraldehyde 3-phosphate dehydrogenase (GAPDH)]; GAG CTT GCC ATG CAT CAA AA (reverse, aromatase) and TGA CGG TGC CAT GGA ATT T (reverse, GAPDH). The amplification program involved the following steps: 10 min at 95°C, 40 cycles of 15 s at 95°C and 1 min at 60°C. Finally, the temperature was gradually raised (0.1°C/s) from 65°C to 95°C for melting curve analysis to confirm the specificity of the amplification. Amplicon sizes (93 bp for aromatase and 88 bp for GAPDH) were verified on 1% agarose gel, and the aromatase amplicon was checked by sequencing (sequence compared with the aromatase sequence stored in the GenBank database: nM_000103). Q-PCR was performed using SYBR Green staining

(Applied Biosystems, Foster City, CA, USA) with a 7000 Sequence Detection System (Applied Biosystems), according to the manufacturer's protocol. Aromatase expression was normalized to that of GAPDH, which was previously shown to be expressed independently of the phase of the menstrual cycle (Brosens *et al.*, 2004).

TaqMan amplification was also carried out (protocol III) (Dassen *et al.*, 2007), using cDNA recovered from 19 patients. Primers and probes for aromatase (Hs00240671-m1) were purchased from Applied Biosystems as pre-developed assays. Human cyclophilin A (Hs9999904-m1) was selected as an endogenous RNA control. All PCR reactions were performed using a 7000 Sequence Detection System (Applied Biosystems). The amplification program involved the following steps: 10 min at 95°C, 40 cycles of 15 s at 95°C and 1 min at 60°C.

Q-PCR experiments (protocols II and III) were performed for each sample in duplicate. A standard curve was generated using five dilutions of plasmid constructions (from 100 000 to 10 copies of the aromatase gene). Q-PCR efficiency was always higher than 0.98.

Results

In this study, aromatase expression was investigated in three distinct endometriotic entities (peritoneal, ovarian and rectovaginal endometriotic lesions) and their matched endometrium. The histological characteristics of endometriosis were always confirmed after hematoxylin–eosin staining by an experienced pathologist.

Aromatase immunohistochemistry set-up

The specificity of the primary antibodies was tested by western blotting. Only one band (~55 kDa) corresponding to aromatase was detected in human placental protein extracts with Abl (Fig. 1A, lane 1) and AbII. In a preliminary experiment conducted in our laboratory, only one band was observed in mature testicular protein samples too (data not shown).

Aromatase immunohistochemistry was performed on paraffin-embedded tissue using the avidin–biotin amplification system, as applied in previous studies (Kitawaki *et al.*, 1997; Turner *et al.*, 2002; Fazleabas *et al.*, 2003; Ishihara *et al.*, 2003; Velasco *et al.*, 2006; Acien *et al.*, 2007; Bukulmez *et al.*, 2007; Fechner *et al.*, 2007; Hudelist *et al.*, 2007). However, endogenous biotin was labeled in the epithelial lining of endometriotic glands incubated with (Fig. 1B) or without (Fig. 1C) primary antibody (Abl and AbII). An endogenous biotin blocking step was therefore added before incubation with primary antibody, which led to the loss of glandular staining.

Aromatase protein localization (immunohistochemistry) in endometriotic lesions

As observed in previous studies, placental syncytiotrophoblasts (Fig. 1D), granulosa and internal theca cells of pre-ovulatory follicles (Fig. 1E and F), and luteal cells of corpus luteum (Fig. 1G) were found to stain positive for aromatase.

All endometriotic lesions (19 peritoneal, 19 ovarian and 20 rectovaginal with Abl; 34 peritoneal, 34 ovarian and 30 rectovaginal with AbII), their matched eutopic endometrium (48 with Abl; 63 with AbII), and endometrium from disease-free patients ($n = 10$) were found to be aromatase-negative in both the glandular and stromal compartments (Table I, Fig. 2A–D).

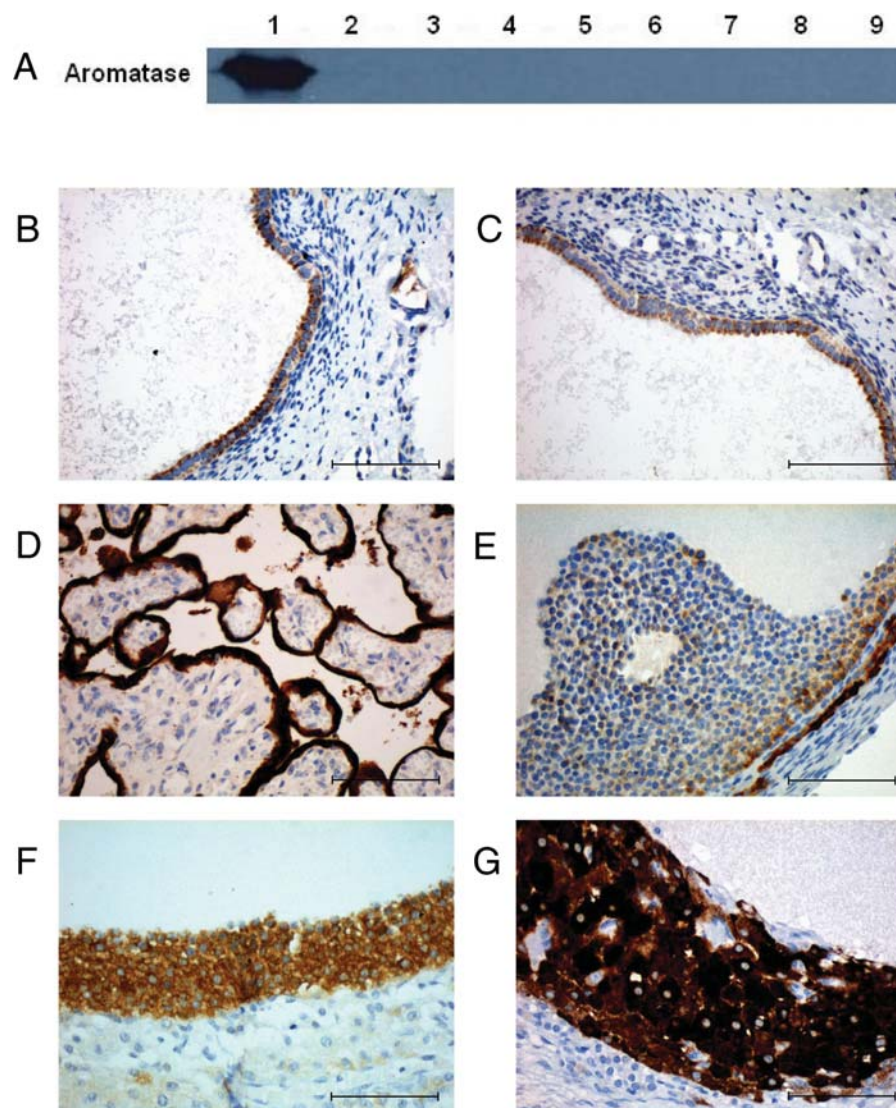


Figure 1 Aromatase immunohistochemistry set-up.

Western blot performed on protein extracts recovered from human placental tissue (lane 1), peritoneal endometriotic lesions (lanes 2, 4, 6, 8, 9) and eutopic endometrium from endometriosis patients (lanes 3, 5, 7) with mouse monoclonal anti-aromatase antibody (Abl, 1/250; HRP-conjugated goat anti-mouse secondary antibodies, 1/10 000, 40 μ g of protein charged in each lane) (A). Aromatase immunohistochemistry (Abl) of a peritoneal endometriotic lesion without endogenous biotin blocking (B), and its negative control (C). Aromatase immunohistochemistry of human placental sections (D) and human ovary sections (E–G). Original magnification: 200 \times (B–G), scale bars = 100.0 μ m.

As expected, on endometrioma sections, granulosa cells and internal theca cells from pre-ovulatory follicles were shown to be aromatase-positive. Non-specific stromal staining was also observed on these sections (Fig. 2E). This was due to iron deposition, as assessed by an experienced pathologist and confirmed by Perls' staining (Fig. 2F).

Preliminary results obtained by western blot with Abl and AbII on protein extracted from endometriotic lesions and their matched eutopic endometrium (10 peritoneal lesions, 2 ovarian lesions, 3 rectovaginal lesions, 8 eutopic endometrium; mean age of patients: 28.4 ± 5.4 years; proliferative phase: 7; secretory phase: 5; spontaneous cycles: 5; estrogen treatment: 7; GnRH analog therapy: 1) showed an absence of aromatase protein in these

samples (Fig. 1A, lanes 2–9), confirming the immunohistochemical results.

Aromatase gene expression (PCR and Q-PCR) in endometriotic lesions

An initial PCR study (35 cycles) was conducted with a first set of primers (Fig. 3A). Although a band was detected in placental mRNA extracts, no aromatase expression was observed in endometriotic lesions (8 peritoneal, 8 ovarian and 8 rectovaginal) or matched eutopic endometrium ($n = 15$) (Table II).

Q-PCR analysis (increased to 40 cycles) was therefore performed on mRNA extracted from other endometriotic lesions (11 peritoneal, 11 ovarian and 17 rectovaginal) and their matched eutopic

Table I Summary of immunohistochemical results

		Spontaneous		Hormonal treatment	
		Proliferative	Secretory	EP	GnRH α
Abl	Peritoneal endometriosis	0/9	0/7	0/3	0/0
	Ovarian endometriosis	0/6	0/9	0/4	0/0
	Rectovaginal endometriosis	0/0	0/6	0/13	0/1
	Eutopic endometrium	0/14	0/20	0/13	0/1
	Disease-free endometrium	0/7	0/3	0/0	0/0
Abll	Peritoneal endometriosis	0/13	0/11	0/9	0/1
	Ovarian endometriosis	0/10	0/13	0/10	0/1
	Rectovaginal endometriosis	0/4	0/8	0/16	0/2
	Eutopic endometrium	0/18	0/24	0/19	0/2
	Disease-free endometrium	0/7	0/3	0/0	0/0

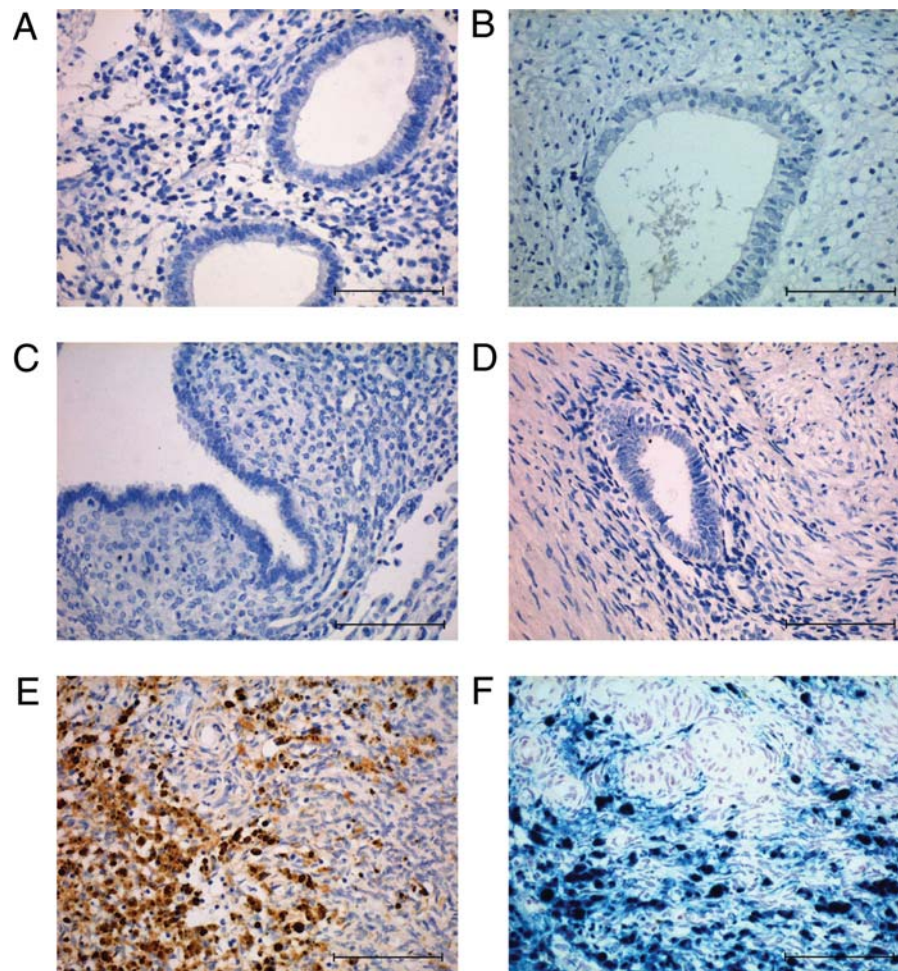


Figure 2 Aromatase immunohistochemistry of human endometrium and endometriotic lesions, and iron deposit staining. Aromatase immunohistochemistry (Abl) of eutopic endometrium from disease-free patients (A), peritoneal lesions (B), ovarian lesions (C) and rectovaginal lesions (D). Aromatase immunohistochemistry (E) and Perls' staining (F) of endometrioma sections. Original magnification: 200 \times , scale bars = 100.0 μ m.

endometrium ($n = 30$), with other sets of primers (Fig. 3B). Discernible levels (near the detection limit) were found in almost all the endometriomas tested (10/11; mean aromatase C_T : 35.0 \pm 1.9; mean GAPDH C_T : 20.4 \pm 1.2), in a few samples of peritoneal (1/11) and rectovaginal (3/17) endometriotic lesions, and in one sample of eutopic endometrium (1/30) (Table II).

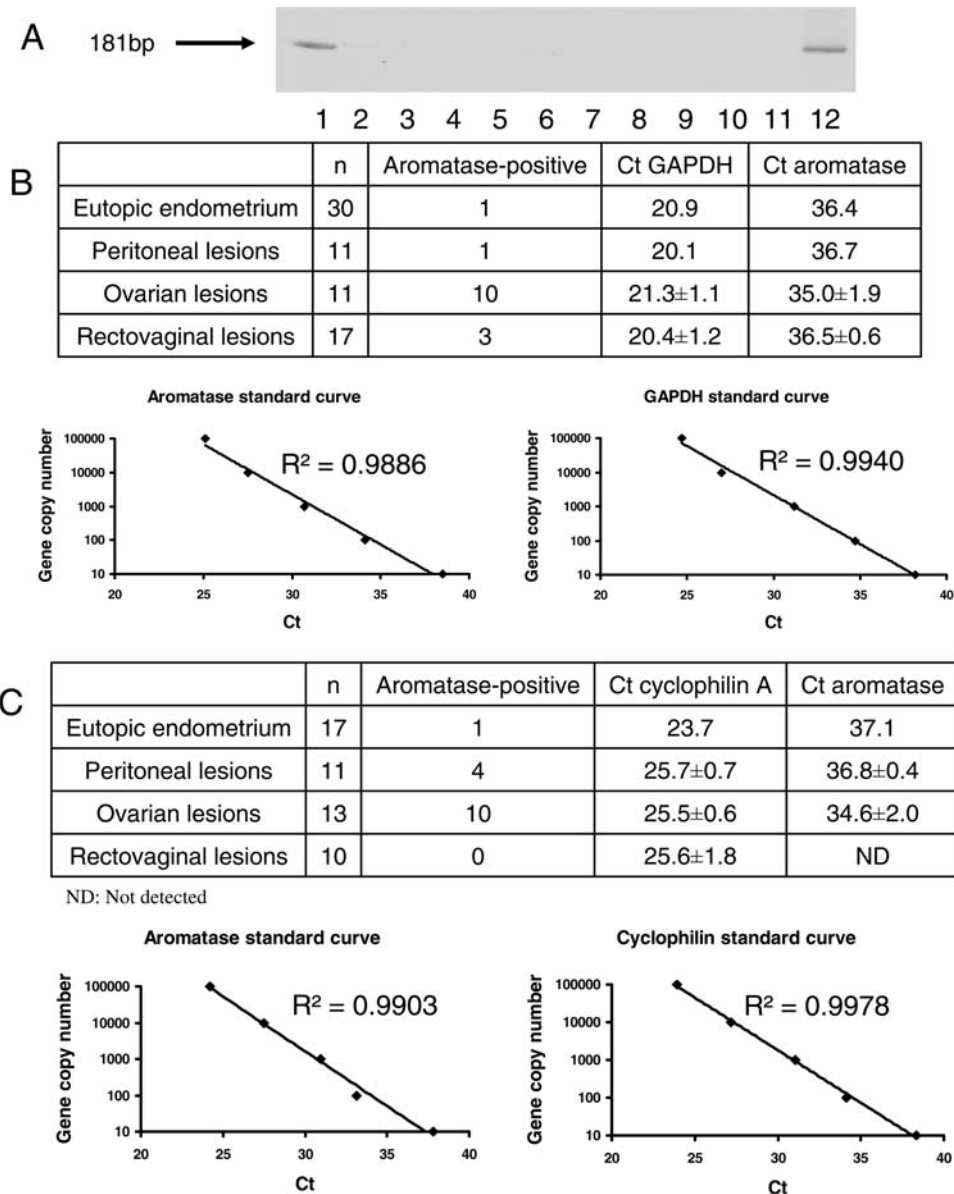


Figure 3 Aromatase mRNA expression.

Aromatase mRNA expression with protocol I (A) in placental tissue (lanes 1 and 12), eutopic endometrium from endometriosis patients (lanes 2, 6, 10, 11), and ovarian (lane 3), peritoneal (lanes 4, 5, 7) and rectovaginal (lanes 8 and 9) endometriotic lesions. Aromatase mRNA expression with protocol II (B) and III (C).

A third analysis was conducted with TaqMan probes (Fig. 3C). Again, discernible levels were found in almost all the endometriomas tested (10/13; mean aromatase Ct: 34.6 ± 2.0 ; mean cyclophilin A Ct: 25.5 ± 0.6), in a few samples of peritoneal endometriotic lesions (4/11), and in one sample of eutopic endometrium (1/17). No aromatase expression was detected in rectovaginal endometriotic lesions (Table II).

Plasmids were constructed and Q-PCR was applied to determine the limit of detection (according to the procedure described on the Applied Biosystems website: http://www3.appliedbiosystems.com/cms/groups/mcb_marketing/documents/generaldocuments/cms_04_2486.pdf). This corresponds to the Ct value of samples containing 10 molecules of mRNA of genes of interest (aromatase SYBR Green:

38.0; GAPDH SYBR Green: 38.1; aromatase TaqMan: 37.6; cyclophilin A TaqMan: 38.2).

Discussion

In endometriosis, aromatase is thought to be involved in a positive feedback loop that favors expression of key steroidogenic genes (Bulun et al., 2005). According to this hypothesis, estrogen stimulates production of the cyclooxygenase type 2 (COX-2) enzyme, resulting in elevated levels of prostaglandin E2 (PGE2), which is a potent stimulator of aromatase activity in endometriosis. This leads to continuous local production of E₂ and PGE2 in endometriotic tissue. Estrogen enhances the growth and invasion of endometriotic tissue, while

Table II Summary of PCR and Q-PCR studies

		Spontaneous		Hormonal treatment	
		Proliferative	Secretory	EP	GnRHa
Protocol I	Peritoneal endometriosis	0/4	0/3	0/1	0/0
	Ovarian endometriosis	0/4	0/3	0/1	0/0
	Rectovaginal endometriosis	0/3	0/2	0/2	0/1
	Eutopic endometrium	0/6	0/4	0/4	0/1
Protocol II	Peritoneal endometriosis	0/2	0/1	1/5	0/3
	Ovarian endometriosis	1/1	1/2	6/6	2/2
	Rectovaginal endometriosis	0/5	0/3	3/9	0/2
	Eutopic endometrium	0/6	0/4	1/14	0/6
Protocol III	Peritoneal endometriosis	2/4	0/2	2/5	0/0
	Ovarian endometriosis	3/4	2/3	5/6	0/0
	Rectovaginal endometriosis	0/2	0/2	0/6	0/0
	Eutopic endometrium	0/5	0/4	1/8	0/0

prostaglandins mediate pain, inflammation and infertility (Bulun *et al.*, 2005). This molecular link between inflammation and estrogen production could be responsible in part for the devastating symptoms of endometriosis.

The main objective of this study was to precisely localize (stromal and/or glandular tissue) and quantify aromatase expression in three distinct types of endometriotic lesions (peritoneal, ovarian and rectovaginal) by immunohistochemistry and Q-PCR. No aromatase protein was detected in the glands or stroma of any lesions by immunohistochemistry, while Q-PCR revealed only low aromatase mRNA levels in endometriomas, and barely detectable levels in a few peritoneal and rectovaginal endometriotic lesions and eutopic endometrium samples.

Our method of immunostaining was validated by several positive control tissues. Indeed, aromatase staining was found in human placental syncytiotrophoblasts, granulosa and internal theca cells of pre-ovulatory follicles, and luteal cells from corpus luteum. Similarly, pre-ovulatory follicles sometimes observed on endometrioma sections showed positive aromatase staining.

The specificity of anti-human aromatase antibodies was confirmed by western blot on human placental protein extracts, since a band corresponding to aromatase (~55 kDa) was detected with AbI and AbII, while a complete absence of bands was observed in endometriotic lesion protein extracts, confirming our immunohistochemical results.

Our study showed low levels of aromatase mRNA expression in ovarian endometriotic lesions, as observed in our previous studies (Heilier *et al.*, 2006a, b). This was probably due to the presence of follicular cells in the biopsies. Indeed, follicles are known to have high aromatase levels before ovulation (Sasano *et al.*, 1989), which was also evidenced in our immunohistochemical results.

The findings of the present study contradict most of the existing literature on the subject. Indeed, in published studies, aromatase was detected by immunohistochemistry (Kitawaki *et al.*, 1997, 1999a, b; Ishihara *et al.*, 2003; Wöflfler *et al.*, 2005; Velasco *et al.*, 2006; Acien *et al.*, 2007; Bukulmez *et al.*, 2007; Hudelist *et al.*, 2007) and Q-PCR (Noble *et al.*, 1996; Dheenadayalu *et al.*, 2002; Ishihara *et al.*, 2003; Heilier *et al.*, 2006a, b; Matsuzaki *et al.*, 2006; Dassen *et al.*, 2007; Kyama *et al.*, 2007; Smuc *et al.*, 2007; Attar *et al.*, 2008; Smuc *et al.*, 2008; Aghajanova *et al.*, 2009) in both eutopic

and ectopic endometrium from endometriosis patients, but not in eutopic endometrium from disease-free women. Nevertheless, there are discrepancies between many of these immunohistochemical studies, since some papers report stromal aromatase localization in human endometriotic lesions (Wöflfler *et al.*, 2005; Velasco *et al.*, 2006; Acien *et al.*, 2007) and lesions induced in baboons (Fazleabas *et al.*, 2003), while others demonstrate glandular aromatase localization in human endometriotic lesions (Kitawaki *et al.*, 1997, 1999a, b; Ishihara *et al.*, 2003; Wöflfler *et al.*, 2005; Hudelist *et al.*, 2007) and lesions induced in mice (Fechner *et al.*, 2007). Glandular aromatase expression was also evidenced by laser capture microdissection in human endometriotic lesions (Matsuzaki *et al.*, 2006). However, a recent paper reported an absence of aromatase activity in endometriotic samples (Delvoux *et al.*, 2008).

In our immunohistochemical analysis, glandular staining was based on avidin–biotin amplification, as in most papers showing aromatase protein localization in endometriosis (Turner *et al.*, 2002; Fazleabas *et al.*, 2003; Velasco *et al.*, 2006; Acien *et al.*, 2007; Fechner *et al.*, 2007; Hudelist *et al.*, 2007). Since we also detected labeling in our negative controls (endometriotic lesions without primary antibody), we added an endogenous biotin blocking step to our protocol before incubation with primary antibody (only previously done by Turner *et al.*, 2002). This resulted in the disappearance of glandular staining. We therefore suggest that what some authors took to be aromatase protein in endometriotic lesions was actually endogenous biotin.

Moreover, similar staining to that found by other authors in human endometriotic lesions (Velasco *et al.*, 2006; Acien *et al.*, 2007) and induced endometriotic lesions in baboons (Fazleabas *et al.*, 2003) was observed on our endometrioma sections. These authors considered this staining to be evidence of stromal localization of aromatase. However, on our sections, the presence of siderophages or iron deposits was suspected and subsequently confirmed by Perls' staining. Indeed, the same surface areas were labeled with both stains.

Concerning PCR detection, Heilier *et al.* previously showed aromatase expression to be higher in endometriomas than in peritoneal and rectovaginal endometriotic lesions (Heilier *et al.*, 2006a, b). However, the majority of results were obtained after 40 cycles of amplification (up to 55 cycles) and the Ct values could well have resulted from

non-specific amplification. We therefore conducted new Q-PCR analysis with the same primers, but stopping mRNA amplification at 40 cycles, and included additional controls (analysis of mRNA quality, sequencing of amplification products, standard curve analysis with dilutions of plasmid constructions and limit of detection determination). We then checked the dissociation curves (only one peak observed for each sample) and Q-PCR efficiency (always higher than 0.98). The amplicon amplified with this protocol (protocol II) was also sequenced and confirmed. Nevertheless, we only detected low levels of aromatase in our endometrioma samples. As confirmed by our immunohistochemical results, these low levels were probably due to follicular cells contaminating the biopsies. Barely detectable levels of aromatase were also found in a few peritoneal and rectovaginal endometriotic lesions, and in some eutopic endometrium samples. Although the lesions were carefully dissected, one cannot exclude contamination by surrounding tissues, such as adipose tissue or intact peritoneum (Simpson *et al.*, 1994; Kyama *et al.*, 2007), which may account for the occurrence of a few aromatase mRNA copies in these samples.

Our study investigated a broad range of patients (in proliferative or secretory phases, treated with estroprogestins or GnRH analogs), and low levels of aromatase expression detected by Q-PCR were found in non-treated as well as treated patients, indicating that treatment and cycle phase had no impact on our results.

The present study, showing an absence of aromatase expression at both the protein and mRNA levels, is furthermore corroborated by a recent publication by Delvoux *et al.*, who used a different technique but obtained similar results. Indeed, they were also unable to detect aromatase activity in their endometriotic samples (Delvoux *et al.*, 2008).

The good results obtained with AIs in clinical trials for endometriosis treatment should therefore be reinterpreted in the light of our data. The beneficial effects of AIs may well be explained by a systemic response or by inhibition of estrogen production in intraperitoneal tissues, such as intact peritoneum (Kyama *et al.*, 2007) or adipose tissue, rather than inhibition in endometriotic lesions themselves (Bulun *et al.*, 2005). Although aromatase levels per adipose tissue fibroblast or peritoneal cell may be small, the sum of estrogen arising from all these cells in the peritoneal cavity could have an impact on endometriotic lesion development.

In conclusion, our results failed to confirm previously published studies on aromatase expression in human endometriotic lesions. Indeed, we observed no aromatase protein in the glandular or stromal compartments of ectopic endometrial tissue, and barely detectable aromatase mRNA expression, suggesting that locally produced aromatase (within endometriotic lesions) could be less implicated than previously postulated.

Acknowledgements

J.C.L. is an FNRS Research Fellow. The authors thank Dolores Gonzalez and Olivier Van Kerk (Department of Gynecology) for their technical assistance. We thank Mira Hryniuk, B.A., for reviewing the English language of the manuscript. We also thank the Department of Anatomopathology for endometriotic lesion embedding and hematoxylin–eosin staining, and especially Professor E. Marbaix for his interpretation of the immunohistochemical results.

Funding

Fonds de la Recherche Scientifique—FNRS, Belgium (no I.5.130.08); Région Wallonne; PregLem S.A.; Vicomte Ph. de Spoelberch and Baron A. Frère.

References

- Acién P, Velasco I, Gutierrez M, Martinez-Beltran M. Aromatase expression in endometriotic tissues and its relationship to clinical and analytical findings. *Fertil Steril* 2007;**88**:32–38.
- Aghajanova L, Hamilton A, Kwintkiewicz J, Vo KC, Giudice LC. Steroidogenic enzyme and key decidualization marker dysregulation in endometrial stromal cells from women with versus without endometriosis. *Biol Reprod* 2009;**80**:105–114.
- Attar E, Tokunaga H, Imir G, Bertan Yilmaz M, Redwine D, Putman M, Gurates B, Attar R, Yaegashi N, Hales DB *et al.* Prostaglandin E2 via steroidogenic factor-1 coordinately regulates transcription of steroidogenic genes necessary for estrogen synthesis in endometriosis. *J Clin Endocrinol Metab* 2008; in press.
- Brosens J, Verhoeven H, Campo R, Gianaroli L, Gordts S, Hazekamp J, Hagglund L, Mardesic T, Varila E, Zech J *et al.* High endometrial aromatase P450 mRNA expression is associated with poor IVF outcome. *Hum Reprod* 2004;**19**:352–356.
- Bukulmez O, Hardy DB, Carr BR, Word RA, Mendelson CR. Inflammatory status influences aromatase and steroid receptor expression in endometriosis. *Endocrinology* 2007;**149**:1190–1204.
- Bulun SE, Yang S, Fang Z, Gurates B, Tamura M, Zhou J, Sebastian S. Role of aromatase in endometrial disease. *J Steroid Biochem Mol Bio* 2001;**79**:19–25.
- Bulun SE, Lin Z, Imir G, Amin S, Demura M, Yilmaz B, Martin R, Utsunomiya H, Thung S, Gurates B *et al.* Regulation of aromatase expression in estrogen-responsive breast and uterine disease: from bench to treatment. *Pharmacol Rev* 2005;**57**:359–383.
- Conley A, Hinshelwood M. Mammalian aromatases. *Reproduction* 2001;**121**:685–695.
- Dassen H, Punyadeera C, Kamps R, Delvoux B, Van Langendonck A, Donnez J, Husen B, Thole H, Dunselman G, Groothuis P. Estrogen-metabolizing enzymes in endometrium and endometriosis. *Hum Reprod* 2007;**22**:3148–3158.
- Delvoux B, Groothuis P, D'Hooghe T, Kyama C, Dunselman G, Romano A. Increased production of 17beta-estradiol in endometriosis lesions is the result of impaired metabolism. *J Clin Endocrinol Metab* 2008; in press.
- Dheenadayalu K, Mak I, Gordts S, Campo R, Higham J, Puttemans P, White J, Christian M, Fusi L, Brosens J. Aromatase P450 messenger RNA expression in eutopic endometrium is not a specific marker for pelvic endometriosis. *Fertil Steril* 2002;**78**:825–829.
- Donnez J, Van Langendonck A, Casanas-Roux F, Van Gossum JP, Pirard C, Jadoul P, Squifflet J, Smets M. Current thinking on the pathogenesis of endometriosis. *Gynecol Obstet Invest* 2002;**54**:52–62.
- Fabian CJ. The what, why and how of aromatase inhibitors: hormonal agents for treatment and prevention of breast cancer. *Int J Clin Pract* 2007;**61**:2051–2063.
- Fazleabas AT, Brudney A, Chai D, Langoi D, Bulun SE. Steroid receptor and aromatase expression in baboon endometriotic lesions. *Fertil Steril* 2003;**80**:820–827.
- Fechner S, Husen B, Thole H, Schmidt M, Gashaw I, Kimmig R, Winterhager E, Grümmer R. Expression and regulation of estrogen-converting enzymes in ectopic human endometrial tissue. *Fertil Steril* 2007;**88**:1029–1038.

- Heilier JF, Donnez J, Defrère S, Van Kerckhove V, Donnez O, Lison D. Serum dioxin-like compounds and aromatase (CYP19) expression in endometriotic tissues. *Toxicol Lett* 2006a;**167**:238–244.
- Heilier JF, Donnez O, Van Kerckhove V, Lison D, Donnez J. Expression of aromatase (P450 aromatase/CYP19) in peritoneal and ovarian endometriotic tissues and deep endometriotic (adenomyotic) nodules of the rectovaginal septum. *Fertil Steril* 2006b;**85**:1516–1518.
- Hudelist G, Czerwenka K, Keckstein J, Haas C, Fink-Retter A, Gschwandler-Kaulich D, Kubista E, Singer CF. Expression of aromatase and estrogen sulfotransferase in eutopic and ectopic endometrium: evidence for unbalanced estradiol production in endometriosis. *Reprod Sci* 2007;**14**:798–805.
- Ishihara H, Kitawaki J, Kado N, Koshiba H, Fushiki S, Honjo H. Gonadotropin-releasing hormone agonist and danazol normalize aromatase cytochrome P450 expression in eutopic endometrium from women with endometriosis, adenomyosis, or leiomyomas. *Fertil Steril* 2003;**79**:735–742.
- Kitawaki J, Noguchi T, Amatsu T, Maeda K, Tsukamoto K, Yamamoto T, Fushiki S, Osawa Y, Honjo H. Expression of aromatase cytochrome P450 protein and messenger ribonucleic acid in human endometriotic and adenomyotic tissues but not in normal endometrium. *Biol Reprod* 1997;**57**:514–519.
- Kitawaki J, Kusuki I, Koshiba H, Tsukamoto K, Fushiki S, Honjo H. Detection of aromatase cytochrome P-450 in endometrial biopsy specimens as a diagnostic test for endometriosis. *Fertil Steril* 1999a;**72**:1100–1106.
- Kitawaki J, Kusuki I, Koshiba H, Tsukamoto K, Honjo H. Expression of aromatase cytochrome P450 in eutopic endometrium and its application as a diagnostic test for endometriosis. *Gynecol Obstet Invest* 1999b;**48**:21–28.
- Kyama CM, Overbergh L, Mihalyi A, Meuleman C, Mwenda JM, Mathieu C, D'Hooghe TM. Endometrial and peritoneal expression of aromatase, cytokines, and adhesion factors in women with endometriosis. *Fertil Steril* 2007;**89**:301–310.
- Matsuzaki S, Canis M, Pouly JL, Déchelotte PJ, Mage G. Analysis of aromatase and 17 β -hydroxysteroid dehydrogenase type 2 messenger ribonucleic acid expression in deep endometriosis and eutopic endometrium using laser capture microdissection. *Fertil Steril* 2006;**85**:308–313.
- Mihalyi A, Simsa P, Mutinda KC, Meuleman C, Mwenda JM, D'Hooghe TM. Emerging drugs in endometriosis. *Expert Opin Emerg Drugs* 2006;**11**:503–524.
- Murakami K, Nomura K, Shinohara K, Kasai T, Shozu M, Inoue M. Danazol inhibits aromatase activity of endometriosis-derived stromal cells by a competitive mechanism. *Fertil Steril* 2006;**86**:291–297.
- Nisolle M, Donnez J. Peritoneal endometriosis, ovarian endometriosis, and adenomyotic nodules of the rectovaginal septum are three different entities. *Fertil Steril* 1997;**68**:585–596.
- Noble LS, Simpson ER, Johns A, Bulun SE. Aromatase expression in endometriosis. *J Clin Endocrinol Metab* 1996;**81**:174–179.
- Noble LS, Takayama K, Zeitoun KM, Putman JM, Johns DA, Hinshelwood MM, Agarwal VR, Zhao Y, Carr BR, Bulun SE. Prostaglandin E2 stimulates aromatase expression in endometriosis-derived stromal cells. *J Clin Endocrinol Metab* 1997;**82**:600–606.
- Patwardhan S, Nawathe A, Yates D, Harrison GR, Khan KS. Systematic review of the effects of aromatase inhibitors on pain associated with endometriosis. *BJOG* 2008;**115**:818–822.
- Perls M. Nachweis von Eisenoxyd in gewissen Pigmenten. *Virchows Arch* 1867;**39**:42–48.
- Purohit A, Fusi L, Brosens J, Woo LWL, Potter BVL, Reed MJ. Inhibition of steroid sulphatase activity in endometriotic implants by 667 COUMATE: a potential new therapy. *Hum Reprod* 2007;**23**:290–297.
- Sampson JA. Peritoneal endometriosis due to the menstrual dissemination of endometrial tissue into the peritoneal cavity. *Am J Obstet Gynecol* 1927;**14**:422–469.
- Sasano H, Okamoto M, Mason JI, Simpson ER, Mendelson CR, Sasano N, Silverberg SG. Immunolocalization of aromatase, 17 α -hydroxylase and side-chain-cleavage cytochromes P-450 in the human ovary. *J Reprod Fertil* 1989;**85**:163–169.
- Simpson ER, Mahendroo MS, Means AD, Kilgore MW, Hinshelwood MM, Graham-Lorence S, Amarneh B, Ito Y, Fisher CR, Michael MD *et al*. Aromatase cytochrome P450, the enzyme responsible for estrogen biosynthesis. *Endocr Rev* 1994;**15**:342–355.
- Simpson ER, Clyne C, Speed C, Rubin G, Bulun S. Tissue-specific estrogen biosynthesis and metabolism. *Ann N Y Acad Sci* 2001;**949**:58–67.
- Smuc T, Ribic Pucelj M, Sinkovec J, Husen B, Thole H, Nanisnik Rizner T. Expression analysis of the genes involved in estradiol and progesterone action in human ovarian endometriosis. *Gynecol Endocrinol* 2007;**23**:105–111.
- Smuc T, Hevir N, Ribič-Pucelj M, Husen B, Thole H, Rižner TL. Disturbed estrogen and progesterone action in ovarian endometriosis. *Mol Cell Endocrinol* 2008;. in press.
- Turner KJ, Macpherson S, Millar MR, McNeilly AS, Williams K, Cranfield M, Groome NP, Sharpe RM, Fraser HM, Saunders PTK. Development and validation of a new monoclonal antibody to mammalian aromatase. *J Endocrinol* 2002;**172**:21–30.
- Velasco I, Rueda J, Acien P. Aromatase expression in endometriotic tissues and cell cultures of patients with endometriosis. *Mol Hum Reprod* 2006;**12**:377–381.
- Wölfler MM, Nagele F, Kolbus A, Seidl S, Schneider B, Huber JC, Tschgguel W. A predictive model for endometriosis. *Hum Reprod* 2005;**20**:1702–1708.

Submitted on January 28, 2009; resubmitted on April 1, 2009; accepted on May 6, 2009