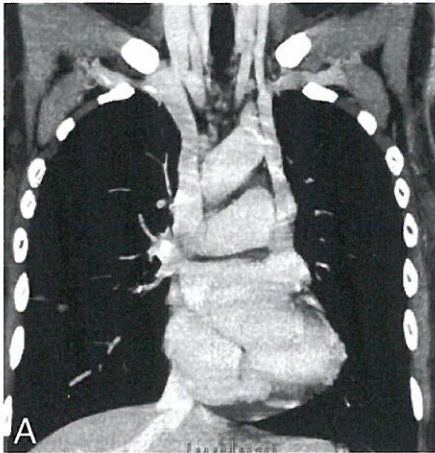


**IMAGES IN CLINICAL RADIOLOGY**

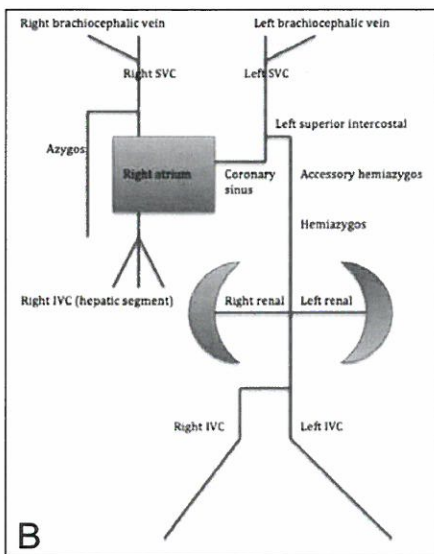


*Duplicate inferior vena cava continuing as a hemiazygos continuation draining into the right atrium via persistent left superior vena cava*

J. Joskin<sup>1</sup>, N. Bleus<sup>1</sup>, T. Couvreur<sup>1</sup>, L. Tselikas<sup>2</sup>, M. Milicevic<sup>1</sup>

A 59-year-old woman with known breast cancer presented liver lesions. As part of a metastatic workup, a thoracoabdominal enhanced contrast CT was performed. It revealed a persistent left superior vena cava (SVC) which reached the right atrium via an enlarged coronary sinus. This CT-scan also demonstrated the hemiazygos vein which was connected to the left SVC via the left superior intercostal vein. The right SVC was also present (Fig. A). At the abdominal level, CT showed a duplicate inferior vena cava (IVC) which was interrupted at the level of the renal hilum and continued as a hemiazygos vein cephalad (not shown). The renal veins drained into the left IVC. There was no corresponding IVC on the right side, except for the hepatic segment which seemed to drain to the right atrium directly by the confluence of the hepatic veins.

The anomaly in this case is drawn schematically (Fig. B) and demonstrated in the reformatted volume rendering thoracoabdominal CT-scan (Fig. C).

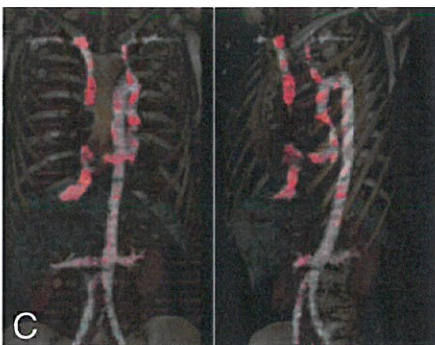


**Comment**

In most cases, congenital venous anomalies have no consequence, but this variant is important to avoid erroneous diagnosis. The enhanced contrast CT-scan is the exam of choice to differentiate the venous circulation. A review of the embryogenesis of the thoracic and abdominal venous circulation is essential to understand any developmental anomaly. Embryologically, the anterior cardinal veins drain the cephalic part of the body including the chest and the posterior cardinal veins drain the caudal part including the abdomen.

At the thoracic level, the normal right superior vena cava (SVC) is formed by the right anterior cardinal vein. The persistence of the left SVC results from the failure of obliteration of the left anterior cardinal vein (0.3%-0.5% of the normal population, 4.4%-12.9% in the population with congenital heart disease). It usually (92%) drains into the coronary sinus, but it can also drain rarely (8%) into the left atrium, and thus generate a right-to-left shunt. In the vast majority of cases (82-90%) the right SVC is also present with a bridging left brachiocephalic vein in 35-60% of cases.

At the abdominal level, the normal inferior vena cava (IVC) is formed by the successive development and regression of posterior cardinal veins. The posterior cardinal veins are functionally replaced by the supracardinal (infrarenal vena cava) and subcardinal (suprarenal vena cava) veins. The right venous system becomes the IVC, which drain into the right atrium and the left venous system usually involutes almost completely. In the case of a double infrarenal IVC with a retroaortic right renal vein and hemiazygos continuation of the IVC, the embryologic development can be explained as follows : first, the double infrarenal vena cava (0.2% to 0.5% of the general population) results of the persistence of the right venous system, second, the hemiazygos continuation of the IVC (> 0.3% of the general population) results from the absence of the right suprarenal vena cava and the persistence of the left anastomosis between the left suprarenal vena cava and the hemiazygos. The hepatic segment of the IVC (right venous system) ordinarily drains independently directly into the right atrium. Third, the right infrarenal vena cava with the right renal vein cross posterior to the aorta to join the left IVC and continue cephalad as the hemiazygos vein. Finally, the hemiazygos vein drains into the left SVC through the accessory hemiazygos and the left SVC drains into the right atrium by way of the enlarged coronary sinus.



**Reference**

1. Kim H.J., Park E.D.: Hemiazygos Continuation of a Left Inferior Vena Cava Draining into the Right Atrium via Persistent Left Superior Vena Cava: Demonstration by Helical Computed Tomography. *Cardiovasc Intervent Radiol*, 1995,18: 65-67.

1. Department of Radiology, CHU Sart-Tilman, Liege, Belgium, 2. Department of Radiology, Georges Pompidou Hospital, Paris, France.