

## CASE REPORT

### Primary osteosarcoma of the breast: a case report

Julie Crèvecoeur<sup>1</sup>, Véronique Jossa<sup>2</sup>, Christine Gennigens<sup>3</sup>, Jean-Claude Parmentier<sup>1</sup>  
& André Crèvecoeur<sup>1</sup>

<sup>1</sup>Center of Senology Drs Crèvecoeur, Liège, Belgium

<sup>2</sup>Laboratory of anatomy and pathology, CHC St-Joseph, Liège, Belgium

<sup>3</sup>Department of medical oncology, CHU, Liège, Belgium

#### Correspondence

Julie Crèvecoeur, Center of Senology Drs Crèvecoeur, Boulevard piercot 20, 4000 Liège, Belgium. Tel.: 003242230710; Fax: 003242234189; E-mail: julie.crevecoeur@gmail.com

#### Funding Information

No sources of funding were declared for this study.

Received: 3 March 2015; Revised: 15 September 2015; Accepted: 25 October 2015

doi: 10.1002/ccr3.450

#### Introduction

Primary osteosarcoma of the breast is a very rare and aggressive neoplasm. Approximately, 150 cases of this pathology have been reported in the literature since 1957 [1, 2]. Histologically, this tumor is indistinguishable from the conventional osteosarcomas of the bone or other extra skeletal ones [3, 4]. The mechanism of tumorigenesis of primary breast osteosarcoma remains unclear. Some reports have suggested that the tumor arises from totipotent mesenchymal cells of the breast stroma or the transformation of a preexisting fibroadenoma or phyllode tumor [2, 5–7]. Unfortunately, primary breast osteosarcoma is considered a poor prognosis cancer with early tumor recurrence and a propensity for hematogenous rather than lymphatic spread most commonly to the lungs [7–9]. We present the case of a 65-year-old Caucasian woman who was diagnosed with an osteosarcoma in her right breast. The senology monitoring of this patient is illustrated by mammographies that have been performed before and after discovering the pathology. Details of the diagnostic process, treatment, and follow-up will be described below.

#### Key Clinical Message

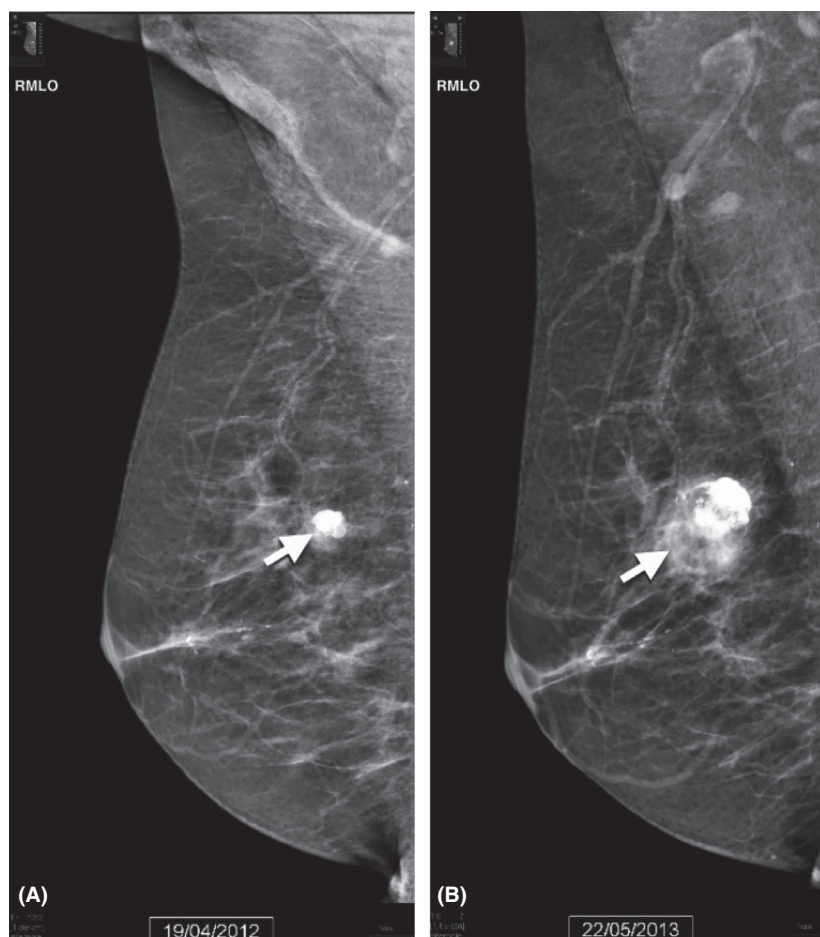
We report a rare case of primary osteosarcoma of the breast in a patient who presented a calcified fibroadenoma one year before the appearance of the malignant lesion. We describe the follow-up of the patient and the discovery of a similar osteosarcoma in the other breast one year later.

#### Keywords

Breast cancer, fibroadenoma, osteosarcoma.

#### Case Report

A 65-year-old woman came to our Center of Senology with pain in the outer region of the right breast. She was menopausal and she denied using any hormonal therapy or family history of breast cancer. She had a mammography in our center one year earlier. At that time, we described a calcified fibroadenoma that measured 1 cm (Fig. 1A). The new clinical examination revealed a mobile nodule in the right upper quadrant of her right breast, without skin retraction and satellite adenopathy. On the mammography, we identified a dense opacity area with numerous calcifications, estimated to be 25 mm wide and 29 mm high (Fig. 1B). This new lesion seems to have developed from the nodule which was observed there one year before. No lesion has been demonstrated in the left breast. To obtain a histologic diagnosis, a microbiopsy was performed. The samples were submitted for a blind analysis to three independent anatomopathologists who all diagnosed a primitive osteosarcoma of the breast. Immunohistochemical staining on biopsy did not reveal any positive expression for the cytokeratin AE1-AE3 and CK7 while the CD68 staining was observed positive. The



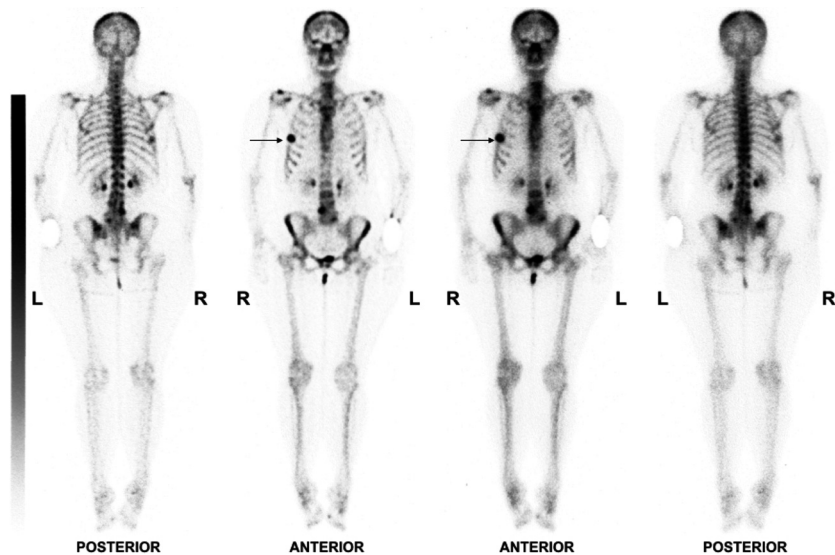
**Figure 1.** Mediolateral oblique view of the right breast demonstrates (A) in April 2012, the presence of a calcified fibroadenoma (arrow) and (B) in May 2013, a dense opacity, slightly heterogeneous with numerous calcifications in the part upper outer of the breast (arrow).

proliferative activity of tumor cells (KI67 positivity) was raised to 45%. There was also no expression for the estrogen and progesterone receptors, as well as the HER-2/NEU oncoprotein. The chest radiography and the abdominal ultrasound did not reveal any metastasis. A technetium 99-methylene diphosphonate (Tc-99 m) bone scintigraphy did demonstrate an intense localized uptake in the right breast (Fig. 2), no metastatic lesions were observed. After multidisciplinary discussion, the patient underwent a tumorectomy with sentinel lymph node dissection. Histology of the tumorectomy showed a prominent component of high-grade spindle cell sarcoma with osseous differentiation in which there may be patches of osteoid formation and multinucleated osteoclastic giant cells associated with hemorrhagic cysts with telangiectatic appearance (Fig. 3). The mitotic activity was elevated. Four axillary lymph nodes were negative. The tumor appeared to be close to the resection margin. As a result, a mastectomy of the right breast was performed three weeks after the first intervention. The histologic reports confirmed the

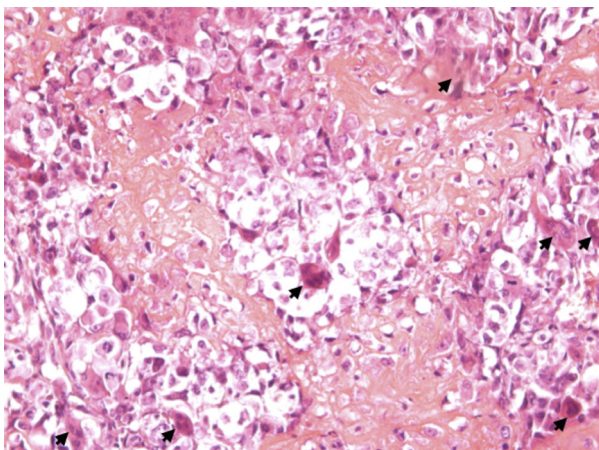
persistence of aggressive osteosarcoma found at the edge of the tumorectomy, in the retro-areolar region and chest wall. The immunohistologic profile of the mastectomy specimen was similar to the biopsy and tumorectomy.

The Oncology service then took care of the patient. An adjuvant chemotherapy associating Doxorubicin 20 mg/m<sup>2</sup> with Ifosfamide 2.5 g/m<sup>2</sup> at D1 to D3, every three weeks due to six cures, was initiated. After the chemotherapy, a radiation therapy was performed. Unfortunately, three months after the end of radiation therapy, a PET-scan showed a metastatic nodule in the right lung. The patient underwent surgery for resection of this metastasis. The anatomopathologic report confirmed lung metastasis measuring 2 cm with osteosarcoma component, necrotic at 40%.

Only three months after this surgery, the patient returned to our center because she noticed a nodule in lower region of the left breast. A mammography showed a nodular dense opacity measuring 25 mm wide and 27 mm high (Fig. 4). No axillary adenopathy was



**Figure 2.** Technetium 99-methylene diphosphonate bone scintigraphy showing an intense uptake in the right breast corresponding to the primary osteosarcoma (arrows).



**Figure 3.** Microscopic image from the piece of tumorectomy showed malignant mesenchymal tumor-like osteogenic sarcoma with osteoclastic and osteoblastic activity with osteoid formation, (hematoxylin-eosin, original magnification  $\times 200$ ). Multinucleated osteoclastic giant cells (arrows).

observed. A microbiopsy was performed on this lesion. The histologic analysis of this biopsy demonstrated a massive infiltration by malignant sarcomatous appearance of high grade, with a proliferative index at 90%. The immunostaining for desmine, actine, cytokeratine AE1-AE3, and CD34 were all negative. Consequently, a thoraco-abdominopelvic CT scan was performed. The breast neoplasia was confirmed and a right pleural carcinomatosis was observed. The patient was hospitalized for a resumption of chemotherapy with gemcitabine  $900 \text{ mg/m}^2$  at D1 to D8 and docetaxel  $100 \text{ m/m}^2$  at D8. In spite of this treatment, the patient succumbed to

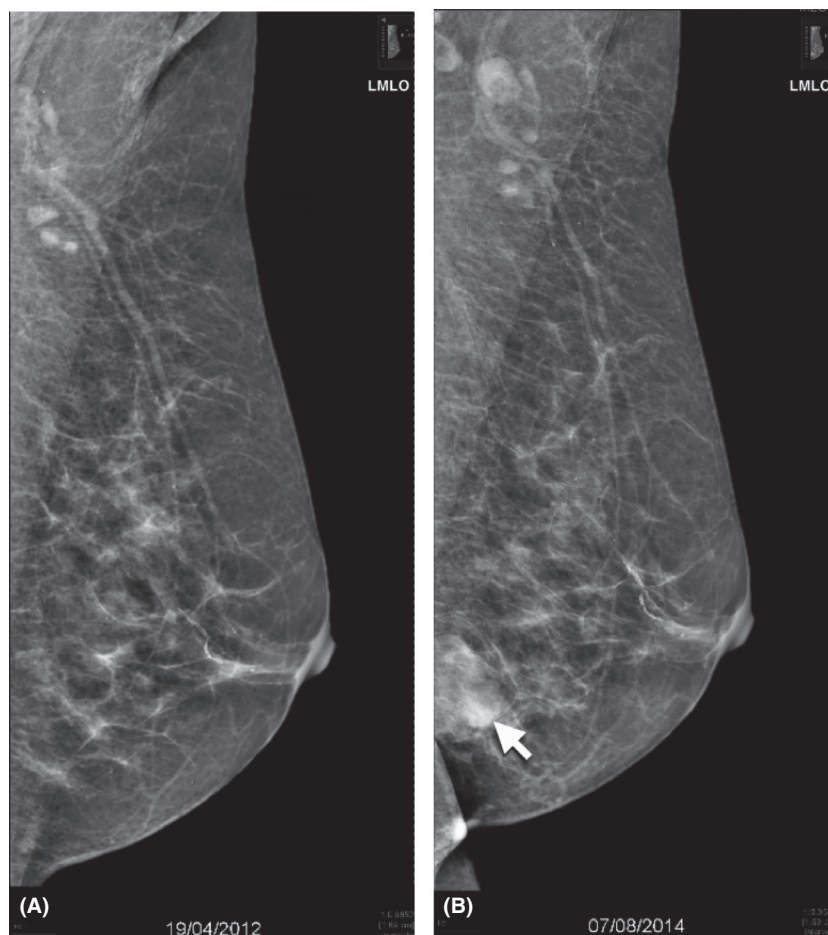
the disease due to metastatic dissemination after seven weeks.

## Discussion

Osteosarcoma of the breast is an infrequent and highly aggressive tumor with a prevalence of  $<1\%$  of all primary breast malignancies [9, 10]. The histogenesis of primary breast osteosarcoma remains unclear, but an evolution from totipotent mesenchymal cells of the breast stroma or a transformation from a preexisting fibroadenoma or phyllodes tumors have been suggested [1, 4]. The mean age of breast osteosarcoma is 64.5 years [10, 11], in contrast to skeletal osteosarcoma which occurs in younger patients. Due to the rarity of the disease, its clinical features and optimal treatment remain unclear.

We have herein described a case of osteosarcoma of the breast. For the first time, we have shown the presence of a calcified fibroadenoma one year before the diagnostic of breast osteosarcoma. The mammographic appearance of this tumor is a well-circumscribed dense mass with numerous calcifications. It is likely that this lesion must develop from a preexisting fibroadenoma. This report confirms other cases describing the association of this tumor with a fibroadenoma [2]. It has been showed that fibroadenomas and carcinomas may contain bone and osteoid cells. Moreover, metastatic bone formation can be found in fibroadenomas and phyllodes tumors [12].

Generally, the treatment for a primary osteosarcoma of breast or for that matter any sarcoma is very wide excision with negative margins. But some authors reported that



**Figure 4.** Mediolateral oblique view of the left breast (A) in April 2012, no abnormality is detected and (B) in August 2014, a dense nodular opacity, with slightly irregular outline in the infero-medial region, is observed (arrow).

optimal management of this pathology should include a mastectomy. Wide local excision seems to be complicated by local recurrence [2, 11]. The case described here confirms the interest of this invasive surgery because histologically the margins of the tumorectomy specimen were positive after the tumorectomy. Concerning axillary nodes, they are rarely involved [4, 9, 11]. In the present case, sentinel lymph node dissection was performed and four axillary lymph nodes were reported to be negative. When the patient developed an osteosarcoma in the other breast, fifteen months after the discovery of first tumor, no axillary adenopathy was observed. Therefore, lymph node dissection can be considered unnecessary. In contrast, sarcomatoid carcinomas and primary breast sarcomas often require axillary node dissection.

The role of adjuvant therapy is unclear because of limited data and its efficacy has not been well established [13]. Chemotherapy with either doxorubicin, cisplatin, or ifosfamide has increased the survival of patient with bone osteosarcomas but in patients suffering breast osteosar-

coma, the benefits of these regimes are not proven [1, 4]. Moreover, recurrence due to metastasis occurs mainly via the hematogenous route, most commonly to the lungs, bone, and liver [1, 2]. The patient described in this report quickly developed metastasis in the right lung, despite adjuvant chemotherapy combining doxorubicin and ifosfamide, and also radiation therapy. After the detection of another osteosarcoma in the left breast, a resumption of chemotherapy with gemcitabine and docetaxel had no effect. Consequently, this case report challenges the therapeutic protocol followed for the treatment of primary breast osteosarcoma.

In conclusion, we reported an example of primary osteosarcoma of the breast. As illustrated by this case report, the development of primary osteosarcoma of the breast is associated with preexisting fibroadenoma. Mastectomy appears to be the most adapted primary treatment for this tumor and the use of an adjuvant therapy still requires further investigations. Due to the aggressivity and the rarity of this disease, it seems to be important to sys-



tematically follow-up such cases in order to appropriately manage patients suffering of this pathology.

## Conflict of Interest

None declared.

## References

1. Khan, S., E. Griffiths, N. Shah, and S. Ravi. 2008. Primary osteogenic sarcoma of the breast: a case report. *Cases J.* 1:148. 1–4.
2. Silver, S. A., and F. A. Tavassoli. 1998. Primary osteogenic sarcoma of the breast: a clinicopathologic analysis of 50 cases. *Am. J. Surg. Pathol.* 8:925–933.
3. Dey, S., M. K. Chaudhury, S. K. Basu, A. K. Manna, and S. K. Dutta. 2013. Primary osteosarcoma of breast, a rare case. *J. Clin. Diagn. Res.* 7:1710–1711.
4. Bahrami, A., E. Resetkova, J. Y. Ro, J. D. Ibanez, and A. G. Ayala. 2007. Primary osteosarcoma of the breast. Report of 2 cases. *Arch. Pathol. Lab. Med.* 131:792–795.
5. Remadi, S., I. Doussis-Anagnostopoulou, and W. Mac Gee. 1995. Primary osteosarcoma of the breast. *Pathol. Res. Pract.* 191:471–474.
6. Mertens, H. H., D. Langnickel, and F. Staedtler. 1982. Primary osteogenic sarcoma of the breast. *Acta Cytol.* 4:512–516.
7. Szajewski, M., W. J. Kruszewski, M. Ciesielski, U. Smialek-Kusowska, M. Czerepko, and J. Szeffel. 2014. Primary osteosarcoma of the breast: a case report. *Oncol. Lett.* 7:1962–1964.
8. Gull, S., P. Patil, and R. Spence. 2011. Primary osteosarcoma of breast. *BMJ Case Rep.* doi:10.1136/bcr.03.2011.4015.
9. Zhao, J., X. Zhang, J. Liu, and J. Li. 2013. Primary osteosarcoma of the breast with abundant chondroid matrix and fibroblasts has a good prognosis: a case report and review of the literature. *Oncol. Lett.* 6:745–747.
10. Argus, A., and L. Halton. 2011. Case of the season: osteosarcoma of the breast. *Semin. Roentgenol.* 46:1. 4–6.
11. Murakami, S., H. Isozaki, T. Shou, K. Sakai, Y. Yamamoto, M. Oomori, et al. 2009. Primary osteosarcoma of the breast. *Pathol. Int.* 59:111–115.
12. Uner, A., B. Ozturk, M. Benekli, U. Coskun, S. Kocak, A. O. Kaya, et al. 2008. Synchronize primary breast osteosarcoma and contralateral benign cystosarcoma phylloides: radiologic and pathologic imaging. *Breast J.* 14:109–110.
13. Momoi, H., Y. Wada, S. Sarumaru, N. Tamaki, T. Gomi, S. Kanaya, et al. 2004. Primary osteosarcoma of the breast. *Breast Cancer* 11:396–400.