

Journal of Feline Medicine and Surgery

<http://jfm.sagepub.com/>

Aspergillosis in Cats: ABCD guidelines on prevention and management

Katrin Hartmann, Albert Lloret, Maria Grazia Pennisi, Lluís Ferrer, Diane Addie, Sándor Belák, Corine Boucraut-Baralon, Herman Egberink, Tadeusz Frymus, Tim Gruffydd-Jones, Margaret J Hosie, Hans Lutz, Fulvio Marsilio, Karin Möstl, Alan D Radford, Etienne Thiry, Uwe Truyen and Marian C Horzinek
Journal of Feline Medicine and Surgery 2013 15: 605
DOI: 10.1177/1098612X13489223

The online version of this article can be found at:
<http://jfm.sagepub.com/content/15/7/605>

Disclaimer

The Journal of Feline Medicine and Surgery is an international journal and authors may discuss products and formulations that are not available or licensed in the individual reader's own country. Furthermore, drugs may be mentioned that are licensed for human use, and not for veterinary use. Readers need to bear this in mind and be aware of the prescribing laws pertaining to their own country. Likewise, in relation to advertising material, it is the responsibility of the reader to check that the product is authorised for use in their own country. The authors, editors, owners and publishers do not accept any responsibility for any loss or damage arising from actions or decisions based on information contained in this publication; ultimate responsibility for the treatment of animals and interpretation of published materials lies with the veterinary practitioner. The opinions expressed are those of the authors and the inclusion in this publication of material relating to a particular product, method or technique does not amount to an endorsement of its value or quality, or the claims made by its manufacturer.

Published by:

[International Society of Feline Medicine](#)



[American Association of Feline Practitioners](#)



and

<http://www.sagepublications.com>

Additional services and information for *Journal of Feline Medicine and Surgery* can be found at:

Email Alerts: <http://jfm.sagepub.com/cgi/alerts>

Subscriptions: <http://jfm.sagepub.com/subscriptions>

Reprints: <http://www.sagepub.com/journalsReprints.nav>

Permissions: <http://www.sagepub.com/journalsPermissions.nav>

>> [Version of Record](#) - Jun 27, 2013

[What is This?](#)

Downloaded from jfm.sagepub.com at Universite de Liege on September 3, 2013



ASPERGILLOSIS IN CATS

ABCD guidelines on prevention and management

Katrin Hartmann, Albert Lloret, Maria Grazia Pennisi, Lluís Ferrer*, Diane Addie, Sándor Belák, Corine Boucraut-Baralon, Herman Egberink, Tadeusz Frymus, Tim Gruffydd-Jones, Margaret J Hosie, Hans Lutz, Fulvio Marsilio, Karin Möstl, Alan D Radford, Etienne Thiry, Uwe Truyen, and Marian C Horzinek



Agent properties

Aspergillosis is caused by fungal organisms of the genus *Aspergillus*. *Aspergillus* species are ubiquitous saprophytes. The organism is occasionally also isolated from healthy animals.

There is some confusion in the nomenclature of these fungi. Species identification only on the basis of phenotypic features probably leads to overidentification of *Aspergillus fumigatus*. Some species initially identified as *A fumigatus* by conventional methods now have been classified as *Neosartorya* species, *Aspergillus lentulus* and *Aspergillus udagawae* using molecular techniques. Differences in virulence and

invasion ability between species exist, and severe cases commonly seem to be associated with *Neosartorya* species infections.¹ Species included in the *A fumigatus* complex are responsible for the majority of infections in cats, but *Aspergillus*

European Advisory Board on Cat Diseases
The European Advisory Board on Cat Diseases (ABCD) is a body of experts in immunology, vaccinology and clinical feline medicine that issues guidelines on prevention and management of feline infectious diseases in Europe, for the benefit of the health and welfare of cats. The guidelines are based on current scientific knowledge of the diseases and available vaccines concerned.

The latest version of the aspergillosis in cats guidelines is available at www.abcd-vets.org

flavus, *Aspergillus nidulans*, *Aspergillus niger* and *Aspergillus terreus* have also been detected. Recently, *A udagawae*, a rare opportunistic pathogen, was identified in a cat causing fatal orbital aspergillosis.²

Epidemiology

Aspergillus species are found worldwide in soil and decaying vegetation. All mammals, including humans, are susceptible to aspergillosis. Immunosuppressed persons (eg, by human immunodeficiency virus infection) are particularly prone to acquiring the disease. Cats and other animals are infected through contamination of the environment. Direct transmission does not occur – thus, aspergillosis is not a zoonosis.

Overview: Aspergillosis is a sporadic mycosis that occurs worldwide in mammals and birds and leads to a usually chronic, and only rarely acute, disease that mainly affects the nasal cavity and sinuses.

Infection: *Aspergillus* species infections are commonly associated with predisposing local or systemic factors. Local disease can spread and involve the central nervous system or the lungs. Some *Aspergillus* species can also disseminate, causing systemic infections. In contrast to dogs, in which (nasal) aspergillosis is relatively common, aspergillosis is rare in cats, but considered an emerging infection.

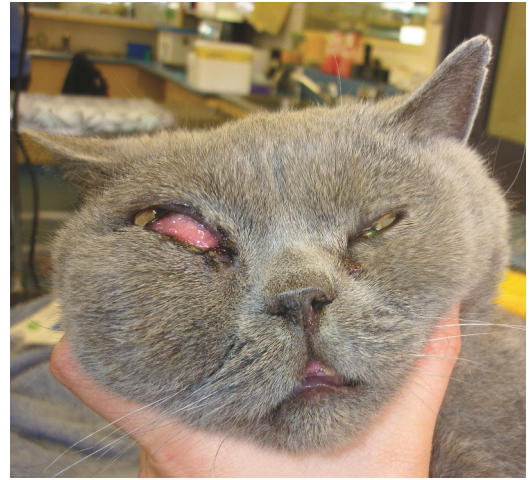
Clinical signs: There are two clinical forms of aspergillosis in cats, the sinonasal form (characterised by signs of chronic nasal infection) and the newly emerging, more invasive sino-orbital form (characterised by signs of orbital and surrounding tissue invasion). Sino-orbital involvement has been described now in approximately half of the reported cases.

Disease management: Treatment should consist of local and systemic antifungal therapy.

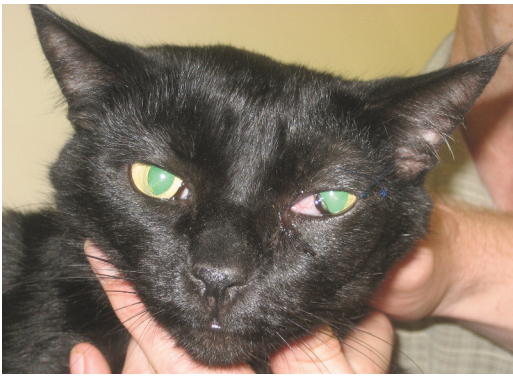

Figure 1 Exophthalmos of the left eye in a cat with a left retrobulbar fungal granuloma (sino-orbital aspergillosis). There is prolapse of the third eyelid. A partial lateral tarsorrhaphy was performed to prevent exposure keratitis. Courtesy of Vanessa Barrs, University Veterinary Teaching Hospital, Sydney, Australia

Figure 2 Right exophthalmos, third eyelid prolapse and oedema and swelling of the right side of the face in a cat with a right retrobulbar and paranasal fungal granuloma. Courtesy of Vanessa Barrs, University Veterinary Teaching Hospital, Sydney, Australia



There are two clinical forms of aspergillosis in cats, the sinonasal and the newly emerging, more invasive sino-orbital form.



Pathogenesis

Aspergillosis occurs worldwide. Most of the cases have been reported from Australia, but feline aspergillosis has been described in North America, the United Kingdom, Switzerland, Germany, Japan and Italy.^{1,3-5} No age or sex predisposition has been detected. A predisposition was found in brachycephalic breeds, especially Persian and Himalayan cats.^{1,3,6,7} Reduced drainage of upper respiratory secretions has been suggested as a predisposing factor.⁸ Additional suggested factors include innate defects of mucosal immunity, previous viral upper respiratory tract infections, and antibiotic treatment.³ A relationship between sino-orbital aspergillosis and lymphoplasmacytic rhinitis in a cat treated with oral prednisone has been suggested,⁴ indicating that immunosuppression may play a role. No association between aspergillosis and feline retrovirus infections has been reported.⁹

Infection usually occurs from *Aspergillus* species accumulated in pet food and litter. The spores are inhaled and deposited in the sinusal cavity, the primary site of infection. The fungus must adhere to the respiratory epithelium, penetrate it, destroy surrounding cells, and resist phagocytosis. *Aspergillus* species conidia bind to various cell surface proteins using specific adhesion molecules, such as hydrophobins. *A fumigatus* also produces an immunosuppressive toxin (gliotoxin) that inhibits macrophage phagocytosis. Other metabolites impair mucociliary action and prolong the organisms' epithelial resistance, while enzymes (eg, proteases) help to invade tissues.

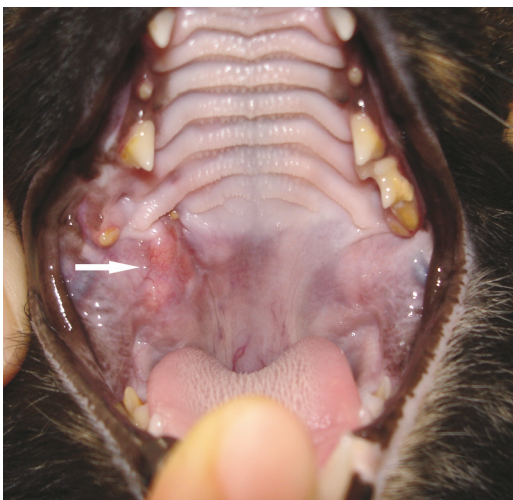

Figure 3 Ventral expansion of retrobulbar fungal granulomas causing a mass effect in the pterygopalatine fossa in a cat with a right retrobulbar fungal granuloma (arrow). Courtesy of Vanessa Barrs, University Veterinary Teaching Hospital, Sydney, Australia

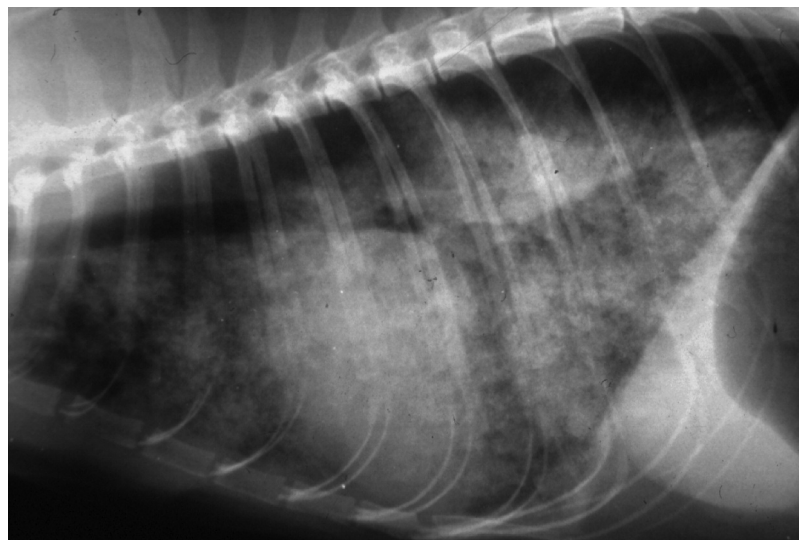


Figure 4 Thoracic radiograph (laterolateral view) of a cat with pulmonary aspergillosis, confirmed at necropsy. Courtesy of Katrin Hartmann, Ludwig Maximilians University, Munich, Germany

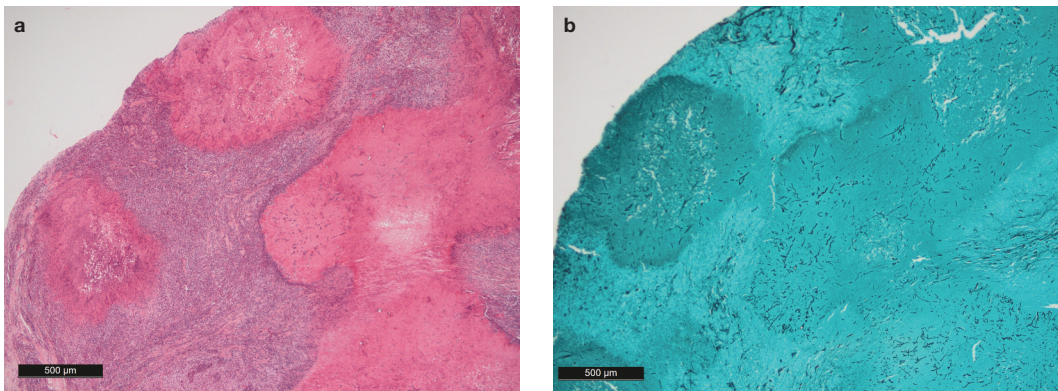


Figure 5 (a) Haematoxylin and eosin stained section of a retrobulbar fungal granuloma consisting of a large central granuloma surrounded by smaller satellite granulomas. Centrally each granuloma contains necrotic cellular debris within which branching, septate fungal hyphae are confined, as seen on the Grocott stained section (b). There are surrounding zones of neutrophils and eosinophils, macrophages, fibroblasts and a peripheral cuff of lymphocytes and plasma cells. Courtesy of Vanessa Barrs, University Veterinary Teaching Hospital, Sydney, Australia

Clinical signs

Aspergillosis occurs in two main forms in cats, sinonasal aspergillosis (SNA) and sino-orbital aspergillosis (SOA). SNA is characterised by more local signs of chronic nasal infection, such as sneezing, uni- or bilateral serous to mucopurulent nasal discharge, and sometimes epistaxis. Stertorous breathing, granuloma formation, soft tissue masses protruding from the nares, and bone lysis are less frequent abnormalities.^{3,7}

SOA is the more invasive form. The clinical manifestation depends on the invading fungal species, and SOA probably represents an extension of SNA to orbital and subcutaneous tissues, caused by invasive *Aspergillus* species, like *Neosartorya* species. Most cats with SOA indeed have a history of nasal discharge, and nasal lesions have been seen at necropsy in addition to lysis of the orbital lamina identified using imaging techniques.^{1,4,6} SOA is characterised by signs of orbital and sur-

Sino-orbital involvement has been described now in approximately half of the reported cases.



rounding tissue invasion, including unilateral exophthalmos, third eyelid prolapse (Figure 1), conjunctival hyperaemia and keratitis (Figure 2). In some cases, a mass in the pterygopalatine fossa (Figure 3) or an ulceration of the hard palate, or even extension and destruction of the nasal cavity (sometimes with swelling and skin ulcers), can be seen. The central nervous system can be involved leading to neurological signs, peripheral vestibular signs and blindness, and regional lymphadenopathy and fever can occur.

Atypical cases of aspergillosis have been reported, including pneumonia (Figure 4) and pyothorax in a diabetic cat,¹⁰ a cat with generalised systemic infection,⁵ and a cat with ulcerative keratitis.¹¹

Laboratory abnormalities in cats with aspergillosis are non-specific and the result of chronic inflammation. Hyperglobulinaemia is the most frequently reported abnormality.^{1,6,12,13}

Immunity

Immunity against *Aspergillus* species infection is poorly understood. Many cats develop antibodies, but some cats produce only low or undetectable antibody levels (mostly in cases of *A fumigatus* infection).⁷ Additionally, cats can produce antibodies without clinical disease, which is likely the result of non-invasive mucous membrane colonisation that occurs in many healthy cats.

Diagnosis

Diagnosis is based on demonstration of fungal hyphae by cytology or histology (Figure 5) and definitive confirmation by fungal culture (Figure 6). Advanced imaging techniques (computed tomography [CT] or magnetic reso-

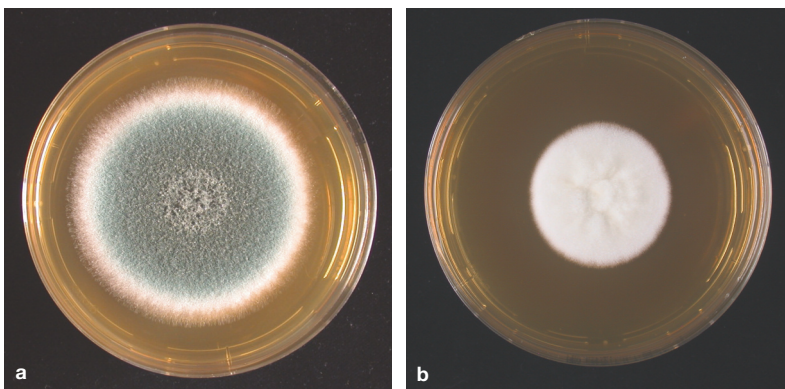


Figure 6 (a) Growth of *A fumigatus* on malt extract agar (MEA). Colonies are typically olive green and velvety due to rapid sporulation. (b) By contrast some species of *Aspergillus* in the *A fumigatus* complex that cause sino-orbital aspergillosis are slow to sporulate and the colonies appear whitish until sporulation occurs. Courtesy of Vanessa Barrs, University Veterinary Teaching Hospital, Sydney, Australia

nance imaging [MRI]) are helpful to assess disease extension and to find the best location for obtaining diagnostic samples during rhinoscopy (Figure 7) [EBM grade IV].⁷ CT and MRI are also important tools to rule out neoplasia. However, in a study including 10 cats (five with aspergillosis), CT findings neither allowed discrimination between different fungal infections nor distinguished aspergillosis from neoplasia [EBM grade III].¹⁴

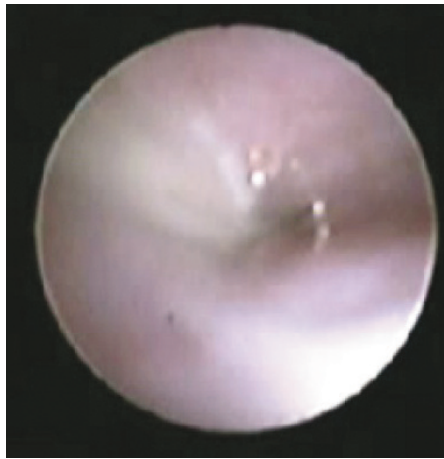

Figure 7 Rhinoscopic findings in a cat with sinonasal aspergillosis. Courtesy of Blanka Schulz, Ludwig Maximilians University, Munich, Germany

Direct detection of the organism

A definitive diagnosis is usually obtained by histology and detection of the organism in biopsy specimens obtained by rhinoscopy (Figure 8) or nasal cavity lavage techniques [EBM grade III]. As *Aspergillus* species can be found on mucosal surfaces of healthy animals, infection can only be diagnosed if samples are taken from a deep layer of tissue, and it is important to take samples directly from affected areas. Within tissues, *Aspergillus* species grows with branched, septate hyphae (2–5 µm diameter).

Cytology of fine needle aspirates of orbital or palatine lesions can sometimes demonstrate fungal hyphae, but a negative result does not rule out aspergillosis.

If cultured on special growth media (eg, Sabouraud agar), *Aspergillus* species form mycelia with clearly visible conidia on conidiophores within 5–7 days (Figure 9). A single positive culture from swabs or secretions without histological evidence is not diagnostic, as the organism is ubiquitous.




Figure 9 *A fumigatus* conidial heads from a squash preparation of fungal plaques (inset) in a Scottish shorthair cat with sinonasal aspergillosis. Courtesy of Vanessa Barrs, University Veterinary Teaching Hospital, Sydney, Australia

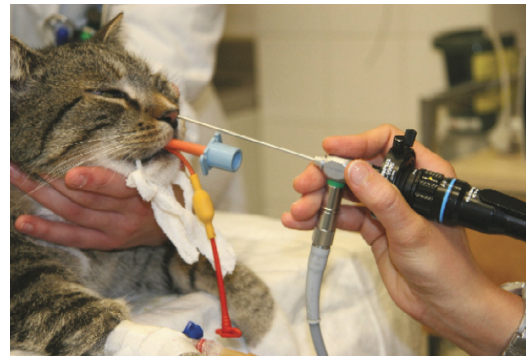


Figure 8 Rhinoscopy being performed in a cat with chronic nasal discharge to obtain samples for histology and culture of *Aspergillus* species. Courtesy of Blanka Schulz, Ludwig Maximilians University, Munich, Germany

As *Aspergillus* species can be found on mucosal surfaces of healthy animals, infection can only be diagnosed if samples are taken from a deep layer of tissue.



EBM grades
The ranking system for grading the level of evidence of various statements within this article is described on page 533 of this Special Issue.

Polymerase chain reaction has recently been offered for the detection of *Aspergillus* species, but its relevance in veterinary medicine is not yet clear.¹⁵

A new non-invasive test is the measurement of serum galactomannan, a polysaccharide fungal cell wall component by one-stage, immunoenzymatic sandwich ELISA. Overall, the test is moderately specific, but has a poor sensitivity and, thus, is not very helpful to rule out the disease [EBM grade IV].¹⁶

Detection of antibodies

Aspergillus species antibody testing for cats is available on the basis of agar gel immunodiffusion, latex agglutination, counter-immunoelectrophoresis or ELISA. Due to high numbers of positive results in healthy cats (up to 15%), positive test results should always be evaluated in combination with clinical signs and histology results. Negative results should also be interpreted with caution, as some individuals only produce low amounts of antibodies (mostly when infected with *A fumigatus*) that might be missed. Antibody testing was not useful in two of four cats with fungal rhinitis [EBM grade IV].⁷ Nevertheless, antibody measurement can give useful hints in some potentially affected cats when interpreted carefully and can be very helpful in the decision to perform more invasive diagnostics [EBM grade III].¹

Treatment

No prospective controlled studies exist on the treatment of aspergillosis in cats, and the available information is based only on retrospective case reports. In general, response to therapy and prognosis in SNA is good when intensive and sufficiently long treatment is instituted. Response to treatment is less successful in invasive SOA, and the prognosis is worse.⁸ In systemic aspergillosis, the prognosis is generally poor.

In SNA, the treatment of choice is a

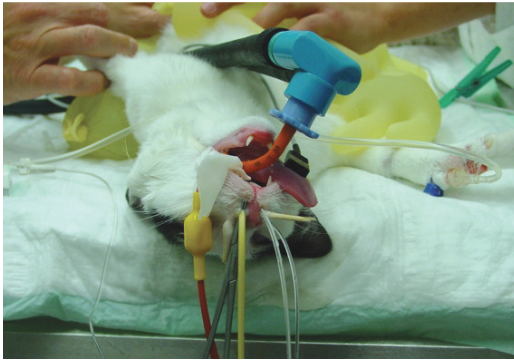


Figure 10 Local infusion of clotrimazole under general anaesthesia in a cat with sinonasal aspergillosis. Courtesy of Bianka Schulz, Ludwig Maximilians University, Munich, Germany

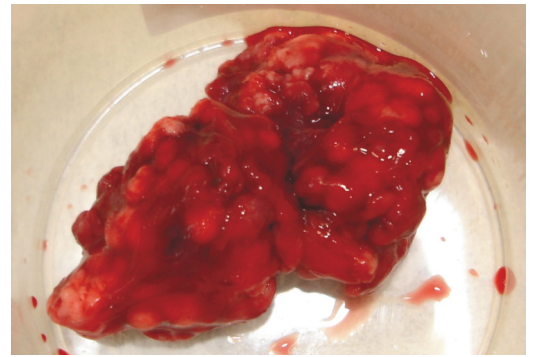


Figure 11 Retrobulbar granuloma after radical orbital debridement surgery. Courtesy of Vanessa Barrs, University Veterinary Teaching Hospital, Sydney, Australia

combination of systemic antifungal treatment (itraconazole, fluconazole, amphotericin B, posaconazole, voriconazole or terbinafine) in combination with local therapy, using clotrimazole or enilconazole intranasal infusions under general anaesthesia (Table 1) [EBM grade III]. Systemic antifungal treatment should be administered over several months, and owners should be informed early about the long treatment required. Based on case series, best choices for systemic treatment are itraconazole (5 mg/kg q12h PO) alone or in combination with amphotericin B, or the new azoles posaconazole (2.5–4.5 mg/kg q12h PO) and voriconazole (5–12 mg/kg q24h PO) [EBM grade III]. Voriconazole looks like a promising drug, but can result in adverse neurological effects, including ataxia, paraplegia and cranial nerve deficits.¹⁷ Therefore, voriconazole should only be used in selected cases until more studies on safety in cats have been performed. In cases of central nervous system involvement, fluconazole (1.25–2.5 mg/kg q12h PO) is a good option.

The local treatment is usually performed with infusion of clotrimazole (Figure 10). This requires access to affected tissues and is less effective when the infection occurs deep in the tissue. Surgical debridement of gross fungal lesions (Figure 11) before local treatment is recommended to increase the chance of complete remission [EBM grade III].^{8,18} A single intranasal infusion of clotrimazole led to long-term resolution of clinical signs in two studies, involving three cats³ and two cats [EBM grade IV].¹⁹ Multiple local treatments probably are better to

reduce relapses. Systemic treatment solely without local infusions is not as successful. Four cats with fungal rhinitis were treated with itraconazole orally; when therapy was discontinued, clinical signs recurred [EBM grade IV].⁷

In SOA, treatment is more difficult. In severe SOA, surgery is necessary – either lateral orbitotomy or eye enucleation.¹³ In a series of three cases with SOA, two cats were treated with voriconazole and surgery with successful results [EBM grade IV].¹³ Other drugs have been used in cats with SOA, including echinocandins in two cats, caspofungin as single treatment with good results in one cat [EBM grade IV],¹ and micafungin in one cat showing no success.² In one case, posaconazole cured a cat with SOA which had not responded to itraconazole plus amphotericin B [EBM grade III];¹² in another case, long clinical remission was achieved with posaconazole after no improvement with itraconazole plus terbinafine treatment [EBM grade III].¹⁸

If only the eyes are involved, local treatment can be successful. An 8-year-old cat that suffered from ulcerative keratitis with stromal loss, stromal infiltrate, corneal oedema, perilimbal vascularisation and miosis was treated with 1% voriconazole solution, and the keratomycosis resolved successfully [EBM grade III].¹¹

Although associated with a poor prognosis, one cat with pulmonary aspergillosis was successfully managed with a combination of surgery (lung lobectomy and chest drainage) and systemic itraconazole therapy for 1 month [EBM grade IV].¹⁰

When treated aggressively and for long enough, the prognosis for sinonasal aspergillosis is good; it is guarded in sino-orbital, and poor in systemic aspergillosis.



Table 1 Systemic treatment for aspergillosis (most commonly used drugs)

Drug	Dose	Comments
Clotrimazole		Single or multiple intranasal local instillation
Itraconazole	5 mg/kg q12h PO	Suggested drug of choice after local treatment (should be given for at least 2–3 months or 1 month beyond clinical cure)
Fluconazole	1.25–2.5 mg/kg q12h PO	Should be considered in cases of CNS infection (should be given for at least 2–3 months or 1 month beyond clinical cure)

PO = oral, CNS = central nervous system

Prevention

Due to the ubiquitous occurrence and the high resistance of the pathogen, prophylaxis is hardly possible. Although an association of aspergillosis with immunosuppression is not clearly established, prophylactic measures in immunocompromised animals consist of reducing exposure. Therefore, immunosuppressed animals should be kept indoors.

Funding

The authors received no specific grant from any funding agency in the public, commercial or not-for-profit sectors for the preparation of this article. The ABCD is supported by Merial, but is a scientifically independent body.

Conflict of interest


The authors do not have any potential conflicts of interest to declare.

References

- Barrs VR, Halliday C, Martin P, Wilson B, Krockenberger M, Gunew M, et al. **Sinonasal and sino-orbital aspergillosis in 23 cats: aetiology, clinicopathological features and treatment outcomes.** *Vet J* 2012; 191: 58–64.
- Kano R, Itamoto K, Okuda M, Inokuma H, Hasegawa A and Balajee SA. **Isolation of *Aspergillus udagawae* from a fatal case of feline orbital aspergillosis.** *Mycoses* 2008; 51: 360–361.
- Tomsa K, Glaus TM, Zimmer C and Greene CE. **Fungal rhinitis and sinusitis in three cats.** *J Am Vet Med Assoc* 2003; 222: 1380–1384, 1365.
- Barachetti L, Mortellaro CM, Di Giancamillo M, Giudice C, Martino P, Travetti O, et al. **Bilateral orbital and nasal aspergillosis in a cat.** *Vet Ophthalmol* 2009; 12: 176–182.
- Schulz B, Unterer S, Hartmann A, Werckenthin C, Brühshwein A and Hartmann K. **Diagnostik und therapie der nasalen aspergillose bei der katze – fallbeschreibung und literaturübersicht.** *Tierärztl Prax* 2007; 35: 281–286.
- Hamilton HL, Whitley RD and McLaughlin SA. **Exophthalmos secondary to aspergillosis in a cat.** *J Am Anim Hosp Assoc* 2000; 36: 343–347.
- Whitney BL, Broussard J and Stefanacci JD. **Four cats with fungal rhinitis.** *J Feline Med Surg* 2005; 7: 53–58.
- Barrs VR, Beatty JA, Lingard AE, Malik R, Krockenberger MB, Martin P, et al. **Feline sino-orbital aspergillosis: an emerging clinical syndrome.** *Aust Vet J* 2007; 85: N23.
- Goodall SA, Lane JG and Warnock DW. **The diagnosis and treatment of a case of nasal aspergillosis in a cat.** *J Small Anim Pract* 1984; 25: 627–633.
- Hazell KL, Swift IM and Sullivan N. **Successful treatment of pulmonary aspergillosis in a cat.** *Aust Vet J* 2011; 89: 101–104.
- Labelle AL, Hamor RE, Barger AM, Maddox CW and Breaux CB. ***Aspergillus flavus* keratomycosis in a cat treated with topical 1% voriconazole solution.** *Vet Ophthalmol* 2009; 12: 48–52.
- McLellan GJ, Aquino SM, Mason DR, Kinyon JM and Myers RK. **Use of posaconazole in the management of invasive orbital aspergillosis in a cat.** *J Am Anim Hosp Assoc* 2006; 42: 302–307.
- Smith LN and Hoffman SB. **A case series of unilateral orbital aspergillosis in three cats and treatment with voriconazole.** *Vet Ophthalmol* 2010; 13: 190–203.
- Karnik K, Reichle JK, Fischetti AJ and Goggin JM. **Computed tomographic findings of fungal rhinitis and sinusitis in cats.** *Vet Radiol Ultrasound* 2009; 50: 65–68.
- Lau A, Chen S, Sorrell T, Carter D, Malik R, Martin P, et al. **Development and clinical application of a panfungal PCR assay to detect and identify fungal DNA in tissue specimens.** *J Clin Microbiol* 2007; 45: 380–385.
- Whitney J, Beatty JA, Martin P, Dhand NK, Briscoe K and Barrs VR. **Evaluation of serum galactomannan detection for diagnosis of feline upper respiratory tract aspergillosis.** *Vet Microbiol* 2013; 162: 180–185.
- Quimby JM, Hoffman SB, Duke J and Lappin MR. **Adverse neurologic events associated with voriconazole use in 3 cats.** *J Vet Intern Med* 2010; 24: 647–649.
- Giordano C, Gianella P, Bo S, Vercelli A, Giudice C, Della Santa D, et al. **Invasive mould infections of the naso-orbital region of cats: a case involving *Aspergillus fumigatus* and an aetiological review.** *J Feline Med Surg* 2010; 12: 714–723.
- Furrow E and Groman RP. **Intranasal infusion of clotrimazole for the treatment of nasal aspergillosis in two cats.** *J Am Vet Med Assoc* 2009; 235: 1188–1193.

KEY POINTS

- ❖ Aspergillosis is a fungal disease occurring worldwide; it is less common in cats than in dogs.
- ❖ Animals are infected through contamination from the environment; direct transmission does not occur.
- ❖ Aspergillosis is not a zoonosis; humans also acquire the infection from the environment.
- ❖ In cats, aspergillosis occurs in two main forms: the sinonasal, and the more invasive sino-orbital form.
- ❖ Diagnosis relies on detection of the organism in affected tissues, usually by cytology or histology.
- ❖ Treatment should consist of local and systemic antifungal therapy.
- ❖ When treated aggressively and for long enough, the prognosis for sinonasal aspergillosis is good; it is guarded in sino-orbital, and poor in systemic aspergillosis.



Available online at jfms.com

Reprints and permission: sagepub.co.uk/journalsPermissions.nav