

# Journal of Feline Medicine and Surgery

<http://jfm.sagepub.com/>

## **Sporotrichosis in cats: ABCD guidelines on prevention and management**

Albert Lloret, Katrin Hartmann, Maria Grazia Pennisi, Lluís Ferrer, Diane Addie, Sándor Belák, Corine Boucraut-Baralon, Herman Egberink, Tadeusz Frymus, Tim Gruffydd-Jones, Margaret J Hosie, Hans Lutz, Fulvio Marsilio, Karin Möstl, Alan D Radford, Etienne Thiry, Uwe Truyen and Marian C Horzinek  
*Journal of Feline Medicine and Surgery* 2013 15: 619  
DOI: 10.1177/1098612X13489225

The online version of this article can be found at:  
<http://jfm.sagepub.com/content/15/7/619>

### **Disclaimer**

The Journal of Feline Medicine and Surgery is an international journal and authors may discuss products and formulations that are not available or licensed in the individual reader's own country. Furthermore, drugs may be mentioned that are licensed for human use, and not for veterinary use. Readers need to bear this in mind and be aware of the prescribing laws pertaining to their own country. Likewise, in relation to advertising material, it is the responsibility of the reader to check that the product is authorised for use in their own country. The authors, editors, owners and publishers do not accept any responsibility for any loss or damage arising from actions or decisions based on information contained in this publication; ultimate responsibility for the treatment of animals and interpretation of published materials lies with the veterinary practitioner. The opinions expressed are those of the authors and the inclusion in this publication of material relating to a particular product, method or technique does not amount to an endorsement of its value or quality, or the claims made by its manufacturer.

Published by:

[International Society of Feline Medicine](#)



[American Association of Feline Practitioners](#)



and

<http://www.sagepublications.com>

**Additional services and information for *Journal of Feline Medicine and Surgery* can be found at:**

**Email Alerts:** <http://jfm.sagepub.com/cgi/alerts>

**Subscriptions:** <http://jfm.sagepub.com/subscriptions>

**Reprints:** <http://www.sagepub.com/journalsReprints.nav>

**Permissions:** <http://www.sagepub.com/journalsPermissions.nav>

>> [Version of Record](#) - Jun 27, 2013

[What is This?](#)

Downloaded from [jfm.sagepub.com](http://jfm.sagepub.com) at Universite de Liege on September 3, 2013



# SPOROTRICHOSIS IN CATS

## ABCD guidelines on prevention and management

Albert Lloret, Katrin Hartmann, Maria Grazia Pennisi, Lluís Ferrer\*, Diane Addie, Sándor Belák, Corine Boucraut-Baralon, Herman Egberink, Tadeusz Frymus, Tim Gruffydd-Jones, Margaret J Hosie, Hans Lutz, Fulvio Marsilio, Karin Möstl, Alan D Radford, Etienne Thiry, Uwe Truyen and Marian C Horzinek



### Agent properties

Sporotrichosis is a deep cutaneous mycosis caused by the dimorphic saprophytic fungus *Sporothrix schenckii* (a 3–5 µm wide, 5–9 µm long, pleomorphic, round, oval or cigar-shape yeast). Many mammalian species – including horses, camels, cattle and swine, as well as dogs and cats – can be infected. Feline infection was first reported in 1971.<sup>1</sup>

The fungus exists as a hyphal or mycelial form at environmental temperatures below 37°C and as a yeast form at body temperature. Several subtypes have been recognised using molecular techniques, but – in humans – these are not correlated with the various clinical pictures or responses to treatment.<sup>2</sup> In cats, however, differences

in virulence have been found between isolates from individuals showing cutaneous forms versus disseminated forms.<sup>3</sup>

### Epidemiology

*S. schenckii* is found worldwide in soil, wood, living plants and

decaying plant material. Human infections are caused by traumatic inoculation of contaminated soil or organic material (sphagnum moss, hay bales, mould, plant thorns, wood splinters), especially in forestry workers, but also after contact with animals (fish spines, squirrel bites, armadillo scratches, and draining lesions and scratches of infected cats or dogs).<sup>4</sup> Many humans are thought to have been infected by cats – even healthy cats that have been in contact with infected cats may pose a risk, as their oral samples have tested culture positive.<sup>5</sup>

Both human and animal disease is rare in Europe,<sup>6</sup> the USA<sup>7,8</sup> and Japan;<sup>9</sup> cases have been described in particular areas (eg, in the Apulia region in Italy, and southeastern and southwestern USA). In a recent

**Overview:** Sporotrichosis is an important subcutaneous fungal infection of humans and animals in some endemic tropical and subtropical areas. Among domestic species, cats are the most frequently infected.

**Infection:** The primary mode of transmission is traumatic inoculation of fungal conidia from plants and soil. Contact with infected cats is the major mode of transmission to humans, especially in endemic areas like Brazil, where a large epidemic has occurred in the past decade.

**Disease signs:** Most cases in cats are cutaneous, presenting as multiple ulcerated nodules and draining tracts in the skin. Lymphadenopathy, respiratory signs and systemic dissemination may also occur.

**Diagnosis** Diagnosis is based on fungal detection by cytology and/or histology, and confirmation by culture.

**Treatment:** Treatment consists of at least 2 months' systemic antifungal therapy, with itraconazole as the first-choice agent.

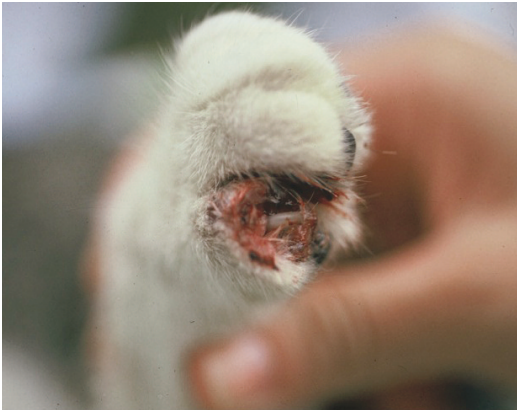The prognosis is favourable provided there is good owner compliance and adverse drug effects do not occur.

**Prevention:** Contact with infected cats carries a high zoonotic risk. Cat owners travelling to endemic areas should be warned and advised to keep their cats indoors to prevent infection. Professionals must wear gloves when handling cats with skin nodules and ulcers and dealing with diagnostic samples.

#### European Advisory Board on Cat Diseases

The European Advisory Board on Cat Diseases (ABCD) is a body of experts in immunology, vaccinology and clinical feline medicine that issues guidelines on prevention and management of feline infectious diseases in Europe, for the benefit of the health and welfare of cats. The guidelines are based on current scientific knowledge of the diseases and available vaccines concerned.

The latest version of the sporotrichosis in cats guidelines is available at [www.abcd-vets.org](http://www.abcd-vets.org)



**Figure 1** Ulcerative lesions around the claw in a cat with sporotrichosis. Courtesy of Dr Larsson, São Paulo, Brazil

retrospective study of 23 cases in various mammalian species in California, the cat was the most commonly affected (14 out of the 23 cases).<sup>10</sup> In Central and South America, however, sporotrichosis represents the most common deep mycosis. In Brazil it is endemic, and an important epidemic outbreak affecting humans, cats and dogs has been reported from Rio de Janeiro.<sup>2,5,11</sup>

The disease in cats is mainly reported in free-roaming intact males.<sup>12</sup> Presumably, most infections occur when the fungus is inoculated into a bite or scratch wound from an infected cat. The fungus can be isolated from claws<sup>13</sup> and skin lesions (Figure 1), but also, importantly, from the nasal and oral cavities.<sup>11</sup>

**Pathogenesis**

Infection occurs through contact or skin puncture wounds at the inoculation site, and there may be local propagation. Infection spreads via the regional lymphatic system, producing lymphangitis and lymphadenitis.<sup>4</sup> On rare occasions, mainly in immunocompromised patients, the infection may disseminate systemically.

In cats, sporotrichosis is mainly reported in free-roaming intact males.



**Clinical presentation**

Sporotrichosis has three clinical forms in cats: cutaneous, cutaneolymphatic and disseminated.

In the cutaneous form, there are multiple, ulcerated and crusted nodules, draining tracts and abscesses or cellulitis on the head (Figure 2), limbs (Figures 3 and 4) and tail-base region, reflecting common areas for bites and scratches during fights. In some cases, these lesions may become necrotic, exposing underlying tissues.<sup>10,14</sup> Although most cases of generalised cutaneous lesions arise from haematogenous spread, dissemination (eg, to the paws, limbs and ears) may follow autoinoculation during grooming.<sup>4</sup>

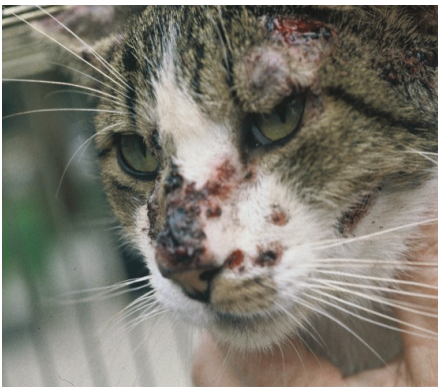Lymphatic involvement may not be clinically evident, but can be demonstrated histologically, either in biopsies or necropsy samples.<sup>10,14</sup>

Many organs may be affected in disseminated cases, the lungs and liver being preferred sites.<sup>10,15</sup> Widespread cutaneous lesions typically arise from haematogenous dissemination after a primary respiratory infection. In these cases, the fungus can be cultured from blood.

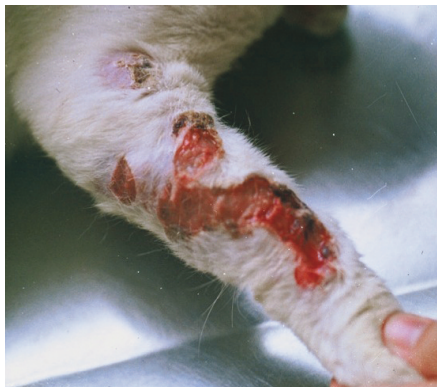Systemic signs are non-specific and include lethargy, anorexia and fever. Respiratory signs occur in about one-third of cases, representing the most frequent non-cutaneous sign.<sup>14,16</sup> Sneezing has been reported in infected cats, in which the fungus was isolated from nasal mucosa.<sup>16</sup>

Some cats with disseminated disease have been found to be infected with feline immunodeficiency virus (FIV), but immunosuppression is not required for infection or clinical manifestation of the disease. Some FIV-positive cats affected with sporotrichosis have been treated, with complete resolution of the fungal lesions.<sup>14</sup>

Blood abnormalities (anaemia, leukocytosis, neutrophilia, hyperglobulinaemia and hypoalbuminaemia) reported in cats with feline sporotrichosis are non-specific, and consistent with a chronic inflammatory condition.<sup>14</sup>



**Figure 2** Ulcerative crusted facial lesions in a cat with sporotrichosis. Courtesy of Dr Larsson, São Paulo, Brazil



**Figure 3** Multiple ulcerative crusted lesions on the forelimb of a cat with sporotrichosis. Courtesy of Dr Larsson, São Paulo, Brazil



**Figure 4** Ulcerative lesions on the hind limb of a cat with sporotrichosis. Courtesy of Dr Larsson, São Paulo, Brazil



## Diagnosis

Although uncommon in Europe, sporotrichosis should be included in the differential diagnosis of nodular and/or ulcerative skin disease with draining tracts. This is particularly true for outdoor (fighting) cats, if a bacterial cause was initially suspected but the response to antibiotic treatment was poor, and/or the cat comes from an endemic area.

The fungus may be demonstrated by cytology and/or histology, with confirmation by fungal culture.

### Cytology

Smears from draining tracts and ulcers or fine needle aspirates from nodules or ulcers should always be obtained. Stained samples (eg, Romanowsky) should be examined carefully for yeast-like organisms. Special stains (eg, periodic acid-Schiff [PAS]) may help to visualise and confirm the presence of fungi. Some authors report easy identification in exudates from cats, while others have found this difficult.<sup>4,10</sup> Good sensitivity (78.9%) of cytological examination as compared with culture has recently been reported in a study of 806 cats [EBM grade III].<sup>17</sup>

*S schenckii* appears to be mainly intracellular, residing within macrophages and inflammatory cells, but may sometimes also be found extracellularly. Suspicious samples should be submitted for confirmatory fungal culture.

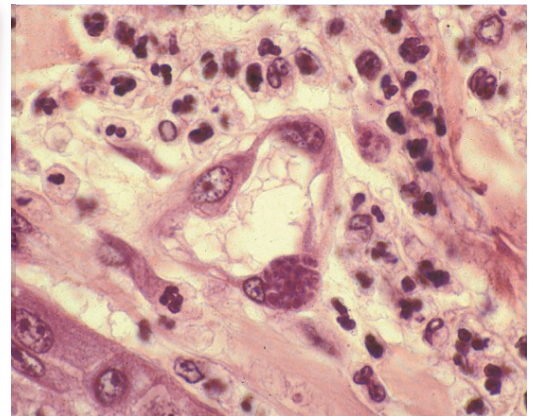
### Fungal culture

Culture is the confirmatory test of choice.<sup>18</sup> Only a few organisms may be present in the lesions, and exudate samples are best collected from the deep areas of the draining tracts/ulcers.<sup>4,17</sup> Preferably, a piece of tissue should be submitted to the laboratory to avoid false-negative results. Blood culture is recommended if the disseminated form is suspected.<sup>19</sup> *S schenckii* has also been cultured from nasal swabs and bronchoalveolar lavage samples in cats with respiratory signs.<sup>16</sup>

#### EBM grades

The ranking system for grading the level of evidence of various statements within this article is described on page 533 of this Special Issue.

Sporotrichosis should be included in the differential diagnosis of nodular and/or ulcerative skin disease with draining tracts.



**Figure 5** Pyogranulomatous inflammatory reaction showing numerous *Sporothrix* organisms within macrophages  
Courtesy of Dr Larsson, São Paulo, Brazil

### Histology

Histopathology is useful for the diagnosis of sporotrichosis in cases with intact nodules. The histological pattern is similar to that seen in other fungal infections, with a nodular to diffuse pyogranulomatous inflammatory reaction involving the dermis and subcutaneous tissues, and sometimes extending into deeper tissues.<sup>10</sup> The organisms, which are usually inside macrophages, may be numerous and readily visualised upon haematoxylin-eosin staining (Figure 5); when they are scarce, special PAS staining is necessary to improve sensitivity.<sup>10</sup>

### Other tests

Recently, an ELISA for the detection of *S schenckii* antibodies has been evaluated, showing good sensitivity and specificity (over 90%); it may serve as a screening tool for feline sporotrichosis [EBM grade I].<sup>20</sup> The PCR has been successfully used to identify *S schenckii* in biopsy samples.<sup>21</sup>

### Treatment

Prospective studies on the treatment of feline sporotrichosis do not exist, and all information stems from retrospective studies and case reports.

Itraconazole is the treatment of choice (Table 1) [EBM grade III].<sup>10,18</sup> Treatment should be continued 1 month beyond clinical cure, which means that the drug needs to be administered for more than 2 months. Itraconazole is potentially hepatotoxic; cat owners should be warned about clinical signs suggestive of hepatic disease, and monthly monitoring of serum liver enzymes is recommended.

A supersaturated solution of potassium iodide given orally is the treatment of choice for sporotrichosis in dogs; it has also been used in cats, where hepatotoxic effects are

Table 1 Treatment of sporotrichosis		
Drug	Dose and frequency	Comments
Itraconazole	10 mg/kg q24h PO	Suggested treatment of choice; continue for 2–3 months or 1 month beyond clinical cure
Potassium iodide	Supersaturated solution 2.5–20 mg/kg q24h PO	Clinical adverse effects, mainly hepatotoxicity, may occur in many cats Alternative if adverse effects or lack of efficacy to itraconazole
Terbinafine	30 mg/cat q24h PO	May be used in combination with itraconazole Consider if adverse effects or lack of efficacy to itraconazole
Fluconazole	50 mg/cat q24h PO	Consider if disseminated infection May be used in combination with itraconazole

more likely to develop. However, a recent observational study in 48 cats treated with oral potassium iodide in capsules (variable doses from 2.5–20 mg/kg q24h) showed a success rate of 47.9%; also, fewer adverse effects compared with previous studies were seen, and this drug might serve as an alternative to itraconazole [EBM grade III].<sup>22</sup>

Ketoconazole, commonly used in dogs as an alternative to potassium iodide, has also been used in cats, but adverse hepatic effects are more frequent compared with itraconazole.<sup>23</sup>

Recent reports have demonstrated the efficacy of terbinafine (allylamine derivative) in people with sporotrichosis.<sup>24</sup> As it showed good efficacy in vitro,<sup>25</sup> this drug might be an alternative for the treatment of cats that do not tolerate itraconazole, in cases that respond poorly, and/or if an azole resistance is suspected [EBM grade IV].

In a large retrospective study in Brazil, various regimens and combinations of antifungals, including itraconazole plus potassium iodide, itraconazole plus fluconazole, itraconazole plus terbinafine, and ketoconazole alone, were examined. About one-fifth of the cats were cured (68/347); in the others some clinical improvement was observed.<sup>15</sup> In a retrospective study in California, most cats were successfully treated with itraconazole; in two cases treated with iodide derivatives and one case of disseminated disease treated with fluconazole the infection was controlled [EBM grade III].<sup>10</sup>

Successful intralesional amphotericin B treatment was documented in a single case report, and in a series of 26 cats (in combination with itraconazole) to treat refractory skin disease [EBM grade III].<sup>26,27</sup>

Concurrent bacterial infection, which is common, must be treated with an appropriate antibiotic for 1–2 months.<sup>4</sup>

## Zoonotic risk

Close feline contacts are a potential source of zoonotic infection. In recent years, a growing number of human cases have been described, which have occurred after contact with sick infected and healthy carrier cats in countries where disease is endemic, such as Brazil or India.<sup>28–30</sup> A genuine epidemic of human sporotrichosis associated with transmission by cats has occurred in Brazil over the past decade.<sup>31</sup> Today, this route of human infection is considered significant, and more common than vegetal or organic environmental sources. Cats are more efficient transmitters than other animals, presumably because larger amounts of the fungus are present in tissues, exudates and even faeces, and the infection may be transmitted even in the absence of penetrating skin lesions.<sup>7</sup>

Veterinarians and persons handling infected cats are at a high risk of acquiring the infection. It is recommended that disposable gloves are always worn when handling cats with any kind of ulcerated, draining tract skin lesions, especially in areas where the infection is endemic.

### Zoonosis

Veterinarians and persons handling infected cats are at high risk of acquiring *S schenckii* infection (sporotrichosis).



## Prognosis

The prognosis is usually good, if treatment duration and owner compliance are adequate.<sup>10,14</sup> However, it is poor in disseminated infections and/or if treatment is discontinued before the end of the recommended regimen.<sup>14</sup>

## Prevention

As a preventive measure, cats should be kept indoors in endemic areas to avoid contact with infected or carrier cats; this is especially important in immunocompromised animals (eg, retrovirus-infected cats or those receiving immunosuppressive drugs). Owners moving to endemic areas, like Central and South America, should be warned about sporotrichosis, especially if cats will be allowed to have access to outdoors.

## KEY POINTS

- ❖ Sporotrichosis is an important subcutaneous infection of humans and animals. Cats are most frequently infected.
- ❖ Sporotrichosis is endemic in some tropical and subtropical areas; it is particularly frequent in Brazil, but has been diagnosed in certain areas of Europe, North America and Japan.
- ❖ The zoonotic risk is high, through contact with infected cats, which can be healthy carriers.
- ❖ Sporotrichosis should be included in the list of differential diagnoses for cats with multiple ulcerated nodules, ulcers and draining tracts, especially in 'fight and bite' locations.
- ❖ Diagnosis is based on recognition of the fungus in cytology or histology samples and confirmation by culture.
- ❖ Itraconazole is the first choice for treatment. Other antifungals may be helpful: potassium iodide in capsules, fluconazole, amphotericin B and combinations.
- ❖ Treatment should be extended for 1 month after resolution of the lesions.
- ❖ Owner compliance is the most important factor in determining the prognosis.
- ❖ Cat owners travelling to endemic areas must be warned about the disease. Veterinarians dealing with infected or suspicious cats must use preventive measures to avoid infection.



## Funding

The authors received no specific grant from any funding agency in the public, commercial or not-for-profit sectors for the preparation of this article. The ABCD is supported by Merial, but is a scientifically independent body.

## Conflict of interest

The authors do not have any potential conflicts of interest to declare.

## References

- Werner RE Jr, Levine BG, Kaplan W, Hall WC and Nilles BJ. **Sporotrichosis in a cat.** *J Am Vet Med Assoc* 1971; 159: 407–411.
- Galhardo MC, de Oliveira RM, Valle AC, Paes Rde A, Silvatavares PM, Monzón A, et al. **Molecular epidemiology and antifungal susceptibility pattern of *Sporothrix schenckii* isolates from a cat-transmitted epidemic of sporotrichosis in Rio de Janeiro, Brazil.** *Med Mycol* 2008; 46: 141–151.
- Nobre Mde O, Antunes Tde A, de Faria MO, Cleff MB, Fernández CG, Muschner AC, et al. **Differences in virulence between isolates of feline sporotrichosis.** *Mycopathologia* 2005; 160: 43–49.
- Rosser EJ and Dunstan RW. **Sporotrichosis.** In: Greene CE (ed). *Infectious diseases of the dog and the cat.* 3rd ed. St Louis: Saunders, 2006, pp 608–612.
- Schubach TM, Schubach AO, dos-Reis RS, Cuzzi-Maya T, Blanco TC, Monteiro DF, et al. ***Sporothrix schenckii* isolated from domestic cats with and without sporotrichosis in Rio de Janeiro, Brazil.** *Mycopathologia* 2002; 153: 83–86.
- Gonzalez Cabo JF, de las Heras Guillamon M, Latre Cequiel MW and García de Jalón Ciercoles JA. **Feline sporotrichosis: a case report.** *Mycopathologia* 1989; 108: 149–154.
- Dunstan RW, Langham RF, Reimann KA and Wakenell PS. **Feline sporotrichosis: a report of five cases with transmission to humans.** *J Am Acad Dermatol* 1986; 15: 37–45.
- Carvalho J Jr, Caldwell JB, Radford BL and Feldman AR. **Feline-transmitted sporotrichosis in the southwestern United States.** *West J Med* 1991; 154: 462–465.
- Nakamura Y, Sato H, Watanabe S, Takahashi H, Koide K and Hasewaga A. ***Sporothrix schenckii* isolated from a cat in Japan.** *Mycoses* 1996; 39: 125–128.
- Crothers SL, White SD, Ihrke PJ and Affolter VK. **Sporotrichosis: a retrospective evaluation of 23 cases seen in northern California (1987–2007).** *Vet Dermatol* 2009; 20: 249–259.
- Schubach A, Barros MB and Wanke B. **Epidemic sporotrichosis.** *Curr Opin Infect Dis* 2008; 21: 129–133.
- Davies C and Troy GC. **Deep mycotic infections in cats.** *J Am Anim Hosp Assoc* 1996; 32: 380–391.
- Schubach TM, Valle C, Gutierrez-Galhardo MC, Monteiro PC, Reis RS, Zancopé-Oliveira RM, et al. **Isolation of *Sporothrix schenckii* from the nails of domestic cats (*Felis catus*).** *Med Mycol* 2001; 39: 147–149.
- Welsh RD. **Sporotrichosis.** *J Am Vet Med Assoc* 2003; 223: 1123–1126.
- Schubach TM, Schubach A, Okamoto T, Barros MB, Figueiredo FB, Cuzzi T, et al. **Evaluation of an epidemic of sporotrichosis in cats: 347 cases, 1998–2001.** *J Am Vet Med Assoc* 2004; 224: 1623–1629.
- Leme LR, Schubach TM, Santos IB, Figueiredo FB, Pereira SA, Reis RS, et al. **Mycological evaluation of bronchoalveolar lavage in cats with respiratory signs from Rio de Janeiro, Brazil.** *Mycoses* 2007; 50: 210–214.
- Pereira SA, Menezes RC, Gremiao ID, Silva JN, Honse C de O, Figueiredo FB, et al. **Sensitivity of cytopathological examination in the diagnosis of feline sporotrichosis.** *J Feline Med Surg* 2011; 13: 220–223.
- Barros MB, de Almeida Paes R and Schubach AO. ***Sporothrix schenckii* and sporotrichosis.** *Clin Microbiol Rev* 2011; 24: 633–654.
- Schubach TM, Schubach AO, Okamoto T, Pellon IV, Fialho-Monteiro AV, Reis RS, et al. **Hematogenous spread of *Sporothrix schenckii* in cats with naturally acquired sporotrichosis.** *J Small Anim Pract* 2003; 44: 395–398.
- Fernandes GF, Lopes-Bezerra LM, Bernardes-Engemann AR, Schubach TM, Dias MA, Pereira SA, et al. **Serodiagnosis of sporotrichosis infection in cats by enzyme-linked immunosorbent assay using a specific antigen, SsCBF, and crude exoantigens.** *Vet Microbiol* 2011; 147: 445–449.
- Kano R, Watanabe K, Murakami M, Yanai T and Hasegawa A. **Molecular diagnosis of feline sporotrichosis.** *Vet Rec* 2005; 156: 484–485.
- Reis EG, Gremiao ID, Kitada AA, Rocha RF, Castro VS, Barros MB, et al. **Potassium iodide capsule treatment of feline sporotrichosis.** *J Feline Med Surg* 2012; 14: 399–404.
- Pereira SA, Passos SR, Silva JN, Gremião ID, Figueiredo FB, Teixeira JL, et al. **Response to azolic antifungal agents for treating feline sporotrichosis.** *Vet Rec* 2010; 166: 290–294.
- Francesconi G, Valle AC, Passos S, Reis R and Galhardo MC. **Terbinafine (250 mg/day): an effective and safe treatment of cutaneous sporotrichosis.** *J Eur Acad Dermatol Venereol* 2009; 23: 1273–1276.
- Meinerz AR, Nascente Pda S, Schuch LF, Cleff MB, Santrin R, Brum Cda S, et al. **In vitro susceptibility of isolates of *Sporothrix schenckii* to terbinafine and itraconazole.** *Rev Soc Bras Med Trop* 2007; 40: 60–62.
- Gremiao ID, Schubach TM, Pereira SA, Rodríguez AM, Chaves AR and Barros MB. **Intralesional amphotericin B in a cat with refractory localised sporotrichosis.** *J Feline Med Surg* 2009; 11: 720–723.
- Gremiao I, Schubach T, Pereiras S, Rodrigues A, House C and Barros M. **Treatment of refractory feline sporotrichosis with a combination of intralesional amphotericin B and oral itraconazole.** *Aust Vet J* 2011; 89: 346–351.
- Barros MB, Schubach Ade O, do Valle AC, Gutierrez Galhardo MC, Conceição-Silva F, Schubach TM, et al. **Cat transmitted sporotrichosis epidemic in Rio de Janeiro, Brazil: description of a series of cases.** *Clin Infect Dis* 2004; 38: 529–535.
- Cordeiro FN, Bruno CB, Paula CD and Motta Jde O. **Familial occurrence of zoonotic sporotrichosis.** *An Bras Dermatol* 2011; 86: 121–124.
- Yegneswaran PP, Sripathi H, Bairy I, Lonikar V, Rao R and Prabhu S. **Zoonotic sporotrichosis of lymphocutaneous type in a man acquired from a domesticated feline source: report of a first case in southern Karnataka, India.** *Int J Dermatol* 2009; 48: 1198–1200.
- Schubach AO, Schubach TM and Barros MB. **Epidemic cat-transmitted sporotrichosis.** *N Engl J Med* 2005; 353: 1185–1186.

Available online at [jfms.com](http://jfms.com)