

HEPATOZOONOSIS IN CATS

ABCD guidelines on prevention and management



Albert Lloret, Diane D Addie, Corine Boucraut-Baralon, Herman Egberink, Tadeusz Frymus, Tim Gruffydd-Jones, Katrin Hartmann, Marian C Horzinek, Margaret J Hosie, Hans Lutz, Fulvio Marsilio, Maria Grazia Pennisi, Alan D Radford, Etienne Thiry, Uwe Truyen and Karin Möstl

Overview: Hepatozoonosis of domestic cats has been reported in several countries, mainly as a subclinical infection.

Disease agent: Infection has been described mostly in areas where canine infection is present and, in recent years, *Hepatozoon felis* has been identified as a distinct species by molecular techniques. The vector for feline hepatozoonosis remains unknown and the pathogenesis has not been elucidated.

Infection in cats: Feline hepatozoonosis is mainly a subclinical infection and few cases have been reported with clinical signs. The diagnosis of hepatozoonosis in cats can be made by observation of parasite gamonts in blood smears, parasite meronts in muscles by histopathology, and detection of parasite DNA in blood and tissue by PCR.

Disease management: The treatment of choice is not known, but single cases have been treated with doxycycline or oxytetracycline and primaquine. Although the mode of transmission and the type of vector is not known, preventive treatment against blood-sucking vectors (fleas and ticks) is advised.

Agent properties

Hepatozoon species are apicomplexan parasites (family *Hepatozoidae*) with a blood-sucking arthropod final host and a vertebrate intermediate host.¹ In general, the agent is acquired by ingestion of the infected arthropod (eg, *Rhipicephalus sanguineus* in *H canis* and *H americanum* infection of dogs), but meat eating and hunting are also routes of infection (*H americanum*), as is transplacental transmission (*H canis*).²

More than 340 species of *Hepatozoon* have been described, not only in mammals but also in amphibians, reptiles, birds and marsupials. The first report in a domestic cat dates from 1908 when the parasite was named *Leucocytozoon felis domestici*.³ Later it was reclassified in the genus *Hepatozoon* species⁴ as a result of similarities with the species infecting dogs and wild canids. For some time, reports of the infection in cats referred to *Hepatozoon* species or *Hepatozoon*-like species.

More recently, with the use of molecular techniques, *H felis* was identified as a distinct and predominant species in cat infections;^{5,6} however, there is also evidence that *H canis* can infect cats.^{7–9}

Epidemiology

Feline hepatozoonosis has been reported in several countries worldwide, including India, South Africa, Nigeria, the USA, Brazil, Israel, Spain, France and Portugal.^{3,6,10–16} The prevalence of infection varies depending on the geographical area, cat life style and type of samples tested. Two studies showed a high prevalence of infection in Israel. In one study, meronts were found in the myocardium of 36% of cats examined post mortem.¹⁴ In a more recent study, *Hepatozoon* DNA was found in blood samples of 36% of cats tested.⁹ In Spain, in studies using blood PCR, prevalence rates were much lower, but varied depending on the study populations: 0.6% in domestic cats, 16% in a colony of feral cats and 4% in a group of privately owned cats visiting a referral hospital.^{5,6,17} Two recent studies in Portugal found *H felis* DNA in blood samples in 15.6% of randomly sampled cats and 8.6% of owned and shelter cats.^{16,18}

A significant association between infection and outdoor access has been reported, but no association with gender or age has been observed.⁹ There are conflicting observations as regards retroviral status; one study

European Advisory Board on Cat Diseases

The European Advisory Board on Cat Diseases (ABCD) is a body of experts in immunology, vaccinology and clinical feline medicine that issues guidelines on prevention and management of feline infectious diseases in Europe, for the benefit of the health and welfare of cats. The guidelines are based on current scientific knowledge of the diseases and available vaccines concerned.

The latest version of the hepatozoonosis in cats guidelines is available at www.abcdcatsvets.org and www.abcd-vets.org



European Advisory Board on Cat Diseases
www.abcdcatsvets.org
www.abcd-vets.org
 Corresponding author: Albert Lloret
 Email: Albert.LLoret@uab.cat



found no association between feline immunodeficiency virus (FIV) infection and *H felis* infection,⁹ while other studies found a significant association between FIV and feline leukaemia virus (FeLV) infection and hepatozoonosis in cats.^{15,17,19}

The route of transmission has not been fully elucidated yet, but the association with outdoor access suggests transmission by some ubiquitous vectors such as the common flea, mites or ticks, or predation as in other species. The arthropod vectors of *H felis* remain unknown, but recently *H felis* DNA was detected in ticks (*R sanguineus*) in Turkey and Portugal.^{20,21} Transplacental transmission of *H felis* has been suggested and could represent an important route of infection.⁹

Pathogenesis

There have been no published studies on the pathogenesis of infection in cats. Two forms of the parasite have been found in the cat: intracellular gamonts in neutrophils and monocytes, and meronts in several tissues. *H felis* usually produces an infection of myocardial and skeletal muscles.^{14,15} The infection does not lead to significant inflammatory reaction around the parasite meronts, so the cat rarely develops clinical signs.^{9,14,15} The presence of meronts has been observed in many other tissues as well as skeletal muscle and myocardium; for example, lung, liver, pancreas, bone marrow, lymph node and placenta, as well as in amniotic fluid.⁹

The level of parasitaemia is low, with fewer than 1% of neutrophils and monocytes containing *H felis* gamonts.¹⁹ Some studies have shown no correlation between the presence of gamonts in blood smears and meronts in muscle tissues.^{7,14,19}

Clinical presentation

Feline hepatozoonosis caused by *H felis* is mostly subclinical; a high proportion of cats appear to be infected with no overt clinical signs.⁹

The scant clinical information on the disease that exists is based on three case reports describing systemic disease; liver and/or kidney disease were present and *Hepatozoon*-like parasites were demonstrated in liver or blood.^{11,12,22} The remaining reported cases were infected cats with no clinical signs. In a retrospective study of seven cats with *Hepatozoon* species detected in

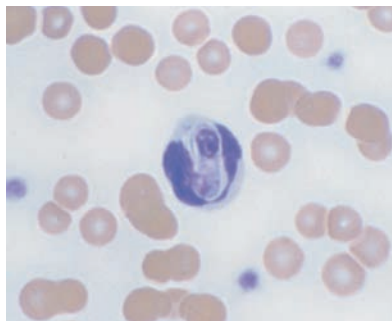


Figure 1 *Hepatozoon felis* gamont within a neutrophil in a cat blood smear. Courtesy of Professor Gad Baneth, School of Veterinary Medicine, Hebrew University, Jerusalem, Israel

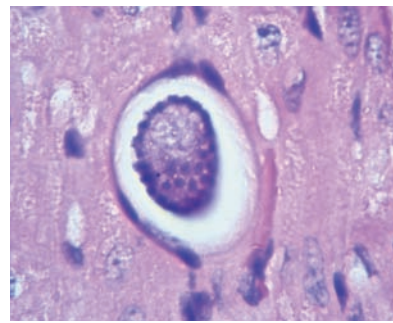


Figure 2 *Hepatozoon felis* meront within myocardial muscle in a cat. Courtesy of Professor Gad Baneth, School of Veterinary Medicine, Hebrew University, Jerusalem, Israel

H felis gamonts are less prominent and so are easily missed compared with the larger *H canis* gamonts in dogs.



blood smears, diverse clinical signs (lethargy, fever, weakness, lymphadenopathy) and clinicopathological abnormalities (anaemia and thrombocytopenia) were described.¹⁹ However, all seven cats were suffering from other diseases, which could explain the clinical signs. Four of the cats were co-

infected with retrovirus and two with haemotropic mycoplasmas, suggesting that the clinicopathological abnormalities were not associated with *Hepatozoon* infection. Interestingly, five of the cats had clinicopathological abnormalities suggesting muscular damage (elevated levels of creatine kinase and lactate dehydrogenase).¹⁹

Observation of *H felis* gamonts in a feline blood smear might be a sign of immunosuppression, which is why retrovirus testing and investigations for other co-infections and diseases is indicated. In an epidemiological study in Barcelona, Spain, four cats that tested positive for *H felis* were sick (attributed to other diseases) and one had leishmaniosis,⁶ suggesting that immunosuppression and/or concurrent disease could be risk factors for *Hepatozoon* infection.

Diagnosis

In clinical practice, diagnosis is usually based on the observation of *Hepatozoon* gamonts in the cytoplasm of neutrophils and monocytes in blood smears stained with Diff-Quik or May-Grunwald Giemsa methods. *H felis* gamonts have an ellipsoidal shape and are 10.5 x 4.7 µm in size (Figure 1). They are less prominent and so are easily missed compared with the larger *H canis* gamonts in dogs.

Several studies have shown that blood smears have low sensitivity for diagnosis of *Hepatozoon* infection compared with PCR detection of DNA. In one study in Thailand, 32% of 300 cats were PCR positive but gamonts were observed in blood smears in only 0.7% of cats.⁷ Similarly, in a study in Israel, none of the cats with meronts in the myocardium tested positive when blood smears were examined.¹⁴ Therefore, blood PCR should be considered the diagnostic test of choice for confirming *Hepatozoon* infection when blood smears do not show parasites, and is the best tool for prevalence and epidemiological studies. However, positive DNA results should be interpreted in the light of the

EBM grades

The ranking system for grading the level of evidence of a statement within the treatment section of this article is described on page 574 of this Special Issue.

clinical picture, as it is most likely that clinical signs are associated with another infectious agent. A quantitative PCR test has been developed to improve the sensitivity of detection.⁸

Meronts (round to oval parasites surrounded by a thick membrane, and measuring 39 x 34.5 µm) in skeletal muscle (Figure 2) might be detected in cats in which muscle biopsies are obtained during investigations of muscle pain or polymyositis, but this scenario has not been reported so far. Meronts in skeletal and myocardial muscle might also be detected as incidental or unexpected findings at necropsy of cats in endemic areas.

Treatment


There have been no prospective controlled studies on the treatment of feline hepatozoonosis and so all information is based on a few historical case reports. Doxycycline was used in one case with no clear results,¹² while a combination of oxytetracycline and primaquine in another case led to a successful outcome [EBM grade IV].¹¹ Treatment with drugs that are frequently used in canine hepatozoonosis has not been reported in cats.

Prevention

No clear recommendations on the prevention of infection can be made, as the routes of transmission in cats remain unknown. It is likely that, as in dogs, transmission is related to blood-sucking vectors, as well as the consumption of meat and the transplacental route. Therefore, preventive treatment against external parasites (fleas, ticks, others) is strongly advised in any cat, especially one with outdoor access.

KEY POINTS

- ❖ Hepatozoonosis in cats has been reported in many countries, mainly as a subclinical infection or an incidental finding.
- ❖ Ingestion of infected vectors (ticks, fleas) or meat, and transplacental transmission seem to be the most common routes of infection.
- ❖ *H felis* is the predominant species in cats, although *H canis* can also infect cats.
- ❖ Observation of *H felis* gamonts in a cat may be a sign of immunosuppression.
- ❖ Blood smears have low diagnostic sensitivity; blood PCR is the diagnostic method of choice.
- ❖ No evidence-based treatment protocol exists for cats.
- ❖ Preventive treatment against ticks and fleas is recommended.



Funding

The authors received no specific grant from any funding agency in the public, commercial or not-for-profit sectors for the preparation of this article. The ABCD is supported by Merial, but is a scientifically independent body and its members receive no stipends from Merial.

Conflict of interest

The authors do not have any potential conflicts of interest to declare.

References

- 1 Smith TG. The genus *Hepatozoon*. *J Parasitol* 1996; 82: 565–585.
- 2 Baneth G. Perspectives on canine and feline hepatozoonosis. *Vet Parasitol* 2011; 181: 3–11.
- 3 Patton WS. The haemogregarines of mammals and reptiles. *Parasitol* 1908; 1: 318–321.
- 4 Wenyon CM. Protozoology: a manual for medical men, veterinarians and zoologists. William Wood, New York, 1926, pp 1085–1095.
- 5 Criado-Fornelio A, Ruas JL, Casado N, et al. New molecular data on mammalian *Hepatozoon* species (Apicomplexa: Adeleorina) from Brazil and Spain. *J Parasitol* 2006; 92: 93–99.
- 6 Tabar MD, Altet L, Francino O, et al. Vector-borne infections in cats: molecular study in Barcelona area (Spain). *Vet Parasitol* 2008; 15: 332–336.
- 7 Jittapalpong S, Rungphisutthipongse O, Maruyama S, et al. Detection of *Hepatozoon canis* in stray dogs and cats in Bangkok, Thailand. *Ann NY Acad Sci* 2006; 1081: 479–488.
- 8 Criado-Fornelio A, Buling A, Cunha-Filho NA, et al. Development and evaluation of a quantitative PCR assay for detection of *Hepatozoon* spp. *Vet Parasitol* 2007; 150: 352–356.
- 9 Baneth G, Sheiner A, Eyal O, et al. Redescription of *Hepatozoon felis* (Apicomplexa: Hepatozoidae) based on phylogenetic analysis, tissue and blood from morphology, and possibly transplacental transmission. *Parasit Vectors* 2013; 6: 102.
- 10 Leeflang P and Ilemobade AA. Tick-borne disease of domestic animals in northern Nigeria. II. Research summary, 1966 to 1976. *Trop Anim Health Prod* 1977; 9: 211–218.
- 11 Van Amstel S. Hepatozoonose in 'n kat. *J S Afr Vet Med Assoc* 1979; 50: 215–216.
- 12 Ewing GO. Granulomatous cholangiohepatitis in a cat due to a protozoan parasite resembling *Hepatozoon canis*. *Feline Pract* 1977; 7: 37–40.
- 13 Perez RR, Rubini AS and O'Dwyer LH. The first report of *Hepatozoon* spp. (Apicomplexa, Hepatozoidae) in domestic cats from São Paulo state, Brazil. *Parasitol Res* 2004; 94: 83–85.
- 14 Klopfer U, Nobel TA and Neumann F. *Hepatozoon*-like parasite (schizonts) in the myocardium of the domestic cat. *Vet Pathol* 1973; 10: 185–190.
- 15 Beaufilet JP, Martin-Granel J and Jumelle P. *Hepatozoon* spp. parasitemia and feline leukemia virus infection in two cats. *Feline Pract* 1998; 26: 10–13.
- 16 Vilhena H, Martínez-Díaz VL, Cardoso L, et al. Feline vector-borne pathogens in the north and centre of Portugal. *Parasit Vectors* 2013; 6: 99.
- 17 Ortuño A, Castellà J, Criado-Fornelio A, et al. Molecular detection of a *Hepatozoon* species in stray cats from a feline colony in North-eastern Spain. *Vet J* 2008; 177: 134–135.
- 18 Maia C, Ramos C, Coimbra M, et al. Bacterial and protozoal agents of feline vector-borne diseases in domestic and stray cats from southern Portugal. *Parasit Vectors* 2014; 7: 115.
- 19 Baneth G, Aroch I, Tal N, et al. *Hepatozoon* species infection in domestic cats: a retrospective study. *Vet Parasitol* 1998; 79: 123–133.
- 20 Aktas M. A survey of ixodid tick species and molecular identification of tick-borne pathogens. *Vet Parasitol* 2014; 200: 276–283.
- 21 Maia C, Ferreira A, Nunes M, et al. Molecular detection of bacterial and parasitic pathogens in hard ticks from Portugal. *Ticks Tick Borne Dis* 2014; 5: 409–414.
- 22 Baneth G, Lavy E and Presentey BZ. *Hepatozoon* spp. parasitemia in a domestic cat. *Feline Pract* 1995; 23: 1012.