

# One-year follow-up of platelet-rich plasma infiltration to treat chronic proximal patellar tendinopathies

Kaux JF<sup>1</sup>, Bruyère O<sup>2</sup>, Croisier O<sup>3</sup>, Forthomme B<sup>3</sup>, Le Goff C<sup>4</sup>, Crielaard JM<sup>1</sup>

1. Physical Medicine and Sports Traumatology Department, University and University Hospital of Liège, Liège, Belgium.
2. Department of Public Health, Epidemiology and Health Economics, University of Liège, Liège, Belgium.
3. Physiotherapy Service, Department of Motility Sciences, University of Liège, Liège, Belgium.
4. Department of Clinical Biology, University Hospital of Liège, University of Liège, Liège, Belgium.

## Introduction

Infiltration of Platelet-Rich Plasma (PRP) may be considered as a recent therapeutic option for chronic tendinopathies. The aim of this study is to evaluate the clinical status and the return to sports activities in patients with chronic upper patellar tendinopathies.

## Material and methods

Twenty subjects with chronic upper patellar tendinopathy benefited from 1 infiltration of PRP. Platelets were collected using an apheresis machine. This machine offered a reproducible PRP from the autologous blood of each patient, with only very limited concentration of white and red blood cells. We decided to collect platelets with a concentration of around 8-9.10<sup>9</sup> platelets/ $\mu$ L. Just before infiltration, 300  $\mu$ L of CaCl<sub>2</sub> were added to the PRP to activate the platelets. Six millilitres of PRP were injected in the patellar tendon after disinfection without local anaesthetic. The follow-up (up to 1 year) was assessed by means of a Visual Analogue Scale (VAS), the International Knee Documentation Committee (IKDC) form and the Victorian Institute of Sport Assessment (VISA-P) score. Moreover, subjects had to answer an information questionnaire concerning their life and sports activities.

## Results

Seventy percents of the patients reported a favourable evolution with decrease of pain, and returned to sports activities. With time, VAS (Fig. 1) dropped significantly and both IKDC (Fig. 2) and VISA-P (Fig. 3) scores improved also significantly.

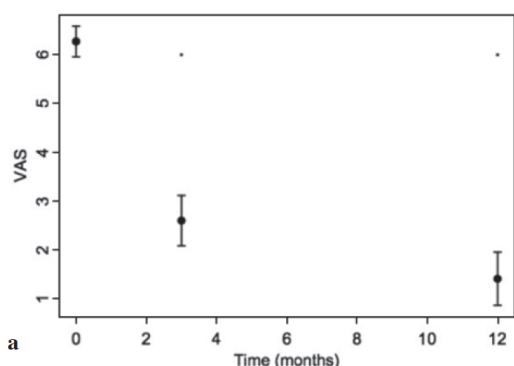


Fig. 1: Results for VAS

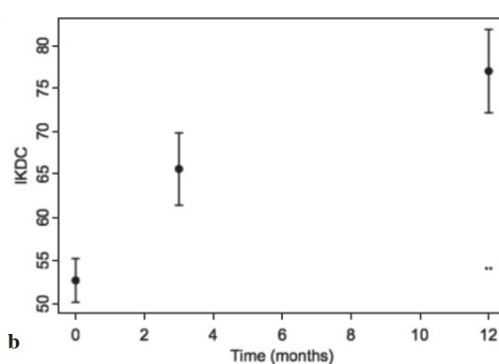


Fig. 2: Results for IKDC

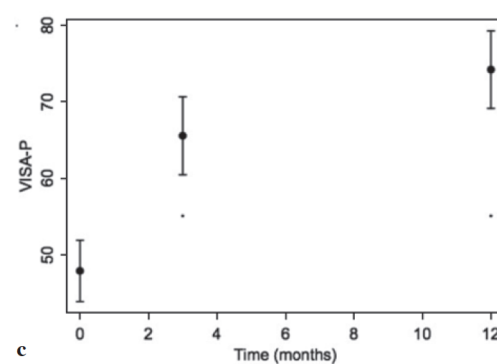


Fig. 3: Results for VISA-P

## Conclusion

This study confirms that a local injection of PRP coupled with a program of eccentric rehabilitation for treating a chronic jumper's knee, improves pain symptoms and the functionalities of the subjects' knee up to 1 year after injection.

## Reference

Kaux JF, Bruyère O, Croisier JL, Forthomme B, Le Goff C, Crielaard JM. **One-year follow-up of platelet-rich plasma infiltration to treat chronic proximal patellar tendinopathies.** *Acta Orthop. Belg.*, 2015, 81, 251-256.