



REVIEW ARTICLE

## Prognosis of HPV-positive head and neck cancers: implication of smoking and immunosuppression

Anaëlle Duray<sup>1,2</sup>, Daniel Lacreman<sup>2</sup>, Stéphanie Demoulin<sup>2</sup>,  
Philippe Delvenne<sup>2</sup> and Sven Saussez<sup>1\*</sup>

<sup>1</sup>Laboratory of Anatomy and Cell Biology, Faculty of Medicine and Pharmacy, University of Mons, Mons, Belgium; <sup>2</sup>Department of Pathology, CHU Sart-Tilman, University of Liège, Liège, Belgium

Head and neck squamous cell carcinomas (HNSCCs) remain a significant cause of morbidity and represent the sixth most common malignancy diagnosed worldwide. Tobacco use and alcohol consumption are the most important risk factors for the development of HNSCC. However, epidemiological studies reported an association with human papillomavirus (HPV) infection in a subgroup of HNSCCs. The prognosis of patients with HPV-positive HNSCC is widely discussed in the literature, with contradictory results being reported. Most authors report that the presence of HPV is a favorable prognosis factor with regard to recurrence and survival. However, other studies did not show a correlation between HPV infection and clinical outcomes or showed that HPV-positive patients had a worse prognosis. In this review, we propose various hypotheses that could explain this discrepancy including the anatomical site, patient immunosuppression caused by the virus or cigarette smoking and the interactions between tobacco and HPV. In fact, smoking and immunosuppressive status could have the potential to favor the carcinogenic effect of HPV. We also suggest that it is important to separate clearly HPV-positive HNSCC tumors related to tobacco and alcohol consumption from HPV-positive HNSCC tumors without these classical risk factors in order to evaluate the prognosis.

Keywords: *human papillomavirus; head and neck cancer; smoking; immune system*

\*Correspondence to: Sven Saussez, Laboratory of Anatomy and Cell Biology, Faculty of Medicine and Pharmacy, University of Mons, Pentagone 2A-Avenue du Champ de Mars, 6, BE-7000 Mons, Belgium, Email: sven.saussez@umons.ac.be

Received: 13 August 2014; Revised: 10 October 2014; Accepted: 14 October 2014; Published: 4 November 2014

Head and neck squamous cell carcinomas (HNSCCs) remain a significant cause of morbidity worldwide, with as many as 466,831 and 168,368 cases diagnosed in 2008 among men and women, respectively (1–3). Collectively, HNSCCs represent the sixth most common malignancy diagnosed worldwide (3). HNSCCs constitute a collection of diseases that may differ in histological features, pathogenesis, biology, sub-location, and response to treatment. These divergent features can affect quality of life parameters as well as survival (2, 3). HNSCCs involve different anatomical areas, such as the larynx, oral cavity, hypopharynx, oropharynx, sinonasal tract, and nasopharynx. In the early clinical stages of the disease (I and II), HNSCC patients have similar survival rates with a 5-year survival rate between 70 and 90% (independent of the sub-location or treatment) (4). In contrast, in the advanced clinical stages of the disease (III and IV), patients display different survival rates depending on the tumor histological type

and sub-location (4, 5). The treatment of advanced-stage disease combines surgery, radiation oncology, medical oncology, medical imaging, and clinical pathology (2–5). Unfortunately, concomitant chemoradiotherapy, which is the gold standard treatment for advanced-stage disease, is frequently associated with adverse side effects, such as dysphagia, dysphonia, and even conditions that require a tracheotomy. Therefore, even if significant progress has been obtained with combined treatments, the following statements regarding HNSCCs remain valid: 1) almost two-thirds of HNSCC patients have advanced forms (stages III and IV) of the disease at diagnosis, 2) 50% of HNSCC patients die within 2 years following the initial diagnosis, and 3) 5% of the patients develop additional primary tumors yearly. Therefore, novel approaches are needed to provide head and neck oncologists with a more effective armamentarium against this challenging disease (6).

Tobacco use and alcohol consumption are the most important risk factors for the development of HNSCC.

However, a small population of HNSCCs is not exposed to these risk factors (7). In this regard, Sturgis and Cinciripini reported that the overall incidence of HNSCC has declined in the United States over the past 20 years. The decline in HNSCC incidence was attributed to a decrease in smoking. Nevertheless, the study also described an increase in the frequency of tongue and pharyngeal cancers (8). These findings suggested that other risk factors could be related to this observation. In this context, human papillomavirus (HPV), which is the primary cause of cancer of the uterine cervix, has received considerable attention in the recent years (9).

The significance of oncogenic HPV infection and its relationship to patient prognosis remains an important matter of debate, especially considering the contradictory results presented in the literature (10–12). Generally, most authors report a favorable prognosis in patients with HPV-positive HNSCC (13–15). Other studies showed no association between HPV positivity and patient prognosis (7, 12, 16–18), whereas others suggested that the HPV-positive subgroup correlates with a greater risk of recurrence or developing a second primary tumor (11, 19–21).

To better understand these conflicting results, we reviewed various hypotheses that could explain this discrepancy, such as the anatomical site, tobacco consumption and immune status of the patient.

### Anatomical site: oropharyngeal cancer *versus* non-oropharyngeal cancer

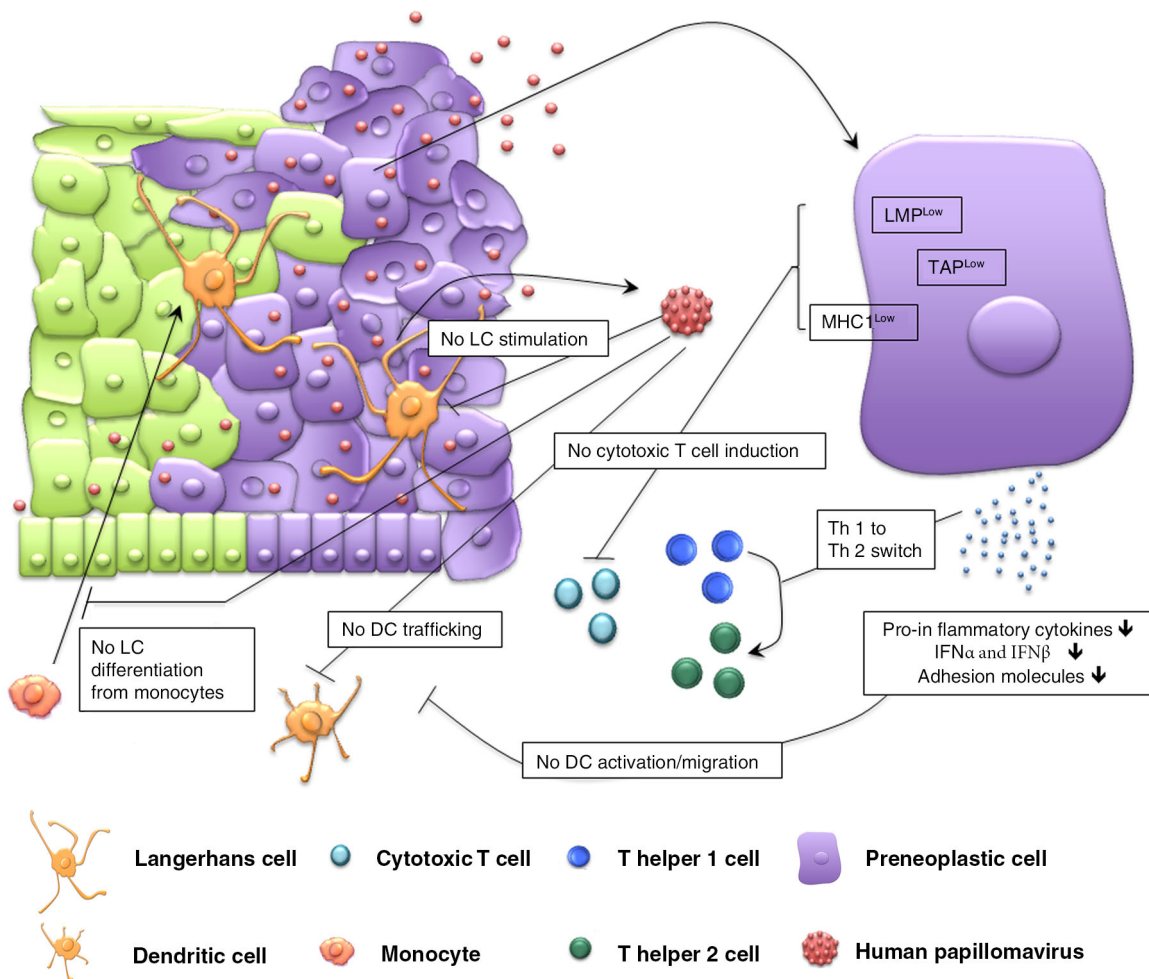
As mentioned above, many studies showed that HPV-positive HNSCC exhibits a reduced risk of tumor recurrence and better survival than HPV-negative cancers (7, 10, 13–15, 22–26). For example, a US survey, made on patients presenting HNSCC, reported that a concomitant infection by HPV improves the prognosis of patients. Indeed, they found that only 6% of HPV-positive patients died from cancer and that none of them presented a disease recurrence while 46% of HPV-negative patients died from cancer and 31% developed a recurrence (27). However, most studies demonstrating increased survival were performed on patients with cancers of the oropharynx (13, 28, 29). Several meta-analyses examining the relationship between HPV and overall survival showed no difference in survival between HPV-positive and HPV-negative patients diagnosed with head and neck cancer (non-oropharyngeal) (30, 31). In 2000, Gillison et al. made similar observations, suggesting that oropharyngeal tumors may have a different etiology than non-oropharyngeal carcinomas (7). Although the mechanism of improved survival remains unclear, there are several possible explanations. HPV-positive cancers may display enhanced radiosensitivity due to a wild-type TP53, allowing an apoptotic response of cancer cells to chemoradiotherapy. Alternatively, HPV-positive patients do not abuse tobacco and alcohol and pRB and p53 pathways

are only compromised by E6 and E7 binding (9, 26, 32). Moreover, the better overall survival of HPV-positive oropharyngeal patients may depend on their younger age at diagnosis. Indeed young people who had oral sexual practices are more susceptible to contract HPV infection in the oropharynx. Tonsils, as the uterine cervix, are composed of many crypts that may collect viral particles. In addition, squamous epithelia of the cervix and tonsils derive from the same embryonic endodermal layer. Although most HPV-related oropharyngeal cancers display a positive prognosis, it is evident that there is a subset, which behaves more aggressively and leads to poor clinical outcome (33, 34). Recently, Ang et al. demonstrated that oropharyngeal patients have a different prognosis according to the HPV status, smoking and tumor node stages. Patients with stage III and IV HPV-positive oropharyngeal SCCs were considered to be at low risk while smokers with advanced nodal stage were associated with an intermediate risk. HPV-negative oropharyngeal SCCs were reported to be at high risk and the non-smokers with T2-T3 stages were at intermediate risk (29). Other studies have failed to show an association between HPV-positive cancers and prognosis (12, 16, 18, 35). In contrast, several investigators showed that, among patients with oropharyngeal and oral cancers, the HPV-positive group has a higher risk of recurrence or developing a second primary tumor (11, 20, 21). In 1994, Clayman et al. demonstrated that HPV positivity is significantly correlated with decreased survival (19). Two Swedish studies also demonstrated that oral HPV infection is associated with a dramatically increased risk of oral SCC development (11, 20). The reasons for the poor prognosis of HPV-positive HNSCC patients have not been elucidated but one possible explanation is that immunosuppression may promote HPV infection. Indeed, several studies made a link between many viral infections and an immunosuppressive state of the patient (36–38). These co-infections may play an important role in the initiation of neoplastic transformation in human oral epithelial cells. HPV infections are also involved in several tumor cell immune escape responses. Indeed, the correlation between HPV infection and a poor prognosis could be related to the patient's immune status. We will detail these hypotheses in the following paragraphs.

### Immune system

#### *Immune escape and HPV*

HPV immune escape is crucial for the establishment of a persistent infection, a key event for HPV-induced cellular transformation. However, the correlation between HPV infection and prognosis could be influenced by the smoking status of the patient (see next chapter). Several studies identified non-smoking HPV-negative patients as well as heavy smokers with HPV-positive status. Moreover,



**Fig. 1.** Immunosuppressive mechanisms in the tumor microenvironment. HPV developed several mechanisms to escape the host immune system such as the suppression of immune responses via the modulation of pro-inflammatory cytokines, type I interferon (IFN $\alpha$ , IFN $\beta$ ) and adhesion molecules expression. There is also an inhibition of Th1 response in the presence of a switch from Th1 to Th2. The capsid of HPV particles may influence the recruitment, stimulation and trafficking of Langerhans cells (LC) and dendritic cells (DC). The preneoplastic cells infected by HPV exhibit a reduced expression of major histocompatibility complex class I (MHC I), transporters of antigenic peptides (TAP) and low-molecular proteins (LMP), thereby preventing cytotoxic T cell induction.

tobacco consumption is also known to suppress immune function, facilitating infection persistence.

To avoid detection by the host's immune defense system, HPV has developed several mechanisms. Viral gene expression and protein synthesis are confined to keratinocytes, which are programmed to die. Therefore, HPV replication does not directly cause cell death and does not give danger signal to the immune system (39, 40). Because cell lysis does not occur, pro-inflammatory cytokines, which are important for the activation and migration of dendritic cells, are not released (39, 40). HPV has no blood-borne phase. Therefore, only minimal amounts of the replicating virus are exposed to the immune system. Thus, HPV is practically invisible to the patient's immune system (40, 41). Another HPV-evolved mechanism

is that HPV oncoproteins avoid the effects of type I interferon, which are classified as anti-viral, anti-proliferative, anti-angiogenic and immune stimulatory (41) (Fig. 1). The L1 major capsid may differentially influence the trafficking of human dendritic cells or Langerhans cells according to the vaccination or natural infection context. However, Langerhans cells that come in contact with the L2 minor capsid are not phenotypically or functionally mature (42, 43). The E6 oncoprotein also blocks monocyte differentiation into a competent antigen-presenting cell (44) (Fig. 1). The inhibition of protective immune responses may also result from the decreased production of soluble or adhesion molecules that activate the migration and function of Langerhans and dendritic cells, such as E-cadherin (45). HPV also reduces the

expression of major histocompatibility complex class I (MHC I), proteasome subunits, low-molecular-mass proteins (LMP) and the transporters of antigenic peptides (TAP) (41, 46). Kanodia et al. described an additional evasion mechanisms employed by HPV to suppress immune responses, mainly the modulation of chemokines (suppression of MCP-1 expression, down regulation of IL-8 expression, alteration of CCL20 expression) and pro-inflammatory cytokines (down regulation of IL-18 expression) expression and inhibition of the Th1 response via induction of a shift from Th1 to Th2 (41, 47) (Fig. 1). Two studies proposed that the immune system failure may be explained by the fact that the E7 oncoprotein shares similarity with several human proteins, such as the xeroderma pigmentosum group G complementing protein (XPGC) and the retinoblastoma binding protein 1 (RBP-1). The consequence is that the immune system may not recognize HPV oncoproteins as foreign molecules but as self-molecules (48, 49).

#### **Possible impacts of HPV on the immune system of HNSCC patients**

In the literature, there are few data on the interactions between the host immune system and HPV infection in head and neck cancers. Therefore, the role of innate and adaptive immunity in the development and the progression of HPV-positive head and neck cancer is largely unknown.

Similarly, Albers et al. and Hoffmann et al. found that patients with HPV16+ HNSCC exhibit an increased number of T cells specific for peptides derived from the HPV E7 oncoprotein compared with HPV-negative cancers patients or healthy volunteers (50, 51). These studies suggest that antiviral immunity can be maintained against E7. However, T cells are unable to eradicate tumors (51), perhaps due to tumor cell escape mediated by the absence of recognition by cytotoxic T lymphocyte (CTL) (50). Indeed, decreased expression of the components of the antigen presentation machinery (APM) and HLA class I antigens was observed in HPV-16+ carcinomas compared with adjacent normal squamous epithelium (50). Recently, another study indicated that the specific T cell immune response against HPV-16 included CD4+ T cells and CD8+ T cells (52). Further studies are therefore required to explain this tumor resistance.

Wansom et al. studied HNSCC patient peripheral blood to determine the clinical importance of adaptive immunity and whether it affects patient outcome. An increased percentage of CD8 cells and a reduced CD4:CD8 ratio were observed in HPV16+ oropharyngeal SCC patients. The percentage of CD8 cells was similar in smokers vs. non-smokers, suggesting that the difference in CD8+ cells is linked to HPV and not to tobacco use. These results were also associated with a complete tumor response after chemoradiotherapy and an improved overall survival.

Therefore, it was concluded that circulating CD8 cells could serve as a prognostic factor and that improved adaptive immunity may positively influence HPV16+ patient prognosis (53).

Some researchers also studied HNSCC immune cells *in situ*. One study examined the number of Langerhans cells in oral cavity carcinomas. HPV-positive tumors displayed decreased numbers of Langerhans cells compared with HPV-negative tumors. However, this difference was not statistically significant (54). Several studies showed an increase in the number of CTL as well as the CTL/Treg (regulatory T cells) ratio in HPV-positive patients compared with HPV-negative patients. In addition, these results were correlated with a better prognosis (55, 56). As mentioned previously, Wansom et al. demonstrated that increased levels of CD8 in the peripheral blood of HPV-positive patients correlated with a better prognosis. However, when using immunohistochemistry to study various markers (CD4, CD8, CD68 and FoxP3) in tissue samples of oropharynx carcinoma, no difference in the expression of these markers was identified in relation to HPV status. These results suggest that peripheral blood markers of adaptive immunity are not ideal substitutes for immune parameters of the tumor microenvironment (57).

Williams et al. generated HPV-positive and HPV-negative tonsil cell lines able to form squamous cell cancers in mice to investigate whether HPV-specific immune mechanisms cause tumor clearance. The authors observed a difference in growth and survival patterns in immunocompetent and immunodeficient mice injected with HPV-positive or HPV-negative cells. In fact, approximately one-third of the immunocompetent mice injected with HPV+ cells displayed tumor clearance compared with no mice injected with HPV-negative cells. Among the mice lacking tumor clearance, HPV-positive mice had enhanced survival compared with HPV-negative mice. In the mice lacking B and T cell mediated immunity, no differences in the tumor growth pattern or survival were observed between HPV-positive *versus* HPV-negative mice. Moreover, the immune clearance capacity of a cleared mouse could be transferred to an immunodeficient mouse by splenocyte injection. These data indicated that the clearance of HPV-positive tumors requires an intact immune system and oncogenic viral proteins (58).

In this section, we reported several studies which examined HPV and immune status in animal experiments, *in situ* and in the peripheral blood of patients with HNSCC and showed that the data about the interactions between the patient's immune system and HPV infections do not allow to address the exact role of the immune response in the development and progression of HPV-related cancers in the head and neck areas. Some authors support the hypothesis that the HPV-specific immune response may contribute to a better prognosis in HPV-positive HNSCC but, in this case, a non-altered immune

system is essential. In addition, these studies were limited to oropharyngeal cancers, which typically have a better prognosis compared with other sites of HNSCC. Furthermore, some authors performed peripheral blood experiments which do not allow to certify that the observed alterations are directly related to HPV-positive carcinoma and not to other infections which are frequent in cancer patients.

### Smoking and HPV-positive HNSCC patients

HPV-positive HNSCC tumors related to tobacco and alcohol consumption form a distinct biological and clinical entity from HPV-positive HNSCC tumors without these classical risk factors, which are associated with a better prognosis. In this regard, smoking habits in Europe trends show some significant differences among populations (59). Indeed, a significant decrease in smoking was observed in the populations of Norway, Finland and the Netherlands. Northern European countries are less exposed to traditional risk factors compared with Southern European countries (59).

Numerous studies correlated the improved treatment response and survival of HPV-positive HNSCC with several sociodemographic, clinical and pathological factors, such as young age, male gender, Caucasian ethnic origin, little or no smoking/drinking, increased exposure to oral sex, oropharyngeal location, lymph node metastasis, decreased pRb expression, increased p16 expression, poorly differentiated tumor and the presence of non-keratinized cells. In fact, various studies also showed that the subgroup of patients with better survival consists of HPV+ and p16+ carcinomas (24, 60–62). In addition, HPV-positive carcinomas without p53 mutations have a better prognosis (63). In this context, Byrd et al. performed a retrospective review on patients with HNSCC between 2006 and 2010 to identify a combination of sociodemographic factors of HPV-negative patients that are associated with clinical and pathological features that would allow clinicians to precisely predict the HPV status of patients. Four ear, nose and throat surgery residents were asked to predict a patient's HPV status based on clinical and histopathological data. The data from 174 patients were included in the study and 95 of these patients were HPV positive. Residents were able to correctly predict HPV status in 110 of 125 patients (63–72%), with positive predictive values of 76–84% and negative values of 61–69%. The male gender and oropharyngeal location were significantly associated with the HPV status of the patient. In their study, only four patients had a 'typical' HPV-positive profile. Therefore, these characteristics do not precisely predict HPV status in patients with HNSCC (64). This study confirms the results of D'Souza's previous work based exclusively on sociodemographic factors (65). The absence of smoking in the HPV-positive group that was observed in several studies is also a challenge.

HPV-associated HNSCC is considered a disease limited to non-drinkers/non-smokers. Nevertheless, the study identified non-smoking HPV-negative patients as well as heavy smoking HPV-positive patients (65). Indeed, Byrd et al. also showed that 28% of HPV-positive patients were smokers and 34% were former smokers (64). This finding is also supported by a study from Maxwell et al. that examines the effect of tobacco use on disease recurrence among patients with HPV-positive oropharyngeal cancer. In this study, only 32% of HPV-positive patients never smoked and the majority of HPV-positive patients were tobacco users. In addition, the HPV-positive smoker group had an increased risk of recurrence and distant metastases as well as reduced survival compared with the HPV-positive non-smoker group. In fact, the rate of disease recurrence among HPV-positive patients was lowest among non-smokers (6.1%) followed by former users (19.6%) and highest in current smokers (34.8%) (66). The possible negative impact of smoking on the prognosis of HPV-positive patients is important especially in countries where the vast majority of patients are avid tobacco consumers. Four additional studies also found that HPV-positive smokers have reduced survival compared with HPV-positive non-smokers given the increased risk for both local recurrence and distant metastases in HPV-positive smokers (25, 67–69). Recently, the analysis of Gillison et al. demonstrated that p16+ patients are more likely to be non-smokers and have significantly reduced tobacco exposure. These p16+ patients displayed statistically more favorable survival compared with p16– patients ( $p < 0.001$ ). Indeed, the 5-year survival was 49% and 19.6% for p16+ and p16– patients, respectively. Moreover, the risk of cancer progression or death increased as a direct function of the pack-years or total smoking years, even after considering HPV status (70).

However, it is unclear whether an association between tobacco/alcohol consumption and HPV exists. In fact, several studies demonstrated a synergistic or additive association (71–74), whereas other authors observed no difference in risk of tumor development by tobacco/alcohol habits and HPV status (7, 75–79). Based on these inconsistent results, the potential role of alcohol and/or tobacco use in HPV-associated HNSCC is not well delineated. A multicenter study reported that HPV-negative smokers (OR = 11.2, 95% CI = 5.9–21.4), HPV16-positive non-smokers (OR = 64.5, 95% CI = 18.3–226.7) and HPV16-positive smokers (OR = 56.2, 95% CI = 22.5–140.4) have an increased risk for oropharyngeal cancer when compared with HPV16– non-smokers. The findings from this study show the typical pattern of additivity between smoking and HPV infection (72). A study conducted by Schwartz et al. (71) demonstrated a synergistic interaction between smoking and alcohol and HPV VLP serology (71). An additional group showed an additive effect

between classical risk factors and HPV. In fact, HPV-positive smokers had a greater risk of HNSCC (OR = 5.5, 95% CI = 2.1–14.1) than patients who were only smokers (OR = 1.6, 95% CI = 0.9–2.8) or only HPV positive (OR = 1.4, 95% CI = 0.5–3.6) (73). In 2010, the same group demonstrated that heavy smoking patients with HPV VLP seropositivity had an OR of 2.3, whereas heavy smoking patients with HPV seronegativity displayed an OR of 2.6. These authors suggested that smoking increased the risk of HNSCC in both HPV-negative and HPV-positive patients and that HPV infection may be not sufficient to cause HNSCC as the accumulation of additional cellular changes is required (74).

As stated above, the persistence of HPV infection is a critical step in the development of HPV-related cancers. HPV has developed several mechanisms to escape patient immune surveillance to sustain infection. However, tobacco use is also known to suppress immune function, thereby facilitating infection persistence. Given its immunosuppressive functions, smoking may prevent the body from mounting immunologic responses to eradicate the virus-related cancer cells (80). The inhibitory effects of tobacco have been shown to be induced by nicotine, hydroquinone and carbon monoxide (80). A smoker's increased susceptibility to respiratory tract infections is linked to the fact that cigarette smoke alters the response of T cells and reduces the phagocytic and killing functions of macrophages and also the survival of these cells (81). Some studies also reported reduced cytolytic activity of natural killer cells in smokers (82). Smoking suppresses certain Th1 responses and facilitates Th2 inflammation. For example, the mononuclear cells of smokers release TNF- $\alpha$ , IL-1, IL-8, and GM-CSF as well as decreased IL-10 and IFN- $\gamma$  levels. The secretion of the inflammatory mediators promotes chronic immune cell recruitment and inflammation (80, 83). Moreover, tobacco induces DNA breaks in human cells and is involved in the process of HPV integration, which occurs at fragile sites or 'hot spots' of DNA breakage, thereby increasing the carcinogenic potential of HPV (17). These observations suggest that the poor prognosis reported in some studies is likely to be linked to the fact that smoking and immunosuppressive status has the potential to favor infection, persistence and the carcinogenic effect of HPV.

## Conclusion

In this review, we reported different hypotheses for the discordant prognosis data in HPV-positive and HPV-negative HNSCCs. We also discussed the issues of anatomical site, immune system and tobacco consumption in relation with HPV infection. The different survival rates observed in oropharyngeal cancers patients suggest that it would be useful to treat these patients separately from patients with HNSCC (non-oropharynx). Future researches should examine HPV in the presence or absence

of tobacco/alcohol to evaluate differences in molecular pathways and the exact impact on the prognosis. Characteristics such as immunoprofiling and smoking habits should be considered for the assessment of HPV-positive patients' prognosis as they were shown to be valuable prognostic tools. A better understanding of the factors that cause an immune suppression in HPV-positive HNSCCs might be relevant for the development of new therapeutic or prophylactic anticancer approaches.

## Authors' contributions

AD is a scientific collaborator of the FNRS-Télévie. SD is a Ph.D. student supported by a grant from the FNRS (Bourse Télévie). PhD is a Senior Research Associate with the FNRS. AD and DL participate equally to this work.

## Financial disclosure

None.

## Conflict of interest and funding

The authors have not received any funding or benefits from industry or elsewhere to conduct this study.

## References

1. Globocan 2008. International Agency for Research on Cancer [cited 2011 May 16]; Available from: <http://globocan.iarc.fr/>
2. Grandis JR, Pietenpol JA, Greenberger JS, Pelroy RA, Mohla S. Head and neck cancer: Meeting summary and research opportunities. *Cancer Res.* 2004;64:8126–9.
3. Shah JP, Patel SG. *Head and neck surgery and oncology.* New York, NY: Mosby, 2003.
4. Forastiere AA, Trotti A. Radiotherapy and concurrent chemotherapy: A strategy that improves locoregional control and survival in oropharyngeal cancer. *J Natl Cancer Inst.* 1999; 91:2065–6.
5. Denis F, Garaud P, Bardet E, Alfonsi M, Sire C, Germain T, et al. Final results of the 94–01 French head and neck oncology and radiotherapy group randomized trial comparing radiotherapy alone with concomitant radiochemotherapy in advanced-stage oropharynx carcinoma. *J Clin Oncol.* 2004;22: 69–76.
6. Duray A, Demoulin S, Hubert P, Delvenne P, Saussez S. Immune suppression in head and neck cancers: A review. *Clin Dev Immunol.* 2010;2010:1–15.
7. Gillison ML, Koch WM, Capone RB, Spafford M, Westra WH, Wu L, et al. Evidence for a causal association between human papillomavirus and a subset of head and neck cancers. *J Natl Cancer Inst.* 2000;92:709–20.
8. Sturgis EM, Cinciripini PM. Trends in head and neck cancer incidence in relation to smoking prevalence: An emerging epidemic of human papillomavirus-associated cancers? *Cancer.* 2007;110:1429–35.
9. Syrjänen S. The role of human papillomavirus infection in head and neck cancers. *Ann Oncol.* 2010;21:243–5.
10. Dahlstrand H, Näsman A, Romanitan M, Lindquist D, Ramqvist T, Dalianis T. Human papillomavirus accounts both for increased incidence and better prognosis in tonsillar cancer. *Anticancer Res.* 2008;28:1133–8.
11. Rosenquist K, Wennerberg J, Annertz K, Schildt EB, Hansson BG, Bladström A, et al. Recurrence in patients with oral and oropharyngeal squamous cell carcinoma: Human

- papillomavirus and other risk factors. *Acta Otolaryngol.* 2007; 127:980–7.
12. Duray A, Descamps G, Arafa M, Decaestecker C, Rimmelink M, Sirtaine N, et al. High incidence of high-risk HPV in benign and malignant lesions of the larynx. *Int J Oncol.* 2011;39:51–9.
  13. Lindel K, Beer KT, Laissue J, Greiner RH, Aebersold DM. Human papillomavirus positive squamous cell carcinoma of the oropharynx: A radiosensitive subgroup of head and neck carcinoma. *Cancer.* 2001;92:805–13.
  14. Lindquist D, Romanitan M, Hammarstedt L, Näsman A, Dahlstrand H, Lindholm J, et al. Human papillomavirus is a favourable prognostic factor in tonsillar cancer and its oncogenic role is supported by the expression of E6 and E7. *Mol Oncol.* 2007;1:350–5.
  15. Fakhry C, Westra WH, Li S, Cmelak A, Ridge JA, Pinto H, et al. Improved survival of patients with human papillomavirus-positive head and neck squamous cell carcinoma in a prospective clinical trial. *J Natl Cancer Inst.* 2008;100:261–9.
  16. Koskinen WJ, Chen RW, Leivo I, Mäkitie A, Bäck L, Kontio R, et al. Prevalence and physical status of human papillomavirus in squamous cell carcinomas of the head and neck. *Int J Cancer.* 2003;107:401–6.
  17. Ragin CC, Modugno F, Gollin SM. The epidemiology and risk factors of head and neck cancer: A focus on human papillomavirus. *J Dent Res.* 2007;86:104–14.
  18. Morshed K. Association between human papillomavirus infection and laryngeal squamous cell carcinoma. *J Med Virol.* 2010;82:1017–23.
  19. Clayman GL, Stewart MG, Weber RS, el-Naggar AK, Grimm EA. Human papillomavirus in laryngeal and hypopharyngeal carcinomas. Relationship to survival. *Arch Otolaryngol Head Neck Surg.* 1994;120:743–8.
  20. Hansson BG, Rosenquist K, Antonsson A, Wennerberg J, Schildt EB, Bladström A, et al. Strong association between infection with human papillomavirus and oral and oropharyngeal squamous cell carcinoma: A population-based case-control study in southern Sweden. *Acta Otolaryngol.* 2005; 125:1137–44.
  21. Duray A, Descamps G, Decaestecker C, Rimmelink M, Sirtaine N, Lechien J, et al. Human papillomavirus DNA strongly correlates with a poorer prognosis in oral cavity carcinoma. *Laryngoscope.* 2012;122:1558–65.
  22. Schwartz SR, Yueh B, McDougall JK, Daling JR, Schwartz SM. Human papillomavirus infection and survival in oral squamous cell cancer: A population based study. *Otolaryngol Head Neck Surg.* 2001;125:1–9.
  23. Ritchie JM, Smith EM, Summersgill KF, Hoffman HT, Wang D, Klussmann JP, et al. Human papillomavirus infection as a prognostic factor in carcinomas of the oral cavity and oropharynx. *Int J Cancer.* 2003;104:336–44.
  24. Reimers N, Kasper HU, Weissenborn SJ, Stützer H, Preuss SF, Hoffmann TK, et al. Combined analysis of HPV-DNA, p16 and EGFR expression to predict prognosis in oropharyngeal cancer. *Int J Cancer.* 2007;120:1731–8.
  25. Kumar B, Cordell KG, Lee JS, Worden FP, Prince ME, Tran HH, et al. EGFR, p16, HPV Titer, Bcl-xL and p53, sex, and smoking as indicators of response to therapy and survival in oropharyngeal cancer. *J Clin Oncol.* 2008;26:3128–37.
  26. Hennessey PT, Westra WH, Califano JA. Human papillomavirus and head and neck squamous cell carcinoma: Recent evidence and clinical implications. *J Dent Res.* 2009;88:300–6.
  27. Ringström E, Peters E, Hasegawa M, Posner M, Liu M, Kelsey KT. Human papillomavirus type 16 and squamous cell carcinoma of the head and neck. *Clin Cancer Res.* 2002;8: 3187–92.
  28. Sedaghat AR, Zhang Z, Begum S, Palermo R, Best S, Ulmer KM, et al. Prognostic significance of human papillomavirus in oropharyngeal squamous cell carcinomas. *Laryngoscope.* 2009;119:1542–9.
  29. Ang KK, Harris J, Wheeler R, Weber R, Rosenthal DI, Nguyen-Tân PF, et al. Human papillomavirus and survival of patients with oropharyngeal cancer. *N Engl J Med.* 2010;363: 24–35.
  30. Ragin CC, Taioli E. Survival of squamous cell carcinoma of the head and neck in relation to human papillomavirus infection: Review and meta-analysis. *Int J Cancer.* 2007;121: 1813–20.
  31. Isayeva T, Li Y, Maswahu D, Brandwein-Gensler M. Human papillomavirus in non-oropharyngeal head and neck cancers: A systematic literature review. *Head Neck Pathol.* 2012;6: 104–20.
  32. Bose P, Brockton NT, Dort JC. Head and neck cancer: From anatomy to biology. *Int J Cancer.* 2013;133:2013–23.
  33. Bishop JA, Westra WH. Human papillomavirus-related small cell carcinoma of the oropharynx. *Am J Surg Pathol.* 2011;35: 1679–84.
  34. Kraft S, Faquin WC, Krane JF. HPV-associated neuroendocrine carcinoma of the oropharynx: A rare new entity with potentially aggressive clinical behavior. *Am J Surg Pathol.* 2012;36:321–30.
  35. Ernoux-Neufcoeur P, Arafa M, Decaestecker C, Duray A, Rimmelink M, Leroy X, et al. Combined analysis of HPV DNA, p16, p21 and p53 to predict prognosis in patients with stage IV hypopharyngeal carcinoma. *J Cancer Res Clin Oncol.* 2011;137:173–81.
  36. Kreimer AR, Alberg AJ, Daniel R, Gravitt PE, Viscidi R, Garrett ES, et al. Oral human papillomavirus infection in adults is associated with sexual behavior and HIV serostatus. *J Infect Dis.* 2004;189:686–98.
  37. Moscicki AB, Hills N, Shiboski S, Powell K, Jay N, Hanson E, et al. Risks for incident human papillomavirus infection and low-grade squamous intraepithelial lesion development in young females. *JAMA.* 2001;285:2995–3002.
  38. Tung YC, Lin KH, Chu PY, Hsu CC, Kuo WR. Detection of human papilloma virus and Epstein-Barr virus DNA in nasopharyngeal carcinoma by polymerase chain reaction. *Kaohsiung J Med Sci.* 1999;15:256–62.
  39. Stanley MA. Immune responses to human papillomavirus. *Vaccine.* 2006;24:16–22.
  40. Stanley MA. Immune responses to human papillomaviruses. *Indian J Med Res.* 2009;130:266–76.
  41. Kanodia S, Fahey LM, Kast WM. Mechanisms used by human papillomaviruses to escape the host immune response. *Curr Cancer Drug Targets.* 2007;7:79–89.
  42. Herman L, Hubert P, Herfs M, Kustermans G, Henrotin Y, Bousarghin L, et al. The L1 major capsid protein of HPV16 differentially modulates APC trafficking according to the vaccination or natural infection context. *Eur J Immunol.* 2010; 40:3075–84.
  43. Fahey LM, Raff AB, Da Silva DM, Kast WM. A major role for the minor capsid protein of human papillomavirus type 16 in immune escape. *J Immunol.* 2009;183:6151–6.
  44. Iijima N, Goodwin EC, Dimaio D, Iwasaki A. High-risk human papillomavirus E6 inhibits monocyte differentiation to Langerhans cells. *Virology.* 2013;444:257–62.
  45. Hubert P, Caberg JH, Gilles C, Bousarghin L, Franzen-Detrooz E, Boniver J, et al. E-cadherin-dependent adhesion of dendritic and Langerhans cells to keratinocytes is defective in cervical human papillomavirus-associated (pre)neoplastic lesions. *J Pathol.* 2005;206:346–55.

46. Venuti A, Paolini F, Nasir L, Corteggio A, Roperto S, Campo MS, et al. Papillomavirus E5: The smallest oncoprotein with many functions. *Mol Cancer*. 2011;10:1–18.
47. Caberg JH, Hubert P, Herman L, Herfs M, Roncarati P, Boniver J, et al. Increased migration of Langerhans cells in response to HPV16 E6 and E7 oncogene silencing: Role of CCL20. *Cancer Immunol Immunother*. 2009;58:39–47.
48. O'Donovan A, Wood RD. Identical defects in DNA repair in xeroderma pigmentosum group G and rodent ERCC group 5. *Nature*. 1993;363:185–8.
49. Scherly D, Nospikel T, Corlet J, Ucla C, Bairoch A, Clarkson SG. Complementation of the DNA repair defect in xeroderma pigmentosum group G cells by a human cDNA related to yeast RAD2. *Nature*. 1993;363:182–5.
50. Albers A, Abe K, Hunt J, Wang J, Lopez-Albaitero A, Schaefer C, et al. Antitumor activity of human papillomavirus type 16 E7-specific T cells against virally infected squamous cell carcinoma of the head and neck. *Cancer Res*. 2005;65:11146–55.
51. Hoffmann TK, Arsov C, Schirlau K, Bas M, Friebe-Hoffmann U, Klussmann JP, et al. T cells specific for HPV16 E7 epitopes in patients with squamous cell carcinoma of the oropharynx. *Int J Cancer*. 2006;118:1984–91.
52. Heusinkveld M, Goedemans R, Briet RJ, Gelderblom H, Nortier JW, Gorter A, et al. Systemic and local human papillomavirus 16-specific T-cell immunity in patients with head and neck cancer. *Int J Cancer*. 2012;131:74–85.
53. Wansom D, Light E, Worden F, Prince M, Urba S, Chepeha DB, et al. Correlation of cellular immunity with human papillomavirus 16 status and outcome in patients with advanced oropharyngeal cancer. *Arch Otolaryngol Head Neck Surg*. 2010;136:1267–73.
54. Pereira KM, Soares RC, Oliveira MC, Pinto LP, Costa Ade L. Immunohistochemical staining of Langerhans cells in HPV-positive and HPV-negative cases of oral squamous cells carcinoma. *J Appl Oral Sci*. 2011;19:378–83.
55. Näsman A, Romanitan M, Nordfors C, Grün N, Johansson H, Hammarstedt L, et al. Tumor infiltrating CD8+ and Foxp3+ lymphocytes correlate to clinical outcome and human papillomavirus (HPV) status in tonsillar cancer. *PLoS One*. 2012;7:1–8.
56. Jung AC, Guihard S, Krugell S, Ledrappier S, Brochot A, Dalstein V, et al. CD8-alpha T-cell infiltration in human papillomavirus-related oropharyngeal carcinoma correlates with improved patient prognosis. *Int J Cancer*. 2013;132:26–36.
57. Wansom D, Light E, Thomas D, Worden F, Prince M, Urba S, et al. Infiltrating lymphocytes and human papillomavirus-16-associated oropharyngeal cancer. *Laryngoscope*. 2012;122:121–7.
58. Williams R, Lee DW, Elzey BD, Anderson ME, Hostager BS, Lee JH. Preclinical models of HPV+ and HPV – HNSCC in mice: An immune clearance of HPV+ HNSCC. *Head Neck*. 2009;31:911–8.
59. Giskes K, Kunst AE, Benach J, Borrell C, Costa G, Dahl E, et al. Trends in smoking behaviour between 1985 and 2000 in nine European countries by education. *J Epidemiol Community Health*. 2005;59:395–401.
60. Smith EM, Wang D, Kim Y, Rubenstein LM, Lee JH, Haugen TH, et al. P16INK4a expression, human papillomavirus, and survival in head and neck cancer. *Oral Oncol*. 2008;44:133–42.
61. Weinberger PM, Yu Z, Haffty BG, Kowalski D, Harigopal M, Brandsma J, et al. Molecular classification identifies a subset of human papillomavirus associated oropharyngeal cancers with favorable prognosis. *J Clin Oncol*. 2006;24:736–47.
62. Weinberger PM, Yu Z, Kountourakis P, Sasaki C, Haffty BG, Kowalski D, et al. Defining molecular phenotypes of human papillomavirus associated oropharyngeal squamous cell carcinoma: validation of three-class hypothesis. *Otolaryngol Head Neck Surg*. 2009;141:382–9.
63. Smith EM, Wang D, Rubenstein LM, Morris WA, Turek LP, Haugen TH. Association between p53 and human papillomavirus in head and neck cancer survival. *Cancer Epidemiol Biomarkers Prev*. 2008;17:421–7.
64. Byrd JK, Wilhoit CS, Fordham MT, Reeves TD, McRackan TR, Nguyen SA, et al. Predicting HPV status in head and neck cancer: the predictive value of sociodemographic and disease characteristics. *Arch Otolaryngol Head Neck Surg*. 2012;138:1155–9.
65. D'Souza G, Zhang HH, D'Souza WD, Meyer RR, Gillison ML. Moderate predictive value of demographic and behavioral characteristics for a diagnosis of HPV16-positive and HPV-16negative head and neck cancer. *Oral Oncol*. 2010;46:100–4.
66. Maxwell JH, Kumar B, Feng FY, Worden FP, Lee JS, Eisbruch A, et al. Tobacco use in human papillomavirus-positive advanced oropharynx cancer patients related to increased risk of distant metastases and tumor recurrence. *Clin Cancer Res*. 2010;16:1226–35.
67. Hafkamp HC, Manni JJ, Haesevoets A, Voogd AC, Schepers M, Bot FJ, et al. Marked differences in survival rate between smokers and nonsmokers with HPV 16-associated tonsillar carcinomas. *Int J Cancer*. 2008;122:2656–64.
68. Tribius S, Hoffmann AS, Bastrop S, Görögh T, Haag J, Röcken C, et al. HPV status in patients with head and neck of carcinoma of unknown primary site: HPV, tobacco smoking, and outcome. *Oral Oncol*. 2012;48:1178–84.
69. Lin BM, Wang H, D'Souza G, Zhang Z, Fakhry C, Joseph AW, et al. Long-term prognosis and risk factors among patients with HPV-associated oropharyngeal squamous cell carcinoma. *Cancer*. 2013;119:3462–71.
70. Gillison ML, Zhang Q, Jordan R, Xiao W, Westra WH, Trotti A, et al. Tobacco smoking and increased risk of death and progression for patients with p16-positive and p16-negative oropharyngeal cancer. *J Clin Oncol*. 2012;30:2102–11.
71. Schwartz SM, Daling JR, Doody DR, Wipf GC, Carter JJ, Madeleine MM, et al. Oral cancer risk in relation to sexual history and evidence of human papillomavirus infection. *J Natl Cancer Inst*. 1998;90:1626–36.
72. Herrero R, Castellsagué X, Pawlita M, Lissowska J, Kee F, Balaram P, et al. Human papillomavirus and oral cancer: The International Agency for Research on Cancer multicenter study. *J Natl Cancer Inst*. 2003;95:1772–83.
73. Smith EM, Ritchie JM, Summersgill KF, Klussmann JP, Lee JH, Wang D, et al. Age, sexual behavior and human papillomavirus infection in oral cavity and oropharyngeal cancers. *Int J Cancer*. 2004;108:766–72.
74. Smith EM, Rubenstein LM, Haugen TH, Hamsikova E, Turek LP. Tobacco and alcohol use increases the risk of both HPV-associated and HPV-independent head and neck cancers. *Cancer Causes Control*. 2010;21:1369–78.
75. Snijders PJ, Scholes AG, Hart CA, Jones AS, Vaughan ED, Woolgar JA, et al. Prevalence of mucosotropic human papillomaviruses in squamous-cell carcinoma of the head and neck. *Int J Cancer*. 1996;66:464–9.
76. Paz IB, Cook N, Odom-Maryon T, Xie Y, Wilczynski SP. Human papillomavirus (HPV) in head and neck cancer. An association of HPV 16 with squamous cell carcinoma of Waldeyer's tonsillar ring. *Cancer*. 1997;79:595–604.
77. D'Souza G, Kreimer AR, Viscidi R, Pawlita M, Fakhry C, Koch WM, et al. Case-control study of human papillomavirus and oropharyngeal cancer. *N Engl J Med*. 2007;356:1944–56.
78. Gillison ML, D'Souza G, Westra W, Sugar E, Xiao W, Begum S, et al. Distinct risk factor profiles for human papillomavirus



- type 16-positive and human papillomavirus type 16-negative head and neck cancers. *J Natl Cancer Inst.* 2008;100:407–20.
79. Hong AM, Martin A, Chatfield M, Jones D, Zhang M, Armstrong B, et al. Human papillomavirus, smoking status and outcomes in tonsillar squamous cell carcinoma. *Int J Cancer.* 2013;132:2748–54.
80. Arnson Y, Shoenfeld Y, Amital H. Effects of tobacco smoke on immunity, inflammation and autoimmunity. *J Autoimmun.* 2010;34:258–65.
81. Mehta H, Nazzari K, Sadikot RT. Cigarette smoking and innate immunity. *Inflamm Res.* 2008;57:497–503.
82. Palmer RM, Wilson RF, Hasan AS, Scott DA. Mechanisms of action of environmental factors – tobacco smoking. *J Clin Periodontol.* 2005;32:180–95.
83. Lee J, Taneja V, Vassallo R. Cigarette smoking and inflammation: Cellular and molecular mechanisms. *JDR.* 2012;91:142–9.