

CASE REPORT

Expulsion of a uterine myoma in a patient treated with ulipristal acetate

Frederic Chantraine¹, Gaele Poismans¹, Julia Nwachuku², Elke Bestel² & Michelle Nisolle¹

¹Department of Obstetrics and Gynecology, CHR Citadelle, University of Liège, Liege, Belgium

²PregLem S.A., Geneva, Switzerland

Correspondence

Frederic Chantraine, Department of Obstetrics and Gynecology, University of Liege, CHR Citadelle, Blv 12ème de Ligne 1, 4000 Liege, Belgium. Tel: +32 4 223 89 02; Fax: +32 4 224 00 05; E-mail: fchantraine@chu.ulg.ac.be

Funding Information

No funding information provided.

Received: 16 September 2014; Revised: 28 October 2014; Accepted: 4 December 2014

doi: 10.1002/ccr3.211

Introduction

Ulipristal acetate is a selective progesterone receptor modulator (SPRM). It has clinical applications in emergency contraception and presurgical treatment of uterine myomas [1].

Uterine myomas are the most common pelvic tumors in women [2] and are frequently responsible for premenopausal menorrhagia and pelvic pain. The most common treatment options include surgical interventions such as hysterectomy or myomectomy. A study on hysterectomy patients found myomas in 77% of hysterectomy specimens [3]. Several drugs have been shown to be beneficial in preparation for myomectomy or vaginal hysterectomy. The effects sought are a reduction in the size of myomas and an improvement in the patient's general health by stopping the menorrhagia.

Clinical studies are currently underway which aim to examine the benefits of ulipristal acetate (UPA) treatment on myomas, assessing improvement of symptoms, bleeding profile, and quality of life. It is in the context of the PEARL III study (PGL4001's Efficacy Assessment in Reduction of Symptoms due to uterine Leiomyomata III) [4] that we report a case of spontaneous expulsion of a uterine myoma in a patient treated with UPA.

Key Clinical Message

Description of a spontaneous expulsion of a submucosal myoma in a patient treated with ulipristal acetate.

Keywords

Expulsion, myoma, selective progesterone receptor modulator, ulipristal acetate.

Case History

This report concerns a gravida 2 para 2 patient aged 45 with no relevant medical–surgical history who had been suffering from menorrhagia for 6 months. She had been using estrogen–progestin contraception (ethinyl-estradiol 0.02 mg, desogestrel 0.15 mg; Deso20[®]) for 6 months. Menorrhagia treatment with tranexamic acid (Exacyl[®]) had proven ineffective. A transvaginal ultrasound exam diagnosed a polyfibromatous uterus (>four myomas with diameters of between 43 and 15 mm).

Participation in the PEARL III study (a phase III, randomized, double-blind clinical study) was suggested. This study involves the administration of UPA at a dose of 10 mg per day for 3 months. The patient is then allocated, by randomization, either a progestin (norethisterone acetate [NETA] 10 mg) or a placebo for a period of 10 days. This cycle is administered once in total and then followed by an optional extension study, which repeats the UPA/NETA or UPA/placebo course three more times. Each treatment cycle is separated by an “off-drug interval” allowing for return of menstruation and a full menstrual cycle. The aim of this study was to demonstrate the efficacy and safety of using UPA as a long-term intermittent treatment of uterine myomas.

Outcome and Follow-up

After study enrolment, the patient was given the study medication between September 2010 and September 2011. Amenorrhea was achieved after 3 days and persisted while UPA was being taken, apart from intervals when the medication was suspended. No adverse effects were noted and clinical monitoring, as well as routine laboratory tests, was normal. The sizes of the three largest myomas and the thickness of the endometrium were measured regularly via ultrasound (Fig. 1). A continuous decrease in size of the myomas was observed over the study period. The expelled myoma was not one of those followed by ultrasound measurements; however, we can assume a similar size reduction.

Endometrial biopsies, repeated several times within the context of the study, showed no abnormalities when examined histologically.

At the follow-up visit of September 2011, the endovaginal ultrasound indicated that a myoma was in the process of being expelled at the cervix uteri (Fig. 2). A gynecological exam confirmed the presence of the myoma in the endocervix. The diagnosis of spontaneous expulsion of submucosal myoma was postulated. Pedicle torsion enabled the myoma to be extracted in the outpatient clinic, with no complications or excessive bleeding during the procedure.

Anatomopathological analysis confirmed the diagnosis of a submucosal myoma of 25 × 20 × 18 mm. The endometrium was at that time in a state of progesterone impregnation and had a secretory appearance.

Discussion

There is a vast amount of literature published on the treatment of uterine myomas. The growth of myomas is not only estrogen dependent but is also influenced by progesterone [5]. Several SPRMs have shown an antagonist effect on myoma growth (reduction in

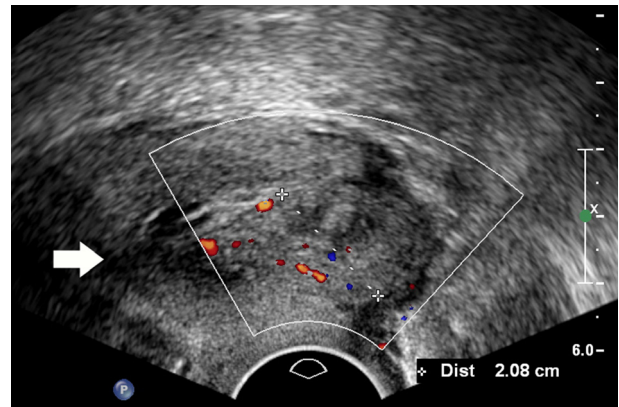


Figure 2. Transvaginal ultrasound, sagittal view of the cervix: 21 mm myoma in the external orifice of the cervix. The vascular end-foot ascends to the cervical canal. The arrow shows the internal opening of the cervix.

size) with no deleterious effect on the endometrium [6–8].

Three recent publications have demonstrated the effect of UPA, derived from 19-norprogesterone, on the control of menorrhagia related to uterine myomatosis and on the reduction in size of myomas [4, 9, 10]. UPA is an SPRM, which acts as a progesterone receptor antagonist and can also act as an agonist [5, 11–13] in certain conditions. It acts specifically on the progesterone receptor with no clinically relevant antiglucocorticoid activity (less than mifepristone, a 19-nortestosterone derivative [14]).

Myoma expulsions reported in the published literature are mainly expulsions secondary to postembolization necrosis. In addition, some descriptions of myoma expulsion following treatment with GnRH agonists have been published [15–17]. This is the first incidence of myoma expulsion under SPRM treatment to our knowledge. The link between the administration of UPA and expulsion of the myoma in our case is not clear. In *in vitro* models of myoma cell cultures, UPA has antiproliferative,

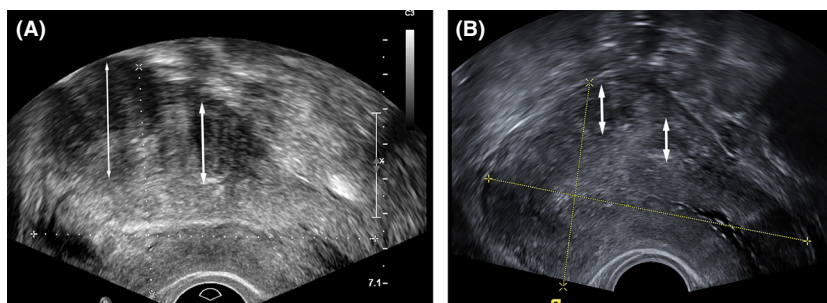


Figure 1. Transvaginal ultrasound, sagittal view of the uterus: two subserosal myomas in the posterior wall. (A) before UPA treatment, (B) after UPA-treatment. UPA, ulipristal acetate.

proapoptotic and antifibrotic effects [18]. Therefore, we theorize that a reduction in the size of the myoma causes the submucosal myoma to separate from the myometrium and the adjacent endometrium. Then, the ischemic submucosal myoma is expelled by contractions of the myometrium, as in a pregnancy that terminates in the first trimester.

In order to understand the molecular mechanism responsible for the reported persistence, for several months after treatment, of the beneficial effect of UPA on myoma size [10], further studies are required. Optimal management of uterine myomatosis remains a real challenge in gynecology. It is important to be alert to the frequency of this disease and to the presentation of its classic clinical symptoms. Despite the abundance of published literature on this disease, there are still numerous pathways to be explored, particularly with regard to drug treatment. To date, no molecule has resulted in a permanent therapeutic solution. UPA may offer an interesting and reassuring alternative and longer term studies with UPA are ongoing.

Conclusion

This case describes the potential of UPA to result in size reduction of a myoma, which can result in the expulsion of a submucosal myoma.

Conflict of Interest

None declared.

References

- Bouchard, P., N. Chabbert-Buffet, and B. C. Fauser. 2011. Selective progesterone receptor modulators in reproductive medicine: pharmacology, clinical efficacy and safety. *Fertil. Steril.* 96:1175–1189.
- Buttram, V. C. Jr, and R. C. Reiter. 1981. Uterine leiomyomata: etiology, symptomatology, and management. *Fertil. Steril.* 36:433–445.
- Cramer, S. F., and A. Patel. 1990. The frequency of uterine leiomyomas. *Am. J. Clin. Pathol.* 94:435–438.
- Donnez, J., F. Vazquez, J. Tomaszewski, K. Nouri, P. Bouchard, B. C. Fauser, et al. 2014. Long-term treatment of uterine fibroids with ulipristal acetate. *Fertil Steril* 2014; 101:1565–73.
- Nisolle, M., S. Gillerot, F. Casanas-Roux, J. Squifflet, M. Berliere, and J. Donnez. 1999. Immunohistochemical study of the proliferation index, oestrogen receptors and progesterone receptors A and B in leiomyomata and normal myometrium during the menstrual cycle and under gonadotrophin-releasing hormone agonist therapy. *Hum. Reprod.* 14:2844–2850.
- Catherino, W. H., M. Malik, P. Driggers, S. Chappel, J. Segars, and J. Davis. 2010. Novel, orally active selective progesterone receptor modulator CP8947 inhibits leiomyoma cell proliferation without adversely affecting endometrium or myometrium. *J. Steroid Biochem. Mol. Biol.* 122:279–286.
- Ohara, N., A. Morikawa, W. Chen, J. Wang, D. A. DeManno, K. Chwalisz, et al. 2007. Comparative effects of SPRM asoprisnil (J867) on proliferation, apoptosis, and the expression of growth factors in cultured uterine leiomyoma cells and normal myometrial cells. *Reprod. Sci.* 14:20–27.
- Chwalisz, K., M. C. Perez, D. Demanno, C. Winkel, G. Schubert, and W. Elger. 2005. Selective progesterone receptor modulator development and use in the treatment of leiomyomata and endometriosis. *Endocr. Rev.* 26:423–438.
- Donnez, J., T. F. Tatarchuk, P. Bouchard, L. Puscasiu, N. F. Zakharenko, T. Ivanova, et al. 2012. Ulipristal acetate versus placebo for fibroid treatment before surgery. *N. Engl. J. Med.* 366:409–420.
- Donnez, J., J. Tomaszewski, F. Vazquez, P. Bouchard, B. Lemieszczuk, F. Baro, et al. 2012. Ulipristal acetate versus leuprolide acetate for uterine fibroids. *N. Engl. J. Med.* 366:421–432.
- Pintiaux, A., N. Chabbert-Buffet, and J. M. Foidart. 2009. Gynaecological uses of a new class of steroids: the selective progesterone receptor modulators. *Gynecol. Endocrinol.* 25:67–73.
- Spitz, I. M. 2003. Progesterone antagonists and progesterone receptor modulators: an overview. *Steroids* 68:981–993.
- Chabbert-Buffet, N., G. Meduri, P. Bouchard, and I. M. Spitz. 2005. Selective progesterone receptor modulators and progesterone antagonists: mechanisms of action and clinical applications. *Hum. Reprod. Update* 11:293–307.
- Hild, S. A., J. R. Reel, L. H. Hoffman, and R. P. Blye. 2000. CDB-2914: anti-progestational/anti-glucocorticoid profile and post-coital anti-fertility activity in rats and rabbits. *Hum. Reprod.* 15:822–829.
- Wen, L., J. Y. Tseng, and P. H. Wang. 2006. Vaginal expulsion of a submucosal myoma during treatment with long-acting gonadotropin-releasing hormone agonist. *Taiwan J. Obstet. Gynecol.* 45:173–175.
- Yu, K. J., C. R. Lai, and M. H. Sheu. 2001. Spontaneous expulsion of a uterine submucosal leiomyoma after administration of a gonadotropin-releasing hormone agonist. *Eur. J. Obstet. Gynecol. Reprod. Biol.* 96:223–225.
- Kriplani, A., N. Agarwal, D. Parul, N. Bhatla, and A. K. Saxena. 2002. Prolapsed leiomyoma with severe haemorrhage after GnRH analogue therapy. *J. Obstet. Gynaecol.* 22:449–451.
- Yoshida, S., N. Ohara, Q. Xu, W. Chen, J. Wang, K. Nakabayashi, et al. 2010. Cell-type specific actions of progesterone receptor modulators in the regulation of uterine leiomyoma growth. *Semin. Reprod. Med.* 28:260–273.