

BHS guidelines for the treatment of marginal zone lymphomas

D. Bron, MD, PhD¹, E. Van den Neste, MD, PhD², A. Kentos, MD³, F. Offner, MD, PhD⁴, W. Schroyens, MD, PhD⁵, C. Bonnet, MD, PhD⁶, A. Van Hoof, MD, PhD⁷, G. Verhoef MD, PhD⁸, A. Janssens, MD⁸

Marginal zone lymphomas are a heterogeneous subtype of indolent B-non-Hodgkin Lymphoma that includes three distinct diseases: Extranodal mucosa associated lymphoid tissue lymphoma, nodal marginal zone lymphoma and splenic marginal zone lymphoma lymphocytes +/- villous lymphocytes. The different diagnosis, work up and treatment options are discussed in these guidelines.

(*Belg J Hematol* 2014;5(1):12-21)

Introduction

Marginal zone lymphoma (MZL) is an indolent B-non-Hodgkin lymphoma (NHL) that includes three distinct diseases, all arising from post-germinal centre marginal zone B cells and sharing a similar immunophenotype (CD20+, CD19+, CD22+, CD 27+, FMC7+, CD5-, CD10-, κ or λ +):¹

1. Extranodal MZL of Mucosa Associated Lymphoid Tissue (MALT) type (including gastric and non-gastric MALT lymphomas)
2. Nodal MZL (with or without circulating B cells)
3. Splenic MZL (with or without villous lymphocytes)

MZL (including MALT) represent 11% of all non-Hodgkin's lymphomas.² The Matutes score is generally very low (below three).

This topic review will separately discuss diagnosis, work up and treatment of gastric and non-gastric MALT lymphoma's, nodal MZL and splenic MZL. These guidelines include the recently published ESMO consensus conference on malignant lymphoma.³

Gastric MZL of MALT type

Incidence

Mucosa associated lymphoid tissue (MALT) lymphomas represent 7-8% of all non-Hodgkin's lymphomas and can arise at any extranodal site; however, at least one-third of them present as a primary gastric lymphoma.^{2,4,5} Its development is often associated with *Helicobacter Pylori* (HP) infection. Median age is 60 years old with a male predominance.

Diagnosis

The most common presenting symptoms of gastric MALT lymphoma are non-specific upper gastrointestinal (GI) complaints that often lead to an endoscopy usually revealing non-specific gastritis or peptic ulcer with mass lesions being unusual.

Diagnosis is based on the histopathological evaluation of the gastric biopsies. If the presence of active HP infection is not demonstrated by histology (sensitivity > 80%), it must be ruled out by a urea breath test and/or a stool antigen test.

In addition to routine histology and immunohistochemistry, fluorescence in situ hybridisation (FISH) analysis

¹Department of Haematology, Institut Jules Bordet (ULB), Brussels, Belgium ²Department of Haematology, Cliniques Universitaires St Luc, Brussels, Belgium ³Department of Haematology, Hôpital de Jolimont, Haine St Paul, Belgium ⁴Department of Haematology, Universitair Ziekenhuis, Gent, Belgium ⁵Department of Haematology, Universitair Ziekenhuis, Antwerp, Belgium ⁶Department of Haematology, Centre Hospitalier Universitaire, Liège, Belgium ⁷Department of Haematology, AZ St Jan, Brugge, Belgium ⁸Department of Haematology, Gasthuisberg, Leuven, Belgium.

Please send all correspondence to: D. Bron, MD, PhD, Institut Jules Bordet, Department of Haematology, 1 Rue Héger Bordet, 1000 Brussels, Belgium, tel: +32 2 541 32 32, email: dbron@ulb.ac.be.

Conflict of interest: The authors have nothing to disclose and indicate no potential conflict of interest.

Keywords: *helicobacter pylori*, marginal zone lymphoma, non-Hodgkin's lymphoma, splenic marginal zone lymphoma.

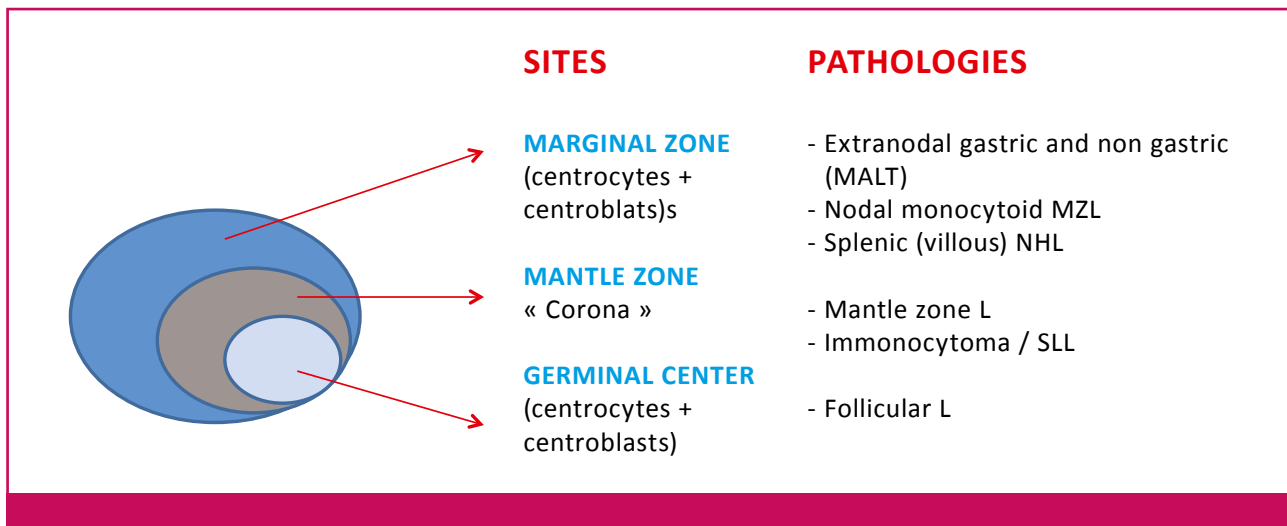


Figure 1. B follicle scheme adapted from C. De Wolf-Peeters.⁴⁵

(or polymerase chain reaction (PCR)) for detection of t(11;18) may be useful for identifying patients that are unlikely to respond to antibiotic therapy and with a possible histologic transformation.² Other chromosomal translocations are t(14;18), t(1;14) or t(3;14).⁶

Work up

- Past history (peptic ulcer? Lyme disease or positive serology for Borrelia? Hepatitis? autoimmune disease, etc.)
- Complaints (night sweats, weight loss, pruritus, fever, diarrhoea, abdominal pain, etc.)
- Physical examination (LN, mucosa, other EN involvement, spleen, skin, etc.)
- Performance status
- Lab tests: CBC with diff and phenotype, biology with LDH, uric acid, ESR, ANA, RF, β 2 microglobulin, viral serologies (HCV, HBV, HIV) and bacterial serologies (HP, Campylobacter)
- Helicobacter P on histology, urea breath test, stool antigen test
- BM biopsy with phenotype. Cytogenetic analysis is optional (FISH or PCR for t(11;18))
- Chest X-ray, CT scan or MRI, endoscopy if indicated (endoscopic ultrasound is then preferred)

Staging and risk assessment

The initial staging procedures should include a gastro-duodenal endoscopy with multiple biopsies taken from each region of the stomach and from any abnormal-appearing site. Endoscopic ultrasound is recommended to evaluate gastric wall infiltration and regional lymph nodes, also useful before irradiation.

PET/CT has limited value in low grade lymphomas such as MZL and is not recommended unless a histologic transformation is suspected.

This type of lymphoma has an unusual clinical course, the international prognostic index (IPI) is not correlated with overall survival (OS) and a specific staging system is now recommended by the National Cancer Comprehensive Network (NCCN) guidelines (*Table 1*).

Treatment plan

Localised HP-positive gastric MALT lymphoma (Lugano staging system: stage IE-IIIE)

Localised HP-positive gastric MALT lymphoma often responds to eradication of HP infection with antibiotics + proton-pump inhibitor as the sole initial treatment.⁷ Any of the highly effective anti-HP antibiotic regimens proposed can be used (*Table 3*). In case of unsuccessful HP eradication (breath test at four-six weeks after treatment, two weeks without PPI), a second-line therapy should be attempted with alternative triple- or quadruple-therapy regimens of proton-pump inhibitor plus antibiotics.^{8,9} HP eradication can induce lymphoma regression and long-term clinical disease control in 50-80% of patients.¹⁰ The length of time necessary to obtain a remission varies from two months to > twelve months (Med = 5 Mos). It is reasonable to wait at least twelve months before starting another treatment in patients who achieve a clinical and endoscopic remission together with eradication of HP, albeit having persistent (residual) lymphoma at the histological level. Several studies of post-antibiotic molecular follow-up have shown the persistence of monoclonal B cells after histological regression of the lymphoma. In these cases, watchful

Table 1. National Cancer Comprehensive Network guidelines for gastrointestinal lymphomas according to the Lugano staging system.

Lugano staging system for gastrointestinal lymphomas	Ann Arbor stage	TNM staging system adapted for gastric lymphoma	Tumour extension
Stage I_E	Confined to GI tract		
I _{E1} = mucosa, submucosa	I _E	T1 N0 M0	Mucosa, submucosa
I _{E2} = muscularis propria, serosa	I _E	T2 N0 M0	Muscularis propria
	I _E	T3 N0 M0	serosa
Stage II_E	Extending into abdomen		
II _{E1} = local nodal involvement	II _E	T1-3 N1 M0	Perigastric lymph nodes
II _{E2} = distant nodal involvement	II _E	T1-3 N2 M0	More distant regional lymph nodes
Stage III_E	II _E	T4 N0 M0	Invasion of adjacent structures
Stage III-IV	III _E	T1-4 N3M0	Lymph nodes on both sides of the diaphragm / distant metastases (e.g. bone marrow or additional extranodal sites)
	IV	T1-4 N0 M3	

waiting is recommended, while active anticancer treatment should be reserved for persistently symptomatic or progressive disease.¹¹ Level of evidence: III – recommendation A.

Localised HP-negative gastric MALT lymphomas who fail HP eradication therapy (Lugano staging system: stage IE-IIIE)

For localised HP-negative gastric MALT lymphomas who fail HP eradication therapy, irradiation or systemic chemo- or immunotherapies should be applied depending on the stage of disease; surgery has not been shown to achieve superior results in comparison with more conservative approaches in various trials.

Gastric MALT lymphomas are usually localised and excellent disease control using radiation therapy alone has been reported by several institutions supporting the use of modest-dose involved-field radiotherapy (30 Gy radiation to the stomach and perigastric nodes given in four weeks).¹² Level of evidence: IV – recommendation B.

Patients with systemic disease (Lugano staging system: stage III-IV)

Patients with systemic disease should be considered for

systemic chemotherapy and/or immunotherapy with anti-CD20 monoclonal antibodies (rituximab 375mg/m²/week x 4).¹³ Only a few compounds and regimens have been tested specifically in MALT lymphomas. Oral alkylating agents (either cyclophosphamide [100mg/d x 6-12 months] or chlorambucil (Chl) [6mg/m²/d x 6-12 months]) or purine analogues (fludarabine [30mg/m²/d x 3 – q28d x 6 months]) can result in a high rate of disease control. The activity of the anti-CD20 monoclonal antibody rituximab has also been shown in a randomised phase III study. Rituximab combined with Chl is now proven to be superior to Chl alone in PFS (68% vs. 50% at five years) but not in OS.¹⁴ The major toxicities of rituximab include infusion reactions (fevers, rigors and hypotension) and infections related to immunosuppression. Rituximab also imposes a risk of hepatitis B reactivation among patients positive for hepatitis B surface antigen (HBsAg) or antibodies against hepatitis B core antigen (anti-HBc). There is no clear evidence in the published literature to recommend any specific drug or regimen; it should, however, be mentioned that treatment with purine analogues might be associated with an increased risk of secondary myelodysplasia. Anthracycline-containing regimens are not recom-

Table 2. Differential Diagnosis of B- Lymphocytosis.

	CLL	HCL	PLL	F NHL	MCL	MZL
↑↑ lympho	++	+	+++	+	+	+++
Spleen	+/-	++	++	+/-	+/-	+++
CD19	++	++	++	++	++	++
CD5	++	-	-	-	++	-
CD23	+	-	-	-	-	-
CD25	+/-	++	-	-	-	-
CD11c	+/-	++	-	-	-	-
FMC7	-	-	++	+	+	+
CD103	-	+	-	-	-	+/-

mended and should be reserved for the few patients with a high tumour burden or transforming histologies. None of the approaches for systemic disease has shown a benefit in survival but median OS is excellent (20 years).¹² Level of evidence: III – recommendation B.

Lymphoma with diffuse large cell infiltration should be treated according to recommendations for diffuse large cell lymphomas.¹⁵

Response evaluation and follow-up

Histological evaluation of repeated biopsies remains an essential follow-up procedure. Unfortunately, the interpretation of the lymphoid infiltrate in post-treatment gastric biopsies can be very difficult and there are no uniform criteria for the definition of histological remission. A surveillance breath test or stool antigen test should be performed at least four weeks after the antibiotic treatment to document HP eradication (PPI must be stopped at least one week before HP testing). Then, a strict endoscopic follow-up is recommended, with multiple biopsies taken two–three months after treatment, and subsequently, at least twice a year for two years, to monitor histological regression of the lymphoma.

Gastric MALT lymphomas have limited tendency to distant spreading and to histological transformation. Transient histological local relapses are possible but tend to be self-limiting especially in the absence of HP

reinfection. In the case of persistent but stable residual disease or histological relapse (without distant dissemination and/or gross endoscopic tumour) a watch-and-wait policy appears to be safe. Nevertheless, long-term careful endoscopic and systemic (blood counts and minimal adequate radiological or ultrasound examinations) follow-up annually is recommended for all patients. Indeed, patients with gastric MALT lymphoma have a sixfold higher risk than the general population of developing a gastric adenocarcinoma.¹⁶

Non-Gastric Extranodal MZL of MALT type

Incidence

Mucosa associated lymphoid tissue (MALT) lymphomas arise in a number of epithelial tissues, including the stomach but also salivary gland, lung, small bowel and colon, thyroid, skin, breast, ocular adnexa, etc.¹⁷ Non-gastric extranodal MZL may also be associated with chronic immune stimulation by infectious agents (HP or H. Heilmanni, Borrelia Burgdorferi, Chlamydia Psittaci, Campylobacter Jejuni, HCV) or autoimmune disorders (Sjögren disease, Hashimoto thyroiditis, Crohn disease, Rheumatoid Arthritis, etc.).^{4,18,19}

Diagnosis

The most common presenting symptoms of non-gastric MALT lymphoma are non-specific complaints (diarrhoea, abdominal pain, cough, skin nodules or any other clinical symptom related to the involved organ). Median age at diagnosis is 60 years old.

Diagnosis is based on the histopathological evaluation of the biopsies. For the GI localisations, presence of active HP infection – not demonstrated by histology – must be ruled out by urea breath test and/or stool antigen test. Campylobacter Jejuni in the small intestine can be detected by PCR in the setting of IPSID.

Viral and bacterial serologies are required to exclude active chronic bacterial stimulation (Borrelia, Chlamydia, Campylobacter and HCV). However, serologies are usually negative and molecular techniques should be performed to exclude these pathogens. The majority of patients present with localised stage I or II disease. Twenty five percent have bone marrow involvement. Thirty percent show a monoclonal gammopathy.^{20,21} A special issue is the primary cutaneous MZL sometimes associated with Borrelia Burgdorferi infections.²² The lesion is usually a deep red infiltrated nodule surrounded by diffuse erythema localised to the extremities or the trunk, rarely disseminated.

Table 3. Approach of extranodal MZL.

Microbial pathogens Dependent MALT lymphoma	Microbial pathogens Independent MALT lymphoma
<p>Helicobacter Pylori</p> <ul style="list-style-type: none"> - PPI triple therapy: - Omeprazole 20 mg + - Clarithromycin 500 x2/d + - Amoxicillin 1 g x2/d for 14d 	<p><i>Localised diseases</i></p> <ul style="list-style-type: none"> • Surgery if not gastric • Local radiotherapy if indicated • Single agent: <ul style="list-style-type: none"> - Rituximab: 375 mg/m²/wk x 4 - Chlorambucil: 16 mg/m²/d, 5d/m x 6mo or 6 mg/m²/d x 6-12mo - Cyclophosphamide: 10 mg/m²/d x 6-12 mo
<p>Chlamydia Psittaci</p> <ul style="list-style-type: none"> - Doxycycline 100 mg/J 3 wks 	<p><i>Disseminated diseases</i></p> <ul style="list-style-type: none"> • Single agent: <ul style="list-style-type: none"> - Rituximab: 375 mg/m²/wk x 4 +/- - Chlorambucil: 16 mg/m²/d, 5d/m x 6mo or 6 mg/m²/d x 6-12mo - CPA: 10 mg/m²/d x 6-12 mo - Fludarabine: 30mg/m²/mo x 6 mo
<p>Borrelia Burgdorferi</p> <ul style="list-style-type: none"> - Doxycycline 100 mg/J or amoxicillin, 3 wks 	<ul style="list-style-type: none"> • Polychemotherapy <ul style="list-style-type: none"> R-CHOP every 3 wk for 6-8 cycles R-FC every 4 wks for 6 cycles
<p>Campylobacter Jejuni</p> <ul style="list-style-type: none"> - Erythromycin or fluoroquinolone 	

Work up

- Past history (Lyme disease or infection? Hepatitis? AIDS? Chlamydia infection? Celiac disease?)
- Complaints (NS, weight loss, pruritus, skin nodule, fever, cough, diarrhoea, abdominal pain, etc.)
- Physical examination (LN, mucosa, other EN involvement, spleen, skin, etc.)
- Performance status
- Lab tests: CBC with diff and phenotype, biology with LDH, uric acid, ESR, ANA, RF, β_2 microglobulin, viral serologies (HCV, HBV, HIV) and bacterial serologies (Borrelia, HP, Chlamydia, Campylobacter)
- Helicobacter P on histology, urea breath test, stool antigen test, HP serology
- BM biopsy with phenotype. Cytogenetic analysis is optional (FISH or PCR for t(11;18))
- Chest X-ray, CT scan or MRI, endoscopy if indicated (endoscopic ultrasound is then preferred)

Staging and risk assessment

The initial staging procedures should include multiple biopsies taken from each abnormal-appearing site. The value of PET scan is controversial and has little clinical value. Patients should be tested for hepatitis B prior to rituximab therapy.

Treatment plan (Table 3)

HP-positive localised MALT lymphoma

In HP-positive localised MALT lymphoma, eradication of HP with antibiotics should be employed (see details in gastric MALT lymphoma) but unlike in gastric lymphomas, the benefit of eradication therapy for non-gastric MALT is unproven.²³

Limited (stage I-II) disease

Limited stage extranodal MALT includes those patients with involvement of a single extralymphatic site (IE) or a lymph node extending into a contiguous extralymphatic organ or tissue (IIE). Surgery is typically used for diagnostic purpose only but may play a role in the treatment of tumours in areas not conducive to radiation therapy (i.e. lung). The addition of adjuvant chemotherapy or antibiotic therapy has not demonstrated improved disease-free or OS.²⁴ There are occasional patients with stage I disease who are not candidates for radiation therapy and may be initially observed closely.²⁵

Locoregional radiotherapy (RT) with 25 to 30 Gy is the principal therapy for most cases of limited stage extranodal MALT. This lymphoma is very sensitive to radiation and doses should not exceed 30 Gy. With this approach, complete responses are seen in >90% of cases.^{26,27}

Table 4. Splenic MZL.

<ul style="list-style-type: none"> • Splenectomy alone
<ul style="list-style-type: none"> • if contra-indications to surgery, single agent: <ul style="list-style-type: none"> - Rituximab: 375 mg/m²/wk x4 - Chlorambucil: 16 mg/m²/d, 5 d/m x 6 mo or 6 mg/m²/d x 6 mo - Cyclophosphamide: 10 mg/m²/d x 6-12 mo - Fludarabine: 30 mg/m²/mo x 6 mo
<ul style="list-style-type: none"> • If associated with HCV <ul style="list-style-type: none"> - pegIFN-α2b (1.0 μg per kg weekly) - plus ribavirin (1000 – 1200 mg/d)
<ul style="list-style-type: none"> • Presence of adverse prognostic factors (high LDH or B symptoms or presence of large cells (20% to 50%) at spleen histology or abdominal lymph nodes) <ul style="list-style-type: none"> - R-CHOP every 3 wks for 6-8 cycles - R-FC every 4 wks for 6 cycles

A prospective phase II study evaluated the use of RT in patients with previously untreated stage IEA non-gastric MALT lymphoma (24 orbital, four thyroid, four salivary gland and five others). Complete remission or complete remission/unconfirmed was achieved in 92% of patients. Three-year OS, PFS, and local control rates were 100, 92 and 97%, respectively.

In a retrospective study of 70 patients with stage IE or IIE MALT lymphoma, including some patients with gastric MALT, mostly treated with involved-field RT alone (25 to 35 Gy) reported five-year disease-free (DFS) and OS of 76% and 96%.

Relapses are most commonly seen in the contralateral paired organ or in a distant site.

Because of the risk of the ocular structures to radiation, doses of 25 to 30 Gy are used for ocular MALT with excellent results. With recurrent disease or advanced disease, lower doses may suffice and doses as low as four Gy given in two fractions can be effective for palliation.

Surgery

Surgery may be used as initial therapy for early stage MALT in locations not amenable to radiation, although with the low doses of radiation required, nearly all sites can be treated. While surgery is not the initial treatment of choice for extranodal MALT, the pathologic diagnosis of MALT may become apparent only after a resection has taken place. If extranodal MALT lymphoma is diagnosed with an excisional biopsy and there is no evidence of residual disease, patients may be followed with close observation. However, if an initial surgical specimen demonstrates positive margins, ad-

juvant involved field RT is administered to avoid local recurrence.

While MZL has a high response rate to chemotherapy, the benefit of adjuvant chemotherapy after radiotherapy has yet to be proven.

Extended (III-IV) disease

Extended (III-IV) disease should be treated according to follicular NHL approaches.²⁸

The addition of anthracycline-based chemotherapy to RT in one RCT of 98 previously untreated patients with stage IE primary orbital MZL did not improve the results obtained following RT alone. A retrospective study of 38 patients with stage III/IV non-gastric MZL reported that the use of an anthracycline-containing chemotherapy regimen after RT improved the rate of CR but not PFS.

Unlike in gastric MALT, the benefit of antibiotic therapy for non-gastric MALT is unproven. In a prospective study of 77 patients with non-gastric MALT, evidence for infection with HP was present in 45%. However, in the sixteen HP-positive patients receiving eradication treatment before anti-lymphoma therapy, partial regression of the lymphoma was seen in only one patient. In relapsed/refractory MALT lymphoma, there is proof of principle for bortezomib (nine CR, five PR in 29 evaluable patients in an open phase II trial).²⁹

In ocular adnexal lymphoma, however, using PCR techniques, the *C. Psittaci* is detected (tumour tissue or conjunctival swab) in up to 89% of the cases. For this reason, doxycycline is recommended for CP irradiation and 65% of lymphoma regression is reported.²⁵

Cutaneous MZL

There are no clear treatment recommendations due to the lack of prospective data.

A localised nodule should be treated by RT (30Gy). In some cases with negative margins after resection, a watch-and-wait approach is recommended. Radiation does not appear inferior to multiagent chemotherapy among patients with multiple lesions that can be included in multiple radiation fields.³⁰ Chemotherapy is reserved for extensive disease.

An asymptomatic multifocal disease may be followed with close observation.

In symptomatic disease, radiation therapy of the symptomatic sites can be useful. Rituximab is given combined with an alkylating agent in symptomatic disseminated disease but has no reimbursement in Belgium.

Table 5. Level of evidence (Infectious Diseases Society of American-United States Public Health Service Grading System).

I	Evidence from at least one large randomised, controlled trial of good methodological quality (low potential for bias) or meta-analyses of well-conducted randomised trials without heterogeneity
II	Small randomised trials of large randomised trials with a suspicion of bias (lower methodological quality) or meta-analyses of such trials or of trials demonstrated heterogeneity
III	Prospective cohort studies
IV	Retrospective cohort studies or case-control studies
V	Studies without control group, case reports, experts opinions
Grade for recommendation	
A	Strong evidence for efficacy with a substantial clinical benefit, strongly recommended
B	Strong or moderate evidence for efficacy but with a limited clinical benefit, generally recommended
C	Insufficient evidence for efficacy or benefit does not outweigh the risk or the disadvantages (adverse events, costs, etc.), optional
D	Moderate evidence against efficacy or for adverse outcome, generally not recommended
E	Strong evidence against efficacy or for adverse outcome, never recommended

Response evaluation and follow-up

Histological evaluation of repeated biopsies remains an essential follow-up procedure for intestinal lymphomas. The interpretation of a lymphoid infiltrate in post-treatment non-gastric biopsies can be very difficult and there are no uniform criteria for the definition of histological remission. In the case of persistent but stable residual disease or histological relapse (without distant dissemination and/or gross endoscopic tumour) a watch-and-wait policy appears to be safe.

In all other cases, long-term careful examination of extranodal organs (MALT) and systemic (blood cells counts, adequate radiological or ultrasound examinations) follow-up annually is recommended for at least five years.

Nodal MZL

Incidence

Nodal MZL represent 1% of all NHL and 10% of MZL. They present primary nodal involvement in the absence of any extra-nodal site with the exception of bone marrow, with or without circulating cells (monocytoid B cells) but often produce a monoclonal immunoglobulin (IgM > IgG). Median age at diagnosis is 50 years old. The disease is often asymptomatic but in some patients, behaviour of the disease is more aggressive.³¹

Diagnosis

Diagnosis is based on the histopathological evaluation of a lymph node biopsy or on the cytomorphological analysis of circulating or bone marrow lymphoma cells. Bone marrow is involved in up to 70% of cases.

No specific cytogenetic abnormalities have been associated with nodal MZL.³²

When a monoclonal B lymphocytosis is present in peripheral blood, other malignant hemopathies such as chronic lymphocytic leukaemia (CLL), hairy cell leukaemia (HCL), prolymphocytic leukaemia (PLL), follicular lymphoma (FNHL) or mantle cell lymphoma (MCL) should be excluded by phenotypic and genetic abnormalities (Table 2).

Work up

- Past history (Hepatitis? co-morbidities?)
- Complaints (weight loss, pruritus, fever, night sweats, etc.)
- Physical examination (LN, mucosa, other EN involvement, spleen, etc.)
- Performance status
- Lab test: CBC with diff and phenotype, biology with LDH, uric acid, ESR, proteins and electrophoresis, ANA, RF, serologies (HCV, HBV, HIV), β_2 -microglobulin

- BM biopsy with phenotypic, cytogenetic and molecular analysis
- Chest X-ray, CT Scan or MRI

Staging and risk assessment

The initial staging procedures should include a lymph node biopsy followed by a work up to evaluate the extent of the disease and co-morbidities.

The value of positron emission tomography (PET) scan is controversial and is not routinely used unless histological transformation is suspected.

Staging is done according to Ann Arbor.

Treatment plan

There is no general consensus regarding the treatment of nodal MZL. Until more data are available patients are treated like those with indolent lymphomas.

Treatment of symptomatic patients with rituximab (either alone or in combination with chemotherapy) has shown remarkable responses.³³

In asymptomatic cases, watchful waiting is recommended, while active anticancer treatment should be reserved for persistently symptomatic or progressive disease.

Only a few compounds and regimens have been tested specifically in MZL. Oral alkylating agents (either cyclophosphamide or Chl) or purine analogues (fludarabine, cladribine) can result in a high rate of disease control. The activity of the anti-CD20 monoclonal antibody rituximab has also been shown in phase II studies and its efficacy in combination with Chl or purine analogs or bendamustine is now demonstrated: OR and CR reach 97 and 60% respectively.^{2,34,35} In a recent multicentre phase II trial presented at the ASH meeting, Bendamustine and rituximab as first line treatment resulted in 98% of CR and 85% of the patients only required four cycles.³⁶ Anthracycline-containing regimens are usually not necessary and should be reserved for the few patients with a high tumour burden.

Benda R as first-line treatment for patients with indolent lymphomas was shown to be equal to R-CHOP with a better tolerance and a benefit in PFS.³⁶

Lymphoma with diffuse large cell infiltration should be treated according to the recommendations for diffuse large cell lymphoma.

Splenic MZL (SMZL)

Incidence

Splenic MZL is a unique entity (<1% NHL, <10% of MZL) of low-grade lymphoma infiltrating spleen, bone

marrow and peripheral blood. Peripheral lymph nodes are not typically involved. Median age is 70 years old with a female predominance.

Diagnosis

The most common presenting symptoms of splenic MZL are non specific abdominal complaints that often lead to abdominal ultrasound or CT, usually revealing splenomegaly or a routine blood cell count revealing circulating monoclonal B lymphocytes in an healthy patient.³² This lymphoma has been reported in patients with hepatitis C virus infection. Regression of the spleen was observed after eradication of the HCV (fourteen out of eighteen patients clearing hepC under interferon went into CR).^{37,38} This represents a subset of splenic MZL associated with chronic hepatitis C and mixed cryoglobulinemia. Many cases of splenic MZL are not hepatitis C driven. Approximately 40% of SMZL are associated with deletion of chromosome 7q32. Trisomy three is frequently associated with SMZL.³⁹ Ten to forty percent of the patients have a serum monoclonal protein. Other lymphomas presenting with splenomegaly and a monoclonal B lymphocytosis are splenic MZL with villous lymphocytes, chronic lymphocytic leukaemia, hairy cell leukaemia, prolymphocytic leukaemia, follicular lymphoma in leukemic phase and mantle cell lymphoma. Morphology, immunophenotype and molecular features are usually helpful for the differential diagnosis (Table 2).

Work up

- Past history (co-morbidities? Hepatitis C?)
- Complaints (NS, weight loss, fever, abdominal pain, etc.)
- Physical examination (LN, spleen, mucosa, etc.)
- Performance status
- Lab test: CBC with diff and phenotype, biology with LDH, uric acid, ESR, protein and electrophoresis, IgM, A, β 2-microglobulin (Coombs, cryoglobulins if + HCV, 10-15% autoimmune phenomena)
- HCV (RT-PCR if + serology), HBV, HIV serology
- BM biopsy with phenotype and cytogenetic data (+ FISH or PCR for chromosome 3 and 7 abnormalities)
- Chest X-ray, CT Scan or MRI, echography
- Pregnancy test (if applicable)

Staging and risk assessment

Work up studies should exclude involvement of other lymph nodes or extranodal sites. The majority of patients demonstrate an indolent course with a median OS in

Key messages for clinical practice

1. Extranodal MALT lymphoma arises in a variety of tissue but primarily in the stomach. They are usually localised and often associated with chronic antigenic stimulation by microbial pathogens. Eradication of the pathogen is part of the first line therapy. Prognosis is excellent and radiotherapy (when feasible) is curative in early stages. In advanced stages, observation, anti CD20 antibodies and/or cytostatic drugs (such as chlorambucil or fludarabine) are therapeutic approaches.
2. Nodal MZL is usually confined in lymph node, bone marrow and peripheral blood. A monoclonal gammopathy (IgG, IgM) is often produced by the lymphoma cells. Because of the lack of RCTs in this population, there are no guidelines and they should be managed as follicular lymphomas.
3. Splenic MZL lymphocytes +/- villous lymphocytes are a unique entity involving the spleen, the bone marrow and the blood. These lymphomas have an indolent behaviour and only symptomatic patients should be treated by splenectomy and/or rituximab (after control for hepatitis C status).

excess of ten years. Factors associated with a shorter survival are elevated LDH, low haemoglobin level, older age and high IPI.³² 14q aberrations and TP53 deletions are also poor prognostic indicators.³⁹ In 25-30% of SMZL, an aggressive behaviour is observed with a shorter survival.

Treatment plan (Table 4)

Treatment is limited to those patients with symptomatic splenomegaly (discomfort, cytopenia, coexisting hepatitis C infection).

Excellent disease control can be achieved by splenectomy or immunotherapy (rituximab). Splenectomy usually corrects pancytopenia and can lead to the reduction of circulating lymphocytes. Although it is a partial response, this situation can be maintained for ten years.⁵ Treatment with single agent rituximab can result in a reduction of splenomegaly and normalisation of absolute lymphocyte counts in >90 % of patients.⁴⁰

A single institution retrospectively analysed 70 patients with SMZL, 43 of whom underwent treatment with rituximab alone (26 patients), chemotherapy alone (11 patients), or rituximab plus chemotherapy (6 patients), reported excellent outcomes in patients treated with single agent rituximab. When compared with those who received chemotherapy alone, patients who received single agent rituximab had superior rates of OR (88% vs. 55%), three year OS (86% vs. 45%) and three year failure-free survival (86% vs. 45%). Outcomes in patients who received both rituximab and chemotherapy were similar to those seen for patients who received rituximab alone.^{41,42}

Although this retrospective, uncontrolled study provides exciting initial data on the use of rituximab in this population, caution must be used with co-existing

hepatitis C infection. Those with HCV should be treated by antiviral therapy (Peg IFN α 2b 1 μ g/kg/w and ribavirin 1g/d) and not rituximab.³⁷

There have been a few series reporting improved symptoms after splenic irradiation or embolisation when the patient is not chemosensitive and not a candidate for splenectomy.^{43,44} Bendamustine also produces durable responses with acceptable toxicity but is only reimbursed in rituximab refractory patients.³⁶

References

1. Swerdlow SH, Campo E, Harris NL, et al. WHO Classification of Tumours of Haematopoietic and Lymphoid Tissues. Lyon, France: IARC Press;2008.
2. Zinzani L. The many faces of marginal zone lymphomas. ASH education book 2012;1:426-32.
3. Dreyling M, Thieblemont C, Gellmann A, et al. ESMO Consensus conferences: guidelines on malignant lymphoma. part 2: marginal zone lymphoma, mantle cell lymphoma, peripheral T-cell lymphoma. Ann Oncol 2013;24(4):857-77.
4. Ferreri AJ, Zucca E. Primary gastric lymphoma pathogenesis and treatment: what has changed over the past 10 years? Br J Hematol 2007;136:521-38.
5. Thieblemont C. Clinical presentation and management of marginal zone lymphoma. Hematology (ASH) 2005:307-13.
6. Kwee I, Rancoita PM, Rinaldi A, et al. Genomic profiles of MALT lymphomas: variability across anatomical sites. Haematologica 2011;96(7):1064-6.
7. Zullo A, Hassan C, Cristofari F, et al. Effects of Helicobacter Pylori eradication on early stage gastric mucosa-associated lymphoid tissue lymphoma. Clin Gastroenterol Hepatol 2010;8(2):105-10.
8. Fuccio L, Laterza L, Zagari RM, et al. Treatment of Helicobacter Pylori infection. BMJ 2008;337:a1454.
9. Chey WD, Wong BC. Practice Parameters Committee of the American College of Gastroenterology. American College of Gastroenterology guideline on the management of Helicobacter pylori infection. Am J Gastroenterol 2007;102(8):1808-25.
10. Stathis A, Chini C, Bertoni F, et al. Long term outcome following Helicobacter

- Pylori eradication in a retrospective study of 105 patients with localized gastric marginal zone B-cell lymphoma of MALT type. *Ann Oncol* 2009;20:1086-93.
11. Fisschbach W, Goebeler ME, Ruskone-Fourmestraux A, et al. Most patients with minimal histological residuals of gastric MALT lymphoma after successful eradication of *Helicobacter Pylori* can be managed safely by a watch and wait strategy: experience from a large international series. *Gut* 2007;56:1685-7.
 12. Zucca E, Dreyling M. On behalf of the ESMO guidelines working group. Gastric marginal zone lymphoma of MALT type: ESMO clinical practice guidelines for diagnosis, treatment and follow up. *Annals of Oncol* 2010;21(Sup 5):v175-6.
 13. Martinelli G, Laszlo D, Ferreri AJ, et al. Clinical activity of rituximab in gastric marginal zone non-Hodgkin's lymphoma resistant to or not eligible for anti-*Helicobacter pylori* therapy. *J Clin Oncol* 2005;23(9):1979-83.
 14. Zucca E, Conconi A, Laszlo D, et al. Addition of rituximab to chlorambucil produces superior event-free survival in the treatment of patients with extranodal marginal-zone B-cell lymphoma: 5-year analysis of the IELSG-19 Randomized Study. *JCO* 2013;31(5): 565-72.
 15. Bosly A. Diffuse Large B Cell Lymphoma: concise review. *Belg J Hematol* 2011;2:57-63.
 16. Capelle LG, de Vries AC, Looman CW, et al. Gastric MALT lymphoma: epidemiology and high adenocarcinoma risk in a nation-wide study. *Eur J Cancer* 2008;44:2470-6.
 17. Decaudin D, de Cremoux P, Vincent-Salomon A, et al. Ocular adnexal lymphoma : a review of clinicopathologic features and treatment options. *Blood* 2006;108:1451.
 18. Suarez F, Lortholary O, Hermine O, et al. Infection associated lymphomas derived from marginal zone B-cells: a model of antigen-driven lymphoproliferation. *Blood* 2006;107:3034.
 19. Oh S, Ryou BY, Kim WS, et al. Nongastric marginal zone B-cell lymphoma: analysis of 247 cases. *Am J Hematol* 2007;82:446.
 20. Sretenovic M, Colovic M, Jankovic G, et al. More than a third of non gastric malt lymphomas are disseminated at diagnosis: a single center survey. *Eur J Haematol* 2009;82:373.
 21. Thieblemont C, Berger F, Dumontet C, et al. Mucosa-associated lymphoid tissue lymphoma is a disseminated disease in one third of 158 patients analyzed. *Blood* 2000;95:802.
 22. Roggero E, Zucca E, Mainetti C, et al. Eradication of *Borrelia burgdorferi* infection in primary marginal zone B-cell lymphoma of the skin. *Hum Pathol* 2000;31(2):263-8.
 23. Grünberger B, Wöhner S, Streubel B, et al. Antibiotic treatment is not effective in patients infected with *Helicobacter Pylori* suffering from extragastric MALT lymphoma. *J Clin Oncol* 2006;24:1370.
 24. Aviles A, Neri N, Calva A, et al. Addition of a short course of chemotherapy did not improve outcome in patients with localized marginal B-cell lymphoma of the orbit. *Oncology* 2006;70:173.
 25. Ferreri AJM, Govi S, Pasini E, et al. Chlamydia Eradication With Doxycycline As First-Line Targeted Therapy for Ocular Adnexal Lymphoma: Final Results of an International Phase II Trial. *J Clin Oncol* 2012;30:2988-94.
 26. Isobe K, Kagami Y, Higuchi K, et al. A multicenter phase II study of local radiation therapy for stage IEA mucosa-associated lymphoid tissue lymphomas: a preliminary report of the Japan Radiation Oncology Group (JAROG). *Int J Radio Oncol Biol Phys* 2007;69:1181.
 27. Goda JS, Gospodarowicz M, Pintilie M, et al. Long term outcome in localized extranodal mucosa-associated lymphoid tissue lymphomas treated with radiotherapy. *Cancer* 2010;116:3815.
 28. Debussche S, Van Hoof A, Sonnet A, et al. Guidelines of the Belgian Hematological Society for newly diagnosed and relapsed follicular lymphoma 2012. *Belg J Hematol* 2012;3:41-50.
 29. Conconi A, Martinelli G, Lopez-Guillermo A, et al. Clinical activity of bortezomib in relapsed/refractory MALT lymphomas: results of a phase II study of the International Extranodal Lymphoma Study Group (IELSG). *Ann Oncol* 2011;22(3):689-95.
 30. Wilcox RA. Cutaneous B-cell lymphomas: 2013 update on diagnosis, risk stratifications and management. *Am J Hematol* 2013;88:74-76.
 31. Thieblemont C. Non MALT marginal zone lymphomas. *Ann Oncol* 2008;19(Sup 4):iv70-73.
 32. Arcaini L, Lazzarino M, Colombo N, et al. Splenic marginal zone lymphoma: a prognostic model for clinical use. *Blood* 2006;107:4643.
 33. Sousou T, Friedberg J. Rituximab in indolent lymphomas. *Semin Hematol* 2010;47:133-142.
 34. Orciuolo E, Buda G, Sordi E, et al. 2CDA chemotherapy and rituximab in the treatment of marginal zone lymphoma. *Leuk Res* 2010;34:184.
 35. Brown JR, Friedberg JW, Feng Y, et al. A phase II study of concurrent fludarabine and rituximab for the treatment of marginal zone lymphomas. *Br J Hematol* 2009;145:741.
 36. Rummel MJ, Niederle N, Maschmeyer G, et al. Bendamustine plus rituximab versus CHOP plus rituximab as first-line treatment for patients with indolent and mantle-cell lymphomas: an open-label, multicentre, randomised, phase 3 non-inferiority trial. *Lancet* 2013;381(9873):1203-10.
 37. Hermine O, Lefrere F, Bronowicki JP, et al. Regression of splenic lymphoma with villous lymphocytes after treatment of hepatitis C virus infection. *N Engl J Med* 2002;347:89.
 38. Saadoun D, Suarez F, Lefrere F, et al. Splenic lymphoma with villous lymphocytes associated with type II cryoglobulinemia and HCV infection: a new entity? *Blood* 2005;105:74.
 39. Salido M, Baró C, Oscier D, et al. Cytogenetic aberrations and their prognostic value in a series of 330 splenic marginal zone B-cell lymphomas: a multicenter study of the Splenic B-Cell Lymphoma Group. *Blood* 2010 ;116(9):1479-88.
 40. Bennett M, Schechter GP. Treatment of splenic marginal zone lymphoma: splenectomy vs. rituximab. *Semin Hematol* 2010;47(2):143-7.
 41. Thieblemont C, Davi F, Noguera ME, et al. Splenic marginal zone lymphoma: current knowledge and future directions. *Oncology (Williston Park)* 2012;26(2):194-202.
 42. Tsimberidou AM, Catovsky D, Schlette E, et al. Outcomes in patients with splenic marginal zone lymphoma and marginal zone lymphoma treated with rituximab with or without chemotherapy or chemotherapy alone. *Cancer* 2006;107:125.
 43. El Weshi A, Ribrag V, Girinski T, et al. Low and medium dose spleen radiation therapy are able to induce long-term responses in splenic lymphoma with villous lymphocytes. *Br J Haematol* 1998;103(4):1212.
 44. Muylle K, Nguyen J, de Wind A, et al. Radioembolization of the Spleen: A Revisited Approach for the Treatment of Malignant Lymphomatous Splenomegaly. *Cardiovasc Intervent Radiol* 2012 Sep 25.
 45. Sagaert X, Sprangers B, De Wolf-Peeters C. The dynamics of the B follicle: understanding the normal counterpart of B-cell-derived malignancies. *Leukemia* 2007;21(7):1378-86.