V. T. Ramaekers[1]
M. Häusler[1]
T. Opladen[1]
G. Heimann[1]
N. Blau[2]

Psychomotor Retardation, Spastic Paraplegia, Cerebellar Ataxia and Dyskinesia Associated with Low 5-Methyltetrahydrofolate in Cerebrospinal Fluid: A Novel Neurometabolic Condition Responding to Folinic Acid Substitution

Abstract

Introduction: Normal brain development and function depend on the active transport of folates across the blood-brain barrier. The folate receptor-1 (FR 1) protein is localized at the basolateral surface of the choroid plexus, which is characterized by a high binding affinity for circulating 5-methyltetrahydrofolate (5-MTHF).
Patients and Methods: We report on the clinical and metabolic findings among five children with normal neurodevelopmental progress during the first four to six months followed by the acquisition of a neurological condition which includes marked irritability, decelerating head growth, psychomotor retardation, cerebellar ataxia, dyskinesias (choreoathetosis, ballism), pyramidal signs in the lower limbs and occasional seizures. After the age of six years the two oldest patients also manifested a central visual disorder. Known disorders have been ruled out by extensive investigations. Cerebrospinal fluid (CSF) analysis included determination of biogenic monoamines, pterins and 5-MTHF.
Results: Despite normal folate levels in serum and red blood cells with normal homocysteine, analysis of CSF revealed a decline towards very low values for 5-methyltetrahydrofolate (5-MTHF), which suggested disturbed transport of folates across the blood-brain barrier. Genetic analysis of the FR 1 gene revealed normal coding sequences. Oral treatment with doses of the stable compound folinic acid (0.5 – 1 mg/kg/day Leucovorin®) resulted in clinical amelioration and normalization of 5-MTHF values in CSF.
Conclusion: Our findings identified a new condition manifesting after the age of 6 months which was accompanied by low 5-MTHF in cerebrospinal fluid and responded to oral supplements with folinic acid. However, the cause of disturbed folate transfer across the blood-brain barrier remains unknown.

Key words
Folate · Blood-Brain Barrier · Folate Receptor

Introduction

Two folate transport mechanisms have been identified in man, i.e., the reduced folate carrier 1 (RFC1) and the folate receptor proteins (FR). Both mechanisms involve the transport of folates from plasma to the cell interior, as well as the folate transport across the placental, intestinal and blood-brain barriers [26, 30, 32, 38].

RFC1 represents an integral membrane protein operating only at relatively high folate concentrations within the micromolar range that is driven by anionic gradients. It was found to mediate intestinal folate transport. A genetic defect of the RFC1 system is thought to be the most likely cause of a rare hereditary disease of intestinal folic acid malabsorption (OMIM No: 229050), causing failure to thrive, macrocytic anaemia, microcephaly, developmental delay, ataxia, extrapyramidal movement disorders and convulsions with intracranial calcifications. Some of these patients have benefitted from oral or parenteral folate administration [9, 28, 30, 37].

The membrane-attached folate receptors (FR 1 and FR 2) possess high affinity for folate in the nanomolar range and therefore are able to bind physiological levels of folate [2, 14, 21]. FR 1 (formerly called the folate binding protein 1 or folate receptor alpha) shows a higher affinity for 5-methyltetrahydrofolate (5-MTHF) compared with FR 2 (synonym: the folate binding protein 2 or fo-

Affiliation
[1] Division of Paediatric Neurology, Department of Paediatrics, University Hospital Aachen, Aachen, Germany
[2] Division of Clinical Chemistry and Biochemistry, University Children's Hospital, Zurich, Switzerland

Correspondence
V. T. Ramaekers, PD, M.D., Ph.D. · Division of Paediatric Neurology, Department of Paediatrics, University Hospital Aachen · Pauwelsstraße 30 · 52074 Aachen · Germany · E-mail: vramaekers@ukaachen.de

Received: April 10, 2002 · **Accepted after Revision:** September 25, 2002

Bibliography
Neuropediatrics 2002; 33: 301 – 308 © Georg Thieme Verlag Stuttgart · New York · ISSN 0174-304X

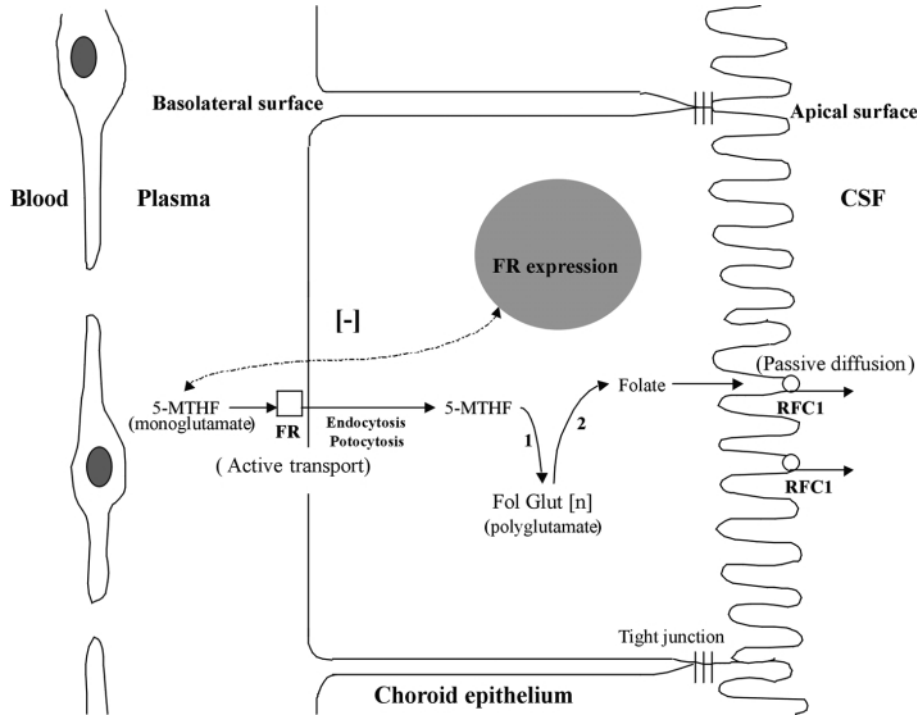

Fig. **1** Mechanisms of active transport for folates across the blood-brain barrier are mainly localized within the choroid epithelium of the choroid plexus. The choroid plexus capillaries have open fenestrations between their lining endothelial cells (left side of the figure). The monoglutamate 5-MTHF is bound to the folate receptor proteins (FR) located at the basolateral surface of choroid epithelium and transported actively against a concentration gradient within the cell interior. Likewise, vitamin B6, B12 and C are also transported by an active transport mechanism. At the apical surface passive diffusion or facilitated diffusion through the reduced folate carrier 1 (RFC1) delivers folates to the cerebrospinal fluid compartment where diffusion to interstitial spaces and subsequent uptake by neurons and neuroglia takes place. Intracellular storage of 5-MTHF inside cells occurs by polyglutamination to folylpolyglutamates (Fol Glut [n]) by the enzyme folylpolyglutamate synthase (1), while pteroyl-polyglutamate conjugase (2) is responsible for the conversion towards monoglutamates. The extracellular folate concentration correlates inversely with the expression of FR proteins at the membrane surface (indicated by the – sign between brackets).

late receptor beta). The FR proteins are crucial for the assimilation, distribution and retention of food folates [31] and have been identified in various cell membranes and extracellular fluids with a tissue-specific distribution in mammalians. FR expression is inversely regulated by the extracellular concentration of folates [21,22]. The mechanism of FR-mediated transport of 5-MTHF from extracellular compartments to the cell interior occurs via typical endocytosis or through the use of caveolae [22,24,29].

The most important site of folate transport to the nervous system is localized at the choroid plexus. Here the active transport of 5-MTHF from plasma to cerebrospinal fluid (CSF) depends mainly on membrane FRs which primarily accumulate folate at the basolateral surface of choroid epithelium, mediate the transport against a concentration gradient into choroid epithelial cells and subsequently deliver 5-MTHF to the CSF [18,43] (Fig. **1**). Due to this active transport process CSF folate levels are 1.5 to 2 times higher than blood folate levels [33,34,41].

Several recent reports have identified genetic defects of FR 1 as one of the possible causes of neural tube defects in children [11,12]. Nullizygous mice lacking the FR 1 gene do not survive pregnancy and show severe embryonic maldevelopment, including defects of neural tube closure [25]. In contrast, nullizygous FR 2 gene mice demonstrated a normal phenotype. One adult patient has been reported with progressive neurological symptoms due to folate depletion in the nervous system in whom a defect of the FR 1 protein at the choroid plexus was suspected [42].

We identified five children without a neural tube defect but with lowered CSF 5-MTHF levels who after the age of 6 months manifested neurological features which resembled to some extent the symptomatology known from patients with hereditary folate malabsorption and from the adult patient with a suspected FR 1-mediated transport defect to the nervous system. Because intestinal folic acid absorption was normal, and no evidence was found for acquired systemic folate depletion or an inborn error of folate metabolism, the possibility of a folate transport disorder across the blood-brain barrier with resultant folate depletion within the central nervous system (CNS) was investigated.

Table **1** Clinical features among five patients

Patient	*Age*	*Head growth*	*Irrit*	*Retardation*	*Ataxia*	*Dyskinesia*	*PS*	*Seizures*	*VD*
1	1.7 yrs	P50 – < P10	+	+	+++	+	+	+	–
2	3.7 yrs	P75 – P25	+	+	++	+	+	+	–
3	4.7 yrs	> P97 – P25	–	+	++	–	+ (a)	–	–
4	8.9 yrs	< P3	+	+	+++	+	+	+	+
5	10.7 yrs	P10 – < P3	+	+	+++	+	+	±	+

Ataxia +: Wobbly gait, but ability to walk; ++: Ataxia with frequent falls; +++: Severe ataxia without the ability to sit, stand or walk. (a): polyneuropathy.
±: Two single and self-limited attacks with generalized tonic-clonic convulsions.
Irrit: Irritability; PS: Pyramidal signs; Dyskinesia: choreathetosis and ballism; VD: central visual disturbance.

Table **2** Results of cerebrospinal fluid analysis

Patient	*Age years*	*Treatment*	*5-MTHF nmol/l*	*Neo*	*Bio*	*5HIAA nmol/l*	*HVA*	*HVA/5HIAA Ratio*
1	1.7	–	**53**	**6.2**	**4**	**70**	312	4.5
	3	–	**0**	12.6	10	**54**	243	4.5
	4.5	15 mg	70.7	**2.3**	**8.9**	147	349	2.4
2	3.7	–	**20.9**	**7.5**	23	**78**	297	3.8
	4.9	15 mg	70	**7.2**	16.4	137	280	2.0
3	4.7	–	**0**	9.9	16.4	**36**	228	6.3
	5.7	15 mg	65.1	10.3	21	183	443	2.4
4	8.9	–	**17.7**	22.6	25.6	**75.8**	324	4.3
	9.7	–	**15.2**	9	19.6	116	582	5.0
	10	15 mg	**31.4**	**5.9**	14.8	110	390	3.5
	10.7	30 mg	**36.1**	**7.6**	17.2	127	361	2.8
5	10.7	–	**39**	**6**	18	142	260	1.8
	13.8	–	**14.9**	**8.3**	17.9	**67**	**119**	1.8
	14.1	30 mg	54	**6.1**	13.2	150	158	1.1
Controls (years)								
0.5 – 1 mean (range)			64 – 182	12 – 30	15 – 40	224 (114 – 336)	660 (295 – 932)	1.5 – 3.5
2 – 4 mean (range)			63 – 111	9 – 30	10 – 30	202 (105 – 299)	603 (211 – 871)	1.5 – 3.5
5 – 10 mean (range)			41 – 117	9 – 20	10 – 30	133 (88 – 178)	523 (144 – 801)	1.5 – 3.5
11 – 16 mean (range)			41 – 117	9 – 20	10 – 30	118 (74 – 163)	399 (133 – 551)	1.5 – 3.5

Neo: neopterin; bio: neopterin. The lowered values have been marked by bold characters.

Patients and Methods

Patients

The five patients (four males and one female, aged between 1.7 and 10.7 years) came from unrelated families and their family history was unremarkable. Tables **1** and **2** summarize the most important clinical features and biochemical findings amongst the five children. Extensive previous investigations had not revealed an underlying cause for their neurological problems.

In one family of Tamil origin (patient 4) the parents were first cousins. Pregnancy, birth and neonatal period were normal except for patient 2 who was born after 28 weeks of pregnancy complicated by HELPP-syndrome. He needed artificial ventilation but no major neurological complications occurred during the neonatal period in the intensive care unit.

In all children early development during the first four to six months of life was described as normal. After 6 months of normal growth, the head circumference growth started to decelerate. The first abnormalities noticed by the parents were marked unrest and irritability with disturbed sleep. After the age of 6 months cognitive and motor developmental progress became severely delayed or even came to a standstill in all patients except patient 3. Ataxic signs of postural control and upon attempted grasping appeared between the age of 6 and 12 months. Moreover, upper limb movements became further complicated due to superimposed dyskinesias with ballistic movements and hand choreoathetosis. From the age of two years neurological examination revealed marked retardation of all milestones with ataxia and dyskinesias, while pyramidal signs were present with a more distal distribution in the lower limbs.

Compared to the other patients, patient 3 was different since he developed a severe polyneuropathy in his lower limbs after the age of two years with complete disappearance of the previously increased tendon reflexes. Repeated attempts to measure motor nerve conduction velocities upon stimulation of the peroneal and posterior tibial nerves revealed an absent response. Motor nerve conduction of the median nerve was normal. A quadriceps muscle biopsy showed only sporadic muscle fibre atrophy, whereas a sural nerve biopsy showed a 50% reduction of the number of large myelinated fibres with sporadic degenerated myelin sheaths. The remaining nerve fibres showed abnormally thin myelin sheaths. There was no onion bulb formation and no accumulation of abnormal substances. In patients 4 and 5, however, electroneuromyographic studies were normal. A sural nerve and quadriceps muscle biopsy in patient 5 showed completely normal findings.

Occasional seizures with absences, myoclonic fits and tonic-clonic convulsions became manifest in the first two years of life in patients 2, 4 and 5 while in patient 1 short attacks with tonic upward eye deviation to the right coincided with left temporo-parieto-occipital spike discharges on the EEG record. Patient 3 never suffered from fits. Anticonvulsant treatment was necessary to control seizures at some time in patients 2 and 4.

In the two oldest children (patients 4 and 5) a severe central visual disturbance became manifest after the age of six years and led to blindness in patient 4. Visual evoked potentials after flash stimuli (VEP) showed delayed latencies with markedly reduced amplitudes for wave N2 and P2.

Acoustic brainstem evoked responses (AEP), studied among patients 2, 4 and 5 (at birth, 10 and 6 years, respectively), were completely normal.

Extensive biochemical, metabolic investigations and high resolution chromosome analysis were completely normal. Appropriate tests excluded Angelman syndrome and genetic alteration of the MECP2-gene has been excluded in the female patient.

Among patients 1, 2, 4 and 5 MRI of the brain showed non-progressive and moderate cerebral atrophy with moderate widening of the third and lateral ventricles but a normal myelinization pattern. In patient 3 with the polyneuropathy, neuro-imaging of the brain and spinal cord was normal.

Taking the age differences into account, patients 1, 2, 4 and 5 shared the same clinical features of decelerating head growth, delayed psychomotor development with irritability, cerebellar ataxia, spastic paraplegia, dyskinesias and occasional seizures. Patient 3 did show some of these features, but was different, because he did not manifest irritability, dyskinesia and seizures. He was found to suffer from an additional severe polyneuropathy of his lower limbs. However, the biochemical findings were identical.

Biochemical investigations

After informed parental consent a lumbar puncture was performed according to a standardized protocol between 8.30 and 10.00 AM and CSF immediately frozen for measurement of the biogenic monoamine end-metabolites for dopamine and serotonin, i.e., homovanillic acid (HVA) and 5-hydroxyindoleacetic acid (5HIAA), respectively. The intermediate metabolites L-dopa, 3-O-methyldopa and 5-hydroxytryptophan were also measured [6]. Total neopterin and biopterin (representing the sum of tetra-, dihydro-biopterin and biopterin) were measured by HPLC after oxidation with manganese dioxide [10].

5-MTHF was measured with HPLC using electrochemical detection. Separation was achieved on a 5 µ Sperisorb ODS-1, (250 × 4.6 mm) analytical column (Stagroma AG, Switzerland), using a 50 mmol sodium acetate in 22% (v/v) methanol, pH 4.5 as a mobile phase. The flow rate was 1 ml/min and the analytical cell (Model 5011, ESA, Bedford, MA, USA) was adjusted to + 0.20 V (ESA Coulochem Model 5100 A, ESA) with a response time of 2 s.

Age-matched median and range values for these metabolites were obtained from previous CSF analysis among healthy children of various age groups [7].

Routine CSF analysis included measurement of protein, glucose, lactate and cell counts. A simultaneous blood sample was drawn for a full haematologic screen and erythrocytic indices, determination of serum glucose, lactate, pyruvate, amino acids, homocysteine, vitamin B12 and measurement of folic acid in serum and red blood cells. The activity of 5,10-methylenetetrahydrofolate reductase was measured in leucocytes.

The procedures used were in accordance with the current revision of the Helsinki Declaration of 1975.

Genetic analysis of the FR 1 gene

Informed parental consent for DNA analysis could only be obtained from the parents of patients 2, 3 and 4.

The FR 1 gene maps to chromosome 11 q13.3-q13.5 and is composed of 7 exons spanning 6.7 kb, while the FR 2 gene maps to the same chromosome locus not more than 23 kb removed from the FR 1 gene [13]. The FR 2 gene comprises 5 exons. After isolation of genomic DNA from whole blood, DNA sequence analysis was performed on PCR products of about 250 bp derived from specific primers based on the genomic sequence of the intron-exon boundaries for the FR 1 gene, as reported previously [13,17]. The FR 1 derived folate binding protein-1 is the most important carrier of folate across the blood-brain barrier while the FR 2 protein binds poorly to folate [25]. Therefore, the current study only focussed on the FR 1 gene analysis.

Treatment protocol

After finding lowered 5-MTHF values in CSF, all patients have been followed up during a period of at least one year to a maximum of 3.4 years (Table **2**). Treatment consisted of a daily oral dose of 0.5 – 1 mg/kg body weight calcium folinic acid (Leucovorin®). Since side-effects of gastrointestinal upset and seizures have been mentioned for calcium folinate, clinical and EEG follow-up studies have been performed after 1, 3 and 6 months. A control lumbar puncture has been repeated between 4 months and 1.5 years after treatment with calcium folinic acid had been initiated. According to the change in CSF levels of 5-MTHF, fur-

ther dose adjustments of folinic acid substitution have been carried out.

Results

Blood and CSF analysis

All patients had normal results for haemoglobin content and erythrocytic indices, plasma levels of lactate, pyruvate, amino acids and homocysteine as well as serum concentrations of vitamin B12. Determination of 5,10-methylenetetrahydrofolate reductase activity in leucocytes was normal. Prior to folinic acid supplementation the folic acid concentrations in plasma for all patients were normal or elevated at 13.3, 11.3, > 45, 30 and > 47 nmol/l, respectively (normal range 4.1 – 20.4 nmol/l). Folic acid content within red blood cells was normal.

Routine CSF analysis showed normal cell count, glucose, protein and lactate values. However, CSF analysis showed diminished 5-MTHF concentrations (Table **2**). In patients 1, 4 and 5, slightly or moderately subnormal 5-MTHF values, found at the age of 1.7, 8.9 and 10.7 years, respectively, diminished on follow-up to lowered concentrations at the age of 3, 9.7 and 13.8 years.

Moreover, the CSF levels for the serotonin end-metabolite 5HIAA were also decreased in the presence of normal levels for the dopaminergic end-metabolite HVA, as well as the intermediate metabolites of the serotonergic and dopaminergic pathways. Consequently the ratio HVA/5HIAA became elevated. In patient 5, the decline of 5-MTHF coincided with a decrease of both the 5HIAA and HVA metabolites, so that the HVA/5HIAA ratio remained normal.

In all patients the neopterin values in CSF were moderately decreased or within the lower normal range. Except for one occasional low value in patient 1, the CSF levels for biopterin were completely normal. Since in patient 1 the CSF values for both neopterin and biopterin were decreased in the presence of normal values in plasma and urine, further tests (phenylalanine loading test, genetic DNA analysis) were performed which excluded GTP-cyclohydrolase-I deficiency [19, 20].

Results after folinic acid treatment

For patients 1 – 5, folinic acid was initiated and resulted in normalization of CSF values for 5-MTHF and 5HIAA after treatment over various periods of time. No adverse effects during folinic acid treatment have been observed. The positive clinical effects following treatment with folinic acid included disappearance of seizures and EEG spike-wave discharges (patients 1, 2, 4, 5), better control of equilibrium with less ataxia, improvement of postural control and intentional movements (patients 1, 2, 3, 4). Patient 3, who had developed a superimposed polyneuropathy, began to show an improved gait with return of the previously lost tendon reflexes of his lower limbs. A reduction of choreoathetosis and hyperexcitability with impulsive behaviour was observed in all patients. Patient 4 with documented blindness due to a central visual disturbance started to respond to visual stimuli and began to smile upon seeing his sisters after treatment for several months. Although all patients still remain retarded, partial recovery from the previously documented neurological abnormalities had coincided with folinic acid substitution.

Genetic analysis

The promotor region, open reading frame and intron-exon boundaries for the FR 1 gene in patients 2, 3 and 4 showed no abnormalities as determined by genomic DNA sequence analysis.

Discussion

The reported patients suffered from a neurological condition of postnatal onset which presented after the age of 6 months and shared the salient features of deceleration of head growth, marked irritability, psychomotor retardation, cerebellar ataxia, extrapyramidal dyskinesias and seizures (in 4 out of 5 patients). All patients acquired pyramidal signs in the lower limbs, whereas in the patient without documented seizures (patient 3) the tendon reflexes in the lower limbs were increased at first and then followed by evidence for development of a mixed sensorimotor neuropathy with loss of myelinated fibres and signs of degenerated myelin sheaths. In the two oldest patients (patients 4 and 5), a central visual disturbance was present. Except for patient 3 who also developed a polyneuropathy, the patient's clinical and biochemical features were identical. Therefore, we assumed a novel, recognizable neurometabolic condition, which responds to treatment with folinic acid.

The normal folic acid concentrations in plasma and red blood cells associated with lowered 5-MTHF concentrations in CSF suggested a disturbance of the active folic acid transport across the blood-brain barrier. The condition responded to oral folinic acid substitution which led to clinical amelioration and normal CSF 5-MTHF levels. To some extent, part of the neurological features of our patients were reminiscent of the clinical picture encountered in hereditary folate malabsorption, inborn errors of folate metabolism and nutritional folate deficiency [28].

An adequate folate pool is necessary for normal embryonic development, growth and maturation of the nervous system. Folates are involved in many processes like *de novo* purine synthesis and DNA replication. Together with cobalamin they subserve the methyl-transfer processes which are necessary to produce methionine and S-adenosylmethionine (SAM), the universal methyl-group donor. In the brain SAM acts in a number of biological methylation processes that modify proteins, nucleic acids, fatty acids, phospholipids and polysaccharides, while it also helps to inactivate biogenic monoamines [35].

Depletion of folate causes pernicious anaemia and demyelinating lesions of white matter around blood vessels in the brain and spinal cord [23]. The histopathology of demyelinating lesions in the spinal cord shows vacuolation of myelin sheaths of the posterior and lateral columns and often the anterior columns, which has been called subacute combined degeneration [1]. Since methyltetrahydrofolate is essential for the methyl-transfer pathways, it was suggested that compromised delivery of methyl-groups will lead to failure of methylation of arginine$_{107}$-myelin basic protein by the specific enzyme protein methylase I. Consequently, destabilization of myelin basic pro-

tein explains the inability to form compact myelin with subsequent disintegration of myelin sheaths [15]. Subacute combined degeneration of the brain and spinal cord has been demonstrated in two childen with inborn errors of metabolism causing intracellular methyltetrahydrofolate deficiency [5,8]. Hydrocephalus internus has also been reported recently in two infants with methylenetetrahydrofolate reductase deficiency [4]. It now appears established that a link exists between subacute combined degeneration and methyltetrahydrofolate deficiency due to either nutritional deficiency, malabsorption and inborn errors of metabolism [35].

Among our patients, the presence of both normal haematologic parameters with normal serum and red blood cell folate, serum vitamin B12, homocysteine and amino acids as well as normal 5,10-methylenetetrahydrofolate reductase activity in leucocytes excluded an underlying cause of systemic folate deficiency, inborn errors of folate metabolism, or hereditary folate malabsorption. Compared to the described patients with hereditary 5,10-methylenetetrahydrofolate reductase deficiency and other inborn errors of folate metabolism, the MRI of our patients did not manifest convincing evidence for internal hydrocephalus, delayed brain myelination, demyelination or subacute combined degeneration of the spinal cord. The normal development during the first 6 months together with normal AEPs followed by decelerating head growth and the late acquisition of central visual disturbance with prolonged latencies on VEP (patients 4,5), indicated that early development and myelination of the CNS and acoustic pathways had been normal for our patients. Our findings suggested that the development of folate depletion within the CNS started to become manifest only after the age of 4–6 months. Prior to treatment the CSF findings among patients 1, 4 and 5 demonstrated initially slightly or moderately lowered values followed by a decline of 5-MTHF levels with advancing age.

As mentioned above, two different mechanisms involve the transport of folates from plasma to the cell interior, as well as the folate transport across the placental, intestinal and blood-brain barriers [26,30,32,38]. A recent study [39] on the localization of the RFC1 by immunohistochemical analysis in mouse tissues showed that while RFC1 is expressed in the small intestine, the folate receptor protein is not. Other localizations of RFC1 were the basolateral surface of renal tubular epithelium, hepatocytes, splenic red pulp cells, neuronal axons and dendrites and the apical membrane of cells lining the spinal canal. In the choroid plexus RFC1 was highly expressed at the apical surface, while FR proteins were clustered at the basolateral surface of choroid epithelial cells which are interconnected by tight junctions to form the blood-CSF barrier [18,39]. Fig. **1** summarizes the mechanisms of active folate transport across the choroid plexus and indicates the vectorial transport of folates towards the cerebrospinal fluid compartment. Folate receptor proteins had a much more limited expression in various tissues but the choroid plexus consistently had the largest amounts of folate receptor, which could also be confirmed in humans [18]. Other tissues containing substantial amounts of folate receptor protein included the lung, thyroid and kidney. The liver, intestines, muscle, cerebellum, cerebrum and spinal cord were immunologically nonreactive. FR gene expression studies confirmed these observations [40].

These studies demonstrated that an intact RFC1 is needed for intestinal folate resorption as well as for the uptake of folates by neuronal axons and dendrites, while an intact choroid plexus with normal function of the FR 1 and FR 2 proteins is an essential prerequisite and largely determines the active folate transport from plasma to the cerebrospinal fluid compartment. In addition the efficient transfer of folates is also determined by intact endocytic pathways and potocytosis [24]. Finally, the intracellular storage of folates is accomplished through action of the enzyme folylpolyglutamate synthase by conversion of folate-monoglutamate through addition of glutamate units to produce folyl-hepta- and octaglutamates [3].

A disorder of folate transport across the choroid plexus has been described in an adult male with a slowly progressive neurological disease characterized by a cerebellar syndrome, distal spinal muscular atrophy, pyramidal tract dysfunction and perceptive hearing loss. Biochemical investigations showed low CSF folate with an unusually low immunoreactive FR protein whereas the binding of FR protein to radioactively labelled folate was unusually high. These findings suggested a defect in the choroid plexus folate receptor, causing disturbed transfer of folate across the choroid plexus [42].

Likewise, the normal serum folate concentrations in our patients associated with low 5-MTHF in CSF would suggest a genetic or non-genetic defect of either FR protein expression or function at the choroid plexus, a disturbed process of endocytosis/potocytosis within choroid epithelium or defective intracellular storage of folyl-hepta- and octaglutamates. The possibility of an anatomical malformation or damage to the choroid plexus was highly unlikely since neuro-imaging in this location was normal.

Gene knock-out experiments of the FR 1 gene among mice have shown severe early embryonic developmental anomalies of the nervous system affecting the FR 1 –/– embryos [25]. Supplementing pregnant heterozygous FR 1 +/– dams with folinic acid could prevent the developmental anomalies in the nullizygous pups. These results have suggested that the FR 1 gene plays a critical role in maternal-fetal transport of folate across the placental barrier and optimizes folate homeostasis during embryonic neurogenesis which is essential for neural tube closure [11,26]. Similar defects of the FR 1 gene have been confirmed in humans with neural tube defects [12]. Gene knock-out experiments of the FR 2 gene in mice resulted in nullizygous pups with a normal phenotype. Since the FR 2 protein binds poorly to folate, these FR 2 gene knock-out experiments in mice confirmed that only the intact FR 1 gene is necessary for efficient folate transfer during fetal and early nervous system development. In our patients FR 1 genetic analysis found normal sequences for the promotor region and open reading frame. Moreover, the absence of craniofacial anomalies, neural tube defects and intracranial calcifications and the presence of normal development during the first four to six months of life, excludes an embryonic developmental defect due to folate deficiency in the fetal stage but would indicate a postnatal onset of impaired folic acid transport to the nervous system [11,12,25]. Since extra folinic acid supplement in FR +/– dams has been shown to prevent embryonic defects, an adequate maternal reserve pool of folic acid in our patients with sufficient maternal-fetal transport of folates across

the placental barrier might have prevented the occurrence of early embryonic defects of morphogenesis. In our patients, the postnatal manifestation of the suspected folic acid transport defect is also supported by the absence of a central myelinization disorder on MR imaging, normal brainstem acoustic pathways, the onset of head growth deceleration after the age of 6 months as well as the observed decline of 5-MTHF levels which were documented in patients 1, 4 and 5. Although the coding sequence of the FR 1 gene was normal, the postnatal onset of a genetic regulatory defect of FR 1 gene expression or post-translational disturbed FR 1-protein modification cannot be ruled out. A systemic defect with disturbed endocytosis/potocytosis would be highly unlikely, since values for homocysteine and methionine in serum were normal. Diseases associated with enzyme deficiencies of folylpolyglutamate synthase or pteroyl polyglutamate hydrolase have not been described so far.

Another important issue was the fact that the lowered 5-MTHF values in CSF have been associated with a simultaneous decrease of the serotonin end-metabolite 5HIAA, which appears to be a secondary consequence of folate depletion in the nervous system. This observation is supported by the therapeutic effect of folinic acid substitution which led to normalization of 5HIAA values. Various studies in animals and observations in humans have confirmed that folate depletion in the central nervous system diminishes the turnover within the serotonergic and dopaminergic axis [16, 36, 44]. The reduced turnover of serotonin and dopamine due to folate depletion might be responsible to some extent for the psychomotor retardation, ataxia and behavioral changes, although a clear separation between the direct pathogenetic consequence of either folate deficiency or reduced biogenic amine turnover with respect to the present clinical features remains difficult. Our previously reported findings about 5 children with reduced serotonin synthesis documented a neurological syndrome of floppiness during infancy with motor delay, development of a hypotonic-ataxic syndrome, learning disability and short attention span [27]. The deceleration of head growth, behavioral changes, dyskinesia, pyramidal signs and late-onset visual disturbances seem to be the more direct consequences of folate depletion in the central nervous system, as suggested by the clinical picture in hereditary folate malabsorption and other disorders of folate metabolism [28].

We also observed a slightly or moderately lowered neopterin concentration in the presence of normal values for total biopterin which represents the sum of tetrahydrobiopterin, dihydro-biopterin and biopterin. However, these pterin values did not show a correlation with the 5-MTHF concentration. Because the *de novo* purine synthesis depends on two folate dependent enzymatic steps, folate depletion in the central nervous system would be expected to have a negative impact on the reserve pool of GTP which is the precursor for neopterin and tetrahydrobiopterin. This hypothesis needs further proof.

Treatment with folinic acid was necessary to obtain normal 5-MTHF levels in CSF.

Interpretation of these findings of impaired folic acid transport to the central nervous system responding to folinic acid treatment suggests that transport of folinic acid can only take place at plasma concentrations well above the physiological nanomolar range. The reduced folate carrier 1 is known to operate at these higher plasma levels, whereas the main mechanism of folate transport across the blood-brain barrier at normal physiological plasma concentrations will depend on the high-affinity uptake mechanisms exerted by the folate receptor protein 1 and 2 [30, 33, 34, 43]. As has already been pointed out above, the intestinal folate absorption appears to be intact, which proves normal RFC1 function. We hypothesize that the oral folinic acid substitution increased the serum folate concentrations after which efficient transfer to the brain became possible. The exact mechanism remains ill-understood until further clarification of the basic pathophysiology has shed more light on this interesting group of patients.

In summary, we assume that a genetic regulatory defect, a non-genetic dysfunction of the folate receptor protein or the endocytosis/potocytosis pathway becomes manifest six months after birth and will disturb folate transfer to the nervous system as reflected by a decline of CSF folate concentrations. Ultimately, postnatal folate-dependent growth and maturation of the central nervous system becomes compromised as can be noticed by the aggravating neurological features in our patients. The peripheral neuropathy in one patient was not a consistent finding of the described neurometabolic condition. Moreover, the lack of folate in the CSF seems to have an important influence on serotonin and dopamine turnover, although the interaction point still remains unclear. With folinic acid treatment normal 5-MTHF levels in CSF have been obtained, which seems to suggest a transfer defect of folate across the blood-brain barrier. To unravel this issue, further analysis of the FR genes and FR protein function as well as regulatory processes of folate receptor expression and folate transfer mechanisms will be necessary.

Acknowledgments

This work was supported in part by the Swiss National Science Foundation Grant no. 3100 – 066953.01 (to N. B.) and in part by the University Clinic Aachen START-program (to V. T. R.).

References

1 Adams RD, Kubik CS. Subacute degeneration of the brain in pernicious anemia. N Engl J Med 1944; 231: 1 – 9
2 Anderson RG, Kamen BA, Rothberg KG, Lacey SW. Potocytosis: sequestration and transport of small molecules by caveolae. Science 1992; 255: 410 – 411
3 Atkinson I, Garrow T, Brenner A, Shane B. Human cytosolic folylpoly-γ-glutamate synthase. Methods Enzymol 1997; 281: 134 – 140
4 Baethmann M, Wendel U, Hoffmann GF, Gohlich-Ratmann G, Kleinlein B, Seiffert P, Blom H, Voit T. Hydrocephalus internus in two patients with 5,10-methylenetetrahydrofolate reductase deficiency. Neuropediatrics 2000; 31: 314 – 317
5 Beckman DR, Hoganson G, Berlow S, Gilbert EF. Pathological findings in 5,10-methylenetetrahydrofolate deficiency. Birth Defects 1987; 23: 47 – 64
6 Blau N, Thöny B, Renneberg A, Penzien JM, Hyland K, Hoffmann G. Variant of dihydropteridine reductase deficiency without hyperphenylalaninemia: Effect of oral phenylalanine loading. JIMD 1999; 22: 216 – 220

[7] Blau N, Duran M, Blaskovics M (eds). Physician's Guide to Laboratory Diagnosis of Metabolic Diseases. Chapter 2: Hyland K et al. Disorders of Neurotransmitter Metabolism. London: Chapman and Hall, 1996: 79 – 98
[8] Clayton PT, Smith I, Harding B, Hyland K, Leonard JV, Leeming RJ. Subacute combined degeneration of the cord, dementia and Parkinsonism due to an inborn error of folate metabolism. J Neurol Neurosurg Psychiatr 1986; 49: 920 – 927
[9] Corbeel L, Van den Berghe G, Jaeken J et al. Congenital folate malabsorption. Eur J Pediatr 1985; 143: 284 – 290
[10] Curtius HC, Blau N, Kuster T. Pterins. In: Hommes FA (ed). Techniques in Diagnostic Human Biochemical Genetics. New York: Wiley-Liss, 1991: 377 – 396
[11] Czeizel AE, Dudas I. Prevention of the first occurrence of neural tube defects by periconceptional vitamin supplementation. New Eng J Med 1992; 327: 1832 – 1835
[12] De Marco P, Moroni A, Merello E et al. Folate pathway gene alterations in patients with neural tube defects. Am J Med Genet 2000; 95: 216 – 223
[13] Elwood PC, Nachmanoff K, Saikawa Y et al. The divergent 5′ termini of the alpha human folate receptor (hFR) mRNAs originate from two tissue-specific promotors and alternative splicing: characterization of the alpha hFR Gene structure. Biochemistry 1997; 36: 1467 – 1478
[14] Fan J, Vitols KS, Huennekens FM. Multiple folate transport systems in L 1210 cells. Adv Enzyme Regul 1992; 32: 3 – 15
[15] Ghosh SK, Syed SK, Jung S, Paik WK, Kim S. Substrate specificity for myelin basic protein-specific protein methylase I. Biochim Biophys Acta 1990; 1039: 142 – 148
[16] Gospe SM, Gietzen DW, Summers PJ et al. Behavioral and neurochemical changes in folate-deficient mice. Physiol Behav 1995; 58: 935 – 941
[17] Heil SG, Van der Put NMJ, Trijbels FJM et al. Molecular genetic analysis of human folate receptors in neural tube defects. Eur J Hum Gen 1999; 7: 393 – 396
[18] Holm J, Hansen SI, Hoier-Madsen M, Bostad L. High-affinity folate binding in human choroid plexus. Biochem J 1991; 280: 267 – 271
[19] Hyland K, Fryburg JS, Wilson WG et al. Oral phenylalanine loading in dopa-responsive dystonia: a possible diagnostic test. Neurology 1997; 48: 1290 – 1297
[20] Ichinose H, Ohye T, Matsuda Y et al. Characterization of mouse and human GTP cyclohydrolase I gene mutations in patients with GTP cyclohydrolase I deficiency. J Biol Chem 1995; 270: 10 062 – 10 071
[21] Kamen BA, Capdevila A. Receptor–mediated folate accumulation is regulated by the cellular folate content. Proc Natl Acad Sci USA 1986; 83: 5983 – 5987
[22] Kane MA, Elwood PC, Portillo RM, Antony AC, Najfeld V, Finley A, Waxman S, Kolhouse JF. Influence on immunoreactive folate-binding protein of extracellular folate concentration in cultured human cells. J Clin Invest 1988; 81: 1398 – 1406
[23] Lever EG, Elwes RDC, Williams A, Reynolds EH. Subacute combined degeneration of the cord due to folate deficiency: response to methyl-folate treatment. J Neurol Neurosurg Psychiatr 1986; 49: 1203 – 1207
[24] Mineo C, Anderson RGW. Potocytosis. Robert Feulgen lecture. Histochem Cell Biol 2001; 116: 109 – 118
[25] Piedrahita JA, Oetama B, Bennett GD, van Waes J et al. Mice lacking the folic acid-binding protein Folbp1 are defective in early embryonic development. Nature genetics 1999; 23: 228 – 232
[26] Prasad PD, Ramamoorthy S, Moe AJ et al. Selective expression of the high-affinity isoform of the folate receptor (FR-alpha) in the human placental syncytiotrophoblast and choriocarcinoma cells. Biochim Biophys Acta Molecular Cell Res 1994; 1223: 71 – 75
[27] Ramaekers V Th, Senderek J, Häusler M et al. A novel neurodevelopmental syndrome responsive to 5-hydroxytryptophane and carbidopa. Mol Genet Metab 2001; 73: 179 – 187
[28] Rosenblatt D. Inherited disorders of folate transport and metabolism. In: Scriver CR, Beaudet AL, Sly WS, Valle D (eds). The Metabolic and Molecular Basis of Inherited Disease. 7th ed. New York, NY: McGraw-Hill, 1995: 3111 – 3128
[29] Rothberg KG, Ying Y, Kolhouse JF et al. The glycophospholipid-linked folate receptor internalizes folate without entering the clathrin-coated pit endocytotic pathway. J Cell Biology 1990; 110: 637 – 649
[30] Said HM, Nguyen TT, Dyer DL et al. Intestinal folate transport: identification of a cDNA involved in folate transport and the functional expression and distribution of its mRNA. Biochim Biophys Acta Biomembranes 1996; 1281: 164 – 172
[31] Selhub J. Folate binding proteins. Mechanism for placental and intestinal uptake. In: Allen L, King J, Lönnerdal B (eds). Nutrient Relation During Pregnancy, Lactation and Infant Growth. New York: Plenum Press, 1994;: 141 – 149
[32] Shen F, Ross JF, Wang X et al. Identification of a novel folate receptor, a truncated receptor, and receptor type beta in hematopoietic cells – cDNA cloning, expression, immunoreactivity and tissue specificity. Biochemistry 1994; 33: 1209 – 1215
[33] Spector R, Lorenzo A. Folate transport in the central nervous system. Am J Physiol 1975; 229: 777 – 782
[34] Spector R. Micronutrient homeostasis in mammalian brain and cerebrospinal fluid. J Neurochem 1989; 53: 1667 – 1674
[35] Surtees R. Biochemical pathogenesis of subacute combined degeneration of the spinal cord and brain. JIMD 1993; 16: 762 – 770
[36] Surtees R, Heales S, Bowron A. Association of cerebrospinal fluid deficiency of 5-methyltetrahydrofolate, but not S-adenosylmethionine, with reduced concentrations of the acid metabolites of 5-hydroxytryptamine and dopamine. Clin Sci (Colch) 1994; 86: 697 – 702
[37] Urbach J, Abrahamor A, Grossowicz N. Congenital isolated folic acid malabsorption. Arch Dis Child 1987; 62: 78 – 80
[38] Wang TTY, Chandler CJ, Halsted CH. Intracellular pteroylpolyglutamate hydrolase from human jejunal mucosa: isolation and characterization. J Biol Chem 1986; 261: 13 551 – 13 555
[39] Wang Y, Zhao R, Russell RG, Goldman ID. Localization of the murine reduced folate carrier as assessed by immunohistochemical analysis. Biochim Biophys Acta 2001; 1513: 49 – 54
[40] Weitman SD, Lark RH, Coney LR, Fort DW, Frasca V, Zurawski VR, Kamen BA. Distribution of the folate receptor GP38 in normal and malignant cell lines and tissues. Cancer Res 1992; 52: 3396 – 3401
[41] Weitman SD, Weinberg AG, Coney LR et al. Cellular localization of the folate receptor: potential role in drug toxicity and folate homeostasis. Cancer Res 1992; 52: 6708 – 6711
[42] Wevers RA, Hansen SI, Hubar JLMV et al. Folate deficiency in cerebrospinal fluid associated with a defect in folate binding protein in the central nervous system. J Neurol Neurosurg Psychiatr 1994; 57: 223 – 226
[43] Wu D, Pardridge WM. Blood-brain barrier transport of reduced folic acid. Pharm Res 1999; 16: 415 – 419
[44] Young SN. The 1989 Borden Award Lecture. Some effects of dietary components (amino acids, carbohydrate, folic acid) on brain serotonin synthesis, mood, and behavior. Can J Physiol Pharmacol 1991; 69: 893 – 903