

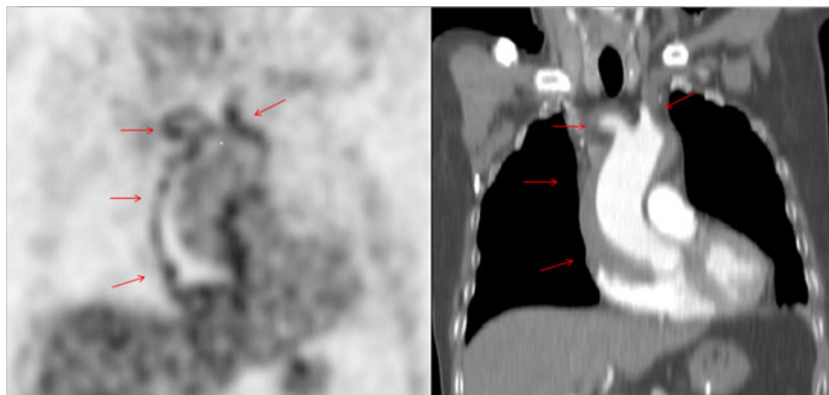
Acute intramural haematoma of the ascending aorta

L. Govaerts · N. Withofs · R. Durieux · V. Spote ·
R. Hustinx

Received: 13 February 2012 / Accepted: 20 March 2012
© Springer-Verlag 2012

A 77-year-old man with a history of mantle cell lymphoma underwent a FDG PET/CT to explore fever and chest pain. A diffuse high FDG uptake is seen within the wall of the enlarged ascending aorta extending from the aortic valve to the brachiocephalic, right subclavian and left common carotid arteries. A photopenic area in the ascending aorta, best seen on the coronal view, suggests the presence of an intramural haematoma. The study is thus consistent with the diagnosis of acute intramural haematoma of the ascending aorta, which was confirmed by echo Doppler, angio-CT and histological examination.

Acute intramural haematoma is considered as a variant of aortic dissection. It can evolve to stabilization and resolution or progress towards classical aortic dissection, development of ulcer-like projections of the aorta, and formation of an aortic aneurysm. Because of this unpredictable evolution, guidelines for its treatment are not clear [1]. Increased FDG uptake by acute intramural haematoma has been reported [2, 3], but it is not known whether such increased uptake is associated with a higher risk of rupture and progression, as shown by PET studies in type-B aortic dissection [4].



L. Govaerts (✉) · N. Withofs · R. Durieux · V. Spote · R. Hustinx
CHU Sart-Tilman,
Liège, Belgium
e-mail: laurencegovaerts@hotmail.com

References

1. Chao CP, Walker TG, Kalva SP. Natural history and CT appearances of aortic intramural hematoma. *Radiographics*. 2009;29(3):791–804.
2. Ryan A, McCook B, Sholosh B, Pryma DA, Jablonowski E, Fuhrman C, et al. Acute intramural hematoma of the aorta as a cause of positive FDG PET/CT. *Clin Nucl Med*. 2007;32(9):729–31.
3. Kuehl H, Eggebrecht H, Boes T, Antoch G, Rosenbaum S, Ladd S, et al. Detection of inflammation in patients with acute aortic syndrome: comparison of FDG-PET/CT and serological markers of inflammation. *Heart*. 2008;94(11):1472–7.
4. Kato K, Nishio A, Kato N, Usami H, Fujimaki T, Murohara T. Uptake of ¹⁸F-FDG in acute aortic dissection: a determinant of unfavorable outcome. *J Nucl Med*. 2010;51(5):674–81.