

# Implantation of Esterified Hyaluronic Acid in Microdissected Reinke's Space After Vocal Fold Microsurgery: Short-and Long-Term Results

Camille L. Finck, †Bernard Harmegnies, \*Angélique Remacle, and \*Philippe Lefebvre, \*Liège, and †Bruxelles, Belgium

**Summary:** In this study are reported the laryngeal and vocal results obtained after a microflap excision of benign vocal fold (VF) lesions and immediate implantation of esterified hyaluronic acid (EHA) in the surgical wound. In a previous pilot study on 11 cases, we have shown an excellent tolerance of this bioimplant. The objectives are to confirm the innocuity of the technique, to demonstrate the laryngeal and vocal evolution at short and long term, and to evaluate the eventual positive impact of EHA implantation on the pliability of the superficial layer of the lamina propria (SLLP) and on voice. This is a Prospective and comparative study on 83 patients suffering from various benign VF lesions. Thirty-three patients were implanted with EHA, whereas 50 patients did not undergo implantation at the end of the microsurgical procedure. All patients undergo rigid laryngoscopy and microflap excision procedure under general anesthesia. After freeing up of the Reinke's space and creation of a mucosal microflap, a few fibers of EHA are inserted in the surgical wound, before closure of the incision with fibrin glue. Serial laryngeal and vocal assessments are performed in all patients using videostroboscopy (Wolff and Xion), perceptual and objective voice evaluation (*MDVP software*, Kay Elemetrics), and phonatory function measurements (Aerophone II). Pre- and early postoperative means are compared by analysis of variance. Delayed and long-term evolution of laryngeal and vocal data are compared by means of nonparametric statistical methods. The longest follow-up in the implanted group is 4 years. Early postoperative results are similar in both groups: a significant improvement of a majority of laryngeal and vocal data is observed after microsurgery. In the long term, the two groups exhibit a different behavior: further improvement of voice, as an ongoing process, is only observed in the EHA implanted group, together with improvement of some videostroboscopic characteristics. The non-implanted group remains stable, with no further improvement of the voice quality obtained after microsurgery. Excellent short- and long-term tolerance of EHA implantation is confirmed by this larger series. The use of EHA implant in microdissected SLLP is safe and leads to good laryngeal and vocal outcomes in the treated patients. More interestingly, treated cases exhibit a continuous improvement over a long period of time.

**Key Words:** Hyaluronic acid–Esterified hyaluronic acid–Reinke's space–Vocal fold microsurgery–Voice evaluation–Healing modulation.

## INTRODUCTION

Microsurgical procedures for benign VF lesions aim at improving the mechanical properties of the laryngeal vibrator. Restoring a good pliability of the SLLP is essential. In normal VFs, the SLLP, also called Reinke's space, demonstrates favorable biomechanical properties in terms of viscosity and stiffness thanks to its cellular and molecular composition: few fibroblasts and macrophages are surrounded by a very loose elastic and collagen fibrous scaffolding and by interstitium molecules of the extracellular matrix (ECM). Among these molecules, an equilibrium between glycosaminoglycans, such as hyaluronic Acid (HA) and decorin, and glycoproteins, such as fibronectin, is necessary to maintain the "jelly-like" structure favorable to vibration. HA is a high-molecular-weight glycosaminoglycan, which is a normal component of the ECM everywhere in the human body. Because of its molecular structure and binding to

a large amount of water molecules, HA plays an important role in determining the mechanical characteristics of the SLLP.<sup>1</sup> It influences the thickness of the lamina propria (LP): men possess a thicker LP compared with that of women, and this could be due to a three- to fourfold amount of HA in the men's LP.<sup>2</sup> HA is necessary to maintain both optimal viscosity and stiffness of SLLP. The removal of HA from the SLLP of human cadavers increases the tissue viscosity by two- to fourfold.<sup>3</sup> Stiffness of the SLLP is also influenced by the amount of HA present: removal of HA from the LP of adult human cadavers decreases the stiffness of the VF cover by an average of 35% but increases dynamic viscosity by 70%.<sup>4</sup> Decreased stiffness leads to unstable vibratory rate, whereas increased viscosity reduces pliability and, hence, mucosal cover traveling wave. However, one of the very interesting characteristics of HA is its influence on cell behavior and regulation of wound repair and of morphogenetic events. Previous studies have shown that HA influences collagen deposition: high levels of HA reduce scar tissue formation with less fibrosis and less contracture.<sup>5</sup>

This clinical work has been initiated because our 20 years' experience in VF microsurgery has made us aware of the difficulty in obtaining good pliability of the mucosal cover when treating rigid and/or destructive lesions of the SLLP. Careful microflap procedures for lesions such as very rigid nodules, extensive and fibrotic intracordal hemorrhages, deep intracordal

Accepted for publication December 31, 2008.

Presented at the 36th Voice Foundation's Symposium: "Care of the Professional Voice," Philadelphia, 29 May–3 June 2007.

From the \*Department of Otorhinolaryngology, University of Liège, Liège, Belgium; and the †Speech Sciences Laboratory, Académie Universitaire Wallonie-Bruxelles, Bruxelles, Belgium.

Address correspondence and reprint requests to Camille L. Finck, Department of Otorhinolaryngology, CHU Sart Tilman, University of Liège, Boulevard de l'Hôpital, B-4000 Liège, Belgium. E-mail: [Camille.finck@chu.ulg.ac.be](mailto:Camille.finck@chu.ulg.ac.be)

Journal of Voice, Vol. ■, No. ■, pp. 1-10

0892-1997/\$34.00

© 2008 The Voice Foundation

doi:10.1016/j.jvoice.2008.12.015

cysts, and destructive lesions such as scars or sulci do not always succeed in restoring the pliability of the mucosal cover. Because of the favorable and important biological and mechanical roles played by HA in normal SLLP, we decided to investigate the use of a HA derivative bioimplant in selected surgical cases. Previous animal studies showed that levels of HA are decreased in injured VF in the early days after injury, and the authors believe that low HA level produces a less than optimal environment for normal tissue regeneration and might contribute to formation of scar tissue.<sup>6</sup> We hypothesized that increasing HA in the wound would contribute to less collagen deposition, less wound contracture, and possibly enhanced pliability of the mucosal cover. Therefore, implantation of exogenous modified HA in the surgical wound aims at playing the role of a spacer between the elevated mucosal flap and the deeper layers of the lamina propria and at modulating the healing and tissue repair processes by raising the local amount of HA. The implant should be resorbable in order to play only a temporary role. The implant needs to create favorable healing conditions inside the SLLP, and these conditions are fulfilled by an increased amount of HA present in the surgical wound as well as by the creation of a highly hydrated matrix favorable to the fibroblastic migration. We chose to use a well-known material initially dedicated to ear, nose, and throat (ENT) surgery: the resorbable bioimplant is made of EHA, commercially known as MeroGel (Medtronic, Xomed, Jacksonville, Florida, USA). This implant is usually used in sinus and otologic surgery to reduce adhesions and scarring processes of the surgical bed.

In a previous pilot study on 11 cases, we have shown an excellent tolerance of this bioimplant made of EHA placed under the mucosal flap, in the Reinke's space, following a microsurgical procedure for a benign VF lesion: no adverse reaction was observed during a time of follow-up comprising between 8 weeks and 19 months.<sup>7</sup> Also, excellent pliability of the mucosal cover is obtained postoperatively, particularly in cases where mucosal stiffness was extremely important preoperatively.

The good results obtained in these first clinical experiences needed to be confirmed by larger series and long-term follow-up. The goals of the actual clinical study are as follows: 1) to confirm the innocuity of the technique, 2) to demonstrate the laryngeal and vocal evolution at short and long term, and 3) to

evaluate the eventual positive impact of EHA implantation, on the voice evolution after VF microsurgery.

## MATERIAL AND METHODS

### Study Design

This clinical study is prospective and comparative but not randomized: selection criteria for implantation of EHA are used, and surgical results obtained in the implanted group are compared to those obtained in a nonimplanted group.

Eighty-three subjects are included in the study and undergo a microsurgical treatment of benign VF lesions. Thirty-three cases benefit from immediate implantation of a resorbable bioimplant made of EHA in the surgical wound. Fifty cases do not undergo implantation at the end of the microsurgical procedure. Selection of cases for implantation is based on lesion characteristics:

- Presurgical lesional absence of pliable SLLP: cases of vergeture, scar, subepithelial fibrosis, and sulcus
- Partial replacement of pliable SLLP by fibrotic tissue: cases of rigid nodules, fibrotic polyps, and organized intracordal hemorrhage, cysts surrounded by fibrosis
- Estimated higher risk of scar, due to the difficulty of dissection in some cases

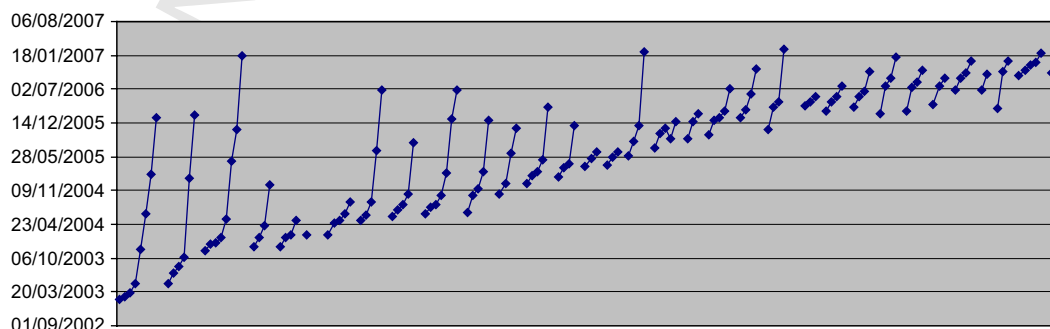
The laryngeal and vocal data obtained in both groups are compared.

All of the patients undergo a serial follow-up. The laryngeal and vocal data obtained are carefully stored and submitted to statistical analysis.

Graph 1 shows the follow-up of the implanted group. Each lozenge represents a clinical evaluation. One preoperative evaluation and several postoperative ones are obtained for each case. The number of postoperative evaluations depends on the moment of microsurgery and on the patient's compliance with the appointments, the first treated cases very logically exhibiting a larger number of postoperative checkups. The longest follow-up is 4 years.

### Subjects

The implanted group. The implanted group is composed of 33 patients (six edemas, five mucous cysts, four polyps, six



**GRAPH 1.** Serial follow-up of the implanted group. Each lozenge represents a clinical evaluation: one preoperative and several postoperative ones are obtained for each patient.

nodules, one sulcus, two scars, two subepithelial fibrosis, three vergetures [two with mucosal bridge], and four open cysts) who underwent a VF microsurgical procedure and implantation of EHA between February 2003 and December 2006. Twenty-three are females (70%), and 10 are males (30%). Twenty percent had microsurgery on the left VF, 59% on the right VF, and 21% had a bilateral procedure. In 18%, CO<sub>2</sub> laser was used for the incision of the VF surface; the other cases were treated only with cold instrumentation (Table 1).

Eight patients benefited from a bilateral implantation. The first 11 cases included in our pilot study are part of this larger series.

**The nonimplanted group.** The nonimplanted group is composed of 50 patients (12 edemas, 4 mucous cysts, 14

polyps, 7 nodules, and 13 pseudocysts) who underwent a VF microsurgical procedure without subsequent implantation of EHA between January 2004 and February 2007. Thirty-eight are females (76%), and 12 are males (24%). Twenty-six percent had microsurgery on the left VF, 34% on the right VF, 40% had a bilateral procedure. In 20%, CO<sub>2</sub> laser was used for the incision of the VF surface; the other cases were treated only with cold instrumentation (Table 1).

The composition of the two groups (Table 1) is homogeneous concerning the sex (Chi-square = 0.405, df = 1, *P* = 0.524), the side of microsurgery (Chi-square = 5.45, df = 2, *P* = 0.06), and the use of laser (Chi-square = 0.07, df = 1, *P* = 0.78).

The distribution of the clinical diagnosis of VF lesions (Table 1) is inhomogeneous (Chi-square = 34.51, df = 11, *P* = 0.0003).

**TABLE 1.**  
**Composition of the Implanted and Nonimplanted Group**

	Implanted Group		Nonimplanted Group		Chi Square
Subjects	N = 33		N = 50		
Sex	23 women (70%) 10 men (30%)		38 women (76%) 12 men (24%)		0.405 ( <i>P</i> = 0.524)
Vocal fold lesion	6 edemas 4 intracordal hemorrhages 5 mucous cysts 6 nodules 1 sulcus 2 scars 3 vergetures 2 subepithelial fibrosis 4 open cysts		12 edemas 14 polyps 4 mucous cysts 7 nodules 13 pseudocysts		<b>34.51 (<i>P</i> = 0.0003)</b>
Side of microsurgery	Left (20%), Right (59%), bilateral (21%)		Left (26%), Right (34%), bilateral (40%)		5.45 ( <i>P</i> = 0.06)
Grade (G)	N	Preoperative mean	N	Preoperative mean	Student's <i>t</i> test
Roughness (R)	32	2.593	50	2.020	<b>-3.55 (<i>P</i> = &lt;0.001)</b>
Breathiness (B)	32	1.562	50	1.260	-1.54 ( <i>P</i> = 0.12)
Asthenia (A)	32	0.562	50	0.560	-0.01 ( <i>P</i> = 0.98)
Strain (S)	32	2.062	50	1.400	<b>-2.45 (<i>P</i> = 0.01)</b>
Instability (I)	32	2.500	50	1.940	<b>-2.98 (<i>P</i> = 0.003)</b>
Glottic closure	31	3.751	47	3.487	-0.98 ( <i>P</i> = 0.32)
Left amplitude	12	1.841	31	2.074	0.30 ( <i>P</i> = 0.76)
Left mucosal wave	12	1.425	32	5.065	<b>3.27 (<i>P</i> = 0.002)</b>
Right amplitude	24	1.491	34	2.640	<b>2.34 (<i>P</i> = 0.02)</b>
Right mucosal wave	24	1.845	32	6.606	<b>4.94 (<i>P</i> = &lt;0.001)</b>
Jitter %	32	2.935	50	2.432	-1.12 ( <i>P</i> = 0.26)
F0 range (semi-tones)	32	6.427	50	5.896	-0.43 ( <i>P</i> = 0.66)
STD (F0)	33	9.818	50	11.435	0.37 ( <i>P</i> = 0.70)
NHR	32	0.158	50	0.157	-0.01 ( <i>P</i> = 0.98)
Shimmer %	32	5.140	50	5.381	0.25 ( <i>P</i> = 0.80)
MPT (s)	18	10.226	37	11.780	1.03 ( <i>P</i> = 0.30)
MFR (L/s)	19	0.217	37	0.257	0.94 ( <i>P</i> = 0.34)
Intraoral pressure (cm H <sub>2</sub> O)	19	10.770	36	10.711	2.26 ( <i>P</i> = 0.95)

Preoperative means of the laryngeal and vocal variables. Significant *P* values are highlighted in bold.

Abbreviations: STD, standard deviation; NHR, noise-to-harmonic ratio; MPT, maximum phonation time; MFR, mean flow rate.

## Bioimplant

The commercially available EHA presents as a solid, fiber material made of an EHA or HYAFF (Fidia Advanced Biopolymers, Abano, Terme, Italy). The HA is a fermentation product from *Streptococcus Equii*. The HA was then esterified on the carboxyl group of the glucuronic acid moiety of the polymer with benzyl alcohol. The EHA implant used in this study is HYAFF 11 (MeroGel), a 20 kDa molecule, in which 100% of carboxyl groups of HA is esterified with benzyl alcohol and is a registered trade mark of Medtronic Xomed, Jacksonville, FL. When placed in contact with the human body fluids, the implant transforms into a highly hydrated gel. HYAFF polymers are biodegradable and follow a well-characterized metabolic pathway: first occurs the hydrolysis of the ester bond, releasing free benzyl alcohol and soluble HA. The HA from the de-esterification of HYAFF is indistinguishable from that of natural origin and undergoes the same metabolic pathways: it is degraded locally by binding to a CD44 receptor on the cell membrane of fibroblasts and macrophages, cellular internalization, and finally destruction in the lysosome by hyaluronidase.<sup>1</sup> The free benzyl alcohol is degraded in the liver in benzoic acid and then conjugated with glycine, to produce hippuric acid, which is excreted in the urine.

## Procedure

All patients undergo general anesthesia and routine laryngeal intubation (tracheal tube size: 5.5–6.5). A direct laryngoscopy is performed in all patients (Kleinsasser type laryngoscope, Storz 8590C and 8590B). The microsurgical procedure is performed under 40× magnification, with a 400 mm focal length (Microscope Leica M655), which corresponds to a real magnification of 10×. The cordal lesion is treated either with cold instrumentation only (Bouchayer instrumentation from MicroFrance and mini-microinstrumentation for laryngeal surgery from Stöpler) or with CO<sub>2</sub> Laser (Sharplan 40C).

All microsurgical procedures are done by the first author.

In both groups, the surgical procedures are identical, except for the use of the bioimplant of EHA: a microflap procedure is performed in all cases (both implanted and nonimplanted cases) except in polyps of small size that are resected as a whole.

We describe here our microsurgical procedures: lesion treatment, implantation of EHA (in the implanted group), and closure of the incision.

**Lesion treatment.** In the case of nodules, the procedure consisted in a subepithelial cleaning of the nodular SLLP with no or a minimal epithelial superficial resection to close the incision perfectly.

In the case of a mucosal bridge associated to a vergeture, the procedure is complex: the adherent epithelium is completely resected during the creation of a mucosal flap, and then the mucosal bridge is sliced longitudinally to preserve the external half of its mucosal cover. This allows to have at one's disposal an "accessory" mucosal flap, to close the incision with less tension and less concavity of the VF's free edge.

For the patients with Reinke's edema and pseudocysts, after suctioning of the submucosal edema, care was taken not to

sacrifice too large an amount of mucosa in order to be able to close the incision without any or minimal superficial defect.

Sessile polyps and intracordal hemorrhages are treated by a subepithelial cleaning of the SLLP of all the fibrin and fibrotic reaction. Polyps of small size or pediculated are more simply resected as a whole.

Scars and subepithelial fibrosis are treated by an elevation of the adherent epithelium from the ligament, creating a mucosal flap under which EHA can be inserted.

Mucous and epidermoid cysts are resected by a mini-microflap technique.

**Implantation of EHA.** The EHA implant is not an injectable material but a solid material, macroscopically resembling cotton-ball fibers. A few fibers of EHA bioimplant are taken with the microforceps and gently arranged in Reinke's space between the ligament and the mucosal flap. The mucosal flap is then redraped over the underlying EHA implant.

**Closure of the incision.** At the end of all microflap procedures (both in implanted and nonimplanted patients), we use fibrin glue (Tissucol DUO 500, 0.5 mL, Baxter, Deerfield, Illinois, USA). With a blunt dissector of Bouchayer, a drop of "glue" (human fibrinogen, fibronectin, plasminogen, and factor XIII) is delicately placed in the incision, followed immediately by a second drop of thrombin. A small external pressure is applied on the treated VF during 5 seconds, permitting a partial polymerization of the glue. This allows a stable position of the microflap and perfect closure of the incision.

**Postoperative care.** Postoperatively, all patients were advised to adhere to a vocal rest for 8 days. Preoperatively, they received a 125 mg IV injection of methylprednisolone. Medical postoperative treatment consisted of degressive oral methylprednisolone, clobutinol hydrochloride, and paracetamol. The implanted group received amoxy-clavulanate for 1 week to prevent infection of the implant.

## Laryngoscopic Examination

All patients undergo a general ENT clinical examination. For each patient, one preoperative and several postoperative video-laryngo-stroboscopies are obtained. We use a Wolff rigid 70° endoscope 4450.47 connected to a Wolff laryngostroboscope 5052 or Xion's EndoSTROB digital camera. Archiving of the videostroboscopic views is done with an Olympus camera Visera OTV-57 and video-recorder Panasonic AG-5700 or with Xion's DiVAS software. Topical anesthesia of the pharynx (xylocaine 10% spray) is used. The patients are asked to sustain an [i] at different pitches.

Amplitude of vibration and of mucosal wave as well as symmetry, inflammation, presence of a glottic gap, and of VF deformation are the videostroboscopic findings that are taken into account. Amplitude of vibration, mucosal wave, and glottic gap are evaluated on analogic visual scales. For amplitude vibration and mucosal wave, we use a bipolar scale: amplitude of vibration is considered normal if noted at half the continuum, increased to the right and decreased to the left. For mucosal wave, the scale is unipolar (normal at the right end, completely



absent at the left end). It is also the case for glottic closure (complete at the right end, absent at the left end).

Pliability of VF cover observed at the level of the lesion is the most important videostroboscopic characteristic to be evaluated pre- and postoperatively. In order to avoid confusion and statistical bias, only the data of the microsurgically treated VFs are included in the study.

In this prospective study, the microsurgeon is not blinded to the situation of his patients. To reduce evaluation bias, videostroboscopic examinations are rated by two otolaryngologists (one of them is the microsurgeon) and one experienced speech therapist via group discussion and consensus.

### Voice Evaluation

The voices are recorded in a soundproof booth on a Kay Elemetrics Computerized Speech Lab with a Kay Elemetrics head-mounted microphone. The distance between the mouth and the microphone is approximately 3 cm. Three sustained vowels /a/ and five standardized texts for French are recorded at each visit.

We use the GRBASI scale for the subjective evaluation of the patient's voice quality, after listening to the five productions of the standardized texts: G (grade), R (roughness), B (breathiness), A (asthenia), S (strain), and I (instability). Each item was quoted 0 (normal), 1 (light), 2 (moderate), and 3 (severe). As for the videostroboscopic examinations, evaluation is not performed in a blinded fashion, and a group discussion is, therefore, performed by two otolaryngologists and one experienced speech therapist, until consensus is reached.

Software from Kay Elemetrics, Multi-Dimensional Voice Program (MDVP) is used to obtain voice quality objective data. Measurements of average fundamental frequency (Average F0), of highest and lowest fundamental frequency, standard deviation of F0 (STD), phonatory F0-range (PFR), jitter % (Jitt %), and noise-to-harmonic ratio (NHR) are derived from 3 second segments of each of the sustained /a/.

### Phonatory Function Measurements

Measurements of maximum phonation time (MPT), intraoral pressure, and mean flow rate (MFR) are realized by the use of Aerophone II.

### Preoperative Data

Mean values of both groups are compared by Student's *t* test, which shows some significant differences between the two groups. Subjective voice ratings G, R, S, I are significantly higher in the preoperative period, whereas the mucosal waves and the right amplitude of vibration are significantly lower, in the patients who will benefit from EHA implantation. All the other obtained data show no significant difference in the preoperative period, between the implanted and the nonimplanted group (Table 1).

### Statistical Analysis

**Early postoperative data: short-term outcome.** Early postoperative means obtained in both groups were

compared by analysis of variance, (SPSS software, GLM<sub>Q10</sub> procedure, repeated measures): the dependent variable was the data under study; the independent variables were the group and the time of examination (preoperative or early postoperative data). The subjects were nested into the groups.

### Delayed and Long-Term Outcome

Evaluation of laryngeal and vocal modifications with the passage of time after microsurgery is one of our goals, as we expect a different tissue remodeling in the two groups. Serial follow-up is mandatory to demonstrate an eventual positive effect of the implantation of EHA in the microdissected SLLP.

The number and the moment of the postoperative evaluations being variable from one patient to another, we decided to use correlation criteria (nonparametric statistical analysis).

In this section, we decided not to take into account the immediate postoperative results but the data obtained at least at the second postoperative consultation and all the following ones. Because of the highly variable moments of the postoperative appointments at our Voice Clinic, we took into consideration the number of days elapsed since microsurgery. We used the correlation criteria of Kendall and Spearman to show a possible correlation between the value of the different variables measured in our patients and the time elapsed since the VF microsurgery. The significance level is  $P < 0.05$ .

## RESULTS

### Early Postoperative Results: Short-Term Outcome

The first postoperative data were obtained between 1 and 6 weeks after the VF microsurgery, although the patients were advised to present at the Voice Clinic 2 weeks after surgery.

An analysis of variance allows a between-time and between-group comparison. The Fisher Snedecor *F* values and *P* values are presented in Table 2. For each variable, two Fisher-Snedecor statistics compare (1) the pre- and the postoperative means and (2) the pre- and postoperative means and group interaction. The level of significance is  $P < 0.05$ . Significant *P* values are highlighted in bold.

- (1) All videostroboscopic and voice data are significantly modified by the microsurgical procedure except NHR ( $P = 0.09$ ), Average F0 ( $P = 0.840$ ), and Asthenia (A) ( $P = 0.191$ ). We observe a postoperative significant decrease in G, R, B, S, I, jitter %, PFR, STD of F0, MFR, and of the subglottic pressure. A postoperative increase in glottic closure ( $P < 0.001$ ), MPT ( $P = 0.04$ ), right amplitude and mucosal wave ( $P < 0.001$ ), and left amplitude and mucosal wave ( $P < 0.001$ ) is observed.
- (2) There is no difference between the two groups, regarding the impact of the microsurgery, except for the left mucosal wave, which is increasing more in the implanted group ( $P = 0.007$ ) and shimmer %, which is decreasing less in the implanted group ( $P = 0.049$ ).

**TABLE 2.**  
**Analysis of Variance, Early Postoperative Results**

Laryngeal and Vocal Variables	Fisher-Snedecort Statistic Comparing Pre- and Postoperative Means (1)		Fisher-Snedecort Statistic Comparing Pre- and Postoperative Means and Group Interaction (2)	
	F	P value	F	P value
G	103.236	<b>0.000</b>	0.583	0.447
R	139.733	<b>0.000</b>	0.192	0.663
B	13.202	<b>0.000</b>	2.457	0.121
A	1.736	0.191	0.367	0.547
S	41.563	<b>0.000</b>	0.291	0.591
I	108.758	<b>0.000</b>	0.115	0.735
Glottic closure	35.084	<b>0.000</b>	0.877	0.352
Left amplitude	82.763	<b>0.000</b>	3.126	0.085
Left mucosal wave	72.524	<b>0.000</b>	8.203	<b>0.007</b>
Right amplitude	35.838	<b>0.000</b>	0.807	0.373
Right mucosal wave	25.830	<b>0.000</b>	0.283	0.597
Average F0	0.041	0.840	0.163	0.687
Jitter %	7.377	<b>0.008</b>	0.923	0.340
F0 phonatory range	5.277	<b>0.024</b>	0.677	0.413
F0 STD	4.711	<b>0.033</b>	1.593	0.211
NHR	2.937	0.328	0.968	0.328
Shimmer %	10.807	<b>0.002</b>	4.006	<b>0.049</b>
MPT	4.265	<b>0.045</b>	0.042	0.839
MFR	7.420	<b>0.009</b>	0.401	0.530
Intraoral pressure	8.975	<b>0.005</b>	0.043	0.837

For each variable, two Fisher-Snedecort statistics compare (1) the pre- and the postoperative means and (2) the pre- and postoperative means and group interaction. Level of significance is  $P < 0.05$ . Significant  $P$  values are highlighted in bold.

### Delayed and Long-Term Outcome

Results are presented in Tables 3 and 4. Table 3 presents, in the implanted group, the correlation coefficients observed between each laryngeal and vocal variable and the number of days elapsed since microsurgery. Ten significant correlations between time elapsed since microsurgery and the data under study are present in the implanted group: G, R, I, glottic closure, left and right amplitude of vibration, right mucosal wave, phonatory range of F0, STD F0, NHR. G, R, I, phonatory range of F0, STD F0, and NHR are negatively correlated with time elapsed since microsurgery: in other words, those variables continue to diminish in the delayed and long-term period only in the implanted group. Glottic closure, bilateral amplitudes of vibration, and right mucosal wave exhibit a positive correlation

with the time elapsed: they keep increasing in the implanted group.

Table 4 presents, in the nonimplanted group, the correlation coefficients observed between each laryngeal and vocal variable and the number of days elapsed since microsurgery. The only datum showing a positive correlation with the time elapsed is the left mucosal wave. All the other variables remain at a stable value, obtained after microsurgery: there is no further evolution in the nonimplanted group.

### DISCUSSION

Before discussing the obtained results, we would like to make some comments on the limitations and strengths of the study design: both of these are intimately linked to the clinical (and not experimental) setting of this work.

The first limitation of this study is the absence of randomization: we used careful selection criteria to determine whether or not to place an implant inside SLLP's surgical wound at the end of the procedure. This explains the disparity of the VF lesions' diagnosis between the implanted and nonimplanted group: the use of esterified HA is limited to VF lesions associated with significant diminution of pliability of the VF cover. In these 33 cases, fibrotic tissue response was always observed inside the SLLP, at the time of surgery. This was especially obvious in cases with a partial or total absence of SLLP, like in sulcus, scar, subepithelial fibrosis, and vergeture. In the implanted group, nodules were rigid and fibrotic compared to the nonimplanted group nodules, which were more flexible and pliable. The polyps treated with subsequent implantation of EHA were sessile and associated with occupation of SLLP by fibrin and fibrosis sequellae of diffuse intracordal hemorrhage. The treated cysts were surrounded by thick fibrotic response, making their dissection difficult, and in the six edemas implanted with EHA, pouches of edemas were surrounded by thick fibrotic septae. These very different SLLP characteristics (absent/rigid in the implanted group, excessive/highly pliable in the nonimplanted group) are the driving justification for using or not using the EHA implant and explain the inhomogeneity of the preoperative diagnosis in the two groups. In such a clinical work evaluating an innovative microsurgical procedure, a prospective approach needs a careful selection of patients and of the material implanted. This is a necessity because of the clinical and ethical issues. Our work has indeed been approved and supervised during 4 years by a thesis committee composed of seven members of our faculty.

A second limitation is due to a nonblinded assessment of the stroboscopic and subjective voice evaluations. Some explanations can be given for this bias: the microsurgeon cannot be blind to the clinical situation of his or her patients, and because of the obvious presence of the VF lesion before surgery, the two other examiners cannot blindly evaluate the first postoperative videostroboscopy.

Finally, a third limitation is the existence of a postoperative antibiotic treatment only in the implanted group: we were concerned by the possibility of infection of the bioimplant placed in the surgical wound.

TABLE 3

**Long-Term Outcome of the Implanted Group: Correlation Coefficients of Kendall and of Spearman, Between the Time Elapsed Since Microsurgery and the Value of the Laryngeal and Vocal Variables**

Laryngeal and Vocal Variables	Implanted Group					
	Kendall Correlation Coefficient			Spearman Correlation Coefficient		
	Coefficient Value	N	P Value	Coefficient Value	N	P Value
G	-0.219	72	<b>0.01</b>	-0.291	72	<b>0.013</b>
R	-0.208	72	<b>0.02</b>	-0.267	72	<b>0.02</b>
B	-0.068	72	0.46	-0.10	72	0.39
A	-0.06	72	0.50	-0.07	72	0.52
S	-0.07	72	0.38	-0.11	72	0.34
I	-0.19	72	<b>0.03</b>	-0.26	72	<b>0.02</b>
Glottic closure	0.20	72	<b>0.01</b>	0.29	72	<b>0.01</b>
Left amplitude	0.32	28	<b>0.02</b>	0.42	28	<b>0.02</b>
Left mucosal wave	0.20	28	0.15	0.27	28	0.16
Right amplitude	0.35	49	<b>0.001</b>	0.48	49	<b>0.000</b>
Right mucosal wave	0.29	48	<b>0.006</b>	0.39	48	<b>0.006</b>
Average F0	0.49	73	0.49	-0.07	73	0.53
Jitter %	-0.13	73	0.09	-0.20	73	0.07
F0 phonatory range	-0.20	73	<b>0.01</b>	-0.29	73	<b>0.01</b>
STD of F0	-0.186	73	<b>0.02</b>	-0.26	73	<b>0.024</b>
NHR	-0.18	72	<b>0.03</b>	-0.25	72	<b>0.03</b>
Shimmer %	-0.08	73	0.29	-0.13	73	0.27
MPT	0.02	46	0.79	0.04	46	0.78
MFR	-0.08	44	0.41	-0.11	44	0.44
Intraoral pressure	0.11	42	0.29	0.18	42	0.23

Significance level is  $P < 0.05$ . Significant correlations are highlighted in bold.

Despite these limitations, the qualities of this clinical study are its prospective nature on quite a large group of patients (if compared with other studies on microsurgical results), the inclusion of long-term follow-up, an extensive evaluation of the cases, and, most importantly, an original nonparametric statistical analysis of the data obtained in the long term. This nonparametric analysis performed outside the immediate postoperative period aims at showing a relation between the value of the different variables and the passage of time. Because of clinical conditions (after surgery, the included patients are never examined at the same period of time), an analysis of variance is inappropriate: artificial temporal grouping of data would be inconclusive. We, therefore, decided to use correlation criteria and to take into account the precise number of days elapsed since the VF microsurgery. This process allows us, although in clinical conditions and serial follow-up, to overcome the difficulty of the time homogeneity of the evaluations: no predefined period of observation gives us the opportunity to evaluate a large number of statistically useful data and observe interesting microsurgical results never described before.

### Early Postoperative Results

The early postoperative results show expected modifications of laryngeal and voice data in both groups. Glottic closure, amplitude of vibration, and mucosal waves significantly increase after microsurgery, whereas quality of voice improves significantly at the subjective rating on the GRBASI scale. Frequency

instability (jitter %, PFR, STD of F0) and intensity instability (shimmer %) regress significantly in both groups. Aerodynamic data are also clearly modified by VF microsurgery: MPT increases, whereas intraoral pressure and MFR significantly diminish. These results are in accordance with results reported in the literature. A significant decrease in the grade of hoarseness (G), roughness (R), breathiness (B), jitter, shimmer, and noise energy is observed 2 weeks after microsurgery for nodules and polyps.<sup>8</sup> Another study on a series of 50 patients with various benign VF pathologies (mainly polyps) shows significant lowering of MFR but not of MPT after VF microsurgery; the authors insist on the importance of improving mucosal wave and amplitude of vibration to improve voice.<sup>9</sup> In a small series of 20 patients treated for Reinke's edema, a significant decrease in shimmer % is obtained but no significant lowering of jitter %, subglottic pressure, or MFR.<sup>10</sup>

In the immediate postoperative period, the observed results have to take into account the viscoelastic properties of the implanted esterified HA and the ongoing healing process. Implanted patients improve their ratings with the same intensity as that of the nonimplanted patients, although they exhibit worse preoperative voice and stroboscopic ratings. Pliability of the VF cover is good in implanted patients. This is an extremely important finding, because it is the first time, to our knowledge, that exogenous HA is used in the vibrating cover of the human VF: the implant is placed inside the microdissected Reinke's space, and many prior studies<sup>11,12</sup> stressed

**TABLE 4**  
**Long-Term Outcome of the Nonimplanted Group: Correlation Coefficients of Kendall and of Spearman, Between the Time Elapsed Since Microsurgery and the Value of the Laryngeal and Vocal Variables**

Laryngeal and Vocal Variables	Nonimplanted Group					
	Kendall Correlation Coefficient			Spearman Correlation Coefficient		
	Coefficient Value	N	P value	Coefficient Value	N	P Value
G	0.001	60	0.98	−0.002	60	0.99
R	0.05	60	0.62	0.06	60	0.63
B	−0.06	60	0.51	−0.08	60	0.51
A	0.009	60	0.93	0.01	60	0.90
S	0.06	60	0.54	0.08	60	0.53
I	−0.11	60	0.25	−0.14	60	0.28
Glottic closure	−0.11	59	0.21	−0.17	59	0.18
Left amplitude	0.18	40	0.10	0.26	40	0.09
Left mucosal wave	0.31	42	<b>0.009</b>	0.41	42	<b>0.006</b>
Right amplitude	0.07	45	0.51	0.10	45	0.48
Right mucosal wave	0.09	43	0.44	0.12	43	0.44
Average F0	−0.13	57	0.14	−0.20	57	0.13
Jitter %	0.03	57	0.70	0.04	57	0.74
F0 phonatory range	−0.02	57	0.83	−0.02	57	0.83
STD of F0	−0.04	57	0.59	−0.08	57	0.55
NHR	0.01	57	0.88	0.02	57	0.86
Shimmer %	0.06	57	0.45	0.10	57	0.45
MPT	0.01	50	0.87	0.01	50	0.90
MFR	−0.03	50	0.69	−0.05	50	0.70
Intraoral pressure	0.008	48	0.93	0.004	48	0.97

Significance level is  $P < 0.05$ . Significant correlations are highlighted in bold.

the importance of the viscoelastic properties of biomaterials for VF procedures. If the implant is too viscous or too rigid, it will lead to lack of pliability of the VF cover, lack of vibratory movement, and poor voice results, which is not, fortunately, what we observe with EHA. Comparison of the viscoelastic properties of the human VF cover and of that of various biomaterials (micronized alloderm; Cymetra, Lifecell corp, Branchburg, New Jersey, USA), Teflon (Mentor Inc, Hingham, Massachusetts, USA), Gelfoam (Upjohn Co, Kalamazoo, Michigan, USA), and collagen (Zyplast Collagen corporation, Palo Alto, California, USA) have shown that all these biomaterials are much more rigid and viscous than the VF cover and are, therefore, not usable inside the mucosal cover.<sup>13–16</sup> By contrast, rheologic and animal studies have shown that biomaterials made up of modified HA exhibit favorable viscoelastic properties that make them good candidates for a very superficial use in the VF's lamina propria.<sup>3,4,11,13,14,16,17</sup>

The potential risk of impaired VF pliability due to the implanted biomaterial explains our choice of first developing this technique in cases in which rigidity of the mucosal cover and tissue fibrosis were pre- and peroperatively evident.

According to the manufacturer of MeroGel, the implant dissolves in 2 weeks in the nose and in 6 weeks in the middle ear. From the observation of the laryngeal image, we interpret the disappearance of a slight convexity of the treated VF observed in three of our cases as the probable resorption of the inserted EHA implant: it would mean that 3 to 4 weeks are necessary for the resorption of the implant. No previous observation is

reported on the use of modified HA in the subepithelial portion of the human VF, all other studies reporting results on deep injections of hyaluronan-based biomaterials for the treatment of glottic insufficiency,<sup>12,18,19</sup> the authors observing good videostroboscopic evolution and the absence of adverse effects. According to a recent study, some hyaluronan-based biomaterials exhibit viscoelastic properties that can make them suitable for superficial injection in the VF: Hylaform and Restylane, which are dermal fillers used in the treatment of wrinkles and skin scars, were tested *in vitro* for their viscosity and elasticity, and they showed slightly higher values compared with those of human SLLP. Hylaform was less viscous than Restylane and, according to the authors, a possible bioimplant for superficial use in the VFs.<sup>13</sup>

### Delayed and Long-Term Results

The delayed and long-term results have to be discussed while taking into account tissue healing and remodeling processes taking place inside the SLLP. In that time frame, the resorbable EHA has been removed from the SLLP by the natural degradation processes. The data show a very different behavior of the implanted group in comparison with the nonimplanted one: the implanted patients exhibit a continuous improvement of 10 laryngeal and voice parameters, whereas the nonimplanted group modifies only one stroboscopic parameter. This is a very important finding for two reasons. First, serial observations over several years of follow-up have never demonstrated continuous improvement after VF microsurgery. The published



studies rather evaluate the immediate postoperative results and long-term stability of the microsurgically obtained results.<sup>12,20</sup> Second, this continuous improvement over time is observed only in the patients implanted with EHA.

Does that long-term evolution depend on a slower improvement of the implanted patients because of worse preoperative laryngeal conditions? This could partly explain the improvement of G, R, S, I, and of right amplitude and mucosal wave, which were significantly worse preoperatively in the implanted group. However, this explanation is insufficient for the continuous improvement of the other measured variables and especially the objective voice variables. Moreover, all the improving laryngeal and vocal variables exhibit the same early postoperative behavior in both groups. The nonimplanted group reaches its acme of improvement in the early postoperative period, and no further evolution is observed. On the other hand, the implanted group exhibits a peculiar evolution, with a slow improvement of 10 voice and laryngeal variables with the passage of time. We think that this is due to the improvement of tissue mechanical properties: a more favorable tissue remodeling of the SLLP in the presence of EHA implanted in the surgical wound is a possible explanation. Positive effects of HA on healing are well known and have been extensively studied in skin tissue repair. Scarless healing of skin is observed in fetal healing, and this regeneration-like tissue repair is thought to be linked to the very high concentration of HA in the amniotic fluid, for a prolonged period of time.<sup>21</sup> Both *in vitro* and *in vivo* (animal and human) studies on skin tissues have been conducted. *In vitro*, contraction by fibroblasts was significantly reduced when concentration of HA was >1 mg/mL.<sup>22</sup> *In vivo*, as early as the seventies, application of high-molecular-weight (>1 × 1,000,000 Da) purified HA to skin incisions, in different animal species, decreased granulation tissue and fibrosis.<sup>23</sup> Subsequent studies have demonstrated that HA provides a beneficial effect on the quality of the scar tissue.<sup>5,24</sup> The actions of HA in the ECM are both mechanical and biological. The molecule binds to a large amount of water molecules, maintaining the volume of the extracellular space and acts as a molecular sieve capable of excluding large molecules such as fibrinogen and of modifying chemotactic gradients. HA plays a wide range of biological roles, regulating several cellular activities such as cell attachment, cell proliferation, cell migration, and cell differentiation. This wide range of activities results from the existence of a large number of HA-binding proteins (termed hyaladherins) that exhibit large differences in their cellular localization, affinity, specificity, and tissue expression.<sup>25</sup> These hyaladherins are present on the cell surface of fibroblasts, neutrophils, activated T cells, and macrophages. HA is, therefore, capable of modifying the activity of those cells and to, thereby, reduce inflammation and subsequent collagen deposition. In skin tissue repair, favorable effects of exogenous HA on healing and scarring processes are achieved when the molecule is maintained at the wound site for a prolonged period of time, at least during several days.<sup>5</sup> As stated before, from the videostroboscopic data obtained in the immediate postoperative period, we suggest that our implant stays in place several weeks, which is a long period of time if we compare it to the time of residence

of implants in skin tissue repair studies. Hardly anything is known on human VF's SLLP healing, remodeling, and scarring processes, and especially nothing is known on the actual levels of HA in the wound site. It is, therefore, impossible to guess which time of residence of the implant is needed to favor better healing conditions in the microdissected SLLP. The desired time of residence of the implant could even be very different, depending on the type of pathology: we hypothesize from our clinical observations that the residence time is probably insufficient in cases of very deeply altered SLLP such as scars and vergetures. Modulation of healing processes by HA in these cases might also be less efficient because of the absence of residual cellular and molecular environment in the altered SLLP, knowing that the action of HA is partly due to cell response, which is context-specific.<sup>26</sup> In a recent study, injection of cross-linked HA (Restylane) in the dermis of photo-damaged human skin stimulated the collagen synthesis by the dermal fibroblasts, partially restoring the lost ECM components.<sup>27</sup> Time of residence of the exogenous HA in the wound is not the only important factor: different parameters of wound repair, like wound contraction and angiogenesis, are influenced by the molecular weight of the HA molecule. High-molecular-weight HA (>1,000,000 Da) accelerates wound contraction and reduces angiogenesis.<sup>28</sup> Conversely, low-molecular-weight HA has a stimulating effect on angiogenesis as demonstrated in various animal models.<sup>29</sup> The EHA implant used in our study is a low-molecular-weight modified HA, only 20,000 Da. We never observed any permanent hypervascularization in any of our patients, but it is of course a clinical evaluation of the laryngeal image, without any histological analysis. A micro-angiogenesis effect is thus still possible.

Only one case of important and long-lasting inflammation was observed, in a patient treated for mucous cyst: fibrinous and rigid VF is visible at the first postoperative evaluation. The patient did not comply with vocal rest and did not take the prescribed medications in the postoperative period. We suggest that the unfavorable evolution is due to infection of the wound. It took several weeks to observe the closure and healing. Inflammation and decreased pliability of the mucosal cover of the treated VF are still observed 8 months after microsurgery. From our data, we can conclude that EHA implantation is well tolerated in our series.

In a dermatologic survey on the safety of injectable non-animal modified HA, published in 2004, the incidence of hypersensitivity is reported to be around 0.6%, and the authors conclude a high safety level of the HA filler in dermatology. The authors stress that no skin testing is necessary before the injection, because the preparation, theoretically, does not contain any protein. The study described one case of hypersensitivity reaction lasting more than a year.<sup>30</sup>

In the field of laryngology, cross-linked hyaluronan has been used in augmentative surgery as an injectable material in patients suffering of glottic insufficiency, with very good results on videostroboscopic parameters and absence of adverse side effects.<sup>12,19</sup> The authors noted a few patients with early signs of inflammation (within a week after injection), but all cases resolved without sequellae within 30 days. In our series, we did

observe a very transient redness of the implanted region of the SLLP in two cases, which resolved in a few weeks. From our data, we can conclude that EHA implantation is well tolerated in our series.

## CONCLUSION

From our several years' experience of the use of EHA in the microdissected SLLP at the end of a microsurgical procedure, we conclude that the use of the implant is safe and leads to good laryngeal and vocal outcomes in the treated patients. More interestingly, treated cases exhibit a continuous improvement over a long period of time. Additional clinical studies are needed to obtain a clear view on the benefits of the use of modified HA inside the microdissected SLLP at the end of a microsurgical procedure like prospective studies in large groups of well-defined benign VF lesions. In addition, after this prospective work, and because of the good functional results as well as the absence of adverse effects of the intra-SLLP implantation, randomized studies could be undertaken.

The observations reported here are encouraging and raise many questions on the lifetime of HA implants in the SLLP, on their viscoelastic properties and modifications over time, on the modulation of healing and, possibly, on the regeneration of the SLLP.

The answers to those questions need thorough investigations *in vitro* and *in vivo* to improve our understanding of the biological maintenance of the human SLLP, both in normal and pathological states and in healing conditions.

## REFERENCES

- Ward PD, Thibeault SL, Gray SD. Hyaluronic acid: its role in voice. *J Voice*. 2002;16:303-309.
- Butler JE, Hammond TH, Gray SD. Gender-related differences of hyaluronic acid distribution in the human vocal fold. *Laryngoscope*. 2001;111:907-911.
- Gray SD, Titze IR, Chan R, Hammond TH. Vocal fold proteoglycans and their influence on biomechanics. *Laryngoscope*. 1999;109:845-854.
- Chan RW, Gray SD, Titze IR. The importance of hyaluronic acid in vocal fold biomechanics. *Otolaryngol Head Neck Surg*. 2001;124:607-614.
- Balazs EA, Larsen NE. Hyaluronan: aiming for perfect skin regeneration. In: Garg HG, ed. *Scarless Wound Healing*. New York: Marcel Dekker; 2000:143-160.
- Thibeault SL, Rousseau B, Welham NV, Hirano S, Bless DM. Hyaluronan levels in acute vocal fold scar. *Laryngoscope*. 2004;114:760-764.
- Finck C, Lefebvre P. Implantation of esterified hyaluronic acid in microdissected Reinke's space after vocal fold microsurgery: first clinical experiences. *Laryngoscope*. 2005;115:1841-1847.
- Uloza V. Effects on voice by endolaryngeal microsurgery. *Eur Arch Otorhinolaryngol*. 1999;256:312-315.
- Woo P, Casper J, Colton R, Brewer D. Aerodynamic and stroboscopic findings before and after microlaryngeal phonosurgery. *J Voice*. 1994;8:186-194.
- Zeitels SM, Hillman RE, Bunting GW, Vaughn T. Reinke's edema: phonatory mechanisms and management strategies. *Ann Otol Rhinol Laryngol*. 1997;106(7 Pt 1):533-543.
- Chan RW, Titze IR. Viscosities of implantable biomaterials in vocal fold augmentation surgery. *Laryngoscope*. 1998;108:725-731.
- Hertegard S, Hallen L, Laurent C, Lindström E, Olofsson K, Testad P, Dahlqvist A. Cross-linked hyaluronan versus collagen for injection treatment of glottal insufficiency: 2-year follow-up. *Acta Otolaryngol*. 2004;124:1208-1214.
- Caton T, Thibeault SL, Klemuk S, Smith ME. Viscoelasticity of hyaluronan and nonhyaluronan based vocal fold injectables: implications for mucosal versus muscle use. *Laryngoscope*. 2007;117:516-521.
- Chan RW, Titze IR. Hyaluronic acid (with fibronectin) as a bioimplant for the vocal fold mucosa. *Laryngoscope*. 1999;109(7 Pt 1):1142-1149.
- Chan RW, Titze IR. Viscoelastic shear properties of human vocal fold mucosa: measurement methodology and empirical results. *J Acoust Soc Am*. 1999;106(4 Pt 1):2008-2021.
- Klemuk SA, Titze IR. Viscoelastic properties of three vocal-fold injectable biomaterials at low audio frequencies. *Laryngoscope*. 2004;114:1597-1603.
- Hallen L, Dahlqvist A, Laurent C. Dextranomers in hyaluronan (DiHA): a promising substance in treating vocal cord insufficiency. *Laryngoscope*. 1998;108:393-397.
- Hallen L, Testad P, Sederholm E, Dahlqvist A, Laurent C. DiHA (dextranomers in hyaluronan) injections for treatment of insufficient closure of the vocal folds: early clinical experiences. *Laryngoscope*. 2001;111:1063-1067.
- Hertegard S, Hallen L, Laurent C, Lindström E, Olofsson K, Testad P, Dahlqvist A. Cross-linked hyaluronan used as augmentation substance for treatment of glottal insufficiency: safety aspects and vocal fold function. *Laryngoscope*. 2002;112:2211-2219.
- Hsiung MW, Lin YS, Su WF, Lee JC, Wang HW. Fat augmentation following microsurgical removal of the vocal nodules: long-term results. *ORL J Otorhinolaryngol Relat Spec*. 2003;65:169-175.
- Longaker MT, Chiu ES, Adzick NS, Stern M, Harrison MR, Stern R. Studies in fetal wound healing. V. A prolonged presence of hyaluronic acid characterizes fetal wound fluid. *Ann Surg*. 1991;213:292-296.
- Huang-Lee LL, Wu JH, Nimni ME. Effects of hyaluronan on collagen fibrillar matrix contraction by fibroblasts. *J Biomed Mater Res*. 1994;28:123-132.
- Rydell N. Decreased granulation tissue reaction after installment of hyaluronic acid. *Acta Orthop Scand*. 1970;41:307-311.
- King SR, Hickerson WL, Proctor KG. Beneficial actions of exogenous hyaluronic acid on wound healing. *Surgery*. 1991;109:76-84.
- Day AJ, Prestwich GD. Hyaluronan-binding proteins: tying up the giant. *J Biol Chem*. 2002;277:4585-4588.
- Savani R, et al. The role of hyaluronan receptor interactions in wound repair. In: *Scarless Wound Healing*. New York: Marcel Dekker; 2000:115-137.
- Wang F, et al. In vivo stimulation of de novo collagen production caused by cross-linked hyaluronic acid dermal filler injections in photo-damaged human skin. *Arch Dermatol*. 2007;143:155-163.
- Breuing K, et al. Healing of partial thickness porcine wounds in a liquid environment. *J Surg Res*. 1991;52:50-58.
- Arnold F, et al. Hyaluronan, heterogeneity and healing: the effects of ultrapure hyaluronan of defined molecular size on the repair of full-thickness pig skin wounds. *Wound Repair Regen*. 1995;3:299-310.
- Andre P. Evaluation of the safety of a non-animal stabilized hyaluronic acid (NASHA - Q-Medical, Sweden) in European countries: a retrospective study from 1997 to 2001. *J Eur Acad Dermatol Venereol*. 2004;18:422-425.