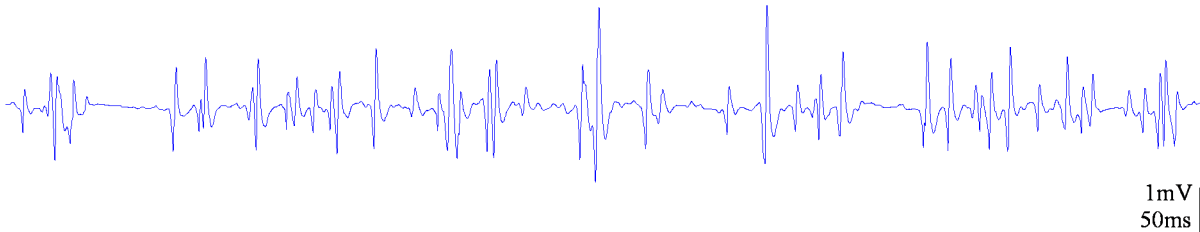


# EMG Findings

Muscle (Innervation)	Interprétation	Voluntary act.					
		Fib	PSW	Amp	Dur	Stabil.	AV
Droit Abd pollicis brev (Medianus, C8 t1)	Déner.réc.part	4/10	4/10	Normal	Normal	Normal	-

## EMG Signals

R Droit Abd pollicis brev (AV)



R Abd pollicis brev

