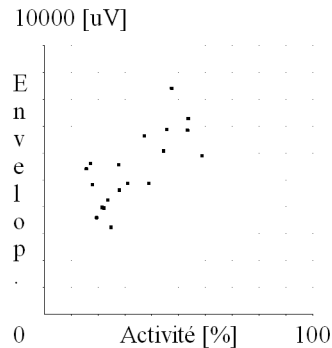
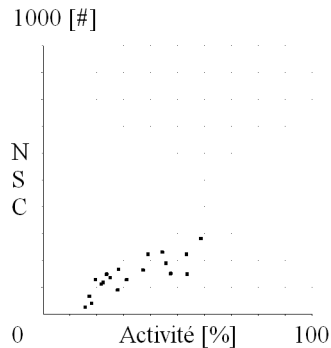
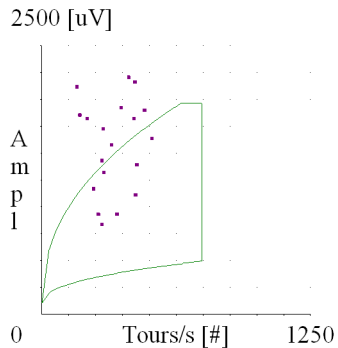


## R Tibialis anterior



## R Vastus lateralis

