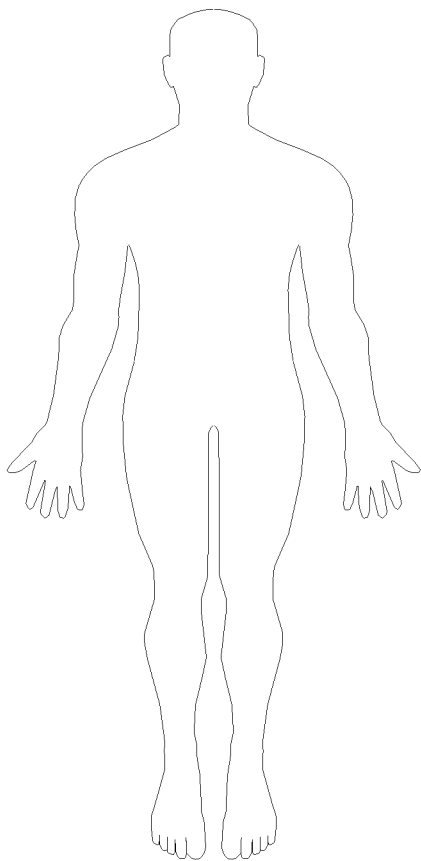
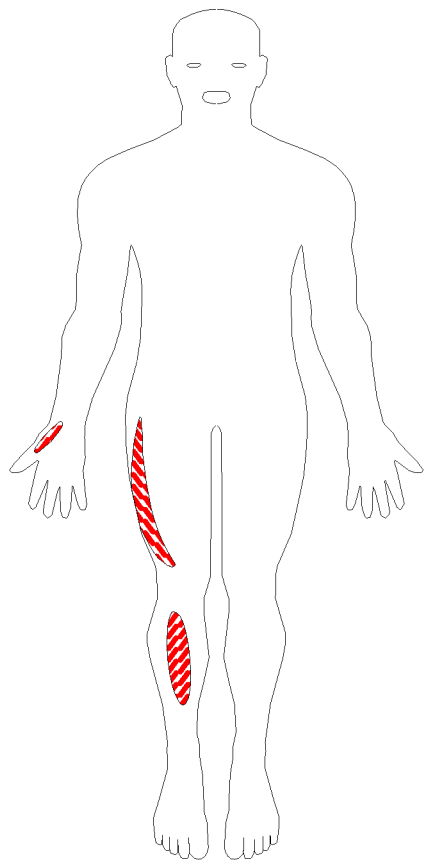

















# EMG Muscle Man



-  Myo.prononcée
-  Myopath.
-  Normal
-  Neur.Chr.Disc
-  Neur.Chr.Mod.
-  Neur.Chr.Pron.
-  Neur.Sub.A.Di
-  Neur.Sub.A.Mod
-  Neur.Sub.A.Pron
-  Déner.réc.part
-  Déner.complète
-  Perte U.M
-  Bloc neuromusc.
-  Faiblesse centr.
-  Autre

## EMG Findings

Muscle (Innervation)	Interprétation	Voluntary act.						
		Fib	PSW	Amp	Dur	Poly	Stabil.	AV
Droit Abd pollicis brev (Medianus, C8 t1)	Neur.Chr.Disc	0/10	0/10	+	+	Normal	Normal	-
Droit Tibialis anterior (Peroneus profundus, l4 L5)	Neur.Chr.Disc	2/10	2/10	++	++	Normal	Normal	-
Droit Vastus lateralis (Femoralis, l2 l3 L4)	Neur.Chr.Mod.	0/10	0/10	++	++			--