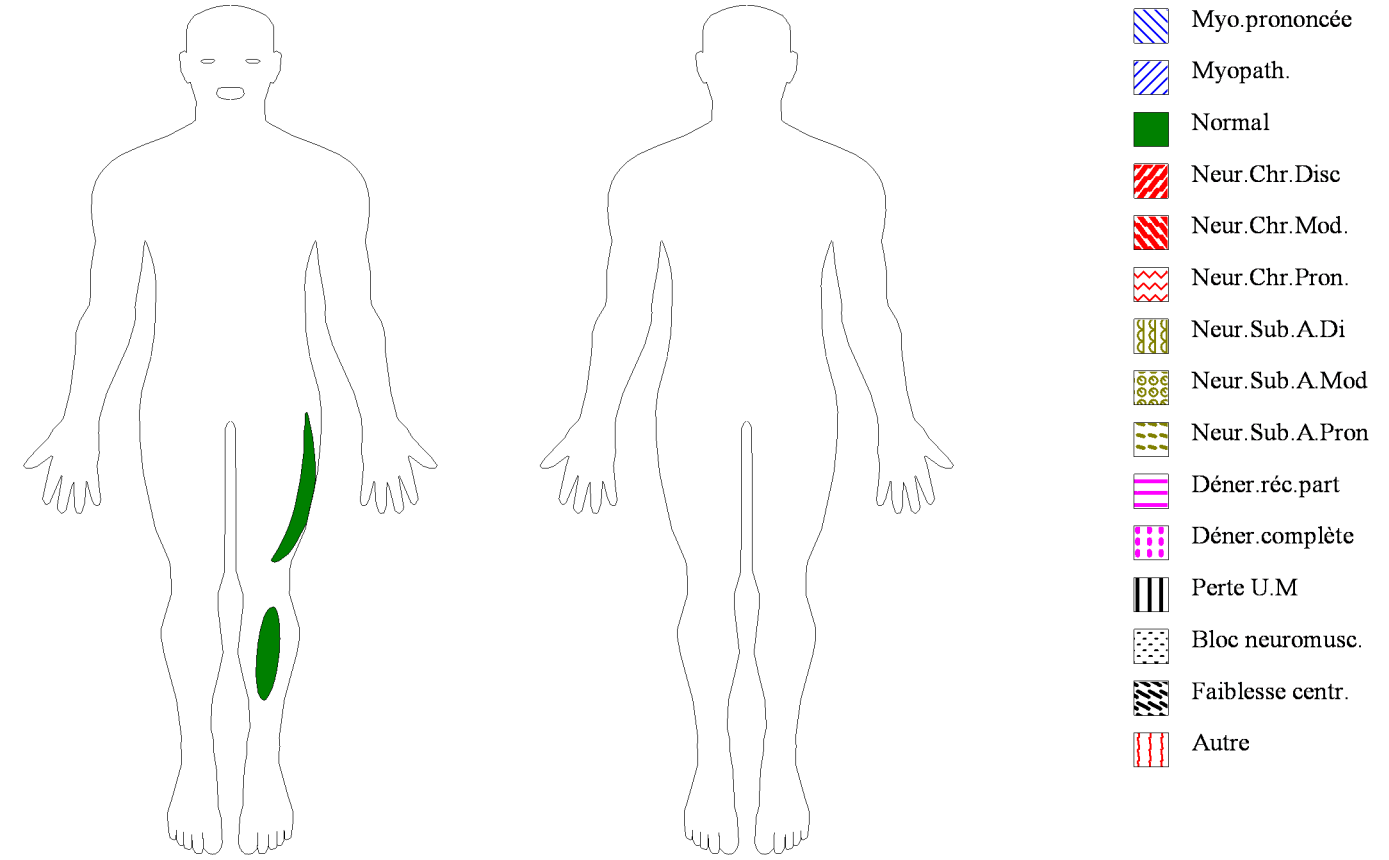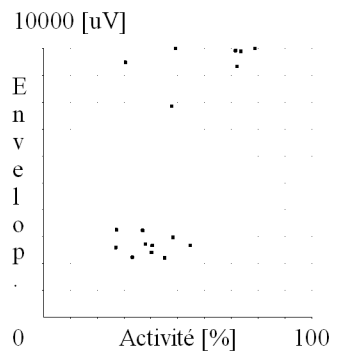
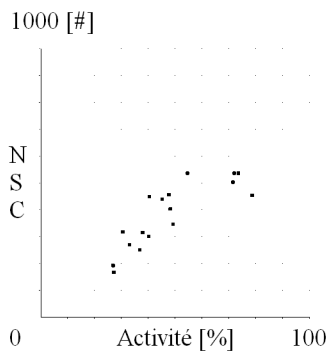
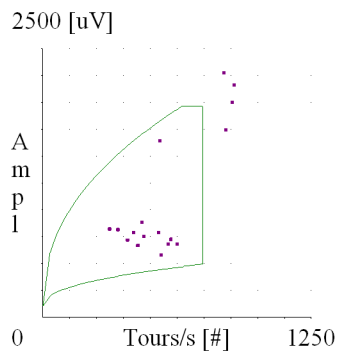


EMG Findings

Muscle (Innervation)	Interprétation	Voluntary act.						
		Fib	PSW	Amp	Dur	Poly	Stabil.	AV
Gauche Tibialis anterior (Peroneus profundus, l4 L5)	Normal	0/10	0/10	Normal	Normal	Normal	Normal	Normal
Gauche Vastus lateralis (Femoralis, l2 l3 L4)	Normal	0/10	0/10	Normal	Normal	Normal	Normal	Normal

L Tibialis anterior



L Vastus lateralis

