

Platelet-rich plasma to treat jumper's knee: Preliminary results

Kaux JF¹, Croisier JL¹, Simoni P², Lonneux V¹, Lapraille S¹, Brabant G¹, Noël D¹, Rodriguez C¹, Daniel C³, Collette J⁴, Gothot A⁴, Le Goff C⁴, Crielaard JM¹



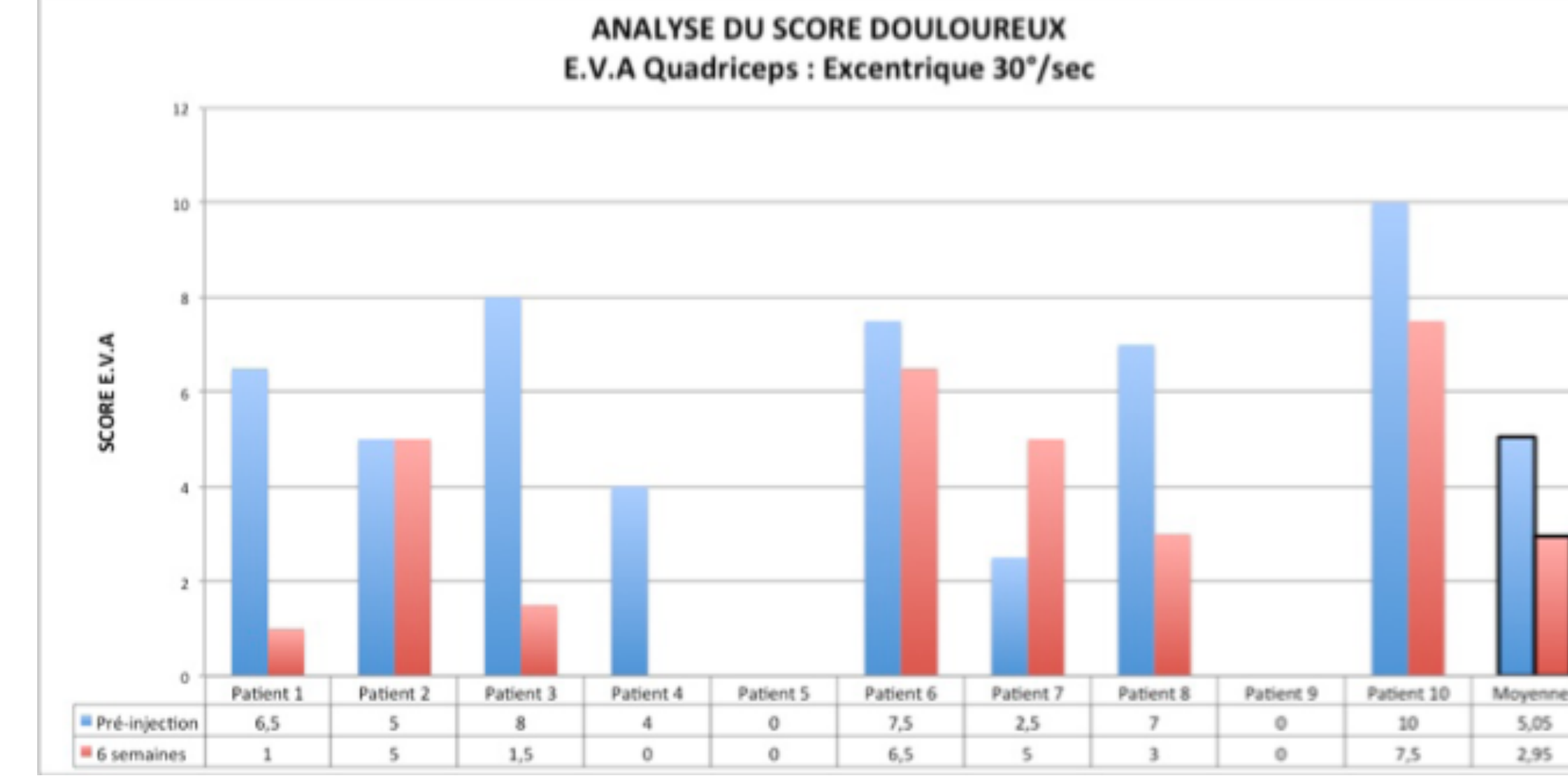
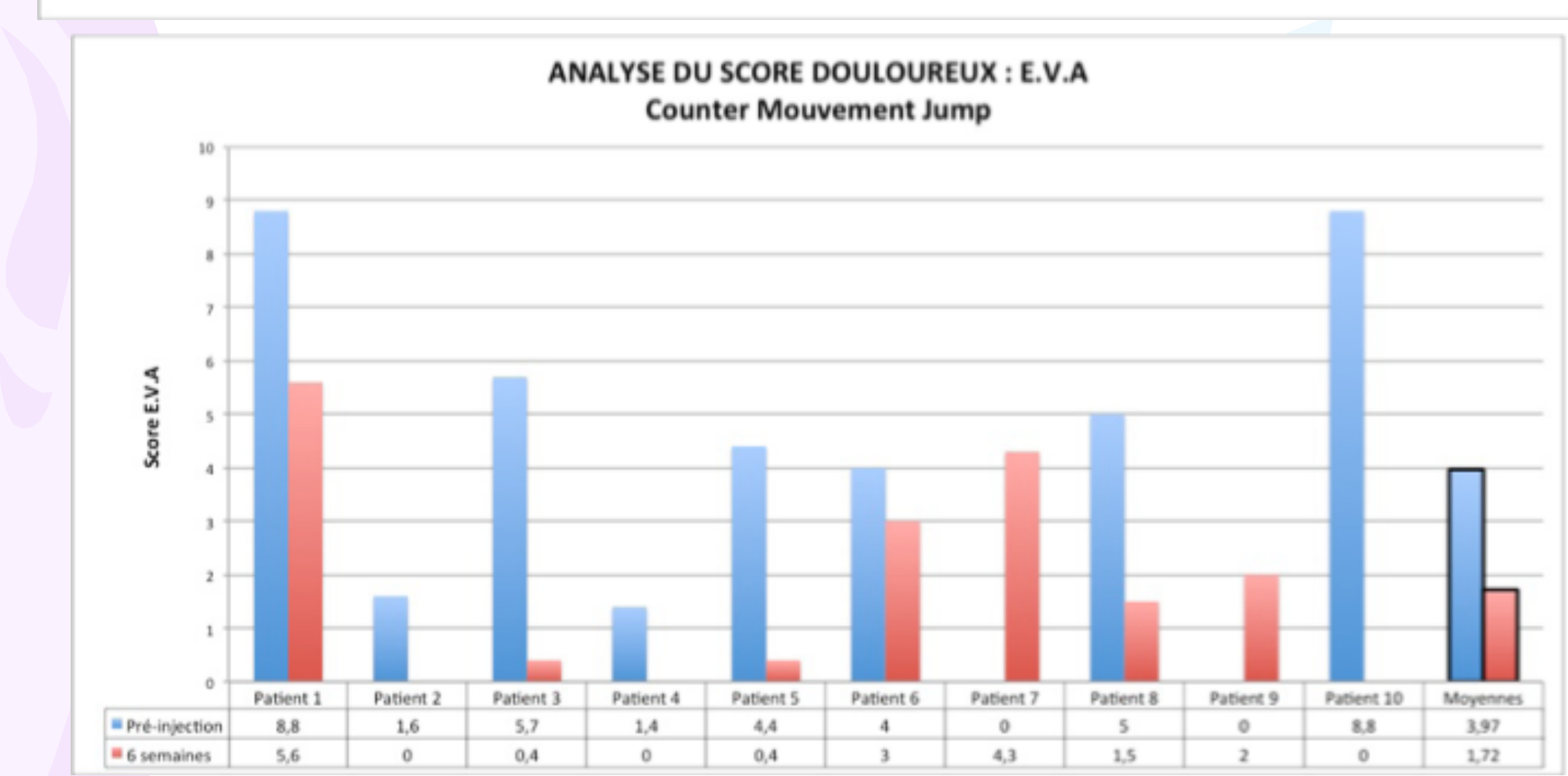
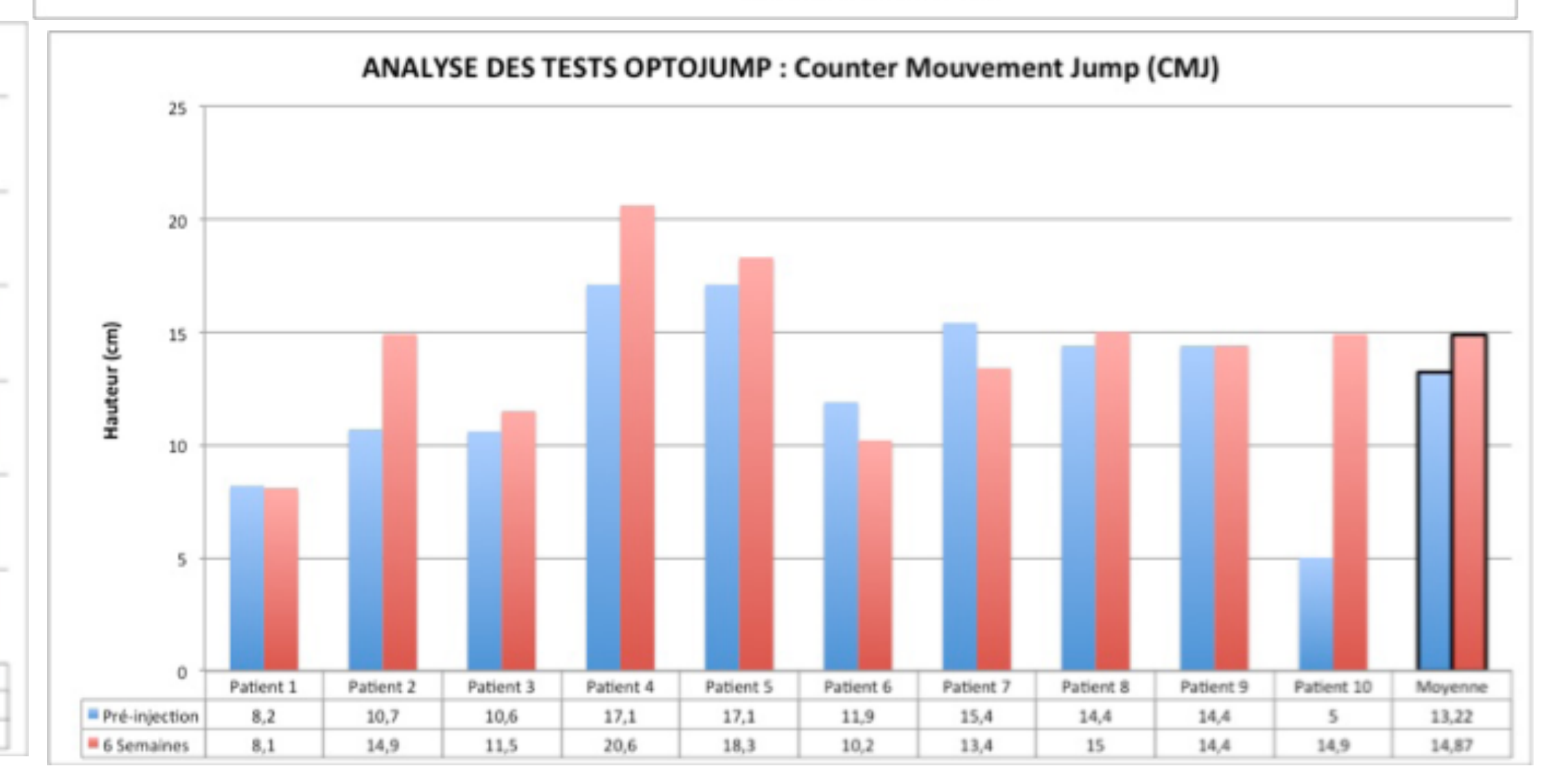
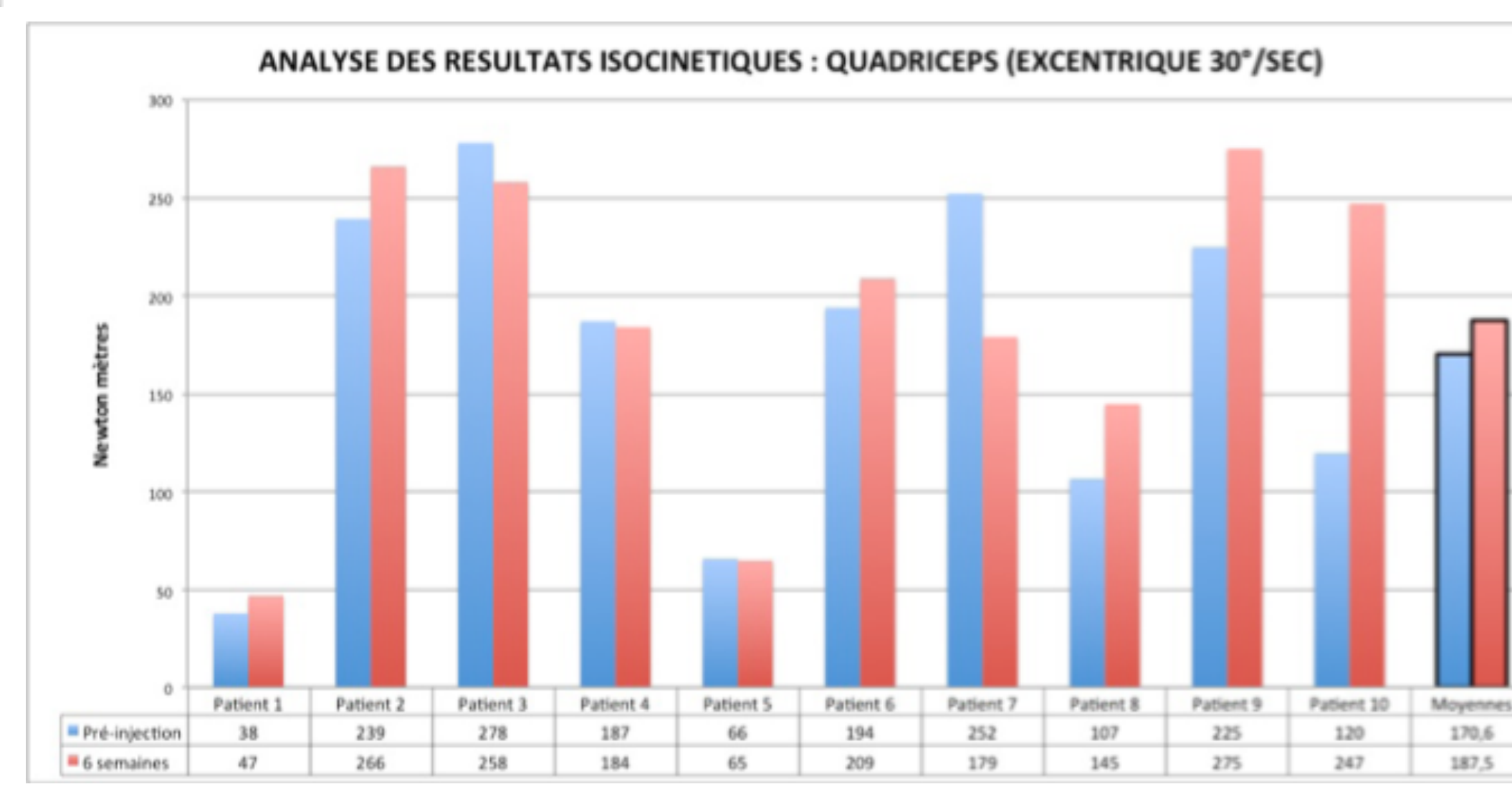
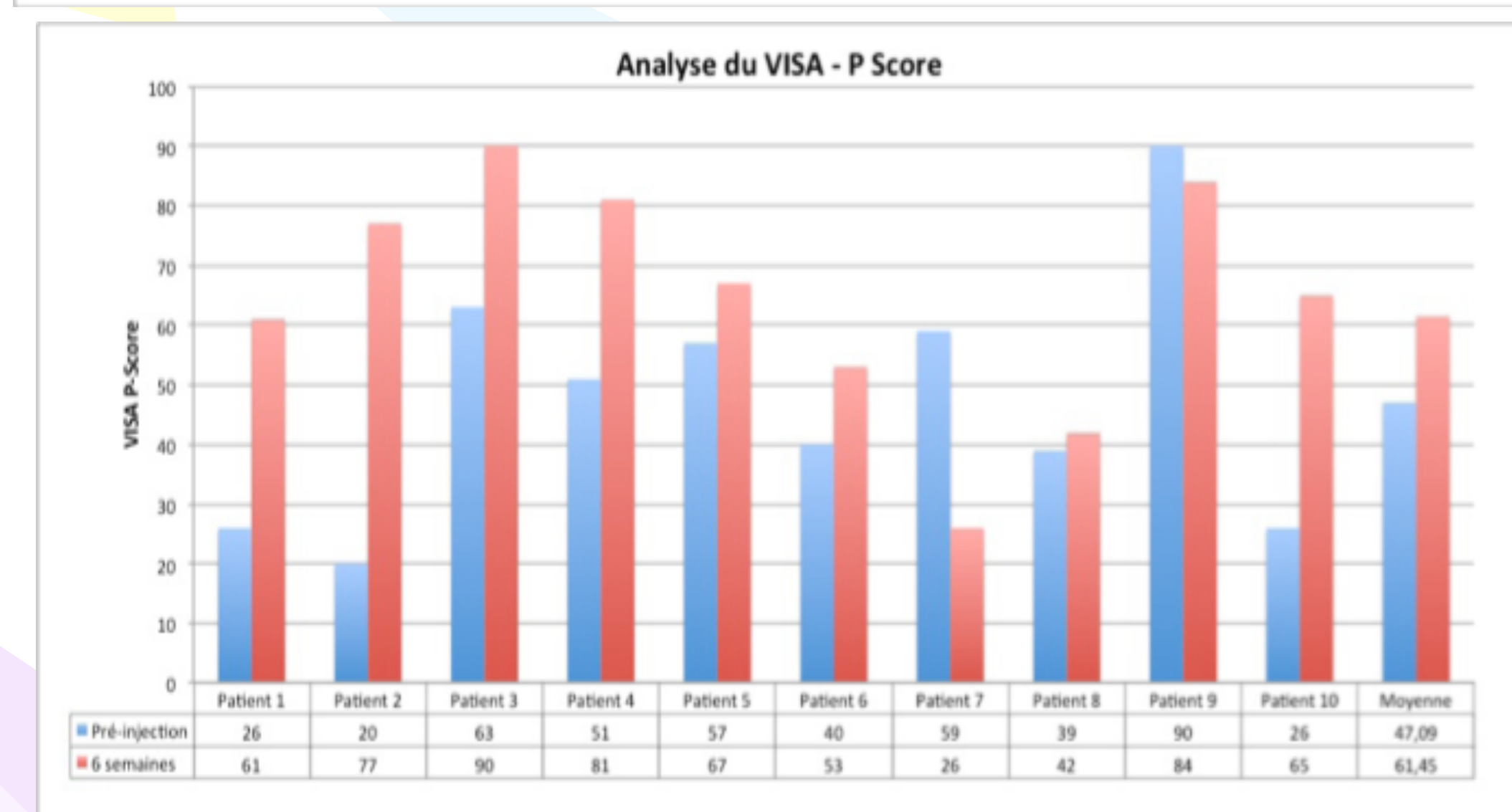
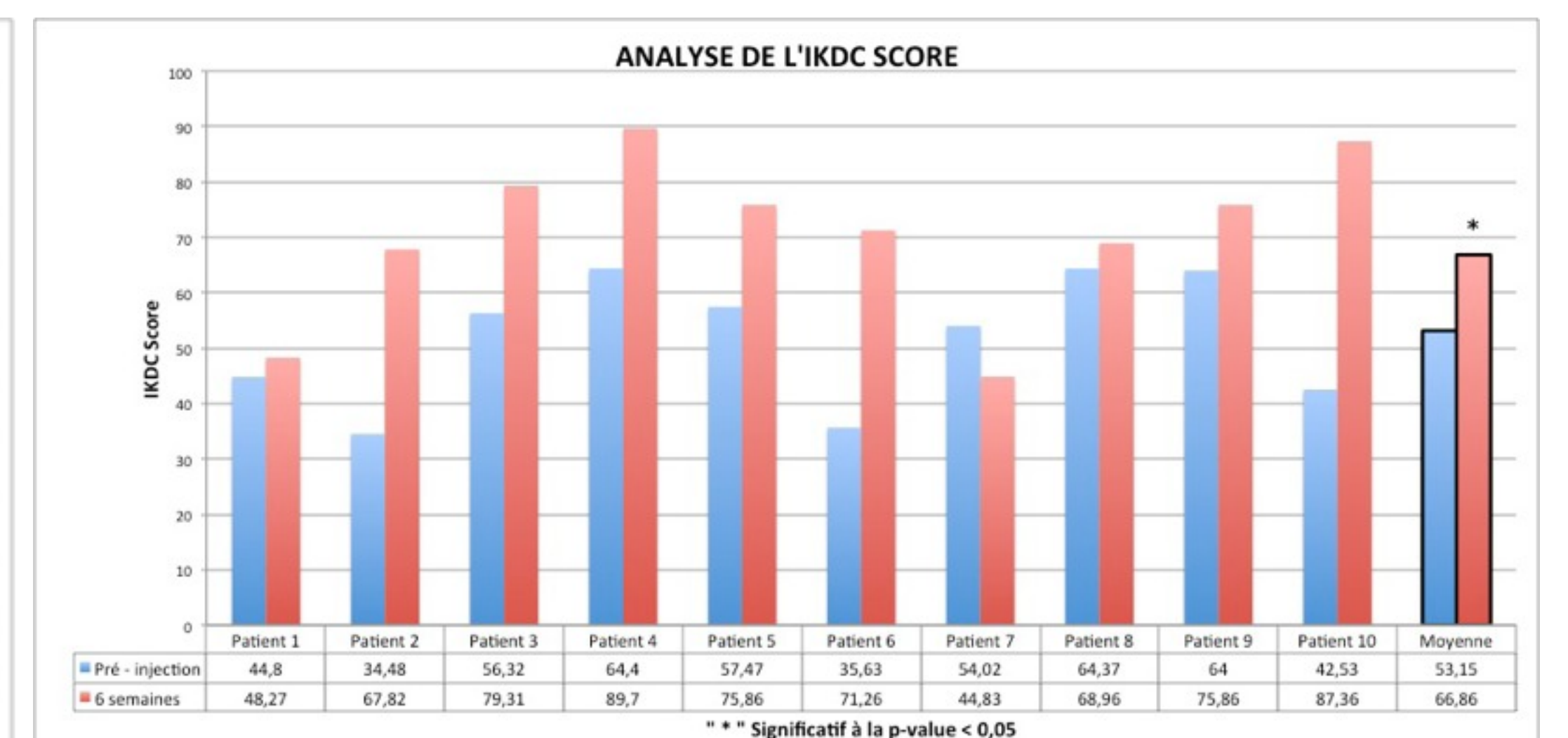
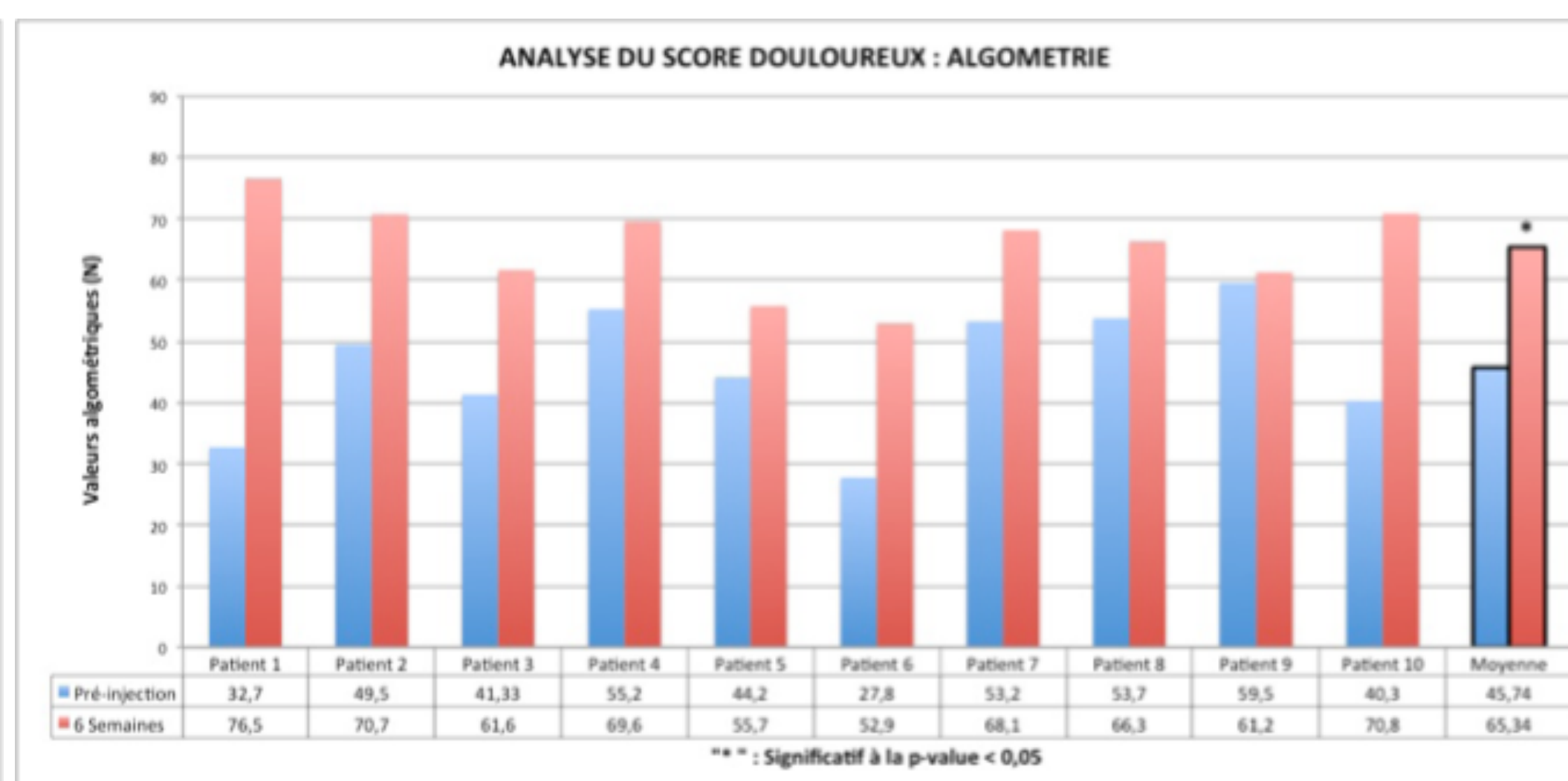
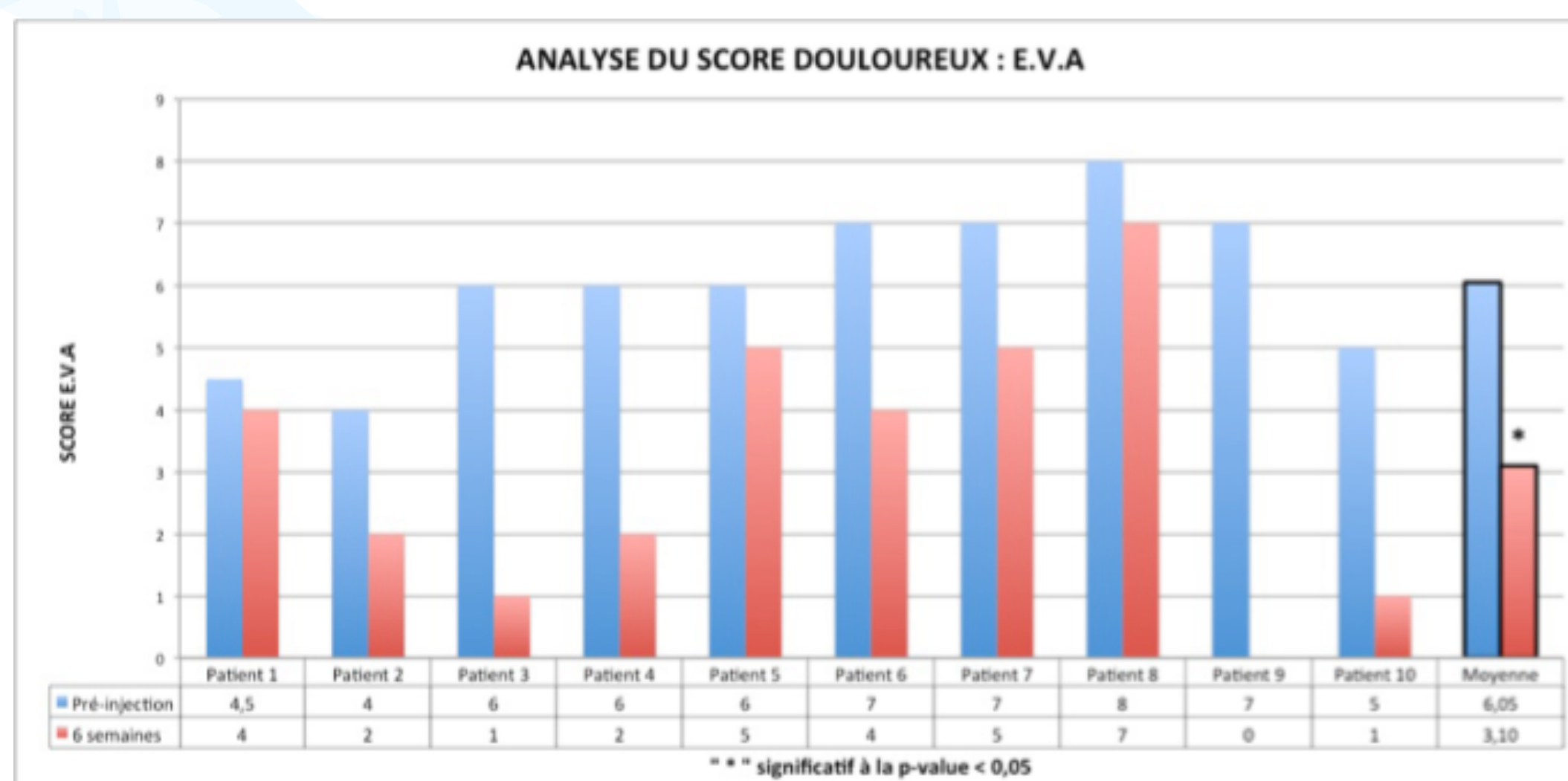
1 Physical Medicine Service, Department of Motility Sciences, University Hospital of Liège, University of Liège, Belgium
2 Medical Imaging Service, University Hospital of Liège, Belgium
3 Orthopaedic Surgery Service, University Hospital of Liège, Belgium
4 Department of Clinical Biology, University Hospital of Liège, University of Liège, Belgium.



Introduction: Patellar tendinopathy, often remain rebel to conservative treatments. Researches have specifically demonstrated the platelets action as mediator and/or enhancer of tissue healing. The aim of our study was to investigate the effect of 1 injection of PRP in patients suffering from chronic patellar tendinopathy. Our protocol was approved by Ethic Committee of University and University Hospital of Liège.

Methods: Patients performed imaging (US and MRI) and functional assessments, and a clinical examination using an algometer, before treatment and 6 weeks after PRP treatment. They were also invited to answer to questionnaire relative to pain and functional status. PRP was obtained from autologous blood using an apheresis system (COM.TEC, Fresenius). The injection of 6mL of PRP was realised without local anaesthesia into the proximal insertion of the patellar tendon. A 48h rest-time was recommended after infiltration. Afterwards, a submaximal eccentric reeducation was initiated 1 week after infiltration 3 times a week during 5 weeks. In case of pain, anti-inflammatory drugs were prohibited and patient were encouraged to take class I or II painkillers.

Results: At this time, 10 patients with patellar tendinopathy were included in our study. Pre-injection tests revealed pain of the upper part of the patellar tendon just below the patella, associated with loss of function. Imaging exams confirmed diagnosis. Six weeks post-injection, the clinical status was improved in all patients, with a significant decrease of algo-functional scores. The pain reported during functional assessments was decreased (in particular for the eccentric actions), yet no significant improvement of physical performances was observed. We found no significant differences between imaging exams before and 6 weeks after PRP injection.



Acknowledgement: This experimentation was financed by "Lejeune-Lechien" and "ADEPS" grants (Leon Frédéricq Funds).

Conclusion: One in situ injection of PRP clinically improved patients with patellar tendinopathy 6 weeks after treatment. All the 10 patients reported a decrease of pain during day-life and through physical activities. However nor functional performances neither imaging were improved. A 3-month follow-up is in process.