

Potential Benefits of Laparoscopic Aorto-Bifemoral Bypass Surgery

A. Rouers*, N. Meurisse*, J. P. Lavigne*, D. Francart, J. Quaniers**, Q. Desiron, R. Limer**

* Dpt of Vascular and General Surgery, CHR Reine Astrid, Huy, Belgium ; ** Dpt of Cardio-Vascular and Thoracic Surgery, CHU Sart Tilman, Liège, Belgium.

Key words. Aortoiliac occlusive disease ; aortobifemoral bypass ; laparoscopy.

Abstract. Background : This series aims to prove the positive impact of laparoscopic approach in aortofemoral bypass grafting.

Methods : It concerns a retrospective non randomized study comparing 58 consecutive patients treated with laparoscopic procedure (n = 30) and with a standard open procedure (n = 28) in a single center. The different operating times, the complications and the follow-up of these two groups are compared

Results : The demographics and angiographic data of the two groups were comparable. Operating time was longer in the laparoscopic group. However, we noticed a significant shorter hospitalisation stay ($p < 0.0001$) after the laparoscopic procedure with a mean 5.1 days. There was no significant difference of morbidity.

Conclusion : We suggest that the trans-peritoneal approach is the best way in laparoscopic procedure in term of exposure and ergonomics. Laparoscopic aortofemoral bypass grafting is feasible, safe and effective. Shortening of operating time is observed as surgeon's experience grows.

Introduction

The potential benefits of laparoscopic surgery include the reduction of postoperative morbidity and pain, less compromise of gastrointestinal function and earlier return to a normal socio-professional activity.

The concept of laparoscopy in aorto-iliac surgery is to supplement the excellent long-term results of open surgery with the advantages of minimally invasive surgery, especially reduction of surgical trauma. This series demonstrates that laparoscopic aortofemoral bypass is feasible and safe with acceptable short-term outcome.

Patients and Methods

We report a retrospective phase II non randomized continuous series concerning 58 patients (45 males, 13 females) treated surgically between March 1999 and March 2005 for an occlusive aorto-iliac disease in a single center. These patients were divided into two groups according to the laparoscopic or a median laparotomy approach used for elective aorto-bifemoral bypass grafting. The degree of occlusive disease did not intervene in the choice of approach. Only patients with ischemic cardiopathy and those with antecedents of major abdominal surgery were excluded from the laparoscopic group. Thirty patients (62 ± 8.6 years) were treated via a laparoscopic approach (Group I) and 28 patients (60.6 ± 7.8 years) were operated via a conventional median laparotomy (Group II).

In the group I, we used a laparoscopic transperitoneal and retrocolic approach as described by COGGIA (1). We first expose both femoral bifurcations via a longitudinal incision. The table is tilted on the right side with a 70° angle. We create a pneumoperitoneum with a Veress needle in the left hypochondre. Six trocars are introduced as described in Fig. 1. We use a 30° view laparoscope through trocar number 6. We approach the infrarenal aorta after dissection of the left Toldt fascia and suspension of the left kidney with a transparietal Ethylon® wire on Gerota's fascia. The left gonadic vein is followed until left renal vein, then sectioned to avoid its damage during aortic dissection. We performe this aortic dissection from the renal vein to the aortic bifurcation with preservation of inferior mesenteric artery. Lumbar branches are occluded with clip only if they bother the aortic dissection or clamping. All patients receive 5000 IU heparin intra-venously before clamping. For all cases, proximal aortic clamping, through the trochar number 1, is applied below the left renal vein. We use the trocar number 4 for distal clamping, placed proximal to the origin of the inferior mesenteric artery (Fig. 2). The vascular graft is inserted in the abdomen through the trocar number 3, after ligature of left graft limb. Under videoscopic control, the right graft limb is gently pulled through the retroperitoneum with a Crafoord clamp inserted in the right Scarpa triangle. This right limb is then clamped. This disposition allows to stabilize the graft in place during suture. The end-to-side anastomosis is accomplished with two single knots

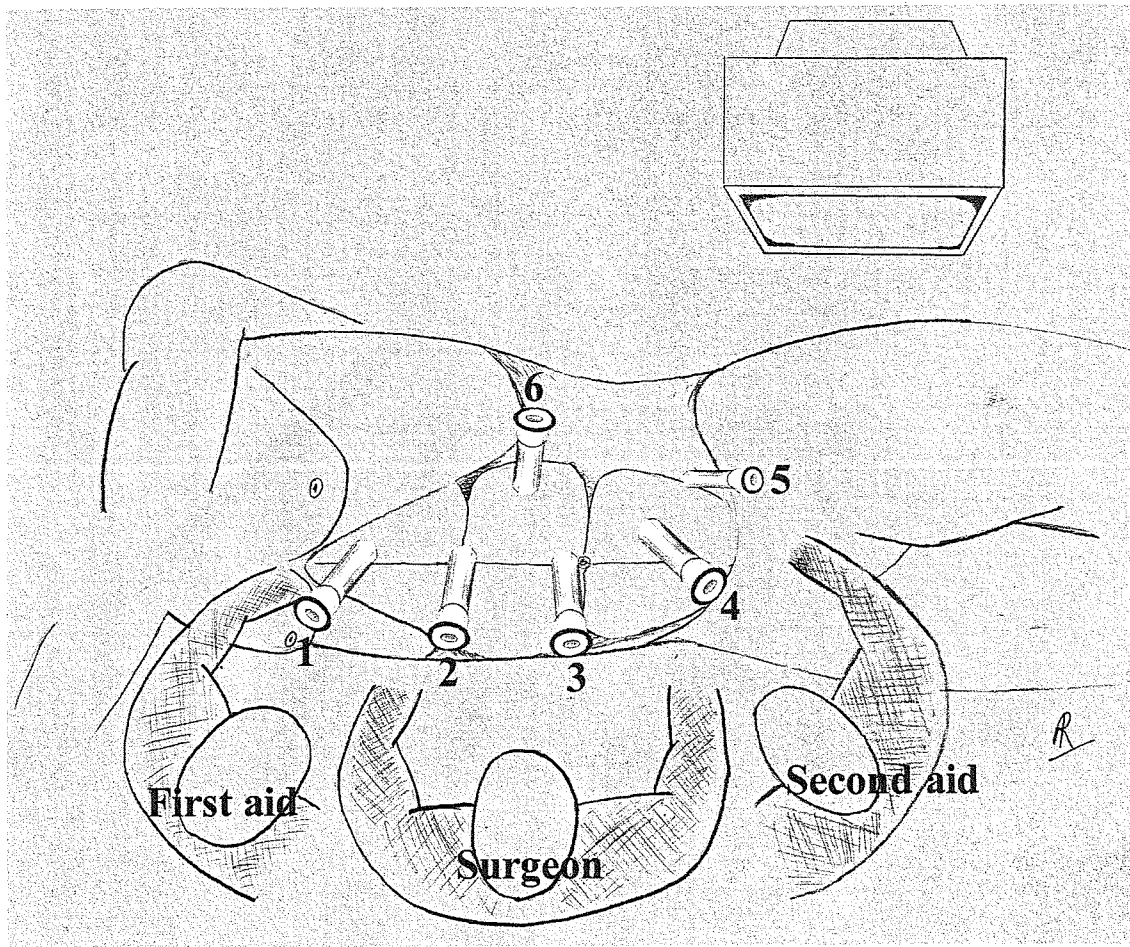


Fig. 1
Trocars site

at the distal edge of the aortotomy and with two semi-circular running sutures of Prolene® 4/0. After clamp removal, the anastomosis is controlled for tightness. The left graft limb is then grasped and pulled down to the groin. Bilateral distal end-to-side anastomosis is performed in an open technique.

In the group II, we performed aorto-bifemoral bypass through a conventional midline laparotomy. The aorta is approached after separation of Treitz's angle. Clamping and anastomosis are similar as in group I, using the same vascular graft.

All patients of group I and II stayed in the intensive-care unit during the first post-operative days.

A t-test has permitted to compare the duration of the different surgical steps (total operating time, aortic dissection, aortic clamping and aortic anastomosis) and to compare the length of stay (total hospitalisation stay, intensive care stay...). We have used a Chi-square test to compare the aortic anastomosis quality and the morbidity in both groups.

Results

In the group I ($n = 30$), 24 patients (80%) have been treated with a full-laparoscopic procedure. In six patients (20%), conversion to laparotomy was needed for calcified non-clampable aorta in three cases, exposition troubles due to ileus in one case, non-tight anastomosis in one case and inadvertent aortic branch injury in another case. We never encountered an infra-renal aorta with atherosclerotic sludge demanding an aortic exclusion and an end-to-end anastomosis.

The duration of the different operative steps of the two groups are summarized in Table I. Total intervention time for patients treated by full laparoscopic procedure (mean 244.3 ± 10.9 minutes) was significantly longer ($p < 0.0001$) than in group II (mean 136 ± 4.3 minutes). Durations of aortic dissection, aortic clamping and suture were also significantly higher in the laparoscopic group than in group II. Complementary sutures for non-tight anastomosis were needed in nine patients of the

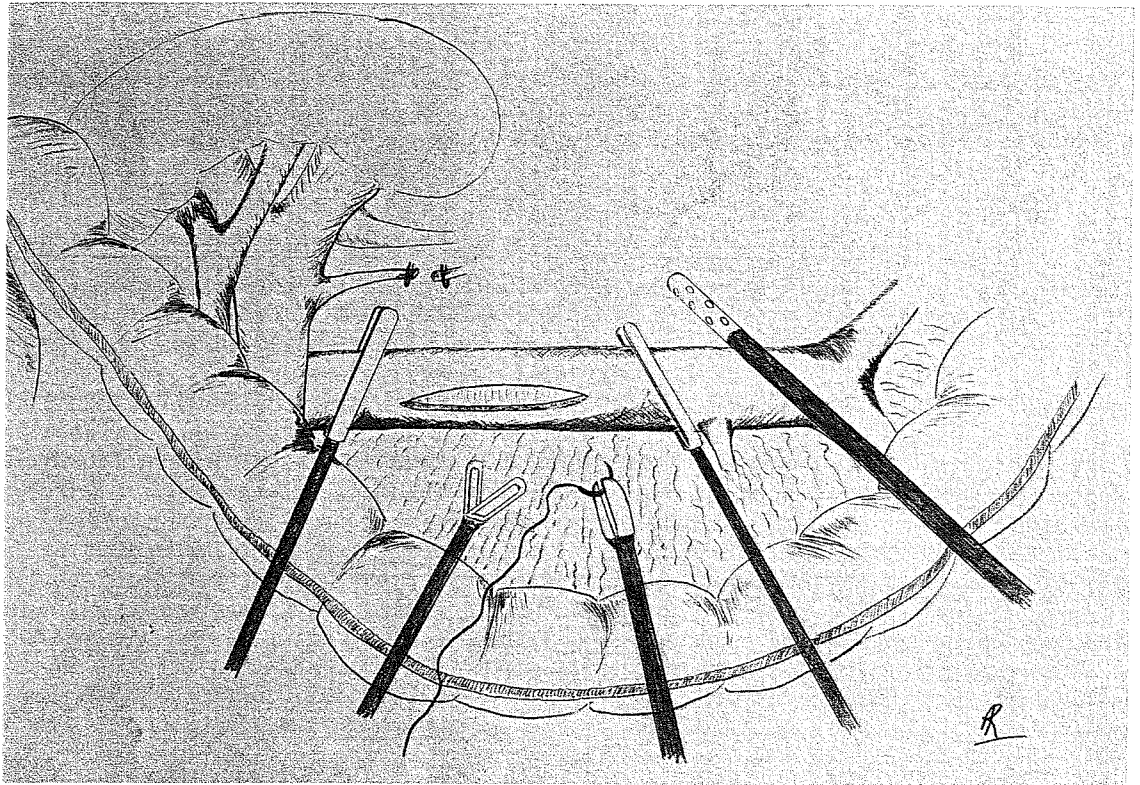


Fig. 2
Transperitoneal approach

Table I
Operative and post-operative results

	Group I : laparoscopic procedure		Group II : open procedure	
Number	n = 30 (24 males, 6 females)		n = 28 (21 males, 7 females)	
Age	62,3 ± 8,6 years		60,6 ± 7,8 years	NS
	Conversion (n = 6)	Full procedure (n = 24)		
Operative duration (minutes)	231,6 ± 23,7	244,3 ± 10,9	136,0 ± 4,3	p < 0,0001
Aortic dissection (minutes)	76,1 ± 8,7	63 ± 3,2	17,7 ± 0,7	p < 0,0001
Aortic clamping (minutes)	56,8 ± 12,9	65,7 ± 4,8	17,2 ± 0,4	p < 0,0001
Aortic anastomosis (minutes)	36,6 ± 7,7	49,6 ± 3,4	12,1 ± 0,3	p < 0,0001
Total hospitalisation (days)	12,1 ± 2,1	5,1 ± 0,3	11,5 ± 0,8	p < 0,0001
Intensive care stay (days)	4,1 ± 1,0	1,5 ± 0,1	3,0 ± 0,1	p < 0,0001
Transit recovering (days)	4,6 ± 1,6	1,3 ± 0,1	4,8 ± 0,3	p < 0,0001
Alimentation (days)	8,1 ± 1,5	2,7 ± 0,2	6,4 ± 0,4	p < 0,0001

group I (37.5%) and in nine patients (32.1%) of the group II (N.S.).

There were no deaths in both groups. The morbidity was similar in the group I and in the group II (N.S.). All complications are listed in Table II. We used cell-saver aspiration in each group and allotransfusion was necessary for only one patient of the group I and for two

patients of the open procedure group (N.S.). We note an ureteral injury in the group I which occurred as consequence of the exteriorisation of the left graft limb.

In the post-operative period, we noticed that the total in-hospital stay (mean 5.1 ± 0.3 days) and the stay in intensive care unit (mean 1.5 ± 0.1 days) were significantly shorter in the group of full laparoscopic procedure

In 13 of 24 patients who benefited totally laparoscopic aorto-bifemoral bypass-grafting, an angio-RMN control was performed after six months and one year. Every angio-RMN demonstrated an excellent graft patency without any pseudoaneurysm or anastomotic stenosis. No case of graft infection was reported.

Discussion

Yet in vascular surgery, video-assisted techniques were mainly applied in peripheral reconstructions and in venous surgery. Major procedures such as aortofemoral bypass grafting were considered to be unsuitable for minimally invasive techniques (2). For patient's safety, adequate access and the use of standard surgical instruments seemed to be essential. However, a number of surgeons promoted laparoscopic techniques to expose the aorta and iliac arteries and to minimise the surgical trauma for aortofemoral reconstructions (3-5).

Basically there are several ways to achieve this goal. Dion *et al* were among the first pioneers who succeeded in performing a laparoscopical aortofemoral bypass (3, 6).

Several experimental studies assessed the feasibility of laparoscopic aortic surgery and underlined the respective advantages of the retroperitoneal and transperitoneal laparoscopic approaches. These preliminary studies revealed the technical difficulties of dissection in the retroperitoneal approach (systematic division of the inferior mesenteric artery, left ureter injury, difficult control of bleeding). The greater omentum and bowel were shifted in the upper abdomen and the table tilted to 30° Trendelenburg position in the transperitoneal approach (7-11). However, this technique described by BARBERA *et al.* (5) gives a lesser exposure of the aorta and the bowel retraction remains difficult, even when using fan retractors. Moreover, the longstanding 30° Trendelenburg position is not always well-tolerated by the patients and, in Barbera's series, ventilatory support was necessary until post-operative day 4 due to apical atelectasis (2, 5, 12).

We prefer the transperitoneal left retrocolic approach described by COGGIA with the table tilted to the right, which enables a sufficient aortic exposure during the anastomosis. The left colon is used as shield for the intrusion of intra-abdominal organs which are shifted to the right part of the abdomen (1).

Contrary to the technique described by COGGIA (1), the surgeon and the two operator assistants are placed on the same right side of the patient. Thus, the first aid is face to the screen and in a more ergonomic position allowing an easier handling of the camera.

The technique of anastomosis uses sutures blocked over pledgets, which avoid the need of intracorporeal knots at the beginning of running sutures. This technical

point is important to avoid a direct trauma to the suture material when performing the starting knots of the running sutures. Compared with a single running suture, the separate use of four short sutures allows avoidance of the obstruction of the operative field. A laparoscopic learning on a pelvi-trainer is necessary to obtain a suture quality comparable to open surgery. In our study, there is no significant difference in additional haemostasis at the level of the aortic suture line between open and laparoscopic repair.

Nonetheless, operative and clamping times in our laparoscopic series were longer than in open surgery, but a trend toward faster laparoscopic procedures has been recorded, reflecting increasing technical experience.

In open surgery, several series have described a post-operative incisional hernia incidence between 7.4 to 12% after aortofemoral reconstruction. Laparoscopic repair avoids the need for large abdominal incisions and preserves abdominal wall integrity (13-15).

In laparoscopic surgery, bowel manipulation is limited and provides shorter postoperative ileus duration, and rapid return to general diet and ambulation. Oral feeding is usually started the day after the procedure.

KOLVENBACH *et al.* show the significant reduction in cytokine release supporting the notion that the video-assisted surgery is less invasive and induces less tissue trauma compared to conventional surgery (10).

The absence of mortality and of significant difference in terms of morbidity indicates that the laparoscopic technique is safe, providing that the surgeon accepts to convert in time. We suggest that the finding of a too calcified aorta or all other factors compromising the exposure should impose systematically a conversion to laparotomy. Finally, we noticed two cases of compartmental syndrome in the laparoscopic group. We do not think that the position of the patient on the table is responsible of this complication. The most probable factors seem to be the long operative duration and also venous stasis and low cardiac flow induced by pneumoperitoneum.

Conclusion

On the basis of the results obtained in this series, we demonstrated that laparoscopic aortofemoral bypass procedures are feasible, safe, and effective.

Nevertheless, a proper patient selection is mandatory and an important training in videoscopic suturing is required.

Growing experience and technological progress may in the future broaden the spectrum of laparoscopic vascular procedures to reduce tissue trauma, applying at the same time the established, well working principles of vascular surgery.

References

1. COGGIA M., JAVERLIAT I., DI CENTA I., COLACCHIO G., CERCEAU P., KITZIS M., GOEUAU-BRISSENIERE O. A. Total laparoscopic infrarenal aortic aneurysm repair : preliminary results. *J Vasc Surg*, 2004, **40** : 448-54.
2. ALIMI Y. S., HARTUNG O., ORSONI P., JUHAN C. Abdominal aortic laparoscopic surgery : retroperitoneal or transperitoneal approach ? *Eur J Vasc Endovasc Surg*, 2000, **19** : 21-6.
3. DION Y. M., KATKHOUDA N., ROULEAU C., AUCOIN A. Laparoscopy-assisted aortobifemoral bypass. *Surg Laparosc Endosc*, 1993, **3** : 425-9.
4. DION Y. M., GRACIA C. R. A new technique for laparoscopic aorto-bifemoral grafting in occlusive aortoiliac disease. *J Vasc Surg*, 1997, **26** : 685-92.
5. BARBERA L., MUMME A., METIN S., ZUMTOBEL V., KEMEN M. Operative results and outcome of twenty-four totally laparoscopic vascular procedures for aortoiliac occlusive disease. *J Vasc Surg*, 1998, **28** : 136-42.
6. DION Y. M., GRACIA C. R., DEMALSY J. C. Laparoscopic aortic surgery. *J Vasc Surg*, 1996, **23** : 539.
7. ALIMI Y., ORSONI P., HARTUNG O., BERDAH S., LONJON T., CADOR L., PICAUD R., JUHAN C. Laparoscopic replacement of the abdominal aorta. Experimental study in the pig. *J Mal Vasc*, 1998, **23** : 191-4. (French).
8. ALIMI Y. S., HARTUNG O., LONJON T., BARTHARES P., CADOR L., JUHAN C. Laparoscopic transperitoneal replacement of the abdominal aorta with left renal artery reimplantation : experimental study on pigs. *J Mal Vasc*, 2002, **27** : 199-204. (French).
9. KOLVENBACH R., DELING O., SCHWIERZ E., LANDERS B. Reducing the operative trauma in aortoiliac reconstructions - a prospective study to evaluate the role of video-assisted vascular surgery. *Eur J Vasc Endovasc Surg*, 1998, **15** : 483-8.
10. KOLVENBACH R., CESHIRE N., PINTER L., DA SILVA L., DELING O., KASPER A. S. Laparoscopy-assisted aneurysm resection as a minimally invasive alternative in patients unsuitable for endovascular surgery. *J Vasc Surg*, 2001, **34** : 216-21.
11. CASTRONUOVO J. J. Jr, JAMES K. V., RESNIKOFF M., MCLEAN E. R., EDOGA J. K. Laparoscopic-assisted abdominal aortic aneurysmectomy. *J Vasc Surg*, 2000, **32** : 224-33.
12. KLINE R. G., D'ANGELO A. J., CHEN M. H., HALPERN V. J., COHEN J. R. Laparoscopically assisted abdominal aortic aneurysm repair : first 20 cases. *J Vasc Surg*, 1998, **27** : 81-7 ; discussion 88.
13. RAFFETTO J. D., CHEUNG Y., FISHER J. B., CANTELMO N. L., WATKINS M. T., LAMORTE W. W., MENZOIAN J. O. Incisional and abdominal wall hernias in patients with aneurysm or occlusive aortic disease. *J Vasc Surg*, 2003, **37** : 1150-4.
14. ADYE B., LUNA G. Incidence of abdominal wall hernia in aortic surgery. *Am J Surg*, 1998, **175** : 400-2.
15. LIAPIS C. D., DIMITROULIS D. A., KAKISIS J. D., NIKOLAOU A. N., SKANDALAKIS P., DASKALOPOULOS M., KOSTAKIS A. G. Incidence of incisional hernias in patients operated on for aneurysm or occlusive disease. *Am Surg*, 2004, **70** : 550-2.

A. Rouers, M.D.
 Rue de l'espérance 250
 B-4000 Liège
 Tel. : 0032-495 25 08 54
 E-mail : a.rouers@skynet.be