

This is an Open Access article licensed under the terms of the Creative Commons Attribution-NonCommercial-NoDerivs 3.0 License (www.karger.com/OA-license), applicable to the online version of the article only. Distribution for non-commercial purposes only.

Autoimmunity-Related Granulomatous Dermatitis in Association with Hepatitis

Grégory Szepetiuk^a Marianne Lesuisse^a
Gérald E. Piérard^b Pascale Quatresooz^b
Claudine Piérard-Franchimont^b

^aDepartment of Dermatology, Regional Hospital Citadelle, and ^bDepartment of Dermatopathology, University Hospital of Liège, Liège, Belgium

Key Words

Granulomatous dermatitis · Autoimmunity · Hepatitis

Abstract

Aim: Both interstitial granulomatous dermatitis (IGD) and palisaded neutrophilic granulomatous dermatitis (PNGD) are rare disorders typically associated with systemic autoimmune conditions. They probably represent different aspects of a disease spectrum encompassing the concept of autoimmunity-related granulomatous dermatitis (ARGD).

Case Report: A 61-year-old woman presented with ARGD and autoimmune hepatitis. The clinical presentation suggested PNGD, while histopathology was consistent with IGD.

Discussion: The association of ARGD with autoimmune hepatitis is apparently a rare event. The present case shows that the clinicopathological correlation in ARGD does not always clearly fit with the classical presentations of IGD or PNGD.

Introduction

A number of autoimmune conditions are associated with cutaneous symptoms. Interstitial granulomatous dermatitis (IGD) is one of these skin disorders [1–3]. The typical clinical presentation corresponds to a linear rope present on the trunk and axillae. On histopathological examination, IGD is characterized by a sparse palisaded histiocytic infiltrate with little neutrophilic debris and eosinophils associated with a necrobiotic aspect of the collagen matrix [4].

In the literature, there is some overlap between IGD and palisaded neutrophilic granulomatous dermatitis (PNGD). Lesions of PNGD typically correspond to papules occasionally admixed with small crusts on the elbows. A dense neutrophilic and

interstitial histiocytic infiltrate is sometimes associated with vasculitis. Other related disorders include rheumatoid papules, Churg-Strauss granuloma, superficial ulcerating rheumatoid necrobiosis, necrobiotic granuloma, palisading granuloma, cutaneous extravascular necrotizing granuloma, and rheumatoid neutrophilic dermatitis [5].

Here, we report a patient who presented with granulomatous dermatitis in combination with autoimmune hepatitis. Such an association has apparently been reported only once before [6].

Case Report

A 61-year-old woman presented with skin lesions over the elbows and the left thenar region. They corresponded to erythematous and discrete hyperkeratotic papules which had been present for a few weeks (fig. 1a, b). There was no pruritus.

A skin biopsy was performed. Despite the clinical aspect, the histopathological presentation was consistent with IGD. The dermis contained a moderate superficial perivascular cell infiltrate exhibiting some interstitial extension. A few multinuclear giant cells were recognized. Discrete deposits of acid polysaccharides were identified by colloidal iron stain. Immunohistochemistry revealed the presence of CD3+ T lymphocytes predominating in the perivascular area (fig. 2a). They were associated with CD68+ and MAC387+ histiocytes as well as factor XIIIa+ dermal dendrocytes (DD1). The patterns of histiocyte distribution were quite distinct regarding cell differentiation. The MAC387+ cells were rather clustered in the vicinity of vessels (fig. 2b), where they were intermingled with lymphocytes. By contrast, CD68+ cells were interspersed between collagen bundles (fig. 2c). The pattern of DD1 distribution was similar to that of CD68+ histiocytes (fig. 2d).

The past medical history of the patient revealed an uneventful cholecystectomy. She presently suffered from allergic asthma. A discretely developing autoimmune hepatitis had been diagnosed 9 years ago. It was characterized by the elevation of anti-smooth muscle antibodies (1:160) and antinuclear antibodies (1:1,280). There were no detectable antibodies directed against nuclear antigens, keyhole limpet hemocyanin and mitochondria. Hepatitis B and C serologies were negative.

At the time of presentation, the patient's liver tests were in the normal range. She had never received any treatment to control the autoimmune hepatitis. She received a topical corticosteroid treatment that temporarily improved the skin lesions. However, they recurred a few months later, and some other lesions appeared on the thighs.

Discussion

In some cases, there is a mismatch between the clinical presentation and the histopathological patterns of IGD and PNGD [7]. Indeed, these two conditions possibly represent a continuum or progression of a single disease process corresponding to autoimmunity-related granulomatous dermatitis (ARGD) [6, 8]. The clinical associations between ARGD, autoimmune disease and lymphoproliferative disorders have been intermixed between both IGD and PNGD diagnoses in the literature [6, 9–14]. The underlying disorder is sometimes not diagnosed at the time of the skin manifestations [15]. IGD and PNGD are probably related disorders in the spectrum of ARGD. It is acknowledged that the inflammatory cell infiltrate is sparse to moderate in IGD, while PNGD has a dense neutrophilic and interstitial histiocytic infiltrate [5]. Some unusual variants have been reported [16].

To the best of our knowledge, only a single case of IGD with autoimmune hepatitis [17] association has been reported so far [6]. Some other autoimmune comorbidities

including arthritis, antiphospholipid syndrome [18, 19] and hematologic malignancy [20] have been reported in association with IGD. In addition, interstitial granulomatous drug reactions have been linked to TNF inhibitors, ACE inhibitors, diuretics [21–28] and soy products in food [29]. This eventuality was ruled out in our patient.

Disclosure Statement

The authors have no conflicts of interest to declare.

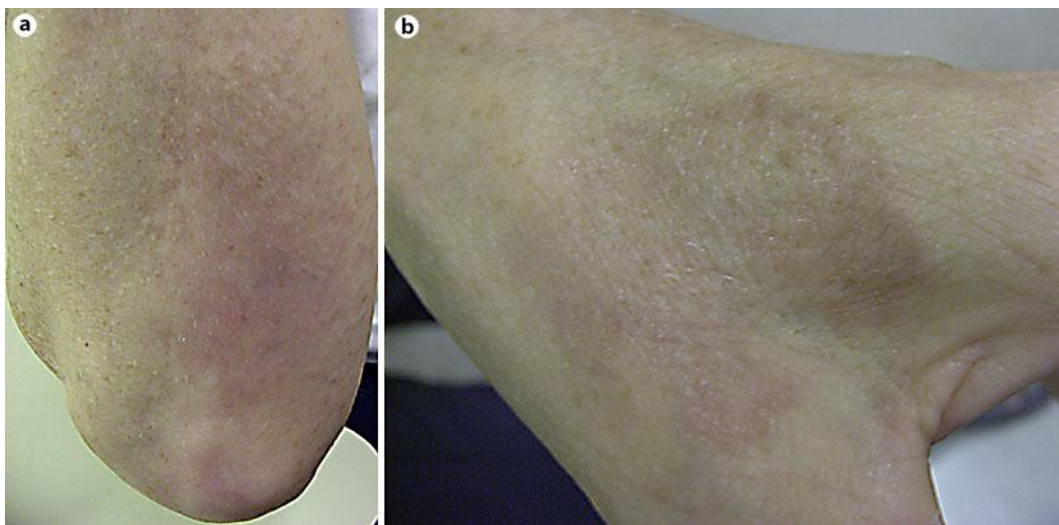


Fig. 1. Clinical presentation of ARGD. **a** Multiple papules in a plaque on the elbow. **b** Multiple papules grouped on the thenar region.

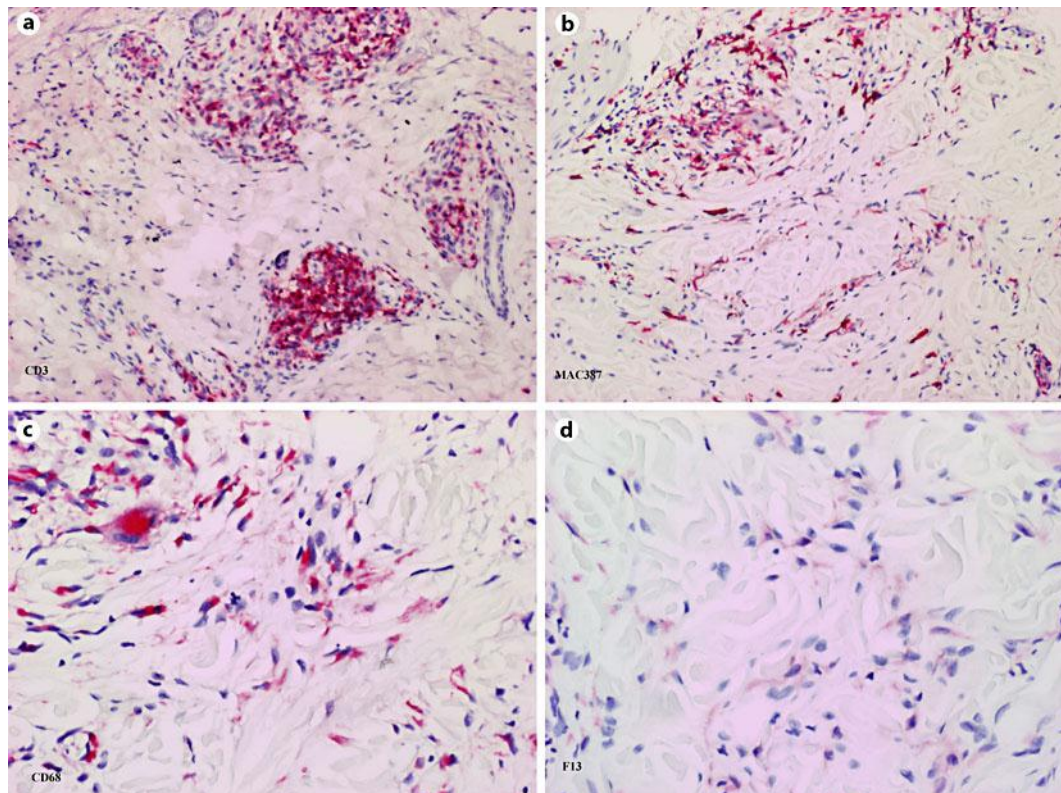


Fig. 2. Immunohistopathology of an ARGD papule. **a** Perivascular clusters of CD3+ lymphocytes ($\times 200$). **b** Perivascular distribution of MAC387+ macrophages ($\times 200$). **c** Interstitial spread of CD68+ macrophages ($\times 200$). **d** Interstitial presence of factor XIIIa+ DD1 ($\times 200$).

References

- 1 Tomasini C, Pippione M: Interstitial granulomatous dermatitis with plaques. *J Am Acad Dermatol* 2002;46:892–899.
- 2 Lee HW, Chang SE, Lee MW, Choi JH, Moon KC, Koh JK: Interstitial granulomatous dermatitis with plaques associated with antiphospholipid syndrome. *Br J Dermatol* 2005;152:814–816.
- 3 Felcht M, Faulhaber J, Göttmann U, Koenen W, Goerdts S, Goebeler M: Interstitial granulomatous dermatitis (Ackerman's syndrome). *Eur J Dermatol* 2010;20:661–662.
- 4 Peroni A, Colato C, Schena D, Gisondi P, Girolomoni G: Interstitial granulomatous dermatitis: a distinct entity with characteristic histological and clinical pattern. *Br J Dermatol* 2011; Epub ahead of print.
- 5 Hawryluk EB, Izikson L, English JC 3rd: Non-infectious granulomatous diseases of the skin and their associated systemic diseases: an evidence-based update to important clinical questions. *Am J Clin Dermatol* 2010;11:171–181.
- 6 Lee KJ, Lee ES, Lee DY, Jang KT: Interstitial granulomatous dermatitis associated with autoimmune hepatitis. *J Eur Acad Dermatol Venereol* 2007;21:684–685.
- 7 Aloï F, Tomasini C, Pippione M: Interstitial granulomatous dermatitis with plaques. *Am J Dermatopathol* 1999;21:320–323.
- 8 Chu P, Connolly MK, LeBoit PE: The histopathologic spectrum of palisaded neutrophilic and granulomatous dermatitis in patients with collagen vascular disease. *Arch Dermatol* 1994;130:1278–1283.

- 9 Bremner R, Simpson E, White CR, Morrison L, Deodhar A: Palisaded neutrophilic and granulomatous dermatitis: an unusual cutaneous manifestation of immune-mediated disorders. *Semin Arthr Rheum* 2004;34:610–616.
- 10 Germanas JP, Mehrabi D, Carder KR: Palisaded neutrophilic granulomatous dermatitis in a 12-year-old girl with systemic lupus erythematosus. *J Am Acad Dermatol* 2006;55:S60–S62.
- 11 Asahina A, Fujita H, Fukunaga Y, Kenmochi Y, Ikenaka T, Mitomi M: Early lesion of palisaded neutrophilic granulomatous dermatitis in ulcerative colitis. *Eur J Dermatol* 2007;17:234–237.
- 12 Biswas A, Chittari K, Gey van Pittius D, Stephens M, Tan BB: Palisaded neutrophilic and granulomatous dermatitis in a child with type I diabetes mellitus and celiac disease. *Br J Dermatol* 2008;159:488–489.
- 13 Hantash BM, Chiang D, Kohler S, Florentino D: Palisaded neutrophilic and granulomatous dermatitis associated with limited systemic sclerosis. *J Am Acad Dermatol* 2008;58:661–664.
- 14 Garcia-Rabasco A, Esteve-Martinez A, Zaragoza-Ninet V, Sanchez-Carazo JL, Alegre-de-Miquel V: Interstitial granulomatous dermatitis in a patient with lupus erythematosus. *Am J Dermatopathol* 2011;33:871–872.
- 15 Misago N, Shinoda Y, Tago M, Narisawa Y: Palisaded neutrophilic granulomatous dermatitis with leucocytoclastic vasculitis in a patient without any underlying systemic disease detected to date. *J Cutan Pathol* 2010;37:1092–1097.
- 16 Patsatsi A, Kyriakou A, Triantafyllidou E, Sotiriadis D: Interstitial granulomatous dermatitis: another clinical variant. *Case Rep Dermatol* 2011;3:195–200.
- 17 Albert JC: Autoimmune hepatitis; in Feldman M, Tschumy WO, Friedman LS, et al. (eds): *Sleisenger and Fordtran's Gastrointestinal and Liver Disease*, ed 7. Philadelphia, Saunders, 2002, pp 1471–1472.
- 18 Verneuil L, Domp Martin A, Comoz F, Pasquier CJ, Leroy D: Interstitial granulomatous dermatitis with cutaneous cords and arthritis: a disorder associated with autoantibodies. *J Acad Dermatol* 2001;45:286–291.
- 19 Busquets-Perez N, Narvaez J, Valverde-Garcia J: Interstitial granulomatous dermatitis with arthritis (Ackerman syndrome). *J Rheumatol* 2006;33:1207–1209.
- 20 Swing DC Jr, Sheehan DJ, Sanguenza OP, Woodruff RW: Interstitial granulomatous dermatitis secondary to acute promyelocytic leukemia. *Am J Dermatopathol* 2008;30:197–199.
- 21 Magro CM, Crowson AN, Schapiro BL: The interstitial granulomatous drug reaction: a distinctive clinical and pathological entity. *J Cutan Pathol* 1998;25:72–78.
- 22 Perrin C, Lacour JP, Michiels JF: Interstitial granulomatous drug reaction with a histological pattern of interstitial granulomatous dermatitis. *Am J Dermatopathol* 2001;23:295–298.
- 23 Fujita Y, Shimizu T, Shimizu H: A case of interstitial granulomatous drug reaction due to sennoside. *Br J Dermatol* 2004;150:1035–1037.
- 24 Lee HW, Yun WJ, Lee MW, Choi JH, Moon KC, Koh JK: Interstitial granulomatous drug reaction caused by Chinese herbal medication. *J Am Acad Dermatol* 2005;52:712–713.
- 25 Deng A, Harvey V, Sina B, Strobel D, Badros A, Junkins-Hopkins JM, Samuels A, Oghilikhan M, Gaspari A: Interstitial granulomatous dermatitis associated with the use of tumor necrosis factor alpha inhibitors. *Arch Dermatol* 2006;142:198–202.
- 26 Chen YC, Hsiao CH, Tsai TF: Interstitial granulomatous drug reaction presenting as erythroderma: remission after discontinuation of enalapril maleate. *Br J Dermatol* 2008;158:1143–1145.
- 27 Groves C, McMenamin ME, Casey M, Bames L: Interstitial granulomatous reaction to strontium ranelate. *Arch Dermatol* 2008;144:268–269.
- 28 Marcollo Pini A, Kerl K, Kamarachev J, French LE, Hofbauer GF: Interstitial granulomatous drug reaction following intravenous ganciclovir. *Br J Dermatol* 2008;158:1391–1393.
- 29 Dyson SW, Hirsch A, Jaworsky C: Interstitial granulomatous dermatitis secondary to soy. *J Am Acad Dermatol* 2004;51:S105–S107.