

Abdominal aortic aneurysm

N Sakalihasan, R Limet, O D Defawe

Lancet 2005; 365: 1577–89

See [Personal Account](#) page 1590

Abdominal aortic aneurysms cause 1·3% of all deaths among men aged 65–85 years in developed countries. These aneurysms are typically asymptomatic until the catastrophic event of rupture. Repair of large or symptomatic aneurysms by open surgery or endovascular repair is recommended, whereas repair of small abdominal aortic aneurysms does not provide a significant benefit. Abdominal aortic aneurysm is linked to the degradation of the elastic media of the atheromatous aorta. An inflammatory cell infiltrate, neovascularisation, and production and activation of various proteases and cytokines contribute to the development of this disorder, although the underlying mechanisms are unknown. In this Seminar, we aim to provide an updated review of the pathophysiology, current and new diagnostic procedures, assessment, and treatment of abdominal aortic aneurysm to provide family practitioners with a working knowledge of this disorder.

Department of Cardiovascular and Thoracic Surgery (N Sakalihasan MD, Prof R Limet MD), and Laboratory of Connective Tissues Biology (O D Defawe PhD), University of Liège, Sart-Tilman 4000 Liège, Belgium

Correspondence to: Prof R Limet rlimet@ulg.ac.be

Abdominal aortic aneurysms are a substantial burden on health care in more developed countries, occurring mostly among men older than 65 years of age. The disorder is the thirteenth leading cause of death in the USA.¹ Although some patients have vague symptoms, such as back pain or abdominal pain, most abdominal aneurysms are asymptomatic until rupture, which leads to death in 65% of patients.² An increased awareness of the characteristics of abdominal aortic aneurysm by first-contact practitioners might reduce the risk of a fatal outcome with this disorder. Here, we review the key aspects of this disorder, including epidemiology, pathogenesis, diagnosis, and treatment.

Terminology

Aneurysm derives from the Greek ανευρυσμα (aneurysma), meaning widening, and can be defined as a permanent and irreversible localised dilatation of a vessel. Although an aneurysm occurring in any portion of the infradiaphragmatic aorta could be termed an abdominal aortic aneurysm, common practice restricts this definition to an aneurysm of the infrarenal aorta. Aneurysms involving the renal ostia (intrarenal, suprarenal aorta) are also included under this term. The normal diameter of the abdominal aorta varies with age, sex, and bodyweight,³ and decreases progressively from its entry into the abdominal cavity to the iliac bifurcation. In elderly men, the infrarenal abdominal aortic diameter is between 15 mm and 24 mm.⁴ McGregor and colleagues⁵ proposed the definition of an abdominal aortic aneurysm as an aorta with an infrarenal diameter greater than 30 mm. In 1991, the Society for Vascular Surgery and the International Society for Cardiovascular Surgery Ad Hoc Committee on Standards in Reporting proposed as a criterion that the infrarenal diameter should be 1·5 times the expected normal diameter.⁶ There is no definite consensus on the definition of abdominal aortic aneurysm; however, the disorder is conventionally diagnosed if the aortic diameter is 30 mm or more. This dilatation affects the three layers of the vascular tunic; otherwise, the dilatation is called a pseudoaneurysm. Most aneurysms are fusiform since

the whole circumference of the artery is affected, whereas an aneurysm that includes only a part of the circumference is termed saccular. An inflammatory aneurysm is characterised by extensive perianeurysmal and retroperitoneal fibrosis and dense adhesions to adjacent abdominal organs.

Epidemiology

The incidence of abdominal aortic aneurysms has increased during the past two decades, due in part to the ageing of the population, the rise in the number of smokers, the introduction of screening programmes, and improved diagnostic tools. Rupture of these aneurysms causes about 8000 deaths per year in the UK and roughly 15 000 per year in the USA.^{1,7} The disorder is more common in men than in women, with prevalence rates estimated at between 1·3% and 8·9% in men and between 1·0% and 2·2% in women.^{8–12} However, since smoking is one of the most important risk factors for abdominal aortic aneurysm¹³ and the number of female smokers is rising,¹⁴ the sex ratios for the prevalence of the disorder will probably change in the future.^{10,11} Most aneurysms discovered by screening are of small size and do not need immediate surgical repair.^{15–17} However, they can become enlarged with time at a mean rate that is initially slow and then increases exponentially.¹⁸ In general, the risk of rupture increases as the diameter of the aneurysm enlarges.^{14,19,20} The overall mortality rate for patients with ruptured abdominal aortic aneurysms is between 65% and 85%,^{2,7} and about half of deaths attributed to rupture occur before the patient reaches the surgical room.^{21,22}

Search strategy and selection criteria

The primary source of references included MEDLINE searches for recent literature with many keywords for both clinical and basic research topics. We largely selected publications in the past 5 years, but did not exclude commonly referenced and highly regarded older publications. We also reviewed books and review articles pertaining to abdominal aortic aneurysm.

Aetiology and risk factors

There are many causes of aneurysmal dilatation, but few abdominal aortic aneurysms are the direct consequence of specific causes such as trauma, acute infection (brucellosis, salmonellosis), chronic infection (tuberculosis), inflammatory diseases (Behçet and Takayasu disease),^{23,24} and connective tissue disorders (Marfan Syndrome, Ehlers-Danlos type IV).²⁵ Thus, most abdominal aortic aneurysms are called non-specific.⁶ Moreover, because this disorder is invariably associated with severe atherosclerotic damage of the aortic wall, it has been traditionally regarded as a consequence of atherosclerosis.²⁶ This conventional view has been increasingly challenged in recent years. Clinical and basic research studies indicate that aneurysms arise through pathogenic mechanisms that differ, at least in part, from those responsible for athero-occlusive disease.^{27,28} Much published work lends support to this concept.^{29,30} Defawe and colleagues³¹ showed that two physiological inhibitors of proteases (TIMP-2 and PAI-1) were expressed less in abdominal aortic aneurysms than in athero-occlusive disease, suggesting a significant role for protease inhibitors during the divergent evolution of the initial atherosclerotic plaque towards either abdominal aortic aneurysm or athero-occlusive disease. Moreover, since not all patients with atherosclerosis develop an abdominal aortic aneurysm, even if atherosclerosis does have a role in the pathogenesis of the disorder, additional factors are probably involved in aneurysm development.

There is a strong clinical association between tobacco smoking and aneurysm development.^{12,14,32,33} The prevalence of abdominal aortic aneurysms in tobacco smokers is more than four times that in life-long non-smokers.¹² A report that compared relative risks for different diseases in chronic cigarette smokers showed that the risk of developing abdominal aortic aneurysms is three-fold greater than the risk for developing coronary artery disease and nearly five-fold greater than the risk for cerebrovascular disease.³⁴ Based on these clinical observations, chronic tobacco smoking is probably the single most important environmental risk factor for development and progression of aortic aneurysms. The rate of growth of these aneurysms has been reported to be higher in current smokers than in non-smokers (2.83 mm per year vs 2.53 mm per year, respectively).³⁵ The mechanisms by which smoking could promote aneurysm formation remain unknown and are being investigated.³⁶ Beside tobacco smoking, other risk factors include male sex, age, hypertension, chronic obstructive pulmonary disease, hyperlipidaemia, and family history of the disorder.^{10–12,35,37}

The familial clustering of abdominal aortic aneurysms has drawn attention to non-environmental risk factors for the disorder. Since the first case report by Clifton in 1977,³⁸ several studies have lent support to the notion that abdominal aortic aneurysms are one of the most

common familial diseases. The frequency of the disorder in first-degree relatives is 15–19% compared with only 1–3% in unrelated patients.³⁹ Familial abdominal aortic aneurysms are more frequently found when the proband is a female and rupture occurs more often and at a younger age than with sporadic aneurysms.^{40,41} Two research groups have attempted segregation analysis of abdominal aortic aneurysm. Majumder and co-workers,⁴² in a segregation analysis based on 91 probands and including 13 familial cases, showed that the most likely genetic model was an autosomal locus with a recessive inherited gene for the disorder. An analysis undertaken in 313 pedigrees, by Verloes and colleagues,⁴⁰ provided evidence for a single autosomal dominant inheritance. A multinational study identified 233 families with 653 affected members;³⁹ the inheritance mode was autosomal recessive in 72% of families and autosomal dominant in 25% of families. Linkage between aortic aneurysm growth and a 4G/5G polymorphism in the plasminogen activator inhibitor (PAI-1) promoter has been recorded.^{43,44} Linkage of abdominal aortic aneurysm frequency to a locus on chromosome 19q13 has also been reported.⁴⁵ Several candidate genes are present in this region of chromosome 19, such as LDL receptor-related protein 3 (LRP3), which is particularly relevant since conditional knockout mice for LRP1, another member of this gene family, developed atherosclerosis and arterial aneurysm.⁴⁶

As discussed by Powell,⁴⁷ familial clustering of abdominal aortic aneurysms is probably not due to chance alone. An underlying cause could be particular genetic background, as mentioned before, but probably in conjunction with environmental factors. In comparison, clear evidence was reported for the interaction between smoking and polymorphic variation in the nitric oxide synthase gene for the development of carotid artery disease.⁴⁸ Familial clustering of abdominal aortic aneurysms could also result from exposure to common environmental factors, such as tobacco smoke. Parental smoking has been suggested to underlie familial clustering.⁴⁷ Additionally, women who smoke tend to have infants of low birthweight who have a high risk of developing coronary diseases later in life.⁴⁹

Pathophysiology

The development of abdominal aortic aneurysms is clearly associated with alterations of the connective tissue in the aortic wall. Elastic fibres and fibrillar collagens are the main determinants of the mechanical properties of the aorta. Elastin and associated proteins form a network of elastic fibres responsible for the viscoelastic properties. Elastin is stabilised by cross-links between the molecules and can be degraded by specific proteases that display elastase activity. Elastic fibres associated with smooth muscle cells are most abundant in the media of the aortic wall. Collagen, in polymeric form, is also a significant component of the media and

the surrounding fibrous adventitia. Two specific types of fibrillar collagen (types I and III) provide tensile strength and help maintain the structural integrity of the vascular wall. Beside elastic and collagen fibres, proteoglycans are also implicated in the organisation of the aortic wall.⁵⁰

One of the most important histological features of aneurysmal tissue is the fragmentation of the elastic fibres and a decreased concentration of elastin during aneurysm growth until the time of rupture.^{51–53} The loss of elastic fibres seems to be an early step in aneurysm formation.⁵⁴ Although elastin fragmentation and medial attenuation are the most important characteristics of the wall of an aneurysm, the adventitial tissue, in which collagen is predominant, is responsible for the resistance of the aorta in the absence of medial elastin. According to Dobrin and Mrkvicka,⁵⁴ collagen degradation is the ultimate cause of rupture. Increased collagen turnover has been reported in abdominal aortic aneurysms in human beings,⁵⁵ suggesting the existence of a repair process as shown in animal models.⁵⁶ An imbalance between collagen degradation and its synthesis could create the catabolic conditions that lead to rupture.

The alteration of elastin and collagen in the aortic wall is dependent on production of proteases by resident vascular wall cells (medial smooth muscle cells and adventitial fibroblasts) and by the cells of the lymphomonocytic infiltrate. These inflammatory cells in the media and adventitia come from the aortic blood and from a medial neovascularisation, which characterises abdominal aortic aneurysms.^{57–59} Leucocyte recruitment into the aortic wall is promoted by elastin degradation fragments as well as proinflammatory cytokines, chemokines, and prostaglandin derivatives produced by both the resident mesenchymal cells and the inflammatory cells themselves.^{60–63} Immunity has been suggested to play a part in the development of abdominal aortic aneurysm.^{64,65} Elastic and collagen fibres are degraded by proteolytic enzymes mostly represented by matrix metalloproteinases (MMP) locally activated by either other MMP or by plasmin generated by plasminogen activators.^{30,31,66–79} The role of MMP and plasmin in the development of abdominal aortic aneurysms has been confirmed in animal models.^{70,76,77,80–84} The tissue inhibitors of matrix metalloproteinases (TIMP) are also increased in the wall of the aneurysm.⁶⁹ However, the balance between proteases and antiproteases seems to be in favour of proteolysis.^{31,85,86} The importance of this imbalance in aneurysm development is reinforced by experimental studies in which the antiproteases are overexpressed or genetically inactivated.^{87–90}

Besides rarefaction of its extracellular matrix, the elastic media also undergoes a reduction in the density of smooth muscle cells, which is regarded as a key event in the development of abdominal aortic aneurysms.⁹¹ Smooth muscle cells participate in vascular wall

remodelling through localised expression of various extracellular matrix proteins as well as proteases and their inhibitors. Additionally, smooth muscle cells have a protective role against inflammation and proteolysis.⁹² In-vitro aortic smooth-muscle cells have been shown to produce less monocyte chemoattractant protein-1 (MCP-1), a major inflammatory mediator in abdominal aortic aneurysms, under cyclic stretching than with static culture, which lends support to the notion of a protective paracrine function of smooth muscle cells.⁹³

The development of abdominal aortic aneurysms is also associated with a mural thrombus in most patients. By contrast with arterial occlusive diseases, blood flow is maintained in aortic aneurysms resulting in a persistent remodelling activity of the components of the thrombus. Evolution of aneurysmal diameter has been reported to correlate with plasma markers of fibrin formation and degradation⁹⁴ as well as the circulating complex plasmin- α_2 -anti-plasmin⁹⁵ potentially related to thrombus turnover. The role of an adherent thrombus in

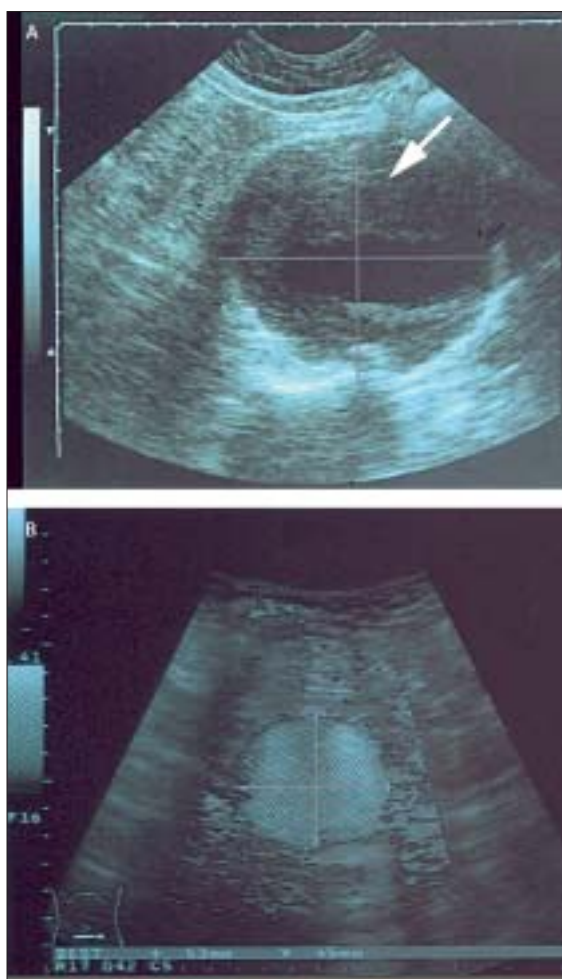

Figure 1: Ultrasonography of an infrarenal aortic aneurysm
A: Sagittal section with parietal thrombus (arrow). B: Transaxial section without thrombus.

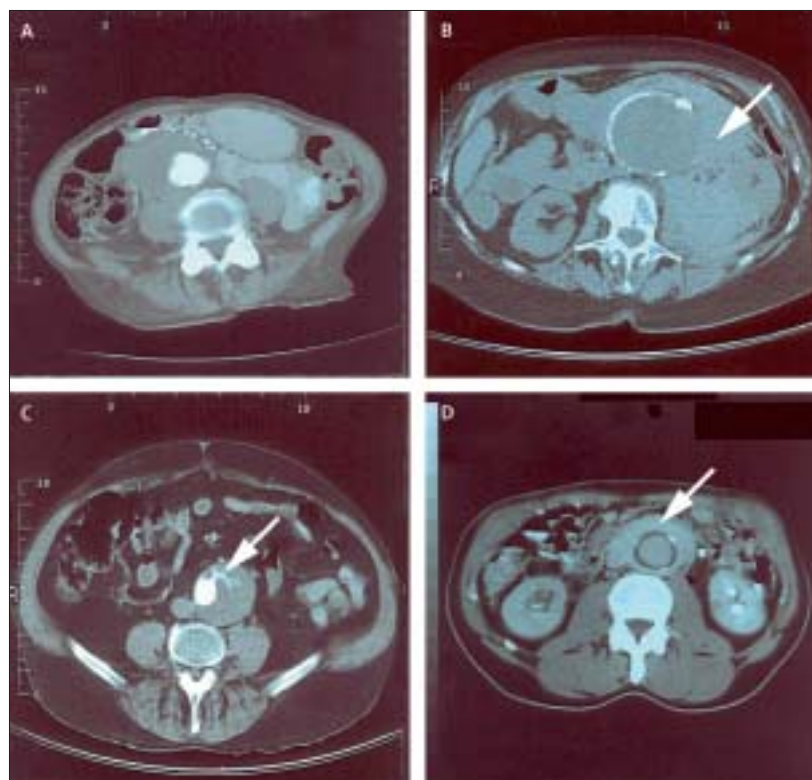


Figure 2: CT images of abdominal aortic aneurysms

A: Scan slices of a dextroconvex aneurysm in a female patient admitted with diagnosis of cholecystitis. B: Retroperitoneal haematoma (arrow) from a ruptured aneurysm. C: Bleeding in a parietal thrombus (arrow) observed in a symptomatic small aneurysm. D: Para-aortic fibrosis associated with ureterohydronephrosis.

aneurysmal degeneration has also been investigated. Although the thrombus can substantially reduce aneurysmal wall stress, its increasing thickness leads to local hypoxia at the inner layer of the media, which can induce increased medial neovascularisation and inflammation.⁹⁶ The implication of the thrombus in aneurysmal evolution in terms of a source of proteases has also been proposed after an initial report of an enrichment of MMP-9 (gelatinase B) in the thrombus.⁶⁸ Furthermore, Fontaine and colleagues⁹⁷ have provided evidence of polymorphonuclear neutrophils (PMN) trapping and storing MMP-9 within the aneurysmal thrombus. They also showed that plasminogen and its activator (u-PA) are present in the thrombus in the aneurysm wall, which might result in local generation of plasmin, an activator of MMP.

Methods of diagnosis

The examination for a pulsatile mass should be done by bimanual palpation of the supraumbilical area. Sensitivity of abdominal palpation for detection of abdominal aortic aneurysms increases with the diameter of the lesion: 61% for aneurysms 3.0–3.9 cm, 69% for those 4.0–4.9 cm, and 82% for those 5.0 cm and larger. The palpation sensitivity also depends inversely on the size of the abdominal waistline.⁹⁸

Abdominal standard radiography can incidentally be diagnostic, mainly in the transverse view, if calcifications are present in the aortic wall, which allows visualisation of dilatation. However, standard radiography is not the method of choice for the diagnosis of abdominal aortic aneurysms. Ultrasonography is the simplest and cheapest diagnostic procedure and can accurately measure the size of the aorta in longitudinal as well as in anteroposterior and transverse directions (figure 1) with an accuracy of 3 mm.⁹⁹ Ultrasonography is largely used not only for the initial assessment and the follow-up

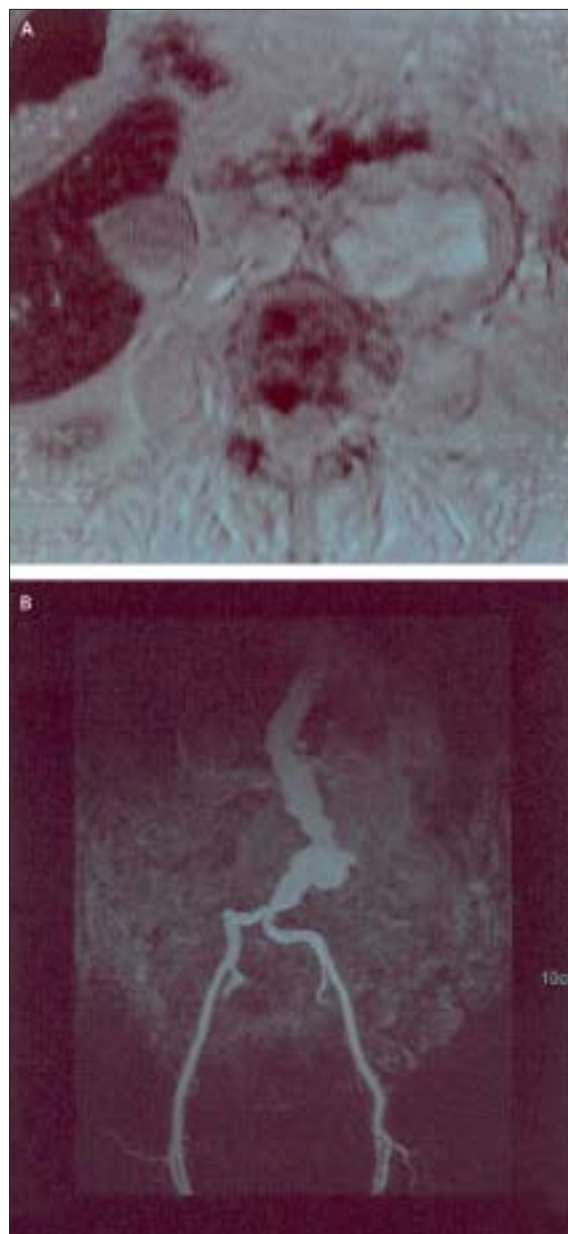


Figure 3: MRI of an abdominal aortic aneurysm

A: 2D T1-weight post contrast MRI. B: Gadolinium-enhanced MRA in the same patient showing tortuous aorta and iliac arteries.

surveillance, but also for population screening. If the diameter of the aneurysm is such that surgical procedure is contemplated, CT is the next step to help determine which treatment should be used (endovascular or open surgery) (figure 2). Serial CT scans can be used to visualise the proximal neck (the transition between the normal and aneurysmal aorta), the extension to the iliac arteries, and the patency of the visceral arteries. They can also measure the thickness of the mural thrombus. Venous anomalies that can be hazardous during the access to the neck are also clearly indicated (left vena cava, posterior left renal vein). CT can also display the presence of blood within the thrombus (crescent sign), which has been regarded by some groups as a predictive marker of imminent rupture^{100–102} (figure 2 C). In case of inflammatory aneurysm, CT allows estimation of the thickness of the aortic wall outside of the calcified deposits and visualisation of the presence of para-aortic fibrosis potentially associated with ureterohydronephrosis (figure 2 D). Extravasation of contrast material is diagnostic of aneurysm rupture. With three-dimensional imaging, helical CT and CT angiography can provide additional anatomical details, especially useful if endovascular procedure is considered.¹⁰³ MRI, combined with magnetic resonance angiography (MRA) (figure 3), is of little harm since non-nephrotoxic contrast material (eg, gadolinium) is used, whereas conventional arteriography uses nephrotoxic contrast material, which can lead to renal failure and distal embolisation. Because of the steady development of MRA and CT angiographies, there will be hardly any place left for conventional aortography during preoperative assessment of the disorder. The use of conventional aortography is mainly restricted to the placement of endovascular devices or when a horse-shoe kidney is diagnosed.

Clinical presentation

Unruptured abdominal aortic aneurysms

Non-ruptured aneurysms are generally asymptomatic in most patients. They are essentially diagnosed incidentally during extensive clinical examination, especially in patients who complain of coronary, peripheral, or cerebrovascular diseases, or during population screening.²² Fleming and co-workers¹⁰⁴ reported that population screening in men aged 65–74 years significantly reduces mortality related to the disorder.

Non-ruptured aneurysms might exceptionally be diagnosed after complications, such as distal embolisation and, even more rarely, acute thrombosis. Minor and less specific symptoms include chronic vague abdominal and back pain, which can result from direct pressure or distension of adjacent structures. Recent onset of severe lumbar pain has been deemed to indicate impending rupture. Ureterohydronephrosis might also take place, especially if the aneurysm is inflammatory or involves the iliac bifurcation (figure 4).

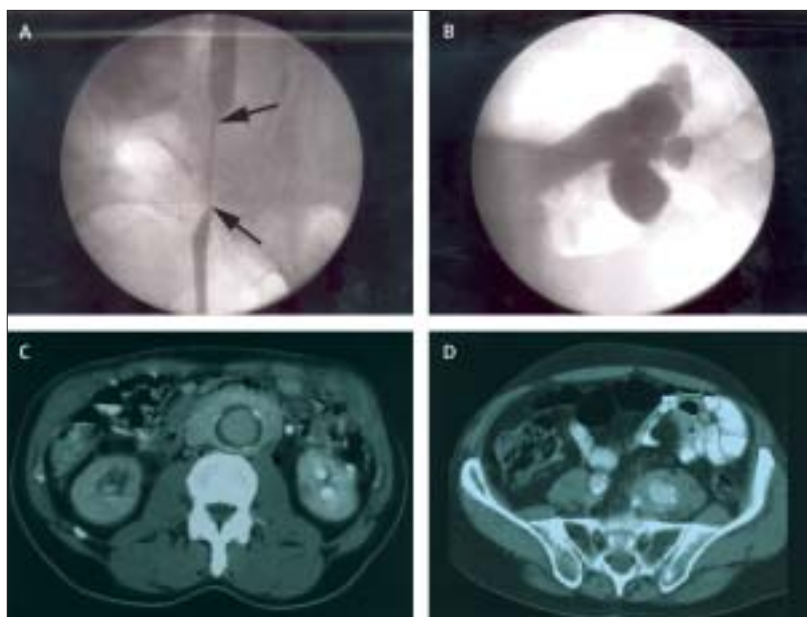


Figure 4: Ureterohydronephrosis associated with abdominal aortic aneurysm

Ureteral stenosis (A) resulting in ureterohydronephrosis (B) in a case of inflammatory aneurysm with para-aortic fibrosis (C) or para-iliac (D) fibrosis.

Ruptured abdominal aortic aneurysms

Rupture of abdominal aortic aneurysms is heralded by the triad of sudden-onset pain in the mid-abdomen or flank (that may radiate into the scrotum), shock, and the presence of a pulsatile abdominal mass. However, the degree of shock varies according to the location and size of the rupture and the delay before the patient is examined. Rupture from the anterolateral wall into the peritoneal cavity (figure 5) is usually dramatic and most often associated with death at the scene. Most patients with a rupture who reach the clinic alive have a rupture of the posterolateral wall into the retroperitoneal space; a small tear can temporarily seal the rupture and the initial blood loss might be small. This initial event is systematically followed within hours by a larger rupture. This biphasic evolution emphasises the importance of the intermediate period after the initial event, which should be used for medical transfer and emergency repair.

Anecdotically, the first episode of rupture could be definitely contained and become a chronic pulsatile extra-aortic haematoma. Very rarely, the aneurysm might spontaneously rupture into the duodenum (figures 5 and 6); an incidence rate at necropsy of 0.04% to 0.07% has been reported.^{105–107} More often, aortoduodenal fistula can occur after previous repair, with an incidence rate of 0.5% to 2.3%.¹⁰⁸ Rupture into the vena cava can also take place with an apparent pattern of lower extremity oedema erroneously attributed to cavitic thrombophlebitis (figure 4). However, the development of high output congestive heart failure and the perception of continuous



Figure 5: Different possible sites of rupture of an abdominal aortic aneurysm
1: Anterolateral free rupture in the abdominal cavity. 2: Retroperitoneal rupture.
3: Rupture of retroperitoneal sac. 4: Rupture into the duodenum. 5: Rupture into the inferior vena cava.

abdominal noise is pathognomonic. The overall prevalence of aortocaval fistula is 3% to 6% of all ruptured aortic aneurysms.¹⁰⁹

Indications for treatment

Although surgical treatment of non-ruptured abdominal aortic aneurysms relies on specific rare indications, such

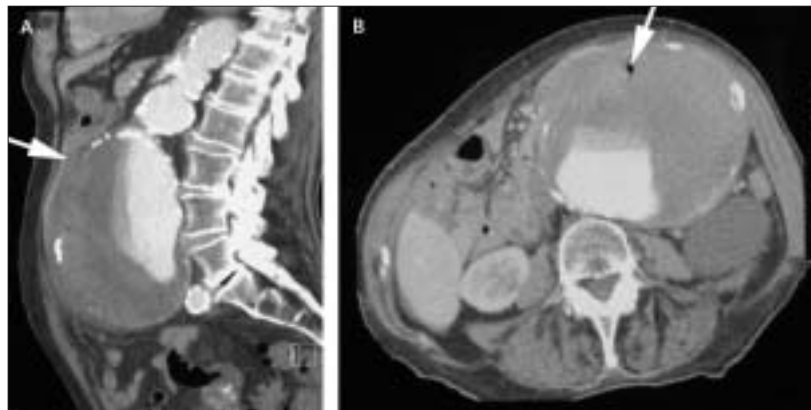

Figure 6: Rupture of an abdominal aortic aneurysm in the duodenum
CT displaying a known large aneurysm leaking into the duodenum (A, arrow), and presenting an air bubble in the parietal thrombus, which is a sign of aorta enteric fistula (B, arrow). The 92-year-old patient and her family had refused any intervention.

as distal embolisation, ureteral compression, or contained retroperitoneal haemorrhage, treatment of intact abdominal aortic aneurysm is essentially prophylactic and aimed at prevention of fatal rupture. Indication for surgical treatment is deduced from the estimated risk of rupture, the estimated risk of the surgical procedure, and the estimated life expectancy of the patient. Figure 7 shows a proposed management plan for asymptomatic abdominal aortic aneurysms.

Risk of rupture

The size of the aneurysm is a universally recognised factor to forecast rupture, and the general consensus is that patients with a large aneurysm should undergo surgery. The real controversy surrounds the management of small aneurysms. A study was undertaken in which patients with small aneurysms (diameter between 4.0 cm and 5.5 cm) were randomly assigned to two groups that underwent either early elective surgery or delayed repair after the diameter of the aneurysm had reached or exceeded 5.5 cm.¹¹⁰ The results show closely similar survival curves for the two groups of patients. A US Veterans Administration study led to similar findings despite a lower operative mortality (2.7% vs 5.8%) with early than with delayed repair.¹⁵ The conclusions of these two studies were similar: rigorous surveillance of infrarenal aortic aneurysms smaller than 5.5 cm in diameter is safe, whereas early surgery is not associated with improved long-term survival.

Rapid expansion of the aortic diameters preceding fissuration and rupture has been observed in abdominal aortic aneurysms independently of their initial size,^{18,20} which suggests that the size of the aneurysm, whatever its practical significance, is probably not the sole useful determinant for risk of rupture. Active investigations have been and still are being done to identify markers other than size that would predict a risk of rupture. A possible candidate is the level of serum MMP-9, which has been directly implicated in the proteolytic degradation of the extracellular matrix of the aortic wall.⁶⁸ The amount of circulating MMP-9 has not only been reported to be significantly higher in patients with abdominal aortic aneurysm,¹¹¹ but has also been significantly associated with the size and expansion rate of these aneurysms.¹¹² Another factor that has been investigated as a potential serum marker is the reduced level of α 1-antitrypsin (α 1-AT) since it is the most abundant serum inhibitor of proteases. However, the importance of this marker for the prognosis of abdominal aortic aneurysms has not been defined because of contradictory findings.¹¹³

Family history represents a risk factor for aneurysm rupture. A study of 313 pedigrees showed a four-fold higher rate of rupture in familial cases than in sporadic cases.⁴⁰ Additionally, a significantly earlier age at rupture (65 years vs 75 years) was also reported in these familial cases. Another potential risk factor for rupture could be

related to the sex of the patient. A report from the UK Small Aneurysm Trial has shown that the risk of rupture in women was four-times higher than in men.¹⁶

Preliminary data obtained by PET imaging of abdominal aortic aneurysms have shown focal uptake of 18-fluorodeoxyglucose (¹⁸F-FDG) within the aneurysm wall in patients with either large, rapidly expanding, or painful aneurysms (figure 8).¹¹⁴ The uptake of ¹⁸F-FDG is regarded as a functional image of the inflammatory infiltrate and thus as a potential non-invasive technique to identify unstable aneurysms that are prone to rupture.

Risk of elective aneurysm repair

Reported mortality rate related to elective aneurysm repair varies among hospitals and surgeons.¹¹⁵ Mean 30-day mortality rate has been reported at between 1·1% and 7·0%.^{116–121} Between 1998 and 2003, 453 patients were admitted to the University Hospital of Liège, Belgium, for elective repair of an abdominal aortic aneurysm (397 by open surgery and 56 by endovascular repair); the overall 30-day mortality, regardless of the risk factors, after open surgery and endovascular repair was 2·7% and 1·8%, respectively. Most deaths resulting from the repair occurred in the so-called high-risk patients. Factors of increased operative risk are renal failure, chronic obstructive pulmonary disease, and, most importantly, myocardial ischaemia. If these patients are excluded, 30-day mortality rate of elective repair should be expected to be as low as 2% in most hospitals.^{121–123}

Several reports have shown the high incidence (between 40% and 60%) of coronary artery disease in patients with abdominal aortic aneurysm, which could be explained by common risk factors (eg, tobacco smoking and hypertension).^{124–127} Complications related to coronary artery disease are the main cause of the operative mortality of aneurysm surgery.^{126,128–131} However, the benefit of coronary artery revascularisation before surgery remains controversial. Simultaneous aneurysm repair and coronary artery revascularisation have been recommended in selected patients scheduled for elective or urgent repair.^{132–134} However, a large randomised study did not show any significant difference in the long-term outcome when coronary-artery revascularisation was undertaken before elective surgery.¹³⁵ The investigators therefore suggested the restriction of preoperative coronary revascularisation to patients with unstable cardiac symptoms. As yet, there is no consensus on the optimum strategy for preoperative cardiac management in patients scheduled for major elective vascular surgery.^{136,137}

As far as emergency repair for ruptured abdominal aortic aneurysms is concerned, mortality depends on the haemodynamic status of the patient at the time of surgery. By contrast with the progress in elective repair mortality, no improvement in operative mortality of ruptured aneurysms has been reported during the past decades, remaining as high as 30–70%.^{2,22} If the

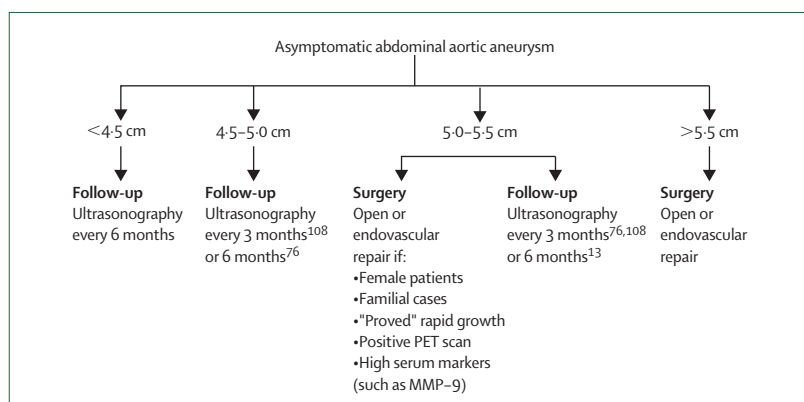


Figure 7: Proposed management of an asymptomatic abdominal aortic aneurysm

mortalities occurring at the scene of rupture, during transfer, shortly after admission to the emergency department, and during surgery are combined, then only 18% of patients with ruptured aortic aneurysms survive.¹³⁸ Prance and co-workers¹³⁸ suggested five preoperative risk factors to predict the mortality rate of ruptured abdominal aortic aneurysms: (1) age older than 76 years; (2) creatinine higher than 190 $\mu\text{mol/L}$; (3) haemoglobin below 9g/dL; (4) loss of consciousness; and (5) ECG evidence of ischaemia. In their study, the mortality rate was 100% when the patient had three or more risk factors and decreased to 48%, 28%, and 18% when the risk factor number decreased to two, one, or zero, respectively.¹³⁸

Management

Open surgical treatment

During open surgical treatment, the abdomen is entered either through a long midline or a wide transverse incision. A retroperitoneal approach has been

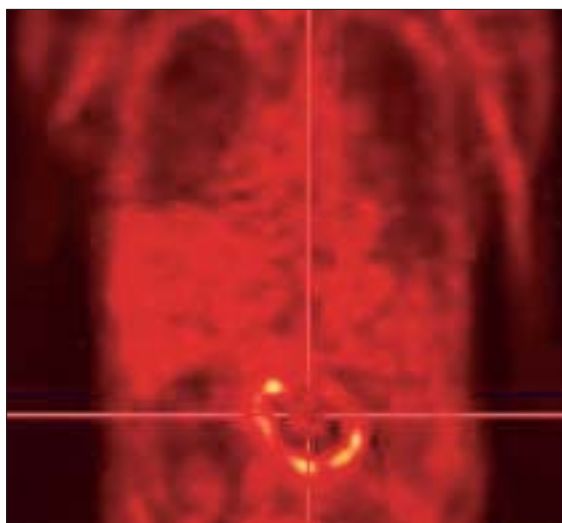


Figure 8: PET of an abdominal aortic aneurysm

Coronal section showing ¹⁸F-FDG uptake in the wall of an aneurysm 7 days before rupture.

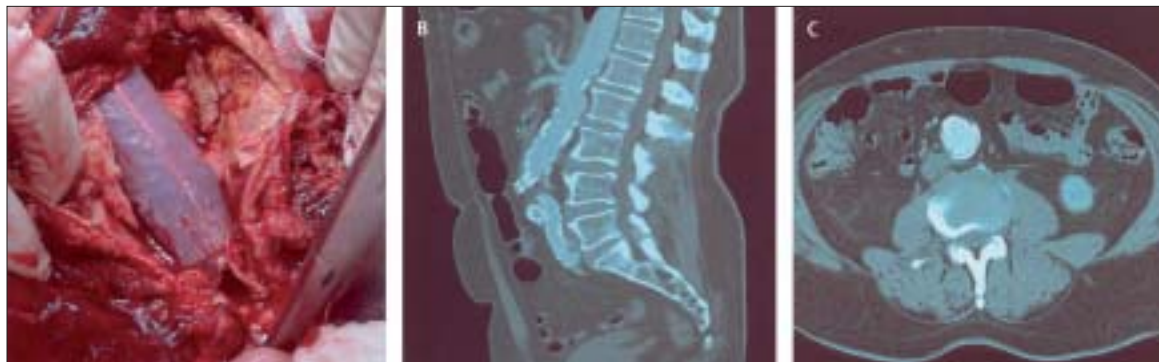


Figure 9: Potential issues of endovascular aneurysm repair

A: Rupture of an abdominal aortic aneurysm 2 years after endovascular repair. B and C: CT in another patient showing the normalisation of the diameter of an aneurysm 6 years after endovascular repair.

recommended in patients with chronic obstructive pulmonary disease. Disadvantages of this approach include: first that the intraperitoneal content cannot be inspected; and second, access to the right iliac artery can frequently be difficult, especially if there is a large right iliac aneurysm. Once the abdominal cavity is opened, the neck of the aneurysm needs to be identified to control it. In the cases of a suprarenal or intrarenal neck, a clamp above the renal arteries might be needed briefly. The iliac arteries are controlled in much the same way. The inferior mesenteric artery is tied close to the aortic wall to keep it collateral to the superior mesenteric artery; in some instances, encircling the inferior mesenteric artery with a rubber to reimplant it on the aortic prosthesis via a Carrell patch could be wise to maintain direct flow for sigmoid and rectum.

The vascular graft is a knitted synthetic textile sealed with collagen or albumin. The upper anastomosis is of the end-to-end type and the distal anastomosis is located on the aortic bifurcation, the iliac bifurcations, or the common femoral arteries depending on the extent of aneurysmal transformation and the patency of the external iliac arteries. Care is taken to preserve at least one internal iliac artery and to detect perioperatively a potential left colonic ischaemia. In sexually active male patients, the recommendation is not to dissect the lateral left aortic wall and the common left iliac artery. Whenever possible, iliac anastomosis should be the preferred choice instead of common femoral anastomosis because anastomosis in the groin is more prone to infection. Specific morbidities linked to surgery are left colon ischaemia and renal failure (eventually due to thrombo-embolic events in renal arteries). Postoperative paraplegia, a huge concern with thoraco-abdominal surgery, is infrequent with abdominal aortic aneurysm surgery. The incidence of paraplegia after endovascular repair or open surgery has been reported to be 0·21%¹³⁹ and 0·25–0·9%,^{140,141} respectively.

Since the very beginning of surgery for abdominal aortic aneurysms, survival after successful elective aneurysm repair has been reported to be less than the

survival of the matched population for age and sex; 5-year survival after abdominal aortic aneurysm repair was about 70%, whereas the expected survival of a matched population was close to 80%.¹³¹

Coggia and co-workers¹⁴² showed, in a preliminary study, the feasibility of repair by total laparoscopic surgery. Even if this technique is minimally invasive and reduces surgical trauma, more experience and further assessment are needed to ensure that the real benefit of this technique is realised compared with open repair.

Endovascular repair

Introduced by Parodi in 1991,¹⁴³ endovascular repair consists basically of the placement of a graft across the aneurysm and the fixation to the normal aortic and iliac wall with stents at both ends. The aortomonoiliac approach consists of the insertion of a stentgraft, which is a tube of conventional graft fabric containing at least two stents. The delivery system consists of a sheath with some type of haemostatic mechanism and an obturator for sheath installation and stentgraft extrusion. Many CT angiogram-derived data are necessary to choose the best-adapted device for the patient. The endograft is composed of fabric and metal stents and comes loaded in a delivery system. Under fluoroscopic guidance, this introducer system is fed through the iliac arteries by means of catheters and guidewires until the endograft is positioned correctly at the top and bottom of the aneurysmal segment. Removal of the introducer system allows the fixing devices to attach to the aortic wall and hold the graft firmly in place, excluding blood flow from the aneurysm sac and removing pressure from the aneurysm wall. Excellent results are characterised by a perfectly canalised blood flow and later by a completely retracted aneurysm wall around the endograft (figure 9). Occasionally, an abdominal aortic aneurysm might rupture, despite the presence of the endograft, if there is still pressure in the aneurysmal sac via endoleaks (figure 9). Some 40–80% of abdominal aortic aneurysms could be amenable to endovascular grafting. However, morphological contraindications for endovascular repair

are diversely proposed in published work. The most accepted contraindication is a proximal neck either shorter than 15 mm or absent.

Two randomised trials that compared conventional and endovascular repair showed a lower operative mortality rate for endovascular repair and less frequent complications than with conventional techniques.^{144,145} However, as discussed by Lederle,¹⁴⁶ the question "Is endovascular repair preferable to open repair?" cannot be answered yet since there has been no long-term follow-up to determine whether the early promise of endovascular repair is sustained. Two large European registries have reported a failure rate for endovascular repair of 3% per year (1% by rupture and 2% by a required conversion to open repair),¹⁴⁷⁻¹⁴⁹ versus a failure rate of 0.3% for open repair.^{15,150,151} Long-term results after endovascular repair have also been reported to be worse for large aneurysms, which are the most in need of repair. Ouriel and colleagues¹⁵² noted that 2 years after endovascular repair, 6.1% of patients with an abdominal aortic aneurysm larger than 5.5 cm died from aneurysm-related causes and 8.2% needed open conversion. Additionally, a 4-year postoperative rupture rate was reported to reach 10% for large abdominal aortic aneurysms (diameter ≥ 6.5 cm).¹⁵³

Non-invasive prevention of growth and rupture

Patients with an abdominal aortic aneurysm are asked to stop smoking tobacco completely to allow a reduction of the growth rate of the aneurysm.³⁵ The central role of MMP in aneurysm development and rupture has led to research interest in the pharmacologic inhibitors of these proteases. Tetracyclines provide a potentially effective treatment. Doxycycline, a synthetic tetracycline derivative, was shown to prevent MMP-mediated aneurysmal growth in animal models.¹⁵⁴ Moreover, findings from a clinical study suggested that doxycycline treatment prevents aneurysm growth in human beings.¹⁵⁵ The use of synthetic inhibitors of MMP activity, such as batimastat (BB-94), has also been shown to suppress the expansion of experimental abdominal aortic aneurysms.^{156,157} However, Defawe and colleagues¹⁵⁸ recently showed that MMP can alter matrix remodelling independently of their proteolytic function, which suggests that the role of MMP might be more complex than mediation of a degradation process. Another attractive option of aneurysmal pharmacotherapy is to target the inflammatory response and interfere with the MMP pathway. Non-steroidal anti-inflammatory drugs, such as indometacin, are known to prevent development of abdominal aortic aneurysms in animal models.¹⁵⁹ In the past decade, various substances have been proposed for the treatment of asymptomatic abdominal aortic aneurysms. The use of β -blocking agents (eg, propranolol) seems to reduce the growth rate of large (>5 cm) aneurysms and even to lessen the size of experimental aneurysms.^{160,161} However, a randomised

trial reported that propranolol does not have a significant effect on the growth rate of small aneurysms.¹⁶² Statins (hydroxymethylglutaryl coenzyme A reductase inhibitors), besides their cholesterol lowering effects, reduce the expression of various inflammatory molecules, including MMP.¹⁶³ The addition of cerivastatin to tissue organ cultures of abdominal aortic aneurysms has been shown to down-regulate the production of MMP-9, which suggests that members of the statins family could prevent elastolysis in patients with this disorder.¹⁶⁴ Long-term statin use in patients who underwent successful surgery was also associated with reduced mortality.¹⁶⁵ Several innovative experimental studies have shown the potential of cell therapies (eg, to seed cells overexpressing antiproteases in aneurysmal walls) for prevention of aneurysmal progression and rupture in animal models.^{92,166,167}

Conclusion

The past five decades have been marked by continuing progress in diagnosis, management, timing of interventional treatments, and assessment of endovascular repair versus conventional surgery. Hopefully, the upcoming decades will provide preventive treatments that can be applied to selected groups of individuals identified as high risk for abdominal aortic aneurysm by genomic or imaging technology, or both. The first goal in abdominal aortic aneurysm history was the prevention of rupture; the next aim will be the prevention of abdominal aortic aneurysm growth.

Conflict of interest statement

We declare that we have no conflict of interest.

Acknowledgments

We thank B V Nusgens and Ch M Lapière (Laboratory of Connective Tissues Biology) for their help in the preparation of this Seminar. The experimental work reported here was supported by the Belgian Fonds Scientifique de la Recherche Médicale (FRSM 3-4785-05), the Fondation L. Fredericq, and the Fonds d'Investissement de la Recherche Scientifique of the University Hospital of Liège. The funding sources had no role in the preparation of this Seminar.

References

- Gillum RF. Epidemiology of aortic aneurysm in the United States. *J Clin Epidemiol* 1995; **48**: 1289-98.
- Kniemeyer HW, Kessler T, Reber PU, Ris HB, Hakki H, Widmer MK. Treatment of ruptured abdominal aortic aneurysm, a permanent challenge or a waste of resources? Prediction of outcome using a multi-organ-dysfunction score. *Eur J Vasc Endovasc Surg* 2000; **19**: 190-96.
- Bengtsson H, Sonesson B, Bergqvist D. Incidence and prevalence of abdominal aortic aneurysms, estimated by necropsy studies and population screening by ultrasound. *Ann N Y Acad Sci* 1996; **800**: 1-24.
- Liddington MI, Heather BP. The relationship between aortic diameter and body habitus. *Eur J Vasc Surg* 1992; **6**: 89-92.
- McGregor JC, Pollock JG, Anton HC. The value of ultrasonography in the diagnosis of abdominal aortic aneurysm. *Scott Med J* 1975; **20**: 133-37.
- Johnston KW, Rutherford RB, Tilson MD, Shah DM, Hollier L, Stanley JC. Suggested standards for reporting on arterial aneurysms. Subcommittee on Reporting Standards for Arterial Aneurysms, Ad Hoc Committee on Reporting Standards, Society for Vascular Surgery and North American Chapter, International Society for Cardiovascular Surgery. *J Vasc Surg* 1991; **13**: 452-58.

- 7 Thompson MM. Controlling the expansion of abdominal aortic aneurysms. *Br J Surg* 2003; **90**: 897–98.
- 8 Lederle FA, Johnson GR, Wilson SE, et al. The aneurysm detection and management study screening program: validation cohort and final results. *Arch Intern Med* 2000; **160**: 1425–30.
- 9 Lindholt JS, Vammen S, Juul S, Fasting H, Henneberg EW. Optimal interval screening and surveillance of abdominal aortic aneurysms. *Eur J Vasc Endovasc Surg* 2000; **20**: 369–73.
- 10 Lederle FA, Johnson GR, Wilson SE. Abdominal aortic aneurysm in women. *J Vasc Surg* 2001; **34**: 122–26.
- 11 Singh K, Bona KH, Jacobsen BK, Bjork L, Solberg S. Prevalence of and risk factors for abdominal aortic aneurysms in a population-based study: the Tromsø Study. *Am J Epidemiol* 2001; **154**: 236–44.
- 12 Vardulaki KA, Walker NM, Day NE, Duffy SW, Ashton HA, Scott RA. Quantifying the risks of hypertension, age, sex and smoking in patients with abdominal aortic aneurysm. *Br J Surg* 2000; **87**: 195–200.
- 13 MacSweeney ST, Ellis M, Worrell PC, Greenhalgh RM, Powell JT. Smoking and growth rate of small abdominal aortic aneurysms. *Lancet* 1994; **344**: 651–52.
- 14 Brown LC, Powell JT. Risk factors for aneurysm rupture in patients kept under ultrasound surveillance. UK Small Aneurysm Trial Participants. *Ann Surg* 1999; **230**: 289–96; discussion 296–97.
- 15 Lederle FA, Wilson SE, Johnson GR, et al. Immediate repair compared with surveillance of small abdominal aortic aneurysms. *N Engl J Med* 2002; **346**: 1437–44.
- 16 Long-term outcomes of immediate repair compared with surveillance of small abdominal aortic aneurysms. *N Engl J Med* 2002; **346**: 1445–52.
- 17 Ashton HA, Buxton MJ, Day NE, et al. The Multicentre Aneurysm Screening Study (MASS) into the effect of abdominal aortic aneurysm screening on mortality in men: a randomised controlled trial. *Lancet* 2002; **360**: 1531–39.
- 18 Limet R, Sakalihan N, Albert A. Determination of the expansion rate and incidence of rupture of abdominal aortic aneurysms. *J Vasc Surg* 1991; **14**: 540–48.
- 19 Nevitt MP, Ballard DJ, Hallett JW Jr. Prognosis of abdominal aortic aneurysms: a population-based study. *N Engl J Med* 1989; **321**: 1009–14.
- 20 Glimaker H, Holmberg L, Elvin A, et al. Natural history of patients with abdominal aortic aneurysm. *Eur J Vasc Surg* 1991; **5**: 125–30.
- 21 Scott RA, Ashton HA, Kay DN. Abdominal aortic aneurysm in 4237 screened patients: prevalence, development and management over 6 years. *Br J Surg* 1991; **78**: 1122–25.
- 22 Wilms TB, Quick CR, Hubbard CS, Day NE. The influence of screening on the incidence of ruptured abdominal aortic aneurysms. *J Vasc Surg* 1999; **30**: 203–08.
- 23 Erentug V, Bozbuga N, Omeroglu SN, et al. Rupture of abdominal aortic aneurysms in Behçet's disease. *Ann Vasc Surg* 2003; **17**: 682–85.
- 24 Matsumura K, Hirano T, Takeda K, et al. Incidence of aneurysms in Takayasu's arteritis. *Angiology* 1991; **42**: 308–15.
- 25 Towbin JA, Casey B, Belmont J. The molecular basis of vascular disorders. *Am J Hum Genet* 1999; **64**: 678–84.
- 26 Reed D, Reed C, Stemmermann G, Hayashi T. Are aortic aneurysms caused by atherosclerosis? *Circulation* 1992; **85**: 205–11.
- 27 Tilson MD. Aortic aneurysms and atherosclerosis. *Circulation* 1992; **85**: 378–79.
- 28 Xu C, Zarins CK, Glagov S. Aneurysmal and occlusive atherosclerosis of the human abdominal aorta. *J Vasc Surg* 2001; **33**: 91–96.
- 29 Ghorpade A, Baxter BT. Biochemistry and molecular regulation of matrix macromolecules in abdominal aortic aneurysms. *Ann N Y Acad Sci* 1996; **800**: 138–50.
- 30 Carrell TW, Burnand KG, Wells GM, Clements JM, Smith A. Stromelysin-1 (matrix metalloproteinase-3) and tissue inhibitor of metalloproteinase-3 are overexpressed in the wall of abdominal aortic aneurysms. *Circulation* 2002; **105**: 477–82.
- 31 Defawe OD, Colige A, Lambert CA, et al. TIMP-2 and PAI-1 mRNA levels are lower in aneurysmal as compared to athero-occlusive abdominal aortas. *Cardiovasc Res* 2003; **60**: 205–13.
- 32 Blanchard JF, Armenian HK, Friesen PP. Risk factors for abdominal aortic aneurysm: results of a case-control study. *Am J Epidemiol* 2000; **151**: 575–83.
- 33 Lindholt JS, Heegaard NH, Vammen S, Fasting H, Henneberg EW, Heickendorff L. Smoking, but not lipids, lipoprotein(a) and antibodies against oxidised LDL, is correlated to the expansion of abdominal aortic aneurysms. *Eur J Vasc Endovasc Surg* 2001; **21**: 51–56.
- 34 Lederle FA, Nelson DB, Joseph AM. Smokers' relative risk for aortic aneurysm compared with other smoking-related diseases: a systematic review. *J Vasc Surg* 2003; **38**: 329–34.
- 35 Brady AR, Thompson SG, Fowkes FG, Greenhalgh RM, Powell JT. Abdominal aortic aneurysm expansion: risk factors and time intervals for surveillance. *Circulation* 2004; **110**: 16–21.
- 36 Buckley C, Wyble CW, Borhani M, et al. Accelerated enlargement of experimental abdominal aortic aneurysms in a mouse model of chronic cigarette smoke exposure. *J Am Coll Surg* 2004; **199**: 896–903.
- 37 Thompson RW, Geraghty PJ, Lee JK. Abdominal aortic aneurysms: basic mechanisms and clinical implications. *Curr Probl Surg* 2002; **39**: 110–230.
- 38 Clifton MA. Familial abdominal aortic aneurysms. *Br J Surg* 1977; **64**: 765–66.
- 39 Kuivaniemi H, Shibamura H, Arthur C, et al. Familial abdominal aortic aneurysms: collection of 233 multiplex families. *J Vasc Surg* 2003; **37**: 340–45.
- 40 Verloes A, Sakalihan N, Koulischer L, Limet R. Aneurysms of the abdominal aorta: familial and genetic aspects in three hundred thirteen pedigrees. *J Vasc Surg* 1995; **21**: 646–55.
- 41 Frydman G, Walker PJ, Summers K, et al. The value of screening in siblings of patients with abdominal aortic aneurysm. *Eur J Vasc Endovasc Surg* 2003; **26**: 396–400.
- 42 Majumder PP, St Jean PL, Ferrell RE, Webster MW, Steed DL. On the inheritance of abdominal aortic aneurysm. *Am J Hum Genet* 1991; **48**: 164–70.
- 43 Rossaak JI, Van Rij AM, Jones GT, Harris EL. Association of the 4G/5G polymorphism in the promoter region of plasminogen activator inhibitor-1 with abdominal aortic aneurysms. *J Vasc Surg* 2000; **31**: 1026–32.
- 44 Jones K, Powell J, Brown L, Greenhalgh R, Jormsjo S, Eriksson P. The influence of 4G/5G polymorphism in the plasminogen activator inhibitor-1 gene promoter on the incidence, growth and operative risk of abdominal aortic aneurysm. *Eur J Vasc Endovasc Surg* 2002; **23**: 421–25.
- 45 Shibamura H, Olson JM, van Vlijmen-Van Keulen C, et al. Genome scan for familial abdominal aortic aneurysm using sex and family history as covariates suggests genetic heterogeneity and identifies linkage to chromosome 19q13. *Circulation* 2004; **109**: 2103–08.
- 46 Boucher P, Gotthardt M, Li WP, Anderson RG, Herz J. LRP: role in vascular wall integrity and protection from atherosclerosis. *Science* 2003; **300**: 329–32.
- 47 Powell JT. Familial clustering of abdominal aortic aneurysm-smoke signals, but no culprit genes. *Br J Surg* 2003; **90**: 1173–74.
- 48 Lembo G, De Luca N, Battagli C, et al. A common variant of endothelial nitric oxide synthase (Glu298Asp) is an independent risk factor for carotid atherosclerosis. *Stroke* 2001; **32**: 735–40.
- 49 Barker DJ. Fetal origins of coronary heart disease. *BMJ* 1995; **311**: 171–74.
- 50 Melrose J, Whitelock J, Xu Q, Ghosh P. Pathogenesis of abdominal aortic aneurysms: possible role of differential production of proteoglycans by smooth muscle cells. *J Vasc Surg* 1998; **28**: 676–86.
- 51 Powell JT. Dilatation through loss of elastic. In: Greenhalgh RM, Mannick JM, Powell JT, eds. The cause and management of aneurysms. London: WB Saunders, 1990.
- 52 Baxter BT, McGee GS, Shively VP, et al. Elastin content, cross-links, and mRNA in normal and aneurysmal human aorta. *J Vasc Surg* 1992; **16**: 192–200.
- 53 Sakalihan N, Heyeres A, Nusgens BV, Limet R, Lapiere CM. Modifications of the extracellular matrix of aneurysmal abdominal aortas as a function of their size. *Eur J Vasc Surg* 1993; **7**: 633–37.
- 54 Dobrin PB, Mrkvicka R. Failure of elastin or collagen as possible critical connective tissue alterations underlying aneurysmal dilatation. *Cardiovasc Surg* 1994; **2**: 484–88.

- 55 Satta J, Juvonen T, Haukipuro K, Juvonen M, Kairaluoma MI. Increased turnover of collagen in abdominal aortic aneurysms, demonstrated by measuring the concentration of the aminoterminal propeptide of type III procollagen in peripheral and aortal blood samples. *J Vasc Surg* 1995; **22**: 155–60.
- 56 Huffman MD, Curci JA, Moore G, Kerns DB, Starcher BC, Thompson RW. Functional importance of connective tissue repair during the development of experimental abdominal aortic aneurysms. *Surgery* 2000; **128**: 429–38.
- 57 Herron GS, Unemori E, Wong M, Rapp JH, Hibbs MH, Stoney RJ. Connective tissue proteinases and inhibitors in abdominal aortic aneurysms: involvement of the vasa vasorum in the pathogenesis of aortic aneurysms. *Arterioscler Thromb* 1991; **11**: 1667–77.
- 58 Holmes DR, Liao S, Parks WC, Thompson RW. Medial neovascularization in abdominal aortic aneurysms: a histopathologic marker of aneurysmal degeneration with pathophysiologic implications. *J Vasc Surg* 1995; **21**: 761–71; discussion 771–72.
- 59 Shah PK. Inflammation, metalloproteinases, and increased proteolysis: an emerging pathophysiological paradigm in aortic aneurysm. *Circulation* 1997; **96**: 2115–17.
- 60 Koch AE, Kunkel SL, Pearce WH, et al. Enhanced production of the chemotactic cytokines interleukin-8 and monocyte chemoattractant protein-1 in human abdominal aortic aneurysms. *Am J Pathol* 1993; **142**: 1423–31.
- 61 Newman KM, Jean-Claude J, Li H, Ramey WG, Tilson MD. Cytokines that activate proteolysis are increased in abdominal aortic aneurysms. *Circulation* 1994; **90**: I1224–27.
- 62 Walton LJ, Franklin IJ, Bayston T, et al. Inhibition of prostaglandin E2 synthesis in abdominal aortic aneurysms: implications for smooth muscle cell viability, inflammatory processes, and the expansion of abdominal aortic aneurysms. *Circulation* 1999; **100**: 48–54.
- 63 Hance KA, Tataria M, Ziporin SJ, Lee JK, Thompson RW. Monocyte chemotactic activity in human abdominal aortic aneurysms: role of elastin degradation peptides and the 67-kD cell surface elastin receptor. *J Vasc Surg* 2002; **35**: 254–61.
- 64 Hirose H, Tilson MD. Abdominal aortic aneurysm as an autoimmune disease. *Ann N Y Acad Sci* 2001; **947**: 416–18.
- 65 Curci JA, Thompson RW. Adaptive cellular immunity in aortic aneurysms: cause, consequence, or context? *J Clin Invest* 2004; **114**: 168–71.
- 66 Rao SK, Reddy KV, Cohen JR. Role of serine proteases in aneurysm development. *Ann N Y Acad Sci* 1996; **800**: 131–37.
- 67 Reilly JM. Plasminogen activators in abdominal aortic aneurysmal disease. *Ann N Y Acad Sci* 1996; **800**: 151–56.
- 68 Sakalihasan N, Delvenne P, Nussgens BV, Limet R, Lapiere CM. Activated forms of MMP2 and MMP9 in abdominal aortic aneurysms. *J Vasc Surg* 1996; **24**: 127–33.
- 69 Thompson RW, Parks WC. Role of matrix metalloproteinases in abdominal aortic aneurysms. *Ann N Y Acad Sci* 1996; **800**: 157–74.
- 70 Carmeliet P, Moons L, Lijnen R, et al. Urokinase-generated plasmin activates matrix metalloproteinases during aneurysm formation. *Nat Genet* 1997; **17**: 439–44.
- 71 Curci JA, Liao S, Huffman MD, Shapiro SD, Thompson RW. Expression and localization of macrophage elastase (matrix metalloproteinase-12) in abdominal aortic aneurysms. *J Clin Invest* 1998; **102**: 1900–10.
- 72 Davis V, Persidskaia R, Baca-Regen L, et al. Matrix metalloproteinase-2 production and its binding to the matrix are increased in abdominal aortic aneurysms. *Arterioscler Thromb Vasc Biol* 1998; **18**: 1625–33.
- 73 Mao D, Lee JK, VanVickle SJ, Thompson RW. Expression of collagenase-3 (MMP-13) in human abdominal aortic aneurysms and vascular smooth muscle cells in culture. *Biochem Biophys Res Commun* 1999; **261**: 904–10.
- 74 Shi GP, Sukhova GK, Grubb A, et al. Cystatin C deficiency in human atherosclerosis and aortic aneurysms. *J Clin Invest* 1999; **104**: 1191–97.
- 75 Nollendorfs A, Greiner TC, Nagase H, Baxter BT. The expression and localization of membrane type-1 matrix metalloproteinase in human abdominal aortic aneurysms. *J Vasc Surg* 2001; **34**: 316–22.
- 76 Silence J, Lupu F, Collen D, Lijnen HR. Persistence of atherosclerotic plaque but reduced aneurysm formation in mice with stromelysin-1 (MMP-3) gene inactivation. *Arterioscler Thromb Vasc Biol* 2001; **21**: 1440–45.
- 77 Longo GM, Xiong W, Greiner TC, Zhao Y, Fiotti N, Baxter BT. Matrix metalloproteinases 2 and 9 work in concert to produce aortic aneurysms. *J Clin Invest* 2002; **110**: 625–32.
- 78 Tromp G, Gatalica Z, Skunca M, et al. Elevated expression of matrix metalloproteinase-13 in abdominal aortic aneurysms. *Ann Vasc Surg* 2004; **18**: 414–20.
- 79 Eriksson P, Jones KG, Brown LC, Greenhalgh RM, Hamsten A, Powell JT. Genetic approach to the role of cysteine proteases in the expansion of abdominal aortic aneurysms. *Br J Surg* 2004; **91**: 86–89.
- 80 Anidjar S, Salzmann JL, Gentric D, Lagneau P, Camilleri JP, Michel JB. Elastase-induced experimental aneurysms in rats. *Circulation* 1990; **82**: 973–81.
- 81 Pyo R, Lee JK, Shipley JM, et al. Targeted gene disruption of matrix metalloproteinase-9 (gelatinase B) suppresses development of experimental abdominal aortic aneurysms. *J Clin Invest* 2000; **105**: 1641–49.
- 82 Dobrin PB. Animal models of aneurysms. *Ann Vasc Surg* 1999; **13**: 641–48.
- 83 Ailawadi G, Eliason JL, Roelofs KJ, et al. Gender differences in experimental aortic aneurysm formation. *Arterioscler Thromb Vasc Biol* 2004; **24**: 2116–22.
- 84 Deng GG, Martin-McNulty B, Sukovich DA, et al. Urokinase-type plasminogen activator plays a critical role in angiotensin II-induced abdominal aortic aneurysm. *Circ Res* 2003; **92**: 510–17.
- 85 Knox JB, Sukhova GK, Whittemore AD, Libby P. Evidence for altered balance between matrix metalloproteinases and their inhibitors in human aortic diseases. *Circulation* 1997; **95**: 205–12.
- 86 Tamarina NA, McMillan WD, Shively VP, Pearce WH. Expression of matrix metalloproteinases and their inhibitors in aneurysms and normal aorta. *Surgery* 1997; **122**: 264–71; discussion 271–72.
- 87 Allaire E, Forough R, Clowes M, Starcher B, Clowes AW. Local overexpression of TIMP-1 prevents aortic aneurysm degeneration and rupture in a rat model. *J Clin Invest* 1998; **102**: 1413–20.
- 88 Allaire E, Hasenstab D, Kenagy RD, Starcher B, Clowes MM, Clowes AW. Prevention of aneurysm development and rupture by local overexpression of plasminogen activator inhibitor-1. *Circulation* 1998; **98**: 249–55.
- 89 Rouis M, Adamy C, Duverger N, et al. Adenovirus-mediated overexpression of tissue inhibitor of metalloproteinase-1 reduces atherosclerotic lesions in apolipoprotein E-deficient mice. *Circulation* 1999; **100**: 533–40.
- 90 Silence J, Collen D, Lijnen HR. Reduced atherosclerotic plaque but enhanced aneurysm formation in mice with inactivation of the tissue inhibitor of metalloproteinase-1 (TIMP-1) gene. *Circ Res* 2002; **90**: 897–903.
- 91 Lopez-Candales A, Holmes DR, Liao S, Scott MJ, Wickline SA, Thompson RW. Decreased vascular smooth muscle cell density in medial degeneration of human abdominal aortic aneurysms. *Am J Pathol* 1997; **150**: 993–1007.
- 92 Allaire E, Muscatelli-Groux B, Mandet C, et al. Paracrine effect of vascular smooth muscle cells in the prevention of aortic aneurysm formation. *J Vasc Surg* 2002; **36**: 1018–26.
- 93 Defawe O, Colige A, Deroanne C, et al. Mechanical strain modulates monocyte chemotactic protein-1 and IL-1 β mRNA expression by cultured human aortic smooth muscle cells. *Cardiovas Pathol* 2004; **13** (suppl 3).
- 94 Yamazumi K, Ojio M, Okumura H, Aikou T. An activated state of blood coagulation and fibrinolysis in patients with abdominal aortic aneurysm. *Am J Surg* 1998; **175**: 297–301.
- 95 Lindholt JS, Jorgensen B, Fasting H, Henneberg EW. Plasma levels of plasmin-antiplasmin-complexes are predictive for small abdominal aortic aneurysms expanding to operation-recommendable sizes. *J Vasc Surg* 2001; **34**: 611–15.
- 96 Vorp DA, Lee PC, Wang DH, et al. Association of intraluminal thrombus in abdominal aortic aneurysm with local hypoxia and wall weakening. *J Vasc Surg* 2001; **34**: 291–99.
- 97 Fontaine V, Jacob MP, Houard X, et al. Involvement of the mural thrombus as a site of protease release and activation in human aortic aneurysms. *Am J Pathol* 2002; **161**: 1701–10.

- 98 Fink HA, Lederle FA, Roth CS, Bowles CA, Nelson DB, Haas MA. The accuracy of physical examination to detect abdominal aortic aneurysm. *Arch Intern Med* 2000; **160**: 833–36.
- 99 Quill DS, Colgan MP, Sumner DS. Ultrasonic screening for the detection of abdominal aortic aneurysms. *Surg Clin North Am* 1989; **69**: 713–20.
- 100 Mehard WB, Heiken JP, Sicard GA. High-attenuating crescent in abdominal aortic aneurysm wall at CT: a sign of acute or impending rupture. *Radiology* 1994; **192**: 359–62.
- 101 Siegel CL, Cohan RH, Korobkin M, Alpern MB, Courneya DL, Leder RA. Abdominal aortic aneurysm morphology: CT features in patients with ruptured and nonruptured aneurysms. *AJR Am J Roentgenol* 1994; **163**: 1123–29.
- 102 Arita T, Matsunaga N, Takano K, et al. Abdominal aortic aneurysm: rupture associated with the high-attenuating crescent sign. *Radiology* 1997; **204**: 765–68.
- 103 Sprouse LR, Meier GH, Parent FN, et al. Is three-dimensional computed tomography reconstruction justified before endovascular aortic aneurysm repair? *J Vasc Surg* 2004; **40**: 443–47.
- 104 Fleming C, Whitlock EP, Beil TL, Lederle FA. Screening for abdominal aortic aneurysm: a best-evidence systematic review for the US Preventive Services Task Force. *Ann Intern Med* 2005; **142**: 203–11.
- 105 Parry DJ, Waterworth A, Kessel D, Robertson I, Berridge DC, Scott DJ. Endovascular repair of an inflammatory abdominal aortic aneurysm complicated by aortoduodenal fistulation with an unusual presentation. *J Vasc Surg* 2001; **33**: 874–79.
- 106 Kane JM, Meyer KA, Kozoll DD. An anatomical approach to the problem of massive gastrointestinal hemorrhage. *AMA Arch Surg* 1955; **70**: 570–82.
- 107 Hirst AE Jr, Affeldt J. Abdominal aortic aneurysm with rupture into the duodenum; a report of eight cases. *Gastroenterol* 1951; **17**: 504–14.
- 108 Lemos DW, Raffetto JD, Moore TC, Menzoian JO. Primary aortoduodenal fistula: a case report and review of the literature. *J Vasc Surg* 2003; **37**: 686–89.
- 109 Davis PM, Gloviczki P, Cherry KJ Jr, et al. Aorto-caval and ilio-iliac arteriovenous fistulae. *Am J Surg* 1998; **176**: 115–18.
- 110 The UK Small Aneurysm Trial Participants. Mortality results for randomised controlled trial of early elective surgery or ultrasonographic surveillance for small abdominal aortic aneurysms. *Lancet* 1998; **352**: 1649–55.
- 111 McMillan WD, Pearce WH. Increased plasma levels of metalloproteinase-9 are associated with abdominal aortic aneurysms. *J Vasc Surg* 1999; **29**: 122–27; discussion 127–29.
- 112 Lindholt JS, Vammen S, Fasting H, Henneberg EW, Heickendorff L. The plasma level of matrix metalloproteinase 9 may predict the natural history of small abdominal aortic aneurysms: a preliminary study. *Eur J Vasc Endovasc Surg* 2000; **20**: 281–85.
- 113 Elzouki AN, Ryden Ahlgren A, Lanne T, Sonesson B, Eriksson S. Is there a relationship between abdominal aortic aneurysms and alpha1-antitrypsin deficiency (PiZ)? *Eur J Vasc Endovasc Surg* 1999; **17**: 149–54.
- 114 Sakalihan N, Van Damme H, Gomez P, et al. Positron emission tomography (PET) evaluation of abdominal aortic aneurysm (AAA). *Eur J Vasc Endovasc Surg* 2002; **23**: 431–36.
- 115 Dueck AD, Kucey DS, Johnston KW, Alter D, Laupacis A. Long-term survival and temporal trends in patient and surgeon factors after elective and ruptured abdominal aortic aneurysm surgery. *J Vasc Surg* 2004; **39**: 1261–67.
- 116 Kieffer E, Koskas F, Dewailly J, Gouny P. Mortalite peroperative de la chirurgie electve de l'anevrisme de l'aorte abdominale: etude multicentrique de l'AURC. In: Kieffer E, ed. Les anevrysmes de l'aorte abdominale sous-renale. Paris, France: AERCv, 1990: 235–243.
- 117 Hollier LH, Taylor LM, Ochsner J. Recommended indications for operative treatment of abdominal aortic aneurysms. Report of a subcommittee of the Joint Council of the Society for Vascular Surgery and the North American Chapter of the International Society for Cardiovascular Surgery. *J Vasc Surg* 1992; **15**: 1046–56.
- 118 Katz DJ, Stanley JC, Zelenock GB. Operative mortality rates for intact and ruptured abdominal aortic aneurysms in Michigan: an 11-year statewide experience. *J Vasc Surg* 1994; **19**: 804–15; discussion 816–17.
- 119 Irvine CD, Shaw E, Poskitt KR, Whyman MR, Earnshaw JJ, Heather BP. A comparison of the mortality rate after elective repair of aortic aneurysms detected either by screening or incidentally. *Eur J Vasc Endovasc Surg* 2000; **20**: 374–78.
- 120 Brady AR, Fowkes FG, Greenhalgh RM, Powell JT, Ruckley CV, Thompson SG. Risk factors for postoperative death following elective surgical repair of abdominal aortic aneurysm: results from the UK Small Aneurysm Trial. *Br J Surg* 2000; **87**: 742–49.
- 121 Elkouri S, Gloviczki P, McKusick MA, et al. Perioperative complications and early outcome after endovascular and open surgical repair of abdominal aortic aneurysms. *J Vasc Surg* 2004; **39**: 497–505.
- 122 Hertzner NR, Mascha EJ, Karafa MT, O'Hara PJ, Krajewski LP, Beven EG. Open infrarenal abdominal aortic aneurysm repair: the Cleveland Clinic experience from 1989 to 1998. *J Vasc Surg* 2002; **35**: 1145–54.
- 123 Rinckenbach S, Hassani O, Thaveau F, et al. Current outcome of elective open repair for infrarenal abdominal aortic aneurysm. *Ann Vasc Surg* 2004; **18**: 704–09.
- 124 Hertzner NR. Fatal myocardial infarction following abdominal aortic aneurysm resection. Three hundred forty-three patients followed 6–11 years postoperatively. *Ann Surg* 1980; **192**: 667–73.
- 125 Hollier LH, Plate G, O'Brien PC, et al. Late survival after abdominal aortic aneurysm repair: influence of coronary artery disease. *J Vasc Surg* 1984; **1**: 290–99.
- 126 Roger VL, Ballard DJ, Hallett JW Jr, Osmundson PJ, Puetz PA, Gersh BJ. Influence of coronary artery disease on morbidity and mortality after abdominal aortic aneurysmectomy: a population-based study, 1971–1987. *J Am Coll Cardiol* 1989; **14**: 1245–52.
- 127 Golden MA, Whittemore AD, Donaldson MC, Mannick JA. Selective evaluation and management of coronary artery disease in patients undergoing repair of abdominal aortic aneurysms: a 16-year experience. *Ann Surg* 1990; **212**: 415–20; discussion 420–23.
- 128 Johnston KW. Multicenter prospective study of nonruptured abdominal aortic aneurysm. Part II: variables predicting morbidity and mortality. *J Vasc Surg* 1989; **9**: 437–47.
- 129 Boersma E, Poldermans D, Bax JJ, et al. Predictors of cardiac events after major vascular surgery: role of clinical characteristics, dobutamine echocardiography, and beta-blocker therapy. *JAMA* 2001; **285**: 1865–73.
- 130 Hallin A, Bergqvist D, Holmberg L. Literature review of surgical management of abdominal aortic aneurysm. *Eur J Vasc Endovasc Surg* 2001; **22**: 197–204.
- 131 Norman PE, Semmens JB, Lawrence-Brown MM. Long-term relative survival following surgery for abdominal aortic aneurysm: a review. *Cardiovasc Surg* 2001; **9**: 219–24.
- 132 Mohr FW, Falk V, Autschbach R, et al. One-stage surgery of coronary arteries and abdominal aorta in patients with impaired left ventricular function. *Circulation* 1995; **91**: 379–85.
- 133 El-Sabroun RA, Reul GJ, Cooley DA. Outcome after simultaneous abdominal aortic aneurysm repair and aortocoronary bypass. *Ann Vasc Surg* 2002; **16**: 321–30.
- 134 Morimoto K, Taniguchi I, Miyasaka S, Aoki T, Kato I, Yamaga T. Usefulness of one-stage coronary artery bypass grafting on the beating heart and abdominal aortic aneurysm repair. *Ann Thorac Cardiovasc Surg* 2004; **10**: 29–33.
- 135 McFalls EO, Ward HB, Moritz TE, et al. Coronary-artery revascularization before elective major vascular surgery. *N Engl J Med* 2004; **351**: 2795–804.
- 136 Pierpont GL, Moritz TE, Goldman S, et al. Disparate opinions regarding indications for coronary artery revascularization before elective vascular surgery. *Am J Cardiol* 2004; **94**: 1124–28.
- 137 Paty PS, Darling RC, Chang BB, Lloyd WE, Kreienberg PB, Shah DM. Repair of large abdominal aortic aneurysm should be performed early after coronary artery bypass surgery. *J Vasc Surg* 2000; **31**: 253–59.
- 138 Prance SE, Wilson YG, Cosgrove CM, Walker AJ, Wilkins DC, Ashley S. Ruptured abdominal aortic aneurysms: selecting patients for surgery. *Eur J Vasc Endovasc Surg* 1999; **17**: 129–32.
- 139 Berg P, Kaufmann D, van Marrewijk CJ, Buth J. Spinal cord ischaemia after stent-graft treatment for infra-renal abdominal aortic aneurysms: analysis of the Eurostar database. *Eur J Vasc Endovasc Surg* 2001; **22**: 342–47.

- 140 Picone AL, Green RM, Ricotta JR, May AG, DeWeese JA. Spinal cord ischemia following operations on the abdominal aorta. *J Vasc Surg* 1986; **3**: 94–103.
- 141 Szilagyi DE, Hageman JH, Smith RF, Elliott JP. Spinal cord damage in surgery of the abdominal aorta. *Surgery* 1978; **83**: 38–56.
- 142 Coggia M, Javerliat I, Di Centa I, et al. Total laparoscopic infrarenal aortic aneurysm repair: preliminary results. *J Vasc Surg* 2004; **40**: 448–54.
- 143 Parodi JC, Palmaz JC, Barone HD. Transfemoral intraluminal graft implantation for abdominal aortic aneurysms. *Ann Vasc Surg* 1991; **5**: 491–99.
- 144 Greenhalgh RM, Brown LC, Kwong GP, Powell JT, Thompson SG. Comparison of endovascular aneurysm repair with open repair in patients with abdominal aortic aneurysm (EVAR trial 1), 30-day operative mortality results: randomised controlled trial. *Lancet* 2004; **364**: 843–48.
- 145 Prinssen M, Verhoeven EL, Buth J, et al. A randomized trial comparing conventional and endovascular repair of abdominal aortic aneurysms. *N Engl J Med* 2004; **351**: 1607–18.
- 146 Lederle FA. Abdominal aortic aneurysm—open versus endovascular repair. *N Engl J Med* 2004; **351**: 1677–79.
- 147 Laheij RJ, Buth J, Harris PL, Moll FL, Stelter WJ, Verhoeven EL. Need for secondary interventions after endovascular repair of abdominal aortic aneurysms: intermediate-term follow-up results of a European collaborative registry (EUROSTAR). *Br J Surg* 2000; **87**: 1666–73.
- 148 Vallabhaneni SR, Harris PL. Lessons learnt from the EUROSTAR registry on endovascular repair of abdominal aortic aneurysm repair. *Eur J Radiol* 2001; **39**: 34–41.
- 149 Beard J, Thomas S. Mid-term results of the RETA registry. *Br J Surg* 2002; **89**: 520.
- 150 Johnston KW. Nonruptured abdominal aortic aneurysm: six-year follow-up results from the multicenter prospective Canadian aneurysm study. *J Vasc Surg* 1994; **20**: 163–70.
- 151 Hallett JW Jr, Marshall DM, Petterson TM, et al. Graft-related complications after abdominal aortic aneurysm repair: reassurance from a 36-year population-based experience. *J Vasc Surg* 1997; **25**: 277–84; discussion 285–86.
- 152 Ouriel K, Srivastava SD, Sarac TP, et al. Disparate outcome after endovascular treatment of small versus large abdominal aortic aneurysm. *J Vasc Surg* 2003; **37**: 1206–12.
- 153 Peppelenbosch N, Buth J, Harris PL, van Marrewijk C, Fransen G. Diameter of abdominal aortic aneurysm and outcome of endovascular aneurysm repair: does size matter? A report from EUROSTAR. *J Vasc Surg* 2004; **39**: 288–97.
- 154 Curci JA, Petrinec D, Liao S, Golub LM, Thompson RW. Pharmacologic suppression of experimental abdominal aortic aneurysms: a comparison of doxycycline and four chemically modified tetracyclines. *J Vasc Surg* 1998; **28**: 1082–93.
- 155 Baxter BT, Pearce WH, Waltke EA, et al. Prolonged administration of doxycycline in patients with small asymptomatic abdominal aortic aneurysms: report of a prospective (Phase II) multicenter study. *J Vasc Surg* 2002; **36**: 1–12.
- 156 Bigatel DA, Elmore JR, Carey DJ, Cizmeci-Smith G, Franklin DP, Youkey JR. The matrix metalloproteinase inhibitor BB-94 limits expansion of experimental abdominal aortic aneurysms. *J Vasc Surg* 1999; **29**: 130–38; discussion 138–39.
- 157 Moore G, Liao S, Curci JA, et al. Suppression of experimental abdominal aortic aneurysms by systemic treatment with a hydroxamate-based matrix metalloproteinase inhibitor (RS 132908). *J Vasc Surg* 1999; **29**: 522–32.
- 158 Defawe OD, Kenagy RD, Choi C, et al. MMP-9 regulates both positively and negatively collagen gel contraction: a non-proteolytic function of MMP-9. *Cardiovasc Res* (in press).
- 159 Holmes DR, Petrinec D, Wester W, Thompson RW, Reilly JM. Indomethacin prevents elastase-induced abdominal aortic aneurysms in the rat. *J Surg Res* 1996; **63**: 305–09.
- 160 Gadowski GR, Pilcher DB, Ricci MA. Abdominal aortic aneurysm expansion rate: effect of size and beta-adrenergic blockade. *J Vasc Surg* 1994; **19**: 727–31.
- 161 Slaiby JM, Ricci MA, Gadowski GR, Hendley ED, Pilcher DB. Expansion of aortic aneurysms is reduced by propranolol in a hypertensive rat model. *J Vasc Surg* 1994; **20**: 178–83.
- 162 Propanol Aneurysm Trial Investigators. Propranolol for small abdominal aortic aneurysms: results of a randomized trial. *J Vasc Surg* 2002; **35**: 72–79.
- 163 Bellosta S, Via D, Canavesi M, et al. HMG-CoA reductase inhibitors reduce MMP-9 secretion by macrophages. *Arterioscler Thromb Vasc Biol* 1998; **18**: 1671–78.
- 164 Nagashima H, Aoka Y, Sakomura Y, et al. A 3-hydroxy-3-methylglutaryl coenzyme A reductase inhibitor, cerivastatin, suppresses production of matrix metalloproteinase-9 in human abdominal aortic aneurysm wall. *J Vasc Surg* 2002; **36**: 158–63.
- 165 Kertai MD, Boersma E, Westerhout CM, et al. Association between long-term statin use and mortality after successful abdominal aortic aneurysm surgery. *Am J Med* 2004; **116**: 96–103.
- 166 Gomes D, Louedec L, Plissonnier D, et al. Endoluminal smooth muscle cell seeding limits intimal hyperplasia. *J Vasc Surg* 2001; **34**: 707–15.
- 167 Allaire E, Muscatelli-Groux B, Guinault AM, et al. Vascular smooth muscle cell endovascular therapy stabilizes already developed aneurysms in a model of aortic injury elicited by inflammation and proteolysis. *Ann Surg* 2004; **239**: 417–27.