

## Short course chemotherapy followed by concomitant chemoradiotherapy and surgery in locally advanced rectal cancer: a randomized multicentric phase II study

R. Maréchal<sup>1\*</sup>, B. Vos<sup>1</sup>, M. Polus<sup>2</sup>, T. Delaunoit<sup>3</sup>, M. Peeters<sup>4</sup>, P. Demetter<sup>5</sup>, A. Hendlisz<sup>6</sup>, A. Demols<sup>1</sup>, D. Franchimont<sup>1</sup>, G. Verset<sup>1</sup>, P. Van Houtte<sup>6</sup>, J. Van de Stadt<sup>7</sup> & J. L. Van Laethem<sup>1</sup>

<sup>1</sup>Department of Gastroenterology, GI Cancer Unit, Erasme University Hospital, Brussels; <sup>2</sup>Department of Gastroenterology, CHU Sart-Tilman, Liège; <sup>3</sup>Department of Gastroenterology and Medical Oncology, CHR Jolimont, Haine-Saint-Paul; <sup>4</sup>Department of Gastroenterology, UZ Ghent, Ghent; <sup>5</sup>Department of Pathology, Erasme University Hospital, Brussels; <sup>6</sup>Department of Medical Oncology, Institut Jules Bordet, Brussels; <sup>7</sup>Department of Digestive Surgery, Erasme University Hospital, Brussels, Belgium

Received 13 May 2011; revised 13 September 2011; accepted 13 September 2011

**Background:** Induction chemotherapy has been suggested to impact on preoperative chemoradiation efficacy in locally advanced rectal cancer (LARC). To evaluate in LARC patients, the feasibility and efficacy of a short intense course of induction oxaliplatin before preoperative chemoradiotherapy (CRT).

**Patients and methods:** Patients with T2-T4/N+ rectal adenocarcinoma were randomly assigned to arm A—preoperative CRT with 5-fluorouracil (5-FU) continuous infusion followed by surgery—or arm B—induction oxaliplatin, folinic acid and 5-FU followed by CRT and surgery. The primary end point was the rate of ypT0-1N0 stage achievement.

**Results:** Fifty seven patients were randomly assigned (arm A/B: 29/28) and evaluated for planned interim analysis. On an intention-to-treat basis, the ypT0-1N0 rate for arms A and B were 34.5% (95% CI: 17.2% to 51.8%) and 32.1% (95% CI: 14.8% to 49.4%), respectively, and the study therefore was closed prematurely for futility. There were no statistically significant differences in other end points including pathological complete response, tumor regression and sphincter preservation. Completion of the preoperative CRT sequence was similar in both groups. Grade 3/4 toxicity was significantly higher in arm B.

**Conclusions:** Short intense induction oxaliplatin is feasible in LARC patients without compromising the preoperative CRT completion, although the current analysis does not indicate increased locoregional impact on standard therapy.

**Key words:** oxaliplatin, radiochemotherapy, rectal adenocarcinoma

### introduction

Rectal cancer remains a significant cause of morbidity and mortality in industrialized countries [1]. Although the emergence of total mesorectum excision (TME) as a new surgical standard technique has led to a significant decrease in local recurrence rate, development of new neoadjuvant strategies can improve both local tumor control and tumor response and possibly the rate of distant recurrence and subsequently survival [2].

Standard treatment for patients with locally advanced rectal cancer (LARC) includes combined chemotherapy and radiotherapy administered before definitive TME. Previous reports have shown advantages to neoadjuvant chemoradiotherapy (CRT) in downstaging large tumors and in

improving local tumor control, resulting in a local relapse rate of <10% after 5 years [3–7]. Unfortunately, despite such low local recurrence rate, the 5-year distant relapse in nearly all the current trial is ~30% and continues to be a challenge by limiting survival benefit [6, 7]. Patients with pathological complete response (pCR) after CRT have better long-term outcome than those without pCR [8]. Adjunction of oxaliplatin to the protracted 5-fluorouracil (5-FU) venous infusion during the radiotherapy did not significantly modify the pCR rate and the distant recurrence rate while the impact on disease-free survival (DFS) is still awaited [9, 10]. The potential benefit of chemotherapy induction before concomitant CRT in LARC patients has been raised in recent studies. In LARC, protracted venous infusion 5-FU and mitomycin C-based chemotherapy induction administered before the CRT allowed R0 resection in 82% of patients with negligible risk of disease progression and low risk of systemic spread [11]. The substitution of mitomycin C by new appropriate chemotherapeutic agents, intrinsically more active against colorectal cancer cells, could be of benefit.

\*Correspondence to: Prof. R. Maréchal, Department of Gastroenterology, GI Cancer Unit, Erasme University Hospital, Université Libre de Bruxelles (ULB), Route de Lennik 808, 1070 Brussels, Belgium. Tel: +32-2-555-37-15; Fax: +32-2-555-4802; E-mail: raphael.marechal@erasme.ulb.ac.be

FOLFOX4 and CAPOX (capecitabine and oxaliplatin) combinations administered in a 12-week short intense induction regimen and followed by tegafur- or capecitabine-sensitized preoperative chemoradiation resulted in substantial tumor regression, rapid symptomatic response and no disease progression during preoperative treatment [8, 12, 13]. However, the real impact of this strategy on tumor response and local control remains questionable since it only relies on historical comparison. Based on these promising results, we designed a randomized phase II trial exploring the impact of a short intense course of oxaliplatin-based chemotherapy (two cycles) before the conventional preoperative CRT.

## patients and methods

### patient selection

Patients with histologically proven resectable rectal adenocarcinoma, staged as clinically T2-4 N+ amenable to indication for CRT and resection were included in the study.

The eligibility criteria were as follows: no prior treatment of this cancer (chemotherapy, radiotherapy) at the exception of colostomy, no evidence of metastatic disease on clinical examination and computed tomography (CT) of chest, abdomen and pelvis; Eastern Cooperative Oncology Group performance status of two or less, age  $\geq 18$  years old, an adequate bone marrow reserve, normal renal and liver functions (polymorphonuclear  $> 1,5 \times 10^9/L$ , platelet  $> 100 \times 10^9/L$ , creatinine clearance  $\geq 30$  ml/min, total bilirubin concentration  $< 1.5 \times$  the upper normal limit, prothrombine time  $\leq 1,5 \times$  the upper normal limit).

Exclusion criteria included metastatic disease, previous treatment (chemotherapy or radiotherapy) for this cancer excepted colostomy; other cancers; known hypersensitivity to any components of study treatments; chronic inflammatory disease of the ileum or the colon; peripheral sensory neuropathy with functional impairment; clinically significant cardiovascular disease (including myocardial infarction, unstable angina, symptomatic congestive heart failure, serious uncontrolled cardiac arrhythmia  $\leq 12$  months before randomization); major surgical procedure  $\leq 28$  days before randomization; medical or psychological conditions that would not permit the patient to complete the study or sign informed consent; pregnancy or breast feeding. This study was approved by the appropriate ethic committee. We obtained written informed consent from all patients before study entry.

### evaluation criteria

Before entry into the study, all patients were assessed by a multidisciplinary team comprising medical, radiation and surgical oncologists, gastroenterologists and radiologists. Patients underwent a medical history, physical examination and staging [pelvic magnetic resonance imaging (MRI); abdominal–pelvis and chest CT scan, colonoscopy]. Endorectal ultrasound was carried out in case of doubtful distal T3 tumors after MRI.

At 4–6 weeks after the CRT completion, the stage of the disease was reevaluated by repeating chest–abdomen–pelvic CT scan and pelvic MRI, in order to assess primary tumor response and to exclude the presence of distant metastases.

Patients were monitored biweekly by history and physical examination. Complete hematology and biochemistry were carried out at each cycle. Toxicity was graded according to National Cancer Institute—Common Toxicity Criteria, version 3.0.

### study design and treatment plan

The patients were randomly allocated between the arm A—which consisted in preoperative CRT (protracted 5-FU venous infusion) followed by TME (control arm)—or the arm B—short course FOLFOX chemotherapy induction (two cycles) followed by the same preoperative CRT and TME

(experimental arm). Random assignment was carried out centrally, and patients were stratified by institution.

*chemoradiation.* Radiotherapy was delivered by a linear accelerator with a minimum of 6 MV by using three or four fields and three-dimensional conformal planning. Usually  $\geq 15$  MV was necessary.

A CT scanner in treatment position will be obtained with joined slices, allowing a three-dimensional reconstruction on a treatment planning system. The maximal distance between the slices was 0.5 cm in the region of the tumor. The reference dose per fraction will be 1.8 Gy at the isocenter, according to ICRU report 50 (1.8 Gy per fraction, 5 days per week). All patients received a total dose of 45 Gy, and a daily fraction of 1.8 Gy was received 5 days per week. During radiotherapy, 5-FU was delivered i.v. in a continuous dose of 225 mg/m<sup>2</sup>/day.

*induction chemotherapy (arm B).* Two cycles of modified FOLFOX6 (mFOLFOX6) was administered before the conventional preoperative CRT. Oxaliplatin was administered on day 1 at a dose of 100 mg/m<sup>2</sup> i.v. over 2 h, with folinic acid 400 mg/m<sup>2</sup> on day 1, 5-FU bolus 400 mg/m<sup>2</sup> on day 1, 5-FU 2000 mg/m<sup>2</sup> CVI over a 46 h period, day 1 = day 14.

Chemotherapy and radiotherapy were interrupted if a grade 3 or 4 toxicity was encountered (except for anemia). Study treatment was restarted when toxicity had resolved to grade  $\leq 1$ . Dose reduction was required after grade 3–4 toxicity. The treatment was resumed at 75% of the original dose for the first or 50% of the original dose for the second occurrence of toxicity.

### surgery and pathology

TME was carried out in both treatment arms at 6–8 weeks after the completion of CRT. The final choice of surgical procedure (abdominoperineal resection or sphincter preservation surgery) was at the surgeon's discretion. Standard pathology examination was carried out by using the methodology of Quirke et al. [14]. Tumor staging was carried out according to the American Joint Committee on Cancer version 6 [15]. A pCR was defined as the absence of viable tumor cells in the primary tumor and the lymph nodes (ypT0N0). R1 resection was defined as tumor cells  $\leq 1$  mm from the circumferential resection margin. Residual tumor masses were semiquantitatively evaluated according to the five-point regression grading scale established by Dworak et al. [16]. Administration of adjuvant chemotherapy was left at the investigator's discretion.

### study end point and statistics

The study was a multicenter, phase II randomized trial.

The primary end point was the ypT0-1N0 rate. Secondary end points included the pCR rate, toxic effects and the sphincter preservation rate.

The expected number of patients for this study had been calculated according to the Simon's optimal two-stage minimax design [17]. Based on previous studies, the projected ypT0-1N0 rate in the control arm (arm A) was 20% [6, 7] and an absolute 20% improvement in ypT0-1N0 rate was deemed clinically significant.

With an  $\alpha$  error of 0.13 and a power of 85%, the planned study would proceed as followed: after a first stage of 28 assessable patients per arm, if two or more patients with a ypT0-1N0 tumor are observed in the experimental arm compared with the control arm, accrual of 30 additional patients per arm in stage 2 (total of 58 per arm) will be achieved. If this condition is not met, the study will be stopped for futility.

After the second step, if there are six or more ypT0-1N0 tumor in the experimental arm than in the control arm, it can be concluded that the rate of ypT0-1N0 tumor is statistically significantly greater than that of the control arm. Differences between ratios were analyzed with the  $\chi^2$  or Fisher's exact test, as appropriate.

We report here the study results of the planned interim analysis for all eligible patients in an intention-to-treat analysis (stage 1).

## results

### patients' characteristics

Demographic and tumor characteristics of the 57 enrolled patients are summarized in Table 1. Most of the patients were men and the predominant clinical disease stage was cT3N+. The majority of the tumors were located in the low and the middle third of the rectum. Patients' characteristics were well balanced between the two arms.

### treatment exposure and compliance

In both arms, all the eligible patients started the allocated treatment. Overall, 28/29 patients (97%) in arm A and 27/28 patients (96%) in arm B completed the study as per protocol. One patient in arm A and one patient in Arm B did not undergo surgery because of distant disease progression after radiochemotherapy completion (arm A) and one toxic-related

death during the chemotherapy induction (arm B). In arm B, 27/28 patients (96%) received the two cycles of mFOLFOX6 [mean relative dose intensity (RDI), 97%]. The mean RDI of 5-FU administered during CRT was 99% and 92% for arm A and B, respectively (Table 2). In both arms, all the patients who started CRT completed the planned radiation therapy.

### toxicity

During chemotherapy induction (arm B), 6 out 28 patients (21%) experienced grade 3–4 toxicity and one chemotherapy-related death due to febrile neutropenia was recorded. Toxic effects were gastrointestinal (diarrhea, 7%; vomiting, 4%), hematological (neutropenia, 7%; thrombopenia, 4%) and neurologic (paresthesia, 4%). During preoperative CRT, the rate of grade 3 to 4 toxicity was similar between the two arms [2/29 patients (7%) in arm A and 2/28 patients (7%) in arm B] (Table 2).

**Table 1.** Population baseline characteristics

Characteristics	Arm A (n = 29) No. (%)	Arm B, induction CT (n = 28) No. (%)	P-value
Age, years			0.92
Median (range)	62 (44–79)	62 (22–80)	
Gender			0.17
Male	16 (55)	21 (75)	
Female	13 (45)	7 (25)	
ECOG status			0.19
0	25 (83)	21 (75)	
1	4 (17)	7 (25)	
LARC staging by US ± MRI			0.52
cT2	3 (10)	1 (4)	
cT3	23 (79)	25 (89)	
cT4	3 (10)	2 (7)	
Any cTxN+	25 (86)	26 (93)	0.94
Tumor location			0.43
Lower third	13 (45)	11 (39)	
Middle third	9 (31)	13 (46)	
Upper third	7 (24)	4 (25)	
Circumferential margin (MRI)			0.10
> 5mm	15 (52)	18 (64)	
≤ 5mm	9 (31)	7 (25)	
Not carried out	5 (17)	3 (11)	
Pathological grade			0.57
Not otherwise specified	2 (7)	1 (4)	
Well differentiated	9 (31)	7 (25)	
Moderately differentiated	16 (55)	18 (64)	
Poorly differentiated	1 (3)	1 (4)	
Operated	28 (97)	27 (96)	0.88
TME	23 (79)	24 (86)	
APR	5 (17)	3 (11)	

APR, abdominoperineal amputation; CRM, circumferential resection margin; CT, chemotherapy; ECOG, Eastern Cooperative Oncology Group; LARC, locally advanced rectal cancer; MRI, magnetic resonance imagery; TME, total mesorectum excision; US, ultrasonography.

**Table 2.** Treatment compliance and toxic effects observed by treatment groups

	Arm A (n = 29) No. (%)	Arm B: induction CT (n = 28) No. (%)	P-value
Treatment completion (per study protocol)			
Neoadjuvant FOLFOX6			
RDI oxaliplatin	—	97	
RDI 5-FU	—	97	
Full doses FOLFOX6	—	27 (96)	
completed			
5-FU-based RCT			
5-FU ≥5 weekly courses	28 (97)	23 (86)	
RDI 5-FU	99	92	
RT completed	29 (100)	27 (96)	
Treatment complications			
Neoadjuvant FOLFOX			
Grade 3–4 toxicity			
Gastrointestinal	—	3 (11)	
Hematological	—	3 (11)	
Muco-cutaneous	—	1 (4)	
Paresthesia	—	1 (4)	
5-FU-based RCT			
Grade 3–4 toxicity			
Gastrointestinal	1 (4)	1 (4)	
Hematological	—	1 (4)	
Muco-cutaneous	1 (4)	—	
Global grade 3–4 toxicity	2 (7)	10 (36)	0.017
Postoperative complications			
Global postoperative complications	9 (31)	7 (25)	0.61
Anastomotic leak	1 (4)	0 (0)	
Pelvic/perineal infections	7 (24)	6 (21)	
Ileo/pseudoocclusive	1 (4)	—	
Dehiscence	—	1 (4)	
Any complication	20 (69)	21 (75)	

RCT, radiochemotherapy; RDI, relative dose intensity; 5-FU, 5-fluorouracil.

**efficacy parameters**

There was no difference for the primary end point of the study between the two arms. On the basis of an intent-to-treat analysis, ypT0-1N0 tumor stage was achieved in 10 patients in arm A (34.5%; 95% CI: 17.2% to 51.8%) and in 9 patients (32.1%; 95% CI: 14.8% to 49.4%) in arm B. After the first stage of the study, preplanned analysis indicated that more ypT0-1N0 tumors were observed in the control group in comparison with the experimental arm. These results did not meet the prerequisite conditions to accrue more patients and the study was thus prematurely closed for futility.

The pCR rate achievement did not differ between the conventional (pCR rate: 28%; 95% CI: 11.3% to 43.9%) and the experimental arm (pCR rate: 25%; 95% CI: 9.0% to 41.0%). The proportion of the different ypT subcategories as well as the T and N downstaging, the tumor regression grade and the sphincter preservation rate were similar between the two arms

**Table 3.** End points for the total patient group

End point	Arm A (n = 29) No. (%)	Arm B: induction CT (n = 28) No. (%)	P-value
Tumor gross diameter, mm			
Median (range)	26 (1–100)	24 (2–80)	—
Pathological T stage			—
ypT0	8	7	
ypTis	1	1	
ypT1	1	1	
ypT2	5	4	
ypT3	12	13	
ypT4	1	1	
Median number of examined LN (range)	12 (4–28)	12 (5–25)	—
Pathological N stage			—
ypN0	16	13	
ypN1	9	9	
ypN2	3	5	
ypT0-1N0	10 (34)	9 (32)	0.85
95% CI (%)	17.2 to 51.8	14.8 to 49.4	
pCR	8 (28)	7 (25)	0.92
95% CI (%)	11.3 to 43.9	9.0 to 41.0	
Downstaging			
T downstaging	14 (48)	13 (46)	0.99
N downstaging	16 (55)	12 (43)	0.64
Circumferential margin + (≤1 mm)	4 (14)	1 (4)	0.35
Tumor response grade <sup>a</sup>			0.67
4: complete regression	8 (28)	7 (26)	
3: >50% of tumor mass	5 (17)	6 (22)	
2: ≥25% to 50% of tumor mass	6 (21)	8 (30)	
1: <25% of tumor mass	8 (28)	5 (18)	
0: no regression	1 (3)	0 (0)	
Not otherwise specified	1 (3)	1 (4)	

CT, chemotherapy; pCR, pathological complete response; TRG, tumor regression grade.

<sup>a</sup>The denominators were the patients who actually underwent resection.

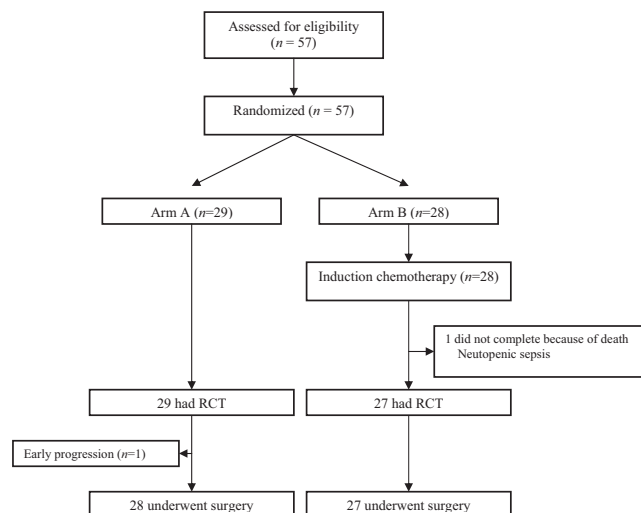
(Table 3). Only one patient progressed during the protocol (arm A).

**discussion**

Our study, reported as the preplanned interim analysis, reveals that a short course of oxaliplatin- and 5-FU-based chemotherapy before the conventional CRT results in similar ypT0-1N0, ypCR, R0 resection, T and N downstaging and tumor regression grade. Indeed, we have observed that the number of ypT0-1N0 tumor in the treatment arm was lower than in the control arm and according to our statistical hypothesis, we had no chance to detect a positive signal with this strategy by completing the whole study. We have to notice that the ypT0-1N0 rate of 36% in the standard arm was substantially higher than previously reported in the FFOCD and EORTC randomized phase III trials [6, 7]. In the same way, the pCR rate we observed in the CRT arm (28%) was about twofold higher than previously reported in phase III studies [6, 7] meaning that we are probably overstaging a large proportion of patients who probably do not require chemoradiation. This observation underlines the absolute need to have a prospective control group in phase II trials in order to detect selection bias, which could artificially increment the efficacy of a new therapeutic strategy.

The most compelling results of this study concern the secondary end points. During the course of the CRT, there was no difference between the two arms regarding the number of patients with grade 3/4 toxic effects and the rate of patients who completed the planned CRT clearly suggesting that this strategy is feasible. However, grade 3 and 4 toxic effects were overall more frequent in arm B than in arm A due to additional toxic effects only observed during the administration of the induction chemotherapy.

Our study was the first to evaluate a short mFOLFOX6 chemotherapy induction administered before the standard concomitant radiotherapy and 5-FU. Two phase II studies have evaluated the adding value of induction chemotherapy before the conventional neoadjuvant CRT [12, 13]. All of these studies



**Figure 1.** CONSORT diagram showing the flow of participants.

demonstrated the feasibility of such approach with a negligible risk of disease progression and a low risk of systemic spread during the chemotherapy induction. With a pCR rate ranging from 20% to 29% and ypT0 rate achievement between 26% and 44%, chemotherapy induction seems to be interesting although its real impact on tumor response and patient's outcome remains questionable since it only relies on historical comparison [8, 12, 13].

Only one randomized phase II study has assessed the feasibility of an oxaliplatin-based chemotherapy before CRT and TME in LARC [18]. Induction CAPOX regimen followed by CRT with capecitabine, oxaliplatin and concurrent radiation was compared with CRT followed by surgery. As observed in our study, the pCR was similar between the two arms and there were no statistically significant difference between downstaging, tumor regression and R0 resection. However, compared with postoperative adjuvant CAPOX, induction CAPOX before CRT achieved a more favorable compliance and a better toxicity profile. Although the incidence of treatment-related death in this study reached 5%, the authors suggested that the optimal therapeutic sequence would include induction chemotherapy followed by CRT and surgery because induction chemotherapy may be associated with a better efficacy and compliance than the adjuvant chemotherapy without compromising completion of the CRT. One of the difficulties of such strategy is to accurately select the patients who require neoadjuvant chemotherapy with the risk of overtreatment. In the German CAO/ARO/AIO 94 rectal cancer trial, 18% of patients who were clinically staged as suitable for preoperative CRT may be over staged [19]. As there is no significant additional effect on local tumor response, it seems to be useless to recommend this combined strategy to high-risk tumors defined by MRI [20]. Another important question in this neoadjuvant strategy is the length of the preoperative chemotherapy course, which was longer in the other studies [8, 11, 13]. Based on the existing data, it may be suggested that a longer course of chemotherapy is preferable providing that disease control rate is high.

Another strategy to decrease distant relapse in LARC is the adjunction of oxaliplatin (once a week) to the 5-FU-based CRT. Adding oxaliplatin did not increase the rate of pCR in the two randomized phase III trials, PRODIGE-ACCOR-2 and STAR 01 [9, 10]. The real impact of the adjunction of oxaliplatin needs longer follow-up data as it is expected that oxaliplatin may impact on the incidence of distant relapse. These results raise the question of the interest of the pCR as a surrogate marker of treatment efficacy in the evaluation of new neoadjuvant strategies in LARC. Indeed, it remains questionable whether, if this earlier end point (pCR) is associated with later end points such as DFS and overall survival (OS) [21]. In the FFCD and EORTC randomized trials, an improvement of 10% in the pCR did not translate into the improvement of OS [6, 7]. However, recent pooled analyses have suggested the prognostic value of the pCR [22]. Although most of the studies considered for the analysis were retrospective, the pCR was associated with significantly improved DFS and OS. In the absence of better early signals of potential efficacy, the pCR could be thus a reasonable end point, especially in phase II trials aiming at determine new strategies efficacy [22]. Whether combined neoadjuvant

strategies impact on pCR and patient outcome remain to be explored in well-designed phase III studies.

Our negative results gathered at the primary end point might be partially explained by a too short duration (low dose-intensity) of the FOLFOX chemotherapy. Furthermore, ypT0-1N0 status seems to be an inappropriate end point as there is no additional effect of FOLFOX induction chemotherapy on local tumor response. For this study, long-term DFS might serve as a more qualified end point to evaluate the real impact of our strategy on patients' outcome. To this end, follow-up data analysis will be informative and will allow definitive conclusions.

In conclusion, a short induction course of chemotherapy before conventional preoperative 5-FU and concurrent radiotherapy, although well feasible, did not appear to impact on local tumor regression.

## acknowledgements

Presented in part at the 46th Annual Meeting of the American Society of Clinical Oncology, Chicago, IL, 4–8 June 2010. EudraCT: 2006-006646-34.

## disclosure

The authors declare no conflicts of interest.

## references

- O'Connell MJ, Martenson JA, Wieand HS et al. Improving adjuvant therapy for rectal cancer by combining protracted-infusion fluorouracil with radiation therapy after curative surgery. *N Eng J Med* 1994; 331: 502–507.
- Heald RJ, Moran BJ, Ryall RD et al. Rectal cancer: the Basingstoke experience of total mesorectal excision, 1978-1997. *Arch Surg* 1998; 133: 894–899.
- Kapiteijn E, Marijnen CAM, Nagtegaal ID et al. Preoperative radiotherapy combined with total mesorectal excision for resectable rectal cancer. *N Eng J Med* 2001; 345: 638–646.
- Marijnen CAM, Peeters KCMJ, Putter H et al. Long term results, toxicity and quality of life in the TME trial. *Radiother Oncol* 2004; 73 (Suppl 1): S127.
- Sauer R, Becker H, Hohenberger W et al. Preoperative versus postoperative chemoradiotherapy for rectal cancer. *N Eng J Med* 2004; 351: 1731–1740.
- Gerard JP, Conroy T, Bonnetain F et al. Preoperative radiotherapy with or without concurrent fluorouracil and leucovorin in T3-T4 rectal cancers: results of the FFCD 9203 randomized trial. *J Clin Oncol* 2006; 24: 4620–4625.
- Bosset JF, Collette L, Calais G et al. Chemotherapy with preoperative radiotherapy in rectal cancer. *N Eng J Med* 2006; 355: 1114–1123.
- Chua YJ, Barbachano Y, Cunningham D et al. Neoadjuvant capecitabine and oxaliplatin before chemoradiotherapy and total mesorectal excision in MRI-defined poor-risk rectal cancer: a phase 2 study. *Lancet Oncol* 2010; 11: 241–247.
- Gerard JP, Azria D, Gourgou-Bourgade S et al. Comparison of two neoadjuvant chemoradiotherapy regimens for locally advanced rectal cancer: results of the phase III trial ACCORD 12/0405-Prodige 2. *J Clin Oncol* 2010; 28: 1638–1644.
- Aschele C, Pinto C, Cordio S et al. Preoperative fluorouracil (FU)-based chemoradiation with and without weekly oxaliplatin in locally advanced rectal cancer: pathologic response analysis of the Studio Terapia Adjuvante Retto (STAR)-01 randomized phase III trial. *J Clin Oncol* 2009; 27 (Suppl): 170s (Abstr CRA4008).
- Chau I, Allen M, Cunningham D et al. Neoadjuvant systemic fluorouracil and mitomycin C prior to synchronous chemoradiation is an effective strategy in locally advanced rectal cancer. *Br J Cancer* 2003; 88: 1017–1024.

12. Chau I, Brown G, Cunningham D et al. Neoadjuvant capecitabine and oxaliplatin followed by synchronous chemoradiation and total mesorectal excision in magnetic resonance imaging-defined poor-risk rectal cancer. *J Clin Oncol* 2006; 24: 668–674.
13. Calvo FA, Serrano FJ, Diaz-Gonzalez JA et al. Improved incidence of pT0 downstaged surgical specimens in locally advanced rectal cancer (LARC) treated with induction oxaliplatin plus 5-fluorouracil and preoperative chemoradiation. *Ann Oncol* 2006; 17: 1103–1110.
14. Quirke P, Durdey P, Dixon MF, Williams NS. Local recurrence of rectal adenocarcinoma due to inadequate surgical resection: histopathological study of lateral tumour spread and surgical excision. *Lancet* 1986; 2: 996–999.
15. Greene FL, Page DL, Fleming ID. Colon and rectum. In: Greene FL, Page DL, Fleming ID, Fritz AP, Balch C, Haller DG, Morrow M (eds), *AJCC Cancer Staging Manual*, 6th edition. Vol. 99. New York, NY: Springer 2002; 113–124.
16. Dworak O, Keilholz L, Hoffmann A. Pathological features of rectal cancer after preoperative radiochemotherapy. *Int J Colorectal Dis* 1997; 12: 19–23.
17. Simon R. Optimal two-stage designs for phase II clinical trials. *Control Clin Trials* 1989; 10: 1–10.
18. Fernandez-Martos C, Pericay C, Aparicio J et al. Phase II, randomized study of concomitant chemoradiotherapy followed by surgery and adjuvant capecitabine plus oxaliplatin (CAPOX) compared with induction CAPOX followed by concomitant chemoradiotherapy and surgery in magnetic resonance imaging-defined, locally advanced rectal cancer: Grupo Cancer de Recto 3 Study. *J Clin Oncol* 2010; 5: 859–865.
19. Guillem JG, Diaz-González JA, Minsky BD et al. cT3N0 rectal cancer: potential overtreatment with preoperative chemoradiotherapy is warranted. *J Clin Oncol* 2008; 26: 368–373.
20. MERCURY Study Group. Diagnostic accuracy of preoperative magnetic resonance imaging in predicting curative resection of rectal cancer. *BMJ* 2006; 222: 779.
21. Methy N, Bedenne L, Conroy T et al. Surrogate end points for overall survival and local control in neoadjuvant rectal cancer trials: statistical evaluation based on the FFCD 9203 trial. *Ann Oncol* 2010; 21: 518–524.
22. Maas M, Nelemans PJ, Valentini V et al. Long-term outcome in patients with pathological complete response after chemoradiation for rectal cancer: a pooled analysis of individual patient data. *Lancet Oncol* 2011; 11: 835–844.