

Emmanuelle UHODA  
Claudine PIÉRARD-  
FRANCHIMONT  
Ludivine PETIT  
Gérald PIÉRARD

Department of Dermatopathology,  
University Hospital Sart Tilman,  
B-4000 Liège, Belgium

Reprints: G.E. Piérard  
Fax: (+ 32) 4 366 29 76  
Email: gerald.pierard@ulg.ac.be

## Skin weathering and ashiness in black Africans

Ashiness describes a common physiological skin condition that may develop in people with dark skin complexion. Environmental influences, particularly cold and dry weather, seem obvious. This condition has seldom been studied so far. In the present study, skin ashiness was assessed in 37 black African women by means of colorimetric assessments and xerosis ratings. Colour changes were measured by the parameters  $a^*$  and the individual typology angle  $ITA^\circ$ . Xerosis was assessed by visual inspection, the ultraviolet light-enhanced visualization (ULEV) method, and the cyanoacrylate skin surface stripping (CSSS) method. The assessments were performed on ashy skin of the legs and on the normal looking forehead during the winter season. Ashy skin was lighter but not erythematous. The  $ITA$ -revealed colour changes were correlated with xerosis severity as assessed by dry dermoscopy and by the ULEV and CSSS methods. In conclusion, ashiness due to skin weathering does not appear to be related to mild inflammation. It corresponds to a peculiar type of xerosis with reduction in Fresnel reflection by the *stratum corneum*.

**Key words:** environment, ethnicity, skin complexion, skin dryness, *stratum corneum*, xerosis

Article accepted on 15/09/2003

**E**thnicity plays an important role in the clinical presentation of diverse skin disorders [1, 2]. In particular, colour changes of lesional skin may be quite prominent in dark skin individuals. This may represent a psychologically distressing condition because of its persistent and visible nature. In particular, ashy hue may develop at the site of a variety of inflammatory skin disorders [2]. Among them, ashy dermatitis which is synonymous with erythema dyschromicum persans is a distinctive melanoderma of unknown etiology combining macular erythema and presence of melanophages in the dermis [3, 4]. Ashiness is a lay term describing another condition characterized by any xerotic process with loss of natural skin shine that prevails in individuals with dark skin complexion [5]. Ashen and ashing skin are other terms used for a similar condition in reference to restricted body sites including the elbows and knees.

This study was performed in black Africans who suffered from seasonal ashiness while under the geoclimatic environment of Belgium.

### Material and methods

The study was performed in winter in 37 women aged from 25 to 38 years. They were phototype VI Africans living in the Liège region for at least 2 years. They complained of seasonal ashiness predominating on the limbs. They were not allowed to use any cosmetic product on the skin for 10 days before the instrumental assessments.

The skin colour was measured on the forehead and on lesional skin of the legs using tristimulus reflectance colorimetry (Chroma Meter CR 200, Minolta, Osaka, Japan). The measurement procedure was performed in the  $L^*a^*b^*$  mode following the EEMCO recommendations [6]. The mean value of 5 measurements was recorded in each subject. The so-called individual typology angle ( $ITA^\circ$ ) [6, 7] was derived following  $ITA^\circ = \text{Arc Tangent} [(L^* - 50)/b^*] \cdot 180\pi^{-1}$ . The values of  $a^*$  and  $ITA^\circ$  served to quantify erythema and the skin typology, respectively.

The skin surface was observed and the severity of xerosis was assessed using the overall dry skin score (ODS) as defined by the EEMCO guidelines [8] and shown in Table I.

Table I. Overall dry skin (ODS) score according to the EEMCO guidelines [from ref. 8]

Score	Description
0	Absent
1	Faint scaling, faint roughness and dull appearance
2	Small scales in combination with a few larger scales, slight roughness, whitish appearance
3	Small and larger scales uniformly distributed, definite roughness, possibly slight redness and possibly a few superficial cracks
4	Dominated by large scales, advanced roughness, redness present, eczematous changes and cracks

Table II. Patterns and severity scores of xerosis as assessed by the ultraviolet light enhanced visualization (ULEV) method and by cyanoacrylate skin surface strippings

Grade	Pattern of xerosis
0	Normal <i>stratum corneum</i>
1	Hyperkeratosis of the primary and secondary lines and/or the appendageal orifices
2	Hyperkeratosis covering less than 30% of the plateaus
3	Hyperkeratosis covering more than 30% of the plateaus
4	Diffuse confluent scales
5	Thick, uneven scales covering the entire surface, obliterating the skin surface furrows

Dry dermoscopy [9, 10] was used to enhance detailed visual perception of xerosis. In addition, the ultraviolet light-enhanced visualization (ULEV) method was used to increase the sensitivity of the observations. For that purpose, a CCD camera equipped with an internal ultraviolet light illumination (Visioscan® VC98, C + K electronic, Cologne, Germany) recorded scaliness as previously described [10, 11]. A cyanoacrylate skin surface stripping (CSSS) harvested as previously described [12-14] on the legs. The severity of xerosis was rated under the microscope according to a grading scale identical to that used for the ULEV method (Table II).

The mean and SD of the  $a^*$  and  $ITA^\circ$  values were calculated. Intra-individual comparisons were made for each colorimetric value between the forehead skin and lesional skin using the two-tailed paired Student *t* test. Correlations between the values of these parameters were searched for using regression model analysis with calculation of the coefficient of correlation *r*. Similar statistical assessments were performed to evaluate the relationships between, on the one hand,  $ITA^\circ$  values and, on the other hand, xerosis severity as assessed by dry dermoscopy, and the ULEV and CSSS methods. A *p* value lower than 0.05 was considered statistically significant.

## Results

Erythema as assessed by the  $a^*$  parameter was similar ( $p = 0.46$ ) on the forehead ( $8.3 \pm 1.3$ ) and on the legs ( $8.5 \pm 1.5$ ). By contrast, the  $ITA^\circ$  value of the forehead ( $-33 \pm 3$ ) was significantly lower ( $p < 0.01$ ) than on leg ashiness ( $-29.7 \pm 6.6$ ). A weak correlation was found between the  $a^*$  and  $ITA^\circ$  values on the forehead ( $r = 0.42$ ), but was absent on leg ashiness ( $r = -0.02$ ).

Xerosis of leg ashiness (Fig. 1) was recognized by dry dermoscopy grading ( $2.7 \pm 0.8$ ), ULEV assessment ( $3.3 \pm 0.9$ ) and CSSS xerosis grading ( $3.7 \pm 0.9$ ). Correlations were found between each of the 3 rating methods of xerosis and  $ITA^\circ$  values (Table III, Figs. 2-4).

## Discussion

Xerosis responsible for ashiness reduces the natural skin shine and presents as whitish areas in darker skinned indi-

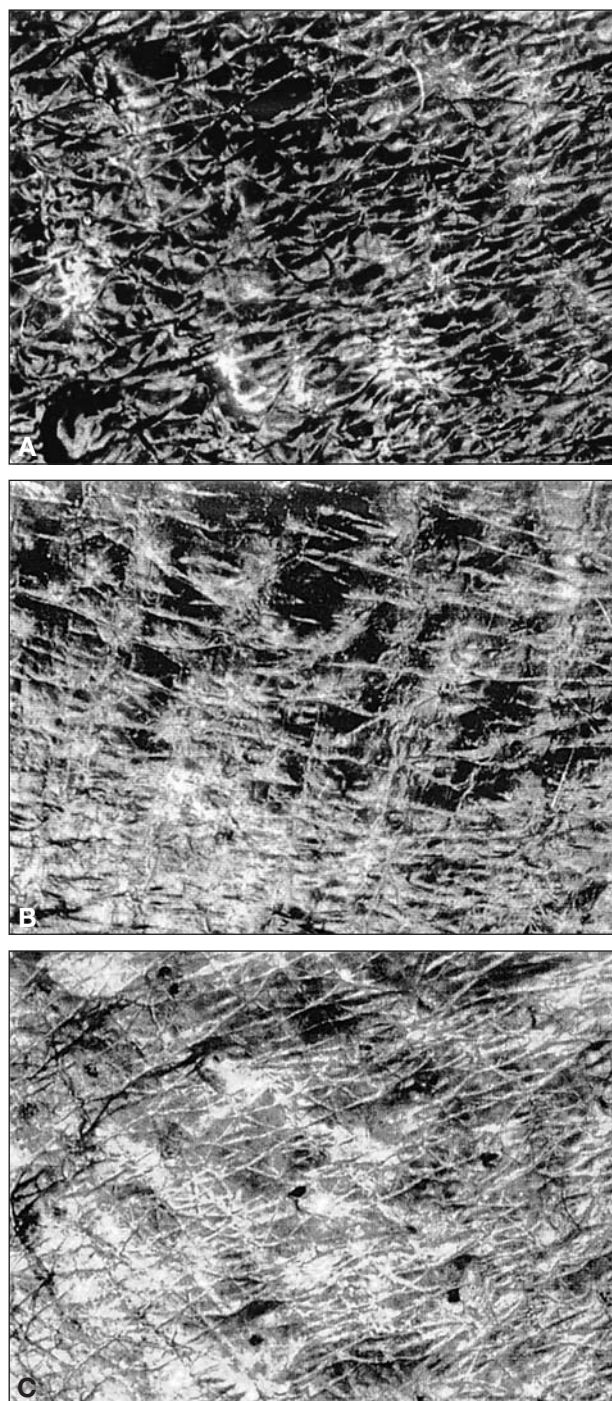


Figure 1. Ultraviolet light-enhanced visualization (ULEV) of skin ashiness. a) grade 2, b) grade 3, c) grade 4.

viduals. Cross-polarized imaging combining image analysis and clinical pattern recognition has been suggested to quantify this skin condition [5]. Skin weathering, particularly during winter, results in some physiological and structural changes [11, 15-25]. Exposure to a cold environment alters the activity of desquamatory enzymes [11, 26]. This effect is amplified when the relative humidity of air is reduced with ensuing water depletion in the outer *stratum*

Table III. Coefficients of correlation  $r$  between the individual typology angle ( $ITA^\circ$ ) and xerosis ratings by dry dermoscopy, ultraviolet light enhanced visualization (ULEV) and by cyanoacrylate skin surface stripping (CSSS) examination

	ULEV	CSSS	$ITA^\circ$
Dry dermoscopy	0.65	0.68	0.73
ULEV		0.83	0.76
CSSS			0.83

corneum [19, 23]. The combination of cold and dry threat can be expressed by dew point variations [15, 20]. The resulting effect of such a process is the development of a peculiar type of xerosis [11, 21, 27] due to a defect in

corneodesmolysis and desquamation [28-30]. The altered specific enzymes are proteases, particularly serine and cathepsin-like enzymes.

The present study was performed combining colorimetric assessments and xerosis ratings by visual inspection, and by the ULEV and CSSS methods. It shows that skin ashiness is similarly objectivated by assessing the *stratum corneum* texture than by measuring skin colour. The whitish, dull and opaque appearance results from the overall increase in diffuse light scattering and a reduction in Fresnel reflection (optical phenomenon responsible for skin glare) at the skin surface. This optical phenomenon is responsible for the variations in skin glare.

Erythema was not evidenced by measurements of parameter  $a^*$  at the site of skin ashiness. This suggests the absence of clinically-relevant inflammation at the origin of this skin condition.

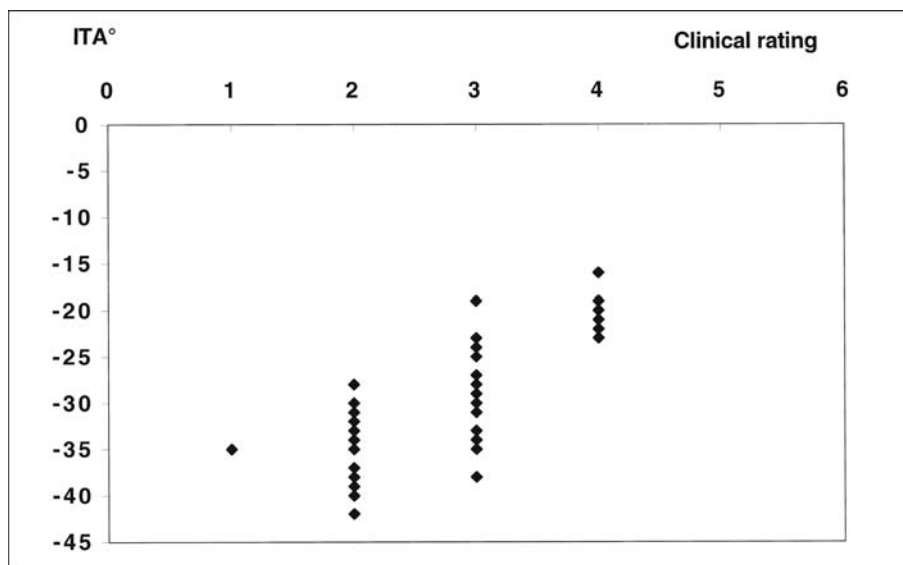


Figure 2. Correlation between  $ITA^\circ$  values and visual rating of skin ashiness of the legs.

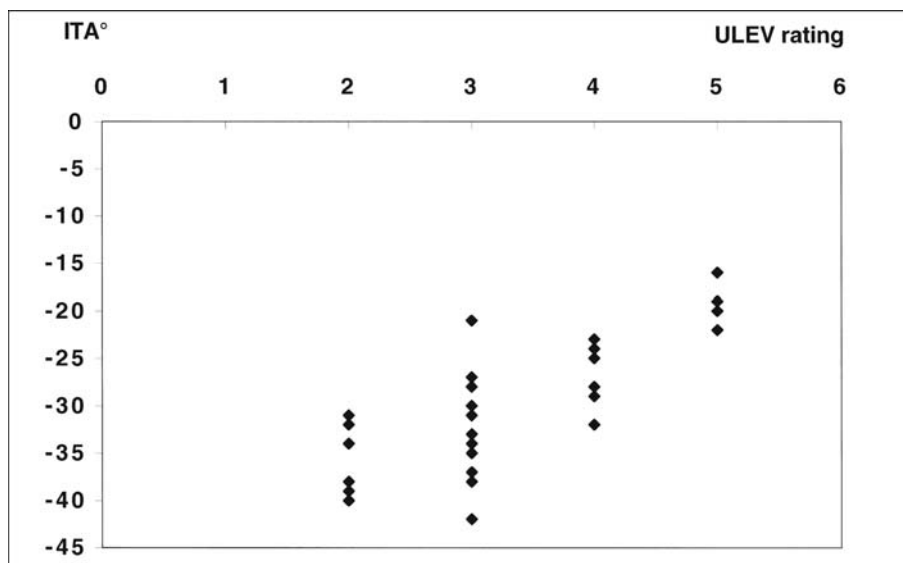


Figure 3. Correlation between  $ITA^\circ$  values and xerosis rating by the ultraviolet light enhanced visualization (ULEV) of skin ashiness of the legs.



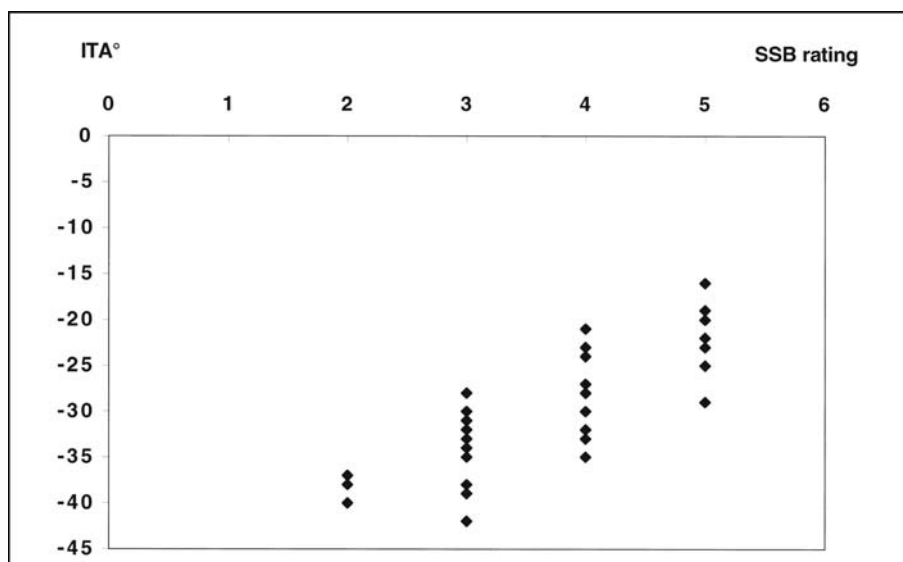


Figure 4. Correlation between ITA° values and xerosis rating on cyanoacrylate skin surface strippings (CSSS) harvested from skin ashiness of the legs.

In conclusion, ashiness as a consequence of skin weathering does not appear to be related to inflammation. Xerosis with a reduction of Fresnel reflexion seems to be the major cause of this common skin condition in individuals with a dark skin complexion. ■

**Acknowledgements.** This work was supported by the "Fonds d'Investissement de la Recherche Scientifique" of the University Hospital of Liège.

## References

- Berardesca E, Maibach H. Ethnic skin: overview of structure and function. *J Am Acad Dermatol* 2003; 48: S139-42.
- Halder RM, Nootheti PK. Ethnic skin disorders overview. *J Am Acad Dermatol* 2003; 48: S143-8.
- Baranda L, Torres-Alvarez B, Cortes-Franco R, Moncada B, Portalez-Perez DP, Gonzalez-Amaro R. Involvement of cell adhesion and activation of molecules in the pathogenesis of erythema dyschromicum perstans (ashy dermatitis). The effect of clofazimine therapy. *Arch dermatol* 1997; 133: 325-9.
- Jang KA, Choi JH, Sung KS, Moon KC, Koh JK. Idiopathic eruptive macular pigmentation: report of 10 cases. *J Am Acad Dermatol* 2001; 44 (suppl): 351-3.
- Santanastasio H, Zhang S, Krishnan S, Velthuisen R, Shah P, Tsaor L. Quantifying skin ashing using cross-polarized imaging. *Skin Res Technol* 2003; 9: 194.
- Piérard GE. EEMCO guidance for the assessment of skin colour. *J Eur Acad Dermatol Venerol* 1998; 10: 1-11.
- Chardon A, Cretois I, Hourseau C. Skin colour typology and sun-tanning pathways. *Int J Cosmet Sci* 1991; 13: 191-201.
- Serup J. EEMCO guidance for the assessment of dry skin (xerosis) and ichthyosis: clinical scoring systems. *Skin Res Technol* 1995; 1: 109-14.
- Piérard GE, Piérard-Franchimont C, Saint-Léger D, Kligman AM. Squamometry: the assessment of xerosis by colorimetry of D-squame adhesive discs. *J Soc Cosmet Chem* 1992; 47: 297-305.
- Piérard-Franchimont C, Petit L, Piérard GE. Skin surface patterns of xerotic legs: the flexural and accretive types. *Int J Cosmet Sci* 2001; 23: 121-6.
- Piérard-Franchimont C, Piérard GE. Beyond a glimpse at seasonal dry skin. A review. *Exog Dermatol* 2002; 1: 3-6.
- Piérard-Franchimont C, Piérard GE. Skin surface strippings in diagnosing and monitoring inflammatory, xerotic and neoplastic diseases. *Ped Dermatol* 1985; 2: 180-4.
- Piérard GE, Piérard-Franchimont C, Piérard GE. Assessment of aging and actinic damages by cyanoacrylate skin surface strippings. *Am J Dermatopathol* 1987; 9: 500-9.
- Piérard GE. EEMCO guidance for the assessment of dry skin (xerosis) and ichthyosis: evaluation by stratum corneum strippings. *Skin Res Technol* 1996; 2: 3-11.
- Gaul LE, Underwood GB. Relation of dew point and barometric pressure to chapping of normal skin. *J Invest Dermatol* 1952; 19: 9-19.
- Rawling AV, Watkinson A, Rogers J, Mayo AM, Hopes J, Scott IR. Abnormalities in stratum corneum structure, lipid composition, and desmosome degradation in soap-induced winter xerosis. *J Soc Cosmet* 1994; 45: 203-20.
- Yoshikawa N, Imokawa G, Akimoto K, Jin K, Higaki Y, Kawashima M. Regional analysis of ceramides within the stratum corneum in relation to seasonal changes. *Dermatology* 1994; 188: 207-14.
- Rogers J, Harding C, Mayo A. Stratum corneum and lipids: The effect of aging and the seasons. *Arch Dermatol Res* 1996; 288: 765-70.
- Denda M, Sato J, Masuda Y, Tsuchiya T, Koyama J, Kuramoto M, Elias PM, Feingold KR. Exposure to a dry environment enhances epidermal permeability barrier functions. *J Invest Dermatol* 1998; 111: 858-63.
- Paquet F, Piérard-Franchimont C, Fumal I, Goffin V, Paye M, Piérard GE. Sensitive skin at menopause: dew point and electrometric properties of the stratum corneum. *Maturitas* 1998; 28: 221-7.
- Berry N, Charneil C, Goujon C, Silvy A, Girard P, Corcuff P, Montastier C. A clinical, biometrological and ultrastructural study of xerotic skin. *Int J Cosmet Sci* 1999; 21: 241-52.
- Black D, Del Pozo A, Lagarde JM, Gall Y. Seasonal variability in the biophysical properties of stratum corneum from different anatomical sites. *Skin Res Technol* 2000; 6: 70-6.
- Watkinson A, Harding C, Moore A, Coan P. Water modulation of stratum corneum chymotryptic enzyme activity and desquamation. *Arch Dermatol Res* 2001; 293: 470-2.
- Kikuchi K, Kobayashi H, Le Fur I, Tschachler E, Tagami H. The winter season affects more severely the facial skin than the forearm skin. Comparative biophysical studies conducted in the same Japanese females in later summer and winter. *Exog Dermatol* 2002; 1: 32-8.

- 25.** Piérard GE. Skin weathering. The face at the interface. *Dermatology*, in press.
- 26.** Piérard GE, Goffin V, Hermanns-Lê T, Piérard-Franchimont C. Corneocyte desquamation. *Int J Mol Med* 2000; 6: 217-21.
- 27.** Piérard GE. What do you mean by dry skin? *Dermatologica* 1989; 179: 1-2.
- 28.** Sato J, Denda M, Nakanishi J, Koyama J. Dry condition affects desquamation of *stratum corneum in vivo*. *J Dermatol Sci* 1998; 18: 163-9.
- 29.** Harding CR, Watkinson A, Scott IR, Rawlings AV. Dry skin, moisturization and corneodesmolysis. *Int J Cosmet Sci* 2000; 22: 21-52.
- 30.** Rawlings AV. Trends in *stratum corneum* research and the management of dry skin conditions. *Int J Cosmet Sci* 2003; 25: 63-95.